

# We are IntechOpen, the world's leading publisher of Open Access books Built by scientists, for scientists

6,900

Open access books available

186,000

International authors and editors

200M

Downloads

Our authors are among the

154

Countries delivered to

TOP 1%

most cited scientists

12.2%

Contributors from top 500 universities



WEB OF SCIENCE™

Selection of our books indexed in the Book Citation Index  
in Web of Science™ Core Collection (BKCI)

Interested in publishing with us?  
Contact [book.department@intechopen.com](mailto:book.department@intechopen.com)

Numbers displayed above are based on latest data collected.  
For more information visit [www.intechopen.com](http://www.intechopen.com)



# Modified Extended Latissimus Dorsi Myocutaneous Flap with Added Vascularised Chest Wall Fat in Immediate Breast Reconstruction After Conservative (Sparing) Mastectomies

Adel Denewer and Omar Farouk

*Surgical Oncology Department, Oncology Center, Mansoura University, Egypt*

## 1. Introduction

Breasts are symbols of femininity rather than feeding young. This physiological fact is eclipsed by the emotional and cultural values placed on the breast which minimizes its basic function and emphasizes femininity and sexuality.

In the light of the above, it is not surprising that many women have concerns about the size, shape and appearance of their breasts ranging from mild satisfaction to severe anxiety and depressive neurosis.

In surgical treatment of the breast cancer, it is obvious that removing a breast leads to grieving for loss while conservative treatment provokes mistrust about that breast with a fear that cancer is still lurking and a mastectomy will prove inevitable. Women with breast cancer are conscious of inevitable death, humiliation, shame, loss of dignity and loss of control (Denewer et al., 2011).

In North Africa, the incidence of breast cancer was similar to that in Europe and slightly less than USA. There was a significant difference as regard younger age incidence by about ten (10) years (Denewer et al., 2010).

The primary goal of breast reconstruction is to recreate form and symmetry by correcting the anatomic defect while preserving patients' safety and health. Breast reconstruction is performed in several stages: restoration of the breast contour, revisions, and reconstruction of the nipple-areola complex. Many options for breast reconstruction exist, which are typically grouped into alloplastic, autologous and a combination of both. The choice of technique is directed by several factors that include the size and shape of the native breast, the location and type of cancer, the quantity and quality of tissues around the breast and at the other donor sites, the patients' demographic information and whether adjuvant therapy is warranted. Breast mound reconstruction can be performed immediately, at the time of mastectomy, or can be delayed for several weeks or months (Hu & Alderman, 2007).

In keeping with the Hippocratic Oath, one of the goals of breast reconstruction is "first do no harm". Reconstruction after mastectomy should not impede the patients' oncologic treatment (i.e., delay administration of chemotherapy or radiation therapy), also it should not add an unacceptable increase in operative morbidity or mortality. Current data indicate that reconstruction is safe and does not delay adjuvant therapy or detection of cancer recurrence (Alderman et al., 2002; Wilson et al., 2004).

Most predictable results in breast reconstruction involve the use of autologous tissue. Many surgeons prefer to use autogenous tissue (i.e., LDF), in part because of greater patient satisfaction with these techniques. In general, it involves the use of the patients' own tissue resulting in a reconstruction that can closely match the opposite breast in size, shape and texture. Depending on the volume of the tissue transferred and the volume of contralateral breast, autologous tissue breast reconstruction sometimes also requires an implant (Patrek & Disa, 2005).

Breast reconstruction is becoming increasingly important due to change in patient expectations and demand. There is growing recognition that immediate reconstruction in appropriately selected women can combine an oncological and aesthetic procedure in one operation with excellent results. Because most breast surgery is performed by general surgeons, most reconstructions were performed as delayed procedures by plastic surgeons. Increasingly, breast surgery is being performed by breast surgeons trained in oncoplastic techniques who can offer immediate reconstruction with both therapeutic and economic benefits (Khoo et al., 1998; Baildam, 2002).

## **2. Immediate autologous breast reconstruction**

Immediate autologous breast reconstruction yields the most durable and natural appearing results with the greatest consistency (Patrek & Disa, 2005).

The aesthetic results from autologous reconstruction are superior to those of implant based reconstruction due to their versatility, their more natural appearance, consistency and durability. Autologous tissue can better withstand radiotherapy.

Although reconstruction with implants can produce good cosmetic outcomes, complications requiring additional surgery occur in 34% of patients over the first 5 years after reconstruction. Problems such as infection, implant exposure, capsular contracture, seroma and rupture or deflation of the implant can occur and can adversely affect the cosmetic outcome and increase the long-term costs by necessitating further surgery and hospitalization (Chevray & Robb, 2007).

Delgado and his co-workers published a study in 2007, whose results showed that the most frequent complications were cutaneous necrosis, some of which was accompanied by seroma. In all the cases that had a seroma, the devices were explanted because of the exposure of the prosthesis (Delgado et al., 2007).

The commonest and least predictable complication of breast implant surgery is capsular contracture in many series. Submuscular placement of silicone gel-filled implants consistently decreases the incidence of significant contracture from 60 to 30%, although this often may be confounded by the effect of preoperative or postoperative irradiation (Salgarello & Farallo, 2005).

Capsular contracture refers to tightening of the implant capsule over time. In mild cases, this causes the reconstructed breast to become more firm and stiff. In moderate cases, capsular contracture can make the reconstructed breast become more round, spherical and rise in position on the chest wall. In severe cases, capsular contracture can cause breast and chest wall pain and restrict shoulder and arm range of motion (Chevray & Robb, 2007).

Autologous Reconstruction can be achieved by:

- i. L.D. with added vascularised fat flap (Denewer & Farouk, 2007; Denewer et al., 2008)
- ii. Myomammary flap from other breast (in huge pendulous breast) (Denewer, 1997; Denewer et al., 2007)
- iii. TRAM flaps; pedicled, free with microvascular, DIEP, SIEP (Hartrampf, 1988).
- iv. Others; superior gluteal artery perforator flap (SGAP) (Allen & Tucker, 1995), the lateral thigh flap (Elliot et al., 1990), The Rubens flap, or deep circumflex iliac soft tissue flap (Tachi & Yamada, 2005).

Surgical treatment of breast cancer has evolved from radical mastectomy with routine removal of the nipple-areolar complex (NAC) to breast conservative therapy with preservation of the breast and NAC. When breast conservation is not appropriate or the patient desires mastectomy for risk reduction, conventional therapy still consists of mastectomy with or without removal of the NAC, followed by reconstruction (Chung & Sacchini, 2008).

### **3. Modified extended latissimus dorsi myocutaneous flap with added vascularised chest wall fat**

#### **3.1 Anatomy of latissimus dorsi muscle**

It is a type V flap according to Mathes and Nahai's classification of muscle vascularisation, which means that it can survive solely on its principal pedicle (Mathes & Nahai, 1982).

The latissimus dorsi, the broadest muscle of the back consists of two triangular shaped muscles with fascial origins from the spinous processes of the lower six thoracic, lumbar and sacral vertebrae, and from the iliac crest. Additionally, there are muscular origins from the anterolateral aspect of the lower four ribs as well as the external oblique and tip of the scapula.

The fibers converge superiolaterally and twist 180° before inserting into the intertubercular groove of the humerus. The muscle, which is largely expendable, functions to extend, adduct and medially rotate the arm.

The lateral part of the muscle is closely associated with the serratus anterior muscle on its deep aspect. The latissimus dorsi muscle has two free borders, (i) an upper border passing from the posterior axillary line to the sixth thoracic spine and (ii) a lateral border demarcating the midaxillary line

#### **3.2 Surgical anatomy of the added vascularised chest wall fat**

The third part of axillary artery contributes in blood supply to lateral chest wall via its largest branch; the subscapular artery, which further gives the thoracodorsal branch. Fat



over serratus anterior muscle is supplied by a small branch of the thoracic part of thoracodorsal artery and in some instances by another branch of the dorsal part.

The technique involves meticulous dissection of the thoracic branch of the thoracodorsal vessels, which supplies the fat and superficial part of the underlying serratus anterior muscle, with transfer of the superficial fibres of the lower three digitations of the serratus anterior muscle to get the benefit of preservation of the blood supply to the overlying fat that dissected and remained attached to latissimus dorsi muscle in continuity (Figures 1&2) at its anterior border (Denewer et al., 2008).

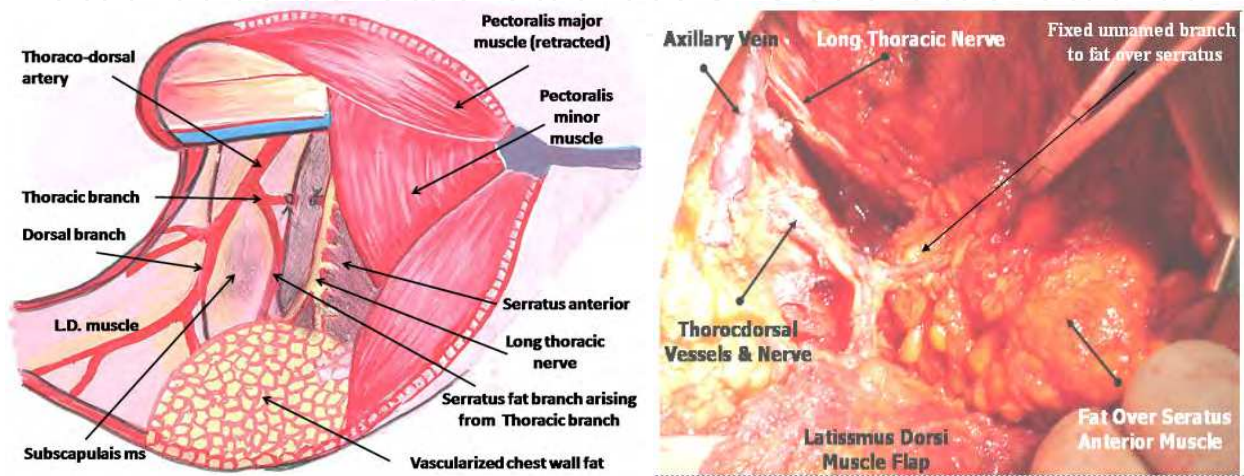


Fig. 1. The vascularized fat over the serratus muscle is supplied constantly by branches from both thoracic branch & dorsal branch which are called serratus branches.

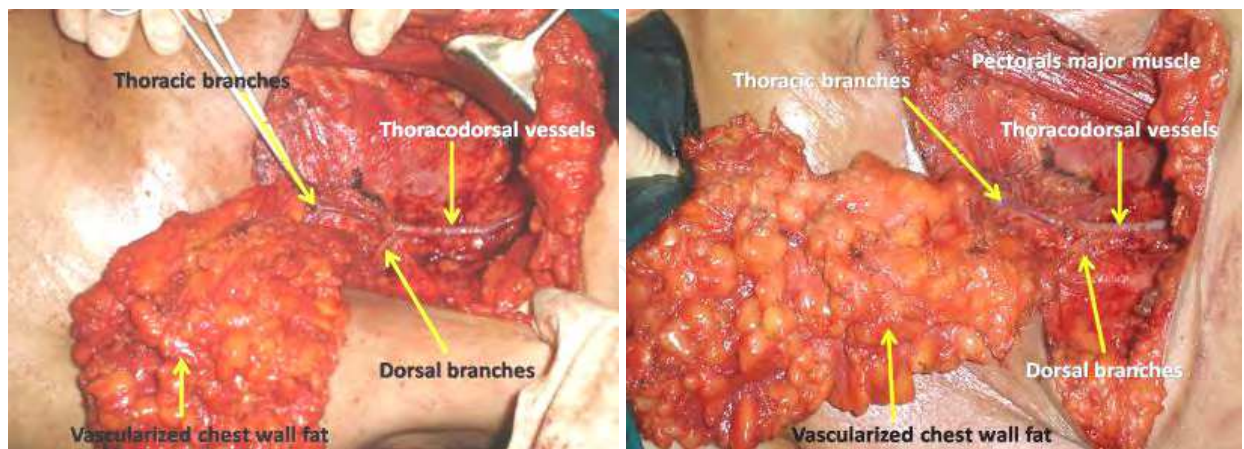


Fig. 2. The vascularised chest wall fat

3.3 The concept of oncological safety of SSM

The development of skin-sparing mastectomy (SSM) with immediate reconstruction achieved the goal of radical excision of the tumor with improved cosmetic outcome. In addition, the overall survival and local recurrence rates were similar to cases of modified radical mastectomy (Carlson et al, 2001; Denewer & Farouk, 2007).

The main oncological concern in both SSM and non-skin sparing mastectomy (NSSM) relates to the possibility of leaving residual tumor within the skin envelope which may manifest later as local recurrence (LR). Indeed, Ho et al. performed histological examinations of the skin and subcutaneous tissue of 30 NSSM specimens and found that the skin flaps (excluding the NAC) were involved in 23% (7 of 30) of cases. In five cases, the skin involved was situated directly over the tumor (Ho et al, 2003). Importantly, long-term follow-up of selected patients has not shown a difference in local recurrence rates after skin-sparing mastectomy versus traditional mastectomy (Hidalgo et al, 1998).

Unfortunately, many of the studies addressing the issue of LR following SSM have not followed-up patients long enough for it to be seen. In addition, there is a significant lack of prospective data and nearly all studies are from single institutions (Cunnick & Mokbel, 2006).

### 3.4 Technique

Skin incisions are generally conservative and in the most favourable cases a small circular incision around the areola will suffice with preservation of the inframammary fold and limited dissection of the skin flaps beyond the breast tissue. Either formal axillary dissection or sentinel node biopsy can be performed at the same time through either the areolar incision, a lateral extension thereof or a separate axillary incision (Nair et al., 2010).

#### 3.4.1 Technical aspects of SSM

Peri-areolar incision (5 mm away from areola) is designed either alone (Figure 3) or with lateral extension rising towards the axilla (tennis racket incision) in order to facilitate mastectomy and axillary dissection (Figure 4). Inferolateral incision may be utilized for its higher cosmetic result (Figure 5).

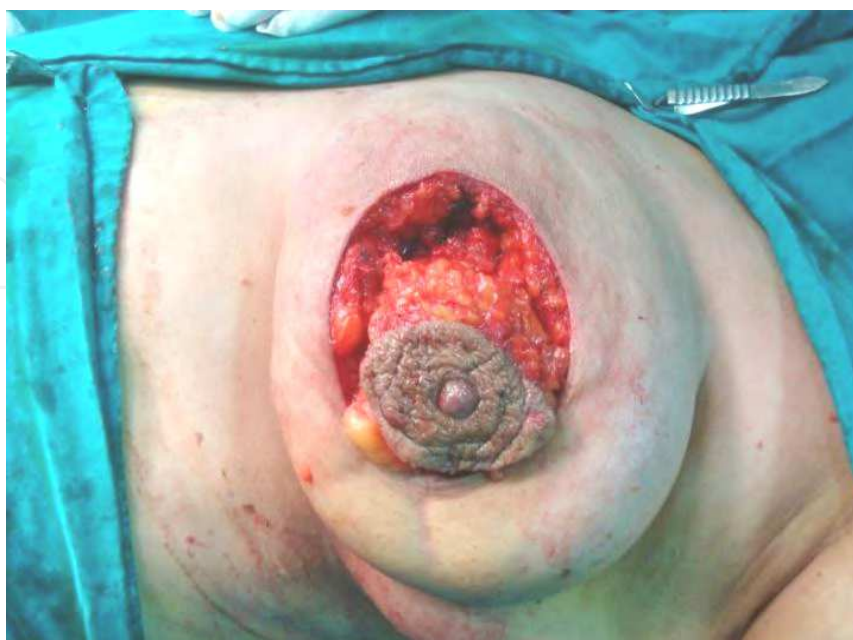

Fig. 3. Peri-aereolar incision in SSM.



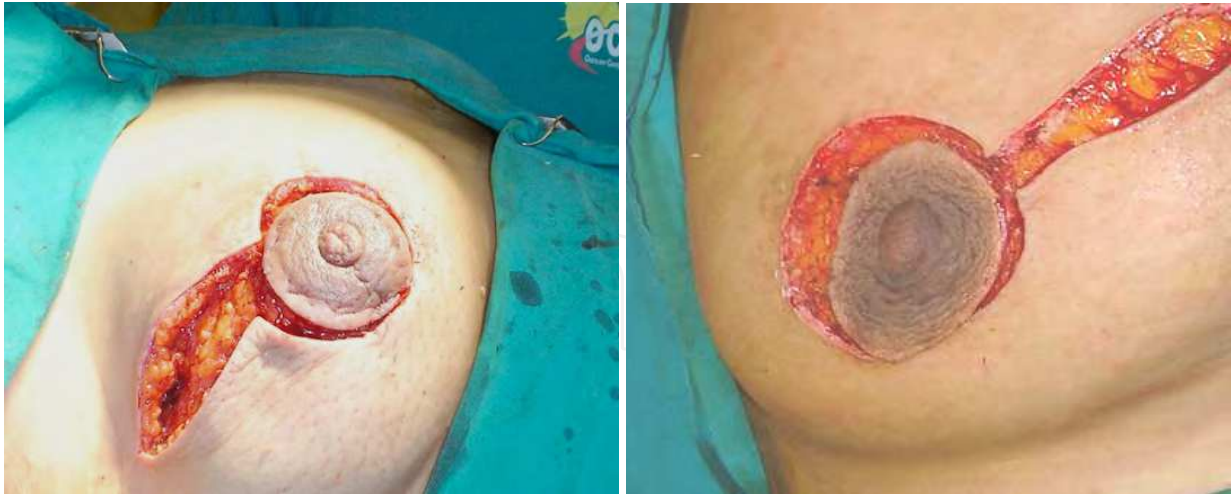

Fig. 4. Peri-areolar incision in SSM, with lateral extension rising towards the axilla (tennis racket incision). (Denewer & Farouk, 2007).

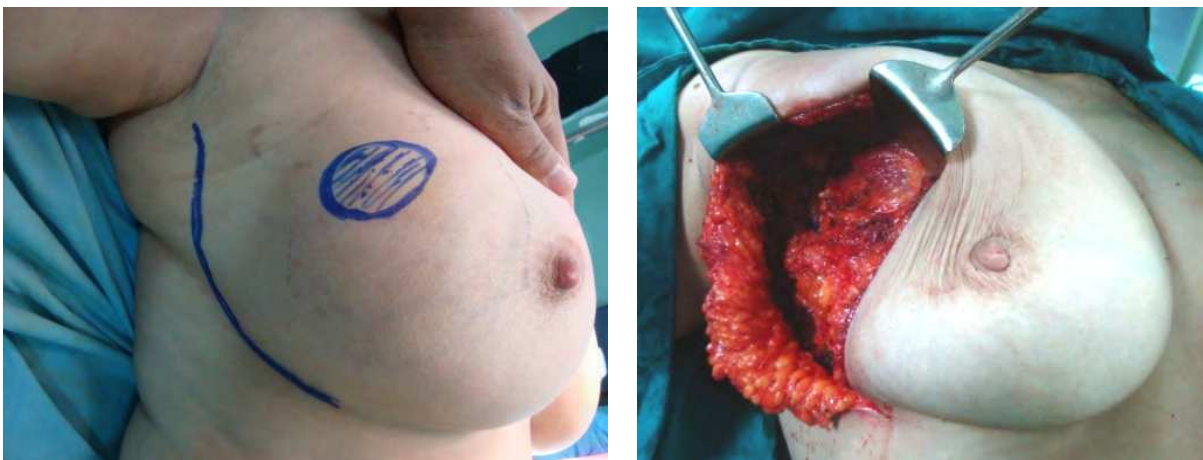

Fig. 5. Infero-lateral incision.

The native skin envelope flaps are dissected and elevated, which should be meticulous in the fatty layer between the dermis and the glandular tissue so as not to jeopardize skin vascularity (Figure 6).

The dissection plane of SSM advances between the breast parenchyma and the subcutaneous fat. Scissors are conventionally used for the sharp dissection and bleeding vessels are typically cauterized using electric bipolar diathermy. This element of the procedure is of vital importance in avoiding later SSM skin-flap complications, given that a solid hemostasis is essential. However, thermal injury to the skin needs to be avoided. In addition, blood supply to the skin should not be compromised, and the perforating arteries should be preserved whenever possible (Meretoja et al., 2008).

To maximize a good cosmetic outcome, the dissection of the lower skin flap should not continue beyond the inframammary fold (Figure 7), so that the final aesthetic shape of the immediate breast reconstruction (IBR) will be very similar to the original breast. The breast tissue is then removed off the pectoralis major muscle as in a (NSM).

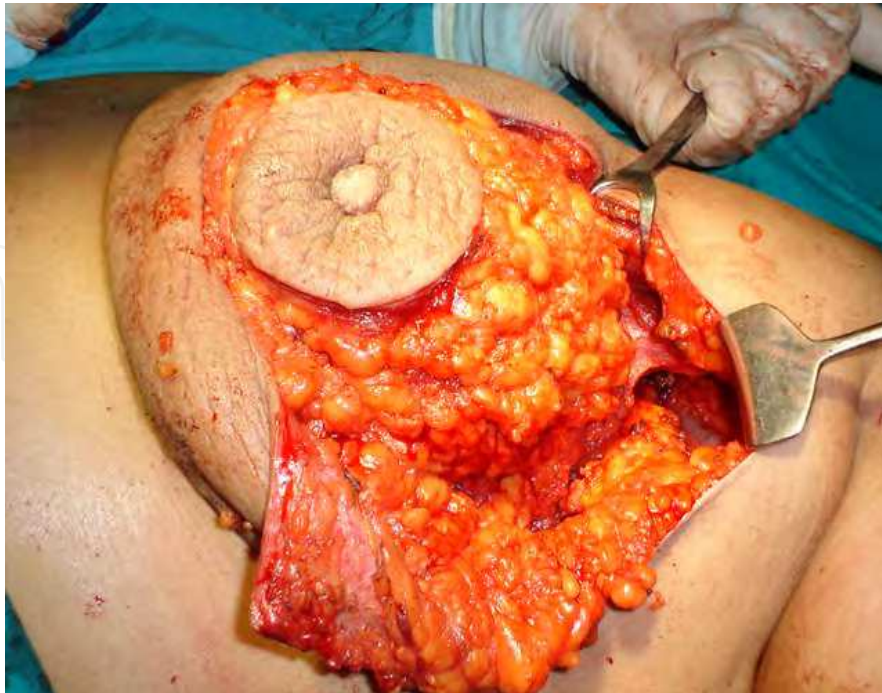

Fig. 6. The native skin envelope flaps are dissected and elevated (Denewer et al., 2008).

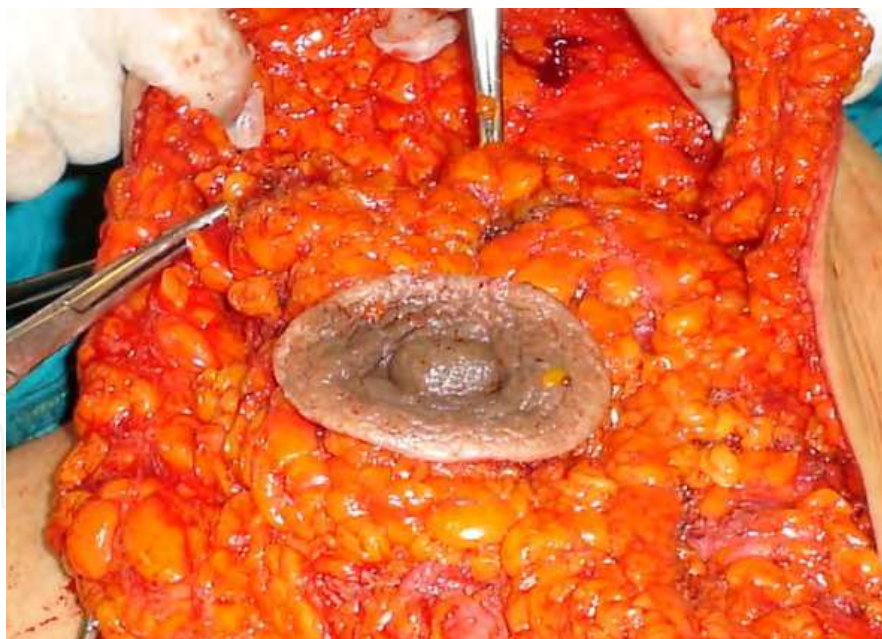

Fig. 7. The dissection of the lower skin flap, with preservation of the inframammary fold (Denewer et al., 2008).

Axillary dissection (level I and II) is then performed through the same incision, with preservation of thoracodorsal vessels and both pectoralis major and minor (Figure 8). Finally the whole breast parenchyma, nipple, areola, and axillary lymph nodes are removed completely as a whole specimen (Figure 9) (Denewer et al., 2008).



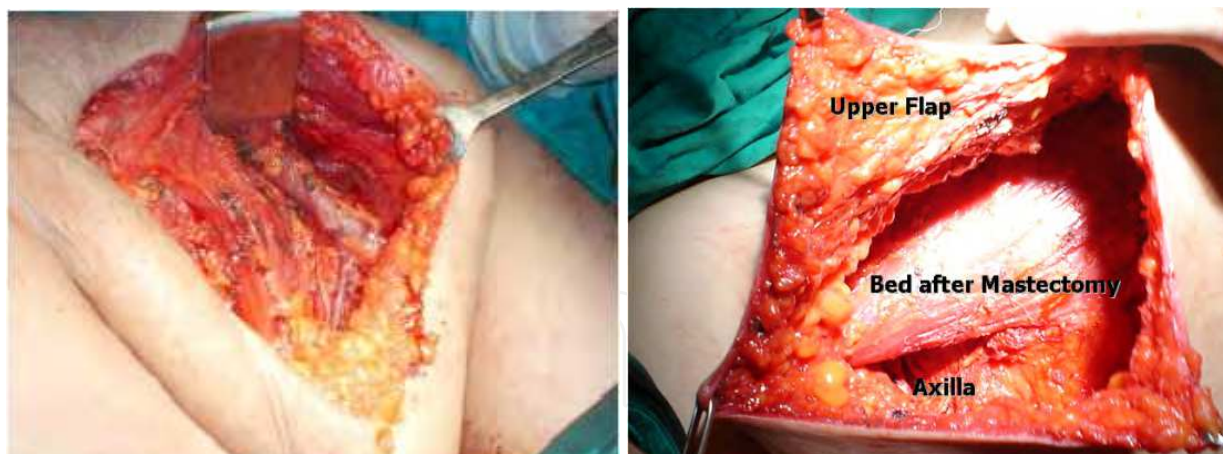


Fig. 8. The breast bed after complete SSM & The axilla after complete axillary dissection (level I and II).

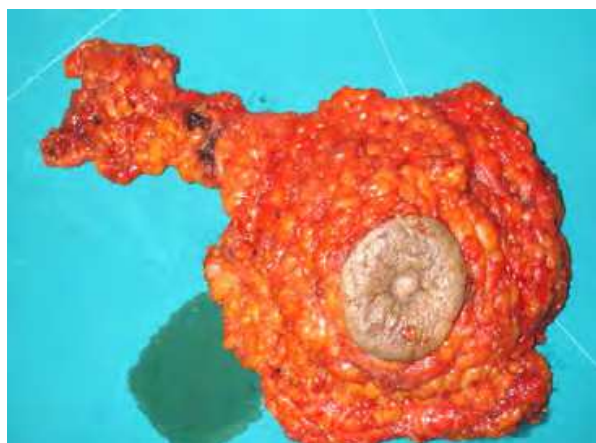

Fig. 9. Specimen appearance after complete resection of the whole breast parenchymal tissue and NAC, with level I and II axillary dissection (in SSM).

### 3.4.2 Technical aspects of L.D. flap

A transverse skin puddle incision with its long axis centered over the seventh rib extending from the posterior axillary line to the parascapular line is marked. The LD muscle with overlying fat is elevated and transected near the iliac crest inferiorly and tendon of insertion is separated from the humerus superiorly (Figure 10). After complete dissection of LD muscle, the back incision is closed (Figure 11).

Where autologous tissue has been imported as part of a myocutaneous flap, a disc of skin can be used from the donor site to replace the defect resulting from excision of the nipple-areola complex. Under these circumstances the skin is closed in a circumferential fashion to yield a scar of dimensions similar to the contralateral areola.

After dissection of the thoracodorsal vessels; the upper branch of the thoracic artery is cut and ligated in order to protect the long thoracic nerve, while the lower branches are preserved to supply the chest wall fat over the serratus anterior muscle, in addition to preservation of the terminal branches of the dorsal artery that supply this fat which remains attached to the anterior border of L.D.

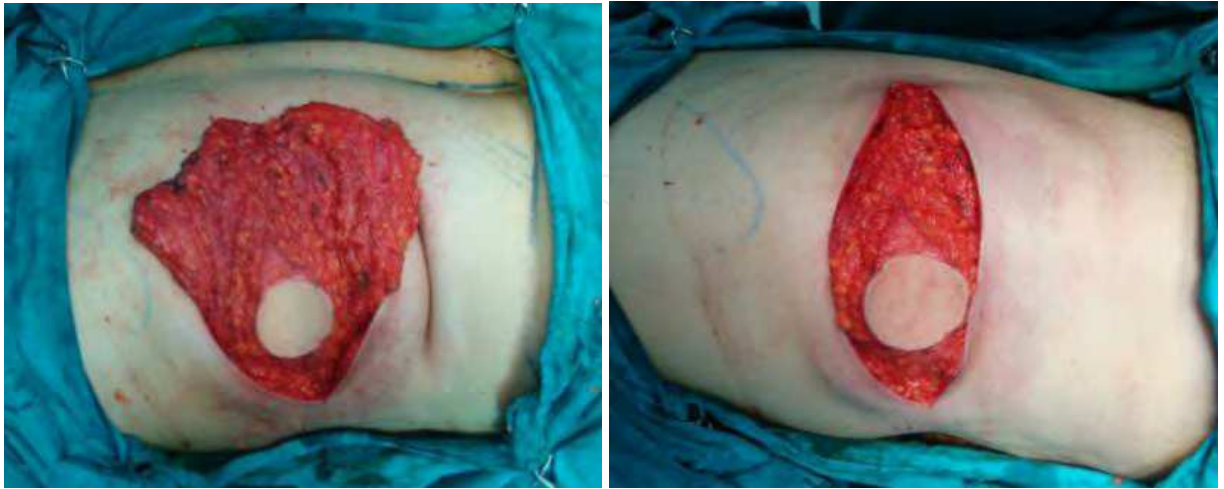

Fig. 10. Dissection of the LD flap.

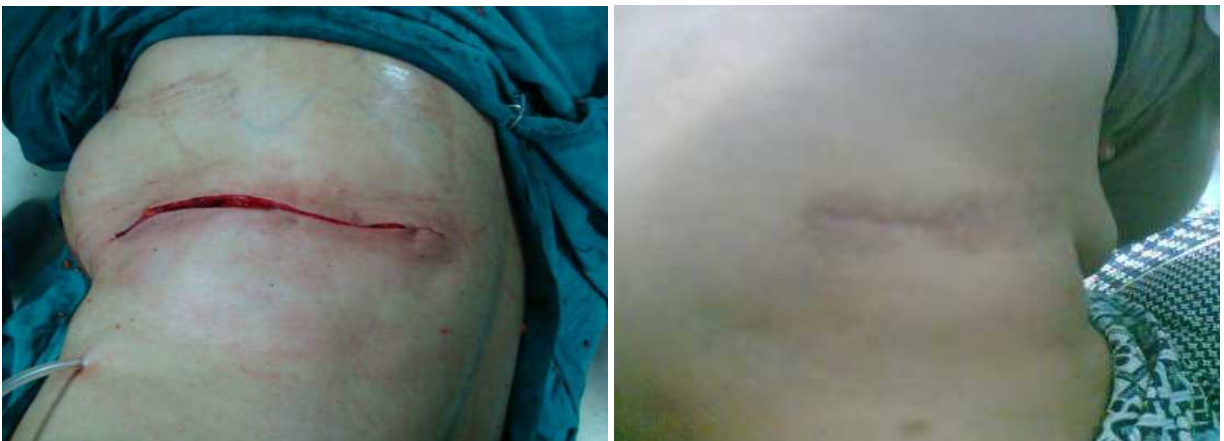

Fig. 11. Closure of the back wound.

This amount of fat is harvested from the chest wall and now is attached to the upper-anterior border of L.D. the vascularisation of this fat is entailed through the terminal branches of both thoracic & dorsal arteries (serratus branches).

Now the modified extended LD myocutaneous flap together with the added vascularized chest wall fat are tunneled through the axilla to be transposed to the breast bed under the skin envelop (Figure 12) (Denewer et al., 2008).

The vascularized fat is fixed to the pectoralis major muscle, forming the first layer of the reconstructed breast (Figure 12c), and then the flap is folded on itself to form the second layer of the desired reconstructed mound, fixed with a few absorbable sutures, and then the skin envelop is closed (Figure 13) to yield the final view of the reconstructed breast (Figures 14 - 16).



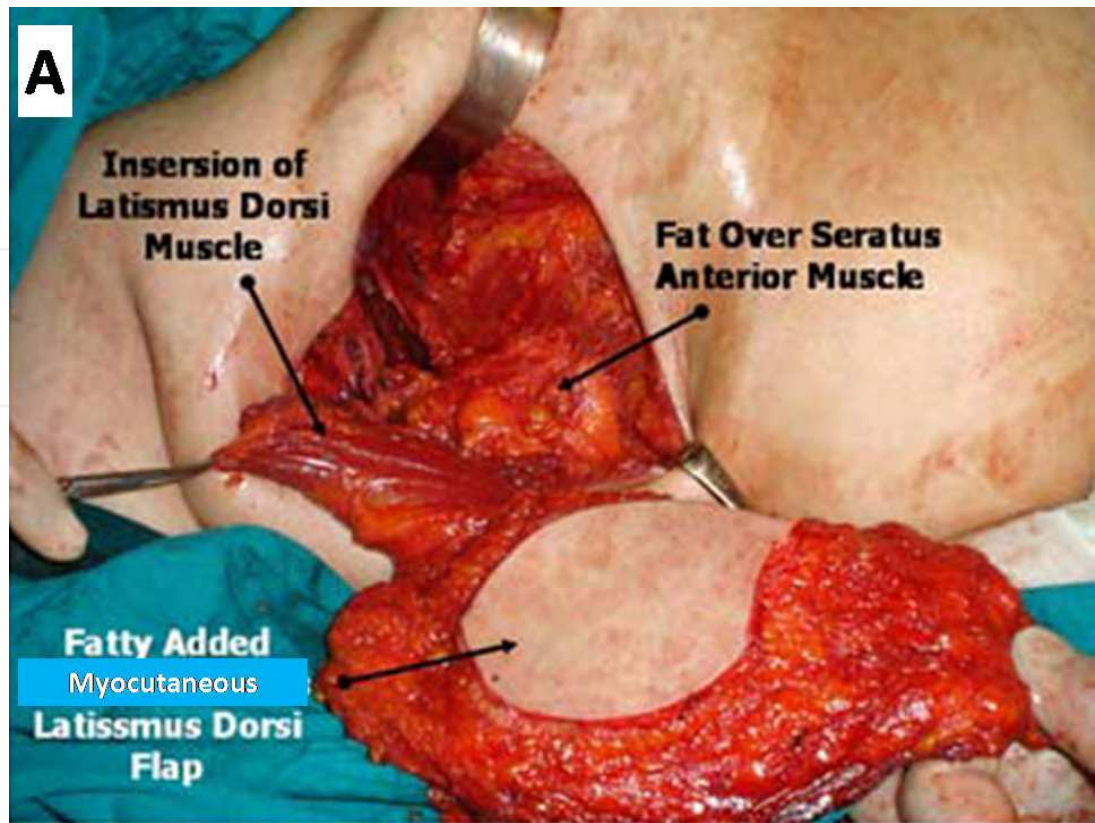


Fig. 12 (A). Dorsal view of the flap after its dissection and transposition through the axilla.

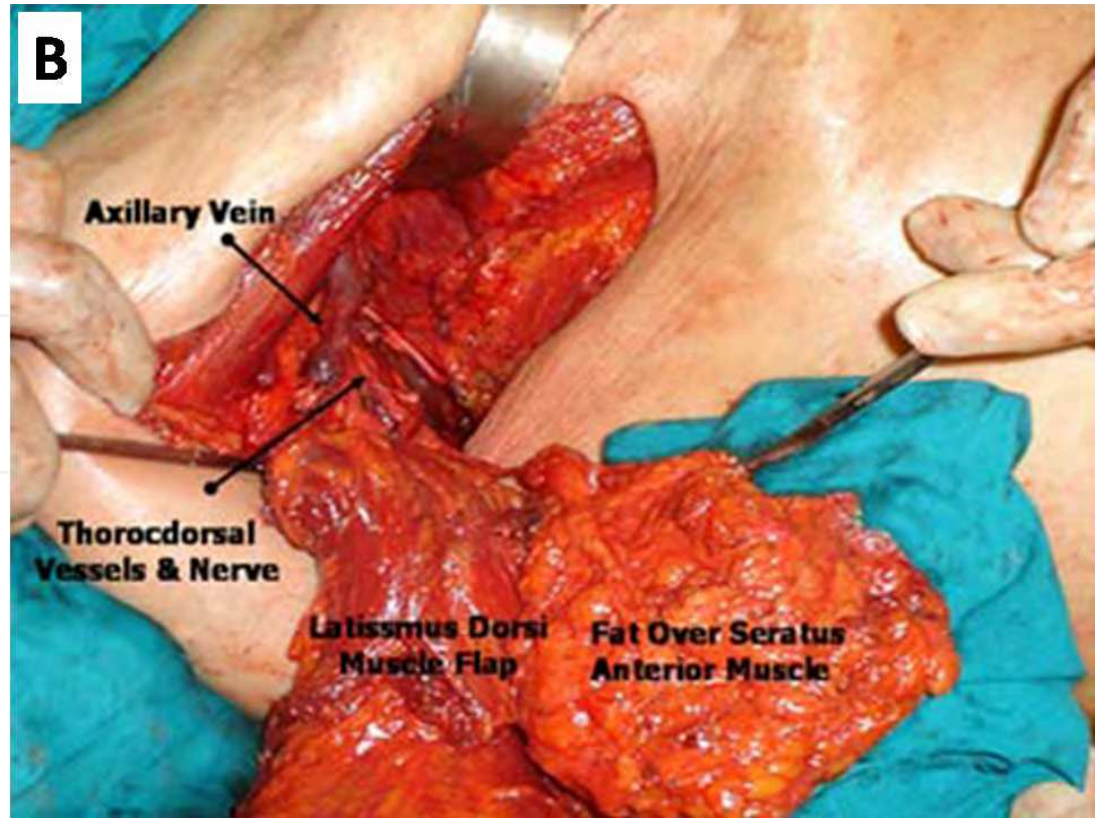


Fig. 12. (B) Ventral view of the flap with the attached fat over seratus anterior muscle.



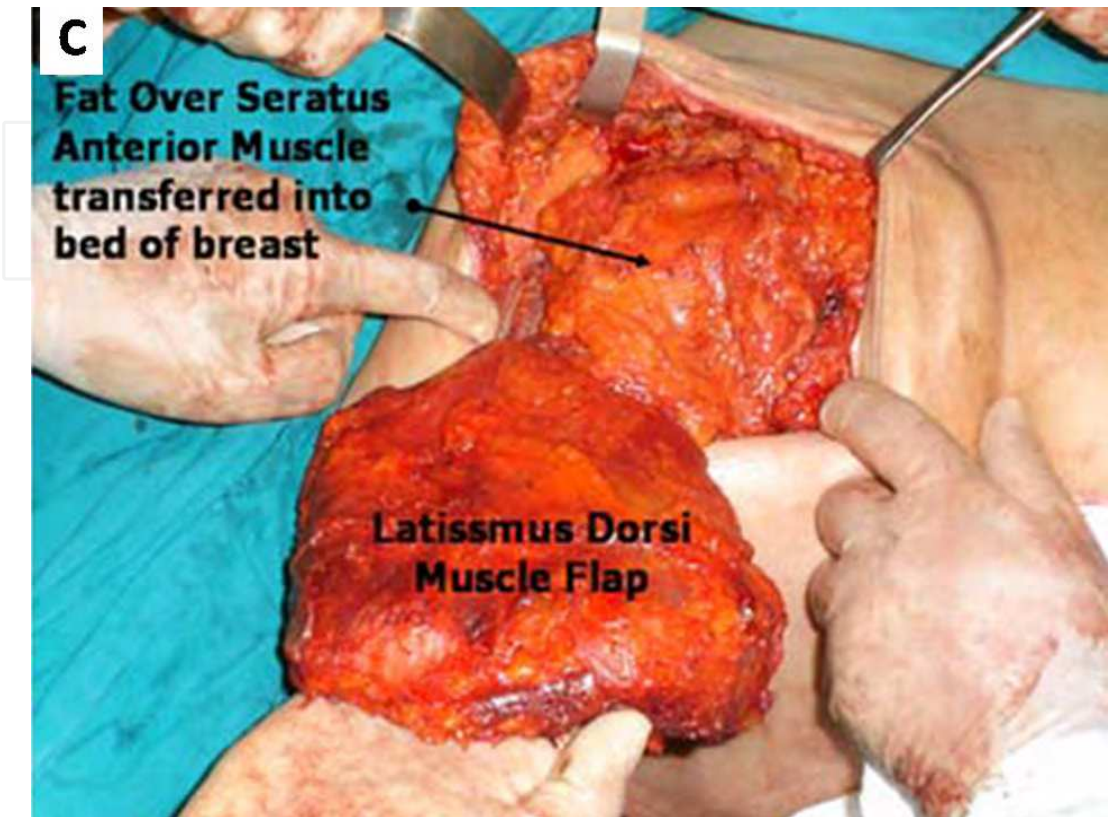


Fig. 12 (C). Fixation of the added vascularized fat to the pectoralis major muscle forming the first layer of the reconstructed breast (Denewer & Farouk, 2007).

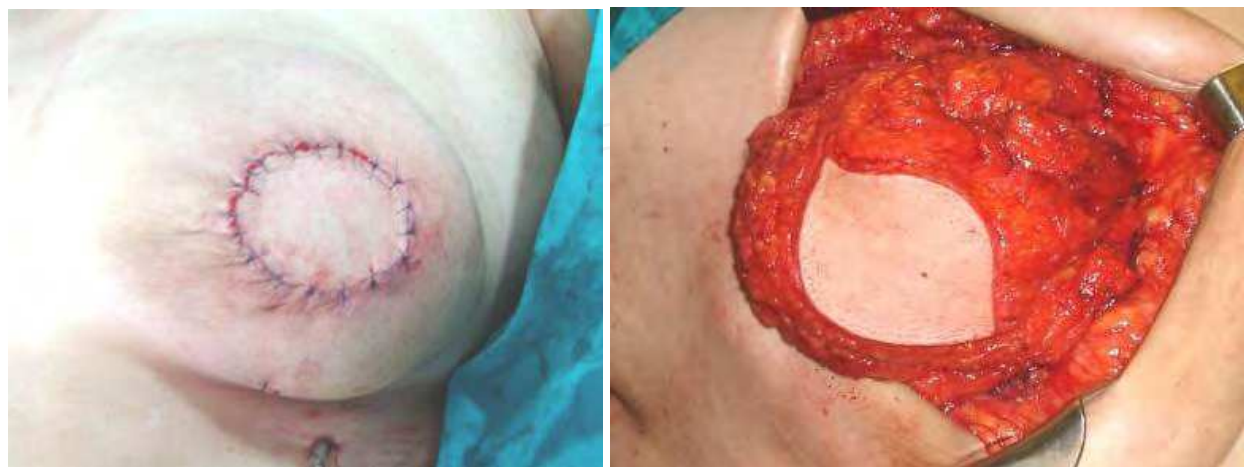

Fig. 13. The remaining of the flap is folded to complete the breast mound with closure of the wounds.

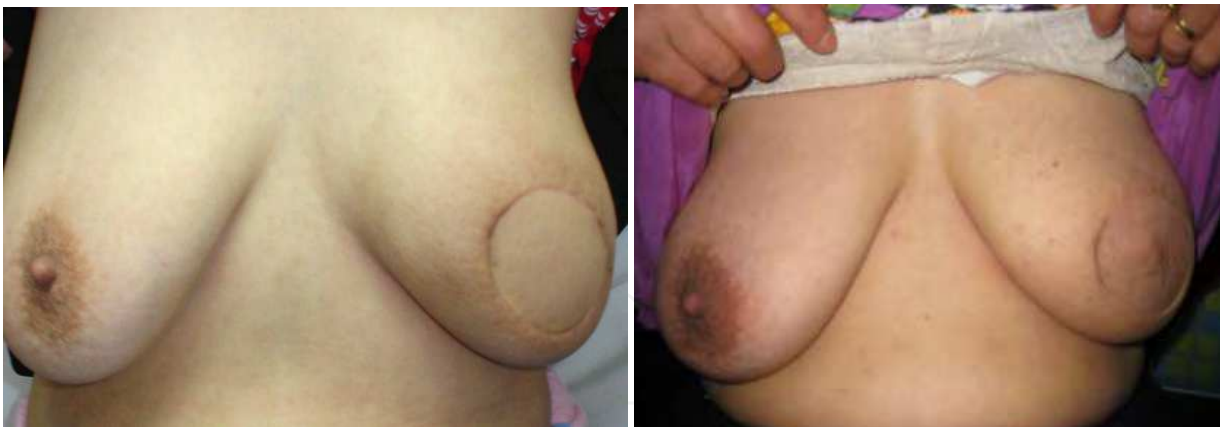

Fig. 14. SSM with modified latissimus dorsi vascularized fat-added flap after 6 months.

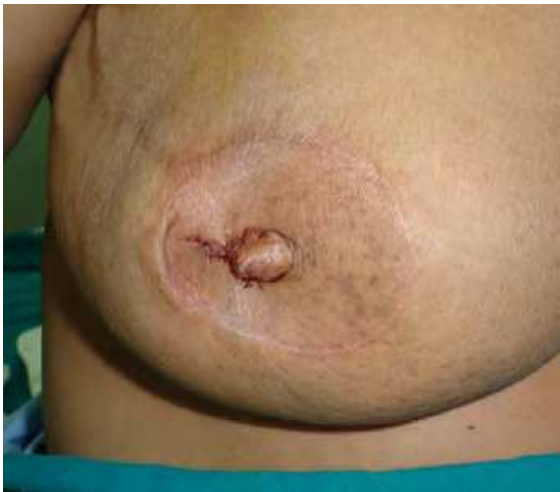

Fig. 15. Nipple reconstruction & first stage tattooing.

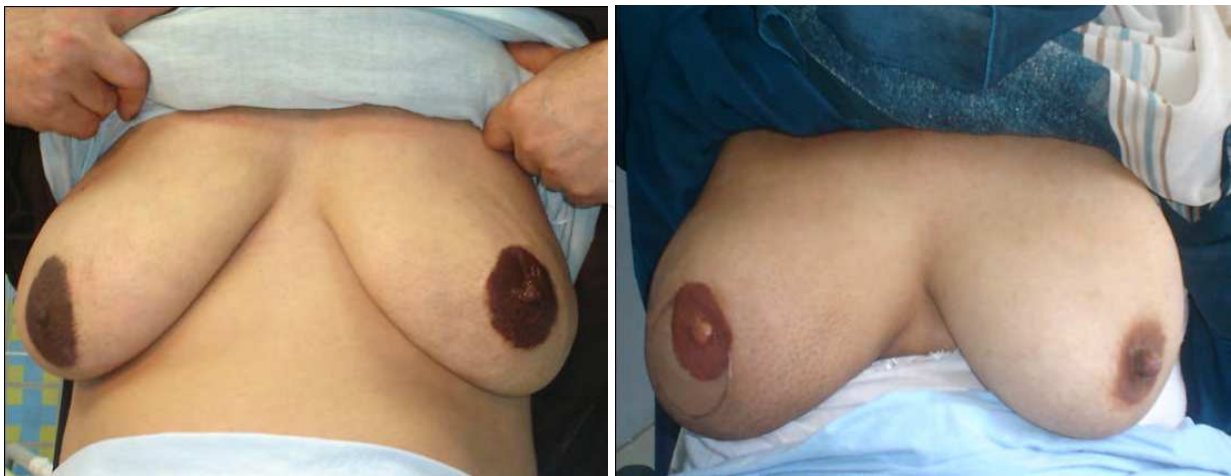

Fig. 16. Final appearance of areola tattooing after nipple reconstruction.

**3.4.3 Technical aspects of NSM**

Rising interest in improved cosmesis has led to the introduction of Nipple sparing mastectomy as potential alternatives to mastectomy (Chung & Sacchini, 2008). Nipple

sparing mastectomy combines skin-sparing mastectomy with preservation of the nipple-areolar complex (NAC) and intraoperative pathologic assessment of the nipple core. This approach preserves the dermis and epidermis of the NAC but removes major ducts from within the nipple (Sookhan et al., 2008).

NSM may be performed according to total mastectomy indications if an intraoperative frozen section (and the corresponding HE histopathology) of the tissue next to the nipple-areola skin is free of tumor. The remaining contraindications for NSM are: extensive tumor involvement of the skin, inflammatory breast cancer, and a clinically suspicious nipple.

In a study, representing OCMU experience, Denewer and Farouk concluded that nipple-sparing mastectomy provides a good cosmetic result with a low risk of postoperative complications. The additional volume obtained by using a new modification of latissimus dorsi fat-added flap allows single-stage NSM with immediate autologous breast reconstruction without implant insertion and without contralateral operations in medium and large-sized breasts (Denewer & Farouk, 2007).

A claw like incision encompassing the lateral half circle of NAC with lateral extension rising towards the axilla is performed. The incision did not involve the NAC in any breast (Figure 17). Inferolateral incision may be utilized for its higher cosmetic result (Figure 5).

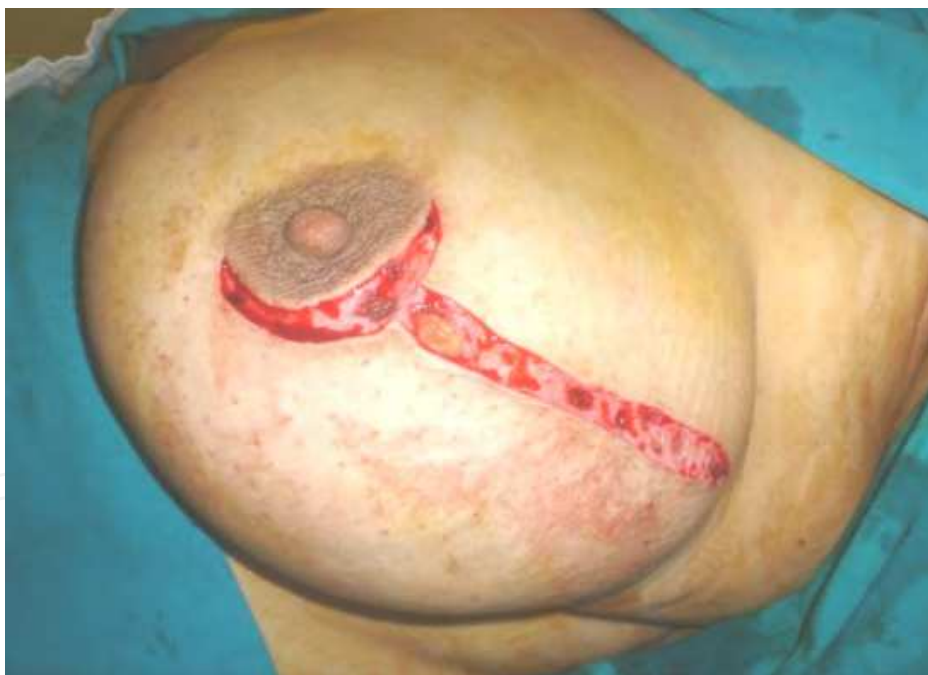

Fig. 17. Claw like incision with lateral extension rising towards the axilla (Denewer & Farouk, 2007).

The NAC is dissected and elevated. At least 3-mm thick nipple-areola flap should remain (so as not to jeopardize its vascularity). An intraoperative frozen section analysis (FSA) of both the undersurface of the nipple itself and the en face retroareolar margin of the resected breast mound is obtained to verify the absence of neoplasia or atypia. The remaining steps of dissection, reconstruction & follow-up are the same as performed in SSM (Figures 18 - 22).



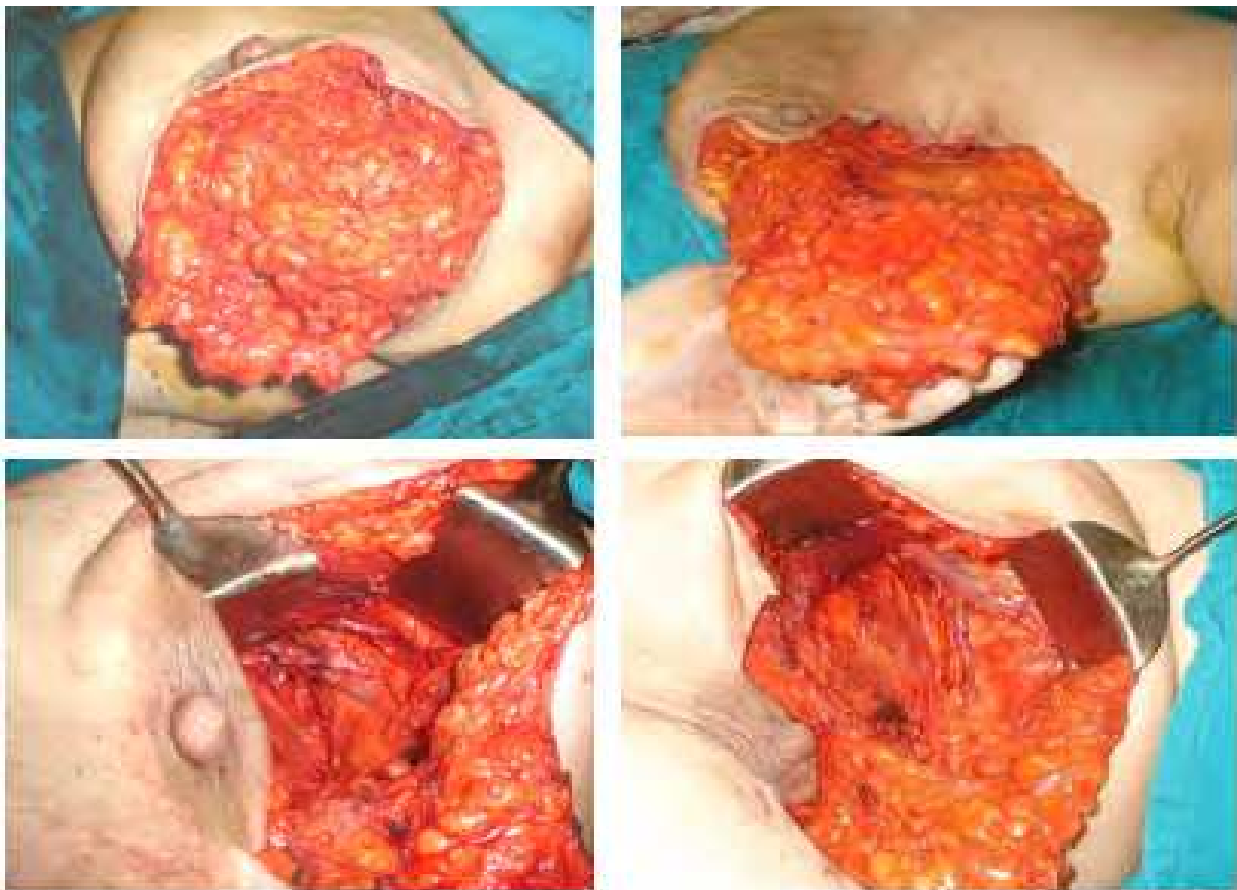


Fig. 18. Standard NSM with level I and II axillary dissection, with preservation of NAC.

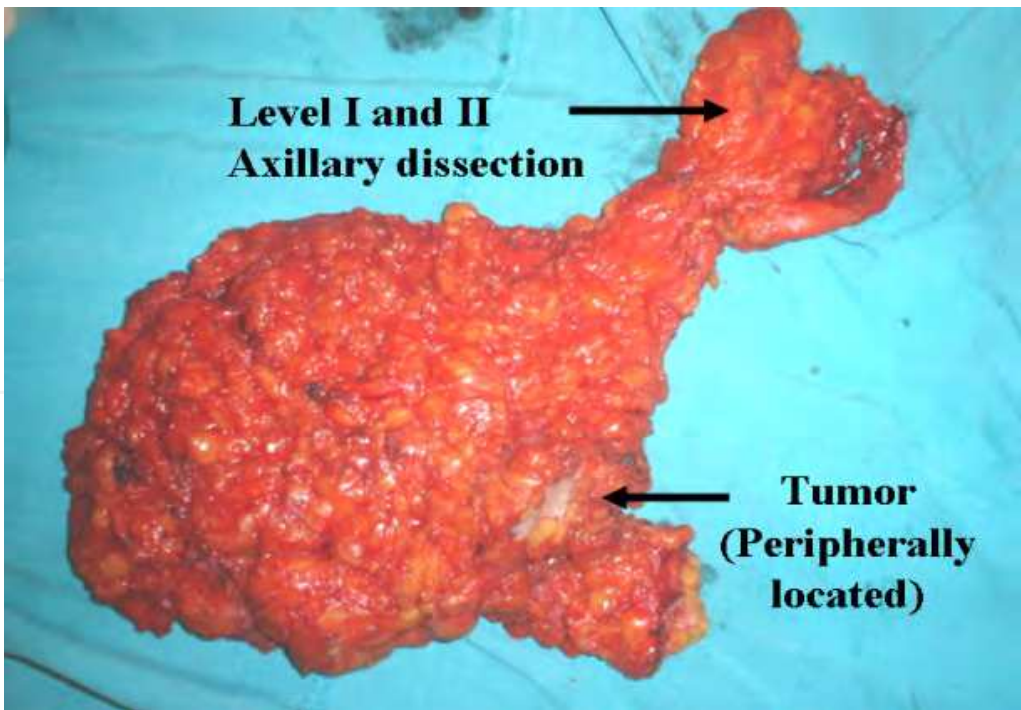


Fig. 19. Gross specimen appearance after complete resection of the whole breast parenchymal tissue with level I and II axillary dissection (in NSM).

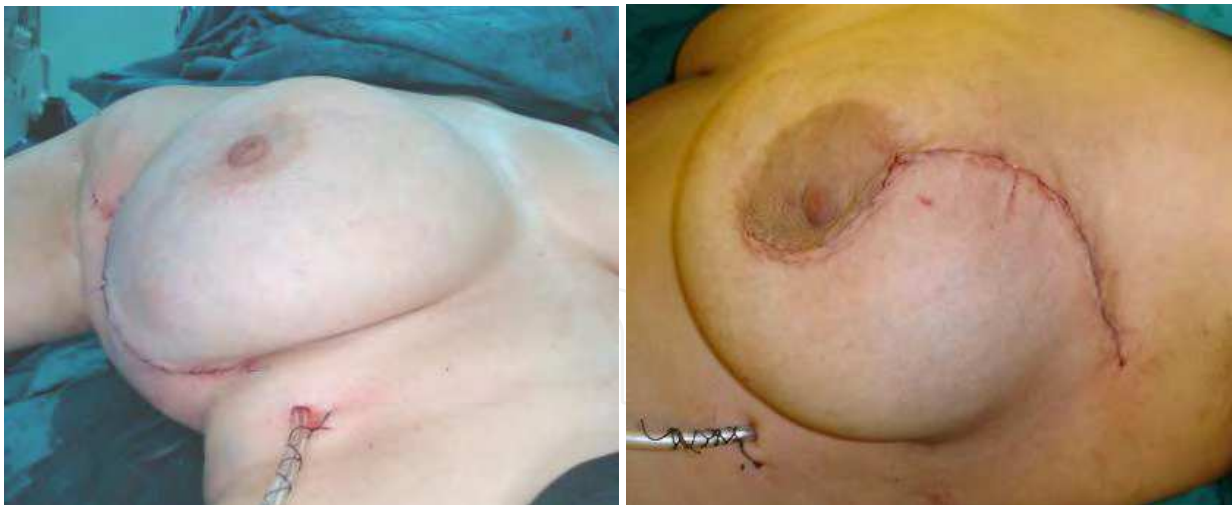

Fig. 20. Single-stage NSM with modified latissimus dorsi vascularized fat-added flap

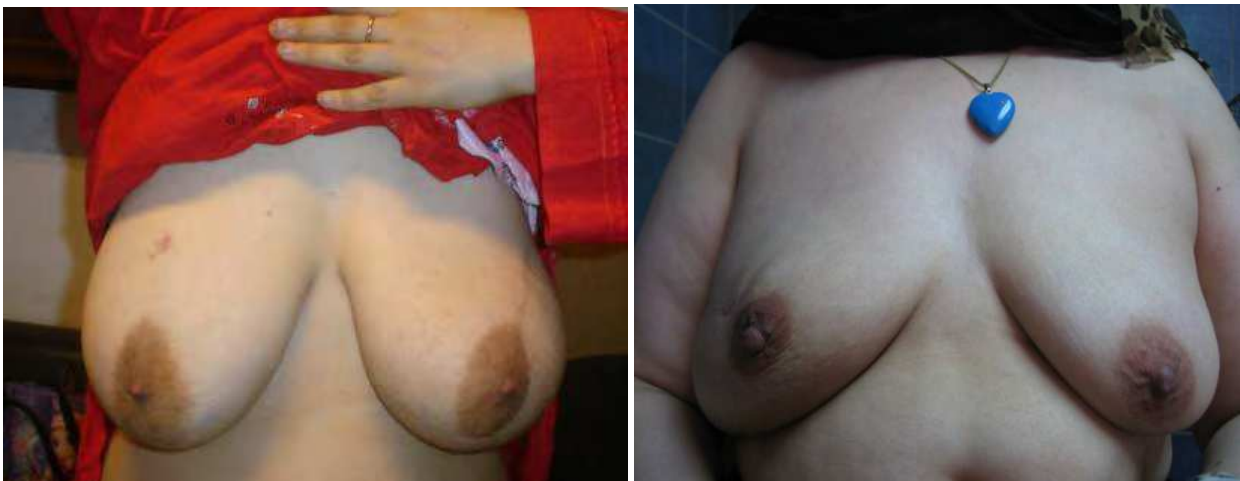

Fig. 21. NSM with modified latissimus dorsi vascularized fat-added flap after 6 months

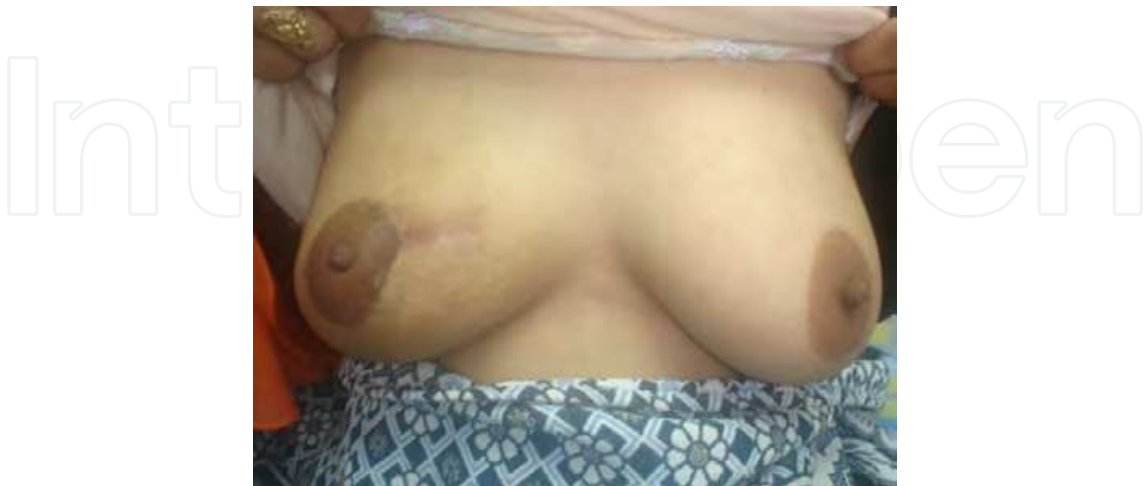

Fig. 22. Another NSM with modified latissimus dorsi vascularized fat-added flap after 5 months in lady with previous unplanned resected tumor in the upper inner quadrant of the right breast.

### 3.5 Oncological safety of nipple and areola sparing mastectomy

NSM appears to be oncologically safe for appropriately selected patients, although additional long-term follow-up is needed, and these patients should be followed with special surveillance following NSM (Benediktsson & Perbeck, 2008). However, 5 years follow up in our series proved to be oncologically safe. In this period of follow up, the rate of local recurrence is 3.8% & the distant metastasis is 3.2%.

It was found that nipple and areolar invasion with malignancy is a rare event in the presence of an early peripherally located tumor; with a clinically normal NAC, this incidence dropped to 1.2 % in peripherally located tumor. Skin & nipple sparing mastectomy is technically feasible in spite of the relatively large size of the breast, with low morbidity & very satisfactory cosmetic results (Stance et al., 2003; Crowe et al., 2004)

When the malignant involvement of the areola versus nipple was analyzed separately, areola involvement was detected in <1% of patients & only in those with central/retroareolar/diffuse invasive carcinomas, large (>5) tumors & multiple positive axillary lymph nodes. No patient with stage 0, I, or II breast carcinoma had areolar involvement. Only patients with stage III had areolar involvement. All patients with areolar involvement also had involvement of nipple (Simmons et al, 2002)

### 3.6 Current status & overall views

Immediate reconstruction does not delay the administration of adjuvant radiotherapy or chemotherapy (Yule et al, 1996). Significant additional morbidity with delay of chemotherapy has not been noted with either breast implants or autogenous tissue (Hidalgo et al, 1998). The overall complication rate of RT following autologous breast reconstruction ranges from 5% to 16%. Following breast reconstruction using the transverse rectus abdominis myocutaneous (TRAM) flap, the most common complications of RT include fat necrosis (16%) and radiation fibrosis (11%), which may cause shrinkage and deformation of the reconstructed breast (Patani et al., 2008).

In our series; five hundred & seventy patients of stage I to III breast carcinoma have autologous breast reconstruction. Age ranges from 23 to 53 years (median = 40.5) have modified extended LDF 47% had SSM and the remaining had NSM. Subjective patient satisfaction was excellent in 71%, good in 20%, fair in 7% & poor in 2% of cases. Bilateral size & shape symmetry are excellent in 56%, good in 26%, fair in 12% & poor in 6% patient. The overall RT-related complications are 9 %, the most common complications are skin burns (5%) & fat necrosis (4%). Patients are followed for mean follow up of 75.5 months (2-96).

Several studies with extended follow up have corroborated the earlier findings .In a 15-year retrospective series of women with stage 0-2 IBC, 225 patients undergoing SSM and IBR were compared to 1022 patients treated by conventional mastectomy .after an average follow -up of 49 months, there was found to be no significance difference in LR (Greenway et al., 2005).

The overall survival and local recurrence rates were similar to cases of modified radical mastectomy (Denewer & Farouk, 2007).



4. Comparison of extended LDF with added vascularized chest wall fat after S.S.M. & N.S.M. versus myocutaneous flap from the contralateral breast versus therapeutic mammoplasty in the management of breast cancer in huge breast

The initial results in three hundreds of huge breast cancer management:

1. Extended LDF with added vascularized chest wall fat.
2. Myomammary flap from other breast.
3. Therapeutic reduction mammoplasty.

The oncologic outcome of extended LDF with added vascularized chest wall fat in the reconstruction of the huge breast (Figure 29 & 30) was superior to myomammary flap (Figures 23 & 24) with near equal oncologic outcome. NSM is better cosmetically than SSM, as there is no need for NAC reconstruction, moreover in good selected cases there is no difference in oncologic safety.

In special situation in management of huge breast cancer; the therapeutic reduction mammoplasty is employed with better outcome than conventional conservative breast surgery as the safety margin which in the first is wider (5-10 cm) and more confidential than the conventional conservative breast surgery (CBS), the aesthetic outcome is better than CBS (Figures 25 - 28) but the operative time and hospital stay are longer than CBS. In comparison to SSM and NSM which are aesthetically near equal to therapeutic mammoplasty, however the oncologic outcome is better than therapeutic mammoplasty. Table (1) summarize the main surgical characteristics of each technique.

Method	Average operative time	Oncologic outcome	Aesthetic outcome	Feasibility of operative technique	Contralateral Surgery
L.D. with vascularized fat	3 hours	++++ (As M.R.M.)	++++	+++	- -
Myomammary Flap	2. 5 hours	++++ (As M.R.M.)	++	+	++++
Therapeutic reduction mammoplasty	3 hours	++  (Less than M.R.M. & better than CBS.	++++	++	++++

Table 1. Comparison of the three methods in immediate reconstruction of huge breast.

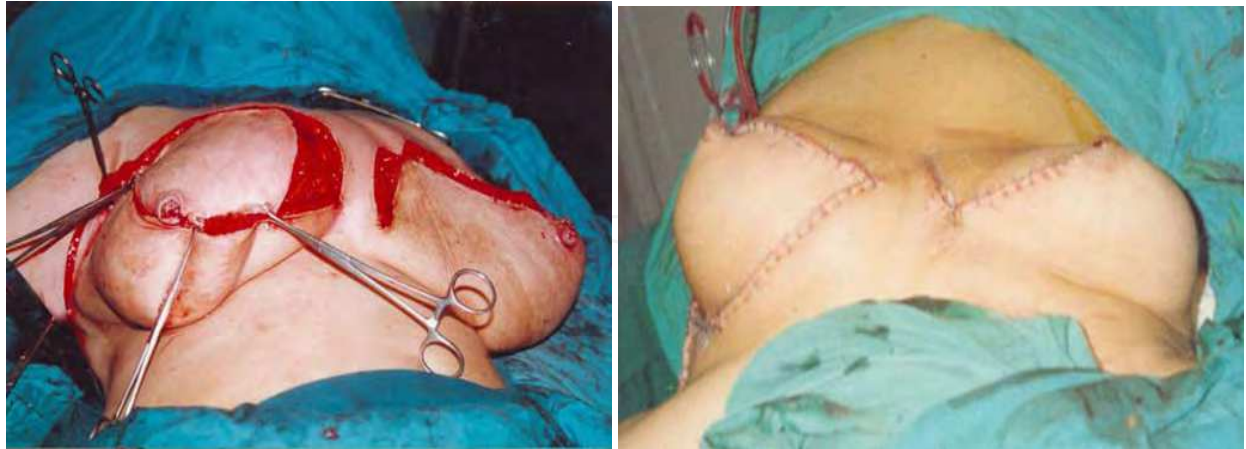

Fig. 23. Operative views of myomammry flap.

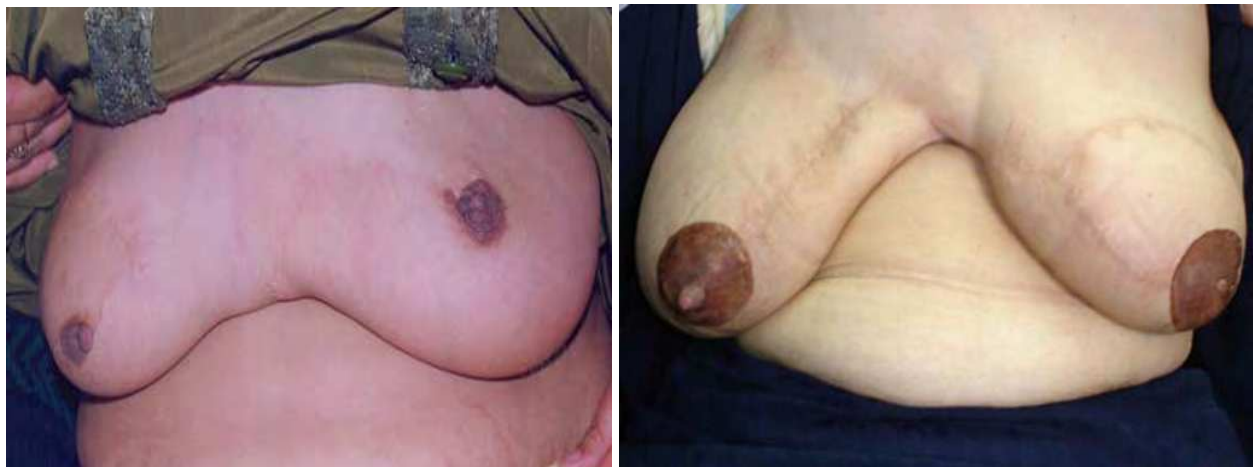

Fig. 24. Post-operative view of patients with myomammry flap reconstruction. Right photo shows bilateral temporary symmetrical tattooing.

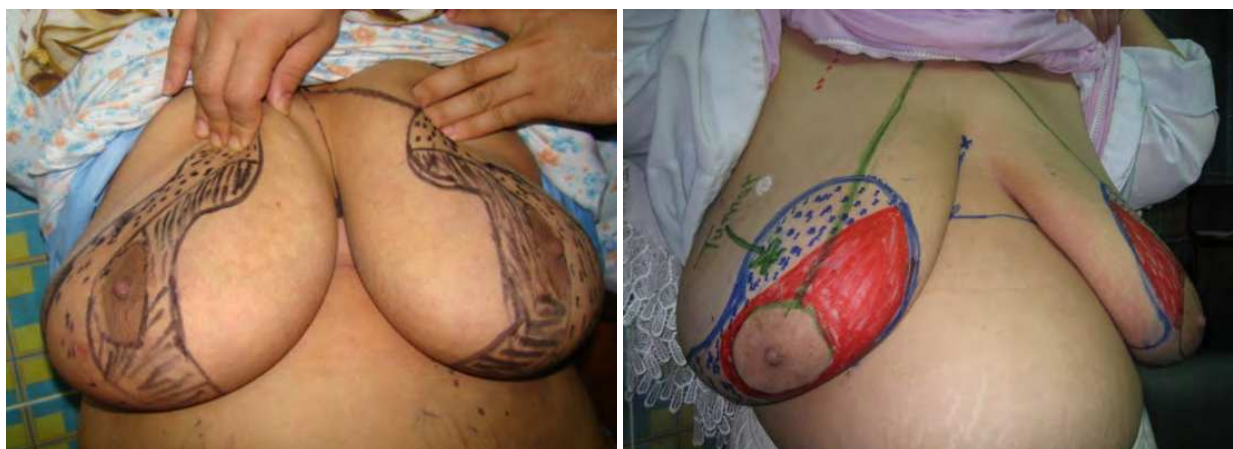

Fig. 25. Preoperative marking of patients with huge breasts, who are planned for therapeutic reduction mammoplasty.



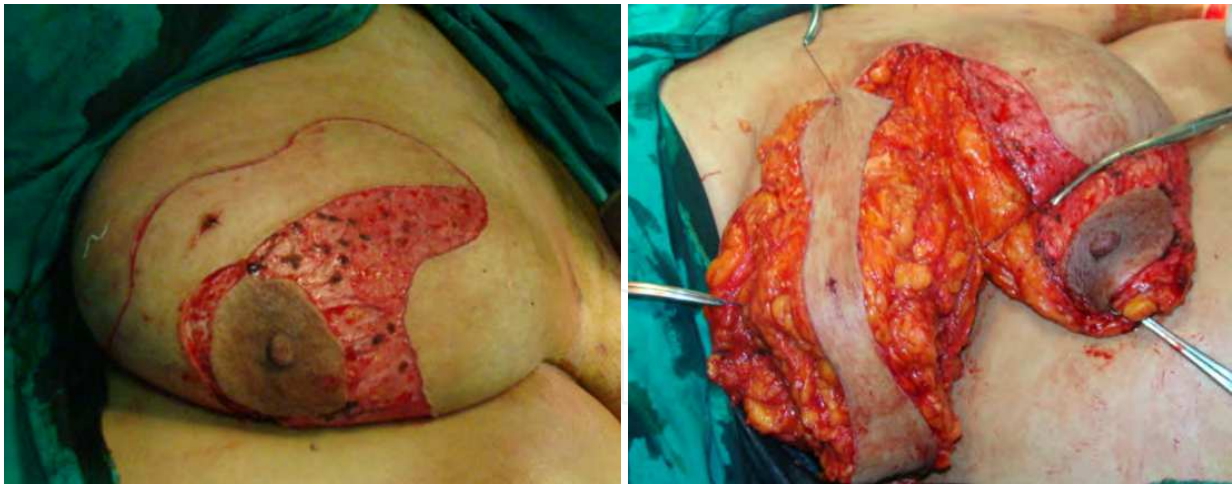

Fig. 26. Operative views of therapeutic reduction mammoplasty; the tumor safety margin is ranged from 5 – 11 cm all-around.

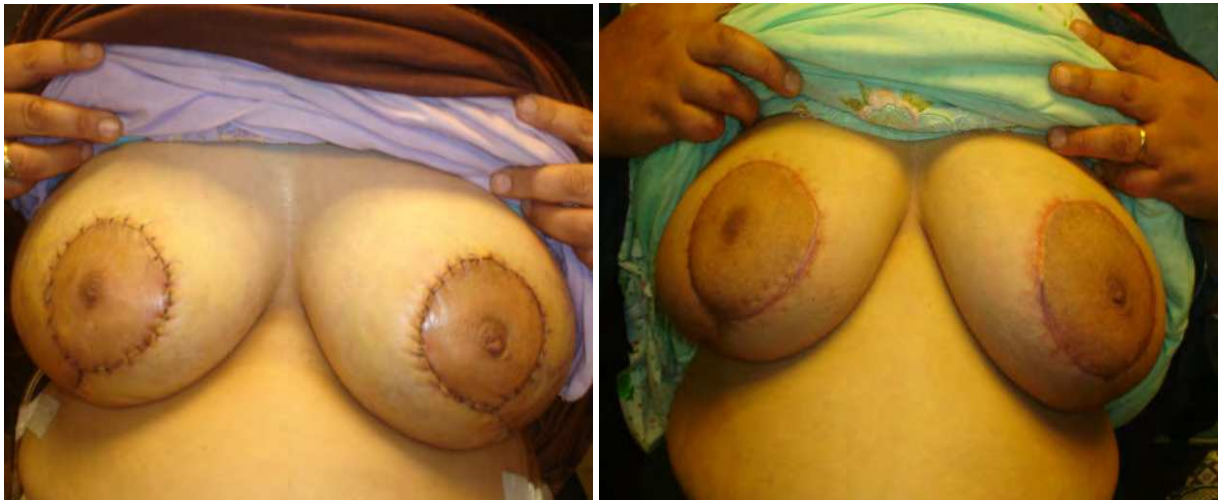

Fig. 27. Early Postoperative views of therapeutic reduction mammoplasty.

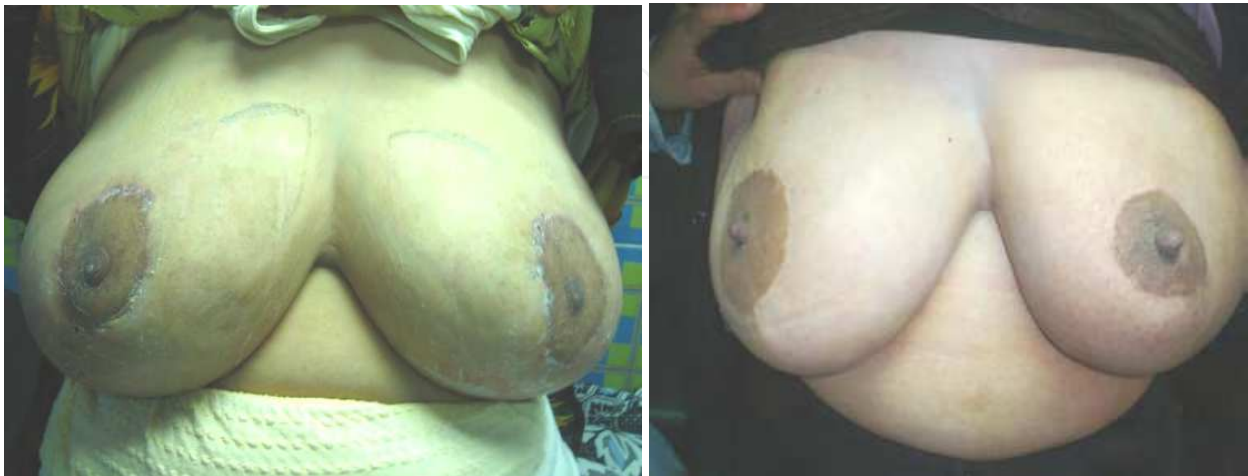

Fig. 28. Late postoperative views of therapeutic reduction mammoplasty; Left photo after 6 months & Right photo shows another patient after 2 years.





Fig. 29. Immediate breast reconstruction of huge breast with SSM using modified latissimus dorsi vascularized fat-added flap with SSM & nipple reconstruction and waiting areolar tattooing.

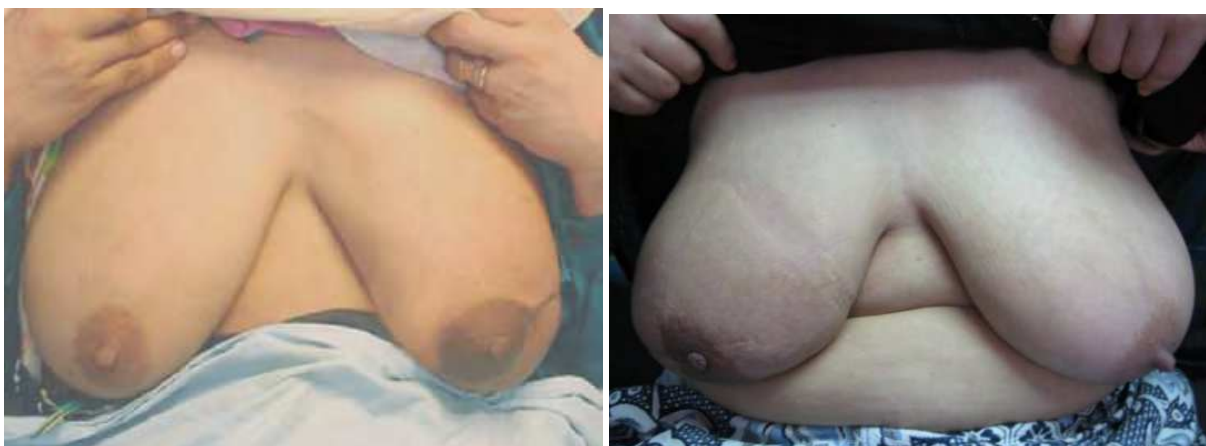

Fig. 30. Immediate breast reconstruction of huge breast with NSM using modified latissimus dorsi vascularized fat-added flap.

## 5. Conclusion

The trend in the surgical management of breast carcinoma has moved toward less radical surgery & has become more conservative. Although conservative surgery has been shown to be an oncologically sound strategy for most early stage breast cancer, mastectomy remains the treatment of choice for many women, either because of patient preference or because of tumor characteristics that are not compatible with a more conservative approach, in addition to consideration of local recurrence.

The development of SSM & NSM with immediate breast reconstruction achieved the goal of radical excision of the tumor with improved cosmetic outcome. Because the NAC area typically has been included in the resection(SSM) ,cosmetic approaches have involved nipple – areola reconstruction . Although this approach can give excellent cosmetic results ,it has potential disadvantages in the form of loss of nipple sensation ,pale color ,and possible loss of projection as the scars soften over time (Denewer & Farouk, 2007)

Single stage totally autologous breast reconstruction allows reconstruction without the additional cost of an implant, many complications of synthetic implants, micro vascular procedure second stage surgery or surgical manipulation in the other breast. In addition the overall survival & local recurrence rates were similar to MRM.

In conclusion, conservative mastectomy (sparing mastectomy; SSM & NSM) is oncologically as safe as MRM and better oncologic outcome than conservative breast surgery. Aesthetically the immediate reconstruction after these two techniques is superior to delayed reconstruction after MRM & immediate oncoplastic conservative breast surgery.

The new technique of vascularized chest wall fat added to LDF can allow immediate autologous breast reconstruction after SSM & NSM in all breast sizes even the huge breast without any synthetic implant with excellent aesthetic and oncologic outcome. This immediate breast reconstruction can avoid contralateral operation in medium and huge breast of cup C and D brassier sizes, moreover avoidance of psychological trauma of mastectomy and postoperative depression, anxiety and obsessions.

In the past three decades, there has been a gradual significant shift in breast cancer management which is the restoration of patient psychological, physical well-being as well as quality of life and body image. This is now considered as paramount importance in overall treatment of breast cancer.

For more efficient outcome, it is mandatory to achieve the following;

1. Pre-operative counseling of the patient
2. Patient selection as regards the disease stage, comorbidity and radiation therapy.
3. Good refinement and understanding of anatomical basis of autologous flaps.
4. Oncoplastic experience
5. Geometrical surgical imagination.
6. Consideration the immediate breast reconstruction
7. Skin sparing mastectomy and nipple sparing mastectomy have the least revision procedures necessary for perfection of breast shape and symmetry.
8. Ensure good vascularization of autologous tissue to decrease complications like fat necrosis, fibrosis and skin necrosis.

## 6. Acknowledgment

The authors gratefully acknowledge the contribution of Dr. Osama El-Damshety, Dr. Mohammed Tharwat, Dr. Hossam Elfeki and staff members of surgical oncology department.

## 7. References

- Alderman A.K., Wilkins E., Kim M. (2002). Complications in post-mastectomy breast reconstruction: two year results of the Michigan breast reconstruction outcome study. *Plast Reconstr Surg* Vol.109, pp. 2265-2274, ISSN 0032-1052 Online ISSN 1529-4242.

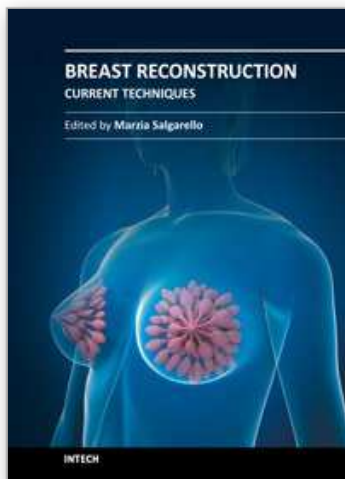
- Allen R.J., Tucker C. (1995). Superior gluteal artery perforator free flap for breast reconstruction. *Plast Reconstr Surg* Vol.95, pp. 1207–1212, ISSN 0032-1052 Online ISSN 1529-4242.
- Baildam AD. (2002). Oncoplastic surgery of the breast. *Br. J. Surg.* Vol.89, pp. 532–533, ISSN: 0007-1323, Online ISSN: 1365-2168.
- Benediktsson KP, Perbeck L. (2008). Survival in breast cancer after nipple-sparing subcutaneous mastectomy and immediate reconstruction with implants: a prospective trial with 13 years median follow-up in 216 patients. *Eur J Surg Oncol.* Vol.34, No.2, pp. 143-148, ISSN 0748-7983.
- Carlson GW, Moore B, Thornton JF, Elliott M, Bolitho G. (2001). Breast cancer after augmentation mammoplasty: treatment by skin-sparing mastectomy and immediate reconstruction. *Plast Reconstr Surg* Vol.107, No.3, pp. 687–692, ISSN 0032-1052 Online ISSN 1529-4242.
- Chevray PM. (2004). Breast reconstruction with superficial inferior epigastric artery flaps: a prospective comparison with TRAM and DIEP flaps. *Plast Reconstr Surg*; Vol.114, pp. 1077–1083, ISSN: 0032-1052 Online ISSN 1529-4242.
- Chevray P, Robb RL (2007). Breast Reconstruction. In: *M.D. Anderson Cancer Care Series: Breast Cancer (Second Edition)*, Hunt KK, Robb GL, Strom EA, Ueno NT, Robb GL., (Ed.), pp. 235-270, Springer, ISBN-13:978-0-387-34950-3 e-ISBN-13:978-0-387-34952-7, New York.
- Chevray PM, Robb GL (2008). Breast Reconstruction. In: *Breast Reconstruction*, Kelly K. Hunt, pp. (2nd edn). New York, Springer 2008.
- Chun YS, Verma K, Rosen H, Lipsitz S, Morris D, Kenney P (2010). Implant-based breast reconstruction using acellular dermal matrix and the risk of postoperative complications. *Plast Reconstr Surg.* Vol.125, pp. 429–436, ISSN 0032-1052 Online ISSN 1529-4242.
- Chung AP and Sacchini V (2008). Nipple-sparing mastectomy: Where are we now? *Surgical Oncology* Vol.17, pp. 261-266, ISSN 0960-7404.
- Cunnick GH and Mokbel K. (2006). Oncological considerations of skin-sparing mastectomy; Review. *International Seminars in Surgical Oncology.* Vol.3, pp. 14, ISSN 1477-7800.
- Crowe JP, Kim JA, Yetman R. (2004). Nipple-sparing mastectomy: technique and results of 54 procedures. *Arch Surg.* Vol.139, pp. 148–150, ISSN (printed): 0004-0010. ISSN (electronic): 0096-6908
- Delgado JM, Martinez-Mendez JR, de Santiago J. (2007). Immediate breast reconstruction (IBR) with direct, anatomic, extra-projection prosthesis:102 cases. *Ann Plast Surg* Vol. 58, pp. 99-104, ISSN 0148-7043.
- Denewer A (1997). Myomammary Flap of Pectoralis Major Muscle for Breast Reconstruction: New Technique. *World J. Surg.* Vol.21, pp. 57-61, ISSN 0364-2313 electronic ISSN 1432-2323.
- Denewer A. & Farouk O. (2007). Can Nipple-sparing Mastectomy and Immediate Breast Reconstruction with Modified Extended Latissimus Dorsi Muscular Flap Improve the Cosmetic and Functional Outcome among Patients with Breast Carcinoma? *World J Surg* Vol.31, pp. 1169–1177, ISSN 0364-2313 electronic ISSN 1432-2323.
- Denewer A., Setit A. and Farouk O. (2007). Outcome of Pectoralis Major Myomammary Flap for Post-mastectomy Breast Reconstruction: Extended Experience. *World J Surg.* Vol.31, pp. 1382–1386, ISSN 0364-2313 electronic ISSN 1432-2323.



- Denewer A., Setit A., Hussein O., Farouk O. (2008). Skin-Sparing Mastectomy with Immediate Breast Reconstruction by a New Modification of Extended Latissimus Dorsi Myocutaneous Flap. *World J Surg.* Vol.32, pp. 2586-2592, ISSN 0364-2313 electronic ISSN 1432-2323.
- Dnewer A, Hussein O, Farouk O, Elnahas W, Khater A and El-Saed A (2010). Cost-effectiveness of clinical breast assessment-based screening in rural Egypt. *World J. Surg.* Vol. 34, No.9, (September 2010), pp. 2204-2210, ISSN 0364-2313 electronic ISSN 1432-2323.
- Denewer A., Farouk O., Mostafa W. and Elshamy K. (2011). Social support and hope among Egyptian women with breast cancer after mastectomy: *breast cancer; basic and clinical research* Vol.5, pp. 93 - 103, ISSN: 1178-2234
- Elliot L.F., Beegle P.H., Hartrampf C.R. (1990). The lateral transverse thigh free flap: an alternative for autogenous-tissue breast reconstruction. *Plast Reconstr Surg* Vol.85, pp. 169-178, ISSN: 0032-1052 Online ISSN 1529-4242
- Hartrampf C.R. (1988). The transverse abdominal island flap for breast reconstruction. A 7-year experience. *Clin Plast Surg.* Vol.15, No.4, pp. 703, ISSN 0094-1298.
- Hidalgo DA, Borgen PJ, Petrek JA, Heerdt AH, Cody HS, and Disa JJ (1998). Immediate reconstruction after complete skin sparing mastectomy with autologous tissue. *J Am Coll Surg*; Vol.187, pp. 17-21, ISSN 1072-7515.
- Ho CM, Mak CK, Lau Y, Cheung WY, Chan MC, and Hung WK. (2003). Skin involvement in invasive breast carcinoma: safety of skin sparing mastectomy. *Ann Surg Oncol* Vol.10, pp.102-107, ISSN 0148-7043.
- Hu E. and Alderman A.K. (2007). Breast reconstruction. In: *Surgical clinics of north America* (87). Martin R.F. & Newman L.A., (Ed.), 453- 467, Elsevier Inc., ISBN 978-1-4160-5125-1, Michigan.
- Khoo A., Kroll S.S., Reece G.P. (1998). A comparison of resource costs of immediate and delayed breast reconstruction. *Plast Reconstr Surg.* Vol.101, No.4, pp. 964-968, ISSN 0032-1052 Online ISSN 1529-4242.
- Mathes SJ and Nahai F. Breast (Ed.), (1982). A systematic approach to flap selection. In: *clinical application for muscle and musculo-cutaneous flaps*, pp.285, Mosby co., ISBN 0801631645, St. Louis.
- Meretoja TJ, von Smitten KA, Kuokkanen HO, Suominen SH, Jahkola TA. (2008). Complications of Skin-Sparing Mastectomy Followed by Immediate Breast Reconstruction. *Ann Plast Surg*, Vol.60, pp. 24-28, ISSN 0148-7043.
- Nair A, Jaleel S, Abbott N, Buxton P, Matey P (2010). Skin-Reducing Mastectomy With Immediate Implant Reconstruction as an Indispensable Tool in the Provision of Oncoplastic Breast Services. *Ann Surg Oncol* Vol.17, No.9, pp. 2480-2485, ISSN 0148-7043.
- Petrek J A, and Disa J J (2005). Rehabilitation after Treatment for Cancer of the Breast; Part of "Chapter 33 - Cancer of the Breast" In: *Cancer: Principles & Practice of Oncology (7th edition)*, Devita VT, Hellman JS and Rosenberg SA, (Eds), pp. 1478- 1488, Lippincott Williams & Wilkins, ISBN 0-718-74450-4 .
- Sacchini V, Pinotti JA, Barros AC. (2006). Nipple sparing mastectomies for breast cancer and risk reduction: oncological or technical problem? *J Am Coll Surg* Vol.203, pp. 704-714, ISSN 1072-7515 Online ISSN: 1365-2168.

- Salgarello M & Farallo F. (2005). Immediate breast reconstruction with definitive anatomical implants after skin-sparing mastectomy. *Br J Plast Surg* Vol.58, pp. 216-222, ISSN 0007-1323.
- Simmons RM, Brennan M, Christos P, King V, and Osborne M. (2002). Analysis of nipple/areolar involvement with mastectomy: can the areola be preserved? *Ann Surg Oncol* Vol.9, pp. 165-168, ISSN (printed): 1068-9265. ISSN (electronic): 1534-4681.
- Sookhan N, Boughey JC, Walsh MF, Degnim AC (2008). Nipple-sparing mastectomy – initial experience at a tertiary center. *The American Journal of Surgery* Vol.196, pp.575-577, ISSN 0002-9610.
- Tachi M. and Yamada A. Choice of flaps for breast reconstruction (2005). *Int J Clin Oncol*. Vol.10, pp. 289-297, ISSN (printed): 1341-9625. ISSN (electronic): 1437-7772.
- Wilson CR, Brown IM, Weiller-Mithoff E. (2004). Immediate breast reconstruction does not lead to a delay in the delivery of adjuvant chemotherapy. *Eur J Surg Oncol* Vol. 30, No.6, pp.624-627, ISSN: 0748-7983; Electronic ISSN: 1532-2157.

IntechOpen



## **Breast Reconstruction - Current Techniques**

Edited by Prof. Marzia Salgarello

ISBN 978-953-307-982-0

Hard cover, 276 pages

**Publisher** InTech

**Published online** 03, February, 2012

**Published in print edition** February, 2012

Breast reconstruction is a fascinating and complex field which combines reconstructive and aesthetic principles in the search for the best results possible. The goal of breast reconstruction is to restore the appearance of the breast and to improve a woman's psychological health after cancer treatment. Successful breast reconstruction requires a clear understanding of reconstructive operative techniques and a thorough knowledge of breast aesthetic principles. Edited by Marzia Salgarello, and including contributions from respected reconstructive breast plastic surgeons from around the world, this book focuses on the main current techniques in breast reconstruction and also gives some insight into specific topics. The text consists of five sections, of which the first focuses on the oncologic aspect of breast reconstruction. Section two covers prosthetic breast reconstruction, section three is dedicated to autogenous breast reconstruction, and section four analyzes breast reconstruction with a fat graft. Finally, section five covers the current approaches to breast reshaping after conservative treatment.

### **How to reference**

In order to correctly reference this scholarly work, feel free to copy and paste the following:

Adel Denewer and Omar Farouk (2012). Modified Extended Latissimus Dorsi Myocutaneous Flap with Added Vascularised Chest Wall Fat in Immediate Breast Reconstruction after Conservative (Sparing) Mastectomies, *Breast Reconstruction - Current Techniques*, Prof. Marzia Salgarello (Ed.), ISBN: 978-953-307-982-0, InTech, Available from: <http://www.intechopen.com/books/breast-reconstruction-current-techniques/modified-extended-latissimus-dorsi-myocautaneous-flap-with-added-vascularized-fat-in-immediate-breast-reconstruction>

**INTECH**  
open science | open minds

### **InTech Europe**

University Campus STeP Ri  
Slavka Krautzeka 83/A  
51000 Rijeka, Croatia  
Phone: +385 (51) 770 447  
Fax: +385 (51) 686 166  
[www.intechopen.com](http://www.intechopen.com)

### **InTech China**

Unit 405, Office Block, Hotel Equatorial Shanghai  
No.65, Yan An Road (West), Shanghai, 200040, China  
中国上海市延安西路65号上海国际贵都大饭店办公楼405单元  
Phone: +86-21-62489820  
Fax: +86-21-62489821



© 2012 The Author(s). Licensee IntechOpen. This is an open access article distributed under the terms of the [Creative Commons Attribution 3.0 License](https://creativecommons.org/licenses/by/3.0/), which permits unrestricted use, distribution, and reproduction in any medium, provided the original work is properly cited.

IntechOpen

IntechOpen