

# We are IntechOpen, the world's leading publisher of Open Access books Built by scientists, for scientists

6,900

Open access books available

186,000

International authors and editors

200M

Downloads

Our authors are among the

154

Countries delivered to

TOP 1%

most cited scientists

12.2%

Contributors from top 500 universities



WEB OF SCIENCE™

Selection of our books indexed in the Book Citation Index  
in Web of Science™ Core Collection (BKCI)

Interested in publishing with us?  
Contact [book.department@intechopen.com](mailto:book.department@intechopen.com)

Numbers displayed above are based on latest data collected.  
For more information visit [www.intechopen.com](http://www.intechopen.com)



# Neoatherosclerosis Within the Implanted Stent

Hironori Kitabata and Takashi Akasaka

*Wakayama Medical University*

*Japan*

## 1. Introduction

Although it is generally recognized that the long-term clinical outcome of bare-metal stents (BMS) is favorable, a late luminal narrowing with restenosis of BMS can occur during the extended follow-up (beyond 5 years), resulting in clinical events such as stent thrombosis and myocardial infarction. Regarding the mechanisms of progressive late luminal renarrowing, a persistent and remarkable foreign body inflammatory reaction to the metal may promote new atherosclerotic changes and consequent plaque vulnerability of the neointimal tissue around the stent struts. However, neointimal atherosclerotic change (neoatherosclerosis) after BMS implantation is rarely reported. Although drug-eluting stents (DES) have dramatically reduced restenosis and target lesion revascularization compared with BMS, long-term safety remains a clinical major concern due to persistent increase in the incidence of very late stent thrombosis (VLST). While stent thrombosis is a multifactorial process, it has shown that tissue coverage over stent struts is an important determinant of late stent thrombosis. Furthermore, the development of neoatherosclerosis inside the DES may be another rare mechanism of late thrombotic events. Neoatherosclerosis in DES (two years after implantation) can occur earlier than in BMS. Because of high resolution up to 10  $\mu$ m, it has been described that optical coherence tomography (OCT) has the potential to identify the features of unstable plaques such as thin fibrous cap, large lipid core, thrombus, macrophage infiltration, and neovascularization. Furthermore, even in the evaluation of stent, OCT has been reported to be able to demonstrate the stented lesion morphology in detail including tissue protrusion, thrombus formation, incomplete apposition, late acquired malapposition, edge dissection, tissue coverage over struts, and so on. This chapter describes about the assessment of neoatherosclerosis within BMS and DES by OCT.

## 2. Late vascular healing response to bare-metal stent

Coronary stenting is an effective strategy to prevent restenosis in atherosclerotic lesions as compared to balloon angioplasty. Bare-metal stent (BMS) is widely used in the interventional cardiology. It has been reported that in-stent restenosis (ISR) after BMS implantation, especially late ISR, is not always benign and late ISR is closely associated with mortality. Furthermore, progressive increases in the incidence of late target lesion revascularization (TLR) is observed beyond 4 years and up to 15 to 20 years after BMS implantation. A serial angiographic follow-up study of BMS has demonstrated several phases, with early restenosis phase until the first 6 months, stabilization and regression phase from 6 months to 3 years, and late luminal renarrowing phase beyond 4 years. With

regard to the mechanisms of progressive late luminal renarrowing, Inoue et al. reported the pathological findings within the BMS. Three years after BMS implantation, apparent chronic inflammatory cell infiltration (mainly T lymphocytes) and neovascularization are recognizable around the stent struts, and beyond 4 years, heavy infiltration of foamy cells (lipid-laden macrophages) is observed. The authors concluded that stainless steel stents evoke a remarkable foreign body inflammatory reaction to the metal and persistent peri-strut chronic inflammatory cells may accelerate new atherosclerotic changes and consequent plaque vulnerability of the neointimal tissue around the stent struts. Although the precise incidence of new atherosclerosis during an extended follow-up after BMS implantation is unknown, several papers report the features in neointima (Table 1).

Yokoyama et al serially evaluated the detailed changes inside the BMS by using angioscopy. Between the first follow-up (6 to 12 months) and the second follow up ( $\geq 4$  years), the frequencies of lipid-laden yellow plaque and thrombus increased from 12% (3 of 26 patients) to 58% (15 of 26 patients) and from 4% to 31%, respectively. BMS segments with yellow plaque were significantly associated with late luminal narrowing.

OCT (LightLab Imaging, Westford, MA, USA) is an intracoronary imaging modality with a high-resolution of 10 to 20  $\mu\text{m}$ , providing detailed information about microstructures such as thin fibrous cap as well as the histology. Furthermore, OCT has the greatest advantage in its accuracy of tissue characterization compared with other coronary imaging modalities. Recently, using OCT, Takano et al observed the differences in neointima between early phase ( $< 6$  months) and late phase ( $\geq 5$  years). When compared with normal neointima (Fig. 1) proliferated homogeneously in the early phase, neointima within the BMS  $\geq 5$  years after implantation was characterized by marked signal attenuation and a diffuse border, suggesting lipid-laden intima (Fig. 2). Its frequency was 67% and lipid-laden intima was not observed in the early phase. Thin-cap fibroatheroma (TCFA)-like intima (Fig. 3) was observed in 29% of the patients in the late phase. Intimal disruption (Fig. 4) and thrombus (Fig. 5) were found frequently in the late phase as compared with the early phase (38% vs. 0% and 52% vs. 5%, respectively;  $p < 0.05$ ). However, there was no significant difference in terms of calcification (Fig. 6) between the 2 phases (10% vs. 0%). Although there was no significant difference with respect to the incidence of persistent neovascularization (Fig. 7A) between the 2 phases (81% vs. 60%,  $p = 0.14$ ), intrainitima neovascularization (Fig. 7B) was observed more frequently in the late phase than in the early phase (62% vs. 0%,  $p < 0.01$ ) and in segments with lipid-laden intima than those in without lipid-laden intima (79% vs. 29%,  $p = 0.026$ ). Furthermore, lipid-laden intima was more frequent in "symptomatic" patients than in asymptomatic patients. The frequencies of late ISR (62% vs. 0%,  $p < 0.001$ ) and late TLR (62% vs. 0%,  $p < 0.001$ ) were higher in patients with lipid-laden intima as compared with those without lipid-laden intima. Four patients with acute coronary syndrome in the late phase had both intimal disruption and thrombus. The authors speculated that neovascularization expanding from the persistent area into the intima with time might play a key role in atherosclerosis progression and the instability of neointimal tissue, as well as plaque neovascularization of nonstent segments in native coronary arteries. Hou et al also performed angiographic and OCT examinations in 39 patients with recurrent ischemia among 1636 patients who underwent BMS implantation. The average time interval between initial BMS implantation and OCT imaging was  $6.5 \pm 1.3$  years. Of 60 stents in 39 patients, 20 stents (33.3%) in 16 patients had OCT-derived lipid-rich plaques inside the stents. In 13 of these 20 stents, angiographic ISR was observed, and 7 restenotic lesions with lipid-rich

Studies	Stent	Imaging device	Implant duration (month)	Lipidic tissue	TCFA	Intimal disruption	Neovascularization		
							peri-stent	intra-intima	Thrombus
Yokoyama et al. (2009)	BMS (26 lesions )	Angioscopy	94.7±34.2	58%	N.A.	*31%	N.A.	N.A.	31%
Takano et al. (2010)	BMS (21 lesions)	OCT	91.5±25.9	67%	29%	38%	81%	62%	52%
Hou et al. (2010)	BMS (60 stents)	OCT	78±15.6	33.3%	N.A.	30%	N.A.	N.A.	5%
Nakazawa et al. (2011)	BMS (197 lesions) DES (209 lesions)	Pathology	BMS 72 (60 to 96) DES 14 (12 to 22.8)	†BMS 16% DES 31%	BMS 4% DES 1% (TCFA/plaque rupture)	-	N.A.	N.A.	N.A.
Kang et al. (2011)	DES (50 ISR lesions)	OCT	32.2 (9.2 to 52.2)	90%	52%	58%	60% (peristent and intraintima)	-	58%
Habara et al. (2011)	BMS (43 ISR lesions)	OCT	113.8±29.6	**90.7% (heterogeneous intima)	N.A.	**13.9%	**25.6%	**16.3%	**16.2%

Table 1. Neoatherosclerosis inside the implanted stent. BMS, bare-metal stent; DES, drug-eluting stent; ISR, in-stent restenosis; N.A., not applicable; OCT, optical coherence tomography; TCFA, thin-cap fibroatheroma; \* Surface irregularity; \*\* Minimum lumen area site; †Any neoatherosclerosis.

plaque manifested clinical presentations of unstable angina. Six lipid-rich plaques had evidence of intimal disruption. However, thrombus was found in only one stent (5%). Notably, 7 (35%) of 20 lipid-rich plaques had features consistent with macrophage infiltration (Fig. 8). More recently, Habara et al evaluated the difference of tissue characteristics between early (within the first year) and very late (> 5 years, without restenosis within the first years) restenotic lesions after BMS implantation by OCT. The mean follow-up period of early and very late ISR was  $8.7 \pm 4.1$  months and  $113.8 \pm 29.6$  months, respectively. The morphological characteristics of restenotic tissue (characterized by heterogeneous intima) in very late ISR

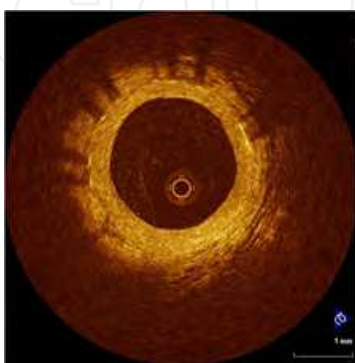

Fig. 1. Normal neointima inside the stent. OCT image of normal neointima showing a homogenous signal-rich band without signal attenuation.

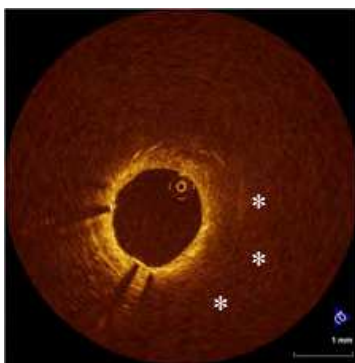


Fig. 2. Lipid-laden neointima inside the stent. OCT image of a neointima with lipid component showing a signal-poor region with poorly delineated border (\*). In this area, the stent struts are invisible.

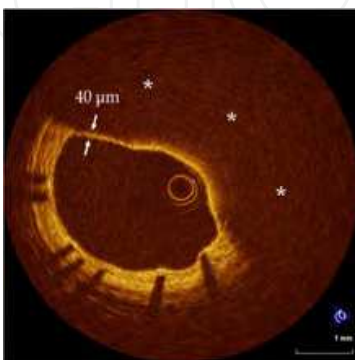


Fig. 3. Thin-cap fibroatheroma-like neointima inside the stent. Thin-cap fibroatheroma-like intima is defined as a lipidic tissue (\*) with a thin fibrous cap measuring  $< 65 \mu\text{m}$ .

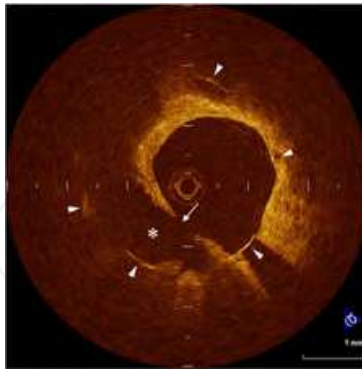


Fig. 4. Neointimal rupture inside the stent. OCT image of a neointimal rupture showing the disruption of fibrous cap (arrow) and cavity formation (\*) within well expanded struts (arrowheads).

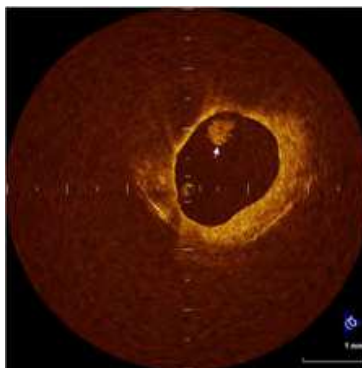


Fig. 5. Intracoronary thrombus inside the stent. OCT image of an intracoronary thrombus (arrow) showing a mass protruding into the vessel lumen.

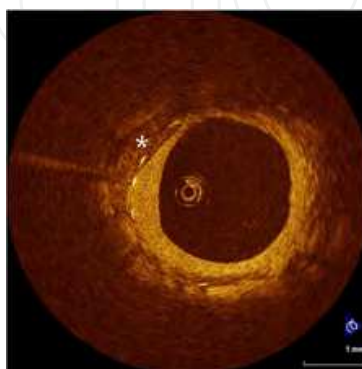


Fig. 6. Calcification inside the stent. OCT image of a calcification (\*) showing a signal-poor region with sharply delineated border.



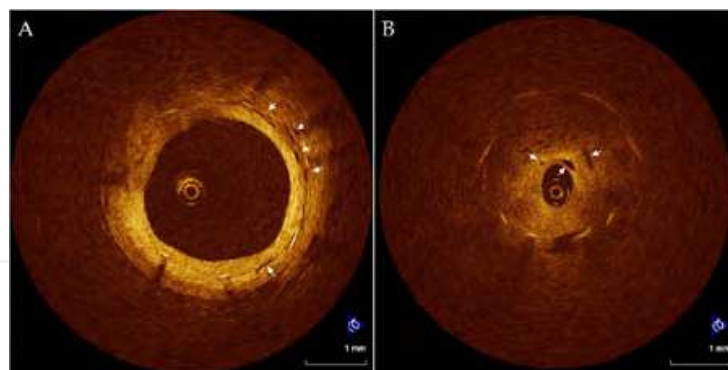


Fig. 7. Neovascularization inside the stent. (A) OCT image of peristent micro-vessels (arrows) showing a cluster of no-signal small vesicular and tubular structures locating around the struts. (B) OCT image of intraintima micro-vessels (arrows) showing small black holes locating near the vessel lumen within the neointimal tissue.

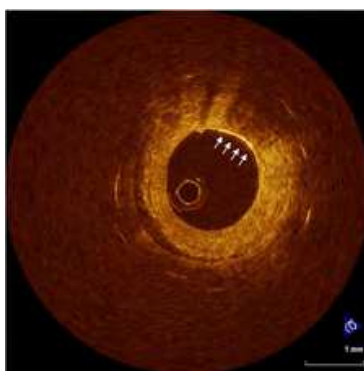


Fig. 8. Macrophage infiltration in neointima inside the stent. OCT image of macrophage infiltration showing a linear high-brightness region with shadowing behind (arrows).

were different from those (characterized by homogeneous intima) in early ISR and consistent with atherosclerotic plaque. In the very late ISR group, 31 (72.1%) of 43 patients underwent TLR. Notably, 17 patients (39.5%) had been asymptomatic until the follow-up angiography. These previous studies suggest that new atherosclerotic plaque formation in neointima may occur during an extended follow-up period after BMS implantation and contribute to clinical coronary events such as very late stent thrombosis. Even when the patients remain clinically stable and asymptomatic until their late follow-up presentations, unstable features such as TCFA and rupture may develop within the implanted BMS (Fig. 9). Therefore, a long-term optimal medical therapy including statins and a good control of coronary risk factors for secondary prevention will be needed to prevent such complications in patients who have previously undergone BMS implantation.

### 3. Vascular healing response to drug-eluting stent

Although drug-eluting stents (DES) have dramatically reduced restenosis and target lesion revascularization compared with BMS, long-term safety remains a clinical major concern because of persistent increase in the incidence of very late stent thrombosis (VLST). VLST in DES, after the first year, was reported at rates of 0.2-0.6% per year up to 3 years and the recommendations for dual antiplatelet therapy consisting of aspirin and thienopyridines

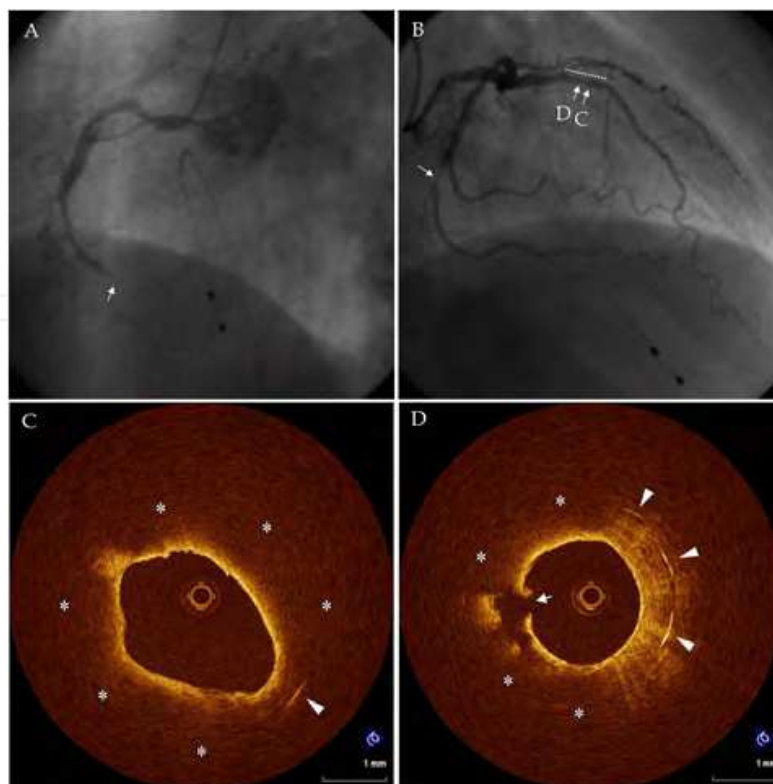


Fig. 9. A case with thin-cap fibroatheroma-like intima and neointimal rupture inside the bare-metal stent. A 57-year-old man was given a diagnosis of anterior ST-segment elevation myocardial infarction and treated with a 4.0X18 mm bare-metal stent (BMS) implanted to the proximal-portion of the left anterior descending artery (LAD) 6 years ago. A scheduled follow-up coronary angiography at 6 months after the index procedure demonstrated no restenosis. Six years after stent implantation, he suddenly presented with chest pain at rest and was admitted to the hospital. An emergent coronary angiography showed total occlusion of the right coronary artery (A, arrow), severe stenosis in the mid-portion of the left circumflex artery (B, arrow), and no in-stent restenosis of the previously implanted BMS of the LAD (B, dotted line). After successful reperfusion therapy of the RCA, optical coherence tomography (OCT) was performed in the LAD. OCT revealed thin-cap fibroatheroma-like intima (C) and neointimal rupture (D) inside the previous BMS. Many stent struts are invisible due to marked signal attenuation, representing lipid component (\*). In this patient, medical control for secondary prevention was insufficient (low-density lipoprotein cholesterol level was 174mg/dL and hemoglobin A1c was 11.8%). Arrowheads indicate stent struts.

were extended to  $\geq 12$  months after DES implantation without a clear evidence whether this extension would reduce the rates of VLST. Although stent thrombosis is a multifactorial, Finn et al has reported that inadequate stent coverage (the ratio of uncovered struts to total struts) is a powerful histological predictor of late stent thrombosis. OCT can reliably distinguish thin neointimal hyperplasia ( $< 100 \mu\text{m}$ ) on stent struts and uncovered struts, which is undetectable by intravascular ultrasound (IVUS). It has also been reported that OCT imaging can accurately assess the extent and thickness of neointimal coverage on stent struts after stent implantation with good histological correlation. Xie et al. performed OCT imaging at 3 months after sirolimus-eluting stent (SES) implantation. In



this study, the frequencies of uncovered struts and struts with neointimal coverage  $< 100 \mu\text{m}$  were 15 % and 94 %, respectively. Matsumoto et al. also investigated 34 patients with SES who underwent OCT examination at 6 months after implantation. Eleven % of struts still remained uncovered. Only 9 SESs (16%) demonstrated full coverage by neointima, whereas the remaining stents had partially uncovered struts. Yao et al, by using OCT, evaluated the time course of neointimal coverage in SES after implantation. Between 6 months and 12 months, the frequency of uncovered struts decreased from 9.2% to 6.6%. Katoh et al also reported a comparison of OCT findings in identical SES at 6 months and 12 months. As a result, the frequency of struts without neointimal coverage (10.4% to 5.7%) was similar to the results of Yao's study. Furthermore, Takano et al. serially performed OCT imaging at 2 and 4 years after implantation in 17 patients treated with 21 SESs. The frequency of patients with uncovered struts significantly decreased from 88% to 29% ( $p = 0.002$ ). The presence of mural thrombus might be one of risk factors for stent thrombosis. Otake et al reported that mural thrombus was detected in 14 (26%) of 53 lesions by OCT at 6 months after SES implantation. Subclinical thrombus was associated with larger number of uncovered struts, uneven neointimal thickness, greater asymmetric stent expansion, and longer SES. However, in this small study, the presence of mural thrombus did not lead to clinical stent thrombosis during follow-up period (median 485 days). Kim et al also reported a large-scale OCT registry data of 226 patients with various DESs. The frequencies of intracoronary thrombus were 28% in SES, 11% in paclitaxel-eluting stent (PES), and 1% in zotarolimus-eluting stent (ZES), respectively. Although the presence of intracoronary thrombus was associated with longer stent length ( $\geq 28\text{mm}$ ), smaller stent diameter ( $< 3.0 \text{ mm}$ ), and more uncovered struts ( $\geq 8$  uncovered struts in each stent), major adverse cardiac events including stent thrombosis were not found in patients with intracoronary thrombus during follow-up period (mean 8 months). These studies demonstrate that there is a relationship between uncovered stent struts and thrombus formation. However, to obtain clear conclusion about clinical implications of subclinical thrombus detected by OCT, further studies with long-term clinical follow-up and larger population are warranted.

Late-acquired incomplete stent apposition (ISA) may also be one of main mechanisms of VLST of DES. One IVUS observational study demonstrated its possible association with VLST after DES implantation. The mechanism of late-acquired ISA is widely accepted to typically be the result of either positive arterial remodeling and/or thrombus dissolution behind the stent struts (especially in myocardial infarction). Although the clinical association of late-acquired ISA and stent thrombosis remains controversial and is under intense investigation, Ozaki *et al.* assessed the fate of ISA post-SES implantation by using OCT. The frequency of incompletely apposed struts post-intervention was 7.2% (309 struts). Of 309 struts, 202 (65%) struts remained persistent ISA without neointimal coverage even at 10-month follow-up. Mural thrombus was observed more frequently in struts with ISA (20.6%) compared with struts with a good apposition (only 2.0%). Thus, it has been suggested that the underlying mechanism of VLST may be different between BMS and DES. However, chronic inflammatory can occur in DES as well as BMS and may be more pronounced with DES due to the presence of the polymer carrying therapeutic drug. This high degree of inflammation can develop neoatherosclerosis with shorter implant duration in DES than in BMS. More recently, it has been reported that the development of neoatherosclerosis may be an additional contributing factor to very late

thrombotic events in DES. Kang et al demonstrated the results of OCT analysis of in-stent neoatherosclerosis in 50 patients with ISR after DES implantation. The median follow-up period was 32.2 months (9.2 to 52.2). Twenty (40%) of 50 patients presented with unstable angina and the remaining 30 (60%) patients with stable angina. Despite clinical presentations of unstable or stable angina, 90% of the lesions had lipid-laden neointima. Fifty-two % of the lesions had at least 1 TCFA-like neointima and 58% had at least 1 neointimal rupture. Compared with DES < 20 months after implantation, DES ≥ 20 months after implantation had a greater incidence of TCFA-like neointima (69% vs. 33%,  $p = 0.012$ ) and red thrombi (27% vs. 0%,  $P = 0.007$ ). Notably, there was a negative correlation between the thickness of the fibrous cap and follow-up period ( $r = -0.318$ ,  $p = 0.024$ ). Furthermore, unstable patients showed a thinner fibrous cap (55  $\mu\text{m}$  vs. 100  $\mu\text{m}$ ,  $p = 0.006$ ) and higher incidence of TCFA-like intima (75% vs. 37%,  $p = 0.008$ ), intimal disruption (75% vs. 47%,  $p = 0.044$ ), and thrombi (80% vs. 43%,  $p = 0.01$ ) than stable patients. The authors concluded that in-stent neoatherosclerosis may be an important mechanism of DES failure, especially late after implantation. However, the majority (70%) of DES evaluated in this study were first-generation DES (SES and PES). Nakazawa et al reported on pathological change in a registry series of 299 autopsies with 406 coronary stented lesions, including 197 BMS and 209 DES. Neoatherosclerosis was defined as clusters of peristrut lipid-laden foamy macrophages within the neointima with or without necrotic core formation. The overall incidence of neoatherosclerosis was significantly higher in DES (31%) than in BMS (16%) lesions ( $p < 0.001$ ). Neoatherosclerosis was found to be more frequent in DES than in BMS and to occur earlier in DES than in BMS. In addition, multiple logistic regression analysis revealed younger age, longer implant durations, DES usage, and underlying unstable plaques as independent predictors of neoatherosclerosis. However, all DES included in this pathological study were also SES (49%) and PES (51%). Because the vascular healing response after implantation may be influenced by the types of DES (different stent material, strut thickness, design, and polymer), long-term follow-up OCT studies with a large number of second-generation DES (ZES and everolimus-eluting stent) are needed to understand the differences in neointimal atherosclerotic change between the DES types.

#### 4. Limitation

OCT abnormal findings inside the BMS and DES observed in these studies above may be similar to the features of vulnerable plaque in a native coronary artery. However, a direct comparison of OCT findings with histology is not done. In fact, there is a discrepancy in the frequency of neoatherosclerosis between OCT findings and pathological findings (Table 1). Therefore, histological data that properly validate OCT findings within the stents are required in the near future.

#### 5. Conclusion

Neointima within the stent in both BMS and DES can transform into atherosclerotic tissue with time although it occurs earlier in DES than BMS. Neoathrosclerosis progression inside the implanted stents may be associated with very late coronary events such as VLST after BMS and DES implantation.

## 6. Acknowledgment

The authors thank Kenichi Komukai, MD; Takashi Kubo, MD; Yasushi Ino, MD; Takashi Tanimoto, MD; Kohei Ishibashi, MD; Kunihiro Shimamura, MD; Makoto Orii, MD; Yasutsugu Shiono, MD for assistance with OCT image acquisition and analysis.

## 7. References

- Chen, MS.; John, JM. & Chew DP. (2006). Bare metal stent restenosis is not a benign clinical entity. *Am Heart J*, Vol. 151, No. 6, (June), pp. 1260-1264.
- Cook, S.; Wenaweser, P. & Togni, M. (2007). Incomplete stent apposition and very late stent thrombosis after drug-eluting stent implantation. *Circulation*, Vol. 115, No. 18, (May), pp. 2426-2434.
- Doyle, B.; Rihal, CS. & O'Sullivan, CJ. (2007). Outcomes of stent thrombosis and restenosis during extended follow-up of patients treated with bare metal coronary stents. *Circulation* Vol. 116, No. 21, (November), pp. 2391-2398.
- Doyle, B. & Caplice, N. (2007). Plaque neovascularization and antiangiogenic therapy for atherosclerosis. *J Am Coll Cardiol*, Vol. 49, No. 21, (May), pp. 2073-2080.
- Finn, AV.; Joner, M. & Nakazawa, G. (2007). Pathological correlates of late drug-eluting stent thrombosis: strut coverage as a marker of endothelialization. *Circulation*, Vol. 115, No. 18, (May), pp. 2435-2441.
- Habara, M.; Terashima, M. & Nasu, K. (2011). Difference of tissue characteristics between early and very late restenosis lesions after bare-metal stent implantation: an optical coherence tomography study. *Circ Cardiovasc Interv*, (Jun), Vol. 4, No. 3, pp. 232-238.
- Hasegawa, K.; Tamai, H. & Kyo, E. (2006). Histopathological findings of new in-stent lesions developed beyond five years. *Catheter Cardiovasc Interv*, Vol. 68, No. 4, (October), pp. 554-558.
- Hou, J.; Qi, H. & Zhang, M. (2010). Development of lipid-rich plaque inside bare metal stent: possible mechanism of late stent thrombosis? An optical coherence tomography study. *Heart*, (August), Vol. 96, No. 15, pp. 1187-1190.
- Inoue, K.; Abe, K. & Ando, K. (2004). Pathological analyses of long-term intracoronary Palmaz-Schatz stenting; Is its efficacy permanent? *Cardiovasc Pathol*, Vol. 13, No. 2, (March-April), pp. 109-115.
- Jang, IK.; Tearney, GJ. & MacNeill, B. (2005). In vivo characterization of coronary atherosclerotic plaque by use of optical coherence tomography. *Circulation*, Vol. 111, No. 12, (March), pp. 1551-1555.
- Kang, SJ.; Mintz, GS. & Akasaka, T. (2011). Optical coherence tomographic analysis of in-stent neoatherosclerosis after drug-eluting stent implantation. *Circulation*, Vol. 123, No. 25, (Jun), pp. 2954-2963.
- Kashiwagi, M.; Kitabata, H. & Tanaka, A. (2010). Very late cardiac event after BMS implantation: In vivo optical coherence tomography examination. *J Am Coll Cardiol Img*, Vol. 3, No. 5, (May) pp. 525-527.
- Katoh, H.; Shite, J. & Shinke, T. (2009). Delayed neointimalization on sirolimus-eluting stents: 6-months. and 12-month follow up by optical coherence tomography. *Circ J*, Vol. 73, No. 6, (Jun), pp. 1033-1037.


- Kimura, T.; Abe, K. & Shizuta, S. (2002). Long-term clinical and angiographic follow-up after coronary stent placement in native coronary arteries. *Circulation*, Vol. 105, No. 25, (Jun), pp. 2986 -2991.
- Kitabata, H.; Tanaka, A. & Kubo, T. (2010). Relation of microchannel structure identified by optical coherence tomography to plaque vulnerability in patients with coronary artery disease. *Am J Cardiol*, Vol. 105, No. 12, (Jun), pp. 1673-1678.
- Kubo, T.; Imanishi, T. & Takarada, S. (2007). Assessment of culprit lesion morphology in acute myocardial infarction: ability of optical coherence tomography compared with intravascular ultrasound and coronary angiography. *J Am Coll Cardiol* Vol. 50, No. 10, (September), pp. 933-939.
- Kume, T.; Akasaka, T. & Kawamoto, T. (2006). Assessment of coronary arterial plaque by optical coherence tomography. *Am J Cardiol*, Vol. 97, No. 8, (April), pp. 1172-1175.
- Kume, T.; Akasaka, T. & Kawamoto, T. (2006). Assessment of coronary arterial thrombus by optical coherence tomography. *Am J Cardiol*, Vol. 97, No. 12, (Jun), pp. 1713-1717.
- Kume, T.; Akasaka, T. & Kawamoto, T. Measurement of the thickness of the fibrous cap by optical coherence tomography. *Am Heart J*, Vol. 152, No. 4, (October), pp. 755e1-4.
- Lemesle, G.; Pinto Slottow, TL. & Wakasman, R. (2009). Very late stent thrombosis after bare-metal stent implantation: case reports and review of the literature. *J Invasive Cardiol*, Vol. 21, No. 2, (February), pp. e27-32.
- Lee, CW.; Kang, SJ. & Park, DW. (2010). Intravascular ultrasound findings in patients with very late stent thrombosis after either drug-eluting or bare-metal stent implantation. *J Am Coll Cardiol*, Vol. 55, No. 18, (May), pp. 1936-1942.
- Nakazawa, G.; Otuska, F. & Nakano, M. (2011). The pathology of neoatherosclerosis in human coronary implants: bare-metal and drug-eluting stents. *J Am Coll Cardiol*, Vol. 57, No. 11, (March), pp. 1314-1322.
- Ozaki, Y.; Okumura, M. & Ismail, TF. (2010). The fate of incomplete stent apposition with drug-eluting stents: an optical coherence tomography-based natural history study. *Eur Heart J*, Vol. 3, No. 12, (Jun), pp. 1470-1476.
- Takano, M.; Yamamoto, M. & Inami, S. (2008). Long-term follow-up evaluation after sirolimus-eluting stent implantation by optical coherence tomography: do uncovered struts persist? *J Am Coll Cardiol*, Vol. 51, No. 9, (March), pp. 968-969.
- Takano, M.; Yamamoto, M. & Inami, S. (2010). Appearance of lipid-laden intima and neovascularization after implantation of bare-metal stents. *J Am Coll Cardiol*, Vol. 55, No. 1, (January), pp. 26-32.
- Waksman, R. (2007). Late stent thrombosis--the "vulnerable" stent. *Catheter Cardiovasc Interv*, (July), Vol. 70, No. 1, pp. 54-56.
- Xie, Y.; Takano, M. & Murakami, D. (2008). Comparison of neointimal coverage by optical coherence tomography of a sirolimus-eluting stent versus a bare-metal stent three months after implantation. *Am J Cardiol*, Vol. 102, No. 1, (July), pp. 27-31.
- Yokoyama, S.; Takano, M. & Yamamoto, M. (2009). Extended follow-up by serial angioscopic observation for bare-metal stents in native coronary arteries: from healing response to atherosclerotic transformation of neointimal. *Circ Cardiovasc Intervent*, Vol. 2, No. 3, (Jun), pp. 205-212.
- Yamaji, K.; Kimura, T. & Morimoto, T. (2010). Very long-term (15 to 20 years) clinical and angiographic outcome after coronary bare metal stent implantation. *Circ Cardiovasc Interv*, Vol. 3, No. 5, (October), pp. 468-475.

- Yabushita, H.; Bouma, BE. & Houser, SL. (2002). Characterization of human atherosclerosis by optical coherence tomography. *Circulation*, Vol. 106, No. 13, (September), pp. 1640 -1645.
- Yao, ZH.; Matsubara, T. & Inada, T. (2008). Neointimal coverage of sirolimus-eluting stents 6 months and 12 months after implantation: evaluation by optical coherence tomography. *Chin Med J*, Vol. 121, No. 6, (March), pp. 503-507.

IntechOpen

IntechOpen





### **Selected Topics in Optical Coherence Tomography**

Edited by Dr. Gangjun Liu

ISBN 978-953-51-0034-8

Hard cover, 280 pages

**Publisher** InTech

**Published online** 08, February, 2012

**Published in print edition** February, 2012

This book includes different exciting topics in the OCT fields, written by experts from all over the world. Technological developments, as well as clinical and industrial applications are covered. Some interesting topics like the ultrahigh resolution OCT, the functional extension of OCT and the full field OCT are reviewed, and the applications of OCT in ophthalmology, cardiology and dentistry are also addressed. I believe that a broad range of readers, such as students, researchers and physicians will benefit from this book.

#### **How to reference**

In order to correctly reference this scholarly work, feel free to copy and paste the following:

Hironori Kitabata and Takashi Akasaka (2012). Neoatherosclerosis Within the Implanted Stent, Selected Topics in Optical Coherence Tomography, Dr. Gangjun Liu (Ed.), ISBN: 978-953-51-0034-8, InTech, Available from: <http://www.intechopen.com/books/selected-topics-in-optical-coherence-tomography/neoatherosclerosis-within-the-implanted-stent>

**INTECH**  
open science | open minds

#### **InTech Europe**

University Campus STeP Ri  
Slavka Krautzeka 83/A  
51000 Rijeka, Croatia  
Phone: +385 (51) 770 447  
Fax: +385 (51) 686 166  
[www.intechopen.com](http://www.intechopen.com)

#### **InTech China**

Unit 405, Office Block, Hotel Equatorial Shanghai  
No.65, Yan An Road (West), Shanghai, 200040, China  
中国上海市延安西路65号上海国际贵都大饭店办公楼405单元  
Phone: +86-21-62489820  
Fax: +86-21-62489821

© 2012 The Author(s). Licensee IntechOpen. This is an open access article distributed under the terms of the [Creative Commons Attribution 3.0 License](https://creativecommons.org/licenses/by/3.0/), which permits unrestricted use, distribution, and reproduction in any medium, provided the original work is properly cited.

IntechOpen

IntechOpen