

We are IntechOpen, the world's leading publisher of Open Access books Built by scientists, for scientists

6,900

Open access books available

185,000

International authors and editors

200M

Downloads

Our authors are among the

154

Countries delivered to

TOP 1%

most cited scientists

12.2%

Contributors from top 500 universities



WEB OF SCIENCE™

Selection of our books indexed in the Book Citation Index
in Web of Science™ Core Collection (BKCI)

Interested in publishing with us?
Contact book.department@intechopen.com

Numbers displayed above are based on latest data collected.
For more information visit www.intechopen.com



[¹⁸F]Fluorodeoxyglucose Positron Emission Tomography in Alzheimer Disease and Related Disorders

Nobuhiko Miyazawa and Toyoaki Shinohara

*Department of PET and Nuclear Medicine, Kofu Neurosurgical Hospital
Japan*

1. Introduction

The numbers of cases of Alzheimer disease (AD) and related disorders have been increasing with higher life expectancy worldwide. In particular, the incidence has sharply increased in people aged 70 to 80 years, with consequent significant burdens on health care systems and economies. In the 1990s, more than 4% of individuals aged over 65 years were affected by AD (Folstein et al., 1991), and 7–10% of this age group in Japan have been estimated to have AD (Meguro et al., 2002). Worldwide, the estimated number of individuals with AD of 24.3 million in 2001 is expected to increase to 42.3 million by 2020, and to 81.1 million by 2040 (Ferri et al., 2005).

AD is characterized by various definitive histopathological findings including presence of amyloid plaques, neurofibrillary tangles, and microglia in different degrees, and neuronal loss and neurotransmitter changes (Mattson et al., 2004; Thal et al., 2002). A characteristic early sign of pathology is the deposition of amyloid- β (A β) peptide in the medial side of the temporal lobe. The diagnosis of AD has been defined by the Diagnostic and Statistical Manual of Mental Disorders, fourth edition, text revision (American Psychiatric Association, 2000) and the National Institute of Neurological and Communicative Disorders and Stroke-Alzheimer's Disease and Related Disorders Association (NINCDS-ADRDA) (McKhann et al., 1984). The definitive diagnosis of AD is based on both the NINCDS-ADRDA criteria and the histopathological findings, but probabilistic clinical diagnosis of AD depends on these criteria without the investigations by magnetic resonance (MR) imaging, positron emission tomography (PET), or other biomarkers (Dubois et al., 2007).

Several potential biomarkers for AD have been proposed, such as biochemical biomarkers based on measurement of the concentration of A β ₄₂ and total tau in the cerebrospinal fluid (CSF), structural neuroimaging biomarker based on MR imaging using specific software, and functional neuroimaging biomarker based on PET using [¹⁸F]fluorodeoxyglucose (FDG) or [¹¹C]Pittsburgh compound B (PIB). Detection of AD based on the concentrations of A β ₄₂ and total tau in patients versus normal individuals achieved sensitivity of 85–94% and specificity of 83–100% (Blennow & Hampel, 2003). Detection of prodromal AD based on the MR imaging measurement of middle temporal lobe volume and lateral temporal lobe or

anterior cingulate volume achieved sensitivity of 68–93% and specificity of 48–96% (Convit et al., 2000; Killiany et al., 2000). Discrimination of AD from controls using FDG-PET achieved sensitivity of 94% and specificity of 73–78% (Foster et al., 1983; Herholz et al., 2002b; Ishii et al., 1999; Mielke et al., 1994; Silverman et al., 2001). Therefore, novel criteria have been proposed based on these distinctive and reliable biomarkers of AD as follows. The core diagnostic criterion is the presence of early and significant episodic memory impairment, and the secondary criterion is the detection of at least one or more abnormal findings of the structural neuroimaging biomarker using MR imaging, molecular neuroimaging biomarker using PET, and A β or tau protein level using CSF analysis (Dubois et al., 2007).

Several clinical trials have tested drugs aimed at modifying the AD process, such as acetylcholinesterase inhibitor, anti-inflammatory drugs, statins, γ and β secretase inhibitors, immunotherapy, and neuroprotective drugs. However, no large trial has attempted to identify the most powerful diagnostic biomarker, and to monitor disease progression and treatment effects. The Alzheimer's Disease Neuroimaging Initiative (ADNI) is a new multicenter clinical AD research project launched in 2004, and intended to detect neuroimaging parameters and biomarkers associated with the cognitive and functional changes in aged individuals with normal cognition, mild cognitive impairment (MCI), and AD in the United States and Canada (Mueller et al., 2005). ADNI-like trials have also been started in Europe, Australia, Japan, and Korea. Together, these trials could identify the most helpful biomarker and the optimum application for monitoring of the progress of AD and treatment effects.

The present review investigates the potential and feasibility of FDG-PET for the detection and monitoring of AD and related disorders, based on reported cases and our own experience (over 500 cases), and discuss the future applications of FDG-PET to the investigation of AD.

2. FDG-PET imaging of AD

2.1 History

Measurements of cerebral blood flow, and of oxygen and glucose metabolism have been made since the 1970s, and could be performed in dementia patients since the early 1980s (Benson et al., 1981; de Leon et al., 1983; Foster et al., 1984; Frackowiak et al., 1981; Jagust et al., 1985). These studies mainly depended on examination of cross-sectional PET images to detect regional decreases in cerebral blood flow or glucose metabolism in temporal or parietal lobe (Benson et al., 1981; Frackowiak et al., 1981). Development of a novel mapping method based on the three-dimensional stereotactic surface projection (3D-SSP) technique in the mid 1990s revealed preclinical metabolic decrease in the posterior cingulate and cinguloparietal transitional cortices in patients with AD (Minoshima et al., 1994, 1997). The statistical parametric mapping (SPM) technique allowing voxel-by-voxel basis analysis appeared in the early 2000s (Herholz et al., 2002). Such techniques have since been modified, such as the fully automatic diagnostic system using 3D-SSP (Ishii et al., 2006). These modified techniques provide more precise and earlier detection of AD compared with 20 years ago.

2.2 Progress of image analysis

2.2.1 3D-SSP

This technique has been developed to facilitate the diagnosis of AD and AD-related disorders by radiologists who are not specialists in nuclear medicine. The base images are corrected for head rotation and realigned to the standard stereotactic coordinate system. After images from different subjects are standardized in the same coordinate system, parametric analysis can be performed across subjects on a pixel-by-pixel basis. The 3D-SSP is used to exclude false findings caused by residual individual anatomic differences and cortical atrophy that is often present in patients with dementia. After individual PET image sets are standardized in the 3D-SSP format, image data obtained from normal individuals can be averaged to form a normal database. Patient PET image sets processed in the same manner can be compared with the normal database, and deviations of regional metabolic activities from normal values are expressed as Z scores. This method can identify areas of statistically significant reduction of metabolism in AD patients (Burdette et al., 1996; Minoshima et al., 1993, 1994, 2003). This method is routinely used worldwide to obtain consistent diagnostic accuracy using FDG-PET in the diagnosis of AD and AD-related disorders [Fig. 1].

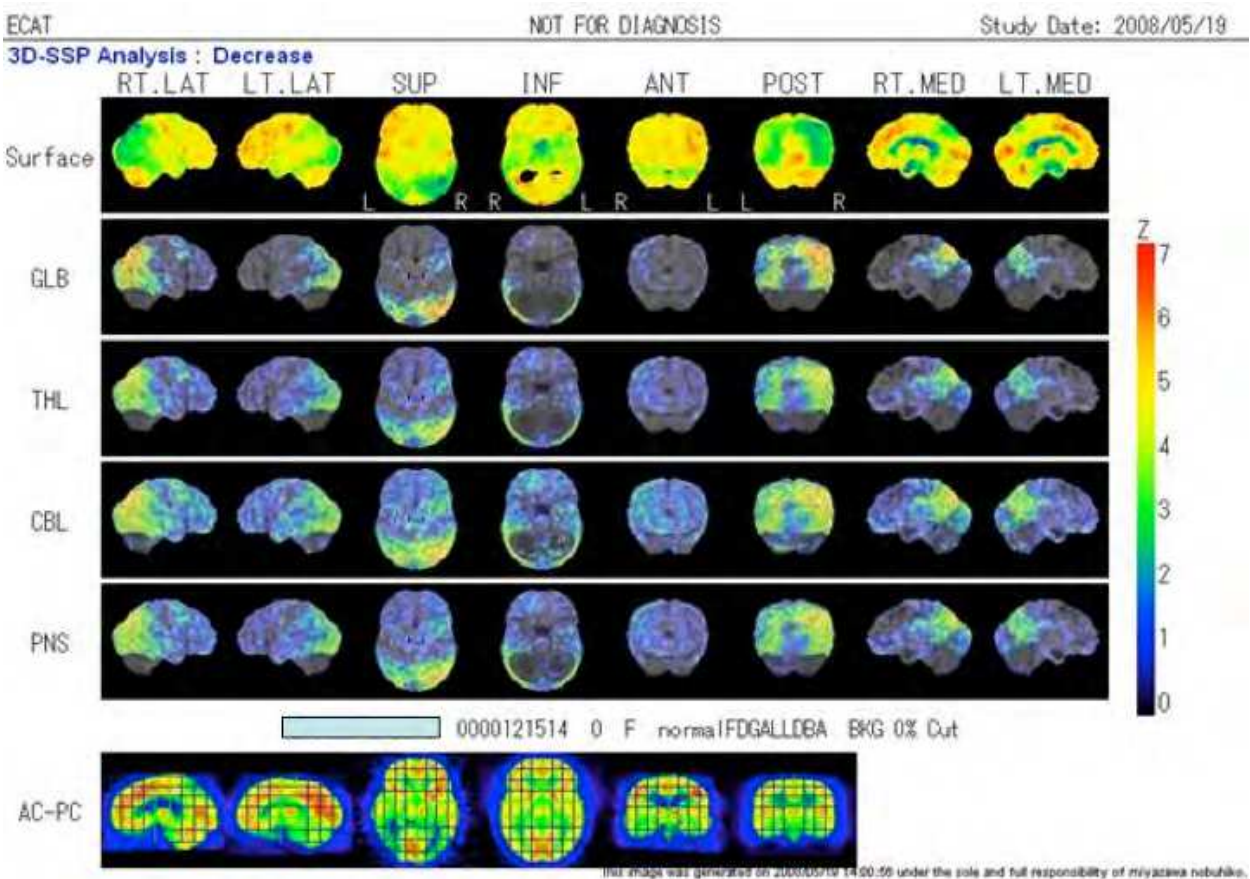


Fig. 1. FDG-PET study of AD patients using 3D-SSP (Minoshima). Z-score mapping compared with normal controls showed decreased glucose metabolism in the bilateral precuneus, posterior cingulate, and temporo-parietal cortices, which is not clearly visible on normal scans by the visual method.

2.2.2 SPM

SPM is also used for analyzing FDG-PET data. MATLAB software (MathWorks, Natick, MA, USA) was utilized for basic image processing with SPM99 software (Wellcome Department of Cognitive Neurology, London, UK) for spatial normalization. Further image analysis was performed with interactive data language programs. MPITool (Advanced Tomo Vision GmbH, Kerpen, Germany) was used for image display and SAS (SAS Institute Inc., Cary, NC, USA) was used for statistical evaluation of results. The t sum, calculated as the sum of t values over all voxels with FDG uptake below the 95% age-adjusted prediction limit, was selected as the global indicator of scan abnormality, and the AD t sum was calculated as the sum over all t values of voxels with FDG uptake below the 95% age-adjusted prediction limit within the AD mask for each individual. Diagnostic accuracy for AD was determined by receiver operating characteristic analysis using the t sum and AD t sum (Herholz et al., 2002a). The usefulness of SPM was recognized by multicenter trials with 395 patients and 110 normal controls (Herholz et al., 2002) [Fig. 2].

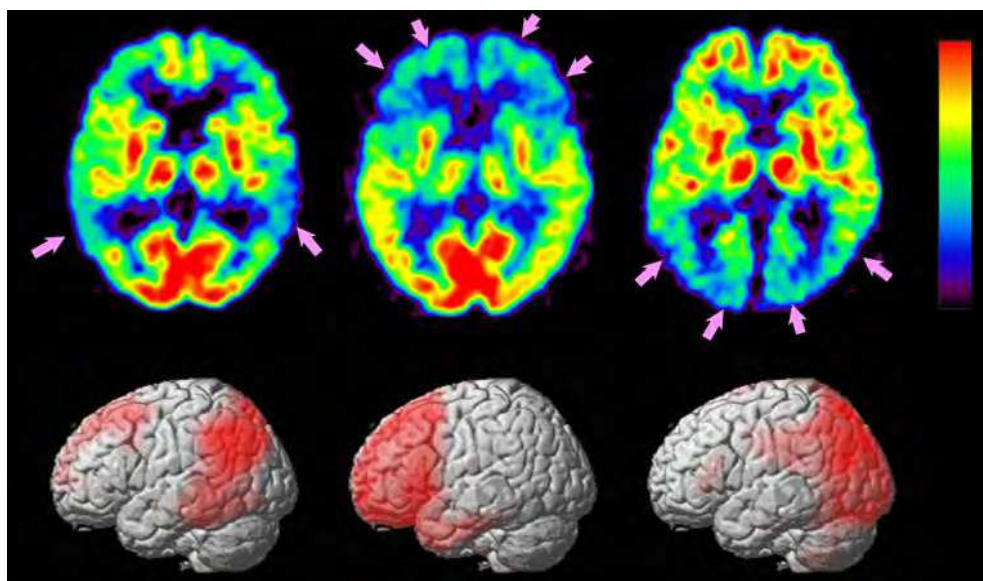


Fig. 2. FDG-PET study of AD (left column), FTD (center column), and DLB (right column) using SPM. Compared to normal scans (upper row), SPM analysis (lower row) disclosed reduced glucose metabolic sites (arrows) clearly and showed the characteristic patterns of 3 major diseases with dementia.

2.3 Distinctive abnormal pattern and possible causes

Reduction of glucose metabolism in AD patients was noted in the temporal and parietal lobes in early studies (Foster et al., 1984) and also in the posterior cingulate cortex (Herholz et al., 2002; Minoshima et al., 1997). Another study confirmed that glucose metabolism is reduced in the parietotemporal, frontal, and posterior cingulate cortices compared with normal individuals, and these reductions accord with the severity of dementia (Mosconi et al., 2005). FDG-PET mainly detects glucose consumption at the synapses (Kadekaro et al., 1985), and these synapses are insulted in the early stage of AD

(Masliah et al., 1991). Early loss of synapses is thought to occur in the hippocampus, especially in the entorhinal cortex. However, reduction of glucose metabolism has not been detected by FDG-PET in such regions. This interesting discordance between histopathological changes and FDG-PET findings may result from overall synaptic loss being milder in the hippocampus and entorhinal cortex than in the frontal or parietal lobe (Masliah et al., 1991).

Reduction of glucose metabolism in these regions remains asymmetric in the earlier stage of AD. As AD progresses, such asymmetrical reduction disappears and frontal involvement become evident (Jagust et al., 1988; Kumar et al., 1991). Other studies disclosed that the cerebellum and large regions of the association cortex are affected in contrast to the relative preservation of the basal ganglia, and motor and sensory cortices in the advanced stage of AD (Herholz et al., 1990; Ishii et al., 1997). Such atypical patterns should be considered as reduction in the bilateral temporal and parietal lobes is less severe in older patients (Grady et al., 1987; Mielke et al., 1992; Small et al., 1989).

The method of FDG-PET provides a highly consistent rate of accuracy compared to normal controls. Using the visual semiquantitative method, sensitivity was 92%, specificity was 83%, and accuracy was 87% (Azari et al., 1993; Burdette et al., 1996; Fazekas et al., 1989; Kippenhan et al., 1992; Scheurich et al., 2005). Quantitative methods showed that overall sensitivity was 94%, specificity was 87%, and accuracy was 91% (Duara et al., 1989; Herholz et al., 1990, 1993; Ishii et al., 2006; Kawachi et al., 2006; Mielke et al., 1994; Minoshima et al., 1995; Mosconi et al., 2005; Ng et al., 2007; Ohyama et al., 2000; Szelies et al., 1994; von Borczyskowski et al., 2006). Overall, the sensitivity was 94%, specificity was 85%, and accuracy was 90% (Ito et al., 2010).

We examined 500 patients with memory impairment by FDG-PET using the 3D-SSP method over approximately 5 years, using 33 subjects with average mini-mental state examination (MMSE) score of 30 as normal controls. The patients were divided into two groups, with MMSE score of 23 or less and 24 or over, to evaluate the age and sex distribution, type of abnormal findings and frequency, and presence of differences in MMSE between AD pattern and normal pattern. To assess the usefulness of FDG-PET for long-term follow up, AD pattern and normal pattern in patients with MMSE score of 24 or over followed up for over 3 years were compared with deterioration of MMSE, and the areas of deterioration were investigated using stereotactic extraction estimation. SPM was used to investigate the differences in the normal database between two institutes. Chi-square test, Fisher's exact test, and Student's t test were utilized to test for significant difference.

The 201 male and 291 female patients were aged from 20 to 90 years (mean 74.9±9.0 years). A total of 359 patients (72%) had MMSE score of 23 or less and 141 patients (28%) had MMSE score of 24 or over, and female predominance was recognized in both groups. The abnormal pattern was recognized in 97.2% of patients with MMSE score of 23 or less, consisting mainly of 77% with the AD pattern, followed by dementia with Lewy bodies (DLB) pattern. The abnormal pattern was recognized in 77% of patients with MMSE score of 24 or over, including 52% with the AD pattern, and 23% with the normal pattern. Significant differences were recognized in MMSE score between the AD pattern and normal pattern, in

both patients with MMSE score of 23 or less ($p=0.0188$) and with MMSE score of 24 or over ($p=1.63E-06$). Twenty-five patients with MMSE score of 24 or over have been followed up for over 3 years, 8 with the normal pattern and 17 with the AD pattern. No patient with normal pattern had deteriorated MMSE score, but 7 of 17 patients (41%) with AD pattern had deteriorated MMSE score, showing a significant difference ($p=0.0324$). This study confirmed that FDG-PET using ordinary imaging and statistical imaging can be helpful to identify patients with memory disturbance based on the MMSE score (Miyazawa et al., 2011) [Fig. 3].

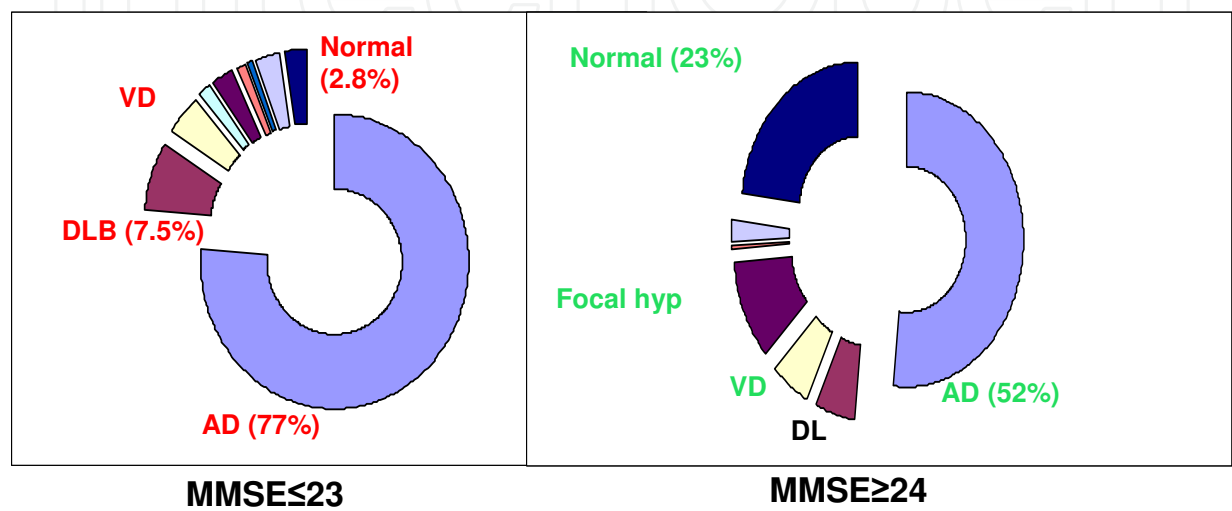


Fig. 3. Incidence of AD and AD-related disorders in 500 cases according to MMSE. In cases with MMSE score of 23 or less, 77% were AD and 2.8% were normal. In cases with MMSE score of 24 or over, 52% were AD and 23% were normal.

2.4 Prediction of deterioration

Prediction of clinical deterioration by FDG-PET may be affected by many bias factors preventing rigorous results, but FDG-PET could predict the occurrence of progressive dementia with sensitivity of 93% and specificity of 76% in 146 cases. Negative FDG-PET finding suggested that the pathological progression of cognitive impairment during a mean 3-year follow-up period was unlikely to occur (Silverman et al., 2001). A prospective longitudinal analysis showed a significant association between initial metabolic impairment and subsequent clinical deterioration. In patients with mild cognitive deficits at entry, the risk of deterioration was up to 4.7 times higher if the metabolism was severely impaired than with mild or absent metabolic impairment (Herholz et al., 1999). Study of a large number of cases (69 probable AD patients, 154 MCI patients, and 79 cognitively normal controls) revealed that the probable AD and MCI groups both had significant declines in 12-month glucose metabolism in the bilateral posterior cingulate, precuneus, medial parietal, lateral parietal, medial temporal, frontal, and occipital cortices ($p<0.001$). In each of these brain regions, the decline in AD patients was significantly greater than in the normal control group ($p<0.001$) (Chen et al., 2010). Careful and periodical follow up with PET study may predict the decline of AD patients [Fig. 4].

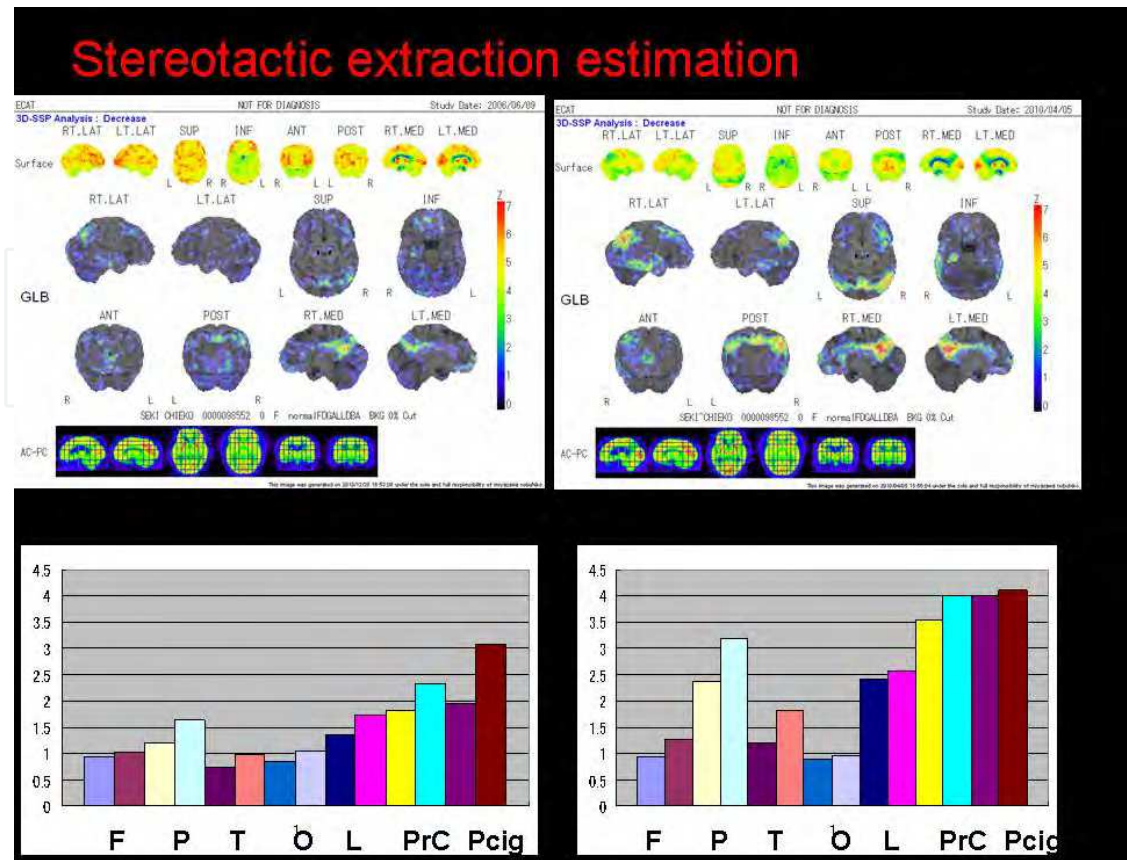


Fig. 4. Longitudinal study of FDG-PET in AD.

2.5 Correlation between FDG-PET and histopathology

Good correlations were found between metabolic reduction in the temporoparietal lobe on FDG-PET and histopathologically verified AD (DeCarli et al., 1992; McGeer et al., 1990; Mielke et al., 1996; Tedeschi et al., 1995). A study of 22 cases investigated whether bilateral temporo-parietal hypometabolism on FDG-PET is the metabolic abnormality associated with AD, and found the sensitivity of 93%, specificity of 63%, and accuracy of 82% could differentiate between AD and other AD-related disorders, confirming that such metabolic reduction is the classic abnormality associated with AD, and patients without AD pattern on FDG-PET should be suspected of AD-related disorders (Hoffman et al., 2000). Another study with 138 patients also reported that FDG-PET could identify AD and AD-related disorders with sensitivity of 94% and specificities of 73% and 78% (Silverman et al., 2001).

2.6 Imaging of treatment response and follow up

FDG-PET is helpful to observe the longitudinal aspect of metabolism in AD and AD-related disorders, as well as the efficacy of drug treatment (Diehl-Schmid et al., 2006; Drzezga et al., 2003; Nordberg et al., 2010). Serial FDG-PET findings elucidated the improvement in specific regions in patients treated with acetylcholinesterase inhibitors (Mega et al., 2001). Treatment effects with rivastigmine, galantamine, and citalopram were also clearly demonstrated by FDG-PET (Kadir et al., 2008; Mega et al., 2005; Smith et al., 2009; Teipel et al., 2006; Tune et

al., 2003). Another treatment using implantation of genetically modified neurotrophin-producing autologous fibroblast yielded improvement of glucose metabolism by FDG-PET (Tuszynski et al., 2005).

2.7 Comparison with MR imaging, single photon emission computed tomography (SPECT), and neuropsychiatric testing

Neuropsychiatric testing has sensitivity of 93% and specificity of 99% for the discrimination of patients with mild AD from healthy people (Buschke et al., 1997), but the overall sensitivity and specificity of clinical diagnosis in cases confirmed at autopsy and Class II articles by American Academy of Neurology rating system were 70–81% (Holmes et al., 1999; Jobst et al., 1998; Lim et al., 1999). Many factors involved with PET and clinical testing contribute to the difficulty in judging prevalence, but overall accuracy of PET is no worse than the accuracy of clinical diagnosis (Minoshima, 2003).

Studies with no direct comparison found sensitivity of 93% and specificity of 74% using SPECT (Read et al., 1995), and 96% and 89% (Jobst et al., 1994). Initial regional cerebral blood flow SPECT studies of MCI may be useful in predicting patients who will develop AD in the near future (Hirao et al., 2005). Studies with direct comparison found that PET is the superior modality both for discrimination of patients with AD from normal individuals and predicting deterioration in MCI (Döbert et al., 2005; Herholz et al., 2002). Recently, comparison of SPECT, MR imaging, CSF biomarker, and PET in 207 patients with probable AD found AD findings in 81.6% with SPECT and 93.1% with PET (Morinaga et al., 2010).

Abnormal findings by MR imaging in the entorhinal cortex have a high predictive value for incipient disease in patients with MCI (deToledo-Morrell et al., 2004; Pennanen et al., 2004). Measurements of hippocampal atrophy by MR imaging can distinguish AD patients from cognitively normal elderly people with 80–90% accuracy (Jagust et al., 2006). Studies with direct comparison showed PET provided better diagnostic accuracy than MR imaging for hippocampus atrophy with accuracies of 73% and 73% in normal individuals and MCI patients, respectively, 91% and 83% in normal individuals and AD patients, respectively, and for middle/inferior and superior temporal gyrus atrophy with accuracies of 100% and 78% in normal individuals and AD patients, respectively (De Santi et al., 2001). AD findings were observed in 77.4% with MR imaging, and 93.1% with PET in 207 patients with probable AD (Morinaga et al., 2010). Further investigations and analysis will be needed to confirm the importance of PET.

3. FDG-PET imaging of MCI

3.1 Criteria and clinical importance of MCI

MCI was first proposed to represent subjective memory impairment and memory impairment by memory test, defined as a score of less than 1.5 standard deviations below the age-matched control, with no dementia and preserved activities of daily living (Petersen et al., 1999). MCI was subsequently classified into 3 subtypes, amnesic type, multiple cognitive domains slightly impaired type, and single non-memory domain impaired type in 2001, with Petersen's type equivalent to the amnesic type. New criteria were proposed to include amnesic MCI single domain, amnesic MCI multiple domain, non-amnesic MCI

single domain, and non-amnestic MCI multiple domain types (Petersen & Morris, 2005). The prevalence of MCI differs between nations and depends on the definition of MCI, but values of approximately 3% are reported from many countries (Panza et al, 2005).

The annual progression rate of amnestic MCI to AD is around 12%, which is significantly higher than that of age-matched non-MCI subjects over 15 years (Petersen & Morris, 2003). On the other hand, 10% of MCI cases did not progress to AD. Meta-analysis of 19 studies showed the annual conversion rate has an average of 10% (Bruscoli & Lovestone, 2004). Clinical features of high rate conversion are high age, female, low score in MMSE, high score in Clinical Dementia Rating or Geriatric Depression Scale, over 4 in Hachinski Ischemic Score, and presence of allele type of ApoE4 (Morris et al., 2006). Such findings strongly indicate that MCI or amnestic MCI should be followed up to monitor progression to AD.

3.2 Abnormal findings and prediction of MCI progression to AD on FDG-PET

Glucose metabolism in the entorhinal cortex was reported to be the most reliable method for discriminating MCI patients from normal individuals (De Santi et al., 2001). MCI patients also had glucose metabolic reduction in the hippocampus, and this reduction was prominent in amnestic MCI (Clerici et al., 2009; Jauhiainen et al., 2008; Mosconi et al., 2005). After correction for the partial volume effect, glucose metabolism reduction in the temporoparietal cortex has become the core finding in MCI rather than glucose metabolism reduction in the hippocampus (Chételat et al., 2008).

Investigation of the prediction of progression from MCI to AD in a small number of cases examined (17 to 20 cases) found progression occurred in 41% to 50% of cases during 18 months to 3 years, associated with glucose metabolism reduction in the association cortex, bilateral temporoparietal cortices, and left temporal cortex (Arnáiz et al., 2001; Berent et al., 1999; Chételat et al., 2003; Morbelli et al., 2010). Study of a larger number of cases (30 to 85 cases) found progression in 29% to 40% of cases during 16 months to 2 years, associated with glucose metabolism reduction in the bilateral parietal and posterior cingulate cortices, bilateral temporoparietal and posterior cingulate cortices, and posterior cingulate cortex (Anchisi et al., 2005; Drzezga et al., 2005; Landau et al., 2010). In our study, 16 of 30 patients with MCI (53%) progressed to AD during 5 years, associated with glucose metabolism reduction in the posterior cingulate cortex and temporoparietal cortex. Another study showed that glucose metabolism reduction in the frontal lobe might also be predictive of MCI progression to AD, and the ApoE-ε4 genotype may be related to impairment of the frontal cortex (Drzezga et al., 2003; Mosconi et al., 2004).

Longitudinal or comparison trials of brain MR imaging and FDG-PET in 20 amnestic MCI patients and 12 controls with mean follow up of about 2 years identified 9 patients who progressed to AD. The discordant topography between atrophy and hypometabolism reported in AD was already present at the amnestic MCI stage. Posterior cingulate-precuneus hypometabolism seemed to be an early sign of memory deficit, whereas hypometabolism in left temporal cortex marked the progression to AD (Morbelli et al., 2010). A comparison study evaluated ApoE-ε4 allele frequency, CSF proteins, glucose metabolism using FDG-PET, hippocampal volume by MR imaging, and episodic memory performance in patients with amnestic MCI (n=85). Baseline FDG-PET and episodic memory predicted progression to AD. CSF proteins and, marginally, FDG-PET predicted

longitudinal cognitive decline (Landau et al., 2010). Estimation of trials using the large number of cases examined suggested 66 AD patients or 217 MCI patients per treatment group were necessary to detect a 25% AD-slowng treatment effect in a 12-month, multi-center randomized clinical trial with 80% power and two-tailed $\alpha=0.05$ (Chen et al., 2010). These findings show the advantages of FDG-PET over conventional trials using neuropsychological testing.

4. FDG-PET imaging of normal individuals

Studies of AD and MCI have suggested that early diagnosis is essential to identify and treat individuals at risk before irreversible neuronal damage occurs. Improved brain imaging like FDG-PET and other methods are promising tools for the early detection of dementia and related disorders.

Two studies reported that normal individuals with the ApoE- $\epsilon 4$ allele and family history of AD had reduced glucose metabolism in the temporoparietal association area (Reiman et al., 1996; Small et al., 1995). Another study found individuals with the ApoE- $\epsilon 4$ allele had metabolic reduction in the temporoparietal and posterior cingulate cortices at about 2% per year (Small et al., 2000). MR imaging-guided FDG-PET disclosed that 12 individuals (25%) demonstrated cognitive decline in a 3-year longitudinal study of 48 healthy normal elderly subjects, associated with hypometabolism in the temporal lobe neocortex and hippocampus, and that ApoE E4 carrier showed marked longitudinal temporal neocortex metabolic reduction in subjects who declined (de Leon et al., 2001). A maternal history of AD was a strong association factor in reduced glucose metabolism (Mosconi et al., 2007, 2009). FDG-PET and additional CSF study showed that the combination of CSF and glucose metabolism significantly improved the accuracy of either measure in discriminating ApoE groups (86% accuracy, odds ratio=4.1, $p<0.001$) and normal ApoE E4 carrier with subjective memory complaint from all other subgroups (86% accuracy, odds ratio= 3.7, $p=0.005$). Parahippocampal gyrus glucose metabolism was the most accurate discriminator of subjective memory complaint groups (75% accuracy, odds ratio=2.4, $p<0.001$) (Mosconi et al., 2008). However, a longitudinal assessment of CSF and FDG-PET biomarkers is necessary to determine the usefulness of any combination (Petrie et al., 2009). Another association study with FDG-PET and MR imaging for prediction of cognitive decline in normal individuals disclosed that among 60 cognitively intact older individuals with mean follow up of 3.8 years, 6 subjects (10%) developed incident dementia or cognitive impairment, suggesting that reductions in temporal and parietal glucose metabolism predict decline in global cognitive function, and reductions in medial temporal brain volumes predict memory decline in normal older individuals (Jagust et al., 2006). Investigation of a larger number of cases is necessary to evaluate the efficacy of FDG-PET or other methods.

5. ADNI

Recently, several methods (biomarkers) have been investigated other than FDG-PET, including MR imaging, CSF/blood biochemical marker, amyloid detecting PET (PIB-PET), and genetic biomarker, to improve the accuracy of diagnosis of AD, MCI, and prodromal AD, and to monitor the progression of these diseases and treatment effects. The most

reliable and valid biomarker for the treatment of AD should be identified within current limitations, but the number of such biomarkers is unclear.

The ADNI has been launched as described elsewhere (Chen et al., 2010; Mueller et al., 2005; Weiner et al., 2010). Briefly, the ADNI started in October 2004 in USA and Canada as a large, multi-center, longitudinal study of 822 older adults, consisting of 188 with probable AD, 405 with amnesic MCI, and 299 cognitively normal controls, followed up at 58 clinical institutes for 5 years. All patients underwent clinical ratings, neuropsychological testing, 1.5 T volumetric MR imaging, and blood and urine sampling at every visit, half of the subjects also underwent FDG-PET or 3 T MR imaging at every visit, a smaller number underwent PIB-PET, and more than half underwent CSF evaluation. Funding for the ADNI ended on October 1, 2010. Over 60 papers had been published by May 2010 (Weiner et al., 2010).

Baseline regional cerebral metabolic rate for glucose (CMRgl) measurement by FDG-PET was compared in 74 AD patients, 142 amnesic MCI patients, and 82 cognitively normal controls, and a correlation between CMRgl and clinical disease severity was observed, in comparison with normal controls. The AD and amnesic MCI patients had significantly lower CMRgl in the bilateral posterior cingulate, precuneus, parietotemporal, and frontal cortices. Clinical disease severity or lower MMSE scores were also correlated with lower CMRgl (Langbaum et al., 2009). Twelve-month follow-up study estimated the need for 66 AD patients or 217 MCI patients per treatment group to detect a 25% AD-slowing treatment effect in a 12-month, multi-center randomized clinical trial with 80% power and two-tailed $\alpha=0.05$, roughly one-tenth of the number of patients needed to study MCI patients using clinical endpoints. These findings support the use of FDG-PET, brain-mapping algorithms, and empirically pre-defined statistical regions of interests in the randomized clinical trials of AD-slowing treatments (Chen et al., 2010).

In the near future, the results of ADNI-like studies are expected from Australia, Europe, Korea, and Japan, started since 2007 aiming at total of 600 cases including 300 MCI, 150 AD, and 150 normal controls, and over 460 cases have been enrolled and over 300 cases examined by FDG-PET in January 2011 in Japan. Analysis of the data and also further trials like ADNI-2 will be needed to confirm the findings.

6. FDG-PET imaging of AD-related disorders

6.1 Fronto-temporal dementia (FTD)

Discrimination of AD and FTD currently depend on the clinical history and examination, but FDG-PET shows different patterns of hypometabolism in these disorders that might aid differential diagnosis. A series of 45 patients with pathologically confirmed AD (n=31) or FTD (n=14) were investigated using five separate methods including FDG-PET SSP metabolic and statistical maps. Visual interpretation of SSP images was superior to clinical assessment and had the best inter-rater reliability (mean $\kappa=0.78$) and diagnostic accuracy (89.6%), as well as the highest specificity (97.6%) and sensitivity (86%), and positive likelihood ratio for FTD (36.5). The addition of FDG-PET to clinical summaries increased diagnostic accuracy and confidence for both AD and FTD. Visual interpretation of FDG-PET after brief training is more reliable and accurate in distinguishing FTD from AD than only

clinical methods. FDG-PET adds important information that appropriately increases diagnostic confidence, even among experienced dementia specialists (Foster et al., 2007).

Twenty-one patients with clinical diagnosis of FTD, 21 patients matched for age, sex, and dementia severity- with probable AD and 21 normal control subjects matched for age and sex were studied by measuring the CMRgl with FDG-PET. In the FTD group, CMRgl was preserved only in the left cerebellum, right sensorimotor area, and occipital lobes. The CMRgl was significantly lower in the FTD group as opposed to the AD group in the hippocampi, orbital gyri, anterior temporal lobes, anterior cingulate gyri, basal ganglia, thalami, middle and superior frontal gyri, and left inferior frontal gyrus. Metabolic abnormality associated with FTD is predominant in the frontal and anterior temporal lobes, and the subcortical structures, but is more widespread than previously believed (Ishii et al., 1998). On the other hand, patients with progressive supranuclear palsy and progressive subcortical gliosis have similar findings (D'Antona et al., 1985; Foster et al., 1986, 1992). The cost of FDG-PET to discriminate AD from FTD has only been covered by insurance in the USA since 2003.

6.2 DLB

The clinical criteria of DLB are rather complicated and the differential diagnosis of Parkinson disease, Parkinson disease dementia, and DLB is difficult. Glucose hypometabolism in the occipital lobe was recognized as a distinctive abnormality in DLB with relative preservation of hippocampal glucose metabolism compared to AD (Higuchi et al., 2000; Imamura et al., 1997; Ishii et al., 1998). The study of morphologic and functional changes in patients with mild DLB compared with patients with AD were investigated in 20 patients with very mild DLB, 20 patients with very mild AD, and 20 healthy volunteers matched for age and sex (normal controls) by both FDG-PET and 3D spoiled gradient echo MR imaging. In DLB patients, volumetric data indicated a significant volume decrease in the striatum, whereas FDG-PET showed significant glucose metabolic reductions in the temporal, parietal, and frontal areas, including the occipital lobe, compared with the normal controls. In contrast, both the hippocampal volume and glucose metabolism were significantly decreased in AD patients, whereas the occipital volume and metabolism were preserved. Comparison of very mild DLB and AD revealed different morphologic and metabolic changes in the medial temporal lobes and the occipital lobe, demonstrating characteristic pathophysiologic differences between these diseases (Ishii et al., 2007).

Parkinson disease dementia and DLB share many similar aspects, and the differential clinical diagnosis relies heavily on an arbitrary criterion, the so-called 1-year rule. One study of 16 patients with Parkinson disease, 13 patients with Parkinson disease dementia, and 7 patients with DLB performed FDG-PET and reconstructed images by iterative reconstruction using computed tomography scans, normalized to a standard template. Compared with patients with Parkinson disease, both Parkinson disease dementia and DLB patients had similar patterns of decreased metabolism in bilateral inferior and medial frontal lobes, and right parietal lobe. In a direct comparison, DLB patients had significant metabolic decrease in the anterior cingulate cortex compared with those with Parkinson disease dementia. These findings support the concept that Parkinson disease dementia and DLB have similar underlying neurobiological characteristics, and can be regarded as a spectrum of Lewy body

disorders (Yong et al., 2007). The diagnostic accuracy of FDG-PET -for AD versus DLB confirmed at autopsy was sensitivity of 90% and specificity of 80% (Minoshima, 2003).

An interesting study of occurrence of visual hallucination in DLB revealed that reduction of glucose metabolism in the visual association cortex may be involved in the occurrence of visual hallucination (Pernecky et al., 2008). Furthermore, we reported that the presence of hypermetabolic areas in the cerebellum, basal ganglia, or motor cortex may be related to the occurrence of visual hallucination in 22 DLB patients (Miyazawa et al., 2010) [Fig. 5].

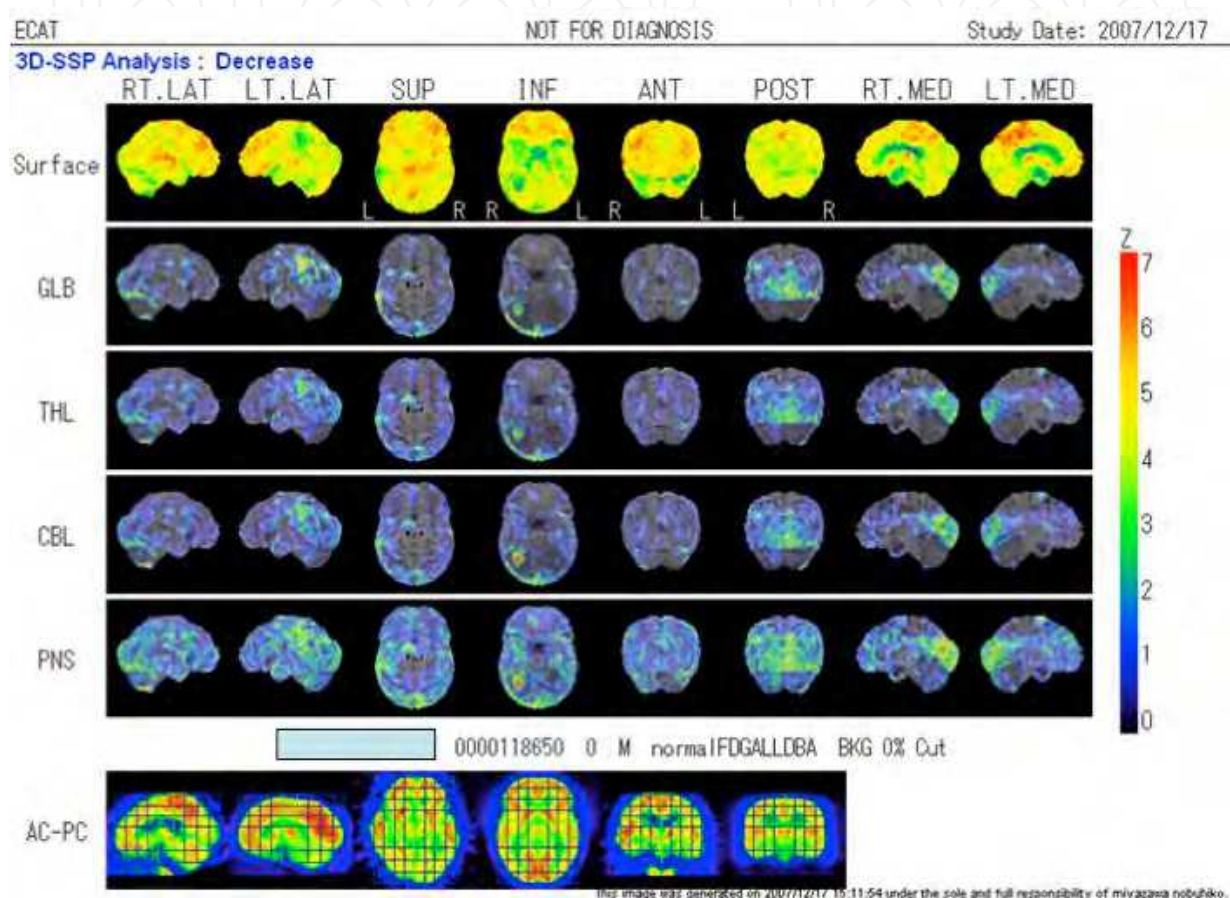


Fig. 5. FDG-PET study of DLB. Hypometabolism in the bilateral occipital lobes and posterior cingulate cortices is clearly detected by Z-score mapping with 3D-SSP.

6.3 Vascular dementia

The diagnosis of vascular dementia by MR imaging or FDG-PET is difficult because pathological changes characteristic of both AD and vascular dementia often co-exist. White matter hyperintensity on MR imaging and lacunar infarction may contribute to reduction in cerebral blood flow and glucose metabolism (DeCarli et al., 1996; Miyazawa et al., 1997). Several studies tried to identify distinctive patterns for vascular dementia on FDG-PET, but due to the limitations of the visual method on FDG-PET, no definitive finding could be obtained (De Reuck et al., 1998; Mielke et al., 1994; Sultzer et al., 1995). However, analysis using SPM and 3-D SSP could detect more precise and subtle differences between AD and vascular dementia. Comparison of the regional metabolic patterns on FDG-PET from 18

patients with subcortical vascular MCI and 25 patients with amnesic MCI matched for age, sex, education, and MMSE score, and 35 healthy subjects, using voxel-wise analysis with SPM 2 for statistical analysis revealed that relative to normal controls, hypometabolic regions in the amnesic MCI patients were located in the bilateral parahippocampal and posterior cingulate cortices, left superior temporal gyri, left inferior parietal lobule, and right inferior frontal gyrus, whereas hypometabolic regions in the subcortical vascular MCI patients were located in the thalamus, insula, superior temporal gyrus, anterior cingulate gyrus, cingulum, right basal ganglia, cerebellum, and brainstem. Further direct comparison of glucose metabolism between subcortical vascular MCI and amnesic MCI showed that glucose hypometabolism in patients with subcortical vascular MCI was more severe in the thalamus, brainstem, and cerebellum, suggesting that subcortical vascular MCI is distinct from amnesic MCI in terms of neuropsychological and PET findings, which may explain their clinical manifestations (Seo et al., 2009). Application of a novel voxel-based multivariate technique to a large FDG-PET data set from 153 subjects, with probable subcortical vascular dementia, probable AD, and normal controls in one third each, showed that lower metabolism differentiating vascular dementia from AD mainly occurred in the deep gray nuclei, cerebellum, primary cortices, middle temporal gyrus, and anterior cingulate gyrus, whereas lower metabolism in AD versus vascular dementia occurred mainly in the hippocampal region and orbitofrontal, posterior cingulate, and posterior parietal cortices. The hypometabolic pattern common to vascular dementia and AD mainly occurred in the posterior parietal, precuneus, posterior cingulate, prefrontal, and anterior hippocampal regions, and linearly correlated with the MMSE. This study shows the potential of voxel-based multivariate methods to highlight independent functional networks in dementia diseases. By maximizing the separation between groups, this method extracted a metabolic pattern that efficiently differentiated vascular dementia and AD with 100% accuracy (Kerrouche et al., 2006). A recent study of 48 subjects (12 with AD, 12 with vascular disease and dementia, 12 with vascular disease without dementia, and 12 healthy controls) with FDG-PET using SPM 2 showed the independent pattern of vascular dementia was glucose metabolic reduction in the thalamus, caudate, and frontal lobe (Pascual et al., 2010). Validation study with postmortem will be needed to confirm these newly-emerged patterns.

6.4 Neurodegenerative disorders showing dementia

6.4.1 Creutzfeldt-Jakob disease

Creutzfeldt-Jakob disease is a rare prion-associated disorder within the dementia spectrum. Only a few cases have been reported in terms of the FDG-PET findings of Creutzfeldt-Jakob disease (Engler et al., 2003; Henkel et al., 2002; Nagasaka et al., 2011). Study with FDG-PET only found that all 8 patients had reduction of CMRgl in at least one temporal or parietal region. The occipital lobe, the cerebellum, or the basal ganglia were involved in another 7 cases. These findings differ from typical patterns of hypometabolism in AD and other neurodegenerative disorders. The distribution was markedly asymmetric in two thirds of the cases. In three of four patients with visual symptoms, FDG uptake was reduced in the bilateral visual cortices. Typical hyperintensity on MR imaging was only found in two of the eight cases at the time of PET studies, which demonstrates that FDG-PET appears to be a sensitive investigation for

Creutzfeldt-Jakob disease and could be useful to differentiate Creutzfeldt-Jakob disease from other neurodegenerative disorders (Henkel et al., 2002). Another study with a relatively large number of cases showed that FDG-PET revealed, in comparison with normal controls, a typical pattern characterized by a pronounced regional decrease in CMRgl in 8 cases, indicative of neuronal dysfunction. These changes were most pronounced in the cerebellum, and the frontal, occipital, and parietal cortices, whereas the pons, the thalamus, and the putamen were less affected, and the temporal cortex appeared unaffected. FDG-PET gave a different pattern in 3 of 15 cases, so hypermetabolism was present in parts of the brain, particularly in the temporal lobes and basal ganglia, which could suggest encephalitis (Engler et al., 2003). We also reported a case with hypermetabolism in the cortical region (Nagasaka et al., 2011). FDG-PET can be used to detect the stage of encephalitis in Creutzfeldt-Jakob disease [Fig. 6].

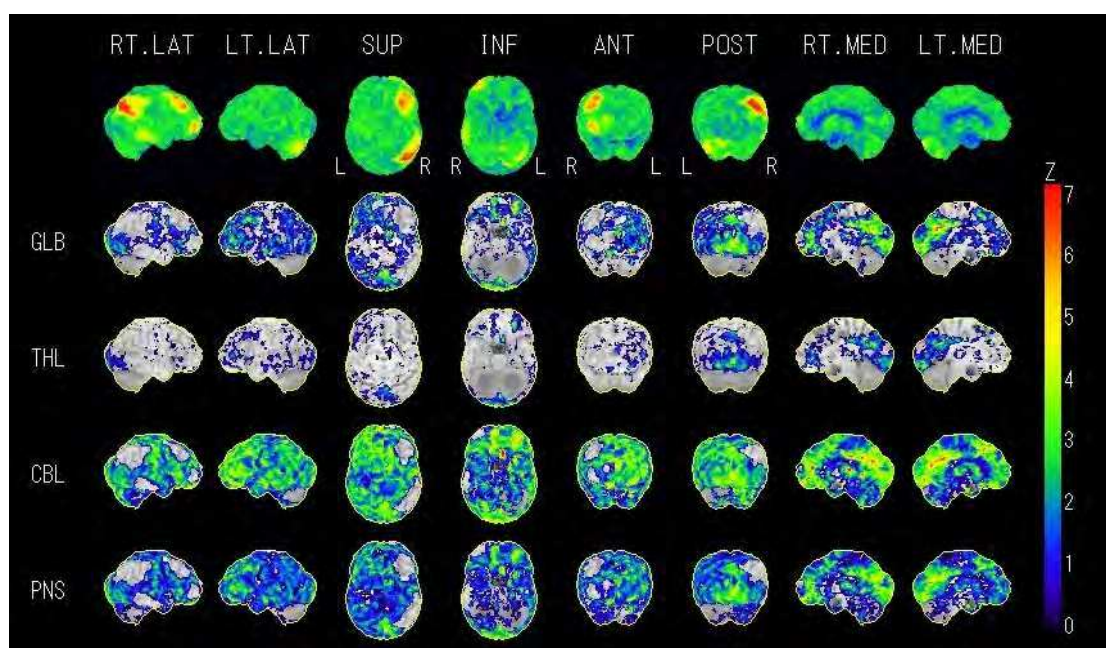


Fig. 6. FDG-PET study of Creutzfeldt-Jakob disease. Hypometabolism and hypermetabolism are both present.

6.4.2 Huntington disease

Huntington disease is another rare hereditary neurodegenerative disorder with characteristic symptoms of cognitive impairment and involuntary movement. FDG-PET of symptomatic Huntington disease found typical metabolic reduction in the striatum (Kuwert et al., 1990; Young et al., 1987) [Fig. 7]. In contrast, the consensus for FDG-PET in presymptomatic individuals at risk or in the early stage has not yet been reached (Hayden et al., 1987; Mazziotta et al., 1987). Cross-sectional study with FDG-PET in 18 presymptomatic individuals and 13 early-stage Huntington disease patients demonstrated significant metabolic covariance patterns characterized by caudate and putaminal glucose hypometabolism and metabolic reduction in the mediotemporal region, as well as relative hypermetabolism in the occipital cortex (Feigin et al., 2001). A longitudinal study of 71 cases in the symptomatic and presymptomatic stages using FDG-PET and MR imaging revealed

that individuals at risk and symptomatic Huntington disease patients had significant glucose metabolic reduction in the cortex and striatum, and more importantly that Huntington disease patients had progressive white matter reduction in the preclinical stage, and decreased glucose uptake in the cortex and striatum in affected and preclinical individuals, suggesting that white matter volume reduction may precede gray matter reduction (Ciarmiello et al., 2006). FDG-PET can detect early signs of changes and is especially helpful in longitudinal studies [Table 1].

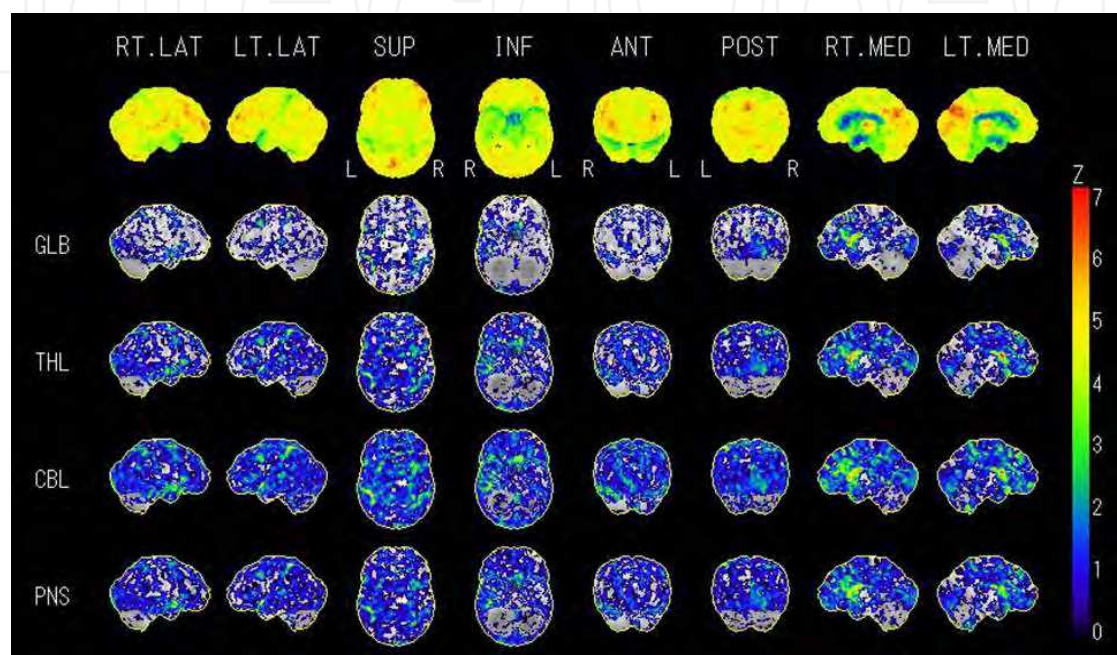


Fig. 7. FDG-PET study of Huntington disease. Hypometabolism is clearly recognized in the caudate and putamen by 3D-SSP.

Name of diseases and disorders	Regions with hypometabolism on FDG-PET
Alzheimer's disease (AD)	precuneus and posterior cingulate cortex temporoparietal association cortex (frontolateral association cortex)
Fronto-temporal dementia (FTD)	frontotemporal cortex
Dementia with Lewy bodies (DLB)	primary visual cortex (same as in AD)
Vascular dementia	dependent on vascular territories affected, usually with laterality
Creutzfeldt-Jakob disease	dependent on cortex affected, similar findings to AD
Huntington disease	putamen and caudate nucleus (thalamus and other basal ganglia)

Table 1. Characteristic findings on FDG-PET in AD and related disorders

7. Conclusion

For 30 years, FDG-PET has been applied to investigate the functional metabolic aspects of AD and related disorders. Approximately 15–10 years ago, the helpfulness of FDG-PET was established using rigorous and valid analyzing software like 3-D SSP or SPM compared to postmortem data, and the sensitivity, specificity, and accuracy of FDG-PET are over 90%. FDG-PET is very useful for the elucidation of the cross-sectional and longitudinal aspects of probable AD, and the monitoring of progression of MCI to AD and normal individuals at risk. Furthermore, differential diagnosis of AD from FTD by FDG-PET is helpful and valid in clinical settings. In parallel with the progress in FDG-PET, other methods like MR imaging using voxel-based volumetry and measuring specific proteins in the blood or CSF have emerged as promising tools for the diagnosis of AD and progression of MCI to AD. The ADNI trial was launched in the USA, and was followed by Europe, Australia, Korea, and Japan. The main concerns are identifying the most powerful probe in future clinical trials and the optimum combinations to minimize the cost burden. Given the several limitations of FDG-PET, this review illustrates that FDG-PET remains a helpful and pivotal tool in clinical studies and trials.

8. References

- American Psychiatric Association. (2000). *Diagnostic and Statistical Manual of Mental Disorders, Fourth Edition, Text Revision (DSM-IV-TR)*, American Psychiatric Publishing, ISBN 0-89042-024-6, Arlington, VA
- Anchisi, D.; Borroni, B., Franceschi, M., Kerrouche, N., Kalbe, E., Beuthien-Beumann, B., Cappa, S., Lenz, O., Ludecke, S., Marcone, A., Mielke, R., Ortelli, P., Padovani, A., Pelati, O., Pupi, A., Scarpini, E., Weisenbach, S., Herholz, K., Salmon, E., Holthoff, V., Sorbi, S., Fazio, F. & Perani, D. (2005). Heterogeneity of Brain Glucose Metabolism in Mild Cognitive Impairment and Clinical Progression to Alzheimer Disease. *Archives of Neurology*, Vol.62, No.11, (November 2005), pp. 1728-1733, ISSN 0003-9942
- Arnáiz, E.; Jelic, V., Almkvist, O., Wahlund, L.O., Winblad, B., Valind, S. & Nordberg, A. (2001). Impaired Cerebral Glucose Metabolism and Cognitive Functioning Predict Deterioration in Mild Cognitive Impairment. *Neuroreport*, Vol.12, No.4, (March 2001), pp. 851-855, ISSN 0959-4965
- Azari, N.P.; Pettigrew, K.D., Schapiro, M.B., Haxby, J.V., Grady, C.L., Pietrini, P., Salerno, J.A., Heston, L.L., Rapoport, S.I. & Horwitz, B. (1993). Early Detection of Alzheimer's Disease: a Statistical Approach Using Positron Emission Tomographic Data. *Journal of Cerebral Blood Flow and Metabolism*, Vol.13, No.3, (May 1993), pp. 438-447, ISSN 0271-678X
- Benson, D.F.; Kuhl, D.E., Phelps, M.E., Cummings, J.L. & Tsai, S.Y. (1981). Positron Emission Computed Tomography in the Diagnosis of Dementia. *Transactions of the American Neurological Association*, Vol.106, pp. 68-71, ISSN 0065-9479
- Berent, S.; Giordani, B., Foster, N., Minoshima, S., Lajiness-O'Neill, R., Koeppe, R. & Kuhl, D.E. (1999). Neuropsychological Function and Cerebral Glucose Utilization in Isolated Memory Impairment and Alzheimer's Disease. *Journal of Psychiatric Research*, Vol.33, No.1, (January-February 1999), pp. 7-16, ISSN 0022-3956

- Blennow, K. & Hampel, H. (2003). CSF Markers for Incipient Alzheimer's Disease. *Lancet Neurology*, Vol.2, No.10, (October 2003), pp. 605-613, ISSN 1474-4422
- Bruscoli, M. & Lovestone, S. (2004). Is MCI Really Just Early Dementia? A Systematic Review of Conversion Studies. *International Psychogeriatrics / IPA*, Vol.16, No.2, (June 2004), pp. 129-140, ISSN 1041-6102
- Burdette, J.H.; Minoshima, S., Vander Borgh, T., Tran, D.D. & Kuhl, D.E. (1996). Alzheimer Disease: Improved Visual Interpretation of PET Images by Using Three-Dimensional Stereotaxic Surface Projections. *Radiology*, Vol.198, No.3, (March 1996), pp. 837-843, ISSN 0033-8419
- Buschke, H.; Sliwinski, M.J., Kuslansky, G. & Lipton, R.B. (1997). Diagnosis of Early Dementia by the Double Memory Test: Encoding Specificity Improves Diagnostic Sensitivity and Specificity. *Neurology*, Vol.48, No.4, (April 1997), pp. 989-997, ISSN 0028-3878
- Chen, K.; Langbaum, J.B., Fleisher, A.S., Ayutyanont, N., Reschke, C., Lee, W., Liu, X., Bandy, D., Alexander, G.E., Thompson, P.M., Foster, N.L., Harvey, D.J., de Leon, M.J., Koeppe, R.A., Jagust, W.J., Weiner, M.W. & Reiman, E.M; Alzheimer's Disease Neuroimaging Initiative. (2010). Twelve-Month Metabolic Declines in Probable Alzheimer's Disease and Amnesic Mild Cognitive Impairment Assessed Using an Empirically Pre-defined Statistical Region-of-Interest: Findings from the Alzheimer's Disease Neuroimaging Initiative. *NeuroImage*, Vol.51, No.2, (June 2010), pp. 654-664, ISSN 1053-8119
- Chételat, G.; Desgranges, B., de la Sayette, V., Viader, F., Eustache, F. & Baron, J.C. (2003). Mild Cognitive Impairment: Can FDG-PET Predict Who is to Rapidly Convert to Alzheimer's Disease? *Neurology*, Vol.60, No.8, (April 2003), pp. 1374-1377, ISSN 0028-3878
- Chételat, G.; Fouquet, M., Kalpouzos, G., Denghien, I., De la Sayette, V., Viader, F., Mézenge, F., Landeau, B., Baron, J.C., Eustache, F. & Desgranges, B. (2008). Three-Dimensional Surface Mapping of Hippocampal Atrophy Progression from MCI to AD and Over Normal Aging as Assessed Using Voxel-Based Morphometry. *Neuropsychologia*, Vol.46, No.6, pp. 1721-1731, ISSN 0028-3932
- Ciarmiello, A.; Cannella, M., Lastoria, S., Simonelli, M., Frati, L., Rubinsztein, D.C. & Squitieri F. (2006). Brain White-Matter Volume Loss and Glucose Hypometabolism Precede the Clinical Symptoms of Huntington's Disease. *Journal of Nuclear Medicine*, Vol.47, No.2, (February 2006), pp. 215-222, ISSN 0161-5505
- Clerici, F.; Del Sole, A., Chiti, A., Maggiore, L., Lecchi, M., Pomati, S., Mosconi, L., Lucignani, G. & Mariani, C. (2009). Differences in Hippocampal Metabolism between Amnesic and Non-amnesic MCI Subjects: Automated FDG-PET Image Analysis. *The Quarterly Journal of Nuclear Medicine and Molecular Imaging*, Vol.53, No.6, (December 2009), pp. 646-657, ISSN 1824-4785
- Convit, A.; de Asis, J., de Leon, M.J., Tarshish, C.Y., De Santi, S. & Rusinek, H. (2000). Atrophy of the Medial Occipitotemporal, Inferior, and Middle Temporal Gyri in Non-demented Elderly Predict Decline to Alzheimer's Disease. *Neurobiology of Aging*, Vol.21, No.1, (January-February 2000), pp. 19-26, ISSN 0197-4580
- D'Antona, R.; Baron, J.C., Samson, Y., Serdaru, M., Viader, F., Agid, Y. & Cambier, J. (1985). Subcortical Dementia. Frontal Cortex Hypometabolism Detected by Positron

- Tomography in Patients with Progressive Supranuclear Palsy. *Brain*, Vol.108, Part 3, (September 1985), pp. 785-799, ISSN 0006-8950
- de Leon, M.J.; Ferris, S.H., George, A.E., Reisberg, B., Christman, D.R., Kricheff I.I. & Wolf, A.P. (1983). Computed Tomography and Positron Emission Transaxial Tomography Evaluations of Normal Aging and Alzheimer's Disease. *Journal of Cerebral Blood Flow and Metabolism*, Vol.3, No.3, (September 1983), pp. 391-394, ISSN 0271-678X
- de Leon, M.J.; Convit, A., Wolf, O.T., Tarshish, C.Y., DeSanti, S., Rusinek, H., Tsui, W., Kandil, E., Scherer, A.J., Roche, A., Imossi, A., Thorn, E., Bobinski, M., Caraos, C., Lesbre, P., Schlyer, D., Poirier, J., Reisberg, B. & Fowler, J. (2001). Prediction of Cognitive Decline in Normal Elderly Subjects with 2-[(18)F]Fluoro-2-Deoxy-D-Glucose/Positron-Emission Tomography (FDG/PET). *Proceedings of the National Academy of Sciences of the United States of America*, Vol.98, No.19, (September 2001), pp. 10966-10971, ISSN 0027-8424
- De Reuck, J.; Decoo, D., Marchau, M., Santens, P., Lemahieu, I. & Strijckmans, K. (1998). Positron Emission Tomography in Vascular Dementia. *Journal of the Neurological Sciences*, Vol.154, No.1, (January 1998), pp. 55-61, ISSN 0022-510X
- De Santi, S.; de Leon, M.J., Rusinek, H., Convit, A., Tarshish, C.Y., Roche, A., Tsui, W.H., Kandil, E., Boppana, M., Daisley, K., Wang, G.J., Schlyer, D. & Fowler, J. (2001). Hippocampal Formation Glucose Metabolism and Volume Losses in MCI and AD. *Neurobiology of Aging*, Vol.22, No.4, (July-August 2001), pp. 529-539, ISSN 0197-4580
- DeCarli, C.; Haxby, J.V., Gillette, J.A., Teichberg, D., Rapoport, S.I. & Schapiro, M.B. (1992). Longitudinal Changes in Lateral Ventricular Volume in Patients with Dementia of the Alzheimer Type. *Neurology*, Vol.42, No.10, (October 1992), pp. 2029-2036, ISSN 0028-3878
- DeCarli, C.; Grady, C.L., Clark, C.M., Katz, D.A., Brady, D.R., Murphy, D.G., Haxby, J.V., Salerno, J.A., Gillette, J.A., Gonzalez-Aviles, A. & Rapoport, S.I. (1996). Comparison of Positron Emission Tomography, Cognition, and Brain Volume in Alzheimer's Disease with and without Severe Abnormalities of White Matter. *Journal of Neurology, Neurosurgery, and Psychiatry*, Vol.60, No.2, (February 1996), pp. 158-167, ISSN 0022-3050
- deToledo-Morrell, L.; Stoub, T.R., Bulgakova, M., Wilson, R.S., Bennett, D.A., Leurgans, S., Wu, J. & Turner, D.A. (2004). MRI-Derived Entorhinal Volume is a Good Predictor of Conversion from MCI to AD. *Neurobiology of Aging*, Vol.25, No.9, (October 2004), pp. 1197-1203, ISSN 0197-4580
- Diehl-Schmid, J.; Grimmer, T., Drzezga, A., Bornschein, S., Perneczky, R., Forstl, H., Schwaiger, M. & Kurz, A. (2006). Longitudinal Changes of Cerebral Glucose Metabolism in Semantic Dementia. *Dementia and Geriatric Cognitive Disorders*, Vol.22, No.4, pp. 346-351, ISSN 1420-8008
- Döbert, N.; Pantel, J., Frölich, L., Hamscho, N., Menzel, C. & Grünwald, F. (2005). Diagnostic Value of FDG-PET and HMPAO-SPET in Patients with Mild Dementia and Mild Cognitive Impairment: Metabolic Index and Perfusion Index. *Dementia and Geriatric Cognitive Disorders*, Vol.20, No.2-3, pp. 63-70, ISSN 1420-8008
- Drzezga, A.; Lautenschlager, N., Siebner, H., Riemenschneider, M., Willoch, F., Minoshima, S., Schwaiger, M. & Kurz, A. (2003). Cerebral Metabolic Changes Accompanying

- Conversion of Mild Cognitive Impairment into Alzheimer's Disease: a PET Follow-up Study. *European Journal of Nuclear Medicine and Molecular Imaging*, Vol.30, No.8, (August 2003), pp. 1104-1113, ISSN 1619-7070
- Drzezga, A.; Grimmer, T., Riemenschneider, M., Lautenschlager, N., Siebner, H., Alexopoulos, P., Minoshima, S., Schwaiger, M. & Kurz, A. (2005). Prediction of Individual Clinical Outcome in MCI by Means of Genetic Assessment and (18)F-FDG PET. *Journal of Nuclear Medicine*, Vol.46, No.10, (October 2005), pp. 1625-1632, ISSN 0161-5505
- Duara, R.; Barker, W., Loewenstein, D., Pascal, S. & Bowen, B. (1989). Sensitivity and Specificity of Positron Emission Tomography and Magnetic Resonance Imaging Studies in Alzheimer's Disease and Multi-infarct Dementia. *European Neurology*, Vol.29, Supplement 3, pp. 9-15, ISSN 0014-3022
- Dubois, B.; Feldman, H.H., Jacova, C., Dekosky, S.T., Barberger-Gateau, P., Cummings, J., Delacourte, A., Galasko, D., Gauthier, S., Jicha, G., Meguro, K., O'Brien, J., Pasquier, F., Robert, P., Rossor, M., Salloway, S., Stern, Y., Visser, P.J. & Scheltens, P. (2007). Research Criteria for the Diagnosis of Alzheimer's Disease: Revising the NINCDS-ADRDA Criteria. *Lancet Neurology*, Vol.6, No.8, (August 2007), pp. 734-46, ISSN 1474-4422
- Engler, H.; Lundberg, P.O., Ekblom, K., Nennesmo, I., Nilsson, A., Bergström, M., Tsukada, H., Hartvig, P. & Långström, B. (2003). Multitracer Study with Positron Emission Tomography in Creutzfeldt-Jakob Disease. *European Journal of Nuclear Medicine and Molecular Imaging*, Vol.30, No.1, (January 2003), pp. 85-95, ISSN 1619-7070
- Fazekas, F.; Alavi, A., Chawluk, J.B., Zimmerman, R.A., Hackney, D., Bilaniuk, L., Rosen, M., Alves, W.M., Hurtig, H.I., Jamieson, D.G., Kushner, M.J. & Reivich, M. (1989). Comparison of CT, MR, and PET in Alzheimer's Dementia and Normal Aging. *Journal of Nuclear Medicine*, Vol.30, No.10, (October 1989), pp. 1607-1615, ISSN 0161-5505
- Feigin, A.; Leenders, K.L., Moeller, J.R., Missimer, J., Kuenig, G., Spetsieris, P., Antonini, A. & Eidelberg, D. (2001). Metabolic Network Abnormalities in Early Huntington's Disease: an [(18)F]FDG PET Study. *Journal of Nuclear Medicine*, Vol.42, No.11, (November 2001), pp. 1591-1595, ISSN 0161-5505
- Ferri, C.P.; Prince, M., Brayne, C., Brodaty, H., Fratiglioni, L., Ganguli, M., Hall, K., Hasegawa, K., Hendrie, H., Huang, Y., Jorm, A., Mathers, C., Menezes, P.R., Rimmer, E. & Scazufca, M.; Alzheimer's Disease International. (2005). Global Prevalence of Dementia: a Delphi Consensus Study. *Lancet*, Vol.366, No.9503, (December 2005), pp. 2112-2117, ISSN 0140-6736
- Folstein, M.F.; Bassett, S.S., Anthony, J.C., Romanoski, A.J. & Nestadt, G.R. (1991). Dementia: Case Ascertainment in a Community Survey. *Journal of Gerontology*, Vol.46, No.4, (July 1991), pp. M132-M138, ISSN 0022-1422
- Foster, N.L.; Chase, T.N., Fedio, P., Patronas, N.J., Brooks, R.A. & Di Chiro, G. (1983). Alzheimer's Disease: Focal Cortical Changes Shown by Positron Emission Tomography. *Neurology*, Vol.33, No.8, (August 1983), pp. 961-965, ISSN 0028-3878
- Foster, N.L.; Chase, T.N., Mansi, L., Brooks, R., Fedio, P., Patronas, N.J. & Di Chiro, G. (1984). Cortical Abnormalities in Alzheimer's Disease. *Annals of Neurology*, Vol.16, No.6, (December 1984), pp. 649-654, ISSN 0364-5134

- Foster, N.L.; Chase, T.N., Patronas, N.J., Gillespie, M.M. & Fedio, P. (1986). Cerebral Mapping of Apraxia in Alzheimer's Disease by Positron Emission Tomography. *Annals of Neurology*, Vol.19, No.2, (February 1986), pp. 139-143, ISSN 0364-5134
- Foster, N.L.; Gilman, S., Berent, S., Sima, A.A., D'Amato, C., Koeppe, R.A. & Hicks, S.P. (1992). Progressive Subcortical Gliosis and Progressive Supranuclear Palsy Can Have Similar Clinical and PET Abnormalities. *Journal of Neurology, Neurosurgery, and Psychiatry*, Vol.55, No.8, (August 1992), pp. 707-713, ISSN 0022-3050
- Foster, N.L.; Heidebrink, J.L., Clark, C.M., Jagust, W.J., Arnold, S.E., Barbas, N.R., DeCarli, C.S., Turner, R.S., Koeppe, R.A., Higdon, R. & Minoshima, S. (2007). FDG-PET Improves Accuracy in Distinguishing Frontotemporal Dementia and Alzheimer's Disease. *Brain*, Vol.130, Part 10, (October 2007), pp. 2616-2635, ISSN 0006-8950
- Frackowiak, R.S.; Pozzilli, C., Legg, N.J., Du Boulay, G.H., Marshall, J., Lenzi, G.L. & Jones, T. (1981). Regional Cerebral Oxygen Supply and Utilization in Dementia. A Clinical and Physiological Study with Oxygen-15 and Positron Tomography. *Brain*, Vol.104, Part 4, (December 1981), pp. 753-778, ISSN 0006-8950
- Grady, C.L.; Haxby, J.V., Horwitz, B., Berg, G. & Rapoport, S.I. (1987). Neuropsychological and Cerebral Metabolic Function in Early vs Late Onset Dementia of the Alzheimer Type. *Neuropsychologia*, Vol.25, No.5, pp. 807-816, ISSN 0028-3932
- Hayden, M.R.; Hewitt, J., Stoessl, A.J., Clark, C., Ammann, W. & Martin, W.R. (1987). The Combined Use of Positron Emission Tomography and DNA Polymorphisms for Preclinical Detection of Huntington's Disease. *Neurology*, Vol.37, No.9, (September 1987), pp. 1441-1447, ISSN 0028-3878
- Henkel, K.; Zerr, I., Hertel, A., Gratz, K.F., Schröter, A., Tschampa, H.J., Bihl, H., Büll, U., Grünwald, F., Drzezga, A., Spitz, J. & Poser, S. (2002). Positron Emission Tomography with [(18)F]FDG in the Diagnosis of Creutzfeldt-Jakob Disease (CJD). *Journal of Neurology*, Vol.249, No.6, (June 2002), pp. 699-705, ISSN 0340-5354
- Herholz, K.; Adams, R., Kessler, J., Szekely, B., Grond, M. & Heiss, W.D. (1990). Criteria for the Diagnosis of Alzheimer's Disease with Positron Emission Tomography. *Dementia and Geriatric Cognitive Disorders*, Vol.1, No.3, pp. 156-164, ISSN 1420-8008
- Herholz, K.; Perani, D., Salmon, E., Franck, G., Fazio, F., Heiss, W.D. & Comar, D. (1993). Comparability of FDG PET Studies in Probable Alzheimer's Disease. *Journal of Nuclear Medicine*, Vol.34, No.9, (September 1993), pp. 1460-1466, ISSN 0161-5505
- Herholz, K.; Nordberg, A., Salmon, E., Perani, D., Kessler, J., Mielke, R., Halber, M., Jelic, V., Almkvist, O., Collette, F., Alberoni, M., Kennedy, A., Hasselbalch, S., Fazio, F. & Heiss, W.D. (1999) Impairment of Neocortical Metabolism Predicts Progression in Alzheimer's Disease. *Dementia and Geriatric Cognitive Disorders*, Vol.10, No.6, (November-December 1999), pp. 494-504, ISSN 1420-8008
- Herholz, K.; Salmon, E., Perani, D., Baron, J.C., Holthoff, V., Frölich, L., Schönknecht, P., Ito, K., Mielke, R., Kalbe, E., Zündorf, G., Delbeuck, X., Pelati, O., Anchisi, D., Fazio, F., Kerrouche, N., Desgranges, B., Eustache, F., Beuthien-Baumann, B., Menzel, C., Schröder, J., Kato, T., Arahata, Y., Henze, M. & Heiss, W.D. (2002a). Discrimination between Alzheimer Dementia and Controls by Automated Analysis of Multicenter FDG PET. *NeuroImage*, Vol.17, No.1, (September 2002), pp. 302-316, ISSN 1053-8119
- Herholz, K.; Schopphoff, H., Schmidt, M., Mielke, R., Eschner, W., Scheidhauer, K., Schicha, H., Heiss, W.D. & Ebmeier, K. (2002b). Direct Comparison of Spatially Normalized

- PET and SPECT Scans in Alzheimer's Disease. *Journal of Nuclear Medicine*, Vol.43, No.1, (January 2002), pp. 21-26, ISSN 0161-5505
- Higuchi, M.; Tashiro, M., Arai, H., Okamura, N., Hara, S., Higuchi, S., Itoh, M., Shin, R.W., Trojanowski, J.Q. & Sasaki, H. (2000). Glucose Hypometabolism and Neuropathological Correlates in Brains of Dementia with Lewy Bodies. *Experimental Neurology*, Vol.162, No.2, (April 2000), pp. 247-256, ISSN 0014-4886
- Hirao, K.; Ohnishi, T., Hirata, Y., Yamashita, F., Mori, T., Moriguchi, Y., Matsuda, H., Nemoto, K., Imabayashi, E., Yamada, M., Iwamoto, T., Arima, K. & Asada, T. (2005). The Prediction of Rapid Conversion to Alzheimer's Disease in Mild Cognitive Impairment Using Regional Cerebral Blood Flow SPECT. *NeuroImage*, Vol.28, No.4, (December 2005), pp. 1014-1021, ISSN 1053-8119
- Hoffman, J.M.; Welsh-Bohmer, K.A., Hanson, M., Crain, B., Hulette, C., Earl, N. & Coleman, R.E. (2000). FDG PET Imaging in Patients with Pathologically Verified Dementia. *Journal of Nuclear Medicine*, Vol.41, No.11, (November 2000), pp. 1920-1928, ISSN 0161-5505
- Holmes, C.; Cairns, N., Lantos, P. & Mann, A. (1999). Validity of Current Clinical Criteria for Alzheimer's Disease, Vascular Dementia and Dementia with Lewy Bodies. *The British Journal of Psychiatry*, Vol.174, (January 1999), pp. 45-50, ISSN 0007-1250
- Imamura, T.; Ishii, K., Sasaki, M., Kitagaki, H., Yamaji, S., Hirono, N., Shimomura, T., Hashimoto, M., Tanimukai, S., Kazui, H. & Mori, E. (1997). Regional Cerebral Glucose Metabolism in Dementia with Lewy Bodies and Alzheimer's Disease: a Comparative Study Using Positron Emission Tomography. *Neuroscience Letters*, Vol.235, No.1-2, (October 1997), pp. 49-52, ISSN 0304-3940
- Ishii, K.; Sasaki, M., Kitagaki, H., Yamaji, S., Sakamoto, S., Matsuda, K. & Mori, E. (1997). Reduction of Cerebellar Glucose Metabolism in Advanced Alzheimer's Disease. *Journal of Nuclear Medicine*, Vol.38, No.6, (June 1997), pp. 925-928, ISSN 0161-5505
- Ishii, K.; Sakamoto, S., Sasaki, M., Kitagaki, H., Yamaji, S., Hashimoto, M., Imamura, T., Shimomura, T., Hirono, N. & Mori, E. (1998). Cerebral Glucose Metabolism in Patients With Frontotemporal Dementia. *Journal of Nuclear Medicine*, Vol.39, No.11, (November 1998), pp. 1875-1878, ISSN 0161-5505
- Ishii, K.; Sasaki, M., Sakamoto, S., Yamaji, S., Kitagaki, H. & Mori, E. (1999). Tc-99m Ethyl Cysteinate Dimer SPECT and 2-[F-18]Fluoro-2-Deoxy-D-Glucose PET in Alzheimer's Disease. Comparison of Perfusion and Metabolic Patterns. *Clinical Nuclear Medicine*, Vol.24, No.8, (August 1999), pp. 572-575, ISSN 0363-9762
- Ishii, K.; Kono, A.K., Sasaki, H., Miyamoto, N., Fukuda, T., Sakamoto, S. & Mori, E. (2006). Fully Automatic Diagnostic System for Early- and Late-Onset Mild Alzheimer's Disease Using FDG PET and 3D-SSP. *European Journal of Nuclear Medicine and Molecular Imaging*, Vol.33, No.5, (May 2006), pp. 575-583, ISSN 1619-7070
- Ishii, K.; Soma, T., Kono, A.K., Sofue, K., Miyamoto, N., Yoshikawa, T., Mori, E. & Murase, K. (2007). Comparison of Regional Brain Volume and Glucose Metabolism between Patients with Mild Dementia with Lewy Bodies and Those with Mild Alzheimer's Disease. *Journal of Nuclear Medicine*, Vol.48, No.5, (May 2007), pp. 704-711, ISSN 0161-5505

- Ito, K.; Kato, T. & Torizuka, K. (2010). [Clinical Value of 18F-FDG PET in Assessment of Alzheimer's Disease: Meta-analysis] (Japanese). *Kaku Igaku*, Vol.47, No.1, (March 2010), pp. 1-8, ISSN 0022-7854
- Jagust, W.J.; Friedland, R.P. & Budinger, T.F. (1985). Positron Emission Tomography with [¹⁸F]Fluorodeoxyglucose Differentiates Normal Pressure Hydrocephalus from Alzheimer-Type Dementia. *Journal of Neurology, Neurosurgery, and Psychiatry*, Vol.48, No.11, (November 1985), pp. 1091-1096, ISSN 0022-3050
- Jagust, W.J.; Friedland, R.P., Budinger, T.F., Koss, E. & Ober, B. (1988). Longitudinal Studies of Regional Cerebral Metabolism in Alzheimer's Disease. *Neurology*, Vol.38, No.6, (June 1988), pp. 909-912, ISSN 0028-3878
- Jagust, W.; Gitcho, A., Sun, F., Kuczynski, B., Mungas, D. & Haan, M. (2006). Brain Imaging Evidence of Preclinical Alzheimer's Disease in Normal Aging. *Annals of Neurology*, Vol.59, No.4, (April 2006), pp. 673-681, ISSN 0364-5134
- Jauhiainen, A.M.; Kangasmaa, T., Rusanen, M., Niskanen, E., Tervo, S., Kivipelto, M., Vanninen, R.L., Kuikka, J.T. & Soininen, H. (2008). Differential Hypometabolism Patterns According to Mild Cognitive Impairment Subtypes. *Dementia and Geriatric Cognitive Disorders*, Vol.26, No.6, pp. 490-498, ISSN 1420-8008
- Jobst, K.A.; Hindley, N.J., King, E. & Smith, A.D. (1994). The Diagnosis of Alzheimer's Disease: a Question of Image? *The Journal of Clinical Psychiatry*, Vol.55, Supplement, (November 1994), pp. 22-31, ISSN 0160-6689
- Jobst, K.A.; Barnetson, L.P. & Shepstone, B.J. (1998). Accurate Prediction of Histologically Confirmed Alzheimer's Disease and the Differential Diagnosis of Dementia: the Use of NINCDS-ADRDA and DSM-III-R Criteria, SPECT, X-ray CT, and Apo E4 in Medial Temporal Lobe Dementias. Oxford Project to Investigate Memory and Aging. *International Psychogeriatrics / IPA*, Vol.10, No.3, (September 1998), pp. 271-302, ISSN 1041-6102
- Kadekaro, M.; Crane, A.M. & Sokoloff, L. (1985). Differential Effects of Electrical Stimulation of Sciatic Nerve on Metabolic Activity in Spinal Cord and Dorsal Root Ganglion in the Rat. *Proceedings of the National Academy of Sciences of the United States of America*, Vol.82, No.17, (September 1985), pp. 6010-6013, ISSN 0027-8424
- Kadir, A.; Darreh-Shori, T., Almkvist, O., Wall, A., Grut, M., Strandberg, B., Ringheim, A., Eriksson, B., Blomquist, G., Långström, B. & Nordberg, A. (2008). PET Imaging of the In Vivo Brain Acetylcholinesterase Activity and Nicotine Binding in Galantamine-Treated Patients with AD. *Neurobiology of Aging*, Vol.29, No.8, (August 2008), pp. 1204-1217, ISSN 0197-4580
- Kawachi, T.; Ishii, K., Sakamoto, S., Sasaki, M., Mori, T., Yamashita, F., Matsuda, H. & Mori, E. (2006). Comparison of the Diagnostic Performance of FDG-PET and VBM-MRI in Very Mild Alzheimer's Disease. *European Journal of Nuclear Medicine and Molecular Imaging*, Vol.33, No.7, (July 2006), pp. 801-809, ISSN 1619-7070
- Kerrouche, N.; Herholz, K., Mielke, R., Holthoff, V. & Baron, J.C. (2006). 18FDG PET in Vascular Dementia: Differentiation from Alzheimer's Disease Using Voxel-Based Multivariate Analysis. *Journal of Cerebral Blood Flow and Metabolism*, Vol.26, No.9, (September 2006), pp. 1213-1221, ISSN 0271-678X
- Killiany, R.J.; Gomez-Isla, T., Moss, M., Kikinis, R., Sandor, T., Jolesz, F., Tanzi, R., Jones, K., Hyman, B.T. & Albert, M.S. (2000). Use of Structural Magnetic Resonance Imaging

- to Predict Who Will Get Alzheimer's Disease. *Annals of Neurology*, Vol.47, No.4, (April 2000), pp. 430-439, ISSN 0364-5134
- Kippenhan, J.S.; Barker, W.W., Pascal, S., Nagel, J. & Duara, R. (1992). Evaluation of a Neural-Network Classifier for PET Scans of Normal and Alzheimer's Disease Subjects. *Journal of Nuclear Medicine*, Vol.33, No.8, (August 1992), pp. 1459-1467, ISSN 0161-5505
- Kumar, A.; Schapiro, M.B., Grady, C.L., Matocha, M.F., Haxby, J.V., Moore, A.M., Luxenberg, J.S., St George-Hyslop, P.H., Robinette, C.D., Ball, M.J. & Rapoport, S.I. (1991). Anatomic, Metabolic, Neuropsychological, and Molecular Genetic Studies of Three Pairs of Identical Twins Discordant for Dementia of the Alzheimer's Type. *Archives of Neurology*, Vol.48, No.2, (February 1991), pp. 160-168, ISSN 0003-9942
- Kuwert, T.; Lange, H.W., Langen, K.J., Herzog, H., Aulich, A. & Feinendegen, L.E. (1990). Cortical and Subcortical Glucose Consumption Measured by PET in Patients with Huntington's Disease. *Brain*, Vol.113, Part 5:, (October 1990), pp. 1405-1423, ISSN 0006-8950
- Landau, S.M.; Harvey, D., Madison, C.M., Reiman, E.M., Foster, N.L., Aisen, P.S., Petersen, R.C., Shaw, L.M., Trojanowski, J.Q., Jack, C.R Jr., Weiner, M.W. & Jagust, W.J.; Alzheimer's Disease Neuroimaging Initiative. (2010). Comparing Predictors of Conversion and Decline in Mild Cognitive Impairment. *Neurology*, Vol.75, No.3, (July 2010), pp. 230-238, ISSN 0028-3878
- Langbaum, J.B.; Chen, K., Lee, W., Reschke, C., Bandy, D., Fleisher, A.S., Alexander, G.E., Foster, N.L., Weiner, M.W., Koeppe, R.A., Jagust, W.J. & Reiman, E.M.; Alzheimer's Disease Neuroimaging Initiative. (2009). Categorical and Correlational Analyses of Baseline Fluorodeoxyglucose Positron Emission Tomography Images from the Alzheimer's Disease Neuroimaging Initiative (ADNI). *NeuroImage*, Vol.45, No.4, (May 2009), pp. 1107-1116, ISSN 1053-8119
- Lim, A.; Tsuang, D., Kukull, W., Nochlin, D., Leverenz, J., McCormick, W., Bowen, J., Teri, L., Thompson, J., Peskind, E.R., Raskind, M. & Larson, E.B. (1999). Clinico-neuropathological Correlation of Alzheimer's Disease in a Community-Based Case Series. *Journal of the American Geriatric Society*, Vol.47, No.5, (May 1999), pp. 564-569, ISSN 0002-8614
- Masliah, E.; Mallory, M., Hansen, L., Alford, M., Albright, T., DeTeresa, R., Terry, R., Baudier, J., & Saitoh, T. (1991). Patterns of Aberrant Sprouting in Alzheimer's Disease. *Neuron*, Vol.6, No.5, (May 1991), pp. 729-739, ISSN 0896-6273
- Mattson, M.P.; Duan, W., Wan, R. & Guo, Z. (2004). Prophylactic Activation of Neuroprotective Stress Response Pathways by Dietary and Behavioral Manipulations. *NeuroRx*, Vol.1, No.1, (January 2004), pp. 111-116, ISSN 1545-5343
- Mazziotta, J.C.; Phelps, M.E., Pahl, J.J., Huang, S.C., Baxter, L.R., Riege, W.H., Hoffman, J.M., Kuhl, D.E., Lanto, A.B. Wapenski, J.A. & Markham, C.H. (1987). Reduced Cerebral Glucose Metabolism in Asymptomatic Subjects at Risk for Huntington's Disease. *The New England Journal of Medicine*, Vol.316, No.7, (February 1987), pp. 357-362, ISSN 0028-4793
- McGeer, E.G.; Peppard, R.P., McGeer, P.L., Tuokko, H., Crockett, D., Parks, R., Akiyama, H., Calne, D.B., Beattie, B.L. & Harrop, R. (1990). 18Fluorodeoxyglucose Positron Emission Tomography Studies in Presumed Alzheimer Cases, Including 13 Serial

- Scans. *The Canadian Journal of Neurological Sciences*, Vol.17, No.1, (February 1990), pp. 1-11, ISSN 0317-1671
- McKhann, G.; Drachman, D., Folstein, M., Katzman, R., Price, D. & Stadlan, E.M. (1984). Clinical Diagnosis of Alzheimer's Disease: Report of the NINCDS-ADRDA Work Group under the Auspices of Department of Health and Human Services Task Force on Alzheimer's Disease. *Neurology*, Vol.34, No.7, (July 1984), pp. 939-944, ISSN 0028-3878
- Mega, M.S.; Cummings, J.L., O'Connor, S.M., Dinov, I.D., Reback, E., Felix, J., Masterman, D.L., Phelps, M.E., Small, G.W. & Toga, A.W. (2001). Cognitive and Metabolic Responses to Metrifonate Therapy in Alzheimer Disease. *Neuropsychiatry, Neuropsychology, and Behavioral Neurology*, Vol.14, No.1, (January 2001), pp. 63-68, ISSN 0894-878X
- Mega, M.S.; Dinov, I.D., Porter, V., Chow, G., Reback, E., Davoodi, P., O'Connor, S.M., Carter, M.F., Amezcua, H. & Cummings, J.L. (2005). Metabolic Patterns Associated with the Clinical Response to Galantamine Therapy: a Fludeoxyglucose F 18 Positron Emission Tomographic Study. *Archives of Neurology*, Vol.62, No.5, (May 2005), pp. 721-728, ISSN 0003-9942
- Meguro, K.; Ishii, H., Yamaguchi, S., Ishizaki, J., Shimada, M., Sato, M., Hashimoto, R., Shimada, Y., Meguro, M., Yamadori, A. & Sekita, Y. (2002). Prevalence of Dementia and Dementing Diseases in Japan: the Tajiri Project. *Archives of Neurology*, Vol.59, No.7, (July 2002), pp. 1109-1114, ISSN 0003-9942
- Mielke, R.; Herholz, K., Grond, M., Kessler, J. & Heiss, W.D. (1992). Differences of Regional Cerebral Glucose Metabolism between Presenile and Senile Dementia of Alzheimer Type. *Neurobiology of Aging*, Vol.13, No.1, (January-February 1992), pp. 93-98, ISSN 0197-4580
- Mielke, R.; Pietrzyk, U., Jacobs, A., Fink, G.R., Ichimiya, A., Kessler, J., Herholz, K. & Heiss, W.D. (1994). HMPAO SPET and FDG PET in Alzheimer's Disease and Vascular Dementia: Comparison of Perfusion and Metabolic Pattern. *European Journal of Nuclear Medicine*, Vol.21, No.10, (October 1994), pp. 1052-1060, ISSN 0340-6997
- Mielke, R.; Schröder, R., Fink, G.R., Kessler, J., Herholz, K. & Heiss, W.D. (1996). Regional Cerebral Glucose Metabolism and Postmortem Pathology in Alzheimer's Disease. *Acta Neuropathologica*, Vol.91, No.2, pp. 174-179, ISSN 0001-6322
- Minoshima, S.; Koeppe, R.A., Mintun, M.A., Berger, K.L., Taylor, S.F., Frey, K.A. & Kuhl, D.E. (1993). Automated Detection of the Intercommissural Line for Stereotactic Localization of Functional Brain Images. *Journal of Nuclear Medicine*, Vol.34, No.2, (February 1993), pp. 322-329, ISSN 0161-5505
- Minoshima, S.; Foster, N.L. & Kuhl, D.E. (1994). Posterior Cingulate Cortex in Alzheimer's Disease. *Lancet*, Vol.344, No.8926, (September 1994), p. 895, ISSN 0140-6736
- Minoshima, S.; Frey, K.A., Koeppe, R.A., Foster, N.L. & Kuhl, D.E. (1995). A Diagnostic Approach in Alzheimer's Disease Using Three-Dimensional Stereotactic Surface Projections of Fluorine-18-FDG PET. *Journal of Nuclear Medicine*, Vol.36, No.7, (July 1995), pp. 1238-1248, ISSN 0161-5505
- Minoshima, S.; Giordani, B., Berent, S., Frey, K.A., Foster, N.L. & Kuhl, D.E. (1997). Metabolic Reduction in the Posterior Cingulate Cortex in Very Early Alzheimer's Disease. *Annals of Neurology*, Vol.42, No.1, (July 1997), pp. 85-94, ISSN 0364-5134

- Minoshima, S. (2003). Imaging Alzheimer's Disease: Clinical Applications. *Neuroimaging Clinics of North America*, Vol.13, No.4, (November 2003), pp. 769-780, ISSN 1052-5149
- Miyazawa, N.; Satoh, T., Hashizume, K. & Fukamachi, A. (1997). Xenon Contrast CT-CBF Measurements in High-Intensity Foci on T2-Weighted MR Images in Centrum Semiovale of Asymptomatic Individuals. *Stroke*, Vol.28, No.5, (May 1997), pp. 984-987, ISSN 0039-2499
- Miyazawa, N.; Shinohara, T., Nagasaka, T. & Hayashi, M. (2010). Hypermetabolism in Patients with Dementia with Lewy Bodies. *Clinical Nuclear Medicine*, Vol.35, No.7, (July 2010), pp. 490-493, ISSN 0363-9762
- Miyazawa, N.; Shinohara, T., Kobayasi, R. & Nagasaka, T. (2011). Application of F-18 FDG-PET by Ordinary and Statistical Images and Methods to Patients with Memory Disturbance: Analysis of its Usefulness with 500 Consecutive Cases. *Nuclear Medicine in Clinic* (in press)
- Morbelli, S.; Piccardo, A., Villavecchia, G., Dessi, B., Brugnolo, A., Piccini, A., Caroli, A., Frisoni, G., Rodriguez, G. & Nobili, F. (2010). Mapping Brain Morphological and Functional Conversion Patterns in Amnesic MCI: a Voxel-Based MRI and FDG-PET Study. *European Journal of Nuclear Medicine and Molecular Imaging*, Vol.37, No.1, (January 2010), pp. 36-45, ISSN 1619-7070
- Morinaga, A.; Ono, K., Ikeda, T., Ikeda, Y., Shima, K., Noguchi-Shinohara, M., Samuraki, M., Yanase, D., Yoshita, M., Iwasa, K., Mastunari, I. & Yamada, M. (2010). A Comparison of the Diagnostic Sensitivity of MRI, CBF-SPECT, FDG-PET and Cerebrospinal Fluid Biomarkers for Detecting Alzheimer's Disease in a Memory Clinic. *Dementia and Geriatric Cognitive Disorders*, Vol.30, No.4, pp. 285-292, ISSN 1420-8008
- Morris, J.C.; Weintraub, S., Chui, H.C., Cummings, J., Decarli, C., Ferris, S., Foster, N.L., Galasko, D., Graff-Radford, N., Peskind, E.R., Beekly, D., Ramos, E.M. & Kukull, W.A. (2006). The Uniform Data Set (UDS): Clinical and Cognitive Variables and Descriptive Data from Alzheimer Disease Centers. *Alzheimer Disease and Associated Disorders*, Vol.20, No.4, (October-December 2006), pp. 210-216, ISSN 0893-0341
- Mosconi, L.; Perani, D., Sorbi, S., Herholz, K., Nacmias, B., Holthoff, V., Salmon, E., Baron, J.C., De Cristofaro, M.T., Padovani, A., Borroni, B., Franceschi, M., Bracco, L. & Pupi, A. (2004). MCI Conversion to Dementia and the APOE Genotype: a Prediction Study with FDG-PET. *Neurology*, Vol.63, No.12, (December 2004), pp. 2332-2340, ISSN 0028-3878
- Mosconi, L.; Tsui, W.H., De Santi, S., Li, J., Rusinek, H., Convit, A., Li, Y., Boppana, M. & de Leon, M.J. (2005). Reduced Hippocampal Metabolism in MCI and AD: Automated FDG-PET Image Analysis. *Neurology*, Vol.64, No.11, (June 2005), pp. 1860-1867, ISSN 0028-3878
- Mosconi, L.; Brys, M., Switalski, R., Mistur, R., Glodzik, L., Pirraglia, E., Tsui, W., De Santi, S. & de Leon, M.J. (2007). Maternal Family History of Alzheimer's Disease Predisposes to Reduced Brain Glucose Metabolism. *Proceedings of the National Academy of Sciences of the United States of America*, Vol.104, No.48, (November 2007), pp. 19067-19072, ISSN 0027-8424


- Mosconi, L.; De Santi, S., Brys, M., Tsui, W.H., Pirraglia, E., Glodzik-Sobanska, L., Rich, K.E., Switalski, R., Mehta, P.D., Pratico, D., Zinkowski, R., Blennow, K. & de Leon, M.J. (2008). Hypometabolism and Altered Cerebrospinal Fluid Markers in Normal Apolipoprotein E E4 Carriers with Subjective Memory Complaints. *Biological Psychiatry*, Vol.63, No.6, (March 2008), pp. 609-618, ISSN 0006-3223
- Mosconi, L.; Mistur, R., Switalski, R., Brys, M., Glodzik, L., Rich, K., Pirraglia, E., Tsui, W., De Santi, S. & de Leon, M.J. (2009). Declining Brain Glucose Metabolism in Normal Individuals with a Maternal History of Alzheimer Disease. *Neurology*, Vol.72, No.6, (February 2009), pp. 513-520, ISSN 0028-3878
- Mueller, S.G.; Weiner, M.W., Thal, L.J., Petersen, R.C., Jack, C.R., Jagust, W., Trojanowski, J.Q., Toga, A.W. & Beckett, L. (2005). Ways Toward an Early Diagnosis in Alzheimer's Disease: the Alzheimer's Disease Neuroimaging Initiative (ADNI). *Alzheimer's & Dementia*, Vol.1, No.1, (July 2005), pp. 55-66, ISSN 1552-5260
- Nagasaka, T.; Nagasaka, K., Ohta, E., Shindo, K., Takiyama, Y., Shiozawa, Z., Miyazawa, N., Yamasaki, N., Mori, N., Onda, H. & Shinohara, T. (2011). Cerebral Hypermetabolism Demonstrated by FDG PET in Familial Creutzfeldt-Jakob Disease. *Clinical Nuclear Medicine*, Vol.36, No.8, (August 2011), pp. 725-727, ISSN 0363-9762
- Ng, S.; Villemagne, V.L., Berlangieri, S., Lee, S.T., Cherk, M., Gong, S.J., Ackermann, U., Saunders, T., Tochon-Danguy, H., Jones, G., Smith, C., O'Keefe, G., Masters, C.L. & Rowe, C.C. (2007). Visual Assessment Versus Quantitative Assessment of 11C-PIB PET and 18F-FDG PET for Detection of Alzheimer's Disease. *Journal of Nuclear Medicine*, Vol.48, No.4, (April 2007), pp. 547-552, ISSN 0161-5505
- Nordberg, A.; Rinne, J.O., Kadir, A. & Långström, B. (2010). The Use of PET in Alzheimer Disease. *Nature Reviews. Neurology*, Vol.6, No.2, (February 2010), pp. 78-87, ISSN 1759-4758
- Ohya, M.; Senda, M., Mishina, M., Kitamura, S., Tanizaki, N., Ishii, K. & Katayama, Y. (2000). Semi-automatic ROI Placement System for Analysis of Brain PET Images Based on Elastic Model: Application to Diagnosis of Alzheimer's Disease. *The Keio Journal of Medicine*, Vol.49, Supplement 1, (February 2000), pp. A105-A106, ISSN 0022-9717
- Panza, F.; D'Introno, A., Colacicco, A.M., Capurso, C., Del Parigi, A., Caselli, R.J., Pilotto, A., Argentieri, G., Scapicchio, P.L., Scafato, E., Capurso, A. & Solfrizzi, V. (2005). Current Epidemiology of Mild Cognitive Impairment and Other Predementia Syndromes. *The American Journal of Geriatric Psychiatry*, Vol.13, No.8, (August 2005), pp. 633-644, ISSN 1064-7481
- Pascual, B.; Prieto, E., Arbizu, J., Marti-Clement, J., Olier, J. & Masdeu, J.C. (2010). Brain Glucose Metabolism in Vascular White Matter Disease with Dementia: Differentiation from Alzheimer Disease. *Stroke*, Vol.41, No.12, (December 2010), pp. 2889-2893, ISSN 0039-2499
- Pennanen, C.; Kivipelto, M., Tuomainen, S., Hartikainen, P., Hänninen, T., Laakso, M.P., Hallikainen, M., Vanhanen, M., Nissinen, A., Helkala, E.L., Vainio, P., Vanninen, R., Partanen, K. & Soininen, H. (2004). Hippocampus and Entorhinal Cortex in Mild Cognitive Impairment and Early AD. *Neurobiology of Aging*, Vol.25, No.3, (March 2004), pp. 303-310, ISSN 0197-4580

- Perneczky, R.; Drzezga, A., Boecker, H., Förstl, H., Kurz, A. & Häussermann, P. (2008). Cerebral Metabolic Dysfunction in Patients with Dementia with Lewy Bodies and Visual Hallucinations. *Dementia and Geriatric Cognitive Disorders*, Vol.25, No.6, pp. 531-538, ISSN 1420-8008
- Petersen, R.C.; Smith, G.E., Waring, S.C., Ivnik, R.J., Tangalos, E.G. & Kokmen, E. (1999). Mild Cognitive Impairment: Clinical Characterization and Outcome. *Archives of Neurology*, Vol.56, No.3, (March 1999), pp. 303-308, ISSN 0003-9942
- Petersen, R.C. & Morris, J.C. (2003). Clinical Features, In: *Mild Cognitive Impairment*, R.C. Petersen, (Ed.), 15-39, Oxford University Press, ISBN 0-19-512342-5, New York, NY, USA
- Petersen, R.C. & Morris, J.C. (2005). Mild Cognitive Impairment as a Clinical Entity and Treatment Target. *Archives of Neurology*, Vol.62, No.7, (July 2005), pp. 1160-1167, ISSN 0003-9942
- Petrie, E.C.; Cross, D.J., Galasko, D., Schellenberg, G.D., Raskind, M.A., Peskind, E.R. & Minoshima, S. (2009). Preclinical Evidence of Alzheimer Changes: Convergent Cerebrospinal Fluid Biomarker and Fluorodeoxyglucose Positron Emission Tomography Findings. *Archives of Neurology*, Vol.66, No.5, (May 2009), pp. 632-637, ISSN 0003-9942
- Read, S.L.; Miller, B.L., Mena, I., Kim, R., Itabashi, H. & Darby, A. (1995). SPECT in Dementia: Clinical and Pathological Correlation. *Journal of the American Geriatrics Society*, Vol.43, No.11, (November 1995), pp. 1243-1247, ISSN 0002-8614
- Reiman, E.M.; Caselli, R.J., Yun, L.S., Chen, K., Bandy, D., Minoshima, S., Thibodeau, S.N. & Osborne, D. (1996). Preclinical Evidence of Alzheimer's Disease in Persons Homozygous for the Epsilon 4 Allele for Apolipoprotein E. *The New England Journal of Medicine*, Vol.334, No.12, (March 1996), pp. 752-758, ISSN 0028-4793
- Scheurich, A.; Muller, M.J., Siessmeier, T., Bartenstein, P., Schmidt, L.G. & Fellgiebel, A. (2005). Validating the DemTect with 18-Fluoro-2-Deoxy-Glucose Positron Emission Tomography as a Sensitive Neuropsychological Screening Test for Early Alzheimer Disease in Patients of a Memory Clinic. *Dementia and Geriatric Cognitive Disorders*, Vol.20, No.5, pp. 271-277., ISSN 1420-8008
- Seo, S.W.; Cho, S.S., Park, A., Chin, J. & Na, D.L. (2009). Subcortical Vascular Versus Amnesic Mild Cognitive Impairment: Comparison of Cerebral Glucose Metabolism. *Journal of Neuroimaging*, Vol.19, No.3, (July 2009), pp. 213-219, ISSN 1051-2284
- Silverman, D.H.; Small, G.W., Chang, C.Y., Lu, C.S., Kung De Aburto, M.A., Chen, W., Czernin, J., Rapoport, S.I., Pietrini, P., Alexander, G.E., Schapiro, M.B., Jagust, W.J., Hoffman, J.M., Welsh-Bohmer, K.A., Alavi, A., Clark, C.M., Salmon, E., de Leon, M.J., Mielke, R., Cummings, J.L., Kowell, A.P., Gambhir, S.S., Hoh, C.K. & Phelps, M.E. (2001). Positron Emission Tomography in Evaluation of Dementia: Regional Brain Metabolism and Long-Term Outcome. *JAMA*, Vol.286, No.17, (November 2001), pp. 2120-2027, ISSN 0098-7484
- Small, G.W.; Kuhl, D.E., Riege, W.H., Fujikawa, D.G., Ashford, J.W., Metter, E.J. & Mazziotta, J.C. (1989). Cerebral Glucose Metabolic Patterns in Alzheimer's Disease. Effect of Gender and Age at Dementia Onset. *Archives of General Psychiatry*, Vol.46, No.6, (June 1989), pp. 527-532, ISSN 0003-990X

- Small, G.W.; La Rue, A., Komo, S., Kaplan, A. & Mandelkern, M.A. (1995). Predictors of Cognitive Change in Middle-Aged and Older Adults with Memory Loss. *The American Journal of Psychiatry*, Vol.152, No.12, (December 1995), pp. 1757-1764, ISSN 0002-953X
- Small, G.W.; Ercoli, L.M., Silverman, D.H., Huang, S.C., Komo, S., Bookheimer, S.Y., Lavretsky, H., Miller, K., Siddarth, P., Rasgon, N.L., Mazziotta, J.C., Saxena, S., Wu, H.M., Mega, M.S., Cummings, J.L., Saunders, A.M., Pericak-Vance, M.A., Roses, A.D., Barrio, J.R. & Phelps, M.E. (2000). Cerebral Metabolic and Cognitive Decline in Persons at Genetic Risk for Alzheimer's Disease. *Proceedings of the National Academy of Sciences of the United States of America*, Vol.97, No.11, (May 2000), pp. 6037-6042, ISSN 0027-8424
- Smith, G.S.; Kramer, E., Ma, Y., Hermann, C.R., Dhawan, V., Chaly, T. & Eidelberg, D. (2009). Cholinergic Modulation of the Cerebral Metabolic Response to Citalopram in Alzheimer's Disease. *Brain*, Vol.132, Part 2, (February 2009), pp. 392-401, ISSN 0006-8950
- Sultzer, D.L.; Mahler, M.E., Cummings, J.L., Van Gorp, W.G., Hinkin, C.H. & Brown, C. (1995). Cortical Abnormalities Associated with Subcortical Lesions in Vascular Dementia. Clinical and Position Emission Tomographic Findings. *Archives of Neurology*, Vol.52, No.8, (August 1995), pp. 773-780, ISSN 0003-9942
- Szelies, B.; Mielke, R., Herholz, K. & Heiss, W.D. (1994). Quantitative Topographical EEG Compared to FDG PET for Classification of Vascular and Degenerative Dementia. *Electroencephalography and Clinical Neurophysiology*, Vol.91, No.2, (August 1994), pp. 131-139, ISSN 0013-4694
- Tedeschi, E.; Hasselbalch, S.G., Waldemar, G., Juhler, M., Høgh, P., Holm, S., Garde, L., Knudsen, L.L., Klinken, L. & Gjerris, F. (1995). Heterogeneous Cerebral Glucose Metabolism in Normal Pressure Hydrocephalus. *Journal of Neurology, Neurosurgery, and Psychiatry*, Vol.59, No.6, (December 1995), pp. 608-615, ISSN 0022-3050
- Teipel, S.J.; Drzezga, A., Bartenstein, P., Möller, H.J., Schwaiger, M. & Hampel, H. (2006). Effects of Donepezil on Cortical Metabolic Response to Activation during (18)FDG-PET in Alzheimer's Disease: a Double-Blind Cross-Over Trial. *Psychopharmacology*, Vol.187, No.1, (July 2006), pp. 86-94, ISSN 0033-3158
- Thal, DR.; Rüb, U., Orantes, M., & Braak, H. (2002). Phases of A Beta-Deposition in the Human Brain and its Relevance for the Development of AD. *Neurology*, Vol.58, No.12, (June 2002), pp. 1791-1800, ISSN 0028-3878
- Tune, L.; Tiseo, P.J., Ieni, J., Perdomo, C., Pratt, R.D., Votaw, J.R., Jewart, R.D. & Hoffman, J.M. (2003). Donepezil HCl (E2020) Maintains Functional Brain Activity in Patients with Alzheimer Disease: Results of a 24-Week, Double-Blind, Placebo-Controlled Study. *The American Journal of Geriatric Psychiatry*, Vol.11, No.2, (March-April 2003), pp. 169-177, ISSN 1064-7481
- Tuszynski, M.H.; Thal, L., Pay, M., Salmon, D.P., U, H.S., Bakay, R., Patel, P., Blesch, A., Vahlsing, H.L., Ho, G., Tong, G., Potkin, S.G., Fallon, J., Hansen, L., Mufson, E.J., Kordower, J.H., Gall, C. & Conner, J. (2005). A Phase 1 Clinical Trial of Nerve Growth Factor Gene Therapy for Alzheimer Disease. *Nature Medicine*, Vol.11, No.5, (May 2005), pp. 551-555, ISSN 1078-8956

- von Borczyskowski, D.; Wilke, F., Martin, B., Brenner, W., Clausen, M., Mester, J. & Buchert, R. (2006). Evaluation of a New Expert System for Fully Automated Detection of the Alzheimer's Dementia Pattern in FDG PET. *Nuclear Medicine Communications*, Vol.27, No.9, (September 2006), pp. 739-743, ISSN 0143-3636
- Weiner, M.W.; Aisen, P.S., Jack, C.R. Jr., Jagust, W.J., Trojanowski, J.Q., Shaw, L., Saykin, A.J., Morris, J.C., Cairns, N., Beckett, L.A., Toga, A., Green, R., Walter, S., Soares, H., Snyder, P., Siemers, E., Potter, W., Cole, P.E. & Schmidt, M.; Alzheimer's Disease Neuroimaging Initiative. (2010). The Alzheimer's Disease Neuroimaging Initiative: Progress Report and Future Plans. *Alzheimer's & Dementia*, Vol.6, No.3, (May 2010), pp. 202-211.e7, ISSN 1552-5260
- Yong, S.W.; Yoon, J.K., An, Y.S. & Lee, P.H. (2007). A Comparison of Cerebral Glucose Metabolism in Parkinson's Disease, Parkinson's Disease Dementia and Dementia with Lewy Bodies. *European Journal of Neurology*, Vol.14, No.12, (December 2007), pp. 1357-1362, ISSN 1351-5101
- Young, A.B.; Penney, J.B., Starosta-Rubinstein, S., Markel, D., Berent, S., Rothley, J., Betley, A. & Hichwa, R. (1987). Normal Caudate Glucose Metabolism in Persons at Risk for Huntington's Disease. *Archives of Neurology*, Vol.44, No.3, (March 1987), pp. 254-257, ISSN 0003-9942

IntechOpen



Positron Emission Tomography - Current Clinical and Research Aspects

Edited by Dr. Chia-Hung Hsieh

ISBN 978-953-307-824-3

Hard cover, 336 pages

Publisher InTech

Published online 08, February, 2012

Published in print edition February, 2012

This book's stated purpose is to provide a discussion of the technical basis and clinical applications of positron emission tomography (PET), as well as their recent progress in nuclear medicine. It also summarizes current literature about research and clinical science in PET. The book is divided into two broad sections: basic science and clinical science. The basic science section examines PET imaging processing, kinetic modeling, free software, and radiopharmaceuticals. The clinical science section demonstrates various clinical applications and diagnoses. The text is intended not only for scientists, but also for all clinicians seeking recent information regarding PET.

How to reference

In order to correctly reference this scholarly work, feel free to copy and paste the following:

Nobuhiko Miyazawa and Toyoaki Shinohara (2012). [18F]Fluorodeoxyglucose Positron Emission Tomography in Alzheimer Disease and Related Disorders, Positron Emission Tomography - Current Clinical and Research Aspects, Dr. Chia-Hung Hsieh (Ed.), ISBN: 978-953-307-824-3, InTech, Available from:
<http://www.intechopen.com/books/positron-emission-tomography-current-clinical-and-research-aspects/-18f-fluorodeoxyglucose-positron-emission-tomography-in-alzheimer-disease-and-related-disorders>

INTECH
open science | open minds

InTech Europe

University Campus STeP Ri
Slavka Krautzeka 83/A
51000 Rijeka, Croatia
Phone: +385 (51) 770 447
Fax: +385 (51) 686 166
www.intechopen.com

InTech China

Unit 405, Office Block, Hotel Equatorial Shanghai
No.65, Yan An Road (West), Shanghai, 200040, China
中国上海市延安西路65号上海国际贵都大饭店办公楼405单元
Phone: +86-21-62489820
Fax: +86-21-62489821

© 2012 The Author(s). Licensee IntechOpen. This is an open access article distributed under the terms of the [Creative Commons Attribution 3.0 License](https://creativecommons.org/licenses/by/3.0/), which permits unrestricted use, distribution, and reproduction in any medium, provided the original work is properly cited.

IntechOpen

IntechOpen