

We are IntechOpen, the world's leading publisher of Open Access books Built by scientists, for scientists

6,900

Open access books available

186,000

International authors and editors

200M

Downloads

Our authors are among the

154

Countries delivered to

TOP 1%

most cited scientists

12.2%

Contributors from top 500 universities



WEB OF SCIENCE™

Selection of our books indexed in the Book Citation Index
in Web of Science™ Core Collection (BKCI)

Interested in publishing with us?
Contact book.department@intechopen.com

Numbers displayed above are based on latest data collected.
For more information visit www.intechopen.com



Cervical Intraepithelial Neoplasia (CIN) (Squamous Dysplasia)

Oguntayo Olanrewaju Adekunle

*Department of Obstetric and Gynaecology, Ahmadu Bello
University Teaching Hospital, Zaria Kaduna State
Nigeria*

1. Introduction

Cervical intraepithelial neoplasia (CIN) is a premalignant cervical disease that is also called cervical dysplasia or **cervical interstitial neoplasia** or cervical squamous intraepithelial lesions (CSIL).

The nomenclature in use in the past was mild, moderate, and severe dysplasia, these were the terms used to describe premalignant squamous cervical cellular changes. Although still in use by some, it has generally been replaced by the term Cervical Intraepithelial Neoplasia(CIN), which is used to describe histologic changes on the uterine cervix. The trend is now tending towards the use of Squamous Intraepithelial Lesions(SIL).

1.1 Definition

What is cervical intraepithelial Neoplasia-? It is a potentially premalignant transformation and abnormal growth (dysplasia) of squamous cells on the surface of the cervix.[Kumar et al 2007] CIN is not cancer, and is usually curable.[ACOG 2010] Most cases of CIN remain stable, or are eliminated by the host's immune system without intervention. However a small percentage of cases progress to become cervical cancer, usually cervical squamous cell carcinoma (SCC), if left untreated.[Agorastos et al 2005]

It can actually be defined as a spectrum of intraepithelial changes (dysplasia) with indistinct boundaries that begins with mild atypia and progresses through stages of more marked intraepithelial abnormalities to carcinoma in situ if untreated or managed. (UVA Health)

1.1.1 Dysplasia is a potentially reversible change characterized by an increase in mitotic rate, atypical cytologic features (size, shape, nuclear features) and abnormal organization (cellularity, differentiation, polarity) that fall short of invasive carcinoma (premalignant change).Dysplasia may progress to cancer and dysplastic changes may be found adjacent to foci of cancer.

1.2 Epidemiology

Population distribution of cervical intraepithelial neoplasia/dysplasia resembles the epidemiology of an infectious disease that is sexually transmitted. Multiple male sexual

partners, early age at first sexual intercourse and male partner with multiple previous/current female sexual partners are very important risk factors.

1.3 Incidence

The estimated annual incidence in the United States of CIN among women who undergo cervical cancer screening is 4 percent for CIN 1 and 5 percent for CIN 2,3 [Agorastos et al 2005]. High grade lesions are typically diagnosed in women 25 to 35 years of age, while invasive cancer is more commonly diagnosed after the age of 40, typically 8 to 13 years after a diagnosis of a high grade lesion. Between 250,000 and 1 million American women are diagnosed with CIN annually. Women can develop CIN at any age, however, women generally develop it between the ages of 25 to 35. [Kumar et al 2007]

In developing Nations like Nigeria the mean age for cervical intraepithelial neoplasia (CIN) was 37.6 years. CIN I accounted for 3.6%, CIN II 0.8% and CIN III was only 0.4%. The combined prevalence was 48 per 1000. The peculiarity of the developing nations result is the poor uptake or use of screening methods (Oguntayo & Samaila).

In view of the fact that CIN is a premalignant or precursor of cervical cancer it is pertinent to briefly see the incidence and prevalence of this disease condition.

Cervical cancer is second only to breast cancer in its incidence world wide. Cancer registry data shows that there are approximately 400,000 new cases of cervical cancer and 200,000 deaths from this disease every year (IARC 2001).

The incidence rate varies from country to country with eighty percent (80%) of the cases occurring in less developed countries. The reasons for this may lie in the socio economic conditions that prevail in these countries where facilities for family planning, obstetric and gynaecological health care are scarce and cervical screening programmes are virtually non existent. (IARC 2001).

The relative incidences of cervical intra-epithelial neoplasia (CIN) and invasive cervical cancer were studied in black and white patients at the academic hospitals of the University of the Orange Free State. A statistically high significant differences was found between black and white patients, with a higher incidence of invasive cervical cancer than stage III CIN (CIN III) in black patients and a higher incidence of CIN III than invasive cervical cancer in white patients ($P=0.000092$; 95% confidence interval -0.355 - -0.128). The time interval between the peak incidence of CIN III and that of invasive cervical cancer was found to be shorter in black than in white patients. These distressing findings emphasise the urgent need for a national cervical cytological screening programme to decrease the incidence of invasive cervical cancer (NEL1994)

2. Anatomy

2.1 Anatomy of the uterine cervix

The cervix is actually the lower, narrow portion of the uterus, connected to the uterine fundus by the uterine isthmus. Its name is derived from the Latin word for "neck." It is cylindrical or conical in shape. Its upper limit is considered to be the internal os, which is an

anatomically and histologically ill-defined junction of the more muscular uterine body and the denser, more fibrous cervical stroma. The size and shape of the cervix varies widely with age, hormonal state, and parity. In parous women, the cervix is bulkier and the external os, or lowermost opening of the cervix into the vagina, appears wider and more slit-like and gaping than in nulliparous fig 2 women. Before childbearing, the external os is a small, circular opening at the center of the cervix fig 1. After the menopause it may narrow almost to a pin point fig 3. The portion of the cervix exterior to the external os is called the ectocervix. The passageway between the external os and the body of the uterus at the isthmus above is referred to as the endocervical canal. Its upper limit is the internal os.⁵

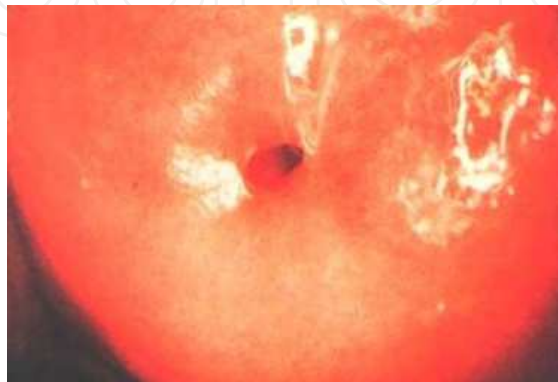

Fig. 1. The nulliparous cervix: note the small round os

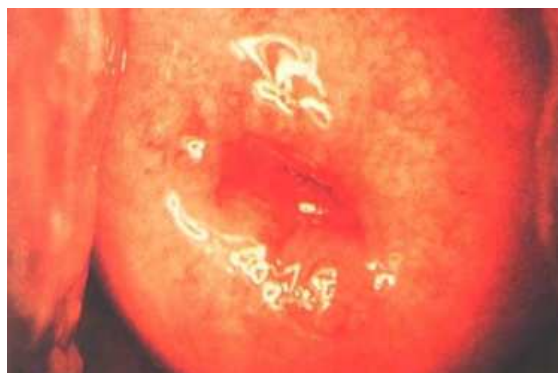

Fig. 2. Multiparous cervix

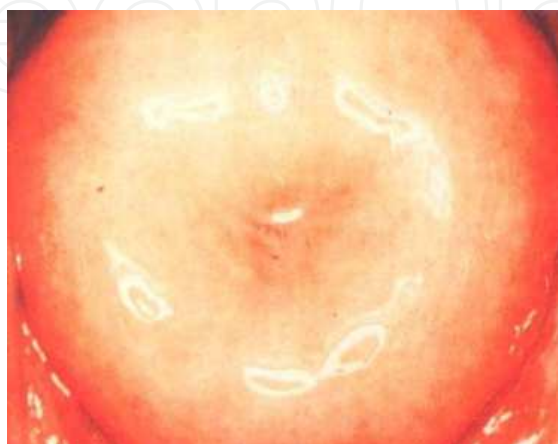

Fig. 3. Menopausal cervix

The canal itself shows a complex configuration of mucosal folds or plicae. These make cytologic screening and colposcopy of the endocervical tissues technically more difficult and less reliable than for the smoother and more accessible squamous epithelium of the ectocervix.(ASCCP 2011)

2.2 Embryology of the uterine cervix

Two paramesonephric ducts form from coelomic epithelium extending beside the mesonephric ducts. In the absence of Mullerian Inhibitory Factor these ducts proliferate and grow extending from the vaginal plate on the wall of the urogenital sinus to lie beside the developing ovary. The paired ducts begin to fuse from the vaginal plate end, forming the primordial body of the uterus and the unfused lateral arms form the uterine tubes.see fig 4

The picture bellow is the summary of the embryonic development of the uterine cervix and the second is showing the infantine uterus as it appears and this is an evidence that there are significant changes that do occur as the girl child grows fig 5. The main clinical reference to this is basically in the epithelia changes between pre pubertal and post pubertal period. The epithelia lining of the cervical canal (endocervix) is the columnar epithelium while that of external cervix (endocervix) is squamous epithelium. The squamo-columnar junction is located at the point where the squamous epithelium and the columnar epithelium meet. The location varies throughout a woman's life due to the process of metaplastic changes in the cervical epithelium which occur after puberty and in pregnancy.(Mark 2010)

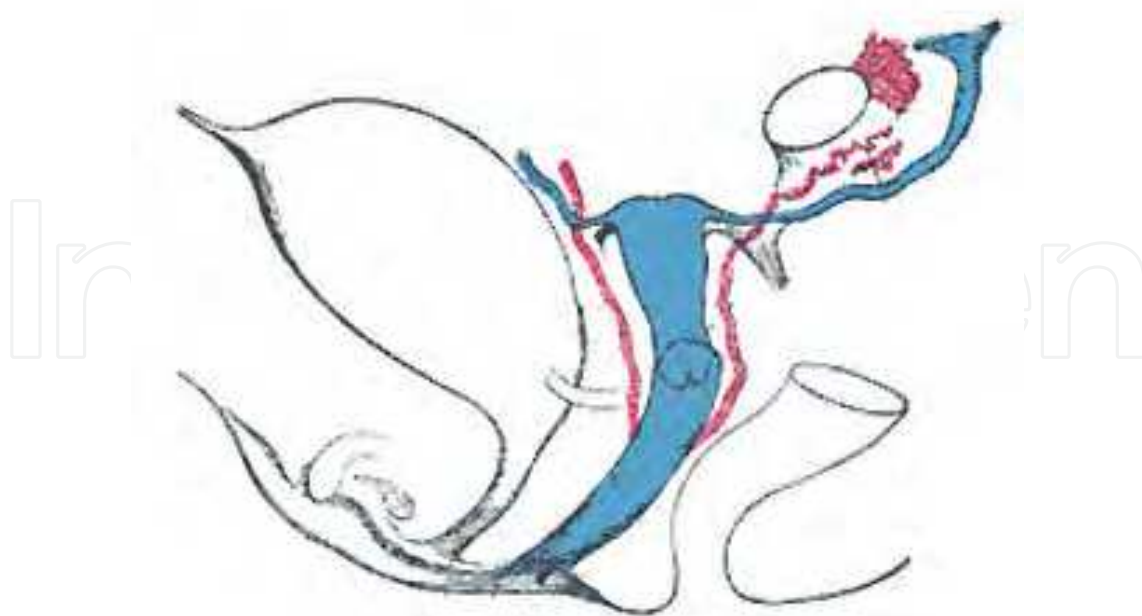


Fig. 4. Embryological Origin of the Uterus

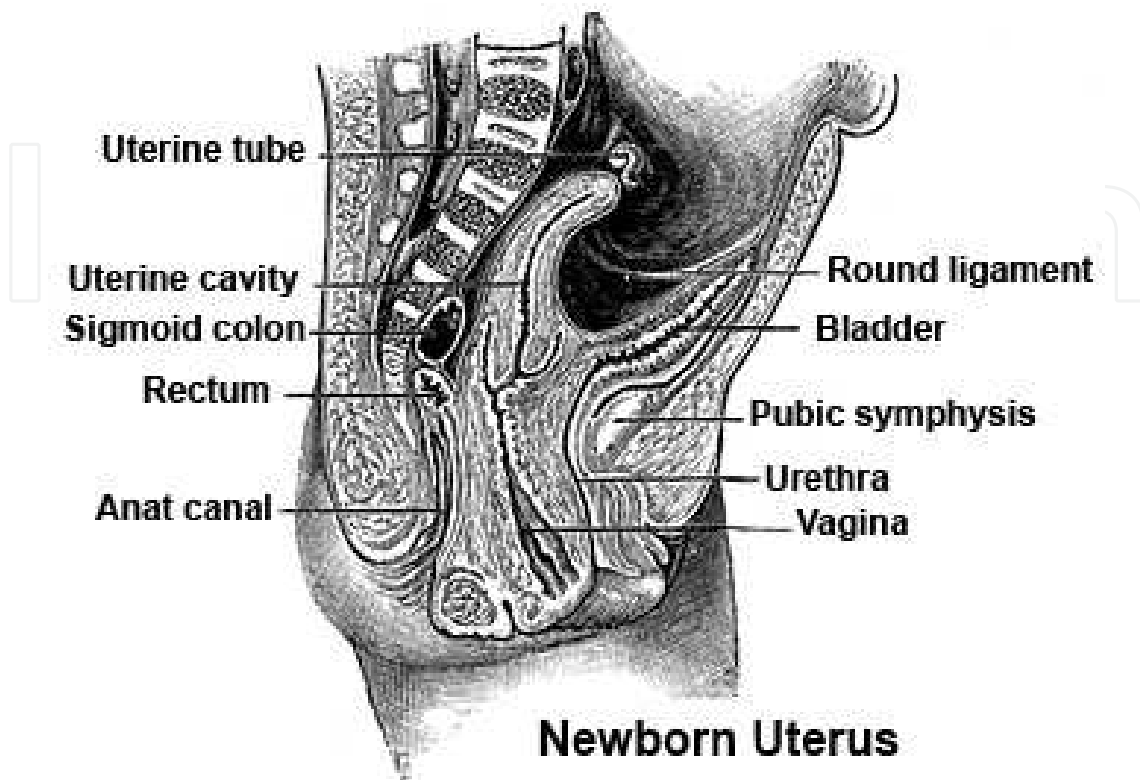


Fig. 5.

2.3 Cervix-normal histology

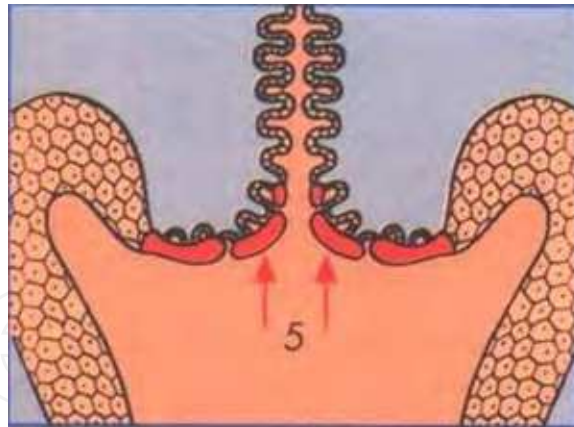
Most of the cervix is composed of fibromuscular tissue. The Epithelium is either squamous or columnar.

The endocervix is lined by columnar epithelium that secretes mucus this epithelium has complex infoldings that resemble glands or clefts on cross section and the mucosa rests on inconspicuous layer of reserve cells.

The ectocervix (exocervix) is covered by nonkeratinizing, stratified squamous epithelium, either native or metaplastic; has basal, midzone and superficial layers. After menopause and in prepubertal girls the superficial layer becomes atrophic with mainly basal and parabasal cells with high nucleo-cytoplasmic ratio that resembles dysplasia.

2.3.1 Squamocolumnar junction: where squamous and glandular (columnar) epithelium meets this a major land mark in cervical dysplasia, it is usually in exocervix. The nearby reserve cells are involved in squamous metaplasia, dysplasia and carcinoma.

2.3.2 Transformation zone: also called ectropion, between original squamocolumnar junction and border of **metaplastic squamous epithelium**; epidermalization and squamous differentiation of reserve cells transform this area to squamous epithelium; site of squamous cell carcinomas and dysplasia.



Metaplastic change of endocervical epithelium in the transformation zone

In the cervix a lot of metaplasia takes place which was what encouraged a lot of study to be conducted.

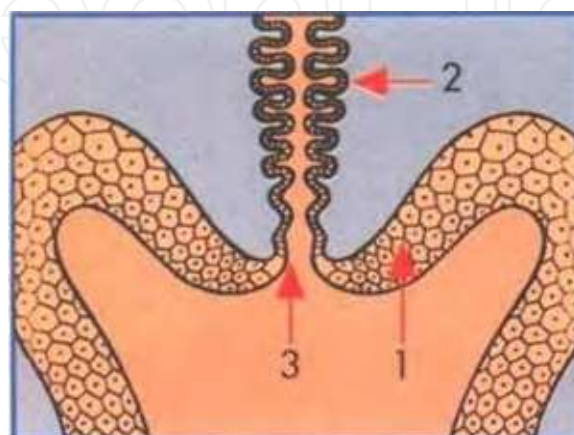
- Metaplasia is the name given to the process by which one fully differentiated type of epithelium changes into another.
- It is usually an adaptive change which occurs in reaction to longstanding (chronic) irritation of any kind, or in response to hormonal stimuli.
- Metaplastic change is reversible and theoretically transformed epithelium should revert to its original form after the stimulus is removed but this does not always happen.
- Metaplasia occurs at many body sites eg gastric mucosa, bladder, bronchi etc. The metaplastic process has been extensively studied in the cervix.

2.4 Physiology of metaplastic changes on the cervix

The metaplastic changes seen are related to the following:

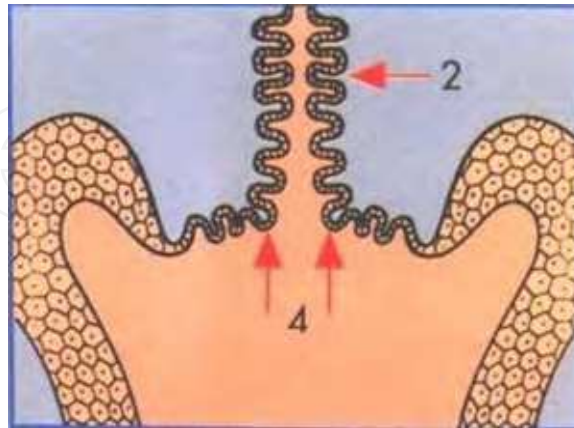
Pre-Puberty, Post puberty, Pregnancy and Menopause.

Pre-puberty-From birth until puberty the endocervical epithelium is composed of columnar epithelium and the ectocervix of native squamous epithelium. The interface between the two is termed the original squamocolumnar junction.



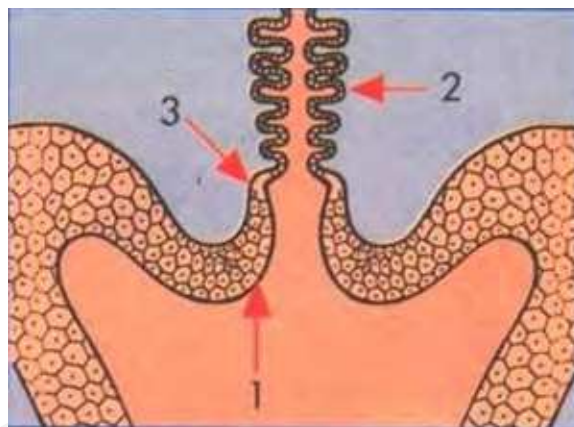
Squamocolumnar junction prior to puberty.

Puberty-During puberty and at the first pregnancy the cervix increases in volume in response to hormonal changes. The endocervical epithelium everts onto the ectocervix (portio vaginalis) exposing it to the acid pH of the vagina. This provides a stimulus for metaplastic change of the columnar epithelium.



Eversion of the endocervical epithelium at puberty and first pregnancy

Menopause-The process of metaplasia is a patchy one: It starts initially in the crypts and at the tips of the endocervical villae which gradually fuse. Eventually the whole of the everted endocervical epithelium may be replaced by squamous epithelium.



Relocation of SCJ in the endocervical canal after the menopause

Key:

- 1: native squamous epithelium
- 2: columnar epithelium of endocervix
- 3: squamocolumnar junction (SCJ)
- 4: Eversion of endocervical epithelium
- 5: Metaplastic change in transformation zone (Eurocytology 2011)

The Clinical significance of squamous metaplasia in the cervix is that, this area of the cervical epithelium has undergone metaplasia (Transformation zone) and all the immature metaplastic areas are susceptible to carcinogens. In view of the aforementioned, it is not surprising that most cervical cancers arise here.

2.4.1 Basal cells (reserve cells): cuboidal to low columnar with scant cytoplasm and round/oval nuclei; acquire eosinophilic cytoplasm as they mature; positive for low molecular weight keratin and estrogen receptor; negative for high molecular weight keratin and involucrin

2.4.2 Suprabasal cells: have variable amount of glycogen, detectable with Lugol/Schiller's test (application of iodine)

2.4.3 Glandular epithelium: positive for estrogen receptor.

3. Aetiology

3.1 Association of human papillomaviruses and cervical Intraepithelia neoplasia

Human papillomaviruses (HPV) are members of a family of viruses known as the Papovaviruses fig 5. They are epitheliotropic viruses which promote cell proliferation which results in the development of benign papillomatous lesions of the genital tract upper respiratory tract, digestive tracts and cutaneous lesions of the skin. More than 70 distinct HPV types have been identified as a result of molecular hybridisation of DNA extracted from condylomata or warty lesions from a variety of sites. Each virus type has a very restricted site of infection and viruses which occupy similar niches appear to be genetically related. Molecular hybridisation of anogenital warts and cervical biopsies have shown that about 30 of the 70 distinct types of HPV are confined to the female genital tract. (Eurocytology).

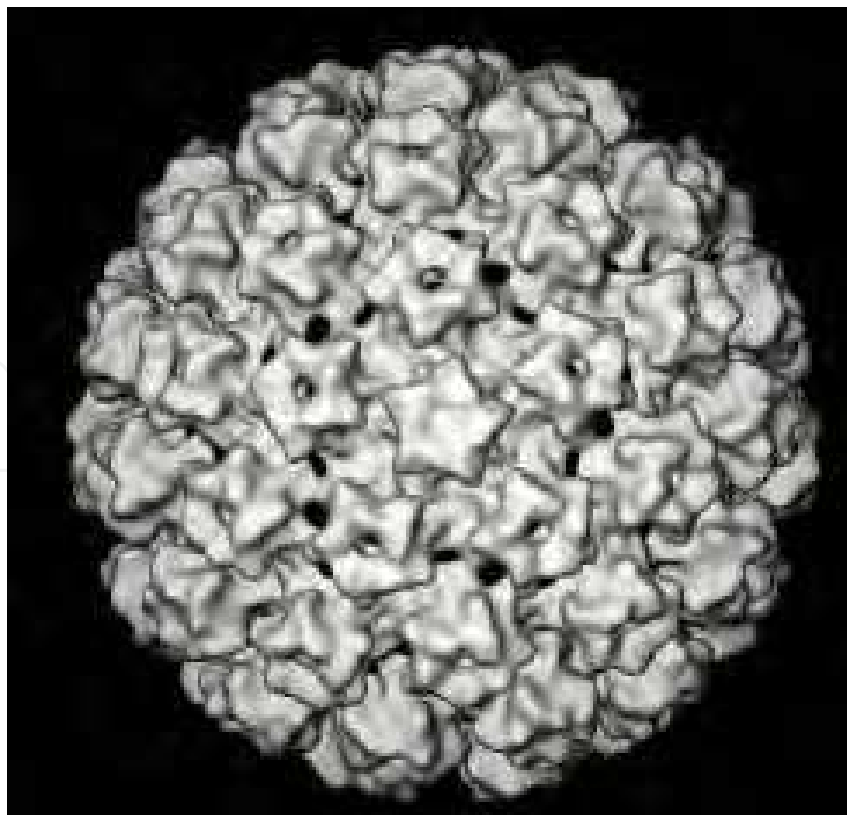


Fig. 6. Electronmicrograph of human papillomavirus (courtesy Eurocytology)

DNA analysis of anogenital warts,CIN and cervical cancerous tissue has shown that two groups of HPV can be identified in the female genital tract. One group of HPV is almost always associated with low grade CIN lesions and exophytic anogenital warts which have a *low risk of progressing to cervical cancer*. A second group of viruses is found most commonly in CIN2 and CIN3 which have a *high risk of developing into invasive cancer*.

3.1.1 HPV types found in the female genital tract

The major cause of CIN is chronic infection of the cervix with the sexually transmitted human papillomavirus (HPV), especially the high-risk HPV types 16 or 18(**viruses from the high risk group (HPV16 and HPV 18) have the ability to immortalise primary human keratinocytes ie extend their lifespan**) In comparison viruses from the low risk group (HPV-6 and HPV -11) do not extend the life span of transfected human cells which mature and die at the same rate as non infected cells fig 7. Similarly the low risk viruses perform poorly in experiments concerned with the malignant transformation of rodent cells in comparison to the high risk HPV types. Moreover, HPV-16 and HPV -18 infected human keratinocytes in raft culture (an organotypic culture medium) exhibit a differentiation pattern very similar to that seen in vivo in CIN.(Eurocytology). Over 100 types of HPV have been identified. About a dozen of these types appear to cause cervical dysplasia and may lead to the development of cervical cancer. Other types cause warts. Wikipedia,



High risk	
	16,18, 31, 33, 35, 39, 45, 51, 52, 56, 58, 59, 68 may lead to Invasive Cancer
Low risk	
	6, 11, 42, 44, 53, 54, 62, 66 may lead to condylomata

Fig. 7.

3.2 The viral DNA Integration

The viral DNA Integration is a consistent finding in all cancers harbouring the *high risk* virus types HPV16 and HPV18 and provides the **strongest evidence** that HPV16 and HPV18 play an important role in the development of cervical cancer. **HPV DNA is present in 90% of all cervical invasive cancer.**

It is not sufficient to say that simple infection with high risk HPV or even integration of HPV 16 /18 into the host cell nucleus is enough for malignant transformation of the cervical epithelium.Obviously Infection of the genital tract with HPV 16 is relatively common whereas invasive cancer is rare; and integration has been detected in some cases of genital warts and CIN lesions. A number of associated-factors have been proposed such as impaired immune response, persistence of virus, smoking and administration of steroid hormones (as oral contraceptives). Other genetic events such as loss of tumour suppressor genes and the activation of oncogenes may also play a role . Mutations in *ras* ,*fos* and other oncogenes have been detected in cervical cancer cell lines but their role *in vivo* is still to be determined.The knowledge of HPV infection has made a remarkable improvement in the screening,diagnosis,treatment,prevention and prognosis of cancer of the cervix.

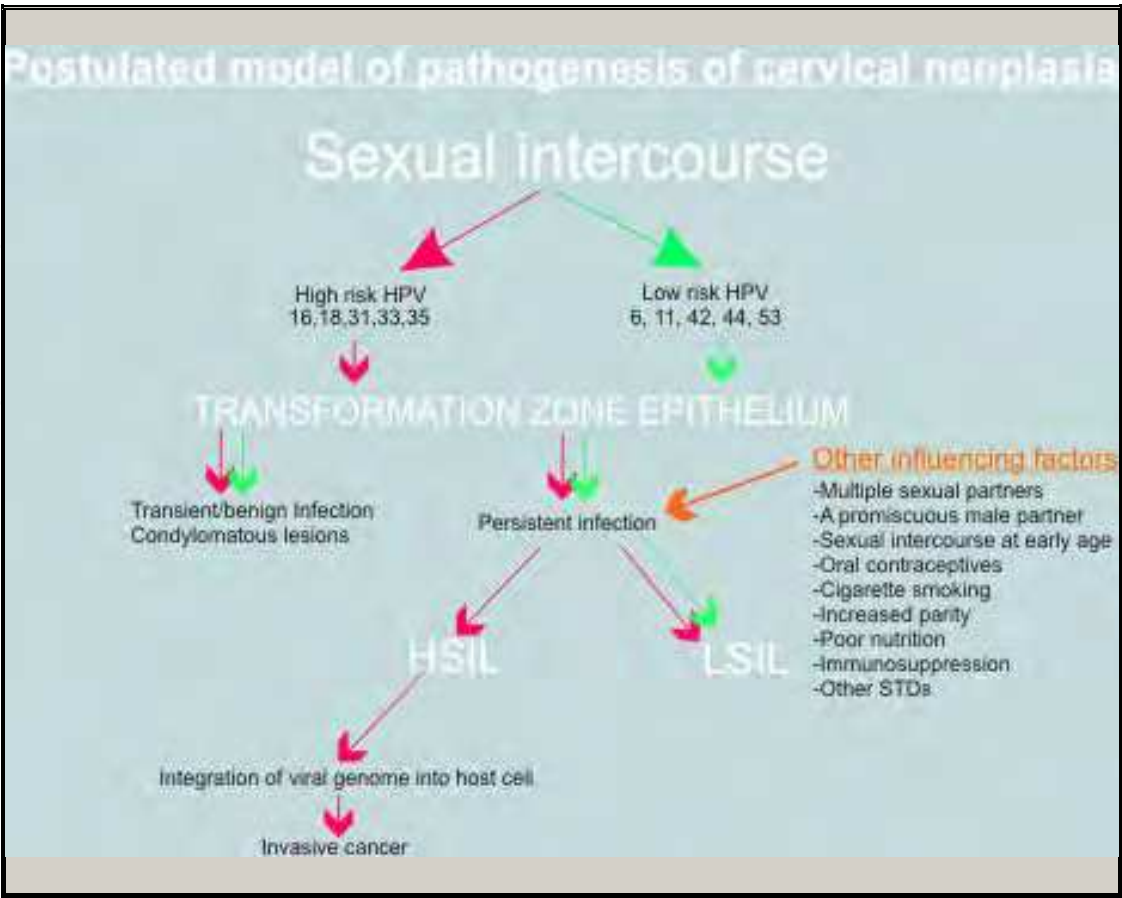


Fig. 8.

3.3 The host immune system and HPV

The host immunity plays a significant role in the control of this disease entity. The fact that HPV remains localised to cervix and vagina further indicates that local immune responses are sufficient in controlling and resolving HPV infection. Both cell mediated immunity and humoral immunity fig 8. Also immunosuppression has been implicated as an associated factor. The majority of infections are transient and not clinically evident with 70-90% of infections clearing within 12-30 months. This suggests that host immunity is generally able to clear HPV infection.

4. Histopathological features

4.1 Histo-pathological changes

Abnormal cellular proliferation, maturation and atypia characterize cervical intraepithelial neoplasia(CIN). Nuclear abnormality is the hallmark of CIN and includes hyperchromasia, pleomorphism, irregular borders, and abnormal chromatin distribution. These nuclear abnormalities persist throughout the epithelium irrespective of cytoplasmic maturation towards the surface. Mitotic rate is increased and abnormal mitotic figures may be seen.

Histologic grading of CIN is based on the proportion of the epithelium occupied by dysplastic cells. The epithelium is divided into thirds.

4.2 Grading

- **4.2.1 CIN 1** is considered a low grade lesion. It refers to mildly atypical cellular changes in the lower third (basal 1/3) of the epithelium (formerly called **mild dysplasia**/Abnormal cell growth). HPV viral cytopathic effect (koilocytotic atypia) is often present. This corresponds to infection with HPV, and typically will be cleared by immune response in a year or so, though can take several years to clear.
- **4.2.2 CIN 2** is considered a high grade lesion. It refers to moderately atypical cellular changes confined to the basal **two-thirds** of the epithelium (formerly called moderate dysplasia) with preservation of epithelial maturation.
- **4.2.3 CIN 3** is also considered a high grade lesion/Severe dysplasia. It refers to severely atypical cellular changes encompassing **greater than two-thirds** of the epithelial thickness, and includes full-thickness lesions (formerly called severe dysplasia or carcinoma in situ).

CIN 1 (mild dysplasia): Dysplastic cells occupy the lower third of the epithelium.fig 9

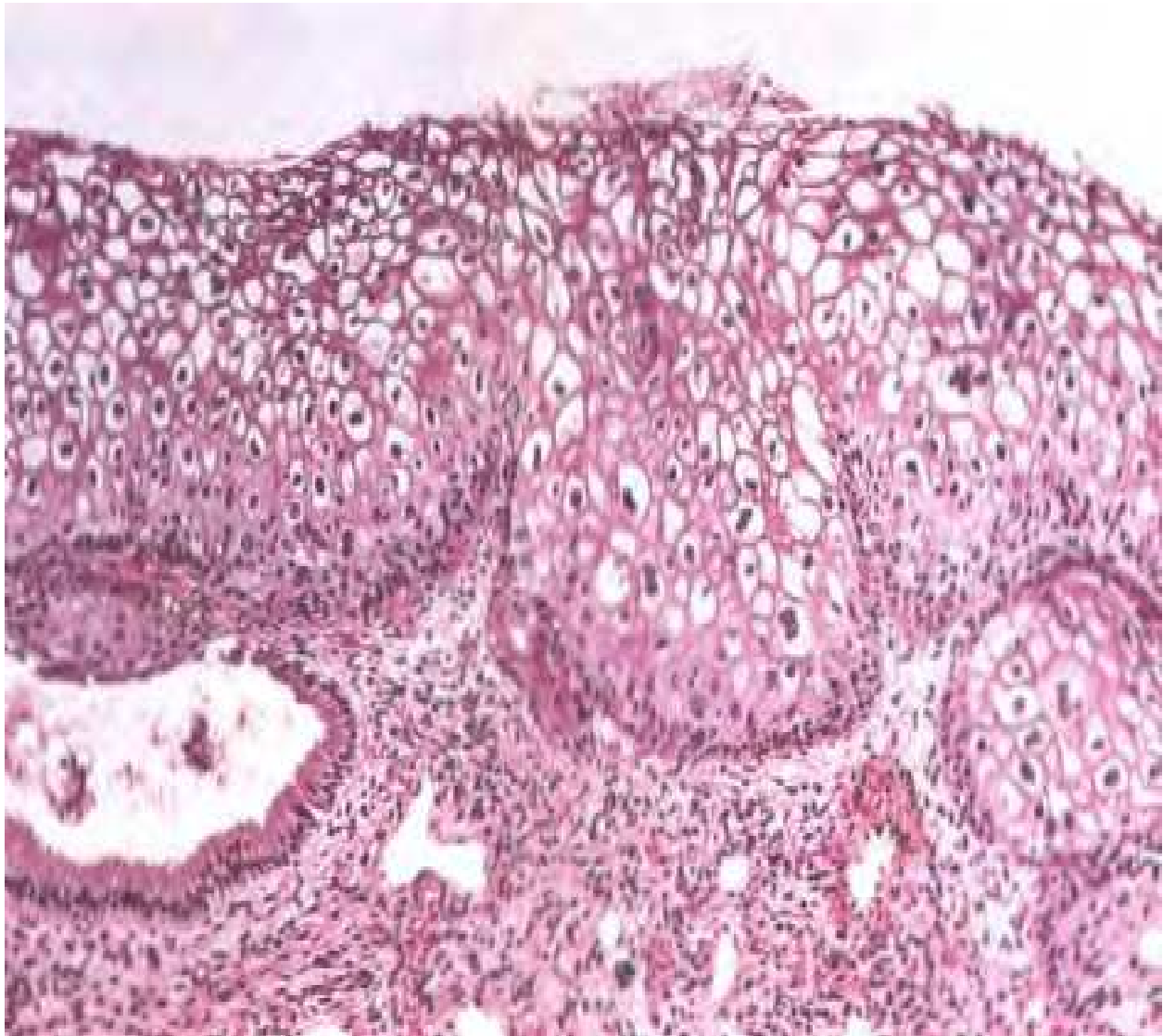


Fig. 9.

CIN 2 (moderate dysplasia): Dysplastic cells occupy up to the middle third of the epithelium. See fig 10.

IntechOpen

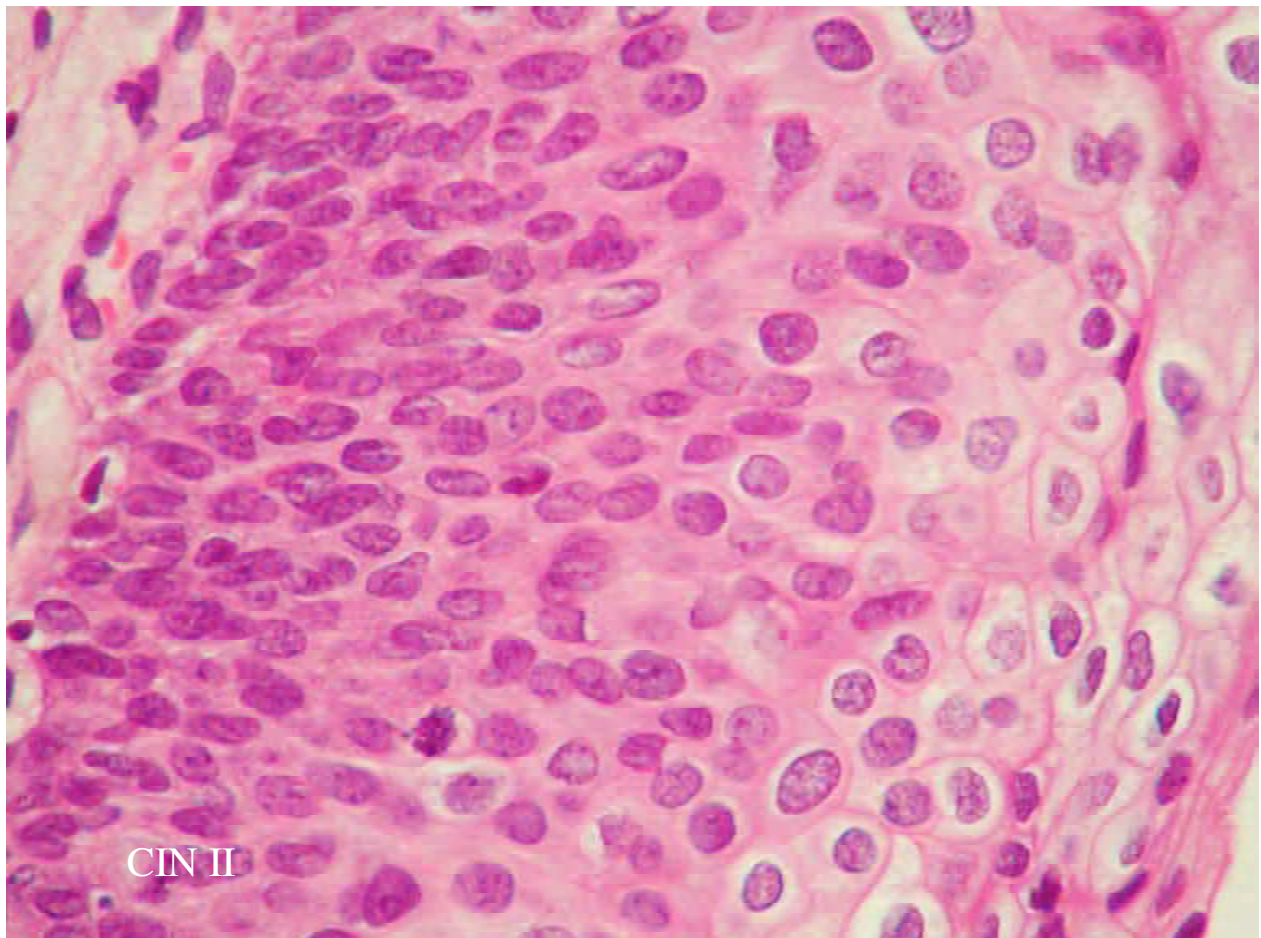


Fig. 10. CIN 2. Note superficial koilocytosis.

CIN 3 (severe dysplasia, carcinoma in situ): Dysplastic cells extend into the upper third and may occupy the full thickness of the epithelium.fig 11

IntechOpen

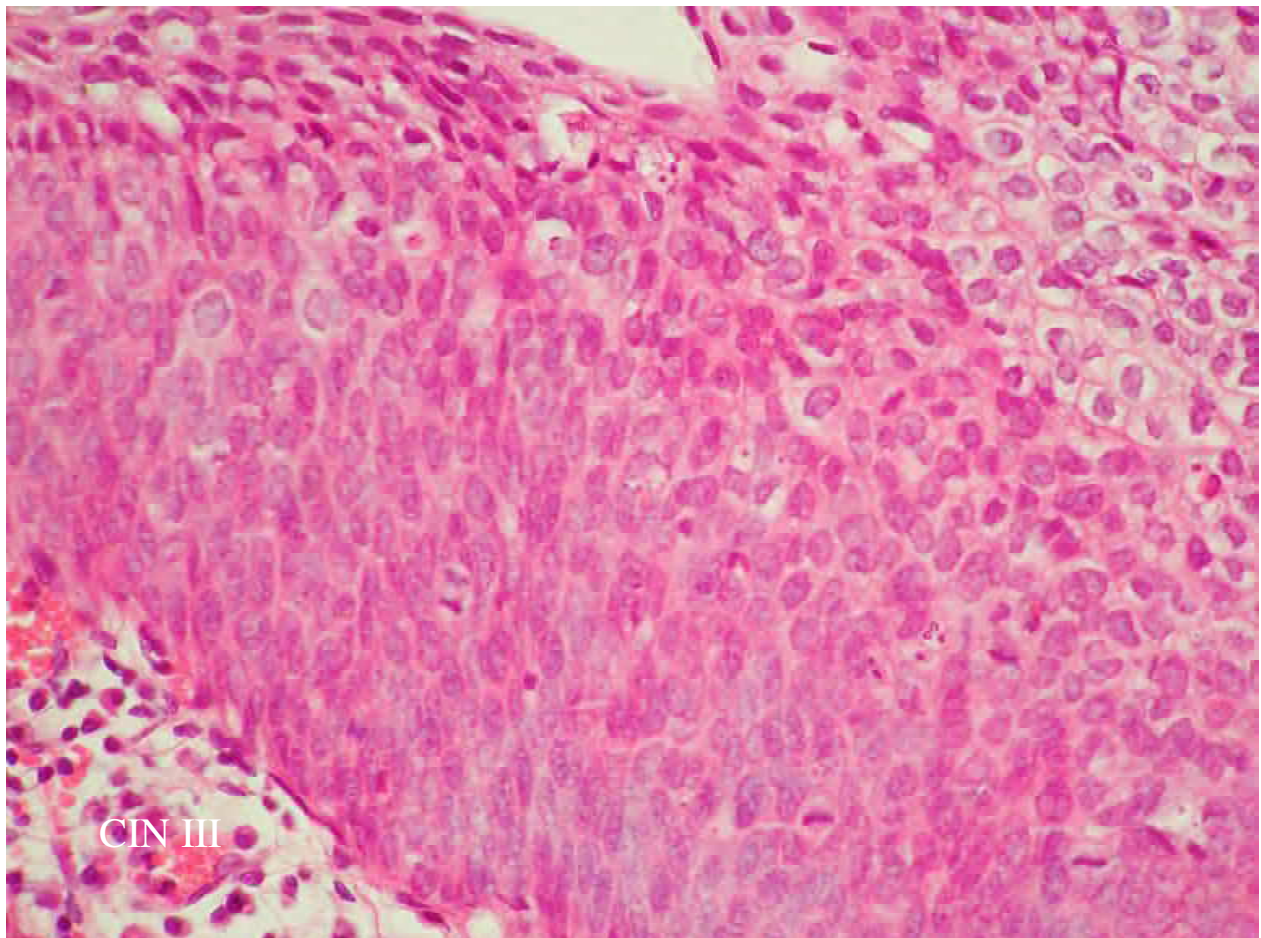


Fig. 11. CIN3. Note adjacent koilocytes (bottom right)

Cytologic grading of CIN also uses a three-tier system. However, the new Bethesda System for cytological diagnosis divides precursors of cervical squamous cell carcinoma into *low-grade squamous intraepithelial lesion* and *high-grade intra-epithelial lesion*.

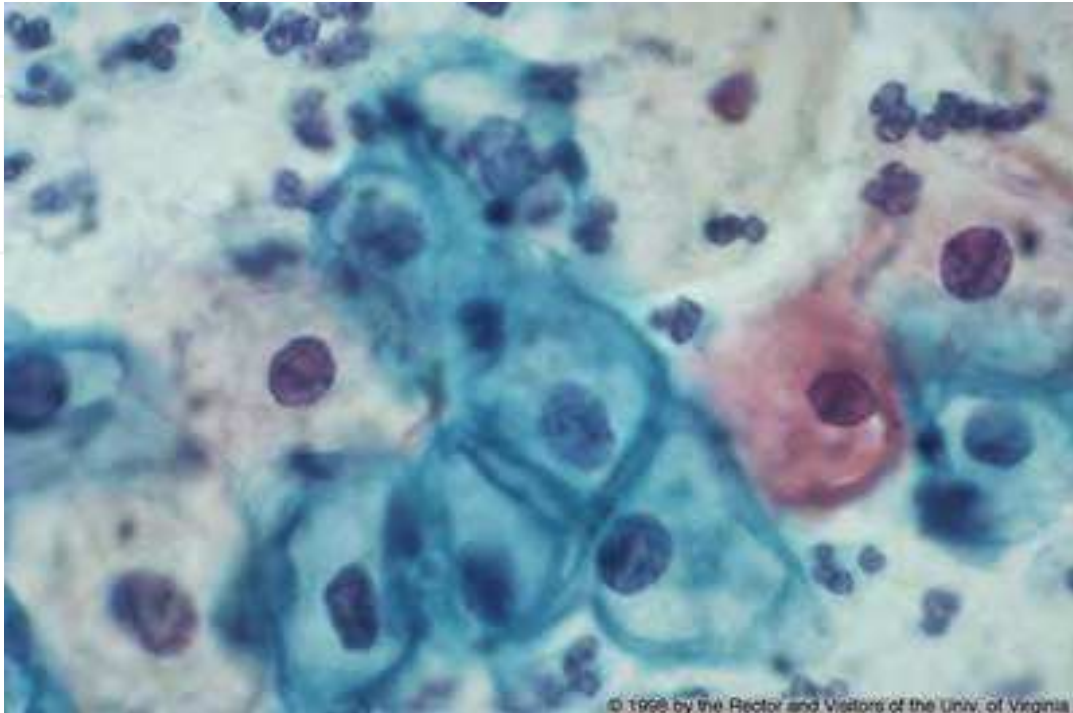


Fig. 12. Pap smear of CIN 1. Note large, dark nuclei, but also large amount of surrounding cytoplasm.

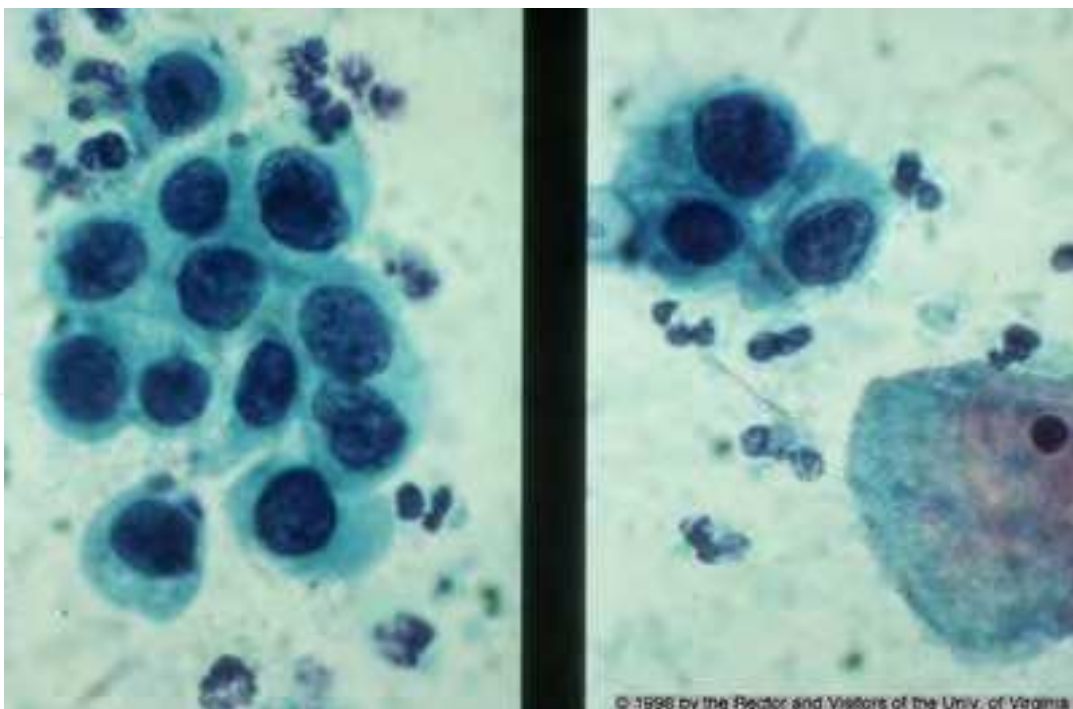


Fig. 13. Pap smear of CIN 3. Note large, dark nuclei with a lesser amount of surrounding cytoplasm. Compare to superficial cell (lower right hand corner).see fig 12 & 13

5. Clinical presentation

5.1 Clinical appearances

CIN lesions are characterized by the appearance of white patches on the cervix following application of acetic acid. Distinct vascular patterns can be seen on colposcopic examination of the cervix in high grade CIN. Lesions occur on the anterior lip twice as commonly as the posterior lip. They are found in the transformation zone and areas of squamous metaplasia in the endocervix and stop abruptly at the junction with the native portio squamous epithelium but can extend along the entire endocervical canal. In general, the portion of CIN on the portio surface is low grade (CIN 1) whereas the portion that extends into the endocervical canal is high grade (CIN 2 and 3).

5.2 Clinical behavior

CIN may regress (spontaneously, especially CIN1), persist or progress. If untreated, up to 16% of CIN1 will progress to CIN3 and up to 70% of CIN3 will progress to invasive squamous cell carcinoma in 1 to 20 years. It is not presently possible to predict which lesions will progress. However, the risk of progression to invasive cancer increases and the time required is shorter with increasing severity of the lesion.(UVa Health).

6. Screening

The aim of screening is to prevent the development of cancer. For screening to be effective, a disease should satisfy the following criteria.

Be common, serious and an important public health concern for the individual and the community.

The disease condition must have a long, latent interval in which pre-malignant change or occult cancer can be detected for the case of cancer of the cervix it is 10-15years.

The natural history of the disease, especially, its evolution from latency to disease should be adequately documented.

There should be effective treatment for pre-malignant change or condition.

The good news is that cervical cancer screening has satisfies the above criteria, especially with regards to developing countries where it really is a public health problem. Cervical screening has been shown to be effective in several countries.

Cervical cancer prevention efforts worldwide have focused on screening women at risk of the disease using Pap smears. Treating precancerous lesions has also prevents cervical cancer in many of the developed countries. In view of the afore mentioned cancer of the cervix is almost extinct in the developed nations,making it the 11th cancer in women and 2nd commonest in developing nations.

6.1 Coverage of the screening programme

It is recommended for all women; especially aged 20 – 64 are invited for screening.

It should be carried out every 3-5 years.

The screening is carried out every 3 years in Women aged 45 years and below.

Where as it is done every 5 years in Women aged >45 yrs.

Some other risk factors that have been found to be important in developing CIN that would benefit from screening includes (Kumar et al 2007)

- Women who become infected by a "high risk" types of HPV, such as 16, 18, 31, or 45
- Women who have had multiple sexual partners
- Women who smoke
- Women who are immunodeficient and Women who give birth before age 17 years.

6.2 Screening technique/process

There are various types of screening test. AS was earlier discussed in this chapter cervical cancer is one of the cancers that has meet all the requirement for cancer screening. The methods that can be employed for this purpose includes, visual inspection using either Acetic acid or Lugol's Iodine, Cytological analysis and Human papilloma virus immune assays.

6.2.1 Types of visual inspection test

Visual inspection with Acetic Acid or Visual Inspection with Lugol's Iodine. The former is the one that is commonly used for ease of interpretation.

6.2.2 Visual inspection with acetic acid (VIA) can be done with the naked eye (also called cervicospoty or direct visual inspection [DVI]), or with low magnification (also called gynospoty, aided VI, or VIAM).

Visual Inspection with Acetic Acid (VIA) – It more relevant in the developing Nations.

Visual inspection with acetic acid (VIA) is an attractive screening method for early-phase cervical cancer in underdeveloped countries. It is an acceptable screening method for cervical cancer and seems to be an efficient and cost-effective method to detect high-level dysplasia.

6.3 Test performance: Sensitivity and specificity (Defn)

Sensitivity: The proportion of all those with disease that the test correctly identifies as positive.

Specificity: The proportion of all those without disease (normal) that the test correctly identifies as negative.

In the screening of cervical cancer, the sensitivity of VIA was high, whereas the corresponding specificity was only at an acceptable level. The Positive Predictive Value (PPV) and Negative Predictive Value of VIA were found to be high. In other words, the validity of VIA during early-phase screening is high in terms of sensitivity and acceptable for specificity and predictive values. (Ardahan et al).

6.4 Technique of VIA

Performing a vaginal speculum exam is the first step; then the health care provider applies dilute (3-5%) acetic acid (vinegar) to the cervix.

Abnormal tissue temporarily appears white when exposed to vinegar.

The cervix is viewed with the naked eye to identify color changes on the cervix.fig 14 & 15

Determining whether the test result is positive or negative for possible precancerous lesions or cancer and this based on the Aceto-white reactions.

VIA Category	Clinical Findings
Test-negative	No acetowhite lesions or faint acetowhite lesions; polyp, cervicitis, inflammation, Nabothian cysts.
Test-positive	Sharp, distinct, well-defined, dense (opaque/dull or oyster white) acetowhite areas – with or without raised margins touching the squamocolumnar junction (SCJ); leukoplakia and warts.
Suspicious for cancer	Clinically visible ulcerative, cauliflower-like growth or ulcer; oozing and/or bleeding on contact.fig 16

Negative VIA

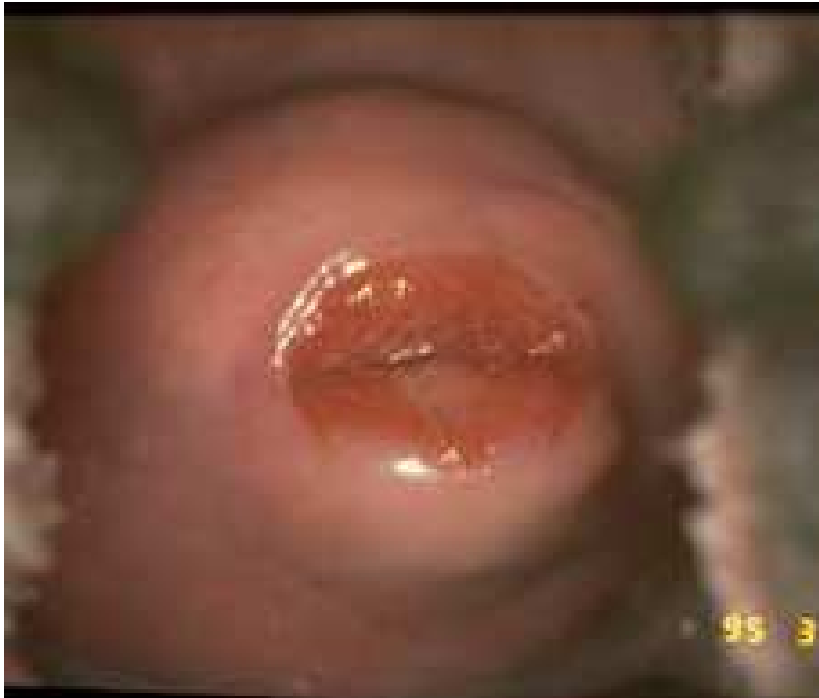

Fig. 14. Photo source: JHPIEGO

Positive VIA

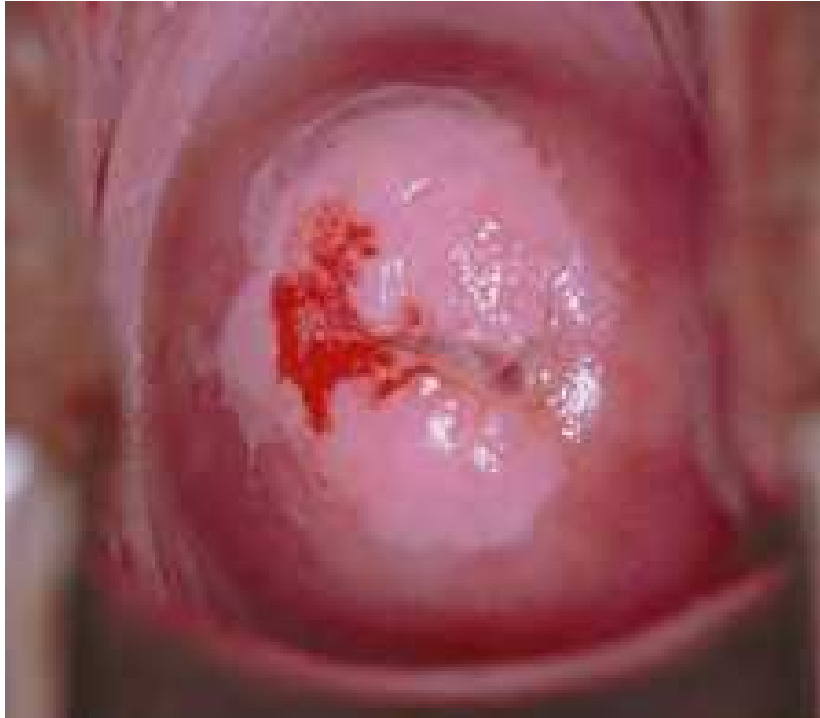

Fig. 15. Photo source: JHPIEGO

Suspicious Cancer

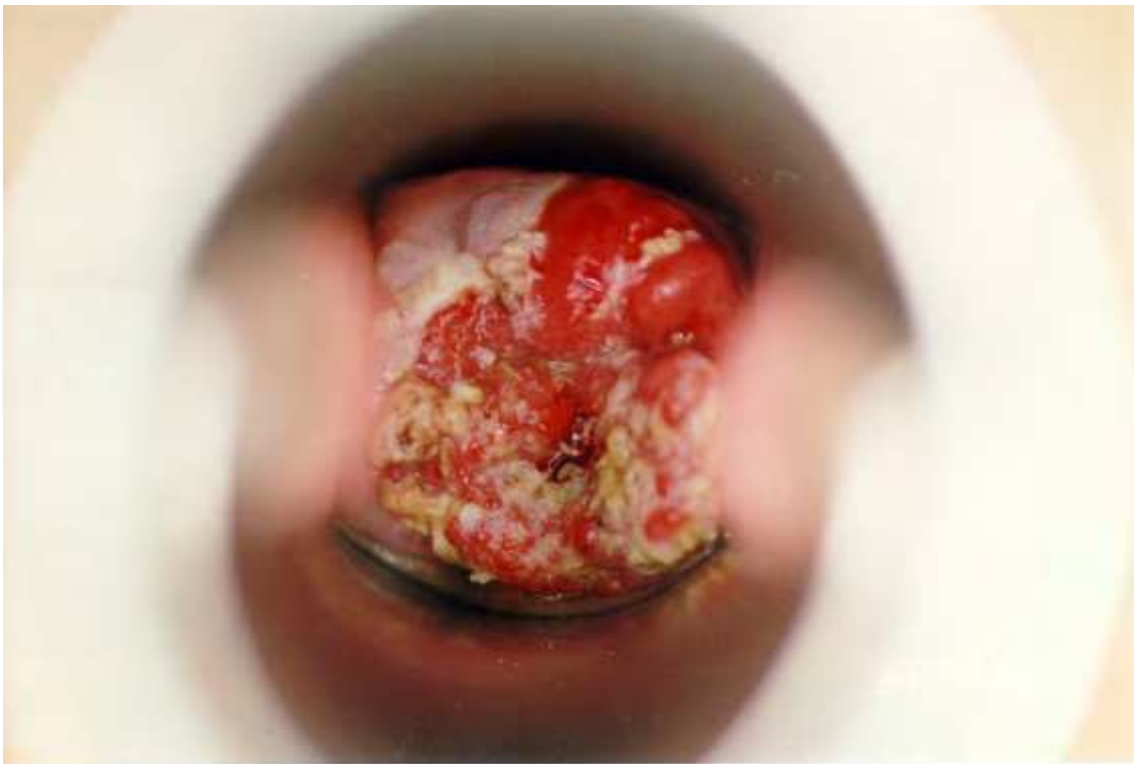

Fig. 16. Suspicion of carcinoma of the cervix. Photo source: PAHO, Jose Jeronimo

6.5 The advantages

It is Simple, easy-to-learn approach that is minimally reliant upon infrastructure.

It is not expensive to start-up and the sustaining costs is affordable.

Many types of health care providers can perform the procedure especially the middle cadre of health care providers.

The Test results are available immediately and as such the issue of follow up is out of the question.

Only requires a single visit.

It may be possible to integrate VIA screening into primary health care services and it will go along way to reduce the incidence and prevalence of carcinoma of the cervix.

There is a need for developing standard training methods and quality assurance measures.

This method isLikely to be less accurate among post-menopausal women caution in its interpretations.

6.6 Visual inspection with Lugol's iodine (VILI)

Visual inspection with Lugol's iodine (VILI), also known as Schiller's test, uses Lugol's iodine instead of acetic acid and it is based on colour change also.

6.7 Pap smear

The Pap test was developed by Dr George Papanicolaou an American anatomist in 1944. Pap test is used primarily as a tool for screening healthy women for preinvasive cervical cancer (CIN) and early invasive cancer. In as much as pap test is a screening tool, it could also be use to identify women at risk of cervical cancer. Women with early invasive cancer (FIGO Stage 1) are often unaware that they are harbouring the tumour as they are usually symptom free. Diagnosis and treatment of invasive cancer while it is still in the early stages of development significantly improves the prognosis (chances of long term survival) of the patient.

It has been proven over time that the cervical smear may be negative even in the presence of an advanced invasive cervical cancer. This is because blood, inflammatory cells and necrotic debris from the cancer site frequently obscure the abnormal cells in the smear.

6.8 Specimen sampling

The sample for pap smear can be collected in three ways

6.8.1 a) liquid-based cytology (LBC) - using a cyto- brush a device which samples both endo and ectocervix. These can be used for preparing conventional smear. Some devices have been modified for the preparation of liquid based cytology (LBC) specimens

6.8.2 b) Papanicolaou (Pap) smear test uses a brush or the Ayres spatula to sample the ectocervix. Scraping the ectocervix with with a modified spatula (the Ayre spatula or a

variation of it). This is the most widely used method in developing countries and some part of Europe for obtaining material for preparing conventional cervical smears

6.8.3 c) Using an endocervical brush to sample the endocervix this grossly inadequate and it is been discouraged.

Some of the items required for Pap smear.

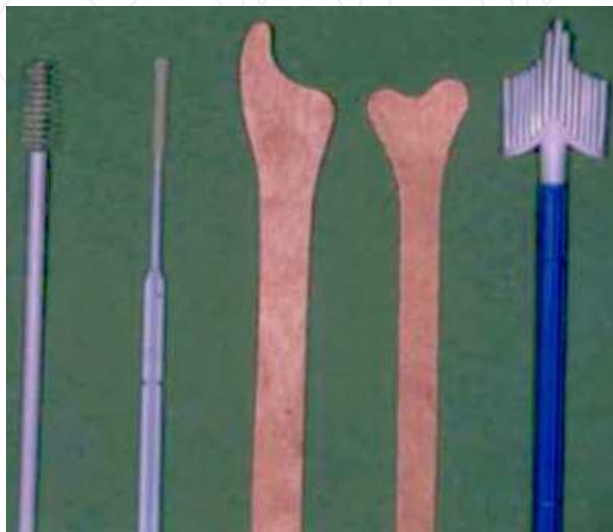

Fig. 17. Example of Fixatives

95% ethanol (for fixation)
80% isopropanol
95% denatured alcohol

Ayres/Cytobrush

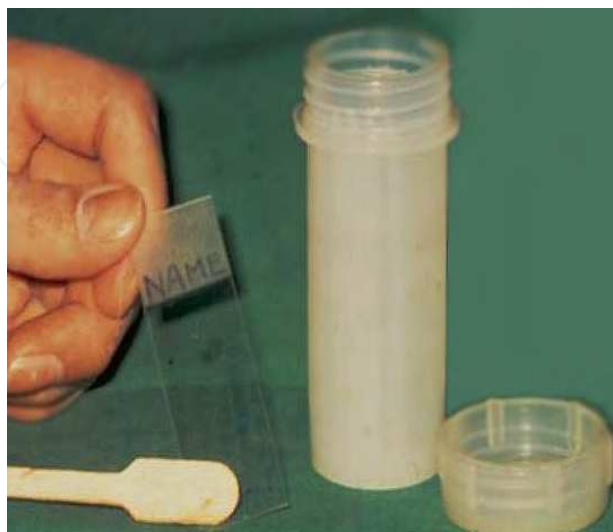

Fig. 18. Fixative Jar/Glass slide

6.8.4 The step by step approach of Pap test

1. A speculum must be inserted into vagina and the cervix clearly visualised. The cervical os should be located.
2. The sampling device(s) used should be selected according to the shape and size of the cervix and the location of the squamocolumnar junction. An Ayre spatula is suitable for sampling the cervix in a parous woman; however a spatula and brush may be needed in a post menopausal woman where the squamocolumnar junction lies within the endocervical canal. fig 17
3. The pointed end of the spatula should be inserted into the cervical os in a nulliparous cervix and the rounded end of the spatula inserted into the patulous os of a parous woman. The device should be rotated 360 degrees to remove the cells from the region of the transformation zone, squamocolumnar junction and endocervical canal.
4. The material on the spatula or brush must be transferred immediately to a glass slide which has been previously labeled with the patient's name and date of birth.
5. The glass slide (fig 18) must be fixed immediately with an appropriate fixative (95% alcohol) and the slides transported to the cytology laboratory in a container for processing together with the corresponding cytology request form.
6. Samples taken for Liquid Based Cytology should be processed strictly in accordance with the manufacturers instructions. After sampling the cervix, the tip of the sampling device should be broken off into the transport medium in the container provided which should then be transported to the laboratory for processing if the Surepath method is being used. However if the Thinprep method is being used it is of the utmost importance that the tip of the sampling device is not included in the container.

Fixation must be immediate. The smear must not be allowed to dry before fixation.

Test Limitations as it relates to the sensitivity and specificity and technique of smear. There is no difference in specificity, but sensitivity is 12% better with LBC compared with the Pap smear, and its "inadequate rate" is only 1.6%, compared with mean of 9.1% with Pap smears (Sasieni P et al). Problems include:

- Variable sampling of appropriate cells from the cervix.
- Poor transfer of cellular material on to the glass slide.
- Sub-optimal preparation and fixation by the smear taker.

6.9 Smear reporting

It is widely acknowledged that the criteria and terminology used to interpret and report cervical smears differs country to country. This has led to problems of communication between cytopathologists, cytotechnologists and clinicians and makes it difficult for epidemiologists to make valid comparisons of the effectiveness of the different cervical screening programmes. The variability in terminology impedes meaningful discussion between laboratories and also affects patient management and the introduction of optimal methods of patient care.

We have the following reporting methods:

- a) British Society: In the UK current reporting guidelines are based on those published by the British Society of Clinical Cytology (BSCC) in 1985
- These are currently under review and new guidelines are expected soon.

- b) American (Bethesda) system.: The system of terminology used in the United States
- First devised in 1988, being revised in 1991 and again in 2001
- A 2 -tier system which refers to :

Atypical Squamous Cells of undetermined significance (**ASC-US**)

Low grade Squamous intraepithelia neoplasia(**LSIL**)

High grade Squamous intraepithelial neoplasia(**HSIL**)

- Proposed new BSCC guidelines will bring it in line with the Bethesda system

Compare and contrast the two (British & American)

BSCC	BETHESDA
Inadequate	Unsatisfactory for evaluation
Borderline Nuclear Change	<ul style="list-style-type: none">• ASC-US• ASC- cannot exclude high grade• Atypical glandular cells
Mild Dyskaryosis	LSIL
Moderate Dyskaryosis	HSIL
Severe Dyskaryosis	HSIL
Severe Dyskaryosis/?SCC	SCC
? Glandular Neoplasia	<ul style="list-style-type: none">• Endocervical Ca in situ• Adenocarcinoma – Endocx., Endomet., Extrauterine, NOS

Fig. 19. Courtesy of Vanessa Jackson

7. Cytology report

7.1 Handling of cytology reports

- Women with normal smears are offered re-screening at the standard 3-5 year interval - follow the advice of your local laboratory. High risk individuals may be screened more frequently. Women with moderate or severe dyskaryotic tests need colposcopy ±biopsy. Women with borderline or mildly dyskaryotic smears are monitored at a reduced screening interval with persistent abnormalities (including persistently inadequate smears) needing colposcopy.

- Unsatisfactory - Repeat smear four weeks later.

7.1.1 Inadequate slide

An inadequate slide may occur as a result of insufficient smear, or when it is adequate it is obscured. As much as possible this should be avoided.

In phase of any abnormal cells, a result of inadequate should not be given rather the abnormality should be reported.

7.1.2 Management of inadequate smear

It is an indication for a Repeat smear

- If there is a recognisable infection present the patient should be treated before a repeat smear is done.
- After three consecutive inadequate samples, there is a need to refer such for colposcopic assessment.

7.1.3 Negative

There should be enough cellular material to cover 1/3 of the slide before a pronouncement or report of a negative smear. The report actually makes the woman to be confident that she is not at risk of any dysplasia for a period of three years.

- In atrophic smears, where the cellular material is comprised of parabasal sheets, 10% of the slide can be considered adequate.
- There are no official guidelines for LBC samples.

It is possible that 15,000 cells will be the standard for adequacy.

7.1.4 Management of negative slides

We should give a recommendation of routine recall to our clients. They should be encouraged to adhere to this recommendation:

- Women Age 25-45 should be advised to repeat their smear *every three years*. While those above 45 years to 65 should have smear every five years.

Exceptions: There are exceptions to the above stated rules or recommendation.

Any patient with Clinical symptoms which are suggestive of immune suppression or are immune compromised or have been diagnosed to have immune compromised disease such as HIV positive women or women on immune suppressive drugs as in patients with renal transplant should have a repeat smear every year/12 months

The other exception is for those women who may have had the following conditions in the past: Post coital bleeding (PCB), Post menopausal bleeding (PMB), and friable cervix

All patients on follow up for previous abnormal smears are candidate for repeat based on the findings.

7.1.5 Reporting of infections

The presence of specific infections may be reported based on the histological features of such infections: Such as

- Candida
- Trichomonas – with advice to culture before treatment
- Herpes Simplex Virus – referral for counselling should be advised
- Actinomyces – like organisms
- Follicular Cervicitis – report in younger women

It is advisable that additional investigations towards definitive diagnosis must be pursued before embarking on treatment.

7.1.6 Follow up of patients on treatment

The Follow-up of women who have been treated for CIN is very crucial to ensure that there is no progression of the disease condition.

- CIN1 – repeat smears at 6months, 12months and 2years this is the schedule if the smear is persistently negative.
- CIN2 and above –This categories of patients require annual smears for 10 years of follow up.
- CGIN(Cervical Glandular Intraepithelia Neoplasia) – are at greater risk of recurrent disease so they are recommended to have smears every 6months for 2years,then annually for 10 years

Follow-up of women with low grade smears but normal colposcopy and no biopsy – require a repeat smear at 6 months, 6 months , 12 months, then return to normal recall

Follow-up of women after hysterectomy for CIN or SCC :

Where there was complete excision and the margins were clear of dysplastic cells, vault smears should be carried out at 6 months and 18 months before recall can be cancelled as no further smears are required.

In the case of women with incomplete or uncertain excision at hysterectomy, they would require follow-up as for women with CIN2 or above.

In women who have been exposed to radiotherapy as an adjuvant therapy, Smears are not advised in this group of women.

7.1.7 Borderline nuclear change

This is a “holding” category where there is genuine doubt as to whether or not a smear is abnormal. The nuclear changes are not typical and convincing of cervical dyskaryosis and as such it can not be labelled as negative.

Borderline nuclear change is used when wart virus changes are seen on the smear, without dyskaryosis.

It can also be used when severe inflammatory changes exist on the smear, which can sometimes appear almost dyskaryotic.

When interpretation of the smear is difficult e.g. as it is in poor handling or fixing and or staining process (such as due to air drying)

7.1.8 Management of borderline nuclear change

The smear should be repeated at 6 months, interval for 1 year and 12 months later. – If all are negative, normal recall can be resumed.

If in the course of the follow up, there are a maximum of 3 reports of borderline nuclear change in the follow-up period, referral for colposcopy is advised.

At any point in time One report of borderline glandular cells requires immediate referral for further evaluation..

In difficult cases, where there is concern that high grade disease may be present, immediate referral can be recommended.

8.1 CIN I/Low sil management

CIN I/Low SIL correlates to Nucleus occupying up to 1/2 of the area of the cell(Nucleocytoplasmic ratio of half)

8.1.1 Management of mild dyskaryosis

It is advisable that she should have a colposcopy done, in centres where this facilities are not available, “it remains acceptable to recommend a repeat test”.

If the repeat smear is the same diagnosis (mild dyskaryosis) then a referral must be advised.

8.2.1 CINII/High SIL

8.2.2 Cytological features

CIN II/High SIL correlates to Nucleus occupying up to 1/2 to 2/3 of the area of the cell(Nucleocytoplasmic ratio of 1/2 to 2/3)

The Chromatin pattern is usually more abnormal compare to CIN I

If a smear is obviously dyskaryotic, but difficult to grade e.g. because there are too few cells or they are poorly preserved, it is recommended that they be coded as moderate.

8.2.3 Management of moderate dyskaryosis

All patients with moderate dyskaryosis should be referred for colposcopy.

8.3.1 CIN III/ High SIL

8.3.2 Cytological features

CIN III/High SIL correlates to Nucleus occupying more than 2/3 of the area of the cell(Nucleocytoplasmic ratio greater than 2/3).The nucleus may have a bizarre shape.

The Chromatin pattern is usually more abnormal compare to CIN I

8.3.3 Management of severe dyskaryosis/CIN III/High SIL

Referral for colposcopy is the standard approach of management. This will include tissue biopsy for histology.

8.4.1 Invasive squamous carcinoma

8.4.2 Cytological features

The histological features are essentially that of Bizarre nuclear changes and keratinisation.

Diathesis is also a notable findings in this patients.

8.4.3 Management of invasive squamous carcinoma

In this case an URGENT referral for colposcopy and tissue diagnosis is advised.

9. Treatment of cervical intra-epithelia neoplasia

9.1 Low grade lesions

In the treatment of this disease entity a colposcopy, with or without a repeat smear, and or tissue biopsy is an essential requirement as stated above. The uses of additional investigative tools are very essential in the treatment of this condition. The time interval between diagnosis and treatment can be very crucial

The option of treatment range between Cryotherapy, cold coagulation, Laser agglutination therapy and Electrocautery. A lot of caution must be applied to avert over treatment especially in young women who are still desirous of conception (over treatment can cause fertility problems).

The follow up schedule as stated above and the patient should be encouraged to adhere to this to achieve the desired goal of screening.

9.2 High grade lesions

The additional investigations include Colposcopy, repeat smear and tissue biopsy is important toward establishing a diagnosis, because the treatment involved is usually irreversible. Such definitive treatment includes ablative procedures and amputation surgeries.

The definitive treatments include Cold coagulation, LLETZ, laser agglutination therapy, electrocautery, knife cone biopsy and trachelectomy.

9.3 Summary of indication for colposcopy examinations

The under listed are the patient that would benefit from colposcopy

- Following 3 consecutive inadequate smears.
- Women with clinical symptoms e.g. PMB, friable cervix
- Post menopausal women with unexplained endometrial cells
- Women with genital warts.
- Persistent borderline smears (maximum 3)
- One report of borderline nuclear change in glandular cells.
- After 3 abnormal smear results (any grade) in a 10 year period.
- One report of mild dyskaryosis.

- One report of moderate dyskaryosis.
- One report of severe dyskaryosis.
- One report of ? invasive SCC.
- One report of ? glandular neoplasia.
- A report of mild or worse in women on follow-up for treated CIN

10. Human immunosuppressive virus and cervical intra-epithelia neoplasia

This is actually of more relevance in the developing nations. It's a major scourge of our time that needs to be address at all time and at every given opportunity.

Follow up in CIN cases is done closely in HIV-positive women: treatment of CIN I has a high failure rate in these women, but it has a relatively low rate of progression (Robert Finn 2011).

HIV-infected women were 3.7 times more likely to develop CIN than HIV-uninfected women. These results highlight the importance of regular cervical cytological screening for HIV-Infected women.(Wright)

The interplay between HIV infection, HPV infection and CIN/cervical cancer is complex (see Box 34.1). Cervical dysplasia and possibly invasive cervical cancer are more prevalent in HIV-positive women. The latter has a higher rate of HPV infections which are strongly associated with high-grade SIL and invasive cervical cancer.(Sun et al 1997) Immune suppression is the factor predisposing HIV positive women to HPV infections fig 20. CIN is commoner in HIV infected women with a lower CD4 count or AIDS. (Sun et al 1995) have suggested that the presence of immunosuppression shifts the ratio of latent: clinically expressed HPV infection from 8:1 in the general population to 3:1 in HIV-positive women with CD4 >500/ μ L and to 1:1 when CD4<200/ μ L. Linking the US AIDS and Cancer Registry, the observed cervical cancer cases in HIV infected women were up to 9 folds higher than the expected number of cases but the likelihood of cervical cancer is not related to the CD4 count. (mbulaiteye et al2003).

The screening process for the HIV positive patients differs significantly based on the prelude of our discussion and as such the have the following schedules:

Pelvic examination and Pap smear are repeated six months after the baseline.(Anderson 2005) If both times are normal, cervical screening is then performed every twelve months alongside with careful vulval, vaginal and anal inspections. There is no specific CD4 threshold under which the frequency of Pap smear would need to be increased, though this may be considered in cases of(Anderson 2005)

- a. Previous abnormal Pap smear
- b. HPV infection
- c. Symptomatic HIV disease
- d. CD4 counts <200/ μ L
- e. Post-treatment for CIN

Other forms of screening may be employed in the management of those who are positive for HIV. *HPV-DNA* has recently been introduced as one form of screening. As there is a high

incidence of HPV infection in HIV patient and most HIV patients with abnormal smear will ultimately need colposcopy evaluation (to rule out CIN and cervical cancer), the use of HPV-DNA in the triage for colposcopy is of limited value and it is not cost effective. On the other hand, despite the higher incidence of cervical abnormality in HIV infected patients, *colposcopy* is not generally recommended for primary cervical screening (Anderson et al 2005) but indicated when pap smear reveals epithelial cell abnormality.

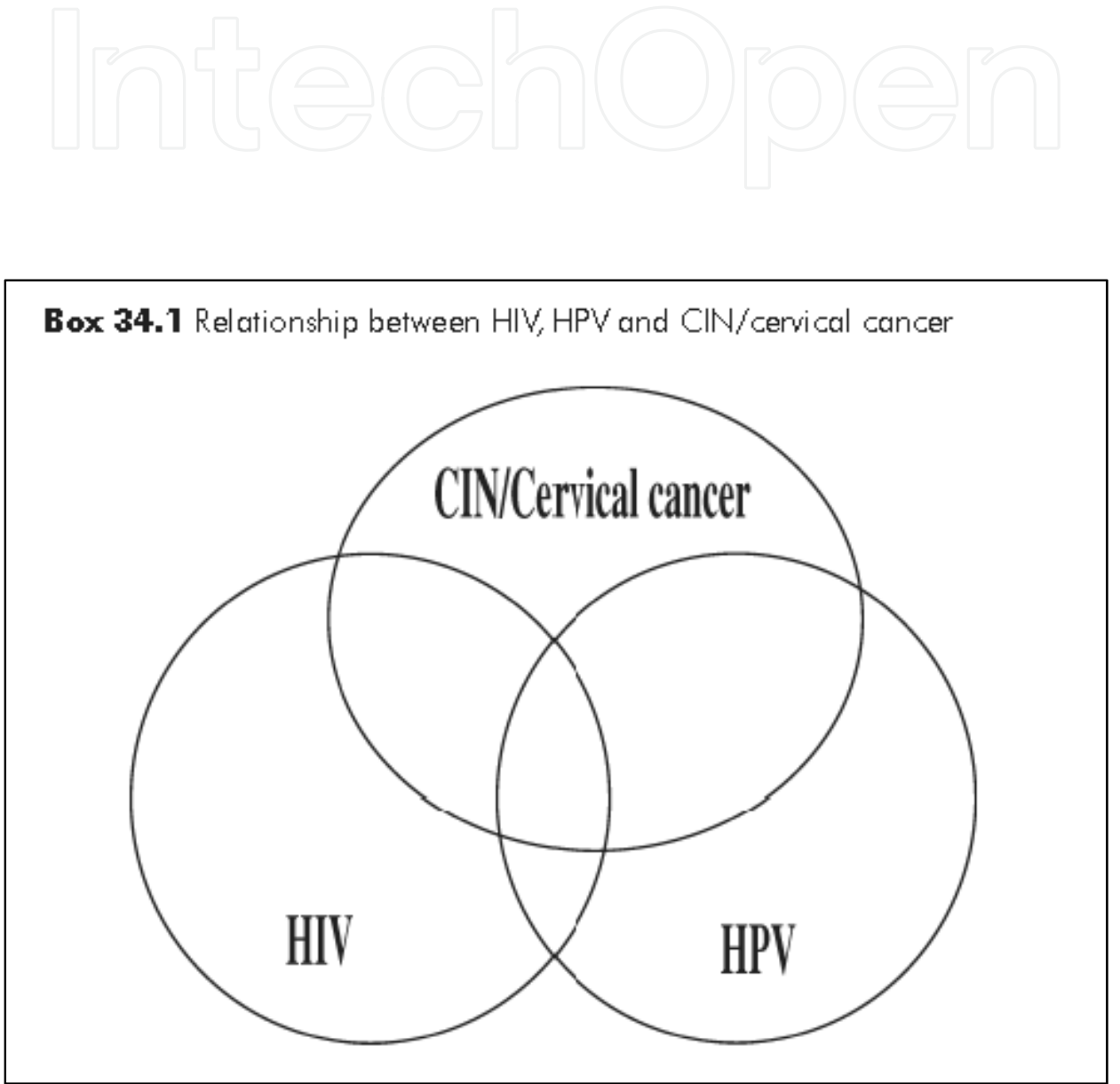


Fig. 20. (Courtesy Siu-Keung LAM) Relationship Between HIV,HPV & CIN 1

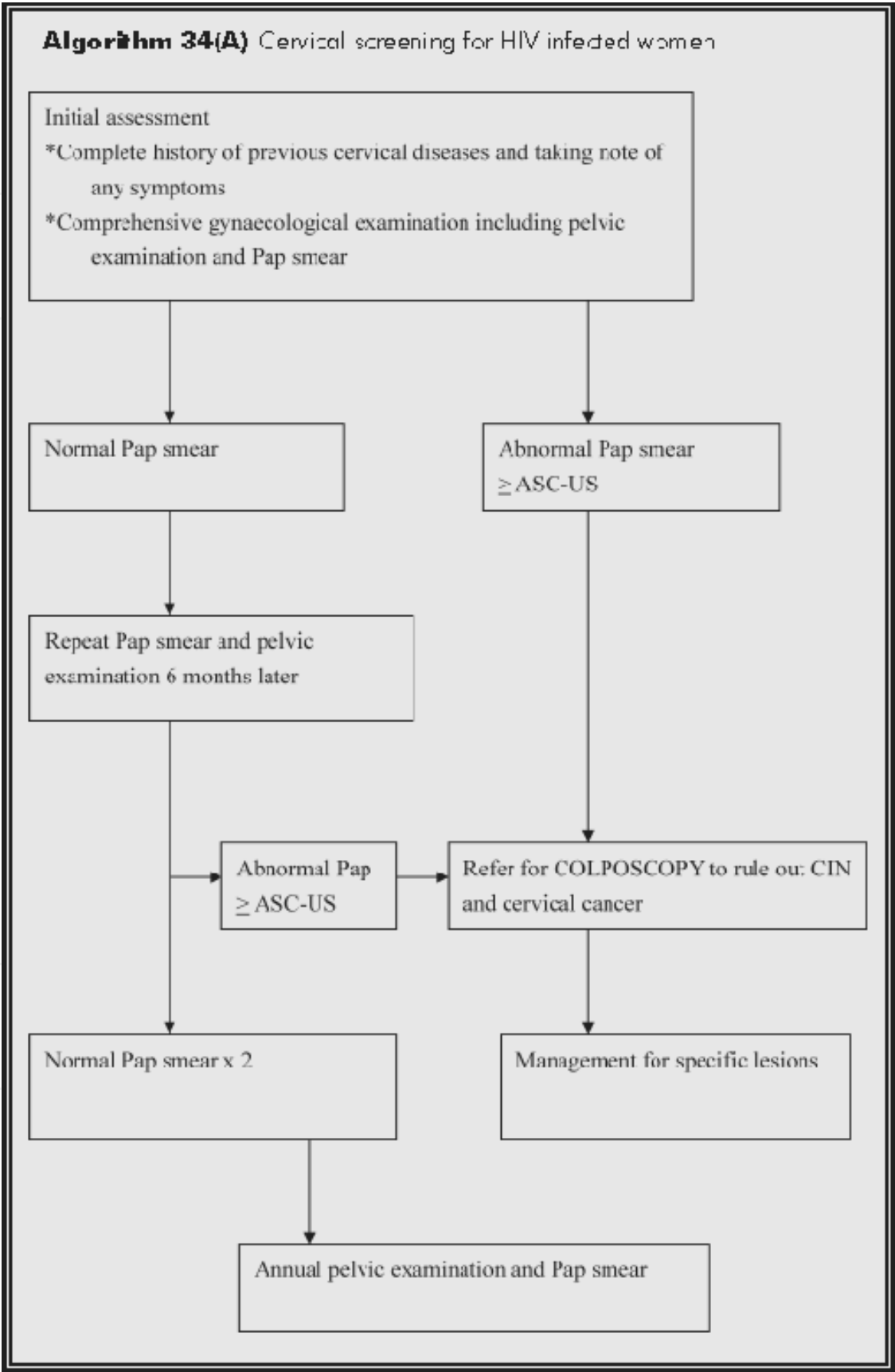


Fig. 21. (Courtesy of Siu-Keung LAM)

10.1 Management of cervical lesion in HIV positive patients

HIV-infected patients with ASC-US cervical lesion or above once on Pap smear should be referred for colposcopy. At a colposcopy clinic, thorough evaluation of the lower genital tract is performed including colposcopy and cervical biopsy at the most suspicious area to rule out CIN and/or malignancy. If there is no HGSIL, patients are followed up regularly in the colposcopy clinic. If HGSIL is found, most patients require large loop excision of transformation zone (LLETZ), to reduce the chance of progression to cervical cancer. This has to be coupled with regular post-treatment cervical smear surveillance as stated above. The other forms of therapy that can be use includes, Laser agglutination therapy, Electrocautery and cone biopsy of the cervix. The role of HAART in preventing CIN recurrence post treatment is still controversial, but it is advised that it should be given. (Siu-Keung LAM)

11. HPV vaccination and cervical intra-epithelia neoplasia

In a randomised control study (double blinded) it was concluded that, In young women who have not been previously infected with human papillomavirus-16 (HPV16), vaccination prevents HPV16-related cervical intra-epithelial neoplasia (CIN). (Mao et al 2006).

It should be noted that only 75% of all cervical cancers are caused the HPV viruses 16 and 18, it is therefore still possible for a woman to develop cervical cancer even though they are immunised. This is because there are other sero types of HPV not covered by those vaccine in the market.

12. References


- ACCP. Visual screening approaches: (October 2002). Promising alternative screening strategies. Cervical Cancer Prevention Fact Sheet.
- ACCP & World Health Organization. November 2003 Cervical cancer prevention in developing countries: A review of screening and programmatic strategies.
- Agorastos T, Miliaras D, Lambropoulos A, Chrisafi S, Kotsis A, Manthos A, Bontis J (2005). "Detection and typing of human papillomavirus DNA in uterine cervixes with coexistent grade I and grade III intraepithelial neoplasia: biologic progression or independent lesions?". *Eur J Obstet Gynecol Reprod Biol* 121 (1): 99-103. doi:10.1016/j.ejogrb.2004.11.024. PMID 15949888.
- American College of Obstetricians and Gynecologists.(ACOG) Obstet Gynecol. 2010;Cervical cancer in adolescents: screening, evaluation, and management. Committee Opinion No. 463. 116:469-72.
- America Society for colposcopy and Cervical Pathology (ASCCP) 2011 Anatomy of the Uterine Cervix. The society for the lower Genital Tract disease.
- Anderson JR. 2005 edition. A guide to the clinical care of women with HIV-. Published by US Department of Health and Human Services, Health Resources and Service Administration, HIV/AIDS Bureau. Available from <http://hab.hrsa.gov/publications/womencare05>.

- Ardahan, Melek PhD, RN; Temel, Ayla Bayik PhD, RN. March/April 2011 Visual Inspection With Acetic Acid in Cervical Cancer Screening
Cancer Nursing: Volume 34 - Issue 2 - pp 158-163doi: 10.1097/NCC.0b013e3181efe69f Articles.
- Barbara G,2011 Cervical Intraepithelia Neoplasia in Up to Date Marketing Professionals.
- Dina.R. Eurocytology 5th-10th September 2011 Hammersmith AdvancedClinical Cytopathology Course Held at Imperial College- HammersmithHospital campus - Commonwealth Building.
- IARC(International Agency for Research on Cancer) 2001 An Introduction to Cervical Intraepithelial Neoplasia (CIN)chapter 2.
- Kumar, V; Abbas, A K.; Fausto, N; & Mitchell, R N. (2007). Robbins Basic Pathology (8th ed.). Saunders Elsevier. pp. 718–721. ISBN 978-1-4160-2973-1. ^Cervical Dysplasia: Overview, Risk Factors.
- Mao C, Koutsky LA, Ault KA, et al. 2006 Efficacy of human papillomavirus-16 vaccine to prevent cervical intraepithelial neoplasia. *Obstet Gynecol*; 107:18-27.
- Mark H (2010)UNSW Embryology of Genital System - Female Uterus
- Mbulaiteye SM, Biggar RJ, Goedert JJ, Engels EA. 2003 Immune deficiency and risk for malignancy among persons with AIDS. *J Acquir Immune Defic Syndr*;32:527-33.
- NEL J. T.; DE LANGE L. ; MEIRING P. J. ; DE WET J. I.1994 Cervical intra-epithelial neoplasia and invasive cervical cancer in black and white patients ; *SAMJ. South African medical journal* ISSN 0256-9574 CODEN SAMJAF , vol. 84, no1, pp. 18-19 (16 ref.)
- Oguntayo O A and Samaila .M O A Prevalence of Cervical Intraepithelia Neoplasia in Zaria,*Annals of African Medicine* Vol 9,No 3;2010:194-5.
- Robert Finn 2011Follow CIN closely in HIV-positive women: .(Gynecology): An article from: *OB GYN News* [HTML] [Digital].
- Sasieni P, Adams J (1999 May):Effect of screening on cervical cancer mortality in England and Wales: analysis of trends with an age period cohort model;*BMJ* 8;318(7193):1244-5.
- Siu-Keung LAM CERVICAL NEOPLASIA IN HIV/AIDS.
- Sun XW, Ellerbrock TV, Lungu O, Chiasson MA, Bush TJ, Wright TC Jr. 1995 Human papillomavirus infection in human immunodeficiency virus-seropositive women. *Obstet Gynecol*;85(5 Pt 1):680-6.
- Sun XW, Kuhn L, Ellerbrock TV, Chiasson MA, Bush TJ, Wright TC Jr. 1997 Human papillomavirus infection in women infected with the human immunodeficiency virus. *N Engl J Med*;337:1343-9.
- UVa Health 2006 Pathology Thread IV. *Premalignant and Malignant Neoplasms* University of Virginia School of Medicine. Department of Patholo PO Box 800214 System www.med-ed.virginia.edu/courses/path/gyn/cervix4.cfm -
- Vanessa Jackson 2006 CERVICAL CYTOLOGY REPORTING AND TERMINOLOGY AND MANAGEMENT OF ABNORMAL SMEARS Advanced Biomedical Scientist Practitioner Leeds Teaching Hospitals NHS Trust.
- Wright TC, Ellerbrock TV, Chiasson MA, Williamson J, Sun X, Bush TJ 1995 Jan 29-Feb 2 Incidence and risk factors for cervical intraepithelial neoplasia (CIN) in HIV-

infected women.; National Conference on Human Retroviruses and Related Infections. *Program Abstr Second Natl Conf Hum Retrovir Relat Infect Natl Conf Hum Retrovir Relat Infect 2nd Wash DC*; 90. Columbia University and NYC Department of Health, NY.

Wart From Wikipedia, the free encyclopedia www.facebook.com/pages/Warts/110511208977959

Wright TC Jr, Cox JT, Massad LS, Twiggs LB, Wilkinson EJ; 2002 ASCCP-Sponsored Consensus Conference. 2001 Consensus Guidelines for the management of women with cervical cytological abnormalities. *JAMA*;287:2120-9.



Intraepithelial Neoplasia

Edited by Dr. Supriya Srivastava

ISBN 978-953-307-987-5

Hard cover, 454 pages

Publisher InTech

Published online 08, February, 2012

Published in print edition February, 2012

The book "Intraepithelial neoplasia" is till date the most comprehensive book dedicated entirely to preinvasive lesions of the human body. Created and published with an aim of helping clinicians to not only diagnose but also understand the etiopathogenesis of the precursor lesions, the book also attempts to identify its molecular and genetic mechanisms. All of the chapters contain a considerable amount of new information, with an updated bibliographical list as well as the latest WHO classification of intraepithelial lesions that has been included wherever needed. The text has been updated according to the latest technical advances. This book can be described as concise, informative, logical and useful at all levels discussing thoroughly the invaluable role of molecular diagnostics and genetic mechanisms of the intraepithelial lesions. To make the materials easily digestible, the book is illustrated with colorful images.

How to reference

In order to correctly reference this scholarly work, feel free to copy and paste the following:

Oguntayo Olanrewaju Adekunle (2012). Cervical Intraepithelial Neoplasia (CIN) (Squamous Dysplasia), Intraepithelial Neoplasia, Dr. Supriya Srivastava (Ed.), ISBN: 978-953-307-987-5, InTech, Available from: <http://www.intechopen.com/books/intraepithelial-neoplasia/cervical-intraepithelial-neoplasia-cin-squamous-dysplasia->

INTeCH
open science | open minds

InTech Europe

University Campus STeP Ri
Slavka Krautzeka 83/A
51000 Rijeka, Croatia
Phone: +385 (51) 770 447
Fax: +385 (51) 686 166
www.intechopen.com

InTech China

Unit 405, Office Block, Hotel Equatorial Shanghai
No.65, Yan An Road (West), Shanghai, 200040, China
中国上海市延安西路65号上海国际贵都大饭店办公楼405单元
Phone: +86-21-62489820
Fax: +86-21-62489821

© 2012 The Author(s). Licensee IntechOpen. This is an open access article distributed under the terms of the [Creative Commons Attribution 3.0 License](https://creativecommons.org/licenses/by/3.0/), which permits unrestricted use, distribution, and reproduction in any medium, provided the original work is properly cited.

IntechOpen

IntechOpen