

We are IntechOpen, the world's leading publisher of Open Access books Built by scientists, for scientists

6,900

Open access books available

185,000

International authors and editors

200M

Downloads

Our authors are among the

154

Countries delivered to

TOP 1%

most cited scientists

12.2%

Contributors from top 500 universities



WEB OF SCIENCE™

Selection of our books indexed in the Book Citation Index
in Web of Science™ Core Collection (BKCI)

Interested in publishing with us?
Contact book.department@intechopen.com

Numbers displayed above are based on latest data collected.
For more information visit www.intechopen.com



Intraepithelial Neoplasia of Breast

Simonetta Monti and Andres Del Castillo
*Senology Division, European Institute of Oncology, Milan,
Italy*

1. Introduction

The early proliferative lesions of the breast have taken on greater significance as a result of mammographic screening and the use of even more sensitive imaging technologies. The intraductal proliferative lesions of the breast are a group of cytologically and architecturally diverse proliferations, typically originating from the terminal duct-lobular unit and confined to the mammary duct-lobular system. In this chapter we consider the most important of these lesions, lobular carcinoma in situ and ductal carcinoma in situ.

Lobular Carcinoma in situ

Foote and Stewart (Foote & Stewart, 1941) first described lobular carcinoma in situ (LCIS) in detail in 1941, emphasizing the morphologic similarity of LCIS cells to those of invasive lobular carcinoma. The multicentricity and high frequency of bilaterality of LCIS were recognized early on. LCIS generally occurs in younger women, and microcalcifications are not a feature (in contrast to the high frequency of microcalcifications seen with ductal proliferative lesions). Microscopically, LCIS is usually characterized by a solid, occlusive proliferation of loosely cohesive uniform cells, some of which may contain intracytoplasmic lumens. The incidence of LCIS in otherwise benign breast biopsy is reported as between 0,5% and 3,8%

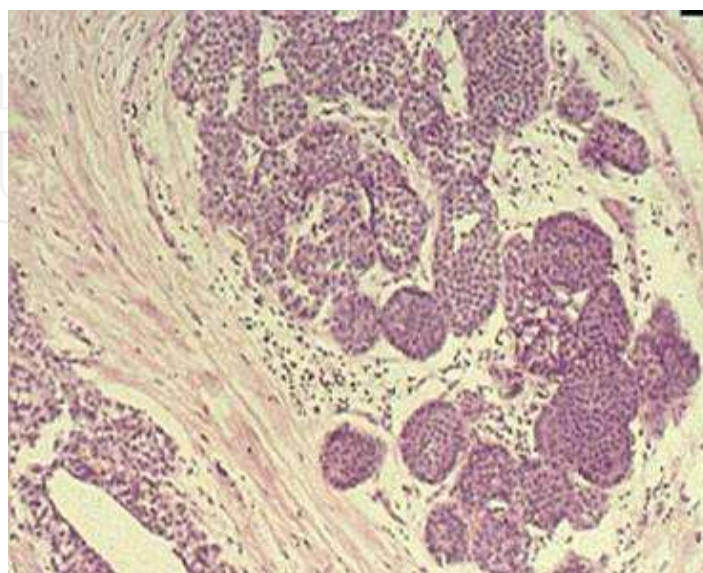


Fig. 1. Lobular carcinoma in situ

Ductal carcinoma in situ

Ductal carcinoma in situ is a heterogeneous group of lesions with diverse malignant potential and range of treatment options. It was infrequently diagnosed in the past, when it accounted for only 1% to 5% of all breast cancers. It usually presented as a palpable lesion, Paget disease, or bloody nipple discharge (Intra et al. 2003). The clinical presentation of Ductal Carcinoma In Situ shifted from a palpable lesion in the pre-mammographic era to a non-palpable lesion detected on the basis of mammographic microcalcifications or density (Tavassoli, 2008).

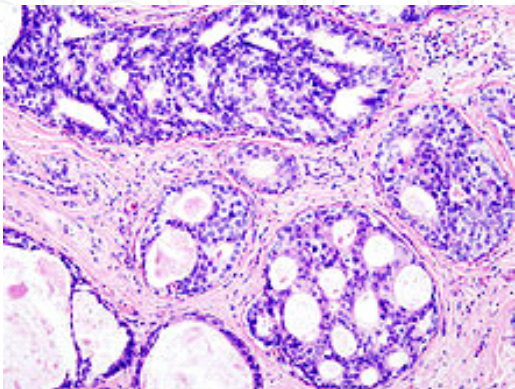


Fig. 2. Ductal carcinoma in situ

2. New classification

As mammographic screening became widespread, the frequency of diagnosis of intraepithelial proliferative lesions increased markedly, highlighting deficiencies in their classification as well a lack of data on natural history, and making clinical management a challenge. The new classification of these entities (DCIS and LCIS), principally due to Tavassoli (Tavassoli et al. 2003), was based on the concept of intraepithelial neoplasia

Ductal intra-epithelial neoplasia (DIN) terminology	Conventional terminology
Low-risk DIN	Intraductal hyperplasia (IDH)
Flat DIN 1	Flat epithelial atypia
DIN 1	<2 mm: atypical ductal hyperplasia (ADH) >2 mm: ductal carcinoma in situ, low grade (DCIS, grade 1)
DIN 2	Ductal carcinoma in situ, intermediate grade (DCIS, grade 2)
DIN 3	Ductal carcinoma in situ, high grade (DCIS, grade 3)

Table 1. DIN translational table (Tavassoli FA 1997)

developed for cervix, vagina, vulva, prostate and pancreas. It does not use the term “cancer” diminishing the likelihood of overtreatment, and perhaps reduces also the level of anxiety and emotional stress a patient feels when told she has a cancer, even if it is only in situ.

3. Diagnosis and treatment

3.1 Diagnosis

The role of clinical examination in the ongoing surveillance of women with these high risk lesions is limited. While many DINs are detected through microcalcifications at mammography, the detection of LIN can be occasionally occur after a biopsy, for example in plastic surgery a histological evaluation of tissue excised in a breast reduction. In this case there is therefore a clear indication for meticulous assessment of both breasts ongoing surveillance of the breast at a relatively short interval. So standard core biopsy (14-18 gauge) is probably the most prevalent method for initial diagnosis of LIN. In the case of DIN it is diagnosed primarily via mammography plus ultrasound followed by stereotactic needle biopsy. However, new techniques such as magnetic resonance imaging (MRI) and analysis of ductal cytology aim to improve DIN detection (Sickles, 1983).

The use of breast MRI for patients with DIN is not yet established. MRI may be more sensitive for DIN detection than mammography but can lack specificity. The potential benefits of MRI include fewer re-excisions after BCS, decreased local recurrence rates after excision, and earlier detection and treatment of contralateral breast cancer (Leonard & Swain, 2004).

At present, therefore, mammography plus ultrasound and SCNB remain the standard diagnostic approaches for DIN (Leonard & Swain 2004).

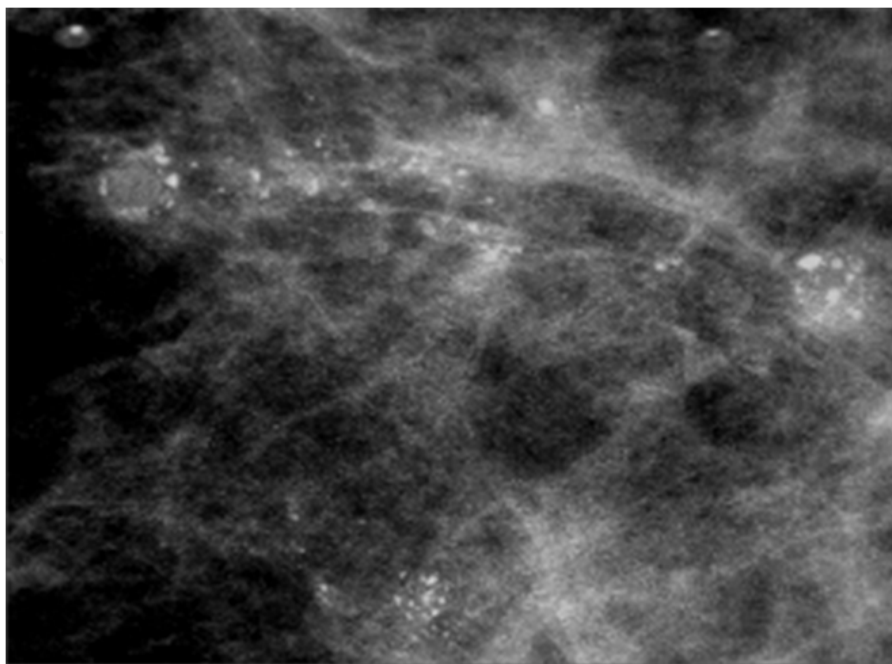


Fig. 3. A typical mammographic view of DIN

3.2 Treatment

Where the surgical biopsy reveals LIN, the margins of excision are paramount in determining further treatment. If the margins are clear, that is, the lesion appears to have been completely excised, no further treatment is required. Where surgical excision reveals a high risk lesion with an involved surgical margin or margins, re-excision should be considered. The goal of course is complete excision, but it must be recognized that LIN can be very extensive, sometimes occupying an entire quadrant or more of the breast. If a generous diagnostic excision suggests this, usually because several margins are involved, it may be clear that a substantially wider excision would have an adverse cosmetic outcome. In such cases observation and surveillance as detailed may be the preferred option. But the patient will be fully informed of the risk of subsequent cancer and involved in this decision. So, while for the LIN management is not yet clear the standard of treatment and in some institutions the decision is made on an individual, case by case basis, for DIN.

The standard of care consists of (a) breast conservative surgery (BCS) (mastectomy is still indicated in large lesions - masses or microcalcifications), axillary dissection is not indicated because of the low prevalence of nodal metastases and the significant morbidity associated with lymph node dissection (b) radiotherapy (RT) after conservative surgery, and (c) medical treatment in estrogen receptor-positive patients (Tavassoli, 2008; Farante et al. 2010; Cox et al. 2001; Intra et al. 2003).

Surgical treatment

The main goal of surgical treatment for women with DIN is BCS plus RT, particularly for those patients with small solid masses, mammographically detected lesions, or limited microcalcification areas (Fisher et al. 1991; Schwartz et al. 2000; Silverstein et al. 1992).

However, mastectomy is still indicated in DIN patients with multicentricity, diffuse microcalcification, large palpable masses, when there is an inability to obtain negative margins as well other contraindications to breast conservation or a personal preference for mastectomy (Farante et al. 2010). At present, mastectomy is performed in about 30% of DIN patients, BCS without RT in about 30% of DIN patients, and BCS followed by RT in about 40% of DIN patients (Guerrieri-Gonzaga et al. 2009; Schmidt et al. 2006; Kuerer et al. 2008).

One important issue in breast cancer surgery is that of surgical margins, mainly in DIN patients, since these lesions are typically vague masses, which often cannot be adequately seen or felt and, thus, the pathological sampling of margins is fairly random (Fisher et al. 1999; Allred 2005). The current treatment of positive or focally involved margins in DIN patients is re-excision (Farante et al. 2010).

There is considerable debate regarding whether width of a negative margin is (width of a margin negative for tumor cells) associated with a decreased risk of recurrence, and classification of the margins makes summary statements difficult. About 10 years ago, the "Consensus on DCIS of Philadelphia" and Silverstein et al. proposed 10 mm of width margin as a limit of oncological safety (Schwartz et al. 2000). Since then other authors have proposed progressively smaller measures, down to 1 mm (Mansell, 2003).

Another important topic in DIN patients is the management of the axilla. Before the sentinel lymph node biopsy (SLNB) era, axillary dissection (AD) was a part of the standard surgical

treatment for these patients (Farante et al. 2010). SLNB is recommended for patients with invasive breast cancer to determine prognosis and to guide adjuvant treatment decisions. In general, SLNB is not recommended for patients with a final or definitive diagnosis of DIN because the preinvasive cells do not metastasize (Virnig et al. 2010).

So not only is AD not necessary, neither should SLNB always be required because of the low prevalence of metastatic involvement, so an SLN biopsy should not be considered a standard procedure in the treatment of all patients with DCIS. The sole criteria for proposing SLN biopsy in DIN should be when there exists any uncertainty regarding the presence of invasive foci at definitive histology (Intra et al. 2008).

Major cancer centers agree that SLNB should be performed (a) always when mastectomy is performed (Cody 2007; Yi et al. 2008; Intra et al. 2007). (b) with large lesions (masses or micro-calcifications) and G3 tumors. (Cody 2007; Julian et al. 2007) and (c) after performing core or mammotome biopsies.

In cases of DIN patients with a positive SLNB, AD should not be immediately performed except for only those cases that present mammary invasion on final pathologic evaluation (Farante et al. 2010).

Radiation therapy

External RT

The standard course of current external RT after BCS for DIN, delivers a total dose of 50 Gy in daily fractions of 1.8/2 Gy without boost (Farante et al. 2010). The role of RT in DIN patients with conservative treatment has been mainly defined by four randomized trials (Bryan et al. 2003; Bijker et al. 2006; Houghton et al. 2003; Emdin et al. 2006). Additional radio-therapy reduced the LR rate by about 50%, with no effect on survival. The controversy is, instead, related if all DIN patients have to undergo RT. According to the 2009 St Gallen Consensus (Goldhirsch et al. 2009) RT could be avoided in elderly patients and in those with G1 DIN and clearly negative margins.

At the IEO in Milan, RT is not administered to DIN patients with G1 or G2 without comedo-necrosis. On the other hand, at least four significant papers from the Saint Gallen Consensus (Goldhirsch et al. 2009), the ECOG trial (Hughes et al. 2009), the Newport Consensus Conference III (Silverstein et al. 2009) and from the National Consensus Cancer Network (National Comprehensive cancer Network, 2009), suggested that some DIN patient sub-groups (i.e., G1 or G2 tumors without comedo-necrosis, and other low-risk sub-groups) could not be candidates to receive RT after BCS.

4. Biomarkers

To guide such optimal treatment, histological classification is not sufficient and additional biological factors are being investigated for their ability to predict outcome for individual patients with intraepithelial neoplasia of the breast. As the molecular and genetic understanding of breast cancer has increased, new biological characteristics have been identified as prognostic indicators, as new adjuvant treatments have been developed. This has resulted in an increasingly personalized approach to breast cancer treatment that takes into account the diverse biological characteristics of the individual and their disease. A

biomarker is an objectively measured feature that indicates a normal biological response, a pathogenic process, or the likelihood of response to a pharmacologic therapy. In oncology, biomarkers may be used to detect or stage disease, monitor response to therapy, and predict outcome (Madu & Lu 2010). A biomarker may be DNA, RNA, or a protein, measured directly in tissue, serum or other body fluids. An optimal biomarker for intraepithelial neoplasias of the breast would provide information additional to that provided by factors such as grade, lesion size, age and margin status (already established as related to the risk of local recurrence) so as to make it possible to predict which cases are unlikely to ever progress to invasive breast cancer and thus would require no further treatment after lesion removal, and also to predict which cases should receive local excision or mastectomy, or would benefit from adjuvant RT (Barker et al. 2003).

4.1 Estrogen receptors (ER)

Estrogens play a central role in the growth and differentiation of normal breast epithelium, stimulating cell proliferation and regulating the expression of genes, including that coding for the progesterone receptor (PgR) (Henderson et al. 1998; Peterson et al. 1987). In the normal pre-menopausal breast, ER-positive cells are luminal cells constituting about 7% of the total epithelial cell population (Peterson et al. 1987). They seem to secrete factors which influence, in paracrine manner, the proliferation of adjacent ER-negative cells (Peterson et al. 1987; Clarke et al. 1997). ER positivity and proliferation activity (as measured by Ki-67) are almost mutually exclusive in normal breast epithelium (Clarke et al. 1997). The proportion of ER-positive cells increases with age to reach a plateau after menopause (Shoker et al. 1999).

High ER expression in normal epithelium is a risk factor for breast cancer, conferring a 3-fold increase in risk compared to minimal expression (Khan et al. 1998). ER positivity together with KI-67 expression, may correlate with progression to more severe lesions in non-atypical epithelial hyperplasia (Iqbal et al. 2001). It has also been suggested that an increased percentage of ER-positive cells in adjacent normal lobules is associated with increased risk of invasive breast cancer rather than ER-positivity within the non-atypical epithelial hyperplasia *per se* (Gobbi et al. 2005).

In other benign breast lesions, such as sclerosing adenosis, radial scar, papilloma, fibroadenoma, and phylloides tumor, the percentage of ER-positive cells is higher than in normal breast tissue (Shoker et al. 2000). Similarly, ER-alpha expression is significantly elevated in hyperplastic enlarged lobular units (HELU), which are the earliest histologically identifiable lesions with premalignant potential. By contrast, intense ER-alpha staining in enlarged lobular units with columnar alteration (ELUCA) seems associated with reduced risk of subsequent invasive carcinoma (McLaren et al. 2005).

Unlike in normal breast, in ADH (atypical ductal hyperplasia), LN (lobular neoplasia) and DCIS (ductal carcinoma in situ), ER-positive cells are surrounded by contiguous cells which are also characterized by ER-positivity (Clarke et al. 1997). Furthermore, in DCIS, cells that are both ER-positive and Ki-67-positive are a characteristic finding (Shoker et al. 2000). In general, non-comedo carcinomas more frequently exhibit ER positivity (Bose et al. 1996; Page et al. 1982).

The expression of ER-beta by breast epithelium is the inverse of that of ER-alpha, declining progressively from normal breast tissue to ADH, DCIS, and IDC (Intraductal Carcinoma)

(Roger et al. 2001; Shaaban et al. 2003). According to a recent article, a high ER- α /ER- β ratio in non-atypical epithelial hyperplasia predicts progression to carcinoma (Shaaban et al. 2005). For the optimal envisagement of the ER network, it should be kept in mind that important regulators exist, such as hsp-27 (O'Neill et al. 2004) or AIB1 (Hudelist et al. 2003), exhibiting more intense expression in breast cancer.

4.2 Progesterone receptors (PgR)

As is the case with ER levels, PgR levels are elevated in early premalignant breast lesions (Lee et al. 2006) and PgR expression decreases with progression to malignancy (Ariga et al. 2001). In DCIS, PgR positivity is associated with ER positivity and lack of comedo necrosis (Barnes et al. 2005; Claus et al. 2001). Studies on the relation of PgR expression to tumor grade (Barnes et al. 2005; Ringberg et al. 2001, Rody et al. 2004; Lebrecht et al. 2002) and recurrence rate (Kepple et al. 2006; Provenzano et al. 2003) have provided contrasting results (reviewed in Provenzano et al. 2003). In ductal carcinoma, PgR expression has been associated with histological grade, but not with lymph node involvement, tumor size, or prognosis (Ariga et al. 2001). Data on PgR expression in lobular neoplasia is scarce but it seems to be expressed in most cases (Fadare et al. 2006; Fisher et al. 1996).

The ratio of PgR-A to PgR-B appears important. In normal breast tissue and non-atypical hyperplasia, PgR-A and PgR-B are expressed in approximately equal quantities, but at an early stage of progression, one receptor (usually PgR-A in advanced lesions) predominates (Mote et al. 2002). In vitro studies indicate that PgR-A exerts modulating effects on cell morphology and adhesion (McGowan et al. 1999; Grahal et al. 2005). In the normal tissue of BRCA mutation carriers, PgR-B is absent (Mote et al. 2004).

4.3 HER2

HER2 or human epidermal growth factor receptor 2 (c-ErbB-2) is a tyrosine kinase receptor and oncoprotein encoded by the ERBB2 gene on chromosome 17q. Alterations in ERBB2 expression are important in malignant transformation (De Potter et al. 1989; Ross et al. 1999). Some studies have found that HER2 was not overexpressed in benign proliferative breast disease or ADH (Gusterson et al. 1988; Heffelfinger et al. 2000) while another used fluorescence in situ hybridization to demonstrate that the extent of HER2 amplification increased with progression to invasive carcinoma (Xu et al. 2002). Patients with benign breast lesions showing low levels of HER2 amplification were found in one study to have a two-fold increased risk of developing breast cancer (Stark et al. 2000); however another study found that HER2 overexpression in benign lesions was not a significant risk factor for developing cancer (Rohan et al. 1998).

A quarter of LCIS cases have been found to be HER2 positive, irrespective of the coexistence of an invasive component (Mohsin et al. 2005). Occasional positivity has also been found in pleomorphic ductal-lobular carcinomas in situ (Sneige et al. 2002).

As far as the role of HER2 in DCIS is concerned, HER2 immunoreactivity has been primarily associated with DCIS of higher grade, in the absence or presence (Tsuda et al. 1998) of IDC, and with comedo type (Albonico et al. 1996). Interestingly, given the association of higher grade with HER2 amplification, the latter has been regarded as an independent prognostic factor (Tsuda et al. 1993). Allred et al (Allred et al. 1992) documented that the percentage of

HER2 immunoreactivity is significantly higher in DCIS than IDC: one of the possible explanations proposed by the authors was that HER2 may be more important for the initiation than the progression of breast cancer, or that HER2 may be downregulated during breast cancer progression.

4.4 P53

P53 is a tumour suppressor gene located on 17p. p53 protein mediates its tumor suppressor functions via the transcriptional regulation or repression of a variety of genes (Toledo et al. 2006; Vogelstein et al. 2000) and is an important component of breast cancer pathophysiology (Gasco et al. 2002). Regarding the role of p53 as a risk factor in benign breast lesions, there data is controversial: the immunohistochemical detection of p53 in benign breast lesions has been associated with elevated cancer risk (Rohan et al. 1998), although there are studies with conflicting results (Younes et al. 1995).

Considering the various types of lesions in the continuum between benign lesions and breast cancer, various studies have assessed the role of p53. In epithelial hyperplasia without atypia, p53 mutations have not been detected (Done et al. 1998). In ADH, the presence and role of p53 mutations is still an open field: p53 mutations were initially not documented (Chitemerere et al. 1996); subsequently studies pointing to p53 mutations appeared (Kang et al. 2001), and, more recently, the presence of mutated p53 in ADH has been demonstrated with the use of laser capture microdissection microscope, single-stranded conformational polymorphism (SSCP) and sequencing (Keohavong et al. 2004). Regarding LN, there is scarcity of data: in two studies, no p53 immunoreactivity was demonstrated in LN lesions (Siziopikou et al. 1996; Sapino et al. 2000), whereas a more recent study on LCIS reported p53 immunoreactivity in one fifth of cases (Mohson et al. 2005).

p53 mutations/accumulation are present in a significant percentage of DCIS cases (Lebeau et al. 2003; Poller et al. 1993), especially in the comedo type (O'Malley et al. 1994). However, the clinical significance of p53 accumulation remains still elusive; although it has been found to influence the proliferation rate (Rudas et al. 1997), a recent study showed that it does not affect the proliferation rate of the DCIS lesion *per se* (Lebeau et al. 2003). Is worth noting that the coexistence of DCIS with IDC is not associated with a different degree of p53 immunostaining (Myonlas et al. 2005).

4.5 Ki-67

Ki-67 is a cell cycle-associated nuclear protein, which is expressed in all cycle phases, with the exception of G0 and early G1, and reacts with MIB-1 antibody (Gerdes et al. 1984). Protein Ki-67 is extensively used as a proliferative index and is linked with malignancy, even in FNA (fine needle aspiration) specimens (Midulla et al. 2002). Moreover, its intrinsic association with apoptosis (bcl-2 status, see below) and p53 expression (see above) seems to be of importance in the diagnosis and prognosis of precursors and pre-invasive breast lesions: low Ki-67 expression/bcl-2 positivity and p53 negativity are a trait of ADH and, subsequently, well-differentiated carcinomas. Conversely, high Ki-67 expression/bcl-2 negativity within the lobules implicate lesions with a potential of poorly differentiated

carcinoma (Viacava P et al. 1999). As mentioned above, also in the context of non-atypical hyperplasia, high Ki-67 and ER-alpha expression seem to predict progression to cancer (Ariga et al. 2001; Shaaban et al. 2002).

Interestingly enough, a clinical application of Ki-67 expression intensity seems to emerge. In non-atypical ductal hyperplasia, lesions with high Ki-67 expression can be clinically detected scintimammographically, since high (99m)Tc-(V)DMSA uptake seems to be their characteristic feature. According to the authors, this could prove useful in identifying women with benign but high-risk breast disease (Papantoniou et al. 2006).

4.6 Bcl-2

The bcl-2 gene is located on 18q. Bcl-2 protein, and belongs to a family of proteins playing a central role in the regulation of apoptosis (reviewed in van Delft et al. 2006; Reed et al. 1994; Hockenbery et al. 1994) and other pathways (reviewed by Kim (Kim, 2005)). With respect to the overall role of apoptosis in breast cancer pathogenesis, there seems to be an intriguing pattern incorporating the proliferation of the lesion. Growth imbalance in favour of proliferation seems crucial in the transition from normal epithelium to hyperplasia and later, from pre-invasive lesions to IDC. Conversely, apoptosis becomes more important at an intermediate stage: in the transition from hyperplasia to preinvasive lesions, the imbalance is in favour of apoptosis (Bai et al. 2001). Bcl-2 is present in the whole spectrum of breast lesions: predominantly in benign lesions, ADH, LN, and well-differentiated DCIS (Sizioupikou et al. 1996; Kapucuoglu et al. 1997; Meteoglu et al. 2005). More specifically, there is a gradual increase in the extent of apoptosis (Bai et al. 2001; Mustonen et al. 1997) and a parallel decrease in bcl-2 expression in benign/precursors/preinvasive/invasive lesions as they become histologically more aggressive (Mustonen et al. 1997). Bcl-2 positivity tends to coincide with p53 negativity in normal breast tissue, non-atypical ductal hyperplasia, ADH, LN and in the majority of the DCIS (Sizioupikou et al. 1996). The role of Bcl-2 expression as a risk factor for breast cancer is described above, together with Ki-67 (see above).

4.7 Vascular endothelial growth factor (VEGF) and angiogenesis

VEGF is a potent angiogenic growth factor, commonly involved in tumor-induced angiogenesis, with a putative therapeutic significance in the context of breast cancer (Lebeau et al. 2003). Interestingly, VEGF gene polymorphisms have been associated with modified breast cancer risk in various populations (Jacobs et al. 2006)

Viacava et al (Viacava et al. 2004) have thoroughly examined the angiogenesis in precursor and preinvasive lesions. Increased vascularization is present in all preinvasive lesions and increases with lesion severity. In ductal lesions, angiogenesis is more intense in poorly/intermediately differentiated intraductal carcinomas than in non-atypical ductal hyperplasia and ADH. Similarly, LCIS, showing microvascular density similar to that of poorly/intermediately differentiated intraductal carcinoma, is more vascularized than ALH. In the same study, VEGF expression in normal glandular structures was lower than in lesions, with the highest levels found in ductal lesions. Interestingly, no correlation was found between VEGF expression and the degree of vascularization in that study. On the other hand, Hieken TJ et al. suggested that VEGF expression may help predict the biologic

aggressiveness of DCIS (Hieken et al. 2001). Additionally, in the context of DCIS, Vogl et al provide evidence to support the idea that VEGF expression is not regulated by the HER2 pathway (Vogl et al. 2005).

4.8 E-cadherin

E-cadherin, a tumor suppressor gene located on 17q, has been implicated especially in lobular breast cancer molecular pathogenesis (Berx et al. 1995). In clinical practice, immunohistochemistry for E-cadherin is a helpful marker for differential diagnosis, since most cases of low-grade DCIS exhibit E-cadherin positivity, whereas LN is almost always E-cadherin negative (Bratthauer et al. 2002, reviewed in Lerwill et al. 2004 and Putti et al. 2005). This implies that E-cadherin disruption is an early event, prior to progression, in lobular carcinogenesis (Vos et al. 1997; Mastracci et al. 2005); more specifically, DNA alterations accompanying the loss of protein expression pertain to LCIS but not to ALH (Mastracci et al. 2005). As expected according to the above, only few studies have focused on E-cadherin in ductal lesions. In the context of DCIS, hypermethylation of E-cadherin 5' CpG islands has been demonstrated (Nass et al. 2000), and, at the protein level, E-cadherin has been linked to better differentiation (Gupta et al. 1997). Moreover, mutational analysis of E-cadherin provided evidence to support that DCIS is the precursor of invasive ductal carcinoma in cases where LCIS coexists (Rieger-Christ et al. 2001).

4.9 TGF-beta

The transforming growth factor-beta (TGF- β) pathway has ambivalent importance in the pathogenesis of breast cancer (reviewed in Wakefield et al. 2001). Serum TGF-beta levels do not differ between patients with breast cancer, DCIS and benign lesions (Lebrecht et al. 2004); however, TGF-beta expression becomes more accentuated in IDC, compared with DCIS (Walker et al. 1992). Surprisingly enough, an interesting study recently showed that loss of TGF-beta-RII expression in epithelial cells of hyperplasia without atypia is associated with increased risk of IDC (Gobbi et al. 1999). No reports exist on ADH and LN, to our knowledge.

4.10 P16 (INK4a)

p16 is an inhibitor of cyclin-dependent kinases 4 and 6 (reviewed in Rocco & Sidransky 2001). With respect to the role of p16, controversial results exist. According to some authors, aberrant methylation of p16 is not demonstrated in benign conditions, epithelial hyperplasia and intraductal papillomas, but is restricted in cancerous epithelium (Lehmann et al. 2004). Conversely, another study showed that IDC demonstrates hypomethylation of p16 and hyperactivity of the p16 gene (enhanced expression of p16 mRNA), contrary to the hypermethylated, inactive state in the normal epithelium (Van Zee et al. 1998). Independently, Di Vinci et al. distinguish between p16 hypermethylation and p16 protein overexpression; the former seems not to be specifically associated with malignancy and to occur both in benign and malignant lesions, whereas the latter, together with cytoplasmic sequestration, is a feature of breast carcinoma (Di Vinci et al. 2005). In the context of such controversy, no studies exist with respect to p16 as a risk factor, with the exception of a study in Poland envisaging p16 as a low penetrance breast cancer susceptibility gene (Debniak et al. 2005).

4.11 p27(Kip1)

The p27 gene encodes for an inhibitor of the cyclin – CDK (cyclin-dependent kinase) active complex. Although numerous studies exist with respect to the role of p27 in breast cancer (reviewed in Colozza et al. 2005; Alkarain et al. 2004 and Musgrove et al. 2004), there is a lack of data regarding precursors, pre-invasive lesions and other predisposing conditions. p27 expression has been documented in DCIS, but its clinicopathological significance is still uncertain (Oh et al. 2001).

4.12 P21 (Waf1)

p21 is a cell cycle regulator, implicated in a variety of pathways (Dotto 2000). p21 immunoreactivity has been detected both in benign and malignant epithelium, and thus its role is hard to interpret (Krogerus et al. 2000). Studies focusing especially on ADH or LN do not exist. As far as DCIS is concerned, p21 positivity has been independently associated with clinical recurrence (Provenzano et al. 2003). On the other hand, Oh YL et al. found a significant correlation between positive p21 immunoreactivity (67.3% of the cases) and well-differentiated histologic grade, non-comedo type, ER-positive and p53-negativity. According to these authors, DCIS with p21+/p53- is likely to be the non-comedo type (Oh et al. 2001).

4.13 14-3-3 sigma

Umbricht and coworkers identified 14-3-3 sigma as a gene whose expression is lost in breast carcinomas, primarily by methylation-mediated silencing. Importantly, the hypermethylation of the locus was absent in hyperplasia without atypia, but was detectable with increasing frequency as the breast lesions progressed from atypical hyperplasia to DCIS, and finally to invasive carcinoma (Umbricht et al. 2001); interestingly, methylated alleles existed in the periductal stromal breast tissue. Subsequently, a parallel, stepwise reduction at the 14-3-3 sigma protein level was documented (Simooka et al. 2004).

Despite the emerging role of 14-3-3 sigma in breast carcinogenesis, to date no studies exist assessing its role as a risk factor for breast cancer development.

5. Genetic events

Complex and heterogeneous sets of genetic alterations are involved in the etiology of breast cancer. However, some of these genetic events occur more often early, or late, in carcinogenesis. Rather, breast cancer to be viewed as the result of accumulation of various major and minor genetic events in a fairly, random order, which is referred to as the “bingo principle” analogous to winning the “prize” (in this case cancer) in this popular game. With the establishment of new global genetic screening techniques such as comparative genomic hybridization (CGH), a pattern of genetic alterations has emerged. More recently other methods have been used for the characterization of pre-invasive breast lesions, such as cDNA microarray and proteomics analysis. Numerous studies have documented differences in the copy number, sequence and expression level of specific genes in cohorts of invasive breast carcinomas, but relatively little is known of the events that mediate the transition of normal human breast epithelial cells to premalignant and early tumorigenic states. Non neoplastic breast tissue often harbors genetic changes

that can be important to understanding the local breast environment within which cancer develops. In fact, most pre invasive lesions of the breast are thought to derive from the transition zone between the duct and the functional unit of the breast, the lobule, which is composed of acini that are lined by an outer myoepithelial layer and a inner luminal or glandular layer containing a putative stem or progenitor cell component, which gives rise to the above- mentioned cells. These cells have recently been described and characterized in more detail. It is noteworthy that many characteristics of these cells are shared in mouse and human cells. At present, the relationship between these cells and breast cancer specific stem cells is unclear. However, these cells can serve as a tool to explain the presence of monoclonal patches within a breast lobule or parts of the ductal tree. In addition, the description of non-recurrent genetic changes within the morphologically normal breast tissue, requiring a large subset of affected cells, favors the idea of long living cells as targets of the initial starting of the genetic cascade towards an overt malignancy. The finding of genetic changes within morphologically normal breast tissue is nowadays not only associated with an increased local recurrence risk, but also exerts a tremendous influence on the validity of progression models of breast cancer and especially the relationship toward proposed precursor lesions.

A recent study (Hannafon, et al. 2011) hypothesized that micro RNA expression might be dysregulated prior to invasive breast carcinoma. This study provides the first report of a microRNA expression profile in normal breast epithelium and the first integrated analysis of microRNA and microRNA expression in paired samples of histologically normal epithelia and preinvasive breast cancer. They further demonstrated, by modulating the expression of several microRNA samples, that the expression of their predicted target genes is affected. Taken together, these findings support their hypothesis that changes in microRNA expression in early breast cancer may control many of the parallel changes in gene expression in this stage. This work also implicates the loss of the tumor suppressor miR-125b and the gain of the oncogenic miRNA miR-182 and miR-183 as major contributors to early breast cancer development. Additionally this study has revealed novel candidate markers of preinvasive breast cancer, which could contribute to the identification of new diagnostic and therapeutic targets.

Another study (Kretschmer et al., 2011) has identified, using transgenic mouse model of DCIS (mice were transgenic for the WAP-SV40 early genome region, so that expression of the SV40 oncogene is activated by lactation) and identified seven genes that are significantly up regulated in DCIS: DEPDC1, NUSAP1, EXO1, RRM2, FOXM1, MUC1 and SPP1. A similar upregulation of homologues of these murine genes was observed in human DCIS samples. So, comparing murine markers for the DCIS of the mammary gland with genes up-regulated in human DCIS samples it is possible to identify a set of genes which might allow early detection of DCIS and invasive carcinoma in the future.

Cichon and her co-workers (Cichon et al., 2010) identified alterations in stromal cell function that may be critical for disease progression from benign disease to invasive cancer: key functions of myoepithelial cells that maintain tissue structure are lost, while tissue fibroblasts become activated to produce proteases that degrade the extracellular matrix and trigger the invasive cellular phenotype. Gene expression profiling of stromal alterations associated with disease progression has also identified key transcriptional changes that

occur early in disease development. This study suggests approaches to identify processes that control earlier stages of disease progression.

Future studies aimed at studying post-translational modifications of histone proteins of the different stages of breast cancer promise to shed new light on the epigenetic regulatory control of gene expression during tumorigenesis (Fiegl et al., 2006).

6. Conclusions

Intraepithelial neoplasias of the breast are non-obligate precursor lesions with an increased risk of invasive carcinoma. The evolution to invasive carcinoma may not however be linear and may involve multiple pathways. Genomic instability drives tumorigenic process in invasive carcinoma and premalignant breast lesions and might promote the accumulation of genetic alterations in apparently normal tissue before histological abnormalities are detectable. Evidence suggests that genomic changes in breast parenchyma affect the behavior of epithelial cells and, ultimately, might affect tumor growth and progression. Inherent instability in genes that maintain genomic integrity, as well as exogenous chemical and environmental pollutants, have been implicated in breast cancer development. Although molecular mechanisms of tumorigenesis are unclear at present, carcinogenetic agents could contribute to field of genomic instability localized to specific areas of the breast. The use of molecular profiling technologies to identify distinct features that predict the future behavior of invasive disease is well documented. However, the application of such approaches to the identification of molecular predictors of clinical behavior of normal breast tissue and pre-invasive disease has been hampered by several problems. First, because pre-invasive disease is frequently microscopic in size, all of the tissue is processed through the use of standard pathological formalin fixed paraffin embedded (FFPE) processes and utilized for clinical diagnostic purposes. Second, standard FFPE processes pose a significant technical challenge for high throughput array CGH and gene expression microarray profiling. Third, and most importantly, large clinical cohorts and clinical trials of pre-invasive disease with well-annotated clinical samples and long (10-20 years) clinical follow up are lacking. Understanding the functional importance of genomic instability in early carcinogenesis is important for improving diagnostic and treatment strategies (Ellsworth et al., 2004).

7. Future directions

Despite many molecular studies, breast carcinogenesis is still not well understood. Our knowledge of the genetic and molecular biology of intraepithelial breast lesions is increasing at a remarkably rapid rate. In addition, more and more data are now available on the morphology and immunophenotype of the different precursor lesions, allowing the pathologists to recognize them. Epidemiologic studies have yielded information on the progression risk of several lesions. Future studies are likely to identify markers at a very early stage indeed that can play a role in the development of these precursor lesions from normal breast tissue. Clearly, prospective studies based on larger patient cohorts representing the whole spectrum of breast cancer are needed before the full power of gene expression profiling will be realized in clinical medicine. Results from studies so far are encouraging for the future.

8. References

- Albonico, G., Querzoli, P., Ferretti, S., Magri, E. & Nenci, I. (1996)., Biophenotypes of breast carcinoma in situ defined by image analysis of biological parameters., *Pathology, Research & Practice*, vol. 192, no. 2, pp. 117-123.
- Alkarain, A., Jordan, R. & Slingerland, J. (2004). p27 deregulation in breast cancer: prognostic significance and implications for therapy, *Journal of Mammary Gland Biology & Neoplasia*, vol. 9, no. 1, pp. 67-80.
- Allred, D.C., Clark, G.M., Molina, R., Tandon, A.K., Schnitt, S.J., Gilchrist, K.W., Osborne, C.K., Tormey, D.C. & McGuire, W.L. (1992). Overexpression of HER-2/neu and its relationship with other prognostic factors change during the progression of in situ to invasive breast cancer., *Human pathology*, vol. 23, no. 9, pp. 974-979.
- Allred, DC (2005). Ductal carcinoma in situ of the breast: pathologic and biologic perspectives. American Society of Clinical Oncology 2005 educational book 41st annual meeting, May 13-17, pp 75-79.
- Ariga, N., Suzuki, T., Moriya, T., Kimura, M., Inoue, T., Ohuchi, N. & Sasano, H. (2001). Progesterone receptor A and B isoforms in the human breast and its disorders., *Japanese Journal of Cancer Research*, vol. 92, no. 3, pp. 302-308.
- Aubele, M., Werner, M. & Hofler, H. (2002). Genetic alterations in presumptive precursor lesions of breast carcinomas, *Analytical Cellular Pathology*, vol. 24, no. 2-3, pp. 69-76.
- Bai, M., Agnantis, N.J., Kamina, S., Demou, A., Zagorianakou, P., Katsaraki, A. & Kanavaros, P. (2001). In vivo cell kinetics in breast carcinogenesis., *Breast Cancer Research*, vol. 3, no. 4, pp. 276-283.
- Barker, P.E. (2003). Cancer biomarker validation: standards and process: roles for the National Institute of Standards and Technology (NIST), *Annals of the New York Academy of Sciences*, vol. 983, pp. 142-150.
- Barnes, N.L., Boland, G.P., Davenport, A., Knox, W.F. & Bundred, N.J. (2005). Relationship between hormone receptor status and tumour size, grade and comedo necrosis in ductal carcinoma in situ., *British Journal of Surgery*, vol. 92, no. 4, pp. 429-434.
- Berx, G., Cleton-Jansen, A.M., Nollet, F., de Leeuw, W.J., van de Vijver, M., Cornelisse, C. & van Roy, F. (1995). E-cadherin is a tumour/invasion suppressor gene mutated in human lobular breast cancers., *EMBO Journal*, vol. 14, no. 24, pp. 6107-6115.
- Bjurstam, N., Bjorneld, L., Warwick, J., Sala, E., Duffy, S.W., Nystrom, L., Walker, N., Cahlin, E., Eriksson, O., Hafstrom, L.O., Lingaas, H., Mattsson, J., Persson, S., Rudenstam, C.M., Salander, H., Save-Soderbergh, J. & Wahlin, T. (2003). The Gothenburg Breast Screening Trial., *Cancer*, vol. 97, no. 10, pp. 2387-2396.
- Bose, S., Lesser, M.L., Norton, L. & Rosen, P.P. (1996). Immunophenotype of intraductal carcinoma., *Archives of Pathology & Laboratory Medicine*, vol. 120, no. 1, pp. 81-85.
- Bratthauer, G.L., Moinfar, F., Stamatakis, M.D., Mezzetti, T.P., Shekitka, K.M., Man, Y.G. & Tavassoli, F.A. (2002). Combined E-cadherin and high molecular weight cytokeratin immunoprofile differentiates lobular, ductal, and hybrid mammary intraepithelial neoplasias., *Human pathology*, vol. 33, no. 6, pp. 620-627.
- Bryan J., Land S., Allred C et al. (2003). DCIS: evidence from randomized trials. Proceedings of the 8th international conference March 12-15, 2003, St Gallen, Switzerland. Breast 12(Suppl. 1):S9 (S24) Breast Cancer Research and Treatment 123.

- Buchberger, W., DeKoekkoek-Doll, P., Springer, P., Obrist, P. & Dunser, M. (1999). Incidental findings on sonography of the breast: clinical significance and diagnostic workup., *AJR.American Journal of Roentgenology*, vol. 173, no. 4, pp. 921-927.
- Buchberger, W., Niehoff, A., Obrist, P., DeKoekkoek-Doll, P. & Dunser, M. (2000). Clinically and mammographically occult breast lesions: detection and classification with high-resolution sonography., *Seminars in Ultrasound, CT & MR*, vol. 21, no. 4, pp. 325-336.
- Burbank, F. (1997). Stereotactic breast biopsy of atypical ductal hyperplasia and ductal carcinoma in situ lesions: improved accuracy with directional, vacuum-assisted biopsy., *Radiology*, vol. 202, no. 3, pp. 843-847.
- Burstein, H.J., Polyak, K., Wong, J.S., Lester, S.C. & Kaelin, C.M. (2004). Ductal carcinoma in situ of the breast, *New England Journal of Medicine*, vol. 350, no. 14, pp. 1430-1441.
- Chitemerere, M., Andersen, T.I., Holm, R., Karlsen, F., Borresen, A.L. & Nesland, J.M. (1996). TP53 alterations in atypical ductal hyperplasia and ductal carcinoma in situ of the breast., *Breast Cancer Research & Treatment*, vol. 41, no. 2, pp. 103-109.
- Cichon, M.A., Degnim A.C, Visscher DW, Radisky DC. (2010). Microenvironmental influences that drive progression from benign breast disease to invasive breast cancer. *Journal of Mammary Gland Biology and Neoplasia*, vol. 15, no. 4, pp. 389-397.
- Clarke, R.B., Howell, A., Potten, C.S. & Anderson, E. 1997, Dissociation between steroid receptor expression and cell proliferation in the human breast., *Cancer research*, vol. 57, no. 22, pp. 4987-4991.
- Claus, E.B., Chu, P., Howe, C.L., Davison, T.L., Stern, D.F., Carter, D. & DiGiovanna, M.P. (2001). Pathobiologic findings in DCIS of the breast: morphologic features, angiogenesis, HER-2/neu and hormone receptors., *Experimental & Molecular Pathology*, vol. 70, no. 3, pp. 303-316.
- Cody, H.S.,3rd (2007). Sentinel lymph node biopsy for breast cancer: indications, contraindications, and new directions., *Journal of surgical oncology*, vol. 95, no. 6, pp. 440-442.
- Colozza, M., Azambuja, E., Cardoso, F., Sotiriou, C., Larsimont, D. & Piccart, M.J. (2005). Proliferative markers as prognostic and predictive tools in early breast cancer: where are we now?, *Annals of Oncology*, vol. 16, no. 11, pp. 1723-1739.
- Cornfield, D.B., Palazzo, J.P., Schwartz, G.F., Goonewardene, S.A., Kovatich, A.J., Chervoneva, I., Hyslop, T. & Schwarting, R. (2004). The prognostic significance of multiple morphologic features and biologic markers in ductal carcinoma in situ of the breast: a study of a large cohort of patients treated with surgery alone., *Cancer*, vol. 100, no. 11, pp. 2317-2327.
- Cox, C.E., Nguyen, K., Gray, R.J., Salud, C., Ku, N.N., Dupont, E., Hutson, L., Peltz, E., Whitehead, G., Reintgen, D. & Cantor, A. (2001). Importance of lymphatic mapping in ductal carcinoma in situ (DCIS): why map DCIS?., *American Surgeon*, vol. 67, no. 6, pp. 513-519.
- De Potter, C.R., Van Daele, S., Van de Vijver, M.J., Pauwels, C., Maertens, G., De Boever, J., Vandekerckhove, D. & Roels, H. (1989). The expression of the neu oncogene product in breast lesions and in normal fetal and adult human tissues., *Histopathology*, vol. 15, no. 4, pp. 351-362.

- Debniak, T., Gorski, B., Huzarski, T., Byrski, T., Cybulski, C., Mackiewicz, A., Gozdecka-Grodecka, S., Gronwald, J., Kowalska, E., Haus, O., Grzybowska, E., Stawicka, M., Swiec, M., Urbanski, K., Niepsuj, S., Wasko, B., Gozdz, S., Wandzel, P., Szczyluk, C., Surdyka, D., Rozmiarek, A., Zambrano, O., Posmyk, M., Narod, S.A. & Lubinski, J. (2005). A common variant of CDKN2A (p16) predisposes to breast cancer., *Journal of medical genetics*, vol. 42, no. 10, pp. 763-765.
- Dershaw, D.D., Abramson, A. & Kinne, D.W. (1989). Ductal carcinoma in situ: mammographic findings and clinical implications., *Radiology*, vol. 170, no. 2, pp. 411-415.
- Di Vinci, A., Perdelli, L., Banelli, B., Salvi, S., Casciano, I., Gelvi, I., Allemanni, G., Margallo, E., Gatteschi, B. & Romani, M. (2005). p16(INK4a) promoter methylation and protein expression in breast fibroadenoma and carcinoma., *International Journal of Cancer*, vol. 114, no. 3, pp. 414-421.
- Done, S.J., Arneson, N.C., Ozelik, H., Redston, M. & Andrulis, I.L. (1998). p53 mutations in mammary ductal carcinoma in situ but not in epithelial hyperplasias., *Cancer research*, vol. 58, no. 4, pp. 785-789.
- Dooley, W.C., Ljung, B.M., Veronesi, U., Cazzaniga, M., Elledge, R.M., O'Shaughnessy, J.A., Kuerer, H.M., Hung, D.T., Khan, S.A., Phillips, R.F., Ganz, P.A., Euhus, D.M., Esserman, L.J., Haffty, B.G., King, B.L., Kelley, M.C., Anderson, M.M., Schmit, P.J., Clark, R.R., Kass, F.C., Anderson, B.O., Troyan, S.L., Arias, R.D., Quiring, J.N., Love, S.M., Page, D.L. & King, E.B. (2001). Ductal lavage for detection of cellular atypia in women at high risk for breast cancer., *Journal of the National Cancer Institute*, vol. 93, no. 21, pp. 1624-1632.
- Dotto, G.P. (2000). p21(WAF1/Cip1): more than a break to the cell cycle?, *Biochimica et biophysica acta*, vol. 1471, no. 1, pp. M43-56.
- Edorh, A., Leroux, A., N'sossani, B., Parache, R.M. & Rihn, B. (1999). Detection by immunohistochemistry of c-erbB2 oncoprotein in breast carcinomas and benign mammary lesions., *Cellular & Molecular Biology*, vol. 45, no. 6, pp. 831-840.
- Ellsworth, D.L., Ellsworth R.E., Liebman M.N., Hooke J.A., & Shriver C. D. (2004). Genomic instability in histologically normal breast tissues: implications for carcinogenesis., *Lancet Oncology*, vol.5, no.12, pp.753-8.
- Emdin, S.O., Granstrand, B., Ringberg, A., Sandelin, K., Arnesson, L.G., Nordgren, H., Anderson, H., Garmo, H., Holmberg, L., Wallgren, A. & Swedish Breast Cancer, G. (2006). SweDCIS: Radiotherapy after sector resection for ductal carcinoma in situ of the breast. Results of a randomised trial in a population offered mammography screening., *Acta Oncologica*, vol. 45, no. 5, pp. 536-543.
- EORTC Breast Cancer Cooperative, G., EORTC Radiotherapy, G., Bijker, N., Meijnen, P., Peterse, J.L., Bogaerts, J., Van Hoorebeeck, I., Julien, J.P., Gennaro, M., Rouanet, P., Avril, A., Fentiman, I.S., Bartelink, H. & Rutgers, E.J. (2006). Breast-conserving treatment with or without radiotherapy in ductal carcinoma-in-situ: ten-year results of European Organisation for Research and Treatment of Cancer randomized phase III trial 10853--a study by the EORTC Breast Cancer Cooperative Group and EORTC Radiotherapy Group., *Journal of Clinical Oncology*, vol. 24, no. 21, pp. 3381-3387.

- Ernster, V.L., Ballard-Barbash, R., Barlow, W.E., Zheng, Y., Weaver, D.L., Cutter, G., Yankaskas, B.C., Rosenberg, R., Carney, P.A., Kerlikowske, K., Taplin, S.H., Urban, N. & Geller, B.M. (2002). Detection of ductal carcinoma in situ in women undergoing screening mammography., *Journal of the National Cancer Institute*, vol. 94, no. 20, pp. 1546-1554.
- Fabian, C.J., Kimler, B.F., Zalles, C.M., Klemp, J.R., Kamel, S., Zeiger, S. & Mayo, M.S. (2000). Short-term breast cancer prediction by random periareolar fine-needle aspiration cytology and the Gail risk model., *Journal of the National Cancer Institute*, vol. 92, no. 15, pp. 1217-1227.
- Fadare, O., Dadmanesh, F., Alvarado-Cabrero, I., Snyder, R., Stephen Mitchell, J., Tot, T., Wang, S.A., Ghofrani, M., Eusebi, V., Martel, M. & Tavassoli, F.A. (2006). Lobular intraepithelial neoplasia [lobular carcinoma in situ] with comedo-type necrosis: A clinicopathologic study of 18 cases., *American Journal of Surgical Pathology*, vol. 30, no. 11, pp. 1445-1453.
- Farante, G., Zurrida, S., Galimberti, V., Veronesi, P., Curigliano, G., Luini, A., Goldhirsch, A. & Veronesi, U. (2011). The management of ductal intraepithelial neoplasia (DIN): open controversies and guidelines of the Istituto Europeo di Oncologia (IEO), Milan, Italy, *Breast Cancer Research & Treatment*, vol. 128, no. 2, pp. 369-378.
- Fiegl H., Millinger S., Goebel G., Müller-Holzner E., Marth C., Laird P.W., & Widschwendter M. (2006). Breast cancer DNA methylation profiles in cancer cells and tumor stroma: association with HER-2/neu status in primary breast cancer., *Cancer Research*, vol. 66, no. 1, pp. 29-33.
- Fisher, B., Land, S., Mamounas, E., Dignam, J., Fisher, E.R. & Wolmark, N. (2001). Prevention of invasive breast cancer in women with ductal carcinoma in situ: an update of the National Surgical Adjuvant Breast and Bowel Project experience., *Seminars in oncology*, vol. 28, no. 4, pp. 400-418.
- Fisher, E.R., Costantino, J., Fisher, B., Palekar, A.S., Paik, S.M., Suarez, C.M. & Wolmark, N. (1996). Pathologic findings from the National Surgical Adjuvant Breast Project (NSABP) Protocol B-17. Five-year observations concerning lobular carcinoma in situ., *Cancer*, vol. 78, no. 7, pp. 1403-1416.
- Fisher, E.R., Dignam, J., Tan-Chiu, E., Costantino, J., Fisher, B., Paik, S. & Wolmark, N. (1999). Pathologic findings from the National Surgical Adjuvant Breast Project (NSABP) eight-year update of Protocol B-17: intraductal carcinoma., *Cancer*, vol. 86, no. 3, pp. 429-438.
- Fisher, E.R., Leeming, R., Anderson, S., Redmond, C. & Fisher, B. (1991). Conservative management of intraductal carcinoma (DCIS) of the breast. Collaborating NSABP investigators., *Journal of surgical oncology*, vol. 47, no. 3, pp. 139-147.
- Foot, F.W. & Stewart, F.W. (1941). Lobular carcinoma in situ. A rare form of mammary cancer. *American Journal of Pathology*, vol. 17, pp. 491-496.
- Frisell, J., Lidbrink, E., Hellstrom, L. & Rutqvist, L.E. (1997). Followup after 11 years--update of mortality results in the Stockholm mammographic screening trial., *Breast Cancer Research & Treatment*, vol. 45, no. 3, pp. 263-270.
- Gasco, M., Shami, S. & Crook, T. (2002). The p53 pathway in breast cancer, *Breast Cancer Research*, vol. 4, no. 2, pp. 70-76.

- Gerdes, J., Lemke, H., Baisch, H., Wacker, H.H., Schwab, U. & Stein, H. (1984). Cell cycle analysis of a cell proliferation-associated human nuclear antigen defined by the monoclonal antibody Ki-67., *Journal of Immunology*, vol. 133, no. 4, pp. 1710-1715.
- Gobbi, H., Dupont, W.D., Parl, F.F., Schuyler, P.A., Plummer, W.D., Olson, S.J. & Page, D.L. (2005). Breast cancer risk associated with estrogen receptor expression in epithelial hyperplasia lacking atypia and adjacent lobular units., *International Journal of Cancer*, vol. 113, no. 5, pp. 857-859.
- Gobbi, H., Dupont, W.D., Simpson, J.F., Plummer, W.D., Jr, Schuyler, P.A., Olson, S.J., Arteaga, C.L. & Page, D.L. (1999). Transforming growth factor-beta and breast cancer risk in women with mammary epithelial hyperplasia., *Journal of the National Cancer Institute*, vol. 91, no. 24, pp. 2096-2101.
- Goldhirsch, A., Ingle, J.N., Gelber, R.D., Coates, A.S., Thurlimann, B., Senn, H.J. & Panel, m. (2009). Thresholds for therapies: highlights of the St Gallen International Expert Consensus on the primary therapy of early breast cancer 2009, *Annals of Oncology*, vol. 20, no. 8, pp. 1319-1329.
- Graham, J.D., Yager, M.L., Hill, H.D., Byth, K., O'Neill, G.M. & Clarke, C.L. (2005). Altered progesterone receptor isoform expression remodels progestin responsiveness of breast cancer cells., *Molecular Endocrinology*, vol. 19, no. 11, pp. 2713-2735.
- Guerrieri-Gonzaga, A., Botteri, E., Rotmensz, N., Bassi, F., Intra, M., Serrano, D., Renne, G., Luini, A., Cazzaniga, M., Goldhirsch, A., Colleoni, M., Viale, G., Ivaldi, G., Bagnardi, V., Lazzaroni, M., Decensi, A., Veronesi, U. & Bonanni, B. (2009). Ductal intraepithelial neoplasia: postsurgical outcome for 1,267 women cared for in one single institution over 10 years., *Oncologist*, vol. 14, no. 3, pp. 201-212.
- Gupta, S.K., Douglas-Jones, A.G., Jasani, B., Morgan, J.M., Pignatelli, M. & Mansel, R.E. (1997). E-cadherin (E-cad) expression in duct carcinoma in situ (DCIS) of the breast., *Virchows Archiv*, vol. 430, no. 1, pp. 23-28.
- Gusterson, B.A., Machin, L.G., Gullick, W.J., Gibbs, N.M., Powles, T.J., Elliott, C., Ashley, S., Monaghan, P. & Harrison, S. (1988). c-erbB-2 expression in benign and malignant breast disease., *British journal of cancer*, vol. 58, no. 4, pp. 453-457.
- Hannafon, B.N., Sebastiani, P., de Las Morenas, A., Lu, J., & Rosenberg, C.L. (2011). Expression of microRNA and their gene targets are dysregulated in preinvasive breast cancer. *Breast Cancer Research & Treatment*, vol. 13, no. 2, pp. R24
- Heffelfinger, S.C., Yassin, R., Miller, M.A. & Lower, E.E. (2000). Cyclin D1, retinoblastoma, p53, and Her2/neu protein expression in preinvasive breast pathologies: correlation with vascularity., *Pathobiology*, vol. 68, no. 3, pp. 129-136.
- Henderson, B.E., Ross, R. & Bernstein, L. (1988). Estrogens as a cause of human cancer: the Richard and Linda Rosenthal Foundation award lecture, *Cancer research*, vol. 48, no. 2, pp. 246-253.
- Hieken, T.J., Farolan, M., D'Alessandro, S. & Velasco, J.M. (2001). Predicting the biologic behavior of ductal carcinoma in situ: an analysis of molecular markers., *Surgery*, vol. 130, no. 4, pp. 593-600.
- Hockenbery, D.M. (1994). bcl-2 in cancer, development and apoptosis, *Journal of Cell Science - Supplement*, vol. 18, pp. 51-55.

- Holland, R., Peterse, J.L., Millis, R.R., Eusebi, V., Faverly, D., van de Vijver, M.J. & Zafrani, B. (1994). Ductal carcinoma in situ: a proposal for a new classification, *Seminars in diagnostic pathology*, vol. 11, no. 3, pp. 167-180.
- Houghton, J. George, W.D. Cuzick, J. Duggan, C. Fentiman, IS. Spittle, M. UK Coordinating Committee on Cancer Research. Ductal Carcinoma in situ Working Party. DCIS trialists in the UK, Australia, and New Zealand (2003). Radiotherapy and tamoxifen in women with completely excised ductal carcinoma in situ of the breast in the UK, Australia, and New Zealand: randomised controlled trial., *Lancet*, vol. 362, no. 9378, pp. 95-102.
- Hudelist, G., Czerwenka, K., Kubista, E., Marton, E., Pischinger, K. & Singer, C.F. (2003). Expression of sex steroid receptors and their co-factors in normal and malignant breast tissue: AIB1 is a carcinoma-specific co-activator., *Breast Cancer Research & Treatment*, vol. 78, no. 2, pp. 193-204.
- Hughes, L.L., Wang, M., Page, D.L., Gray, R., Solin, L.J., Davidson, N.E., Lowen, M.A., Ingle, J.N., Recht, A. & Wood, W.C. (2009). Local excision alone without irradiation for ductal carcinoma in situ of the breast: a trial of the Eastern Cooperative Oncology Group., *Journal of Clinical Oncology*, vol. 27, no. 32, pp. 5319-5324.
- Hwang, E.S., Kinkel, K., Esserman, L.J., Lu, Y., Weidner, N. & Hylton, N.M. (2003). Magnetic resonance imaging in patients diagnosed with ductal carcinoma-in-situ: value in the diagnosis of residual disease, occult invasion, and multicentricity., *Annals of Surgical Oncology*, vol. 10, no. 4, pp. 381-388.
- Ikeda, D.M. & Andersson, I. (1989). Ductal carcinoma in situ: atypical mammographic appearances., *Radiology*, vol. 172, no. 3, pp. 661-666.
- Intra, M., Rotmensz, N., Mattar, D., Gentilini, O.D., Vento, A., Veronesi, P., Colleoni, M., De Cicco, C., Cassano, E., Luini, A. & Veronesi, U. (2007). Unnecessary axillary node dissections in the sentinel lymph node era., *European journal of cancer*, vol. 43, no. 18, pp. 2664-2668.
- Intra, M., Rotmensz, N., Veronesi, P., Colleoni, M., Iodice, S., Paganelli, G., Viale, G. & Veronesi, U. (2008). Sentinel node biopsy is not a standard procedure in ductal carcinoma in situ of the breast: the experience of the European institute of oncology on 854 patients in 10 years., *Annals of Surgery*, vol. 247, no. 2, pp. 315-319.
- Intra, M., Veronesi, P., Mazzarol, G., Galimberti, V., Luini, A., Sacchini, V., Trifiro, G., Gentilini, O., Pruneri, G., Naninato, P., Torres, F., Paganelli, G., Viale, G. & Veronesi, U. (2003). Axillary sentinel lymph node biopsy in patients with pure ductal carcinoma in situ of the breast., *Archives of Surgery*, vol. 138, no. 3, pp. 309-313.
- Iqbal, M., Davies, M.P., Shoker, B.S., Jarvis, C., Sibson, D.R. & Sloane, J.P. (2001). Subgroups of non-atypical hyperplasia of breast defined by proliferation of oestrogen receptor-positive cells., *Journal of Pathology*, vol. 193, no. 3, pp. 333-338.
- Jacobs, E.J., Feigelson, H.S., Bain, E.B., Brady, K.A., Rodriguez, C., Stevens, V.L., Patel, A.V., Thun, M.J. & Calle, E.E. (2006). Polymorphisms in the vascular endothelial growth factor gene and breast cancer in the Cancer Prevention Study II cohort., *Breast Cancer Research*, vol. 8, no. 2, pp. R22.

- Julian, T.B., Land, S.R., Fourchotte, V., Haile, S.R., Fisher, E.R., Mamounas, E.P., Costantino, J.P. & Wolmark, N. (2007). Is sentinel node biopsy necessary in conservatively treated DCIS?, *Annals of Surgical Oncology*, vol. 14, no. 8, pp. 2202-2208.
- Kang, J.H., Kim, S.J., Noh, D.Y., Choe, K.J., Lee, E.S. & Kang, H.S. (2001). The timing and characterization of p53 mutations in progression from atypical ductal hyperplasia to invasive lesions in the breast cancer., *Journal of Molecular Medicine*, vol. 79, no. 11, pp. 648-655.
- Kapucuoglu, N., Losi, L. & Eusebi, V. (1997). Immunohistochemical localization of Bcl-2 and Bax proteins in in situ and invasive duct breast carcinomas., *Virchows Archiv*, vol. 430, no. 1, pp. 17-22.
- Keohavong, P., Gao, W.M., Mady, H.H., Kanbour-Shakir, A. & Melhem, M.F. (2004). Analysis of p53 mutations in cells taken from paraffin-embedded tissue sections of ductal carcinoma in situ and atypical ductal hyperplasia of the breast., *Cancer letters*, vol. 212, no. 1, pp. 121-130.
- Kepple, J., Henry-Tillman, R.S., Klimberg, V.S., Layeeque, R., Siegel, E., Westbrook, K. & Korourian, S. (2006). The receptor expression pattern in ductal carcinoma in situ predicts recurrence., *American Journal of Surgery*, vol. 192, no. 1, pp. 68-71.
- Kerlikowske, K., Molinaro, A., Cha, I., Ljung, B.M., Ernster, V.L., Stewart, K., Chew, K., Moore, D.H. 2nd & Waldman, F. (2003). Characteristics associated with recurrence among women with ductal carcinoma in situ treated by lumpectomy., *Journal of the National Cancer Institute*, vol. 95, no. 22, pp. 1692-1702.
- Khan, S.A., Rogers, M.A., Khurana, K.K., Meguid, M.M. & Numann, P.J. (1998). Estrogen receptor expression in benign breast epithelium and breast cancer risk., *Journal of the National Cancer Institute*, vol. 90, no. 1, pp. 37-42.
- Kim, R. (2005). Unknotting the roles of Bcl-2 and Bcl-xL in cell death, *Biochemical & Biophysical Research Communications*, vol. 333, no. 2, pp. 336-343.
- Krassenstein, R., Sauter, E., Dulaimi, E., Battagli, C., Ehya, H., Klein-Szanto, A. & Cairns, P. (2004). Detection of breast cancer in nipple aspirate fluid by CpG island hypermethylation., *Clinical Cancer Research*, vol. 10, no. 1 Pt 1, pp. 28-32.
- Kretschmer, C., Sterner-Kock, A., Siedentopf, F., Schoenegg, W., Schlag, P.M., & Kemmner, W., (2011). Identification of early molecular markers for breast cancer. *Molecular Cancer*. vol.10, no.1, pp. 15.
- Krishnamurthy, S., Sneige, N., Thompson, P.A., Marcy, S.M., Singletary, S.E., Cristofanilli, M., Hunt, K.K. & Kuerer, H.M. (2003). Nipple aspirate fluid cytology in breast carcinoma., *Cancer*, vol. 99, no. 2, pp. 97-104.
- Krogerus L.A., Leivonen M. & Hästö A.L. (2000). Expression patterns of biologic markers in small breast cancers and preneoplastic breast lesions. *Breast*, vol.9, no.5, pp.281-285.
- Kuerer, H.M., Albarracin, C.T., Yang, W.T., Cardiff, R.D., Brewster, A.M., Symmans, W.F., Hylton, N.M., Middleton, L.P., Krishnamurthy, S., Perkins, G.H., Babiera, G., Edgerton, M.E., Czerniecki, B.J., Arun, B.K. & Hortobagyi, G.N. (2009). Ductal carcinoma in situ: state of the science and roadmap to advance the field, *Journal of Clinical Oncology*, vol. 27, no. 2, pp. 279-288.

- Lagios, M.D. (1990). Duct carcinoma in situ. Pathology and treatment., *Surgical Clinics of North America*, vol. 70, no. 4, pp. 853-871.
- Lebeau, A., Unholzer, A., Amann, G., Kronawitter, M., Bauerfeind, I., Sendelhofert, A., Iff, A. & Lohrs, U. (2003). EGFR, HER-2/neu, cyclin D1, p21 and p53 in correlation to cell proliferation and steroid hormone receptor status in ductal carcinoma in situ of the breast., *Breast Cancer Research & Treatment*, vol. 79, no. 2, pp. 187-198.
- Lebrecht, A., Buchmann, J., Hefler, L., Lampe, D. & Koelbl, H. (2002). Histological category and expression of hormone receptors in ductal carcinoma in situ of the breast., *Anticancer Research*, vol. 22, no. 3, pp. 1909-1911.
- Lebrecht, A., Grimm, C., Euller, G., Ludwig, E., Ulbrich, E., Lantzsch, T., Hefler, L. & Koelbl, H. (2004). Transforming growth factor beta 1 serum levels in patients with preinvasive and invasive lesions of the breast., *International Journal of Biological Markers*, vol. 19, no. 3, pp. 236-239.
- Lee, C.H., Carter, D., Philpotts, L.E., Couce, M.E., Horvath, L.J., Lange, R.C. & Tocino, I. (2000). Ductal carcinoma in situ diagnosed with stereotactic core needle biopsy: can invasion be predicted?., *Radiology*, vol. 217, no. 2, pp. 466-470.
- Lee, S., Mohsin, S.K., Mao, S., Hilsenbeck, S.G., Medina, D. & Allred, D.C. (2006). Hormones, receptors, and growth in hyperplastic enlarged lobular units: early potential precursors of breast cancer., *Breast Cancer Research*, vol. 8, no. 1, pp. R6.
- Lehman, C.D., Gatsonis, C., Kuhl, C.K., Hendrick, R.E., Pisano, E.D., Hanna, L., Peacock, S., Smazal, S.F., Maki, D.D., Julian, T.B., DePeri, E.R., Bluemke, D.A., Schnall, M.D. & ACRIN Trial 6667 Investigators, G. (2007). MRI evaluation of the contralateral breast in women with recently diagnosed breast cancer., *New England Journal of Medicine*, vol. 356, no. 13, pp. 1295-1303.
- Leonard, G.D. & Swain, S.M. (2004). Ductal carcinoma in situ, complexities and challenges, *Journal of the National Cancer Institute*, vol. 96, no. 12, pp. 906-920.
- Lerwill, M.F. (2004). Current practical applications of diagnostic immunohistochemistry in breast pathology, *American Journal of Surgical Pathology*, vol. 28, no. 8, pp. 1076-1091.
- Li, C.I., Malone, K.E., Saltzman, B.S. & Daling, J.R. (2006). Risk of invasive breast carcinoma among women diagnosed with ductal carcinoma in situ and lobular carcinoma in situ, 1988-2001., *Cancer*, vol. 106, no. 10, pp. 2104-2112.
- Madu, C.O. & Lu, Y. (2010). Novel diagnostic biomarkers for prostate cancer., *Journal of Cancer*, vol. 1, pp. 150-177.
- Mansel, R.E. (2003). Ductal carcinoma in situ: surgery and radiotherapy., *Breast*, vol. 12, no. 6, pp. 447-450.
- Mastracci, T.L., Tjan, S., Bane, A.L., O'Malley, F.P. & Andrulis, I.L. (2005). E-cadherin alterations in atypical lobular hyperplasia and lobular carcinoma in situ of the breast., *Modern Pathology*, vol. 18, no. 6, pp. 741-751.
- McGowan, E.M. & Clarke, C.L. (1999). Effect of overexpression of progesterone receptor A on endogenous progestin-sensitive endpoints in breast cancer cells., *Molecular Endocrinology*, vol. 13, no. 10, pp. 1657-1671.
- McLaren, B.K., Gobbi, H., Schuyler, P.A., Olson, S.J., Parl, F.F., Dupont, W.D. & Page, D.L. (2005). Immunohistochemical expression of estrogen receptor in enlarged lobular

- units with columnar alteration in benign breast biopsies: a nested case-control study., *American Journal of Surgical Pathology*, vol. 29, no. 1, pp. 105-108.
- Megha, T., Ferrari, F., Benvenuto, A., Bellan, C., Lalinga, A.V., Lazzi, S., Bartolommei, S., Cevenini, G., Leoncini, L. & Tosi, P. (2002). p53 mutation in breast cancer. Correlation with cell kinetics and cell of origin., *Journal of clinical pathology*, vol. 55, no. 6, pp. 461-466.
- Menell, J.H., Morris, E.A., Dershaw, D.D., Abramson, A.F., Brogi, E. & Liberman, L. (2005). Determination of the presence and extent of pure ductal carcinoma in situ by mammography and magnetic resonance imaging., *Breast Journal*, vol. 11, no. 6, pp. 382-390.
- Meteoglu, I., Dikicioglu, E., Erkus, M., Culhaci, N., Kacar, F., Ozkara, E. & Uyar, M. (2005). Breast carcinogenesis. Transition from hyperplasia to invasive lesions., *Saudi medical journal*, vol. 26, no. 12, pp. 1889-1896.
- Midulla, C., Pisani, T., De Iorio, P., Cenci, M., Divizia, E., Nofroni, I. & Vecchione, A. (2002). Cytological analysis and immunocytochemical expression of Ki67 and Bcl-2 in breast proliferative lesions., *Anticancer Research*, vol. 22, no. 2B, pp. 1341-1345.
- Miller, A.B., To, T., Baines, C.J. & Wall, C. (2002). The Canadian National Breast Screening Study-1: breast cancer mortality after 11 to 16 years of follow-up. A randomized screening trial of mammography in women age 40 to 49 years, *Annals of Internal Medicine*, vol. 137, no. 5 Part 1, pp. 305-312.
- Miller, A.B., To, T., Baines, C.J. & Wall, C. (2000). Canadian National Breast Screening Study-2: 13-year results of a randomized trial in women aged 50-59 years., *Journal of the National Cancer Institute*, vol. 92, no. 18, pp. 1490-1499.
- Mohsin, S.K., O'Connell, P., Allred, D.C. & Libby, A.L. (2005). Biomarker profile and genetic abnormalities in lobular carcinoma in situ., *Breast Cancer Research & Treatment*, vol. 90, no. 3, pp. 249-256.
- Morrow, M., Strom, E.A., Bassett, L.W., Dershaw, D.D., Fowble, B., Harris, J.R., O'Malley, F., Schnitt, S.J., Singletary, S.E., Winchester, D.P., American College of, S., College of American, P., Society of Surgical, O. & American College of, R. (2002). Standard for the management of ductal carcinoma in situ of the breast (DCIS), *CA: a Cancer Journal for Clinicians*, vol. 52, no. 5, pp. 256-276.
- Mote, P.A., Bartow, S., Tran, N. & Clarke, C.L. (2002). Loss of co-ordinate expression of progesterone receptors A and B is an early event in breast carcinogenesis., *Breast Cancer Research & Treatment*, vol. 72, no. 2, pp. 163-172.
- Mote, P.A., Leary, J.A., Avery, K.A., Sandelin, K., Chenevix-Trench, G., Kirk, J.A., Clarke, C.L. & kConFab, I. (2004). Germ-line mutations in BRCA1 or BRCA2 in the normal breast are associated with altered expression of estrogen-responsive proteins and the predominance of progesterone receptor A., *Genes, chromosomes & cancer*, vol. 39, no. 3, pp. 236-248.
- Musgrove, E.A., Davison, E.A. & Ormandy, C.J. (2004). Role of the CDK inhibitor p27 (Kip1) in mammary development and carcinogenesis: insights from knockout mice, *Journal of Mammary Gland Biology & Neoplasia*, vol. 9, no. 1, pp. 55-66.

- Mustonen, M., Raunio, H., Paakko, P. & Soini, Y. (1997). The extent of apoptosis is inversely associated with bcl-2 expression in premalignant and malignant breast lesions., *Histopathology*, vol. 31, no. 4, pp. 347-354.
- Mylonas, I., Makovitzky, J., Jeschke, U., Briesse, V., Friese, K. & Gerber, B. (2005). Expression of Her2/neu, steroid receptors (ER and PR), Ki67 and p53 in invasive mammary ductal carcinoma associated with ductal carcinoma In Situ (DCIS) Versus invasive breast cancer alone., *Anticancer Research*, vol. 25, no. 3A, pp. 1719-1723.
- Nass, S.J., Herman, J.G., Gabrielson, E., Iversen, P.W., Parl, F.F., Davidson, N.E. & Graff, J.R. (2000). Aberrant methylation of the estrogen receptor and E-cadherin 5' CpG islands increases with malignant progression in human breast cancer., *Cancer research*, vol. 60, no. 16, pp. 4346-4348.
- National Comprehensive Cancer Network (NCCN) Guidelines for Treatment of Cancer by Site: Breast Cancer. (2009). Available from http://www.nccn.org/professionals/physician_gls/breast.pdf
- Nofech-Mozes, S., Spayne, J., Rakovitch, E. & Hanna, W. (2005). Prognostic and predictive molecular markers in DCIS: a review, *Advances in Anatomic Pathology*, vol. 12, no. 5, pp. 256-264.
- Nystrom, L., Andersson, I., Bjurstam, N., Frisell, J., Nordenskjold, B. & Rutqvist, L.E. (2002). Long-term effects of mammography screening: updated overview of the Swedish randomised trials, *Lancet*, vol. 359, no. 9310, pp. 909-919.
- Oh, Y.L., Choi, J.S., Song, S.Y., Ko, Y.H., Han, B.K., Nam, S.J. & Yang, J.H. (2001). Expression of p21Waf1, p27Kip1 and cyclin D1 proteins in breast ductal carcinoma in situ: Relation with clinicopathologic characteristics and with p53 expression and estrogen receptor status., *Pathology international*, vol. 51, no. 2, pp. 94-99.
- O'Malley, F.P., Vnencak-Jones, C.L., Dupont, W.D., Parl, F., Manning, S. & Page, D.L. (1994). p53 mutations are confined to the comedo type ductal carcinoma in situ of the breast. Immunohistochemical and sequencing data., *Laboratory Investigation*, vol. 71, no. 1, pp. 67-72.
- O'Neill, P.A., Shaaban, A.M., West, C.R., Dodson, A., Jarvis, C., Moore, P., Davies, M.P., Sibson, D.R. & Foster, C.S. (2004). Increased risk of malignant progression in benign proliferating breast lesions defined by expression of heat shock protein 27., *British journal of cancer*, vol. 90, no. 1, pp. 182-188.
- Orel, S.G., Mendonca, M.H., Reynolds, C., Schnall, M.D., Solin, L.J. & Sullivan, D.C. (1997). MR imaging of ductal carcinoma in situ., *Radiology*, vol. 202, no. 2, pp. 413-420.
- Page, D.L., Dupont, W.D., Rogers, L.W. & Landenberger, M. (1982). Intraductal carcinoma of the breast: follow-up after biopsy only., *Cancer*, vol. 49, no. 4, pp. 751-758.
- Papantoniou, V., Tsiouris, S., Koutsikos, J., Sotiropoulou, M., Mainta, E., Lazaris, D., Valsamaki, P., Melissinou, M., Zerva, C. & Antsaklis, A. (2006). Scintimammographic detection of usual ductal breast hyperplasia with increased proliferation rate at risk for malignancy., *Nuclear medicine communications*, vol. 27, no. 11, pp. 911-917.
- Parker, S.H., Burbank, F., Jackman, R.J., Aucreman, C.J., Cardenosa, G., Cink, T.M., Coscia, J.L., Jr, Eklund, G.W., Evans, W.P., 3rd & Garver, P.R. (1994). Percutaneous large-

- core breast biopsy: a multi-institutional study., *Radiology*, vol. 193, no. 2, pp. 359-364.
- Petersen, O.W., Hoyer, P.E. & van Deurs, B. (1987). Frequency and distribution of estrogen receptor-positive cells in normal, nonlactating human breast tissue., *Cancer research*, vol. 47, no. 21, pp. 5748-5751.
- Poller, D.N., Roberts, E.C., Bell, J.A., Elston, C.W., Blamey, R.W. & Ellis, I.O. (1993). p53 protein expression in mammary ductal carcinoma in situ: relationship to immunohistochemical expression of estrogen receptor and c-erbB-2 protein., *Human pathology*, vol. 24, no. 5, pp. 463-468.
- Provenzano, E., Hopper, J.L., Giles, G.G., Marr, G., Venter, D.J. & Armes, J.E. (2003). Biological markers that predict clinical recurrence in ductal carcinoma in situ of the breast., *European journal of cancer*, vol. 39, no. 5, pp. 622-630.
- Putti, T.C., Pinder, S.E., Elston, C.W., Lee, A.H. & Ellis, I.O. (2005). Breast pathology practice: most common problems in a consultation service, *Histopathology*, vol. 47, no. 5, pp. 445-457.
- Reed, J.C. (1994). Bcl-2 and the regulation of programmed cell death, *Journal of Cell Biology*, vol. 124, no. 1-2, pp. 1-6.
- Rieger-Christ, K.M., Pezza, J.A., Dugan, J.M., Braasch, J.W., Hughes, K.S. & Summerhayes, I.C. (2001). Disparate E-cadherin mutations in LCIS and associated invasive breast carcinomas., *Molecular Pathology*, vol. 54, no. 2, pp. 91-97.
- Ringberg, A., Anagnostaki, L., Anderson, H., Idvall, I., Ferno, M. & South Sweden Breast Cancer, G. (2001). Cell biological factors in ductal carcinoma in situ (DCIS) of the breast-relationship to ipsilateral local recurrence and histopathological characteristics., *European journal of cancer*, vol. 37, no. 12, pp. 1514-1522.
- Roberts, M.M., Alexander, F.E., Anderson, T.J., Forrest, A.P., Hepburn, W., Huggins, A., Kirkpatrick, A.E., Lamb, J., Lutz, W. & Muir, B.B. (1984). The Edinburgh randomised trial of screening for breast cancer: description of method., *British journal of cancer*, vol. 50, no. 1, pp. 1-6.
- Rocco, J.W. & Sidransky, D. (2001). p16(MTS-1/CDKN2/INK4a) in cancer progression, *Experimental cell research*, vol. 264, no. 1, pp. 42-55.
- Rody, A., Diallo, R., Poremba, C., Speich, R., Wuelfing, P., Kissler, S., Solbach, C., Kiesel, L. & Jackisch, C. (2004). Estrogen receptor alpha and beta, progesterone receptor, pS2 and HER-2/neu expression delineate different subgroups in ductal carcinoma in situ of the breast., *Oncology reports*, vol. 12, no. 4, pp. 695-699.
- Roger, P., Sahla, M.E., Makela, S., Gustafsson, J.A., Baldet, P. & Rochefort, H. (2001). Decreased expression of estrogen receptor beta protein in proliferative preinvasive mammary tumors., *Cancer research*, vol. 61, no. 6, pp. 2537-2541.
- Rohan, T.E., Hartwick, W., Miller, A.B. & Kandel, R.A. (1998). Immunohistochemical detection of c-erbB-2 and p53 in benign breast disease and breast cancer risk., *Journal of the National Cancer Institute*, vol. 90, no. 17, pp. 1262-1269.
- Ross, J.S. & Fletcher, J.A. (1999). HER-2/neu (c-erb-B2) gene and protein in breast cancer, *American Journal of Clinical Pathology*, vol. 112, no. 1 Suppl 1, pp. S53-67.
- Rudas, M., Neumayer, R., Gnant, M.F., Mittelbock, M., Jakesz, R. & Reiner, A. (1997). p53 protein expression, cell proliferation and steroid hormone receptors in ductal and


- lobular in situ carcinomas of the breast., *European journal of cancer*, vol. 33, no. 1, pp. 39-44.
- Santamaria, G., Velasco, M., Farrus, B., Zanon, G. & Fernandez, P.L. (2008). Preoperative MRI of pure intraductal breast carcinoma--a valuable adjunct to mammography in assessing cancer extent., *Breast*, vol. 17, no. 2, pp. 186-194.
- Sapino, A., Frigerio, A., Peterse, J.L., Arisio, R., Coluccia, C. & Bussolati, G. (2000). Mammographically detected in situ lobular carcinomas of the breast., *Virchows Archiv*, vol. 436, no. 5, pp. 421-430.
- Schnitt, S.J., Silen, W., Sadowsky, N.L., Connolly, J.L. & Harris, J.R. (1988). Ductal carcinoma in situ (intraductal carcinoma) of the breast, *New England Journal of Medicine*, vol. 318, no. 14, pp. 898-903.
- Schoonjans, J.M. & Brem, R.F. (2000). Sonographic appearance of ductal carcinoma in situ diagnosed with ultrasonographically guided large core needle biopsy: correlation with mammographic and pathologic findings., *Journal of Ultrasound in Medicine*, vol. 19, no. 7, pp. 449-457.
- Schwartz, G.F., Solin, L.J., Olivotto, I.A., Ernster, V.L. & Pressman, P.I. (2000). Consensus Conference on the Treatment of In Situ Ductal Carcinoma of the Breast, April 22-25, 1999, *Cancer*, vol. 88, no. 4, pp. 946-954.
- Shaaban, A.M., Jarvis, C., Moore, F., West, C., Dodson, A. & Foster, C.S. (2005). Prognostic significance of estrogen receptor Beta in epithelial hyperplasia of usual type with known outcome., *American Journal of Surgical Pathology*, vol. 29, no. 12, pp. 1593-1599.
- Shaaban, A.M., O'Neill, P.A., Davies, M.P., Sibson, R., West, C.R., Smith, P.H. & Foster, C.S. (2003). Declining estrogen receptor-beta expression defines malignant progression of human breast neoplasia., *American Journal of Surgical Pathology*, vol. 27, no. 12, pp. 1502-1512.
- Shaaban, A.M., Sloane, J.P., West, C.R. & Foster, C.S. (2002). Breast cancer risk in usual ductal hyperplasia is defined by estrogen receptor-alpha and Ki-67 expression., *American Journal of Pathology*, vol. 160, no. 2, pp. 597-604.
- Shapiro, S. (1997). Periodic screening for breast cancer: the HIP Randomized Controlled Trial. Health Insurance Plan., *Journal of the National Cancer Institute*, vol. Monographs, no. 22, pp. 27-30.
- Shoker, B.S., Jarvis, C., Clarke, R.B., Anderson, E., Hewlett, J., Davies, M.P., Sibson, D.R. & Sloane, J.P. (1999). Estrogen receptor-positive proliferating cells in the normal and precancerous breast., *American Journal of Pathology*, vol. 155, no. 6, pp. 1811-1815.
- Shoker, B.S., Jarvis, C., Clarke, R.B., Anderson, E., Munro, C., Davies, M.P., Sibson, D.R. & Sloane, J.P. (2000). Abnormal regulation of the oestrogen receptor in benign breast lesions., *Journal of clinical pathology*, vol. 53, no. 10, pp. 778-783.
- Sickles E.A. (1983). Sonographic detectability of breast calcifications., *Proceedings of SPIE*, vol. 419, pp. 51-52
- Silverstein, M.J., Cohan, B.F., Gierson, E.D., Furmanski, M., Gamagami, P., Colburn, W.J., Lewinsky, B.S. & Waisman, J.R. (1992). Duct carcinoma in situ: 227 cases without microinvasion., *European journal of cancer*, vol. 28, no. 2-3, pp. 630-634.

- Silverstein, M.J., Recht, A., Lagios, M.D., Bleiweiss, I.J., Blumencranz, P.W., Gizienski, T., Harms, S.E., Harness, J., Jackman, R.J., Klimberg, V.S., Kuske, R., Levine, G.M., Linver, M.N., Rafferty, E.A., Rugo, H., Schilling, K., Tripathy, D., Vicini, F.A., Whitworth, P.W. & Willey, S.C. (2009). Special report: Consensus conference III. Image-detected breast cancer: state-of-the-art diagnosis and treatment, *Journal of the American College of Surgeons*, vol. 209, no. 4, pp. 504-520.
- Simooka, H., Oyama, T., Sano, T., Horiguchi, J. & Nakajima, T. (2004). Immunohistochemical analysis of 14-3-3 sigma and related proteins in hyperplastic and neoplastic breast lesions, with particular reference to early carcinogenesis., *Pathology international*, vol. 54, no. 8, pp. 595-602.
- Siziopikou, K.P., Prioleau, J.E., Harris, J.R. & Schnitt, S.J. (1996). bcl-2 expression in the spectrum of preinvasive breast lesions., *Cancer*, vol. 77, no. 3, pp. 499-506.
- Slanetz, P.J., Giardino, A.A., Oyama, T., Koerner, F.C., Halpern, E.F., Moore, R.H. & Kopans, D.B. (2001). Mammographic appearance of ductal carcinoma in situ does not reliably predict histologic subtype., *Breast Journal*, vol. 7, no. 6, pp. 417-421.
- Smith, G.L., Smith, B.D. & Haffty, B.G. (2006). Rationalization and regionalization of treatment for ductal carcinoma in situ of the breast., *International journal of radiation oncology, biology, physics*, vol. 65, no. 5, pp. 1397-1403.
- Sneige, N., Wang, J., Baker, B.A., Krishnamurthy, S. & Middleton, L.P. (2002). Clinical, histopathologic, and biologic features of pleomorphic lobular (ductal-lobular) carcinoma in situ of the breast: a report of 24 cases., *Modern Pathology*, vol. 15, no. 10, pp. 1044-1050.
- Stark, A., Hulka, B.S., Joens, S., Novotny, D., Thor, A.D., Wold, L.E., Schell, M.J., Melton, L.J., 3rd, Liu, E.T. & Conway, K. (2000). HER-2/neu amplification in benign breast disease and the risk of subsequent breast cancer., *Journal of Clinical Oncology*, vol. 18, no. 2, pp. 267-274.
- Stomper, P.C., Connolly, J.L., Meyer, J.E. & Harris, J.R. (1989). Clinically occult ductal carcinoma in situ detected with mammography: analysis of 100 cases with radiologic-pathologic correlation., *Radiology*, vol. 172, no. 1, pp. 235-241.
- Tabar, L., Vitak, B., Chen, H.H., Duffy, S.W., Yen, M.F., Chiang, C.F., Krusemo, U.B., Tot, T. & Smith, R.A. (2000). The Swedish Two-County Trial twenty years later. Updated mortality results and new insights from long-term follow-up., *Radiologic clinics of North America*, vol. 38, no. 4, pp. 625-651.
- Tavassoli, F.A. (2008). Lobular and ductal intraepithelial neoplasia, *Pathologie*, vol. 29, no. Suppl 2, pp. 107-111.
- Tavassoli, F.A., Hoeffler H, Rosai J et al. 2003 Intraductal proliferative lesions In: Tavassoli F.A., Devilee P (eds) World Health Organization Classification of Tumors: Pathology and genetics of Tumor of the breast and the female genital organs IARC Press, Lyon pp 65-66
- Toledo, F. & Wahl, G.M. (2006). Regulating the p53 pathway: in vitro hypotheses, in vivo veritas, *Nature Reviews.Cancer*, vol. 6, no. 12, pp. 909-923.
- Tsuda, H. & Hirohashi, S. (1998). Multiple developmental pathways of highly aggressive breast cancers disclosed by comparison of histological grades and c-erbB-2

- expression patterns in both the non-invasive and invasive portions., *Pathology international*, vol. 48, no. 7, pp. 518-525.
- Tsuda, H., Iwaya, K., Fukutomi, T. & Hirohashi, S. (1993). p53 mutations and c-erbB-2 amplification in intraductal and invasive breast carcinomas of high histologic grade., *Japanese Journal of Cancer Research*, vol. 84, no. 4, pp. 394-401.
- Umbricht, C.B., Evron, E., Gabrielson, E., Ferguson, A., Marks, J. & Sukumar, S. (2001). Hypermethylation of 14-3-3 sigma (stratifin) is an early event in breast cancer., *Oncogene*, vol. 20, no. 26, pp. 3348-3353.
- van Delft, M.F. & Huang, D.C. (2006). How the Bcl-2 family of proteins interact to regulate apoptosis, *Cell research*, vol. 16, no. 2, pp. 203-213.
- Van Zee, K.J., Calvano, J.E. & Bisogna, M. (1998). Hypomethylation and increased gene expression of p16INK4a in primary and metastatic breast carcinoma as compared to normal breast tissue., *Oncogene*, vol. 16, no. 21, pp. 2723-2727.
- Viacava, P., Naccarato, A.G. & Bevilacqua, G. (1999). Different proliferative patterns characterize different preinvasive breast lesions., *Journal of Pathology*, vol. 188, no. 3, pp. 245-251.
- Viacava, P., Naccarato, A.G., Bocci, G., Fanelli, G., Aretini, P., Lonobile, A., Evangelista, G., Montruccoli, G. & Bevilacqua, G. (2004). Angiogenesis and VEGF expression in pre-invasive lesions of the human breast., *Journal of Pathology*, vol. 204, no. 2, pp. 140-146.
- Virnig, B.A., Tuttle, T.M., Shamliyan, T. & Kane, R.L. (2010). Ductal carcinoma in situ of the breast: a systematic review of incidence, treatment, and outcomes, *Journal of the National Cancer Institute*, vol. 102, no. 3, pp. 170-178.
- Vogelstein, B., Lane, D. & Levine, A.J. (2000). Surfing the p53 network., *Nature*, vol. 408, no. 6810, pp. 307-310.
- Vogl, G., Dietze, O. & Hauser-Kronberger, C. (2005). Angiogenic potential of ductal carcinoma in situ (DCIS) of human breast., *Histopathology*, vol. 47, no. 6, pp. 617-624.
- Vos, C.B., Cleton-Jansen, A.M., Berx, G., de Leeuw, W.J., ter Haar, N.T., van Roy, F., Cornelisse, C.J., Peterse, J.L. & van de Vijver, M.J. (1997). E-cadherin inactivation in lobular carcinoma in situ of the breast: an early event in tumorigenesis., *British journal of cancer*, vol. 76, no. 9, pp. 1131-1133.
- Wakefield, L.M., Piek, E. & Bottinger, E.P. (2001). TGF-beta signaling in mammary gland development and tumorigenesis, *Journal of Mammary Gland Biology & Neoplasia*, vol. 6, no. 1, pp. 67-82.
- Walker, R.A. & Dearing, S.J. (1992). Transforming growth factor beta 1 in ductal carcinoma in situ and invasive carcinomas of the breast., *European journal of cancer*, vol. 28, no. 2-3, pp. 641-644.
- Warren, J.L., Weaver, D.L., Bocklage, T., Key, C.R., Platz, C.E., Cronin, K.A., Ballard-Barbash, R., Willey, S.C. & Harlan, L.C. (2005). The frequency of ipsilateral second tumors after breast-conserving surgery for DCIS: a population based analysis., *Cancer*, vol. 104, no. 9, pp. 1840-1848.
- Winchester, D.P. & Strom, E.A. (1998). Standards for diagnosis and management of ductal carcinoma in situ (DCIS) of the breast. American College of Radiology. American

- College of Surgeons. College of American Pathologists. Society of Surgical Oncology, *CA: a Cancer Journal for Clinicians*, vol. 48, no. 2, pp. 108-128.
- Wrensch, M.R., Petrakis, N.L., Miike, R., King, E.B., Chew, K., Neuhaus, J., Lee, M.M. & Rhys, M. (2001). Breast cancer risk in women with abnormal cytology in nipple aspirates of breast fluid., *Journal of the National Cancer Institute*, vol. 93, no. 23, pp. 1791-1798.
- Xu, R., Perle, M.A., Inghirami, G., Chan, W., Delgado, Y. & Feiner, H. (2002). Amplification of Her-2/neu gene in Her-2/neu-overexpressing and -nonexpressing breast carcinomas and their synchronous benign, premalignant, and metastatic lesions detected by FISH in archival material., *Modern Pathology*, vol. 15, no. 2, pp. 116-124.
- Yi, M., Krishnamurthy, S., Kuerer, H.M., Meric-Bernstam, F., Bedrosian, I., Ross, M.I., Ames, F.C., Lucci, A., Hwang, R.F. & Hunt, K.K. (2008). Role of primary tumor characteristics in predicting positive sentinel lymph nodes in patients with ductal carcinoma in situ or microinvasive breast cancer., *American Journal of Surgery*, vol. 196, no. 1, pp. 81-87.
- Younes, M., Lebovitz, R.M., Bommer, K.E., Cagle, P.T., Morton, D., Khan, S. & Laucirica, R. (1995). p53 accumulation in benign breast biopsy specimens., *Human pathology*, vol. 26, no. 2, pp. 155-158.

IntechOpen



Intraepithelial Neoplasia

Edited by Dr. Supriya Srivastava

ISBN 978-953-307-987-5

Hard cover, 454 pages

Publisher InTech

Published online 08, February, 2012

Published in print edition February, 2012

The book "Intraepithelial neoplasia" is till date the most comprehensive book dedicated entirely to preinvasive lesions of the human body. Created and published with an aim of helping clinicians to not only diagnose but also understand the etiopathogenesis of the precursor lesions, the book also attempts to identify its molecular and genetic mechanisms. All of the chapters contain a considerable amount of new information, with an updated bibliographical list as well as the latest WHO classification of intraepithelial lesions that has been included wherever needed. The text has been updated according to the latest technical advances. This book can be described as concise, informative, logical and useful at all levels discussing thoroughly the invaluable role of molecular diagnostics and genetic mechanisms of the intraepithelial lesions. To make the materials easily digestible, the book is illustrated with colorful images.

How to reference

In order to correctly reference this scholarly work, feel free to copy and paste the following:

Simonetta Monti and Andres Del Castillo (2012). Intraepithelial Neoplasia of Breast, Intraepithelial Neoplasia, Dr. Supriya Srivastava (Ed.), ISBN: 978-953-307-987-5, InTech, Available from:
<http://www.intechopen.com/books/intraepithelial-neoplasia/intraepithelial-neoplasia-of-breast>

INTeCH
open science | open minds

InTech Europe

University Campus STeP Ri
Slavka Krautzeka 83/A
51000 Rijeka, Croatia
Phone: +385 (51) 770 447
Fax: +385 (51) 686 166
www.intechopen.com

InTech China

Unit 405, Office Block, Hotel Equatorial Shanghai
No.65, Yan An Road (West), Shanghai, 200040, China
中国上海市延安西路65号上海国际贵都大饭店办公楼405单元
Phone: +86-21-62489820
Fax: +86-21-62489821

© 2012 The Author(s). Licensee IntechOpen. This is an open access article distributed under the terms of the [Creative Commons Attribution 3.0 License](https://creativecommons.org/licenses/by/3.0/), which permits unrestricted use, distribution, and reproduction in any medium, provided the original work is properly cited.

IntechOpen

IntechOpen