

We are IntechOpen, the world's leading publisher of Open Access books Built by scientists, for scientists

6,900

Open access books available

186,000

International authors and editors

200M

Downloads

Our authors are among the

154

Countries delivered to

TOP 1%

most cited scientists

12.2%

Contributors from top 500 universities



WEB OF SCIENCE™

Selection of our books indexed in the Book Citation Index
in Web of Science™ Core Collection (BKCI)

Interested in publishing with us?
Contact book.department@intechopen.com

Numbers displayed above are based on latest data collected.
For more information visit www.intechopen.com



Treatment Strategy for Recurrent Hepatocellular Carcinoma

Charing Ching Ning Chong and Paul Bo San Lai

*Division of Hepato-Biliary and Pancreatic Surgery, Department of Surgery
Prince of Wales Hospital, the Chinese University of Hong Kong
Hong Kong, SAR*

1. Introduction

Hepatocellular carcinoma is an important malignancy of global significance. It is the seventh commonest cancer and the fourth leading cause of cancer deaths worldwide (GLOBOCAN, 2008). While hepatectomy remains to be the gold standard for treating HCC, long-term prognosis after curative resection remains unsatisfactory with high incidence of recurrence. The reported cumulative 5-year recurrence rate after curative partial hepatectomy averages above 70% in both Eastern and Western centers and the remnant liver is the commonest site of recurrence (Chong et al., 2011; Ercolani et al., 2003; Poon et al., 2001; Yeh et al., 2002).

Intra-hepatic metastasis from the primary resected tumor and multicentric occurrence of a new tumor in the liver remnant are the two major patterns of intra-hepatic recurrence of HCC. In general, intrahepatic metastasis represented early recurrence (within 1 year after hepatectomy) and is associated with the vascular invasion and the subsequent intrahepatic venous spread while multicentric occurrence is associated with the underlying liver status and represented late recurrence (Jwo et al., 1992; Matsumata et al., 1989; Yamamoto et al., 1998). Although the exact mechanism has not been clarified, many studies had shown that late recurrence was associated with a better survival than early recurrence (Poon et al., 1999; Poon et al., 2000; Shimada et al., 1996).

Appropriate treatment for intrahepatic recurrence is crucial in improving long-term outcome after initial hepatectomy. Increased survival rates after aggressive treatment of post-resection HCC recurrence have been reported (Itamoto et al., 2007; Matsuda et al., 2001; Sugimachi et al., 2001; Tralhao et al., 2007; Wu et al., 2009; Zhou et al., 2010). Currently, various therapeutic modalities such as repeat hepatectomy, local ablation therapy and transcatheter arterial chemoembolization (TACE) have been used to treat recurrent HCC. However, there is no standard strategy for selection among different modalities so far.

2. Treatment options for recurrent HCC

2.1 Liver transplantation

Theoretically, liver transplantation would be the optimal treatment for HCC within Milan criteria as it allows radical resection of the tumor together correction of the underlying liver cirrhosis. However, due to the shortage in organ supply and long waiting time,

recommending liver transplantation as the standard treatment for recurrent HCC deems logistically impractical.

2.2 Re-hepatectomy

Repeat hepatic resection has been widely recognised as one of the most effective treatments for intra-hepatic recurrent HCC compared to other therapeutic modalities (Chen et al., 2004; Itamoto et al., 2007; Minagawa et al., 2003; Sugimachi et al., 2001; Tralhao et al., 2007; Wu et al., 2009; Zhou et al., 2010). It should be the treatment of choice in suitable patients with preserved liver function and functional status. The safety and long-term results of repeated resection has been well-established, with operative mortality rates ranging from 0% to 8.5% and the reported cumulative 5-year survival rate after a second hepatectomy was comparable to the survival after initial hepatectomy for primary HCC (Aeii et al., 1998; Farges et al., 1998; Hu et al., 1996; Itamota et al., 2000; Kakazu et al., 1993; Matsuda Y et al., 1993; Minagawa et al., 2003; Nagano et al., 2009; Nagasue et al., 1996; Poon et al., 1999; Shimada et al., 1996, 1998; Suenaga M et al., 1994; Sugimachi et al., 2001; Zhou et al., 2010).

In a recent systemic review where studies reporting in at least 10 patients are included, Zhou et al analysed 29 studies of repeat hepatectomy for recurrent HCC with a curative intent (Zhou et al., 2010). A total of 1149 patients underwent repeat hepatectomy for recurrent HCC and the rate of repeat hepatectomy ranged from 8.7% to 44%. The median or mean operating time ranged from 136 to 365 minutes and the median or mean estimated blood loss ranged from 211 to 1980 ml. Majority of patients received minor resection at the time of repeat resection. The reported ranges of the 1-, 3- and 5-year survival were 69% to 100%, 21% to 87% and 25% to 87% respectively.

These results may support the use of repeat resection for recurrent HCC. Moreover, it is noteworthy that the rate of extra-hepatic spread after hepatic resection is low. The reported incidence of extra-hepatic metastases after primary liver resection was 5% to 20% while that after second resection was almost the same (Belghiti et al., 1991; Bismuth et al., 1995; Kosuge et al., 1993; Makuuchi et al., 1998). Nevertheless, repeat resection is technically demanding and difficult due to possible adhesions between the raw liver surface and the surrounding organs, distortion and anatomical disorientation caused by the rotation of liver remnant as a result of regeneration and limited liver reserve after previous resection (Figure. 1).

So far, no consensus has been reached for the standard selection criteria for re-hepatectomy. In general, patients with good performance status and adequate liver functional reserve could be selected for re-hepatectomy if oncological clearance can be achieved (Zhou et al., 2010). The main consideration remains the probability of patients developing post-hepatectomy liver failure.

An important finding reported by the Japanese groups is that the overall survival after second hepatectomy was significantly poorer in patients who recurred within 1 year after first hepatectomy than those who recurred more than 1 year after initial operation (Minagawa et al., 2003; Nagano et al., 2009). The authors postulated that many of these cases of early recurrence might be a result of intrahepatic metastasis from primary HCC and hence, associated with a poorer outcome. As a result, Minagawa et al, after reviewed 67 patients received repeated hepatectomy for recurrent HCC, concluded that a disease-

free interval of more than 1 year after primary hepatectomy, single HCC at primary resection, and negative portal vein invasion at repeated resection were favourable prognostic factors after repeated resection with excellent 3- and 5-year survival rates of 100% and 86% respectively. They, therefore, recommended these patients should be indicated for repeat resection even if they have undergone major hepatic resection as the primary hepatectomy as long as the liver function can be preserved (Minagawa et al., 2003).

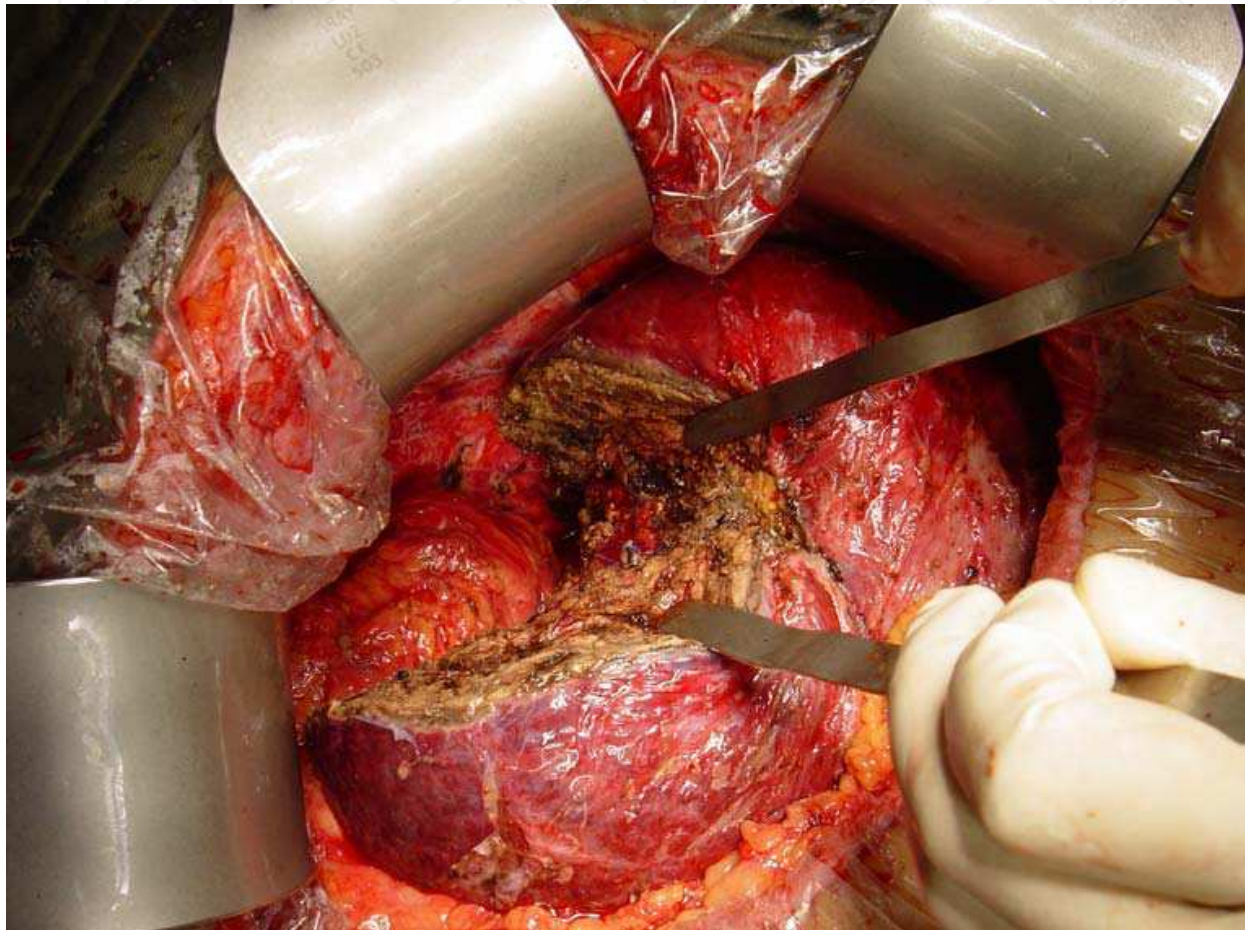


Fig. 1. Intra-operative picture of a patient who underwent right posterior sectionectomy for a recurrent HCC at segment VIII. Multiple adhesions over liver surface were also showed.

The good results from repeat hepatectomy should be interpreted with caution as patients selected for repeat hepatectomy were usually patients with better prognosis, e.g. better liver reserve and smaller tumours.

Recently, laparoscopic hepatectomy is well accepted as a safe and feasible treatment for primary HCC in selected patients with similar result to the open approach (Lee et al., 2007; Vignano et al., 2009). It is recommended for peripheral lesion requiring limited hepatectomy or left lateral sectionectomy (Lee et al., 2011; Vignano et al., 2009). Feasibility of repeat laparoscopic liver resection in recurrent HCC had been reported (Belli et al., 2009; Cheung et al., 2010; Hu et al., 2011; Liang et al., 2009). However, all these reports only focused on the technical aspects and the short-term outcomes. The importance of careful patient selection should be emphasized when considering laparoscopic re-resection and it should only be

done by surgeons who are highly experienced in both laparoscopic and open hepatic surgeries.

2.3 Local ablation therapies

Tumor ablation is defined as the direct application of chemical or thermal therapies to a tumor to achieve eradication or substantial tumor destruction. Although repeat hepatectomy is the most effective treatment for recurrent HCC, impaired liver function and the presence of multicentric tumours often precludes repeat hepatectomy in more than 80% of patients with recurrent HCC (Arii, et al. 1998; Kakazu et al., 1993; Lu et al., 2005; Minagawa et al., 2003; Poon et al., 1999; Shimada et al., 1996; Suenaga et al., 1993). Local ablative therapies have been increasingly used to treat recurrent HCC. They are particularly suitable for treatment of recurrent HCC as recurrence can usually be detected at an early stage on the surveillance imaging after hepatectomy while the nodules are still small.

Radiofrequency ablation (RFA), microwave coagulation therapy (MCT) and percutaneous ethanol injection (PEI) are the three most commonly used local ablative treatment modalities for treatment of small primary HCC. Reports on the use of PEI in treating HCC recurrence are scarce. Both RFA and MCT can be applied percutaneously, laparoscopically, or at open surgery. From the experience in treating primary HCC, RFA and MCT are able to destroy bigger tumor up to 6cm or 7cm in diameter and require fewer treatment sessions than PEI and are therefore gaining attention as a valuable treatment options for ablating recurrent HCC (Goldberg & Gazelle, 2001; Ikeda et al., 2001; Livraghi et al., 1999; Lu et al., 2001; Seki et al., 1999). Currently, most of the currently available results on local ablative therapy for recurrent HCC were using RFA.

2.3.1 Radiofrequency ablation (RFA)

RFA is a thermo-ablative technique, which works by using a high-frequency alternating current applied via electrodes placed within the tissue to induce temperatures changes and generate areas of coagulative necrosis and tissue desiccation. RFA has been increasingly used to treat small primary or recurrent HCC (<5cm) in patients with poor liver reserve (Lau & Lai, 2009). High complete ablation rate (over 90%) and long-term survival comparable to those achieved by hepatectomy have been reported by cohort studies on RFA to treat recurrent HCC after partial hepatectomy. The reported 3-year survival rate averaged above 60% and the 5-year overall survival rate ranged from 18%-51.6% (Camma et al., 2005; Chen et al., 2006; Choi et al., 2007; Lu et al., 2005; Poon et al., 2002; Tateishi et al., 2005; Taura K et al., 2006; Yang et al., 2006).

Besides the good results it achieves, RFA also has a few advantages over the repeat hepatectomy. First of all, it can be used in patients with poor liver function who might not be able to tolerate a repeat hepatectomy. Being a minimally invasive technique, RFA can be applied percutaneously in suitable patients and avoid the risk associated with general anesthesia and laparotomy (Figure. 2). Furthermore, RFA can be applied repeatedly for repeated treatment of recurrence. It is particularly important since in the background of liver cirrhosis, HCC tends to recur repeatedly and repeated treatment may be necessary. Hence, treatment with minimal damage to the non-tumoral hepatic parenchyma may be more preferable.

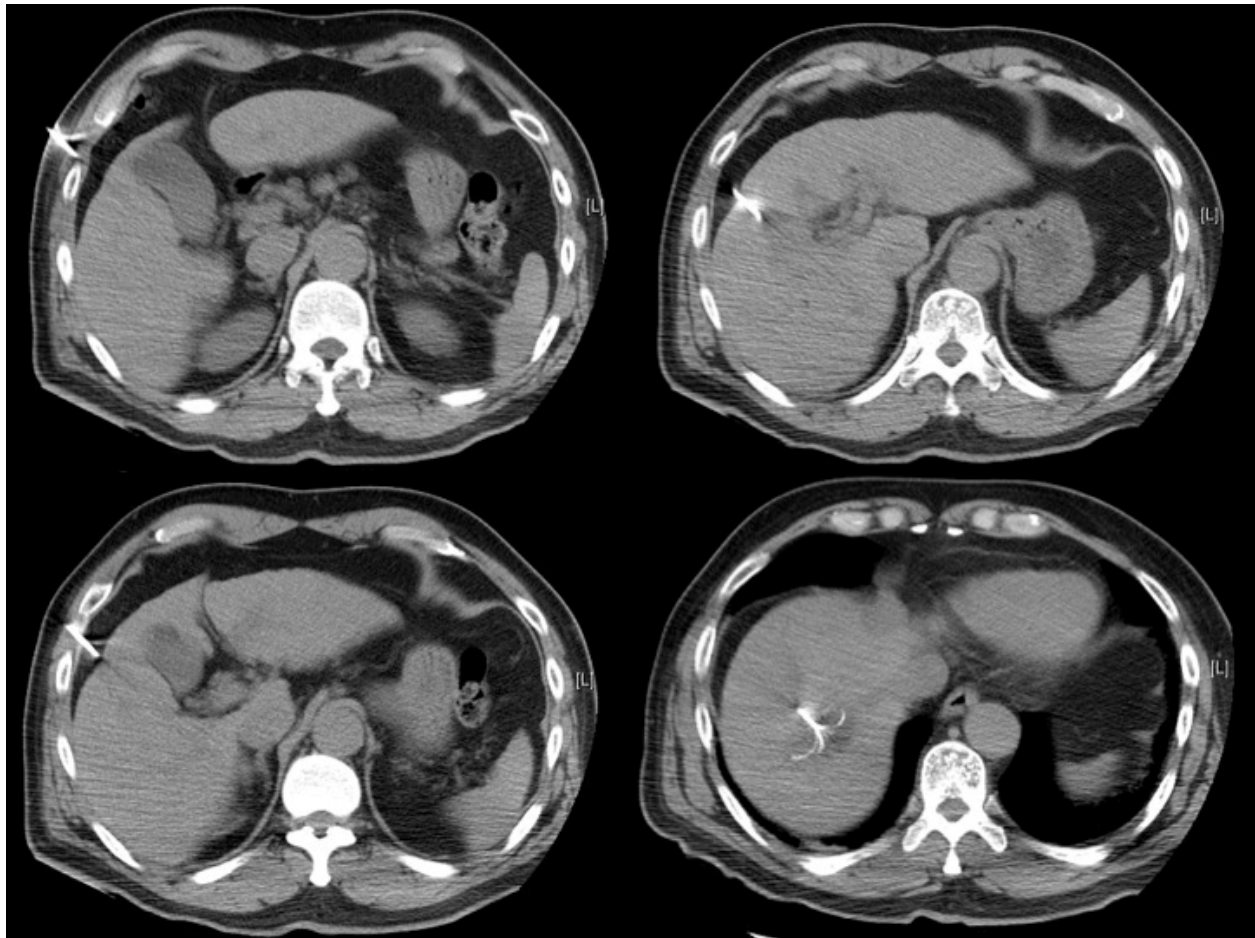
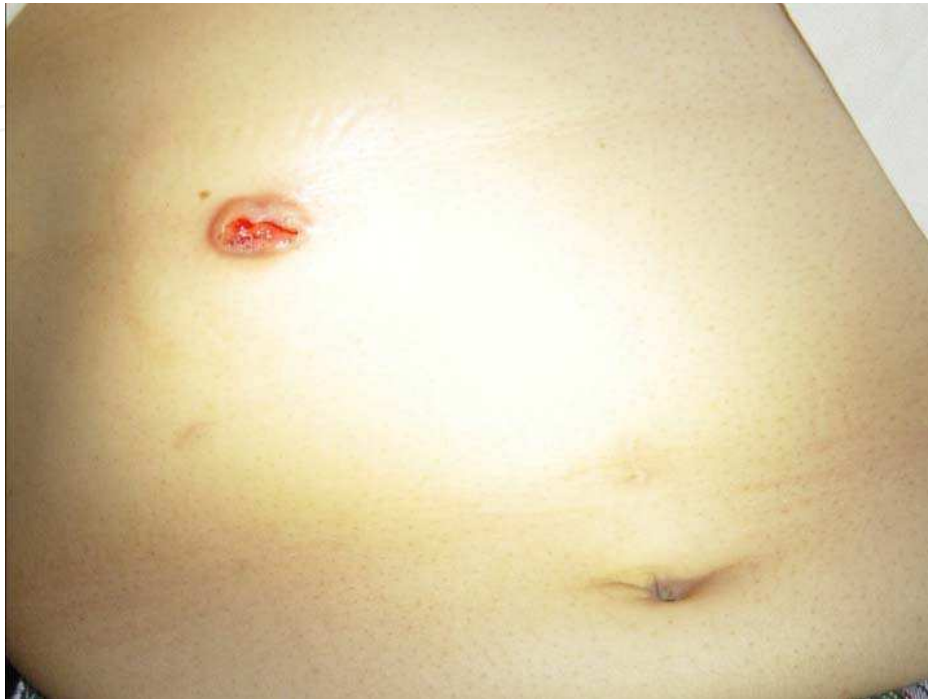

Fig. 2. CT image of a CT-guided percutaneous RFA of a segment VIII recurrent HCC which was performed under local anaesthesia.

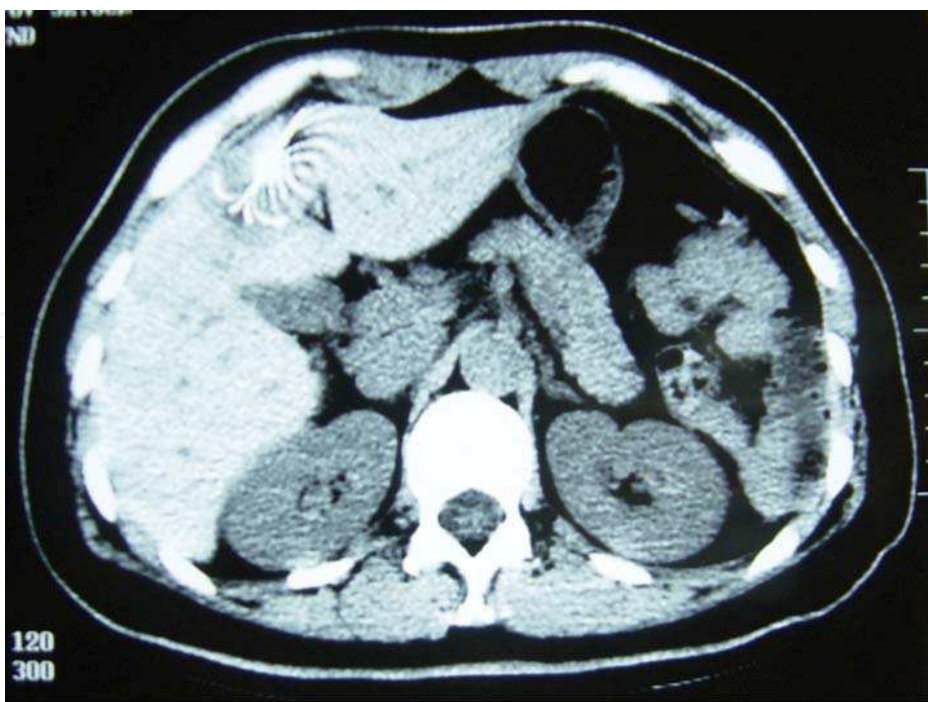Liang et al compared the long-term survival outcomes of percutaneous RFA and repeat partial hepatectomy for recurrent HCC (Liang et al., 2009). They found that there was no significant difference in the overall survival of patients with recurrent HCC treated by repeat hepatectomy or RFA while RFA had the advantage over hepatectomy in being less invasive and causing fewer treatment-related morbidities. The authors attempted to make the baseline demographics in two arms comparable by using the same selection criteria to identify patients received repeat hepatectomy and percutaneous RFA in order to minimize the selection bias. The criteria included fewer than three recurrent tumours with the largest one less than 5cm, no radiological evidence of venous invasion, no extrahepatic metastases, no severe liver dysfunction (Child-Pugh class C), no significant coagulopathy, and no history of encephalopathy, refractory ascites or variceal bleeding.

Of note, as in repeat hepatectomy, the benefit of RFA was more promising for patients with a longer disease-free interval from hepatectomy (Liang et al., 2009; Yang et al., 2006). Yang et al studied 41 patients with 76 recurrent HCC who received percutaneous RFA after hepatectomy. Early and late recurrences were defined as recurrence that occurred within 1 year and after 1 year respectively (Yang et al., 2006). The late-recurrence group had a significantly longer overall survival than the early-recurrence group (mean overall survival 42.9 months *versus* 16.4 months).

Needle tract dissemination is one of the major complications of great concern in percutaneous ablations. (Figure. 3) In a phase II study assessing the treatment-related complications and response rate of RFA in 32 patients by Llovet et al reported that the incidence of needle tract dissemination after radiofrequency ablation was as high as 12.5% (Llovet et al., 2001).



(a)



(b)

Fig. 3. Patient with metastasis at the needle tract (a) after underwent CT-guided RFA for HCC (b).

2.3.2 Microwave Coagulation Therapy (MCT)

Initially developed for intra-operative haemostasis during hepatectomy, MCT has now developed as a new ablative therapy for treatment of HCC with high ablation rate, even for tumor with wider diameters, rapid ablation time and low morbidity and mortality rates and minimal heat sink effect (Itoch et al., 2011; Lloyd et al., 2011) (Figure. 4 & 5).

MCT works by agitating water molecules in the surrounding tissue and producing friction and heat, hence inducing cellular death via coagulative necrosis (Simon et al., 2005) (Figure. 5). Although reports on the efficacy of MCT in primary HCC are numerous, results of MCT on recurrent HCC are limited. Boutros et al reported their experience with MCT in 60 patients with unresectable HCC (Boutros et al., 2010). Complete ablations were achieved in 57 of the 60 patients (95%) judged by contrast-enhanced CT carried out 1-2 weeks after procedure and 1-2 months after discharge. However, 39 of the 60 patients (65%) had recurrence and 7 (11.6%) had local recurrence resulting in a low recurrence-free survival. Among these 60 patients, 45 had recurrent HCC. The reported 1- and 3-year recurrence-free survival rates of the patients who underwent MCT for recurrent HCC were 41.6% and 8.8% respectively.

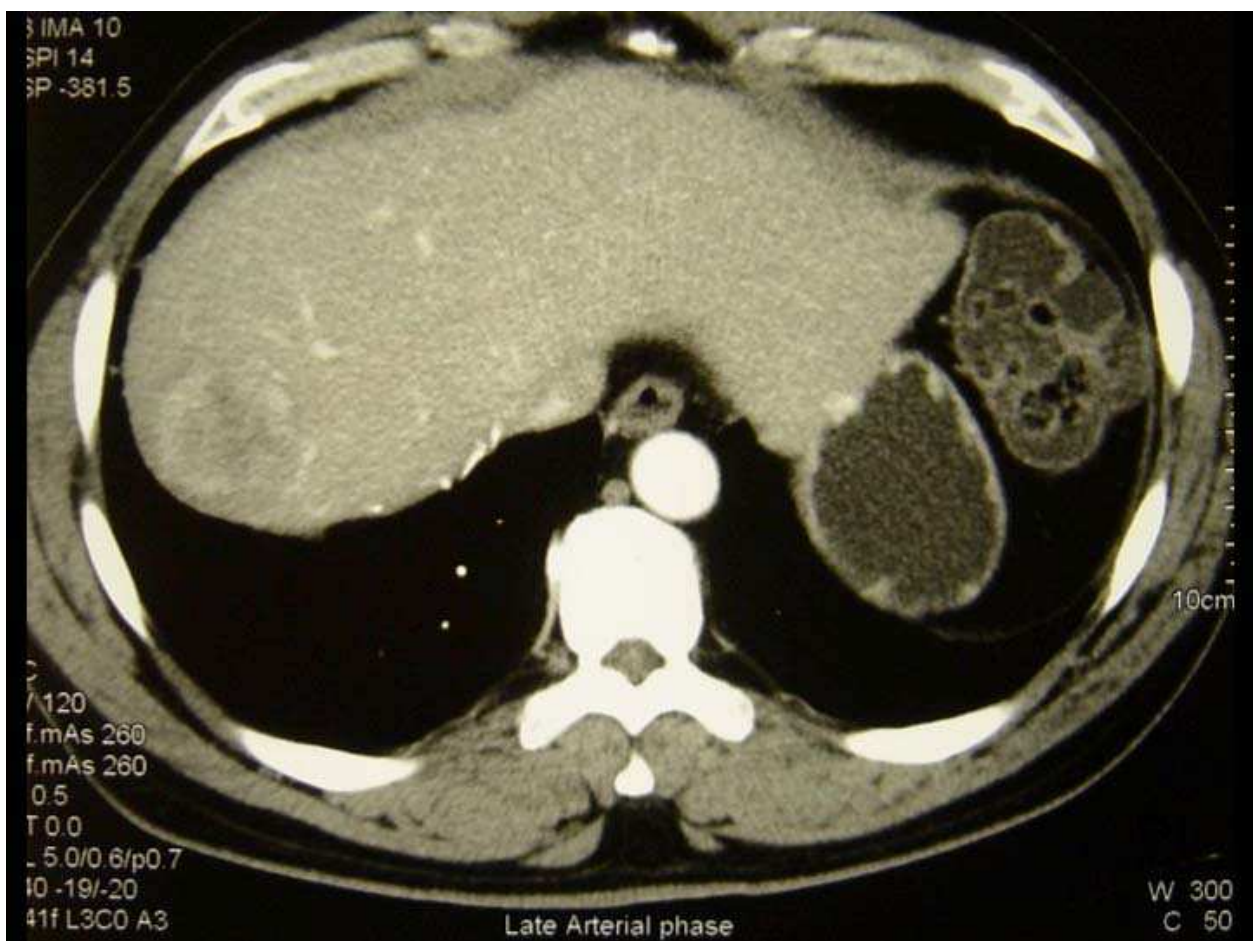


Fig. 4a. Pre-operative CT image of a recurrent HCC at segment VIII of liver.

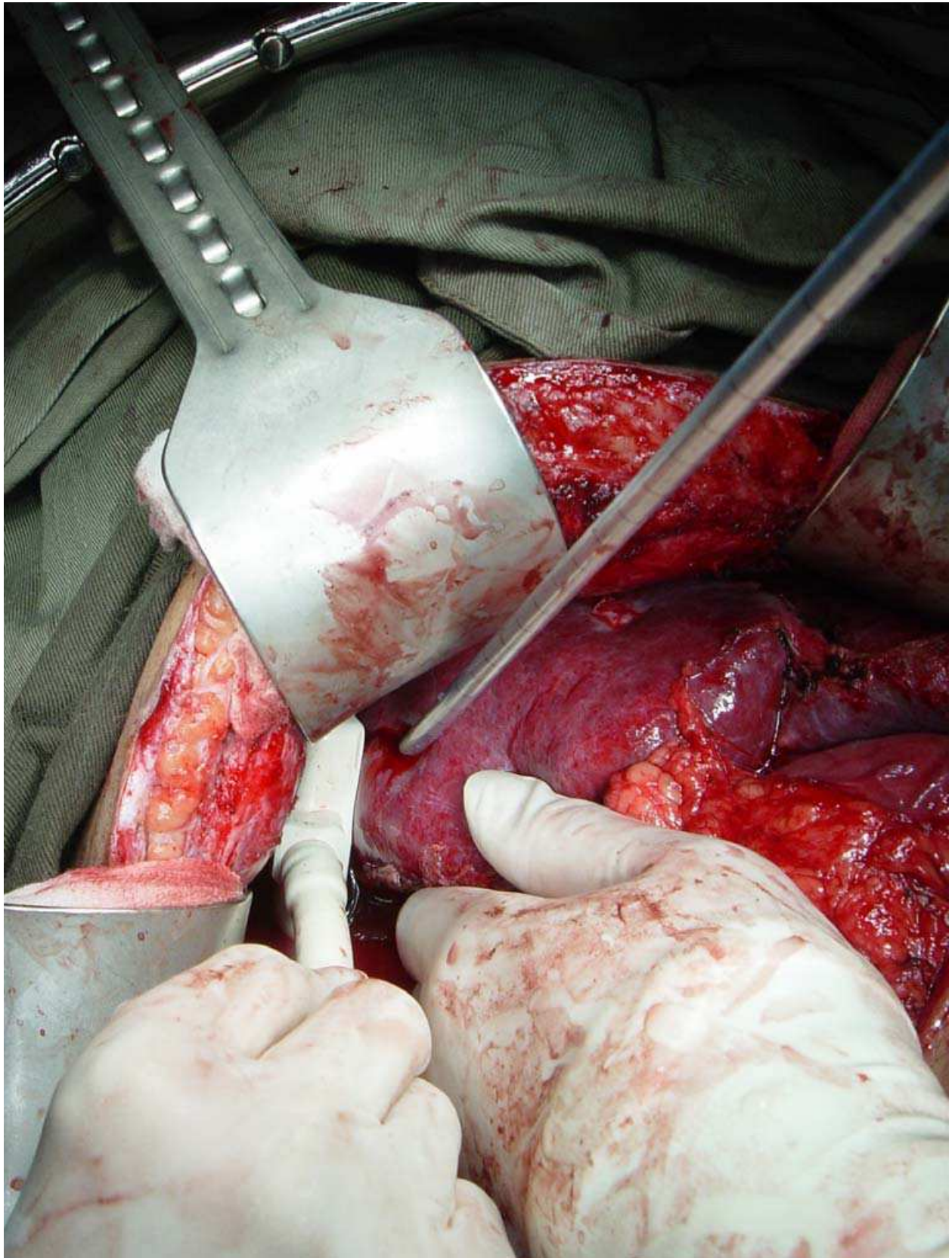


Fig. 4b. Open MCT for segment VIII recurrence guided by operative USG.

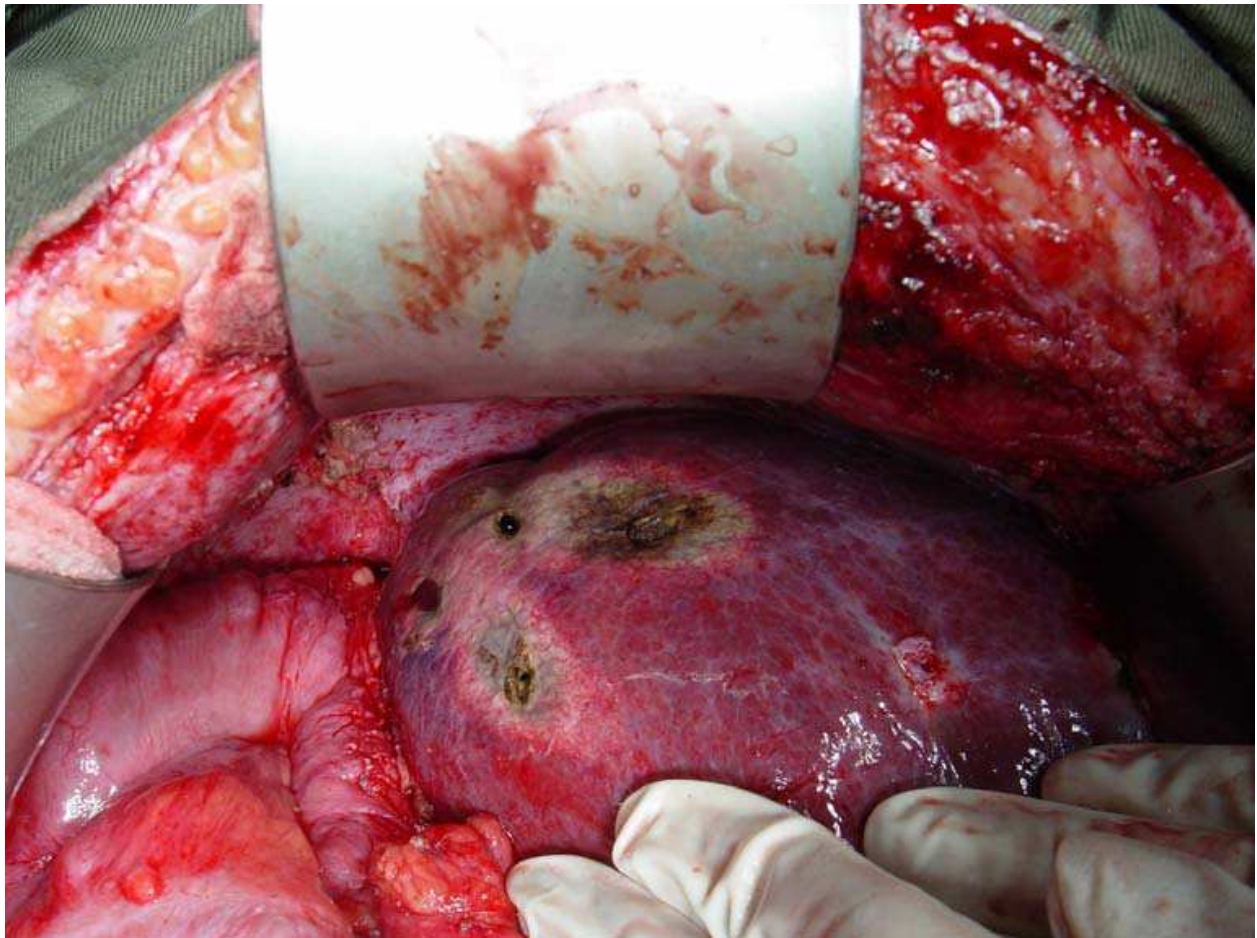


Fig. 4c. Segment VIII tumor after open MCT ablation.

Several studies compared RFA to MCT in treating hepatic tumour (Lu et al., 2005; Ogata et al., 2008; Ohmoto & Yamamoto, 2006; Shibata et al., 2002; Xu et al., 2005). Most of them failed to detect a superiority of one over another. With the currently available evidence, MCT is a safe and effective treatment for HCC. However, further prospective studies with long-term results are needed in order to confirm its role in treatment of recurrent HCC and its performance compared to RFA or liver resection.

2.4 Transarterial therapies

Hepatic flow to the hepatocellular carcinoma and liver parenchyma has a very unique pattern. Typical hepatocarcinoma nodules are highly vascularized with arterial afferents originating from the hepatic artery, whereas the hepatic parenchymal flow is largely derived from the portal vein. This forms the basis of the transarterial therapies.

2.4.1 Transarterial Chemoembolization (TACE)

Despite the results from repeat hepatic resection for intra-hepatic recurrence was well recognised, the re-resection rate is low because of the impairment of functional reserve in the liver remnant and multiplicity of nodules (Eguchi et al., 2006; Kanematsu et al., 1984; Poon et al., 2002). Local ablation should be best performed in patients with recurrences

featuring three or fewer small nodules (Shimada et al., 2007). In contrast, transarterial chemoembolization (TACE) can be applied in any type of HCC, irrespective of tumor size, location, or number of lesions provided that patients have reasonable liver function. In addition, the benefit of TACE on survival in patients with unresectable HCC had already been demonstrated (Llovet & Bruix, 2003; Shim et al., 2009). Therefore, TACE is widely applicable and practical in patients with intra-hepatic HCC recurrence (Choi et al., 2009; Eguchi et al., 2008; Shim et al., 2010).

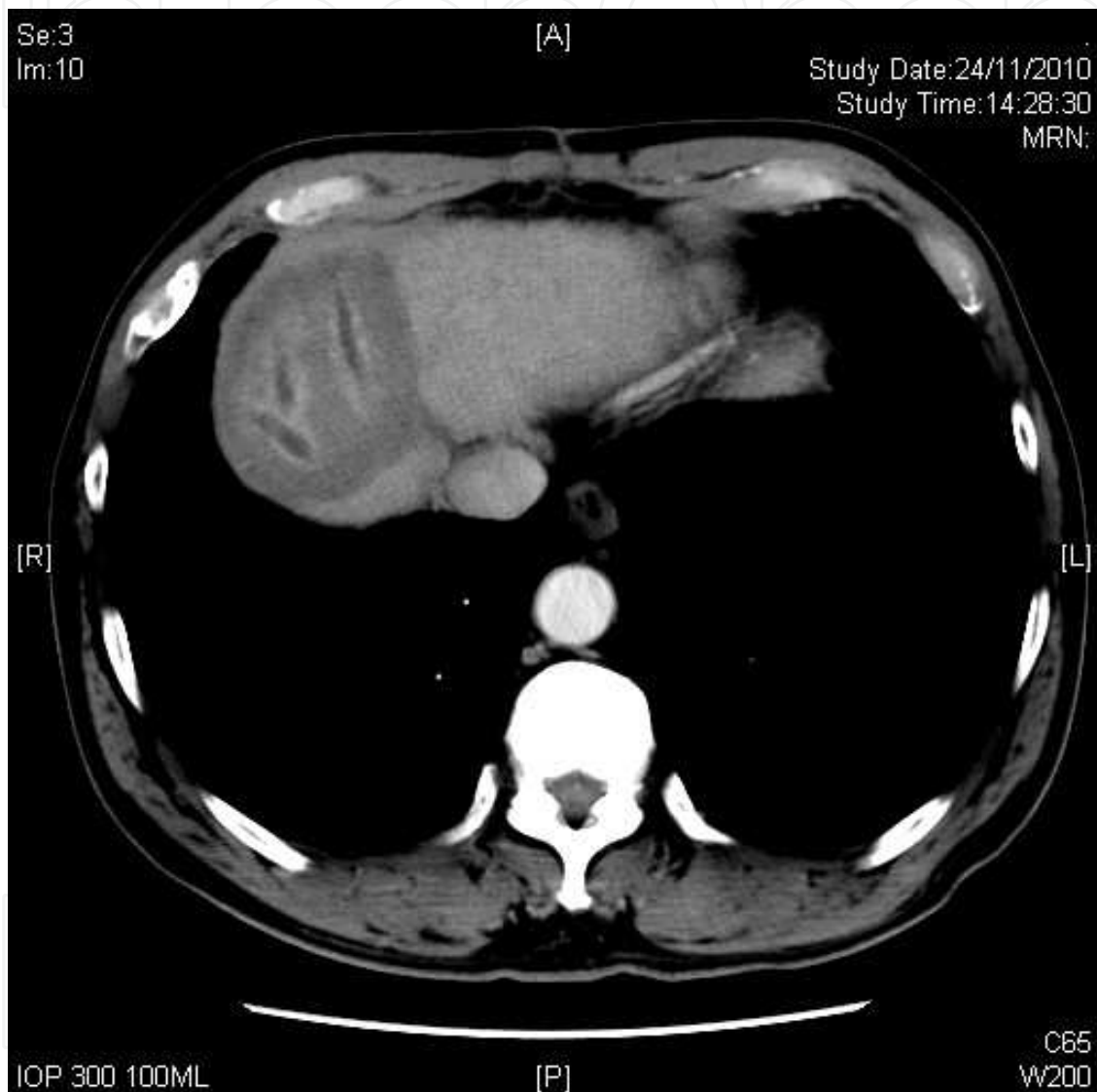


Fig. 5. CT image of a patient with a 5cm segment VIII recurrent HCC at 6 months after microwave ablation. Three passes were performed for a bigger ablative zone and the needle tracts were showed on the follow up scan.

TACE is the intra-arterial administration of chemotherapy combined with arterial embolization and is commonly used as an alternate treatment for recurrent HCC (Figure. 6). There is no standardized protocol in the optimal time interval between treatments and also the choice, dosage, concentration, rate of injection of the chemotherapeutic and the embolizing agents.

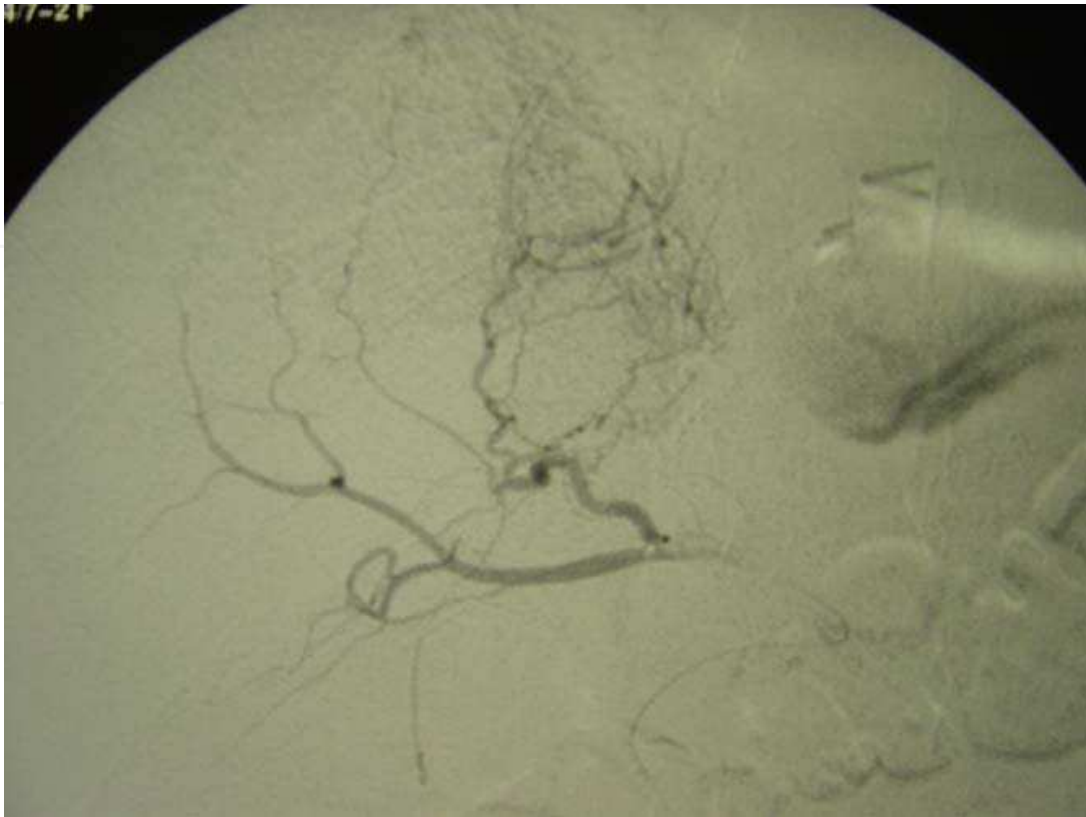


Fig. 6a. Hepatic angiogram showing a hypervascular tumor supplied by left hepatic artery.

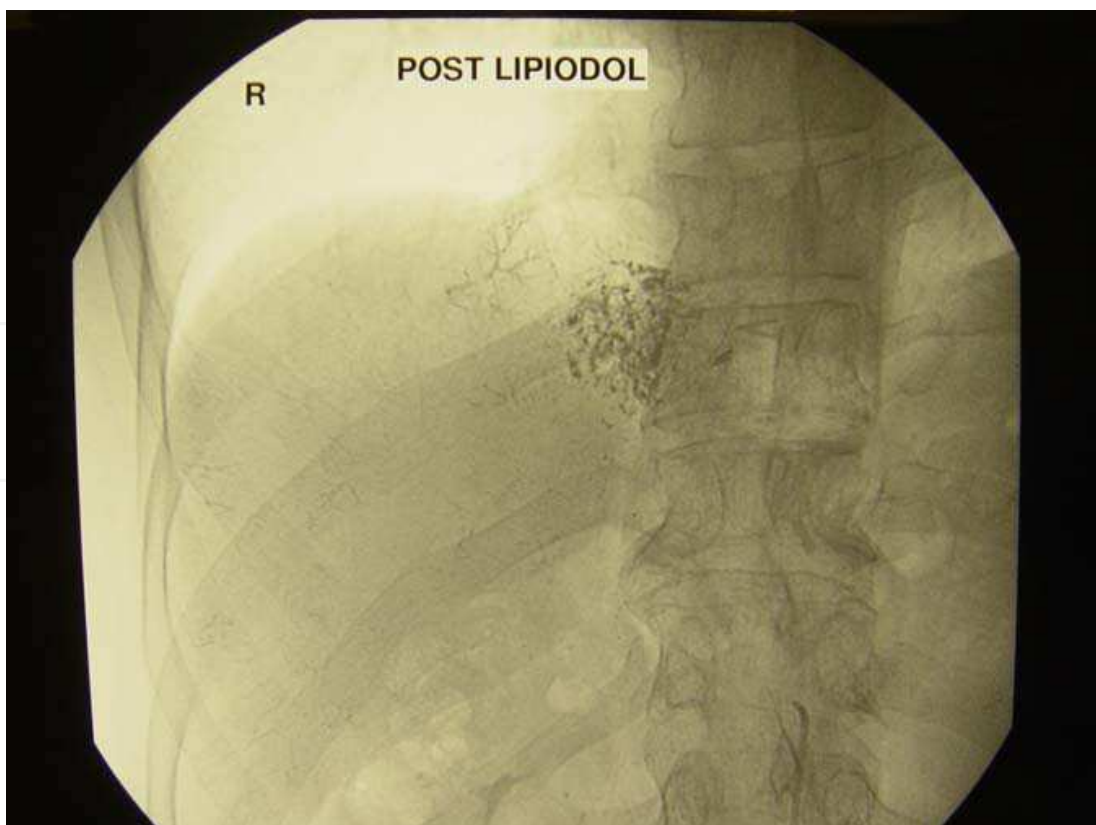


Fig. 6b. The tumor was stained by lipiodol after TACE.

Shim et al analysed data from 199 consecutive HCC patients who underwent curative liver resection and later received repeat TACE for intra-hepatic HCC recurrence. They found that complete tumor necrosis after repeated TACE offered favorable long-term survival outcomes to HCC-recurrent patients, with a median survival time after first TACE of 48.9 months. Despite this, unlike repeat hepatectomy and RFA, TACE cannot be regarded as a curative treatment for recurrent HCC yet.

Although it is not a surgical procedure, the problems of decreased liver reserves and anatomic changes due to previous operation still exist. Moreover, neovascularisation or collaterals that feed the recurrent tumour, damage to the non-tumorous liver tissue, and accumulation of drug toxicity from repeated TACE sessions are the main concern for the use of TACE. Post-embolization syndrome, which is a combination of fever, abdominal pain, nausea and vomiting, elevated liver enzymes and white cell counts for a few hours to a few days, is the most common complication of TACE. Although this syndrome is experienced after 80-90% of TACE procedures, it is mostly self-limited and the treatment is mainly symptomatic. Occasionally, more severe complications like acute cholecystitis, biliary tract necrosis, pancreatitis, gastric erosion or even ulcers can occur as a result of inadvertent injection of the chemotherapeutic and embolizing agents into these organs. Liver failure can develop after TACE and may result in mortality after TACE especially in patients with borderline liver function before treatment. Therefore, patients with portal vein thrombosis or poor liver function are contraindication to TACE.

2.4.2 Selective Internal Radiation Treatment (SIRT)

Selective internal radiation treatment (SIRT) is the delivery of radiation treatment via intrahepatic arterial administration of yttrium 90 (Y-90) microspheres. This technique involved the administration of Y-90 microspheres into the hepatic arterial via the trans-femoral route. The administered Y-90 microspheres are then entrapped within the microvasculature and release irradiation. The high tumor concentration of Y-90 microspheres results in an effective tumoricidal radiation-absorbed level while the radiation injury to the normal liver parenchyma is limited.

Its role as a safe and effective therapeutic option for patients with unresectable hepatocellular carcinoma is increasingly recognized. Recently, Lau et al (Lau et al, 2011) reviewed the role of SIRT with Y-90 microspheres for hepatocellular carcinoma, including recurrent unresectable HCC. SIRT is a recommended option of palliative therapy for large or multifocal HCC without major portal vein invasion or extrahepatic spread. It can be used as a bridging therapy before liver transplantation or as a tumor downstaging treatment, or as a curative treatment for patients who are not fit for surgery. However, the evidence was limited to cohort studies and comparative studies with historical control and was mainly targeted on primary HCC. Future research may yield more information on its role on recurrent HCC and the efficacy when compared to chemoembolization or target therapy.

In contrary to chemoembolization, optimal perfusion is required to enhance the free radical-dependent cell death in SIRT. In order to minimize the treatment-related toxicity, hepatic scintigraphy with technetium Tc 99m (^{99m}Tc) macro-aggregate albumin (MAA) should be performed to determine the arterial anatomy and to calculate the shunt fraction delivered to the lungs before subjecting the patient to SIRT. Pulmonary shunt fraction greater than 15%

on ^{99m}Tc -MAA scan predisposes to radiation pneumonitis and is therefore a contraindication for SIRT. In addition to radiation pneumonitis, other serious complication associated with SIRT include gastric or duodenal ulcers or perforation as a result of reflux of Y-90 microspheres into the gastrointestinal vascular bed and radiation hepatitis resulting from a radiation dose higher than the tolerable level. Nevertheless, most patients only reported mild symptoms like abdominal pain, lethargy or nausea, which may require symptomatic treatment. (Rossi et al, 2010) In most cases, it is a well-tolerated minimally invasive therapy.

3. Extrahepatic recurrence

Extra-hepatic recurrence or extra-hepatic metastasis occurs as a result of tumor extension from the liver or direct spreading to adjacent structures such as the diaphragm, the bowel and the adrenal gland; haematogenous spread via the systemic circulation to the lung; lymphatic spread from the liver to the portal and abdominal lymph nodes; or peritoneal dissemination from tumor rupture. Lung and abdominal lymph nodes are the commonest sites of metastasis, followed by musculoskeletal system, adrenal gland and peritoneum (Katyal et al., 2000; Yang et al., 2007).

There were very few studies addressing the aggressive management of extra-hepatic recurrence after liver resection. This is probably related to the extremely poor prognosis in these patients before the introduction of sorafenib.

3.1 Systemic treatment

In general, extra-hepatic metastasis is regarded as an advanced systemic disease and therefore, only systemic chemotherapy or supportive treatment will be offered only. Unfortunately, the response rate of HCC to systemic chemotherapy such as adriamycin is very low and the results were mostly disappointing (Simonetti et al., 1997).

With better understanding of the mechanism of hepatocarcinogenesis, effective molecularly targeted agents, such as sorafenib, have been emerged and improved survival benefits have been demonstrated in large, placebo-controlled phase III trials in Europe and Asia for patients with advanced HCC (Cheng et al., 2009; Llovet et al., 2008). While some may criticize that the benefit gained from sorafenib over placebo in patients with extra-hepatic metastasis from HCC was marginal only, the extra months gain may well be extremely valuable to patients.

3.2 Surgical resection

Recently, the role of resection of extra-hepatic metastasis from hepatocellular carcinoma has been reviewed (Chua & Morris, 2011). From the results reported in the literatures, prolonged survival after surgical resection may be achieved in selected patients with solitary extra-hepatic recurrence at the sites of the abdominal lymph node, adrenal gland, lung, and peritoneum. Surgical resection might be an effective option in patients with one or two isolated extrahepatic metastases if the patient has otherwise good performance status, good hepatic functional reserve, and well-controlled intrahepatic HCC recurrence. However, it might just reflect a group of patients with a more favourable natural course of disease (Chan et al., 2009; Lam et al., 1998; Nakayama et al., 1999; Sakamoto et al., 1999).

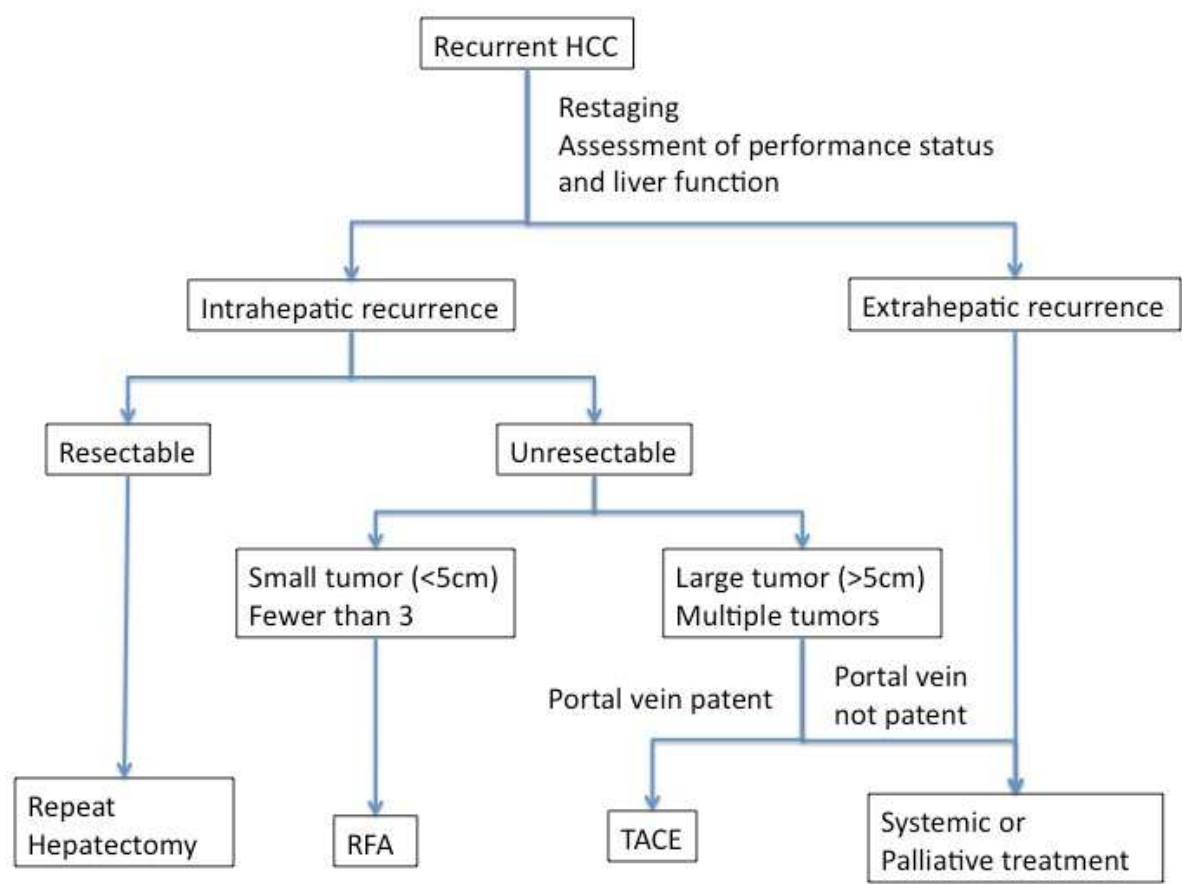


Fig. 7. Algorithm protocol for treatment of recurrent HCC

4. Prevention

Unfortunately, there is still no universally accepted form of adjuvant therapy for preventing recurrence after hepatic resection (Lau et al., 2009). Adjuvant regional therapy and anti-viral therapy are the two main directions that researches on this field are working on.

4.1 Role of adjuvant regional therapy

The preventive effect of TACE on recurrence after operation had been studied by prospective (Peng et al., 2009; Zhong et al., 2009) and retrospective series (Ren et al., 2004; Xi et al., 2007) mostly in eastern centers. The survival benefit of adjuvant TACE after hepatic resection was demonstrated in patients with high risk factors for recurrence while the effect in low risk for recurrence remains questionable. However, the quoted high risk factors for recurrence varied between studies, namely large tumor, multiple nodules, vascular invasion and presence of portal vein tumor thrombus. With the currently available evidence, the adjuvant regional chemotherapy with or without embolization or combination of systemic chemotherapy does not provide any additional benefit (Chan et al., 2000; Lau et al., 2009; Schwartz et al., 2002). Adjuvant transarterial treatments with ¹³¹I-lipiodol and adjuvant immunotherapy with interferon had demonstrated early promising results, which may have a role in preventing early intra-hepatic recurrence (Boucher et al., 2003; Ikeda et al., 2000;

Kudo et al., 2002; Lau et al., 2008; Partensky et al., 2000; Sun et al., 2006; Takjayama et al., 2000). However, its role remains to be confirmed by further studies.

4.2 Antiviral therapy

In Asia, chronic hepatitis B virus (HBV) infection is the major cause of HCC. The risk for HCC development is closely associated with hepatitis B e antigen (HBeAg) status and the serum HBV-DNA level. Recent studies showed that tumour recurrence after curative treatment of HCC was increased with the level of HBV-DNA and alanine aminotransferase (ALT) (Cheung et al., 2008; Huang et al., 2008). This implies that HBV viral replication may play a role in HCC development and tumour recurrence. Scattered results from perspective and retrospective studies have shown that continuous treatment with nucleotide analogue in patients with chronic hepatitis B or cirrhosis could reduce the risk of HCC development (Liaw et al., 2004; Matsumoto et al., 2005). Wong et al reviewed the results of nine cohort studies including more than 500 patients in a recent meta-analysis concluded that anti-viral therapy could significantly reduce the risk of HCC recurrence after curative treatment of HBV-related HCC (Wong et al., 2011). Furthermore, anti-viral therapy might also allow salvage therapy in case of HCC recurrence by better-preserved liver function as supported by the result of two other studies (Kuzuya et al., 2007; Piao et al., 2005). Hence, anti-viral therapy with nucleotide analogues should be considered after curative treatment of HBV-related HCC for the potential benefit in tumor recurrence and overall survival.

5. Conclusion

The principles of therapy for recurrent HCC should be, in fact, the same as those for primary HCC. Patients should have proper pre-operative assessment for their general functional status and evaluation of the functional liver reserve. Active hepatitis seems to be an important factor for patients considered for repeated liver resection, and therefore viral status, viral activity and finally liver function have to be evaluated thoroughly before resection. Depending on the local availability of various imaging modality, detail workup for restaging the disease and to rule out extra-hepatic metastasis is an important part in the decision of the best treatment for patient with recurrent HCC. Re-hepatectomy should be the treatment of choice if the tumour is resectable in terms of patient's performance status, tumour staging and functional reserve of the liver remnant. For patients with small recurrence and borderline liver functional, local ablation therapy is a safe and effective treatment option. In case of multiple intra-hepatic recurrences, TACE can be considered in patients with good liver function as long as the portal veins remain patent.

6. References

- Arii, S.; Monden, K.; Niwano, M.; Furutani, M.; Mori, A.; Mizumoto, M. & Imamura, M. (1998). Results of surgical treatment for recurrent hepatocellular carcinoma: comparison of outcome among patients with multicentric carcinogenesis, intrahepatic metastasis, and extrahepatic recurrence. *Journal of Hepato-biliary-pancreatic Surgery*, Vol.5, No.1, (1998), pp. 86-92, ISSN 0944-1166

- Belghiti, J.; Panis, Y.; Farges, O.; Benhamou, JP. & Fekete, F. (1991). Intrahepatic recurrence after resection of hepatocellular carcinoma complicating cirrhosis. *Annals of Surgery*, Vol.214, No.2, (August 1998), pp. 114–117, ISSN 0003-4932
- Belli, G.; Cioffi, L.; Fantini, C.; D'Agostino, A.; Russo, G.; Limongelli, P. & Belli, A. (2009). Laparoscopic redo surgery for recurrent hepatocellular carcinoma in cirrhotic patients: feasibility, safety, and results. *Surgical Endoscopy*, Vol.23, No.8, (August 2009), pp. 1807–1811, ISSN 0930-2794
- Bismuth, H.; Chiche, L. & Castaing, D. (1995). Surgical treatment of hepatocellular carcinomas in non-cirrhotic liver: experience with 68 liver resections. *World Journal of Surgery*, Vol.19, No.1, (January-February 1995), pp. 35–41, ISSN 0364-2313
- Boucher, E.; Corbinais, S.; Rolland, Y.; Bourguet, P.; Guyader, D.; Boudjema, K.; Meunier, B. & Raoul, JL. (2003). Adjuvant intra-arterial injection of iodine-131-labeled lipiodol after resection of hepatocellular carcinoma. *Hepatology*, Vol.38, No.5, (November 2003), pp. 1237–1241, ISSN 1457-8862
- Boutros, C.; Somasundar, P.; Garrean, S.; Saied, A. & Espat, NJ. (2010). Microwave coagulation therapy for hepatic tumors: review of the literature and critical analysis. *Surgical Oncology*, Vol.19, No.1, (March 2010), pp. 22–32, ISSN 0960-7404
- Camma, C.; Marco, VD.; Orlando, A.; Sandonato, L.; Casaril, A.; Parisi, P.; Alizzi, S.; Sciarrino, E.; Virdone, R.; Pardo, S.; Di Bona, D.; Licata, A.; Latteri, F.; Cabibbo, G.; Montalto, G.; Latteri, MA.; Nicoli, N. & Craxì, A. (2005). Treatment of hepatocellular carcinoma in compensated cirrhosis with radiofrequency thermal ablation (RFTA): a prospective study. *Journal of Hepatology*, Vol.42, No.4, (April 2005), pp. 535–540, ISSN 0168-8278
- Chan, KM.; Yu, MC.; Wu, TJ.; Lee, CF.; Chen, TC.; Lee, WC. & Chen, MF. (2009). Efficacy of surgical resection in management of isolated extrahepatic metastases of hepatocellular carcinoma. *World Journal of Gastroenterology*, Vol.15, No.43, (November 2009), pp. 5481–5488, ISSN 1007-9327
- Chen, MS.; Li, JQ.; Zheng, Y.; Cuo, RP.; Liang, HH.; Zhang, YQ.; Lin, XJ. & Lau, WY. (2006). A prospective randomized trial comparing percutaneous local ablative therapy and partial hepatectomy for small hepatocellular carcinoma. *Annals of Surgery*, Vol.243, No.3, (March 2006), pp. 321–328, ISSN 0003-4932
- Chen, WT.; Chau, GY.; Lui, WY.; Tsay, SH.; King, KL.; Loong, CC. & Wu, CW. (2004). Recurrent hepatocellular carcinoma after hepatic resection: prognostic factors and long-term outcome. *European Journal of Surgical Oncology*, Vol.30, No.4, (May 2004), pp. 414–420, ISSN 0748-7983
- Cheng, AL.; Kang, YK.; Chen, Z.; Tsao, CJ.; Qin, S.; Kim, JS.; Luo, R.; Feng, J.; Ye, S.; Yang, TS.; Xu, J.; Sun, Y.; Liang, H.; Liu, J.; Wang, J.; Tak, WY.; Pan, H.; Burock, K.; Zou, J.; Voliotis, D. & Guan, Z. (2008). Efficacy and safety of sorafenib in patients in the Asia-Pacific region with advanced hepatocellular carcinoma: a phase III randomised, double-blind, placebo-controlled trial. *Lancet Oncology*, Vol.10, No.1, (January 2008), pp. 25–34, ISSN 1470-2045
- Cheung, TT.; Ng, KK.; Poon, RT.; Chan, SC.; Lo, CM. & Fan, ST. (2010). A case of laparoscopic hepatectomy for recurrent hepatocellular carcinoma. *World Journal of Gastroenterology*, Vol.16, No.4, (January 2010), pp. 526–530, ISSN 1007-9327
- Cheung, YS.; Chan, HL.; Wong, J.; Lee, KF.; Poon, TC.; Wong, N. & Lai, PB. (2008). Elevated perioperative transaminase level predicts intrahepatic recurrence in hepatitis B-

- related hepatocellular carcinoma after curative hepatectomy. *Asian Journal of Surgery*, Vol.31, No.2, (April 2008), pp: 41–49, ISSN 1015-9584
- Choi, D.; Lim, HK.; Rhim, H.; Kim, YS.; Yoo, BC.; Pail, SW.; Joh, JW. & Park, CK. (2007). Percutaneous radiofrequency ablation for recurrent hepatocellular carcinoma after hepatectomy: long-term results and prognostic factors. *Annals of Surgical Oncology*, Vol.14, No.8, (August 2007), pp: 2319-2329, ISSN 1068-9265
- Choi, JW.; Park, JY.; Ahn, SH.; Yoon, KT.; Ko, HK.; Lee, do Y.; Lee, JT.; Kim, KS.; Choi, JS.; Han, KH.; Chon, CY. & Kim, do Y. (2009). Efficacy and safety of transarterial chemoembolization in recurrent hepatocellular carcinoma after curative surgical resection. *American Journal of Clinical Oncology*, Vol.32, No.6, (December 2009), pp: 564-569, ISSN 0277-3732
- Chong, CC.; Lee, KF.; Ip, PC.; Wong, JS.; Cheung, SY.; Wong, J.; Ho, SC. & Lai, PB. (2011). Pre-operative predictors of post-hepatectomy recurrence of hepatocellular carcinoma: Can we predict earlier?, *The Surgeon* (2011), doi:10.1016/j.surge.2011.07.004. In press.
- Chua, TC. & Morris, DL. (2011). Exploring the role of resection of extrahepatic metastases from hepatocellular carcinoma. *Surgical Oncology*, (Mar 2011), ISSN 0960-7404. [Epub ahead of print]
- Eguchi, S.; Ijtsma, AJ.; Slooff, MJ.; Porte, RJ.; de Jong, KP.; Peeters, PM.; Gouw, AS. & Kanematsu, T. (2006). Outcome and pattern of recurrence after curative resection for hepatocellular carcinoma in patients with a normal liver compared to patients with a diseased liver. *Hepatogastroenterology*, Vol.53, No.70, (July-August 2006), pp: 592–596, ISSN 0172-6390
- Eguchi, S.; Matsumoto, S.; Hamasaki, K.; Takatsuki, M.; Hidaka, M.; Tajima, Y.; Sakamoto, I. & Kanematsu, T. (2008). Re-evaluation of lipiodolized transarterial chemoembolization therapy for intrahepatic recurrence of hepatocellular carcinoma after curative liver resection. *Journal of Hepato-biliary-pancreatic Surgery*, Vol.15, No.6, (November 2008), pp: 627-633, ISSN 0944-1166
- Ercolani, G.; Grazi, GL.; Ravaioli, M.; Del Gaudio, M.; Gardini, A.; Cescon, M.; Varotti, G.; Cetta, F. & Cavallari, A. (2003). Liver resection for hepatocellular carcinoma on cirrhosis: univariate and multivariate analysis of risk factors for intrahepatic recurrence. *Annals of Surgery*, Vol.237, No.4, (April 2003), pp: 536-543, ISSN 0003-4932
- Farges, O.; Regimbeau, JM. & Belghiti, J. (1998). Aggressive management of recurrence following surgical resection of hepatocellular carcinoma. *Hepatogastroenterology*, Vol.45, No.3, (August 1998), pp: 1275–1280, ISSN 0172-6390
- Globocan 2008, Cancer Incidence and Mortality Worldwide in 2008, In: *World Health Organisation*, 1st August 2011, Available from: < <http://globocan.iarc.fr/> >
- Goldberg, SN. & Gazelle, GS. (2001). Radiofrequency tissue ablation: physical principles and techniques for increasing coagulation necrosis. *Hepatogastroenterology*, Vol.48, No.38, (March-April 2001), pp: 359–367, ISSN 0172-6390
- Hu, M.; Zhao, G.; Xu, D. & Liu, R. (2011). Laparoscopic repeat resection of recurrent hepatocellular carcinoma. *World Journal of Surgery*, Vol.35, No.3, (March 2011), pp: 648-655, ISSN 0364-2313

- Hu, RH.; Lee, PH.; Yu, SC.; Dai, HC.; Sheu, JC.; Lai, MY. & Chen, DS. (1996). Surgical resection for recurrent hepatocellular carcinoma: prognosis and analysis of risk factors. *Surgery*, Vol.120, No.1, (July 1996), pp: 23-29, ISSN 0039-6060
- Huang, Y.; Wang, Z.; An, S.; Zhou, Y.; Chan, HL. & Hou, J. (2008). Role of hepatitis B virus genotypes and quantitative HBV DNA in metastasis and recurrence of hepatocellular carcinoma. *Journal of Medical Virology*, Vol.80, No.4, (April 2008), pp: 591-597, ISSN 0146-6615
- Ikeda K, Arase Y, Saitoh S, Kobayashi M, Suzuki Y, Suzuki F, Tsubota A, Chayama K, Murashima N & Kumada H. (2000). Interferon beta prevents recurrence of hepatocellular carcinoma after complete resection or ablation of the primary tumor-A prospective randomized study of hepatitis C virus-related liver cancer. *Hepatology*, Vol.32, No.2, (August 2000), pp: 228-232, ISSN 0270-9139
- Ikeda, M.; Okada, S.; Ueno, H.; Okusaka, T. & Kuriyama, H. (2001). Radiofrequency ablation and percutaneous ethanol injection in patients with small hepatocellular carcinoma: a comparative study. *Japanese Journal of Clinical Oncology*, Vol.31, No.7, (July 2001), pp: 322-326, ISSN 0368-2811
- Itamoto, T.; Nakahara, H.; Amano, H.; Kohashi, T.; Ohdan, H.; Tashiro, H. & Ashara, T. (2007). Repeat hepatectomy for recurrent hepatocellular carcinoma. *Surgery*, Vol.141, No.5, (May 2007), pp: 589-597, ISSN 0039-6060
- Itoh, S.; Ikeda, Y.; Kawanaka, H.; Okuyama, T.; Kawasaki, K.; Eguchi, D.; Korenaga, D. & Takenaka, K. (2011). Efficacy of Surgical Microwave Therapy in Patients with Unresectable Hepatocellular Carcinoma. *Annals of Surgical Oncology*, (June 2011), ISSN 1068-9265, [Epub ahead of print]
- Jwo, SC.; Chiu, JH.; Chau, GY.; Loong, CC. & Lui, WY. (1992). Risk factors linked to tumor recurrence of human hepatocellular carcinoma after hepatic resection. *Hepatology*, Vol.16, No.6, (December 1992), pp: 1367-1371, ISSN 0270-9139
- Kakazu, T.; Makuuchi, M.; Kawasaki, S.; Miyagawa, S.; Hashikura, Y.; Kosuge, T.; Takayama, T. & Yamamoto, J. (1993). Repeat hepatic resection for recurrent hepatocellular carcinoma. *Hepatogastroenterology*, Vol.40, No.4, (August 1993), pp: 337-341, ISSN 0172-6390
- Kanematsu, T.; Takenaka, K.; Matsumata, T.; Furtuta, T.; Sugimachi, K. & Inokuchi, K. (1984). Limited hepatic resection effective for selected cirrhotic patients with primary liver cancer. *Annals of Surgery*, Vol.199, No.1, (January 1984), pp: 51-56, ISSN 0003-4932
- Katyal, S.; Oliver, III JH.; Peterson, MS.; Carr, BS. & Baron, RL. (2000). Extrahepatic Metastases of Hepatocellular Carcinoma. *Radiology*, Vol.216, No.3, (September 2000), pp: 698-703, ISSN 0033-8419
- Kosuge, T.; Makuuchi, M.; Takayama, T.; Yamamoto, J.; Shimada, K. & Yamasaki, S. (1993). Long-term results after resection of hepatocellular carcinoma: experience of 480 cases. *Hepatogastroenterology*. Vol.40, No.4, (August 1993), pp: 328-332, ISSN 0172-6390
- Kubo, S.; Nishiguchi, S.; Hirohashi, K.; Tanaka, H.; Shuto, T. & Kinoshita, H. (2002). Randomized clinical trial of long-term outcome after resection of hepatitis C virus-related hepatocellular carcinoma by postoperative interferon therapy. *British Journal of Surgery*, Vol.89, No.4, (April 2002), pp: 418-422, ISSN 0007-1323

- Kuzuya, T.; Katano, Y.; Kumada, T.; Toyoda, H.; Nakano, I.; Hirooka, Y.; Itoh, A.; Ishigami, M.; Hayashi, K.; Honda, T. & Goto, H. (2007). Efficacy of antiviral therapy with lamivudine after initial treatment for hepatitis B virus-related hepatocellular carcinoma. *Journal of Gastroenterology and Hepatology*, Vol.22, No.11, (November 2007), pp: 1929– 1935, ISSN 0815-9319
- Lam, CM.; Lo, CM.; Yuen, WK.; Liu, CL. & Fan, ST. (1998). Prolonged survival in selected patients following surgical resection for pulmonary metastasis from hepatocellular carcinoma. *British Journal of Surgery*, Vol.85, No.9, (September 1998), pp: 1198-200, ISSN 0007-1323
- Lau, WY.; Lai, EC.; Leung, TW. & Yu, SC. (2008). Adjuvant intra-arterial iodine-131-labeled lipiodol for resectable hepatocellular carcinoma: a prospective randomized trial-update on 5-year and 10-year survival. *Annals of Surgery*, Vol.247, No.1, (January 2008), pp: 43-48, ISSN 0003-4932
- Lau, WY. & Lai, EC. (2009). The current role of radiofrequency ablation in the management of hepatocellular carcinoma: a systematic review. *Annals of Surgery*, Vol.249, No.1, (January 2009), pp: 20-25, ISSN 0003-4932
- Lau, WY.; Lai, EC. & Lau, SH. (2009). The current role of neoadjuvant/adjuvant/chemoprevention therapy in partial hepatectomy for hepatocellular carcinoma: a systemic review. *Hepatobiliary and Pancreatic Disease International*, Vol.8, No.2, (April 2009), pp: 124-133, ISSN 1499-3872
- Lau, WY.; Lai, EC.; Leung TW. (2011) Current role of selective internal irradiation with yttrium-90 microspheres in the management of hepatocellular carcinoma: a systematic review. *International Journal of Radiation Oncology, Biology, Physics*, Vol.81, No. 2, (Oct 2011), pp: 460-467, ISSN 0360-3016
- Lee, KF.; Cheung, YS.; Chong, CN.; Tsang, YY.; Ng, WW.; Ling, E.; Wong, J. & Lai, PB. (2007). Laparoscopic versus open hepatectomy for liver tumours: a case control study. *Hong Kong Medical Journal*, Vol.13, No.6, (December 2007), pp: 442–448, ISSN 1024-2708
- Lee, KF.; Chong, CN.; Wong, J.; Cheung, YS.; Wong, J.; Lai, P. (2011). Long-Term Results of Laparoscopic Hepatectomy Versus Open Hepatectomy for Hepatocellular Carcinoma: A Case-Matched Analysis. *World Journal of Surgery*, (August 2011), ISSN 0361-2313, [Epub ahead of print]
- Liang, X.; Cai, XJ.; Yu, H.; Wang, YF. & Laing, YL. (2009). Second laparoscopic resection for recurrent hepatocellular carcinoma after initial laparoscopic hepatectomy: case report. *Chinese Medical Journal*, Vol.122, No.11, (June 2009), pp: 1359–1360, ISSN 0366-6999
- Livraghi, T.; Goldberg, SN.; Lazzaroni, S.; Meloni, F.; Solbiati, L. & Gazelle, GS. (1999). Small hepatocellular carcinoma: treatment with radio-frequency ablation versus ethanol injection. *Radiology*, Vol.210, No.3, (March 1999), pp: 655–661, ISSN 0033-8419
- Llovet, JM. & Bruix, J. (2003). Systematic review of randomized trials for unresectable hepatocellular carcinoma: Chemoembolization improves survival. *Hepatology*, Vol.37, No.2, (February 2003), pp: 429–442, ISSN 0815-9319
- Llovet, JM.; Ricci, S.; Mazzaferro, V.; Hilgard, P.; Gane, E.; Blanc, JF.; de Oliveira, AC.; Santoro, A.; Raoul, JL.; Forner, A.; Schwartz, M.; Porta, C.; Zeuzem, S.; Bolondi, L.; Greten, TF.; Galle, PR.; Seitz, JF.; Borbath, I.; Häussinger, D.; Giannaris, T.; Shan, M.; Moscovici, M.; Voliotis, D. & Bruix, J. (2008). Sorafenib in advanced

- Hepatocellular Carcinoma. *The New England Journal of Medicine*, Vol.359, No.4, (July 2008), pp: 378-390, ISSN 0028-4793
- Llovet, JM.; Vilana, R.; Brú, C.; Bianchi, L.; Salmeron, JM.; Boix, L.; Ganau, S.; Sala, M.; Pagès, M.; Ayuso, C.; Solé, M.; Rodés, J. & Bruix, J. (2001). Increased risk of tumor seeding after percutaneous radiofrequency ablation for single hepatocellular carcinoma. *Hepatology*, Vol.33, No.3, (May 2001), pp: 1124-1129, ISSN 0815-9319
- Lu, MD.; Chen, JW.; Xie, XY.; Liu, L.; Huang, XQ.; Liang, LJ. & Huang, JF. (2001). Hepatocellular carcinoma: US-guided percutaneous microwave coagulation therapy. *Radiology*, Vol.221, No.1, (October 2001), pp: 167- 172, ISSN 0033-8419
- Lu, MD.; Xu, HX.; Xie, XY.; Yin, XY.; Chen, JW.; Kuang, M.; Xu, ZF.; Liu, GJ. & Zheng, YL. (2005). Percutaneous microwave and radiofrequency ablation for hepatocellular carcinoma: a retrospective comparative study. *Journal of Gastroenterology*, Vol.40, No.11, (November 2005), pp: 1054-1060, ISSN 0944-1174
- Lu, MD.; Yin, XY.; Xie, XY.; Xu, HX.; Xu, ZF.; Liu, GJ.; Kuang, M. & Zheng, YL. (2005). Percutaneous thermal ablation for recurrent hepatocellular carcinoma after hepatectomy. *British Journal of Surgery*, Vol.92, No.11, (November 2005), pp: 1393-1398, ISSN 0007-1323
- Makuuchi, M.; Takayama, T.; Kubota, K.; Kimura, W.; Midorikawa, Y.; Miyagawa, S. & Kawasaki, S. (1998). Hepatic resection for hepatocellular carcinoma: Japanese experience. *Hepatogastroenterology*. Vol.45, No.3, (August 1998), pp: 1267-1274, ISSN 0172-6390
- Matsuda, M.; Fujii, H.; Kono, H. & Matsumoto, Y. (2001). Surgical treatment of recurrent hepatocellular carcinoma based on the mode of recurrence: repeat hepatic resection or ablation are good choices for patients with recurrent multicentric cancer. *Journal of Hepato-biliary-pancreatic Surgery*, Vol.8, No.4, (2001), pp: 353-359, ISSN 0944-1166
- Matsuda, Y.; Ito, T.; Oguchi, Y.; Nakajima, K. & Izukura, T. (1993). Rationale of surgical management for recurrent hepatocellular carcinoma. *Annals of Surgery*; Vol.217, No.1, (January 1993), pp: 28-34, ISSN 0003-4932
- Matsumata, T.; Kanematsu, T.; Takenaka, K.; Yoshida, Y.; Nishizaki, T. & Sugimachi, K. (1989). Patterns of intrahepatic recurrence after curative resection of hepatocellular carcinoma. *Hepatology*, Vol.9, No.3, (March 1989), pp: 457-460, ISSN 0270-9139
- Minagawa, M.; Makuuchi, M.; Takayama, T. & Kokudo, N. (2003). Selection criteria for repeat hepatectomy in patients with recurrent hepatocellular carcinoma. *Annals of Surgery*, Vol.228, No.5, (November 2003), pp: 703-710, ISSN 0003-4932
- Nakayama, H.; Takayama, T.; Makuuchi, M.; Yamasaki, S.; Kosuge, T.; Shimada, K. & Yamamoto, J. (1999). Resection of peritoneal metastases from hepatocellular carcinoma. *Hepatogastroenterology*, Vol.46, No.26, (March - April 1999), pp: 1049-1052, ISSN 0172-6390
- Ohmoto, K. & Yamamoto, S. (2006). Comparison between radiofrequency ablation and percutaneous microwave coagulation therapy for small hepatocellular carcinomas. *Clinical Radiology*, Vol.61, No.9, (September 2006), pp: 800-801, ISSN 009-9260
- Ogata, Y.; Uchida, S.; Hisaka, T.; Horiuchi, H.; Mori, S.; Ishibashi, N.; Akagi, Y. & Shirouzu, K. (2008). Intraoperative thermal ablation therapy for small colorectal metastases to the liver. *Hepatogastroenterology*. Vol.55, No.82-83, (March - April 2008), pp: 550-556, ISSN 0172-6390

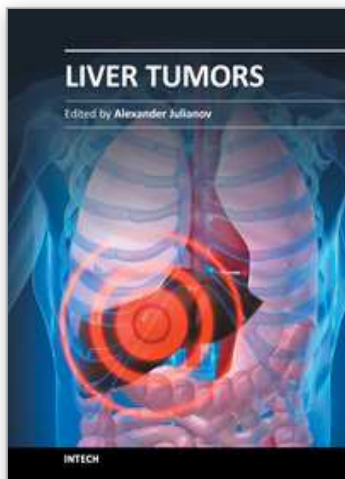
- Partensky, C.; Sassolas, G.; Henry, L.; Pallard, P. & Maddern, GJ. (2000). Intra-arterial iodine 131-labeled lipiodol as adjuvant therapy after curative liver resection for hepatocellular carcinoma: a phase 2 clinical study. *Archives of Surgery*, Vol.135, No.11, (November 2000), pp: 1298-1300, ISSN 0004-0010
- Peng, BG.; He, Q.; Li, JP. & Zhou, F. (2009). Adjuvant transcatheter arterial chemoembolization improves efficacy of hepatectomy for patients with hepatocellular carcinoma and portal vein tumor thrombus. *American Journal of Surgery*, Vol.198, No.3, (September 2009), pp: 313-318, ISSN 0002-9610
- Piao, CY.; Fujioka, S.; Iwasaki, Y.; Fujio, K.; Kaneyoshi, T.; Araki, Y.; Hashimoto, K.; Senoh, T.; Terada, R.; Nishida, T.; Kobashi, H.; Sakaguchi, K. & Shiratori, Y. (2005). Lamivudine treatment in patients with HBV-related hepatocellular carcinoma – using an untreated, matched control cohort. *Acta Medica Okayama*, Vol.59, No.5, (October 2005), pp: 217-224, ISSN 0386-300X
- Poon, RTP.; Fan, ST.; Lo, CM.; Liu, CL. & Wong, J. (1999). Intrahepatic recurrence after curative resection for hepatocellular carcinoma: long-term results of treatment and prognostic factors. *Annals of Surgery*, Vol.229, No.2, (February 1999), pp: 216-222, ISSN 0003-4932
- Poon, RT.; Fan, ST.; Ng, IO.; Lo, CM.; Liu, CL. & Wong, J. (2000). Different risk factors and prognosis for early and late intrahepatic recurrence after resection of hepatocellular carcinoma. *Cancer*, Vol.89, No.3. (August 2000), pp: 500-507, ISSN 0008-543X
- Poon, RT.; Fan, ST.; Lo, CM.; Ng, IO.; Liu, CL.; Lam, CM. & Wong, J. (2001). Improving survival results after resection of hepatocellular carcinoma: a prospective study of 377 patients over 10 years. *Annals of Surgery*, Vol.234, No.1, (Jul 2001), pp: 63-70, ISSN 0003-4932
- Poon, RT.; Fan, ST.; O'Suilleabhain, CB. & Wong, J. (2002). Aggressive management of patients with extrahepatic and intrahepatic recurrences of hepatocellular carcinoma by combined resection and locoregional therapy. *Journal of the American College of Surgeons*, Vol.195, No.3, (September 2002), pp: 311-318, ISSN 1072-7515
- Poon, RT.; Fan, ST.; Tsang, FH. & Wong, J. (2002). Locoregional therapies for hepatocellular carcinoma: a critical review from the surgeon's perspective. *Annals of Surgery*, Vol.235, No.4, (April 2002), pp: 466-486, ISSN 0003-4932
- Ren, ZG.; Lin, ZY.; Xia, JL.; Ye, SL.; Ma, ZC.; Ye, QH.; Qin, LX.; Wu, ZQ.; Fan, J. & Tang, ZY. (2004). Postoperative adjuvant arterial chemoembolization improves survival of hepatocellular carcinoma patients with risk factors for residual tumor: a retrospective control study. *World Journal of Gastroenterology*, Vol.10, No.19, (October 2004), pp: 2791-2794, ISSN 1007-9327
- Rossi, L.; Zoratto, F.; Papa, A.; Iodice, F.; Minozzi, M.; Frati, L. & Tomao, S. (2010). Current approach in the treatment of hepatocellular carcinoma. *World Journal of Gastrointestinal Oncology*, Vol.2, No. 9, (September 2010), pp: 348-359, ISSN 1948-5204
- Sakamoto, Y.; Kubota, K.; Mori, M.; Inoue, K.; Abe, H.; Harihara, Y.; Bandai, Y. & Makuuchi, M. (1999). Surgical management for adrenal gland metastasis of hepatocellular carcinoma. *Hepatogastroenterology*. Vol.46, No.26, (March - April 1999), pp: 1036-1041, ISSN 0172-6390
- Seki, T.; Wakabayashi, M.; Nakagawa, T.; Imamura, M.; Tamai, T.; Nishimura, A.; Yamashiki, N.; Okamura, A. & Inoue, K. (1999). Percutaneous microwave

- coagulation therapy for patients with small hepatocellular carcinoma: comparison with percutaneous ethanol injection therapy. *Cancer*, Vol.85, No.8, (April 1999), pp: 1694-1702, ISSN 0008-543X
- Shibata, T.; Iimuro, Y.; Yamamoto, Y.; Maetani, Y.; Ametani, F.; Itoh, K. & Konishi, J. (2002). Small hepatocellular carcinoma: comparison of radio-frequency ablation and percutaneous microwave coagulation therapy. *Radiology*, Vol.223, No.2, (May 2002), pp: 331-337, ISSN 0033-8419
- Shim, JH.; Park, JW.; Choi, JI.; Kim, HN.; Lee, WJ. & Kim, CM. (2009). Does postembolization fever after chemoembolization have prognostic significance for survival in patients with unresectable hepatocellular carcinoma? *Journal of Vascular and Interventional Radiology*, Vol.20, No.2, (February 2009), pp: 209-216, ISSN 1051-0443.
- Shim, JH.; Kim, KM.; Lee, YJ.; Ko, GY.; Yoon, HK.; Sung, KB.; Park, KM.; Lee, SG.; Lim, YS.; Lee, HC.; Chung, YH.; Lee, YS, & Suh, DJ. (2010). Complete necrosis after transarterial chemoembolization could predict prolonged survival in patients with recurrent intrahepatic hepatocellular carcinoma after curative resection. *Annals of Surgical Oncology*, Vol.17, No.3, (March 2010), pp: 869-877, ISSN 1068-9265
- Shimada, K.; Sakamoto, Y.; Esaki, M.; Kosuge, T.; Morizane, C.; Ikeda, M.; Ueno, H.; Okusaka, T.; Arai, Y. & Takayasu, K. (2007). Analysis of prognostic factors affecting survival after initial recurrence and treatment efficacy for recurrence in patients undergoing potentially curative hepatectomy for hepatocellular carcinoma. *Annals of Surgical Oncology*, Vol.14, No.8, (August 2007), pp: 2337-2347, ISSN 1068-9265
- Shimada, M., Takenaka K, Gion T, Fujiwara Y, Kajiyama K, Maeda T, Shirabe K, Nishizaki T, Yanaga K & Sugimachi K. (1996). Prognosis of recurrent hepatocellular carcinoma: a 10-year surgical experience in Japan. *Gastroenterology*, Vol.111, No.3, (September 1996), pp: 720-726, ISSN 0016-5085
- Shimada, M.; Takenaka, K.; Taguchi, K.; Fujiwara, Y.; Gion, T.; Kajiyama, K.; Maeda, T.; Shirabe, K.; Yanaga, K. & Sugimachi, K. (1998). Prognostic factors after repeat hepatectomy for recurrent hepatocellular carcinoma. *Annals of Surgery*, Vol.227, No.1, (January 1998), pp: 80-85, ISSN 0003-4932
- Simon, CJ.; Dupuy, DE. & Mayo-Smith, WW. (2005). Microwave ablation: principles and applications. *Radiographics*, Vol.25, Suppl 1, (October 2005), S69-83, ISSN 0271-5333
- Simonetti, RG.; Liberati, A.; Angiolini, C. & Pagliaro, L. (1997). Treatment of hepatocellular carcinoma: a systematic review of randomized controlled trials. *Annals of Oncology*, Vol.8, No.2, (February 1997), pp: 117-136, ISSN 0923-7534
- Suenaga, M.; Sugiura, H.; Kokuba, Y.; Uehara, S. & Kurumiya, T. (1994). Repeated hepatic resection for recurrent hepatocellular carcinoma in eighteen cases. *Surgery*, Vol.115, No.4, (April 1994), pp: 452- 457, ISSN 0039-6060.
- Sugimachi, K.; Maehara, S.; Tanaka, S.; Shimada, M. & Sugimachi, K. (2001). Repeat hepatectomy is the most useful treatment for recurrent hepatocellular carcinoma. *Journal of Hepato-biliary-pancreatic Surgery*, Vol.8, No.5, (2001), pp: 410-416, ISSN 0944-1166
- Sun, HC.; Tang, ZY.; Wang, L.; Qin, LX.; Ma, ZC.; Ye, QH.; Zhang, BH.; Qian, YB.; Wu, ZQ.; Fan, J.; Zhou, XD.; Zhou, J.; Qiu, SJ. & Shen, YF. (2006). Postoperative interferon alpha treatment postponed recurrence and improved overall survival in patients after curative resection of HBV-related hepatocellular carcinoma: a randomized

- clinical trial. *Journal of Cancer Research and Clinical Oncology*, Vol.132, No.7, (July 2006), pp: 458-465, ISSN 0171-5216
- Takayama T, Sekine T, Makuuchi M, Yamasaki S, Kosuge T, Yamamoto J, Shimada K, Sakamoto M, Hirohashi S, Ohashi Y & Kakizoe T. (2000). Adoptive immunotherapy to lower postsurgical recurrence rates of hepatocellular carcinoma: a randomized trial. *Lancet*, Vol.356, No.9232, (September 2000), pp: 802-807, ISSN 0140-6736
- Tateishi R, Shiina S, Teratani T, Obi S, Sato S, Koike Y, Fujishima T, Yoshida H, Kawabe T & Omata M. (2005). Percutaneous radiofrequency ablation for hepatocellular carcinoma: an analysis of 1000 cases. *Cancer*, Vol.103, No.6, (March 2005), pp: 1201-1209, ISSN 0008-543X
- Taura, K.; Ikai, I.; Hatano, E.; Fukii, H.; Uyama, N. & Shimahara, Y. (2006). Implication of frequent local ablation therapy for intrahepatic recurrence in prolonged survival of patients with hepatocellular carcinoma undergoing hepatic resection: an analysis of 610 patients over 16 years old. *Annals of Surgery*, Vol.244, No.2, (August 2006), pp: 265-273, ISSN 0003-4932
- Tralhão, JG.; Dagher, I.; Lino, T.; Roudié, J. & Franco, D. (2007). Treatment of tumour recurrence after resection of hepatocellular carcinoma. Analysis of 97 consecutive patients. *European Journal of Surgery Oncology*, Vol.33, No.6, (August 2007), pp: 746-751, ISSN 0748-7983
- Viganò, L.; Tayar, C.; Laurent, A. & Cherqui, D. (2009). Laparoscopic liver resection: a systematic review. *Journal of Hepato-biliary-pancreatic Surgery*, Vol.16, No. 4, (June 2009), pp: 410-421, ISSN 0944-1166
- Wong, JS.; Wong, GL.; Tsoi, KK.; Wong, VW.; Cheung, SY.; Chong, CN.; Wong, J.; Lee, KF.; Lai, PB. & Chan, HL. (2011). Meta-analysis: the efficacy of anti-viral therapy in prevention of recurrence after curative treatment of chronic hepatitis B-related hepatocellular carcinoma. *Alimentary Pharmacology and Therapeutics*, Vol.33, No.10, (May 2011), pp: 1104-1112, ISSN 0269-2813
- Wu, CC.; Cheng, SB.; Yeh, DC.; Wang, J. & Peng, FK. (2009). Second and third hepatectomies for recurrent hepatocellular carcinoma are justified. *British Journal of Surgery*, Vol.96, No.9, (September 2009), pp: 1049-1057, ISSN 0007-1323
- Xi, T.; Yan, ZL.; Wang, K.; Li, J.; Xia, Y.; Shen, F. & Wu, MC. (2007). Role of post-operative transcatheter arterial chemoembolization in hepatocellular carcinoma with different pathological characteristics. *Zhonghua Wai Ke Za Zhi*, Vol.45, No.9, (May 2007), pp: 1587-1590, ISSN 0529-5815
- Xu, HX.; Lu, MD.; Xie, XY.; Yin, XY.; Kuang, M.; Chen, JW.; Xu, Zf. & Liu, GJ. (2005). Prognostic factors for long-term outcome after percutaneous thermal ablation for hepatocellular carcinoma: a survival analysis of 137 consecutive patients. *Clinical Radiology*, Vol.60, No.9, (September 2005), pp: 1018-1025, ISSN 0009-9260
- Yamamoto, J.; Kosuge, T.; Takayama, T.; Shimada, K.; Yamasaki, S.; Ozaki, H.; Yamaguchi, N. & Makuuchi, M. (1996). Recurrence of hepatocellular carcinoma after surgery. *British Journal of Surgery*, Vol.83, No.9, (September 1996), pp: 1219-1222, ISSN 0007-1323
- Yang, W.; Chen, MH.; Yin, SS.; Yan, K.; Gao, W.; Wang, YB.; Huo, L.; Zhang, XP. & Xing, BC. (2006). Radiofrequency ablation of recurrent hepatocellular carcinoma after hepatectomy: therapeutic efficacy on early- and late-phase recurrence. *American Journal of Roentgenology*, Vol.186, 5 Supp, (May 2006), S275-S283, ISSN 0361-803X

- Yang, Y.; Nagano, H.; Ota, H.; Morimoto, O.; Nakamura, M.; Wada, H.; Noda, T.; Damdinsuren, B.; Marubashi, S.; Miyamoto, A.; Takeda, Y.; Dono, K.; Umeshita, K.; Nakamori, S.; Wakasa, K.; Sakon, M. & Monden, M. (2007). Patterns and clinicopathologic features of extrahepatic recurrence of hepatocellular carcinoma after curative resection. *Surgery*, Vol.141, No.2, (February 2007), pp: 196-202, ISSN 0039-6060
- Yeh, CN.; Chen, MF.; Lee, WC. & Jeng, LB. (2002). Prognostic factors of hepatic resection for hepatocellular carcinoma with cirrhosis: univariate and multivariate analysis. *Journal of Surgical Oncology*, Vol.81, No.4, (December 2002), pp: 195-202, ISSN 0022-4790
- Zhong, C.; Guo, RP.; Li, JQ.; Shi, M.; Wei, W.; Chen, MS. & Zhang, YQ. (2009). A randomized controlled trial of hepatectomy with adjuvant transcatheter arterial chemoembolization versus hepatectomy alone for Stage III A hepatocellular carcinoma. *Journal of Cancer Research and Clinical Oncology*, Vol.135, No.10, (October 2009), pp: 1437-1445, ISSN 0171-5216
- Zhou, Y.; Sui, C.; Li, B.; Yin, Z.; Tan, Y.; Yang, J. & Liu, Z. (2010). Repeat hepatectomy for recurrent hepatocellular carcinoma: a local experience and a systematic review. *World Journal of Surgical Oncology*, Vol.8, No.55, (July 2010), ISSN 1477-7819

IntechOpen



Liver Tumors

Edited by Prof. Alexander Julianov

ISBN 978-953-51-0036-2

Hard cover, 200 pages

Publisher InTech

Published online 03, February, 2012

Published in print edition February, 2012

This book is oriented towards clinicians and scientists in the field of the management of patients with liver tumors. As many unresolved problems regarding primary and metastatic liver cancer still await investigation, I hope this book can serve as a tiny step on a long way that we need to run on the battlefield of liver tumors.

How to reference

In order to correctly reference this scholarly work, feel free to copy and paste the following:

Charing Ching Ning Chong and Paul Bo San Lai (2012). Treatment Strategy for Recurrent Hepatocellular Carcinoma, Liver Tumors, Prof. Alexander Julianov (Ed.), ISBN: 978-953-51-0036-2, InTech, Available from: <http://www.intechopen.com/books/liver-tumors/treatment-strategy-for-recurrent-hepatocellular-carcinoma>

INTECH
open science | open minds

InTech Europe

University Campus STeP Ri
Slavka Krautzeka 83/A
51000 Rijeka, Croatia
Phone: +385 (51) 770 447
Fax: +385 (51) 686 166
www.intechopen.com

InTech China

Unit 405, Office Block, Hotel Equatorial Shanghai
No.65, Yan An Road (West), Shanghai, 200040, China
中国上海市延安西路65号上海国际贵都大饭店办公楼405单元
Phone: +86-21-62489820
Fax: +86-21-62489821

© 2012 The Author(s). Licensee IntechOpen. This is an open access article distributed under the terms of the [Creative Commons Attribution 3.0 License](#), which permits unrestricted use, distribution, and reproduction in any medium, provided the original work is properly cited.

IntechOpen

IntechOpen