

# We are IntechOpen, the world's leading publisher of Open Access books Built by scientists, for scientists

6,900

Open access books available

185,000

International authors and editors

200M

Downloads

Our authors are among the

154

Countries delivered to

TOP 1%

most cited scientists

12.2%

Contributors from top 500 universities



WEB OF SCIENCE™

Selection of our books indexed in the Book Citation Index  
in Web of Science™ Core Collection (BKCI)

Interested in publishing with us?  
Contact [book.department@intechopen.com](mailto:book.department@intechopen.com)

Numbers displayed above are based on latest data collected.  
For more information visit [www.intechopen.com](http://www.intechopen.com)



# Robotic Urological Surgery: State of the Art and Future Perspectives

Rachid Yakoubi, Shahab Hillyer and Georges-Pascal Haber  
*Center for Laparoscopic and Robotic Surgery,  
 Glickman Urological and Kidney Institute, Cleveland Clinic, Cleveland, Ohio,  
 USA*

## 1. Introduction

Minimally invasive surgery has gained popularity over the last decade by offering shorter convalescences, improved peri-operative outcomes as well as enhanced cosmesis.

Community urologists have typically performed standard laparoscopic nephrectomies secondary to its short learning curve, low complication rate, and limited requirement for sophisticated laparoscopic skills. However, advanced minimally invasive operations such as partial nephrectomies, pyeloplasties and prostatectomies necessitate advanced laparoscopic adeptness. The emergence of robotics, with 3D vision and articulated instruments, has allowed wider applications of minimally invasive techniques for more complex urological procedures.

Though robotics has overcome some shortcomings of laparoscopic surgery, there remains a limitation with its assertion as a standard amongst the urological community. The lack of tactile feedback, displacement of the surgeon from the bedside, fixed-port system, longer operating room times and cost remain barriers to widespread acceptance of robotics. In addition, the deficiencies within the robotic platform have propagated an evolution in the field with micro and nano-robotics. This chapter highlights the history of robotic surgery along with current and future applications.

## 2. The Da Vinci surgical system and urology

The da Vinci robot (Intuitive Surgical, Sunnyvale, CA, USA) (Figure 1) remains the only commercially available robotic surgical system since the fusion of computer motion and intuitive surgical system (Table 1). It is a master-slave system in which the surgeon operates the robot from a remote console. The articulating laparoscopic instruments in the da Vinci robot offer six degrees of freedom simulating the human wrist movement during open surgery. This facilitates intra-corporeal suturing especially in reconstructive surgery (Yohannes et al., 2002).

Robotic-assisted laparoscopic radical prostatectomy was first reported in 2000 using the da Vinci robot system. Since then, the robotic platform has been applied for a variety of minimally invasive procedures, such as partial nephrectomy, pyeloplasty, cystectomy and adrenalectomy.

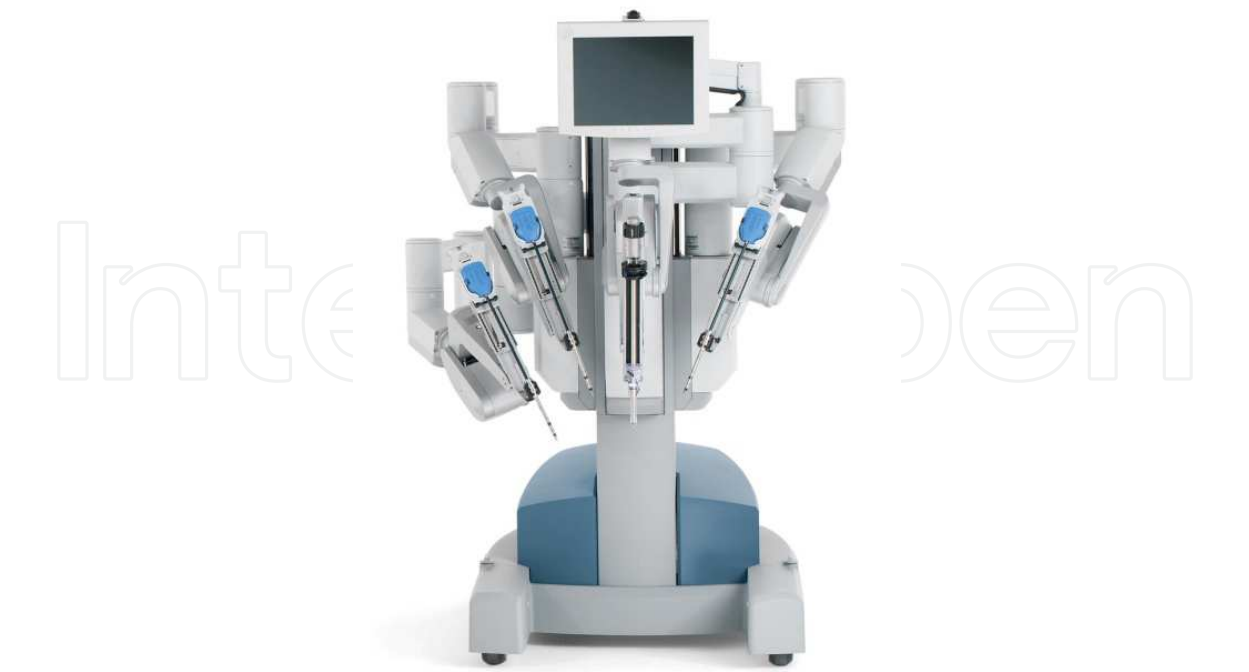

Fig. 1. Da Vinci robot

1985	First surgical robot utilization (Neurosurgery)
1989	First urologic robot (Probot)
1993	First commercially available robot approved by the FDA (AESOP)
1998	Zeus system commercially available
2000	First robotic radical prostatectomy
2001	FDA clearance for Da Vinci system
2003	The Zeus system and Intuitive Surgical fusion

Table 1. Robotic surgery timeline

2.1 Prostatectomy

Robotic-assisted laparoscopic radical prostatectomy (RARP) was first reported in 2000 (Abbou et al., 2000). Since then the number of patients undergoing RARP for prostate cancer has steadily increased. Early comparisons between radical retropubic prostatectomy (RRP) and RARP show encouraging results. Menon et al. in a prospective nonrandomized study, compared results of 30 consecutive patients undergoing (RRP) and 30 initial patients undergoing (RARP). Estimated blood loss (EBL), blood transfusions, pain score, hospital stay, and mean duration of postoperative catheterization were improved in the RARP group. However, the mean operating time increased for RARP (Menon et al. 2002). In a recent review, Ficcarra et al. found that the mean OR time for RARP ranged between 127 and 288 minutes, corroborating a longer operative time with robotics versus open. Nevertheless, transfusion rates and hospital stay were lower with RARP then open RRP. In addition there were comparable complication rates between the RARP and open RRP patients (Ficarra et al., 2009).

Positive surgical margins are a surrogate for oncological outcomes reported for RARP. A significant advantage in positive margin rates was demonstrated for RALP over RRP. This same difference amongst the robotic and open groups does not exist when comparing laparoscopic radical prostatectomy (LRP). The positive surgical margin rates ranged from 11% to 37% after RRP, from 11% to 30% after LRP, and from 9.6% to 26% after RALP (Ficarra et al., 2009).

Recently, survival outcomes have been reported after RARP. Barocas et al. compared 491 open RRP with 1,413 patients undergoing RARP, over a median follow-up of 10 months (Barocas et al., 2010). Robotic group had lower pathological stage (80.5% pT2 vs 69.6% pT2,  $p < 0.01$ ). The 3-year biochemical recurrence-free survival rate was similar between the 2 groups, even after adjusting for pathological stage, grade and margin status. More recently, comparisons of 522 consecutive RARP were matched to patients who underwent LRP and RRP evaluating oncological outcomes (Magheli et al., 2011). Positive surgical margin rates were higher in the robotic group (19%), compared to LRP (13%) and RRP (14%). This difference was not significant for pT2 disease. The mean follow-up was 2.5, 1.4 and 1.3 years for RRP, LRP and RARP respectively, with no statistically significant difference in biochemical-free survival between groups.

Erectile function and continence are major outcomes evaluated after prostatectomy. In a matched cohort, comparing 294 RARP for clinically localized prostate cancer with 588 RRP, showed no difference in continence between the 2 approaches at the 1-year follow-up (Krambeck et al. 2009). Furthermore, Roco et al showed 1year continence rates of 97% vs 88% after RARP and RRP, respectively ( $P = 0.014$ ). The 1 year overall potency recovery rate was 61% vs 41%, after RARP and RRP, respectively ( $P = 0.003$ ). Overall, RRP seems to be a faster procedure. However, EBL, hospitalization time, and functional outcomes were superior with RARP. Early oncological outcome seemed to be equivalent in the two groups (Rocco et al., 2009).

The drawback of RARP is the cost related to purchasing and maintaining the instruments of the robotic system. Bolenz et al. compared the cost of 262 RALP, 220 LRP, and 161 RRP performed at the same institution. The direct cost was higher for the robotic approach than laparoscopic or open. The median direct cost was US\$ 6752, US\$ 5687, and US\$ 4437 for RALP, LRP, and RRP respectively. The most important difference was due to surgical supply and operating room cost (Bolenz et al., 2010). However, the surgical volume may reduce this difference. Scales et al. showed that the cost of RALP is volume dependent, and cost equivalence is achievable with RRP at a surgical volume of 10 cases weekly (Scales et al., 2005). Even the cost of robotic surgery is a difficult question to assess; the cost-effectiveness of robotics will probably continue to improve with time (Wilson & Torrey, 2011).

The available data demonstrates improvements in blood loss, hospital stay, and pain control with RALP. However the lack of long term cancer specific mortality limits robust oncological comparisons of RARP to RRP.

## 2.2 Radical nephrectomy

Robotic radical and simple nephrectomy is a feasible and safe procedure. A comparison of 46 laparoscopic nephrectomies, 20 hand-assisted laparoscopic nephrectomy, and 13 robotic nephrectomies showed no significant advantage of robotics over traditional laparoscopy or hand-assisted approaches. However, cost analysis illustrated far more cost with robotics among the three groups (Boger et al., 2010).

Platforms where robotics may be applied to radical nephrectomies are complex tumors with caval thrombosis. Abaza reported five patients with a renal tumor and inferior vena cava (IVC) thrombus who underwent robotic nephrectomy. The robotic system allowed for venotomy into the vena cava with suture of the defect and no complications. (Abaza, 2011) Robotic-assisted nephrectomy was also applied for live kidney donor. A series of 35 first cases was reported with a mean warm ischemia time of 5.9 minutes. (Louis et al., 2009). However, the cost of the robotic approach may limit its applicability for radical nephrectomies except in complex renal cases with caval thrombosis.

### 2.3 Partial nephrectomy

The da Vinci Surgical System provides advantages during robotic partial nephrectomy (RPN) such as 3-D vision, articulating instruments, scaling of movement, tremor filtration, fourth robotic arm assistance, and the TilePro™ software (Intuitive surgical, Sunnyvale, CA), a live intra-operative ultrasound platform. All these tools are helpful during partial nephrectomy and may overcome the technical challenges of laparoscopic partial nephrectomy (LPN).

Since the first report by Gettman et al. showing the feasibility of robotic assisted partial nephrectomy (RPN) (Gettman et al., 2004), a steadily increasing number of series have been reported.

Forty consecutive RPN and 62 LPN were retrospectively compared in a study by Wang and colleagues showing no significant difference in EBL, collecting system repair (56% for each group), or positive margin rate (1 case in each group). Furthermore, the mean operative time, warm ischemia time (19 vs 25 minutes, for RPN and LPN respectively), and length of stay decreased significantly in the robotic group (Wang & Bhayani, 2009).

Haber et al. compared results of 150 consecutive patients who underwent RPN (n = 75) or LPN (n = 75) by a single surgeon. There was no significant difference between the 2 groups in the mean operative time (200 and 197 minutes) ( $P = .75$ ), warm ischemia time (18.2 minutes vs 20.3 minutes,  $P = .27$ ), length of hospital stay ( $P = .84$ ), change in renal function, or adverse events in the RPN and LPN groups respectively. The mean EBL was higher in the RPN group (323 vs 222 mL); surprisingly fewer patients required a blood transfusion in either group. The higher EBL with RPN may be explained by the surgeons learning curve for RPN compared with LPN. Overall these findings demonstrated comparable outcomes to LPN, regardless of the vast experience the primary laparoscopic surgeon possessed (Haber et al., 2010a).

The safety and effectiveness of RPN regarding functional and oncologic outcomes were evaluated in a multi-institutional review with 183 patients who underwent RPN (Benway et al., 2010). The means of peri-operative demographics and outcomes were analyzed illustrating a tumor size 2.87 cm, total operative time 210 min, warm ischemic time 23.9 min, and EBL of 131.5 mL. Sixty-nine percent of excised tumors were malignant, of which 2.7% had positive surgical margins. The incidence of major complications was 8.2%. At up to 26 months follow-up, there have been no recurrences and no significant change in renal function.

Additionally, indications for RPN have significantly expanded to include RPN for complex renal tumors (Rogers et al., 2008a; White et al., 2011). White et al. reviewed 67 patients who underwent RPN for a moderately or highly complex renal mass according to the R.E.N.A.L. nephrometry score ( $\geq 7$ ). The median tumor size was 3.7 cm, median operative time was 180 minutes, median EBL was 200 mL, and the warm ischemia time was 19.0 minutes (range 15-



26). After a mean follow-up of 10 months, no recurrences had occurred indicating that RPN is a safe and feasible option for highly complex renal masses (White et al., 2011).

RPN seems to be as an effective and safe alternative to LPN. Surgical technique for RPN has improved and indications have been expanded to more challenging tumors. Currently available comparative studies are retrospective and with a limited follow-up. Future trials are expected to confirm encouraging findings from early reported series.

## 2.4 Adrenalectomy

Robotic-assisted adrenalectomy (RAA) was first reported in 1999 and 2001 using the Aesop (Hubens et al., 1999) and Da Vinci systems, respectively (Horgan & Vanuno, 2001). Since then, the few studies published were about RAA using Da Vinci system.

Brunaud et al. prospectively evaluated 100 consecutive patients who underwent RAA. The mean operative time was 95 minutes with a conversion rate 5%. Complication and mortality rates were 10% and 0%, respectively. The mean operative time decreased by 1 minute every 10 cases. Operative time improved more for junior surgeons than for senior surgeons after the first 50 cases. Surgeon's experience, first assistant level and tumor size were independent predictors of operative time. The robotic procedure was 2.3 times more costly than laparoscopic adrenalectomy (Brunaud et al., 2008a).

The same authors, compared prospectively perioperative data of 50 patients who underwent RAA with 59 patients who underwent laparoscopic adrenalectomy (LA). RAA was associated with lower blood loss but longer operative times. However, the difference in operative time was not significant after the learning curve of 20 cases. Operative time increased, only in the LA group for obese patients (body mass index  $>30$  kg/m<sup>2</sup>) and patients with large tumors ( $>55$ mm). Length of hospital stay, complication and conversion rates were equivalent in the groups (Brunaud et al., 2008b).

Recently, Giulianotti et al. examined 42 patients who underwent RAA by a single surgeon. Median hospital stay was 4 days with postoperative complication rate of 2.4% and mortality rate of 2.4% (Giulianotti et al., 2011).

Suggestions have been made that robot assistance may be beneficial for obese patients with large tumors (Brunaud et al., 2008a; Giulianotti et al., 2011), as well as for surgeons with limited laparoscopic experience. Regardless of its feasibility, Prospective studies must focus on potential improve in learning curve with robotic utilization along with a cost analysis evaluating RAA compared to current standards. (Brunaud et al., 2008a)

## 2.5 Pyeloplasty

The first clinical experience of robot-assisted pyeloplasty (RAP) was reported in 2002 (Gettman et al., 2002a). Since then, numerous studies have evaluated the efficiency of RAP. Gupta et al. prospectively evaluated results of 85 consecutive patients who had transperitoneal RAP, using four or five ports. Based on anatomic considerations, different types of pyeloplasty were completed. The mean operative time was 121 min, 47 min of which was for the anastomosis. Mean EBL was 45 mL, with hospital stay of 2.5 days. Three patients had stent migrations, and delayed drainage. Mean follow-up was 13.6 months with an overall success rate of 97%, based on imaging assessment (Gupta et al., 2010).

In a comparative non-randomized study, 98 RAP were compared with 74 LP with a mean operative time of 189.3 and 186.6 minutes for RAP and LP respectively. Complication rate was similar with 5.1% and 2.7% for RAP and LP respectively. The suturing time was shorter

for the RAP but without statistical significance (48.3 and 60 minutes ( $P = 0.30$ ) for RAP and LP respectively). RAP had a success rate of 93.4% versus 95% for LP based on renal scintigraphy (Bird et al., 2011).

Hemal and colleagues illustrated successful application of robotics to pyeloplasty surgery. A nonrandomized study, comparing results of 30 RAP with 30 LP, performed in a transperitoneal approach by a single surgeon. The mean total operating times were 98 minutes and 145 minutes, the mean EBL were 40 mL and 101 mL, and the mean hospital stay of the patients were 2 days and 3.5 days, for RAP and LP, respectively. At follow up, one patient in LP group had obstruction managed by balloon dilation (Hemal et al., 2010).

Insufficient evidence exists for the retroperitoneal approach to RAP. Kaouk et al. reported results of 10 patients who underwent retroperitoneal RAP. Four ports were placed for the robot and a successful operation was accomplished. Operative time was 175 mins with minimal complications. The advantage to the retroperitoneal approach was the direct access to the UPJ; however, retroperitoneal surgery has limited working space with unfamiliar anatomy to most urologist (Kaouk et al., 2008).

Cestari et al. compared 36 patients who underwent retroperitoneal RAP and 19 transperitoneal RAP for UPJO. Median operative time and hospital stay were similar. Complication rates were comparable. (Cestari et al., 2010).

Studies of RAP demonstrate feasibility, efficacy and safety. However, the cost of robotic surgery continues to limit the widespread application of this platform.

## 2.6 Cystectomy

Radical cystectomy with pelvic lymphadenectomy (PLND) remains the gold-standard treatment for patients with muscle-invasive bladder cancer. However, morbidity related to open radical cystectomy (ORC) presents a real challenge. Thus, robotic-assisted radical cystectomy (RRC) represents a potential alternative to the open approach. Similar to other robotic procedures, the potential advantages of RRC over ORC are decrease in blood loss, pain, and hospital stay. On the other hand, the oncologic outcomes of the RRC remain largely unknown.

In a series of 100 consecutive patients who underwent RRC for clinically localized bladder cancer, the mean operative time was 4.6 hours and an EBL 271 ml. Mean hospital stay was 4.9 days with 36 patients experiencing postoperative complications; 8% major complications. Urinary diversion included, ileal conduits 61 % of the time (Pruthi et al., 2010).

Kauffman et al. presented results of 85 consecutive patients treated with RRC for bladder cancer. The median age was 73.5 years with high proportion of patients having comorbidities (46% of ASA class  $\geq 3$ ). Extended pelvic lymphadenectomy was performed in almost all patients (98%). Extravesical disease was found in 36.5% cases and positive surgical margins were present in 6% of patients. At a mean follow-up of 18 months, 20 (24%) patients had presented recurrence; three of them (4%) only had a local recurrence. The overall survival and disease-specific survival rates for the cohort at 2 years were 79% and 85%, respectively. Extravesical disease, positive lymph node, and lymphovascular invasion were associated with worse prognosis (Kauffman et al., 2011). Even with the encouraging results of this study, comparative analysis and long term outcomes are still needed.

Josephson et al., in his report of 58 RRC, found different results, with a overall survival rate of 54% and disease specific survival rates of 76% at 2-year (Josephson et al., 2010). However, stratification of survival outcomes by pathological stage was not reported, making comparisons with other studies futile.

In an others series of 100 patients with a mean follow up of 21 months, 15 patients had disease recurrence and 6 died of bladder cancer (Pruthi et al., 2010). Comparisons between open and robotic cystectomy are lacking because of the heterogeneity in disease burden and patient selection.

In a multi-institutional study, of the 527 patients who underwent RRC, 437 (82.9%) had a lymphadenectomy. Surgeons experience on the robot influenced whether a lymphadenectomy was performed (Hellenthal, 2010a). In the same data base, the Positive surgical margin was 6.5% (Hellenthal, 2010b). In a study of 100 consecutive patients with RRC, no positive margin was found (Pruthi et al., 2010). However in this series only 13% cases were pT3/T4 at the final pathology, which may explain this result.

RRC offers the potential for improving peri-operative outcomes with the advantages of minimally invasive surgery. It may offer shorter hospital stay, decrease blood loss and pain, and offer a smaller incision, with equal complication rates and oncological outcomes to the current gold standard, ORC. Future studies with longer follow up are essential to have robust data on the comparability of RRC to ORC

### **3. Robotic laparoendoscopic single-site surgery and natural orifice transluminal endoscopic surgery: Current status**

Laparoendoscopic single-site surgery (LESS) (Figure. 2) and natural orifice transluminal endoscopic surgery (NOTES) exploit the use of a single incision or natural entry points into the body cavity. A trend towards scareless surgery with the advantages of laparoscopy has fueled the development of a novel surgical technique, LESS and NOTES.

The first laparoscopic transvaginal nephrectomy (NOTES) in a porcine model was described in 2002, introducing another achievable surgical approach (Gettman et al, 2002b). Moreover, the continued dynamism for workable new approaches sprung the inception of the first reported hybrid NOTES nephrectomy in a porcine model utilizing the da Vinci surgical system (Box et al., 2008).

Robotic technologies offer a potential improvement over the current flexible instruments and endoscopes. Other limitations include the indirect transmission of forces and space constraints for the operating surgeon (Table 2).

In 2008, 30 urologic robotic NOTES procedures on 10 porcine models were performed using the current da Vinci robotic system (Haber et al., 2008a). A 12 and an 8-mm port were placed through a single transumbilical incision to introduce the robotic camera along with a robotic arm using a single port (Uni-X (TM) P-navel Systems, Morganville, NJ). A flexible 12-mm cannula 20cm long (US Endoscopy, Mentor, Ohio, USA) served as a transvaginal port, through which the second robotic arm was docked. All interventions were conducted without complications or conversion. However, problems encountered included the inadequate length of transvaginal instruments, essentially prolonging surgical time. In order for widespread use of newer approaches, development of appropriate instruments should simultaneously occur.

The Da Vinci® S robotic system using a LESS approach has also been applied to prostate surgery. A transvesical robotic radical prostatectomy was performed in a cadaver model (Desai et al., 2008a) (Figure. 3). Articulated instruments and 3D vision facilitated the dissection of the prostate through the single-port. Moreover, architectural advances with the robotic system will allow accessibility to a wider range of surgeons interested in LESS and NOTES approaches. An example of robotic modifications helping the growth of LESS came



with the advent of the novel robotic platform (VeSPA, Intuitive Surgical, California, USA) (Figures. 4 & 5). These curved cannulae and semi-rigid instruments have been designed to compensate for the limitations encountered with conventional LESS surgery. The VeSPA curved cannulae and semirigid instrument design allow the cannulae and instruments to be inserted in close proximity while allowing approximate triangulation intra-abdominally. The VESPA platform was successfully applied in a porcine model without conversions or addition of ports (Haber et al., 2010b). However, it is recognized that Robotic-LESS for the kidney is technically more challenging in humans compared to animal model. Therefore, further clinical research is required to confirm these early experimental results.

	Standard LESS	Da Vinci robotic LESS
Scope	Two-dimensional vision, high resolution, unstable vision	Three-dimensional vision, high definition, stable vision
Instruments	Straight and articulating/flexible instruments	Articulating instruments
Triangulation	Lacking (crossed hand surgery)	Lacking (chopstick surgery)
Instrument collision	Significant	Significant (due to bulky robotic arms)
Range of motion	Limited	Enhanced surgeon dexterity because of the Endowrist technology
Tissue dissection	Challenging	Limited at steep angles
Suturing	Extremely challenging	Accurate
Ergonomics	Reduced	Enhanced (surgeon sitting at console)
Main assistant's role	Camera manoeuvring	Managing collisions
Steepness of learning curve	Very high	Medium high

Table 2. From laparoendoscopic single-site surgery to robotic laparoendoscopic single-site surgery: technical advances with da Vinci system

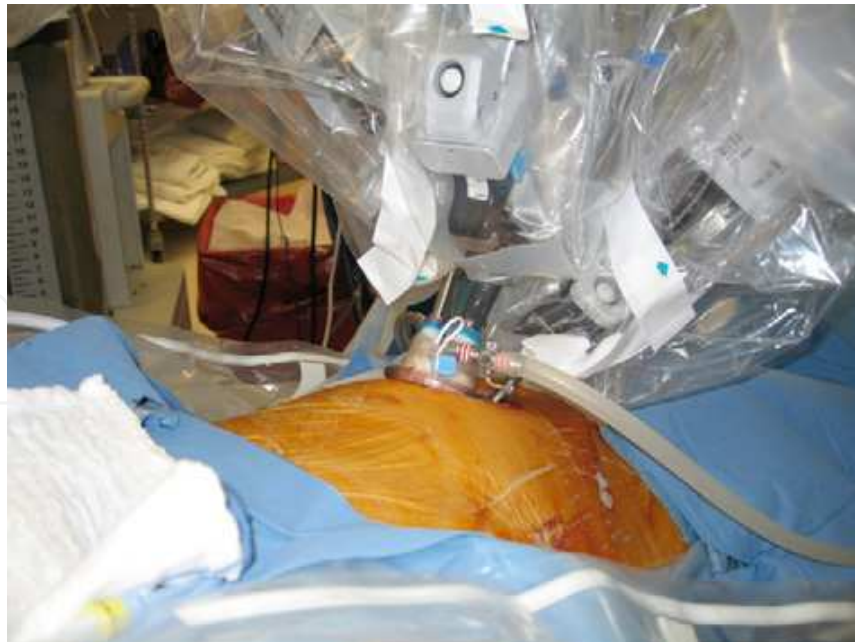

Fig. 2. The robot scope and two arms are inserted through a 2.5-cm incision in the umbilicus

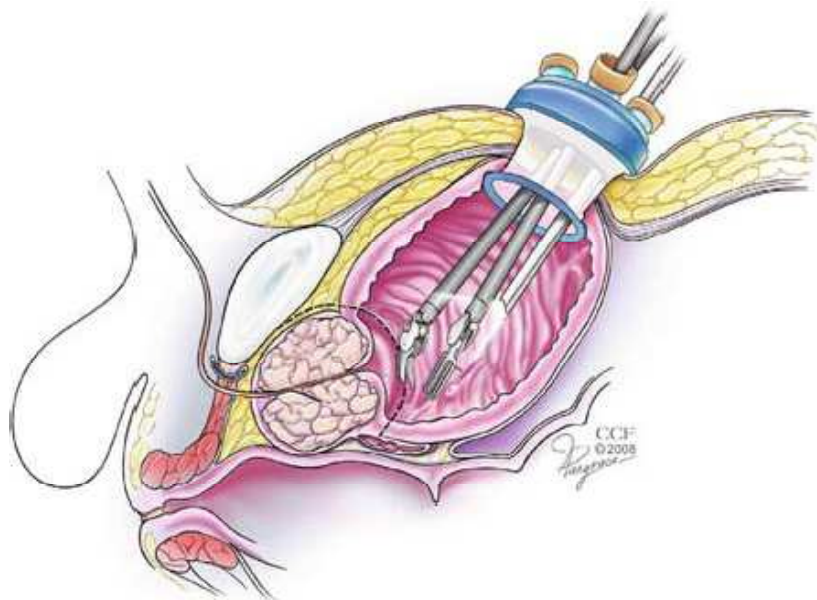


Fig. 3. Single-port and robot instruments through the bladder

The initial clinical experience with robotic single-port transumbilical surgery was reported in 2009 (Kaouk et al, 2009a). A multichannel single port (R-port; Advanced Surgical Concepts, Dublin, Ireland) was inserted through a 2-cm umbilical incision into the abdomen. Three procedures were performed, including radical prostatectomy, dismembered pyeloplasty, and right sided radical nephrectomy. All procedures were completed without intraoperative complications. The radical prostatectomy was completed in 5 h, with 45 min required for the anastomosis. The pathology reported negative margins. The pyeloplasty was completed in 4.5 h, and the radical nephrectomy was completed in 2.5 h. R-LESS procedures were accomplished without additional ports or significant differences in peri-operative outcomes compared to standard robotic approaches.

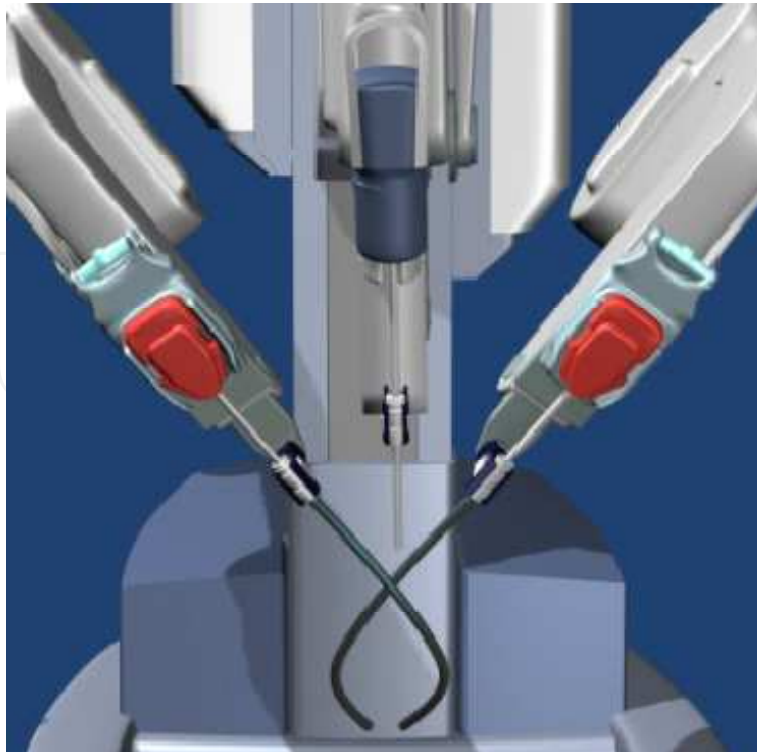


Fig. 4. Da Vinci® robotic with VeSPA instruments

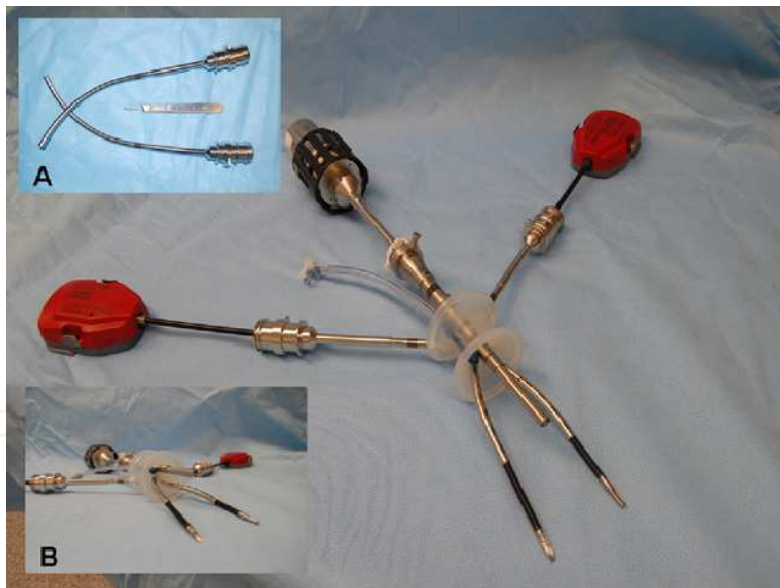

Fig. 5. VeSPA instruments and accessories. (A) Curved cannulae; (B) multichannel single-port, 8.5-mm robotic scope, flexible instruments passed through the cannulae

We recently reported our initial experience with single port robotic partial nephrectomy in two patients without conversions or complications (Kaouk et al. 2009b). A multichannel port (Triport; Advanced Surgical Concepts, Bray, Co Wicklow, Ireland) was utilized. Pediatric 5-mm robotic instruments were used. A 30° robotic lens placed in the upward configuration minimized clashing between the scope and instruments. A 2.8 cm left lower pole tumor and a 1.1 cm right lower pole tumor were excised without renal hilar clamping using the

harmonic scalpel. EBL was 100 ml, operative time was 170 min, length of stay was 3.5 days, and visual analog pain scale at discharge was 1.0/10.

Stein et al. reported robotic LESS using a gel port (Applied Medical, Rancho Santa Margarita, California, USA) as the access platform (Stein et al., 2010). Four clinical procedures were performed, including two pyeloplasties, one radical nephrectomy, and one partial nephrectomy. The gel port system was used to allow for a larger working platform. The partial nephrectomy was completed in 180 min. The mass was excised without hilar clamping, using the harmonic scalpel and Hem-o-lok clips (Weck Closure Systems, Research Triangle Park, North Carolina, USA). A radical nephrectomy was performed for a 5-cm left-sided lower pole mass. The renal vein and artery were secured with an endoscopic stapler, and the remainder of the dissection was completed with hook cautery. The specimen was retrieved with an entrapment sac and removed via the umbilical incision extended to 4 cm. EBL was 250 ml, operative time was 200 min, and the hospital stay was 2 days.

The Da Vinci system has several advantages over conventional laparoscopy allowing an increasing number of urologist adopt this method. Preliminary results of these minimal invasive approaches are encouraging in LESS and NOTES techniques. Further refinement in instrumentation, improved triangulation and development of robotic systems specific to LESS and NOTES may define the new horizons in single site surgery.

#### 4. Flexible robots

The development of robotic technologies has also flourished in endoscopic surgeries. A flexible robotic catheter manipulator (Sensei, Hansen Medical, Mountain View, CA, USA) thought to allow enhanced ergonomics with improved efficiency over standard flexible ureteroscopy was developed by Sensei, Hansen medical. Initial experience in the porcine model showed promising outcomes.

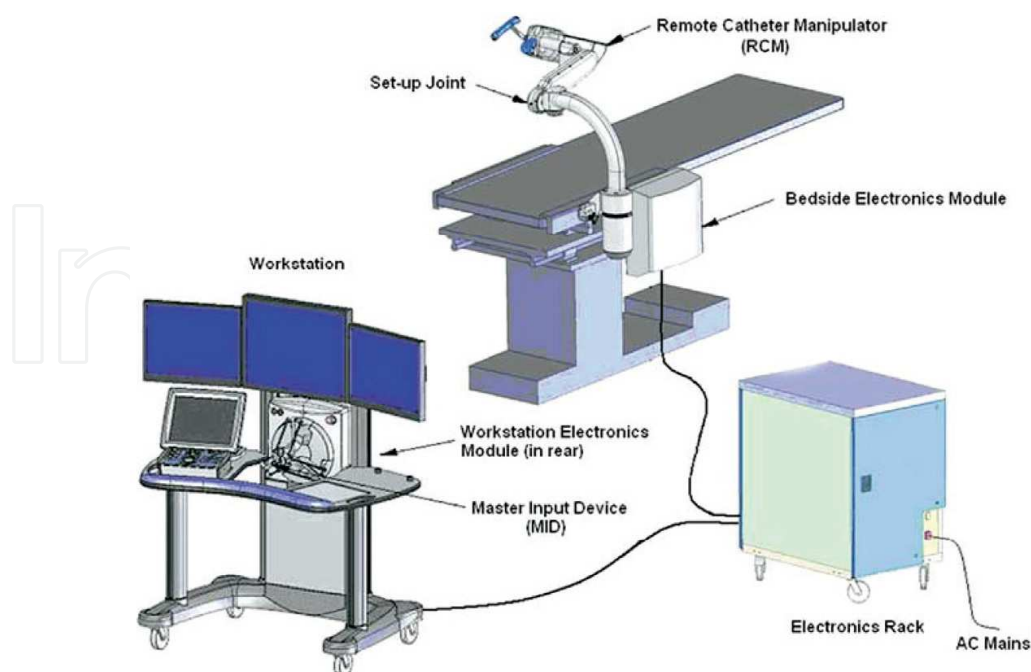


Fig. 6. Pictorial depiction of components of flexible robotic catheter control system. Surgeon console (workstation) showing three LCD screens, one touch screen, and MID





Fig. 7. Robotic arm and steerable catheter

The novel robotic catheter system comprises the following components (Figure. 6 & 7), (a) surgeon console, including the LCD display and master input device, (b) steerable catheter system, (c) remote catheter manipulator, and (d) electronic rack. The master input device (MID) is a three-dimensional joystick the surgeon uses to remotely maneuver the catheter tip. The real-time image of ureteroscopy, fluoroscopy and representation in space of the catheter position is projected simultaneously on the screens. Furthermore, images from the CT scan or an ultrasound probe images display.

The steerable catheter system contains an outer catheter sheath (14F/12F) and an inner catheter guide (12F/10F). The movement of the MID intuitively controls the tip of the catheter guide. The robotic arm, steerable catheter, is attached to the edge of the table. The catheter can be controlled either by fluoroscopy mode, direct vision from the ureteroscope or by a combination of both. In addition, a 3D reconstruction of the extremity the catheter is displayed on the screen, assisting in the identifying the location. Moreover, manoeuvrability is not diminished when the use of fiber laser 200 to 365 microns.

The technical feasibility of the robotic catheter system was evaluated in retrograde renoscopy in the porcine model. Authors concluded that the robotic catheter system could easily manoeuvre the ureteroscope into 83 (98%) of the 85 calices tested in a reproducible manner. The ease and reproducibility of intra-renal navigation was rated at a mean of 10 on the VAS (Desai et al., 2008b). Clinical investigation for flexible robotic system in ureteroscopy was performed in 18 patients who had renal calculi. Mean stone size was 11.9 mm. All procedures were done unilaterally and all patients had ureteral stents placed for 2 weeks. The robotic catheter system was introduced into the renal collecting system manually using fluoroscopic control along a guide wire. All intra-renal manoeuvres were performed completely by the surgeon from the robotic console. All procedures were technically successful, and all calculi were fragmented to the surgeon's satisfaction, without conversion to standard ureteroscopy. Mean operative time was 91 minutes, including a robot docking time of 7 minutes, and stone localization time of 9 minutes. The mean visual analog scale rating (from 1, worst, to 10, best) for ease of stone localization was 8.3, ease of maneuvering was 8.5, and ease of fragmentation was 9.2. Complete fragment clearance was achieved in 56% of patients at 2 months, and in 89% of patients at 3 months. One patient required secondary ureteroscopy for a residual stone (Desai et al, 2008c)

Improvements in flexible instrumentation have brought a revolution with retrograde intra-renal surgery. Advancements in flexible ureteroscopes, laser lithotripsy, and ureteroscope accessories are contributors to the metamorphosis with robotics in endo-urolgy.



Miniaturization has been the key advancement for the progression of robotics in endoscopy. Further studies are needed to corroborate these early clinical results.

## 5. Robotic prostate biopsy

Incorporation of real-time radiographic imaging for biopsy or ablative treatment of urological cancer is currently in development. A robotic arm Vicky® (Endo-Control, Grenoble, France) and an ultra-sound probe (B-K Medical, Denmark), were utilized to perform transrectal prostate biopsies. The software was modified to save up to 24 spatial coordinates and answer the constraints of transrectal ultrasound. Tests on phantom and human cadaver prostates demonstrated the feasibility of robotic transrectal ultrasound, with precision biopsies performed on a target tumor ranging from (0.1 to 0.9 mm) on the prostate and (0.2 to 0.9 mm) on the phantom (Figure. 8). Initial results are encouraging with clinical trials forthcoming (Haber et al., 2008b).

Moreover, a robotic positioning system with a biplane ultrasound probe on a mobile horizontal platform was used to perform prostate biopsies in a phantom model. . The integrated software acquires ultrasound images for three-dimensional modeling, coordinates target planning and directs the robotic positioning system. A repeatable accuracy of <1 mm was obtained (Ho et al., 2009). This robotic prostate biopsy system can theoretically biopsy targets from MRI images after merging the ultrasound images, allowing treatment of positive areas found on biopsies.

Presently, a fully automated robot system, the MrBot, has been developed for transperineal prostate access. (Patriciu et al., 2007). It is mounted alongside the patient in the MR imager and is operated from the control room under image feedback. The robot presents 6 degrees of freedom: 5 for positioning and orienting the injector and 1 for setting the depth of needle insertion. The first driver was developed for fully automated low-dose (seed) brachytherapy. Compared with classic templates for needle guides, the robot enables additional freedom of motion for better targeting. As such, multiple needle insertions can be performed through the same skin entry point. In addition, angulations reduce the pubic arch interference, allowing better prostate access for sampling. The MrBot robot was constructed to be ubiquitous with medical imaging equipment such as ultrasound and MRI. An accuracy of  $0.72 \pm 0.36$  mm was described for seed placement. Furthermore, multiple clinical interventions are possible with the MrBot system, such as biopsy, therapy injections, and radiofrequency ablations. Preclinical testing in cadaver and animal models has shown favorable results (Mozer et al., 2009).

## 6. Future trends in the design and application of surgical robots

Advances in robotic systems accompanied by trends toward miniature devices, microrobots and eventually nanorobots, are realistic near future advancements.

Prototypes of the Microrobot cameras (15 mm / 3 inches) were placed inside the abdomen of a canine model during laparoscopic prostatectomy and nephrectomy allowing for additional views (360-degree) of the surgical field. The microrobot was mobile, controlled remotely to desired locations, further aiding the laparoscopic procedures (Joseph et al., 2008).

More recently, Lehman et al. showed the feasibility of LESS cholecystectomy in a porcine model, using a miniature robot platform (Lehman et al., 2011). The robot platform incorporated a dexterous in-vivo robot and a remote surgeon interface console. In addition,

multiple robots could be inserted through a single incision rather than the traditional use of multiple port sites. Capabilities such as tissue retraction, single incision surgery, supplementary visualization, or lighting can be delivered by these micro-robots.

A well-known limitation of the current robotic platform is the lack of tactile feedback. However, the improved visualization and accuracy of robotic instrumentation may overcome this limitation. Furthermore, newer technologies with multiple compact robots, tracking tools, and tactile feedback apparatus may further expand the application of robotic surgery.

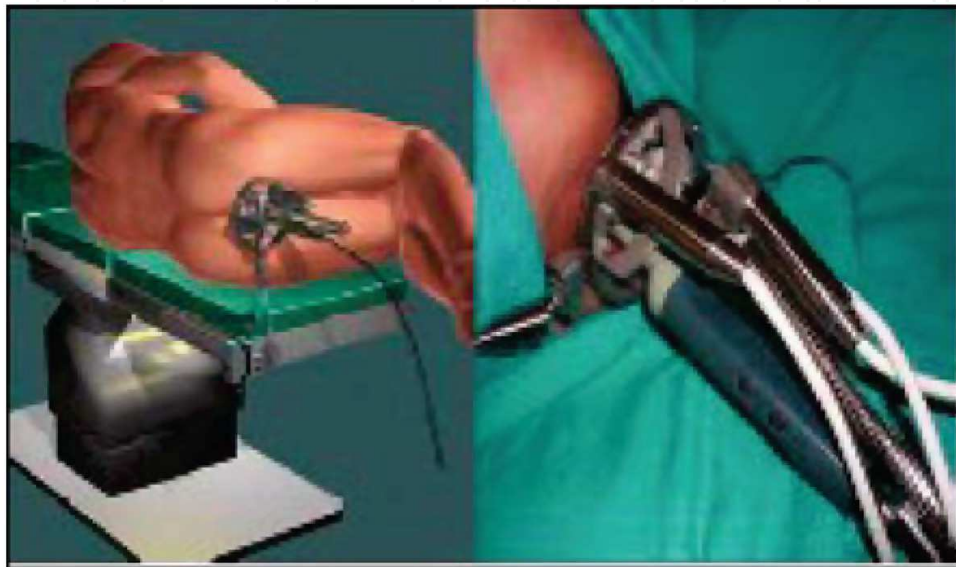

Fig. 8. Robot installation for tranrectal prostate biopsies

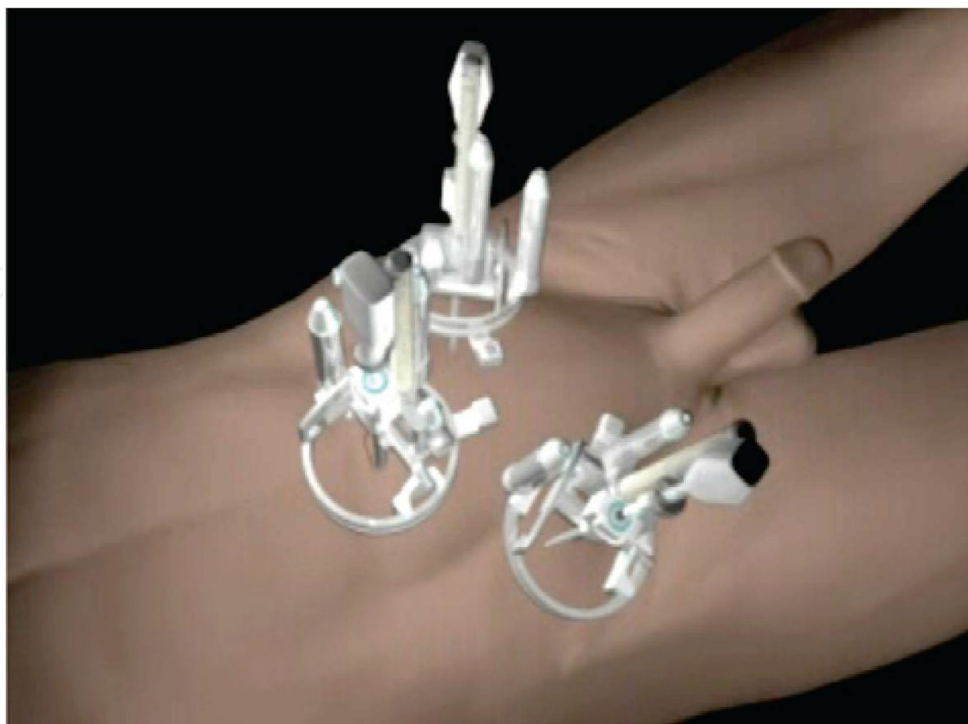

Fig. 9. The combination of multiple compact robots

## 7. Conclusion

Robotic applications in urology are effective and safe technologies. Surgical technique have evolved and indications have been expanded to more challenging scenarios. New technologies are constantly reshaping the urological sphere especially robotics. Further refinements in robotic systems along with a reduction in cost are key components for rapid assimilation amongst the urological community.

## 8. References

- Abaza R. (2011) Initial series of robotic radical nephrectomy with vena caval tumor thrombectomy. *Eur Urol.* 2011 Apr;59(4):652-6.
- Abbou CC, Hoznek A, Salomon L, Lobontiu A, Saint F, Cicco A, Antiphon P, & Chopin D. (2000) [Remote laparoscopic radical prostatectomy carried out with a robot. Report of a case]. *Prog Urol.* 2000 Sep;10(4):520-3.
- Barocas DA, Salem S, Kordan Y, Herrell SD, Chang SS, Clark PE, Davis R, Baumgartner R, Phillips S, Cookson MS, & Smith JA Jr. (2010) Robotic assisted laparoscopic prostatectomy versus radical retropubic prostatectomy for clinically localized prostate cancer: comparison of short-term biochemical recurrence-free survival. *J Urol.* 2010 Mar;183(3):990-6.
- Bird VG, Leveillee RJ, Eldefrawy A, Bracho J, & Aziz MS. (2011) Comparison of robot-assisted versus conventional laparoscopic transperitoneal pyeloplasty for patients with ureteropelvic junction obstruction: a single-center study. *Urology.* 2011 Mar;77(3):730-4.
- Benway BM, Bhayani SB, Rogers CG, Porter JR, Buffi NM, Figenshau RS, & Mottrie A. (2010) Robot-assisted partial nephrectomy: an international experience. *Eur Urol.* 2010 May;57(5):815-20.
- Boger M, Lucas SM, Popp SC, Gardner TA, & Sundaram CP. (2010) Comparison of robot-assisted nephrectomy with laparoscopic and hand-assisted laparoscopic nephrectomy. *JSLs.* 2010 Jul-Sep;14(3):374-80.
- Bolenz C, Gupta A, Hotze T, Ho R, Cadeddu JA, Roehrborn CG, Lotan Y. (2010) Cost comparison of robotic, laparoscopic, and open radical prostatectomy for prostate cancer. *Eur Urol.* 2010 Mar;57(3):453-8.
- Box GN, Lee HJ, Santos RJ, Abraham JB, Louie MK, Gamboa AJ, Alipanah R, Deane LA, McDougall EM, & Clayman RV. (2008) Rapid communication: robot-assisted NOTES nephrectomy: initial report. *J Endourol.* 2008 Mar;22(3):503-6.
- Brunaud L, Ayav A, Zarnegar R, Rouers A, Klein M, Boissel P, & Bresler L. (2008a) Prospective evaluation of 100 robotic-assisted unilateral adrenalectomies. *Surgery.* 2008a Dec;144(6):995-1001.
- Brunaud L, Bresler L, Ayav A, Zarnegar R, Raphoz AL, Levan T, Weryha G, & Boissel P. (2008b) Robotic-assisted adrenalectomy: what advantages compared to lateral transperitoneal laparoscopic adrenalectomy? *Am J Surg.* 2008b Apr;195(4):433-8.
- Cestari A, Buffi NM, Lista G, Sangalli M, Scapaticci E, Fabbri F, Lazzeri M, Rigatti P, & Guazzoni G. (2010) Retroperitoneal and transperitoneal robot-assisted pyeloplasty in adults: techniques and results. *Eur Urol.* 2010 Nov;58(5):711-8.


- Desai MM, Aron M, Berger A, Canes D, Stein R, Haber GP, Kamoi K, Crouzet S, Sotelo R, Gill IS. (2008a) Transvesical robotic radical prostatectomy. *BJU Int.* 2008a Dec;102(11):1666-9.
- Desai MM, Aron M, Gill IS, Haber GP, Ukimura O, Kaouk JH, Stahler G, Barbagli F, Carlson C, & Moll F. (2008b) Flexible robotic retrograde renoscopy: description of novel robotic device and preliminary laboratory experience. *Urology.* 2008b Jul;72(1):42-6.
- Desai MM, Grover R, Aron M, Haber GP, Ganpule A, Kaouk I, Desai M, & Gill IS. (2008c) Remote robotic ureteroscopic laser lithotripsy for renal calculi: initial clinical experience with a novel flexible robotic system. *J Urol* 2008c; 179(4S):435 [Abstract # 1268].
- Ficarra V, Novara G, Artibani W, Cestari A, Galfano A, Graefen M, Guazzoni G, Guillonnet B, Menon M, Montorsi F, Patel V, Rassweiler J, & Van Poppel H. (2009) Retropubic, laparoscopic, and robot-assisted radical prostatectomy: a systematic review and cumulative analysis of comparative studies. *Eur Urol.* 2009 May;55(5):1037-63.
- Gettman MT, Neururer R, Bartsch G, & Peschel R. (2002a) Anderson-Hynes dismembered pyeloplasty performed using the da Vinci robotic system. *Urology* (2002a) 60(3), 509-513
- Gettman MT, Lotan Y, Napper CA, & Cadeddu JA. (2002b) Transvaginal laparoscopic nephrectomy: development and feasibility in the porcine model. *Urology* 2002b; 59:446-450.
- Gettman MT, Blute ML, Chow GK, Neururer R, Bartsch G, & Peschel R. (2004) Robotic-assisted laparoscopic partial nephrectomy: technique and initial clinical experience with DaVinci robotic system. *Urology.* 2004 Nov;64(5):914-8.
- Giulianotti PC, Buchs NC, Addeo P, Bianco FM, Ayloo SM, Caravaglios G, & Coratti A. (2011) Robot-assisted adrenalectomy: a technical option for the surgeon? *Int J Med Robot.* 2011 Mar;7(1):27-32.
- Gupta NP, Nayyar R, Hemal AK, Mukherjee S, Kumar R, & Dogra PN. (2010) Outcome analysis of robotic pyeloplasty: a large single-centre experience. *BJU Int.* 2010 Apr;105(7):980-3.
- Haber GP, Crouzet S, Kamoi K, Berger A, Aron M, Goel R, Canes D, Desai M, Gill IS, & Kaouk J. (2008a) Robotic NOTES (Natural Orifice Translumenal Endoscopic Surgery) in reconstructive urology: initial laboratory experience. *Urology.* 2008a Jun;71(6):996-1000.
- Haber GP, Kamoi K, Vidal C, Koenig P, Crouzet S, Berger A, Aron M, Kaouk J, Desai M, & Gill IS. (2008b) Development and Evaluation of a Transrectal Ultrasound Robot for Targeted Biopsies and Focal Therapy of Prostate Cancer. *EUS 2008 Annual Meeting*; 2008b. p. 85.
- Haber GP, White WM, Crouzet S, White MA, Forest S, Autorino R, & Kaouk JH. (2010a) Robotic versus laparoscopic partial nephrectomy: single-surgeon matched cohort study of 150 patients. *Urology.* 2010a Sep;76(3):754-8.
- Haber GP, White MA, Autorino R, Escobar PF, Kroh MD, Chalikonda S, Khanna R, Forest S, Yang B, Altunrende F, Stein RJ, & Kaouk J. (2010b) Novel robotic da Vinci instruments for laparoendoscopic single-site surgery. *Urology.* 2010b Dec;76(6):1279-82.



- Hellenthal NJ, Hussain A, Andrews PE, Carpentier P, Castle E, Dasgupta P, Kaouk J, Khan S, Kibel A, Kim H, Manoharan M, Menon M, Mottrie A, Ornstein D, Palou J, Peabody J, Pruthi R, Richstone L, Schanne F, Stricker H, Thomas R, Wiklund P, Wilding G, & Guru KA. (2011) Lymphadenectomy at the time of robot-assisted radical cystectomy: results from the International Robotic Cystectomy Consortium. *BJU Int.* 2011 Feb;107(4):642-6.
- Hellenthal NJ, Hussain A, Andrews PE, Carpentier P, Castle E, Dasgupta P, Kaouk J, Khan S, Kibel A, Kim H, Manoharan M, Menon M, Mottrie A, Ornstein D, Palou J, Peabody J, Pruthi R, Richstone L, Schanne F, Stricker H, Thomas R, Wiklund P, Wilding G, & Guru KA. (2010) Surgical margin status after robot assisted radical cystectomy: results from the International Robotic Cystectomy Consortium. *J Urol.* 2010 Jul;184(1):87-91.
- Hemal AK, Mukherjee S, & Singh K. (2010) Laparoscopic pyeloplasty versus robotic pyeloplasty for ureteropelvic junction obstruction: a series of 60 cases performed by a single surgeon. *Can J Urol.* 2010 Feb;17(1):5012-6.
- Ho HS, Mohan P, Lim ED, Li DL, Yuen JS, Ng WS, Lau WK, & Cheng CW. (2009) Robotic ultrasound-guided prostate intervention device: system description and results from phantom studies. *Int J Med Robot.* 2009 Mar;5(1):51-8
- Horgan S, Vanuno D. (2001) Robots in laparoscopic surgery. *J Laparoendosc Adv Surg Tech* 2001;11:415-9. 15.
- Hubens G, Ysebaert D, Vaneerdeweg W, Chapelle T, & Eyskens E. (1999) Laparoscopic adrenalectomy with the aid of the AESOP 2000. *Acta Chir Belg* 1999;99:125-9.
- Joseph JV, Oleynikov D, Rentschler M, Dumpert J, & Patel HR. (2008) Microrobot assisted laparoscopic urological surgery in a canine model. *J Urol.* 2008 Nov;180(5):2202-5.
- Josephson DY, Chen JA, Chan KG, Lau CS, Nelson RA, & Wilson TG. (2010) Robotic-assisted laparoscopic radical cystoprostatectomy and extracorporeal continent urinary diversion: highlight of surgical techniques and outcomes. *Int J Med Robot.* 2010 Sep;6(3):315-23.
- Kaouk JH, Hafron J, Parekattil S, Moinzadeh A, Stein R, Gill IS, & Hegarty N. (2008) Is retroperitoneal approach feasible for robotic dismembered pyeloplasty: initial experience and long-term results. *J Endourol.* 2008 Sep;22(9):2153-9.
- Kaouk JH, Goel RK, Haber GP, Crouzet S, Stein RJ. (2009a) Robotic single-port transumbilical surgery in humans: initial report. *BJU Int.* 2009a Feb;103(3):366-9.
- Kaouk JH, Goel RK. (2009b) Single-port laparoscopic and robotic partial nephrectomy. *Eur Urol* 2009b; 55:1163-1169.
- Kauffman EC, Ng CK, Lee MM, Otto BJ, Wang GJ, & Scherr DS. (2011) Early oncological outcomes for bladder urothelial carcinoma patients treated with robotic-assisted radical cystectomy. *BJU Int.* 2011 Feb;107(4):628-35.
- Krambeck AE, DiMarco DS, Rangel LJ, Bergstralh EJ, Myers RP, Blute ML, & Gettman MT. (2009) Radical prostatectomy for prostatic adenocarcinoma: a matched comparison of open retropubic and robot-assisted techniques. *BJU Int.* 2009 Feb;103(4):448-53.
- Lehman AC, Wood NA, Farritor S, Goede MR, & Oleynikov D. (2011) Dexterous miniature robot for advanced minimally invasive surgery. *Surg Endosc.* 2011 Jan;25(1):119-23.
- Louis G, Hubert J, Ladriere M, Frimat L, & Kessler M. (2009) [Robotic-assisted laparoscopic donor nephrectomy for kidney transplantation. An evaluation of 35 procedures]. *Nephrol Ther.* 2009 Dec;5(7):623-30



- Magheli A, Gonzalgo ML, Su LM, Guzzo TJ, Netto G, Humphreys EB, Han M, Partin AW, & Pavlovich CP. (2011) Impact of surgical technique (open vs laparoscopic vs robotic-assisted) on pathological and biochemical outcomes following radical prostatectomy: an analysis using propensity score matching. *BJU Int.* 2011 Jun;107(12):1956-62.
- Menon M, Tewari A, Baize B, Guillonneau B, & Vallancien G. (2002) Prospective comparison of radical retropubic prostatectomy and robot-assisted anatomic prostatectomy: the Vattikuti Urology Institute experience. *Urology.* 2002 Nov;60(5):864-8.
- Mozier PC, Partin AW, & Stoianovici D. (2009) Robotic image-guided needle interventions of the prostate. *Rev Urol.* 2009 Winter;11(1):7-15
- Patriciu A, Petrisor D, Muntener M, Mazilu D, Schär M, & Stoianovici D. (2007) Automatic brachytherapy seed placement under MRI guidance. *IEEE Trans Biomed Eng.* 2007 Aug;54(8):1499-506
- Pruthi RS, Nielsen ME, Nix J, Smith A, Schultz H, & Wallen EM. (2010) Robotic radical cystectomy for bladder cancer: surgical and pathological outcomes in 100 consecutive cases. *J Urol.* 2010 Feb;183(2):510-4.
- Rocco B, Matei DV, Melegari S, Ospina JC, Mazzoleni F, Errico G, Mastropasqua M, Santoro L, Detti S, & de Cobelli O. (2009) Robotic vs open prostatectomy in a laparoscopically naive centre: a matched-pair analysis. *BJU Int.* 2009 Oct;104(7):991-5.
- Rogers CG, Singh A, Blatt AM, Linehan WM, & Pinto PA. (2008a) Robotic partial nephrectomy for complex renal tumors: surgical technique. *Eur Urol.* 2008a Mar;53(3):514-21
- Scales CD Jr, Jones PJ, Eisenstein EL, Preminger GM, & Albala DM. (2005) Local cost structures and the economics of robot assisted radical prostatectomy. *J Urol.* 2005 Dec;174(6):2323-9.
- Stein RJ, White WM, Goel RK, Irwin BH, Haber GP, & Kaouk JH. (2010) Robotic laparoendoscopic single-site surgery using GelPort as the access platform. *Eur Urol.* 2010 Jan;57(1):132-6
- Wang AJ, Bhayani SB. (2009) Robotic partial nephrectomy versus laparoscopic partial nephrectomy for renal cell carcinoma: single-surgeon analysis of >100 consecutive procedures. *Urology.* 2009 Feb;73(2):306-10.
- White MA, Haber GP, Autorino R, Khanna R, Hernandez AV, Forest S, Yang B, Altunrende F, Stein RJ, & Kaouk JH. (2011) Outcomes of robotic partial nephrectomy for renal masses with nephrometry score of  $\geq 7$ . *Urology.* 2011 Apr;77(4):809-13.
- Wilson T, Torrey R. (2011) Open versus robotic-assisted radical prostatectomy: which is better? *Curr Opin Urol.* 2011 May;21(3):200-5.
- Yohannes P, Rotariu P, Pinto P, Smith AD, & Lee BR. (2002) Comparison of robotic versus laparoscopic skills: is there a difference in the learning curve? *Urology.* 2002. Jul;60(1):39-45



## **Robotic Systems - Applications, Control and Programming**

Edited by Dr. Ashish Dutta

ISBN 978-953-307-941-7

Hard cover, 628 pages

**Publisher** InTech

**Published online** 03, February, 2012

**Published in print edition** February, 2012

This book brings together some of the latest research in robot applications, control, modeling, sensors and algorithms. Consisting of three main sections, the first section of the book has a focus on robotic surgery, rehabilitation, self-assembly, while the second section offers an insight into the area of control with discussions on exoskeleton control and robot learning among others. The third section is on vision and ultrasonic sensors which is followed by a series of chapters which include a focus on the programming of intelligent service robots and systems adaptations.

### **How to reference**

In order to correctly reference this scholarly work, feel free to copy and paste the following:

Rachid Yakoubi, Shahab Hillyer and Georges-Pascal Haber (2012). Robotic Urological Surgery: State of the Art and Future Perspectives, Robotic Systems - Applications, Control and Programming, Dr. Ashish Dutta (Ed.), ISBN: 978-953-307-941-7, InTech, Available from: <http://www.intechopen.com/books/robotic-systems-applications-control-and-programming/robotic-urological-surgery-state-of-the-art-and-future-perspectives>

**INTECH**  
open science | open minds

### **InTech Europe**

University Campus STeP Ri  
Slavka Krautzeka 83/A  
51000 Rijeka, Croatia  
Phone: +385 (51) 770 447  
Fax: +385 (51) 686 166  
[www.intechopen.com](http://www.intechopen.com)

### **InTech China**

Unit 405, Office Block, Hotel Equatorial Shanghai  
No.65, Yan An Road (West), Shanghai, 200040, China  
中国上海市延安西路65号上海国际贵都大饭店办公楼405单元  
Phone: +86-21-62489820  
Fax: +86-21-62489821

© 2012 The Author(s). Licensee IntechOpen. This is an open access article distributed under the terms of the [Creative Commons Attribution 3.0 License](https://creativecommons.org/licenses/by/3.0/), which permits unrestricted use, distribution, and reproduction in any medium, provided the original work is properly cited.

IntechOpen

IntechOpen