

We are IntechOpen, the world's leading publisher of Open Access books Built by scientists, for scientists

6,900

Open access books available

186,000

International authors and editors

200M

Downloads

Our authors are among the

154

Countries delivered to

TOP 1%

most cited scientists

12.2%

Contributors from top 500 universities



WEB OF SCIENCE™

Selection of our books indexed in the Book Citation Index
in Web of Science™ Core Collection (BKCI)

Interested in publishing with us?
Contact book.department@intechopen.com

Numbers displayed above are based on latest data collected.
For more information visit www.intechopen.com



Robotic-Assisted Laparoscopic Radical Cystoprostatectomy and Intracorporeal Urinary Diversion (Studer Pouch or Ileal Conduit) for Bladder Cancer

Abdullah Erdem Canda, Ali Fuat Atmaca and Mevlana Derya Balbay
*Ankara Atatürk Training and Research Hospital, 1st Urology Clinic, Ankara
 Turkey*

1. Introduction

Bladder cancer is the fourth most common malignancy in American men and almost 25% is muscle invasive at the time of diagnosis (Cancer Facts and Figures, 2009; Nieder et al., 2008).

Currently, most effective local treatment of muscle invasive bladder cancer and non-invasive, high-grade bladder tumors that recur or progress despite intravesical therapies is open radical cystoprostatectomy with urinary diversion (Clinical Practice Guidelines in Oncology, 2010; Huang et al., 2007).

With the advancement of technology, minimally invasive surgical approaches including laparoscopic (Huang et al., 2010; Guazzoni et al., 2003) or robotic-assisted laparoscopic (Akbulut et al., 2011; Rehman et al., 2011; Kauffman et al., 2011; Hellenthal et al., 2010; Kasraeian et al., 2010; Pruthi et al., 2010; Schumacher et al., 2009) cystectomies are increasingly being performed.

This chapter summarizes the current state of the use of the surgical robot in performing radical cystoprostatectomy with urinary diversion in patients with bladder cancer.

2. Why to use a surgical robot?

Radical cystoprostatectomy with bilateral extended lymph node dissection and urinary diversion (Studer pouch reconstruction or ileal conduit formation) are complex and time consuming surgical procedures. Performing these complex procedures in an open surgical approach is well established. To perform these complex procedures pure laparoscopically is extremely difficult. However, the use of a surgical robot enables the operating surgeon to perform these procedures much more easily because it has the advantages of the 3-dimensional and magnified image capability, higher grades of wristed hand movements, decreased hand tremor leading to a shorter learning curve. Besides, having the 4th-robotic arm gives the advantage of additional assistance and tissue retraction and letting the console surgeon to operate in a comfortable sitting position rather than standing position for long hours. Menon et al suggested that robotic approach combines the oncological principles of

open surgery with technical advantages of the surgical robot which allows a precise, gentle, quick and safe surgery during performing radical cystectomy for bladder cancer (Menon et al., 2003).

Therefore, following the introduction of da Vinci-S 4-arm surgical robot (Intuitive Surgical, Sunnyvale, California) many centers have started to publish their experiences with the use of a surgical robot in performing these complex surgical procedures (Akbulut et al., 2011; Rehman et al., 2011; Kauffman et al., 2011; Hellenthal et al., 2010; Kasraeian et al., 2010; Pruthi et al., 2010; Schumacher et al., 2009).

3. Open versus robotic approach

3.1 Comparison of complications

A prospective study from Weill Cornell Medical College, Department of Urology, New York, NY, USA has recently evaluated prospective complications of open (n=104) versus robotic (n=83) cystectomy procedures (Ng et al., 2010). Complications were classified due to modified Clavien system. Significantly lower major complications were detected in the robotic group compared to the open surgical approach (17% versus 31%, $p=0.03$). Robotic cystectomy was found to be an independent predictor of fewer overall and major complications at 0-30 day (perioperative) and 31-90 day periods. Another well known study from The University of North Carolina at Chapel Hill, Division of Urologic Surgery, Chapel Hill, North Carolina, USA randomized 21 patients to robotic approach and 20 to the open technique. No significant difference in regard to overall complication rate or hospital stay was detected between the two groups of patients (Nix et al., 2010). In our initial experience of 12 cases whom we performed robot assisted laparoscopic nerve sparing radical cystoprostatectomy with bilateral extended lymph node dissection and intracorporeal Studer pouch construction, we had 6 minor complications (Grade 1 and 2) 2 major complications (Grade 3-5) in the perioperative period (0-30 day) and 3 minor and 2 major complications in the 31-90 day period due to modified Clavien system (Akbulut et al., 2011). Although the number of prospective and randomized studies comparing these two approaches is limited currently in the literature, robotic approach does not seem to add an additional complication risk when compared to open surgery.

3.2 Comparison of oncologic parameters

Lymph node yield, surgical margins, recurrence-free survival and overall survival are important parameters in evaluating surgical oncologic efficacy. The University of North Carolina study which randomized 21 patients to robotic approach and 20 to the open technique did not find any significant difference in the number of lymph nodes removed between two groups (19 versus 18, $p>0.05$). Likewise, surgical margins were negative in all patients in both approaches (Nix et al., 2010). The Weill Cornell Medical College study, having larger numbers of patients similarly did not find significant differences concerning these two parameters between the two approaches (Ng et al., 2010). Mean lymph node yield was 15.7 in the open surgical approach and was 17.9 in the robotic approach ($p>0.05$). Positive surgical margins were detected 8.7% of the patients in open approach and 7.2% of the patients in robotic approach ($p>0.05$). In our initial series of 12 patients, mean lymph node yield was 21.3 ± 8.8 (Akbulut et al., 2011).

A recent review from the Memorial Sloan-Kettering Cancer Center has recently evaluated the oncological outcomes after radical cystectomy for bladder cancer comparing open versus minimally invasive approaches (Chade et al., 2010). Although the follow-up is limited in robotic series compared to open surgical approach, robotic assisted studies reported recurrence-free survival rates of 86% to 91% at 1 to 2 years and 90% to 96% overall survival in 1 to 2 years of follow-up. On the other hand, large open surgery studies showed 62% to 68% recurrence-free survival at 5 years and 50% to 60% at 10 years, with overall survival of 59% to 66% at 5 years and 37% to 43% at 10 years.

With these limited current data, robotic approach seems to provide sufficient short-term surgical oncologic efficacy in patients with bladder cancer.

3.3 Comparison of cost

Controversial reports exist regarding the cost analysis of open versus robotic approaches. One study revealed that robotic assisted laparoscopic radical cystectomy is associated with a higher financial cost than the open approach in the perioperative setting (Smith et al., 2010). Whereas, another study suggested that although robotic approach is more expensive in terms of operative costs and robotic supplies, due to decreased hospital stay in robotic approach and higher complication rates with open surgical approach make total actual costs much higher than robotic approach (Martin et al., 2011).

4. Surgical oncologic safety of robotic approach (lymph node yield and surgical margins)

Regarding open radical cystectomy, lymph node yield and positive surgical margin rates are considered as the significant factors related to surgical quality (Herr et al., 2004; Skinner et al., 2007; Stein et al., 2003). Herr et al and Skinner et al suggested a lymph node yield of greater than 10 and a positive surgical margin rate of less than 10% in surgical oncologic adequacy (Herr et al., 2004; Skinner et al., 2007). Stein et al suggested a lymph node yield of greater than 15 obtained during open radical cystectomy in order to be oncologically acceptable and sufficient (Stein et al., 2003).

Guru et al evaluated whether robot assistance allows adequate pelvic lymph node dissection particularly during the initial experience (Guru et al., 2008). In a series of 67 patients, mean number of lymph nodes retrieved was 18 (6-43) (Guru et al., 2008). Mean lymph node yield was 41.8 (18-67) in another series of 15 consecutive patients who underwent robotic radical cystectomy for bladder cancer (Lavery et al., 2010). Recently, International Robotic Cystectomy Consortium (IRCC) evaluated 527 patients who underwent robotic cystectomy for bladder cancer and mean lymph node yield was 17.8 (range 0-68) (Hellenthal et al., 2011). Mean lymph node yield was 21.3 (range, 8-38) and 24.8 ± 9.2 in our initial series of 12 (Akbulut et al., 2011) and 27 cases (unpublished data), respectively.

Positive surgical margin rates were reported as 6.8%, 0%, 7.2% and 2% in 513, 83, 100 and 50 robotic cystectomy patients (Hellenthal et al., 2010; Pruthi et al., 2010; Ng et al., 2010; Shamim Khan et al., 2010). In our initial series of 12 patients, positive surgical margin rate was 0% (Akbulut et al., 2011). We had only one patient with positive surgical margin (3.7%) who had pT4b disease in the total of 27 patients underwent totally intracorporeal robotic cystectomy (unpublished data).

5. Learning curve of robotic approach

Robotic-assisted laparoscopic radical cystectomy with bilateral extended lymph node dissection and particularly intracorporeal urinary diversion (Studer or ileal conduit) are complex procedures. Therefore, a learning curve is required in order to perform these procedures successfully.

Regarding the completion of the learning curve of robotic cystectomy, some authors have suggested to perform a certain number of cases in the literature. International Robotic Cystectomy Consortium (IRCC) suggested that 21 cases were needed to be performed for operative time to reach 6.5 hours and 8, 20 and 30 patients were required to reach a lymph node yield of 12, 16 and 20, respectively (Hayn et al., 2010). On the other hand, others reported that after the first 20 cases of robotic cystectomy, no further significant improvement was detected in terms of intraoperative parameters, pathologic outcomes and complication rates (Pruthi et al., 2008). Following evaluation of 100 cases of robotic cystectomy, Guru et al stated that operative results and oncologic outcomes for robotic-assisted radical cystectomy constantly improve as the technique evolves (Guru et al., 2009).

We have started performing robotic urological procedures at our institution in February 2009, following initially performing more than 50 cases of robot assisted laparoscopic radical prostatectomy cases some of which also included pelvic lymph node dissection. We recommend to start performing robotic cystectomy cases after a certain experience gained particularly on robotic radical prostatectomy. Additionally, a good knowledge of the pelvic anatomy and adequate open surgical experience are essential.

6. Surgical technique

6.1 Patient position

Patient is placed in deep (30°) Trendelenburg position at the beginning of the procedure until the completion of robotic cystectomy, bilateral extended lymph node dissection and transposition of the left ureter under the mobilized sigmoid colon. During performing intracorporeal Studer pouch reconstruction or ileal conduit formation, patient position is adjusted to mild (5°) Trendelenburg position.

A Veress needle is introduced into the abdominal cavity about 2 cm above the umbilicus. Intra-abdominal pressure is set to 10-12 mmHg during performing bilateral extended lymph node dissection. Regarding rest of the surgery, intra-abdominal pressure is set to 16-18 mmHg.

6.2 Abdominal port locations

Overall, we use 6 trocars with the 4th-arm of the surgical robot placed on the patient's right which provides easy control to the right-handed console surgeon (Figure 1).

Camera port (12-mm) is placed 2 cm above the umbilicus. Two robotic trocars (8-mm) are placed 8 cm apart from the camera port at the level of the umbilicus. An 8-mm sized robotic trocar is placed 3 cm vertically above from the right iliac crest for the 4th-arm. We use 2 assistant trocars on the left abdomen for the assistant surgeon: A 15-mm trocar for introducing for tissue staplers for bowels and endobags for specimens is placed 3 cm vertically above from the left iliac crest and a 12-mm trocar is placed between the camera port and the 2nd-robotic arm.

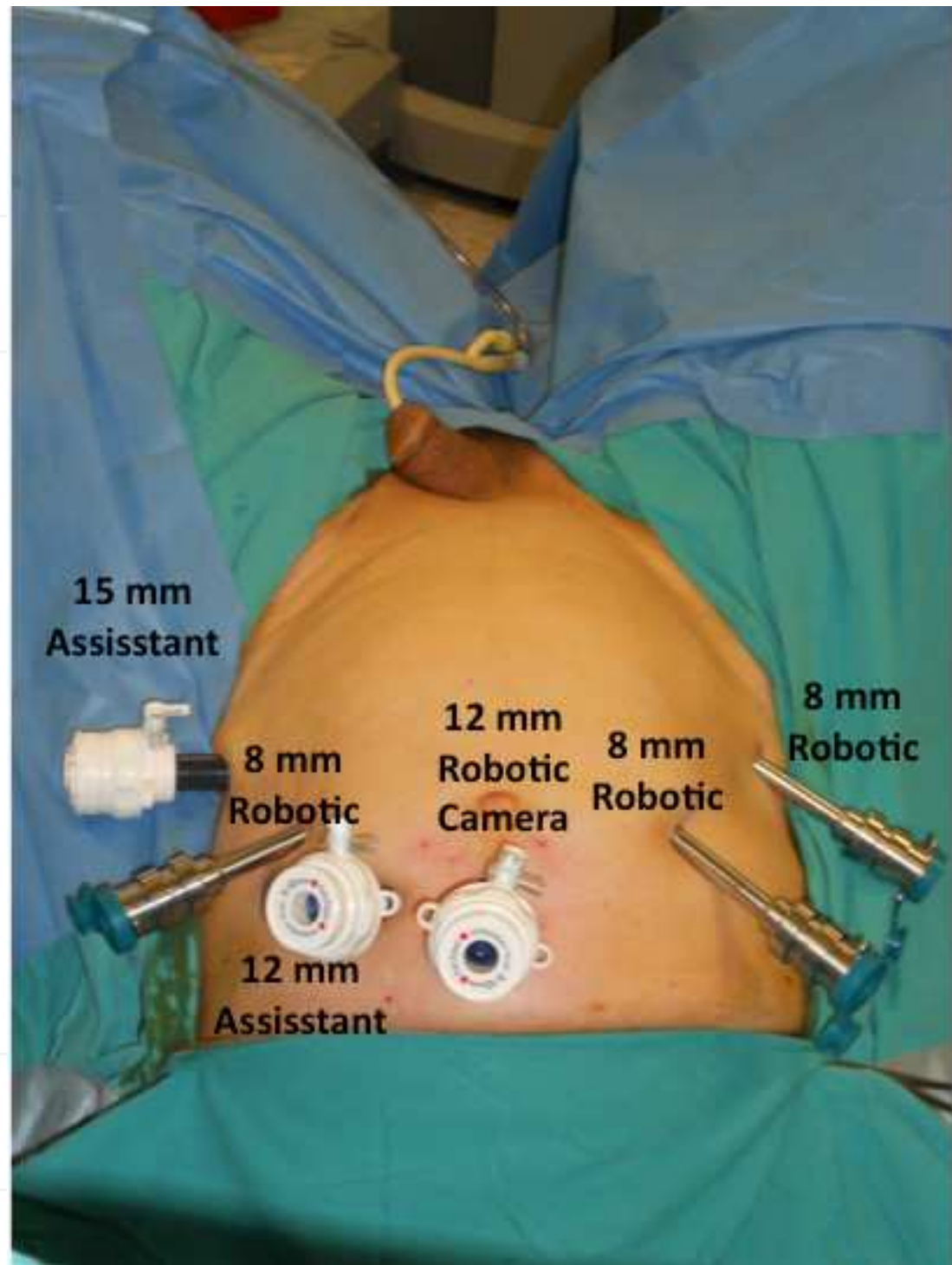


Fig. 1. Abdominal port locations (*Archive of Ankara Atatürk Training and Research Hospital, 1st Urology Clinic, Ankara, Turkey*)

6.3 Robotic-assisted laparoscopic bilateral neurovascular bundle sparing radical cystoprostatectomy in male patients (Akbulut et al., 2011; Canda et al., 2011; Canda et al., 2011; Akbulut et al., 2010)

Surgery starts with dissection of the ureters. They are double clipped and cut where they enter the bladder. Most distal parts are sent for frozen section analysis (Figure 2).

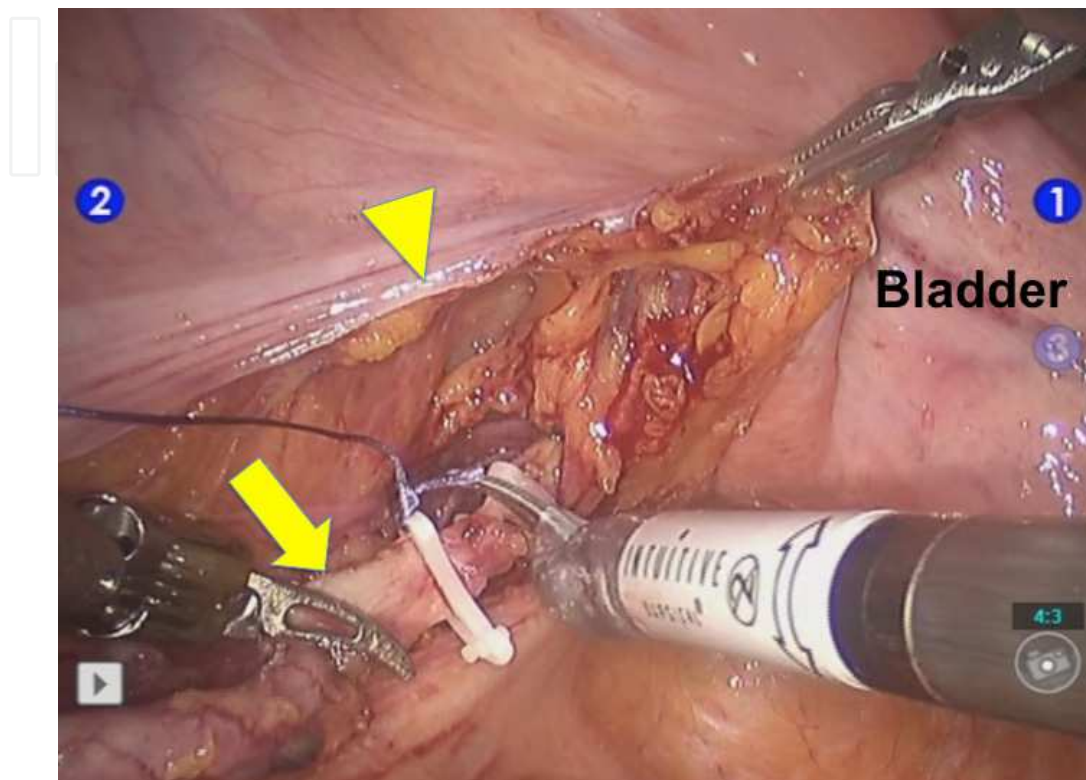


Fig. 2. Ureters are dissected, double clipped and cut where they enter the bladder (left side). Arrow: left ureter, arrowhead: incised and opened peritoneum on the left side. (Archive of Ankara Atatürk Training and Research Hospital, 1st Urology Clinic, Ankara, Turkey)

Peritoneum on the anterior wall of the Douglas' pouch is incised and posterior dissection of the prostate is carried out (Figure 3).

Following the identification of seminal vesicles, Denonvilliers' fascia is opened (Figure 4). Tissue lateral to the tip of the seminal vesicles corresponding to the mid point of the pararectal plexus is marked with Hem-o-lok® clips on both sides (Figure 5). Prostate is dissected off of the rectum. Lateral bladder pedicles are severed with vessel sealing system (Ligasure®) until the Hem-o-lok® clips placed at the tips of the seminal vesicles to mark pararectal plexus of which the neurovascular bundles originate (Figure 6). Then, endopelvic fascia is opened on both sides. Dorsal venous complex is ligated by 0/0 vicryl (40 mm ½ RB needle). High anterior release (intra-fascial) neurovascular bundle preservation is performed on both sides by dissecting the periprostatic fascia over the prostatic capsule alongside the prostate down until the dorsal venous complex suture and bilateral neurovascular bundle dissections are completed (Figure 7).

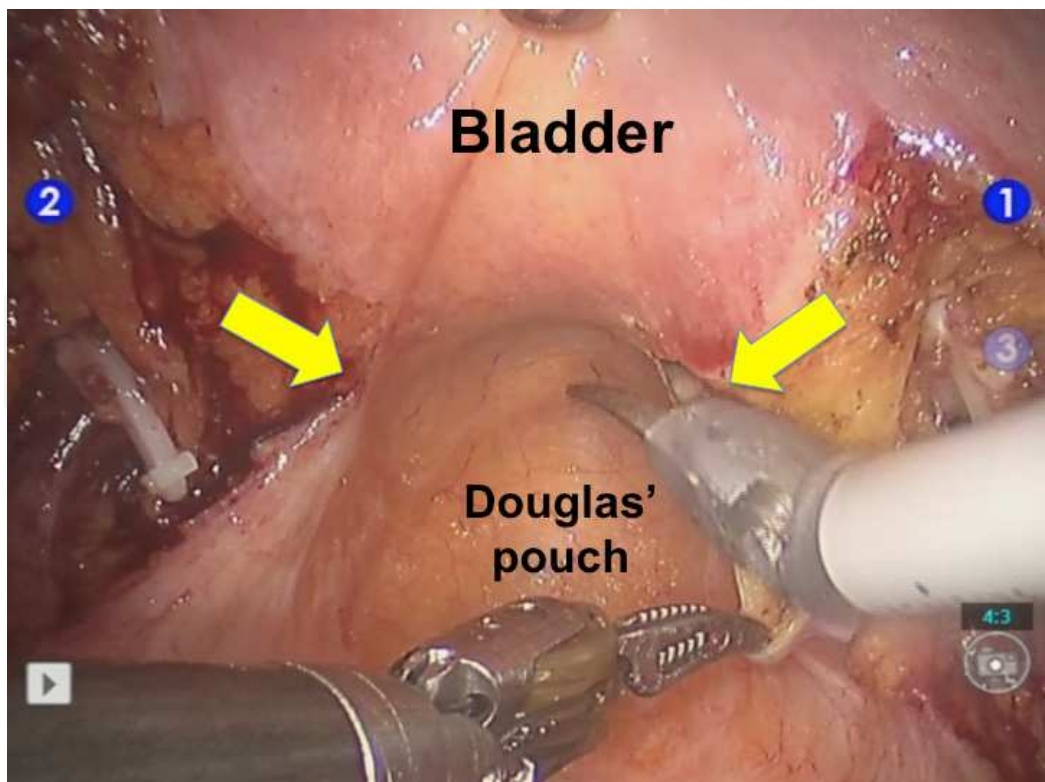


Fig. 3. Incision of the peritoneum on the anterior Douglas' pouch wall (arrows). (Archive of Ankara Atatürk Training and Research Hospital, 1st Urology Clinic, Ankara, Turkey)

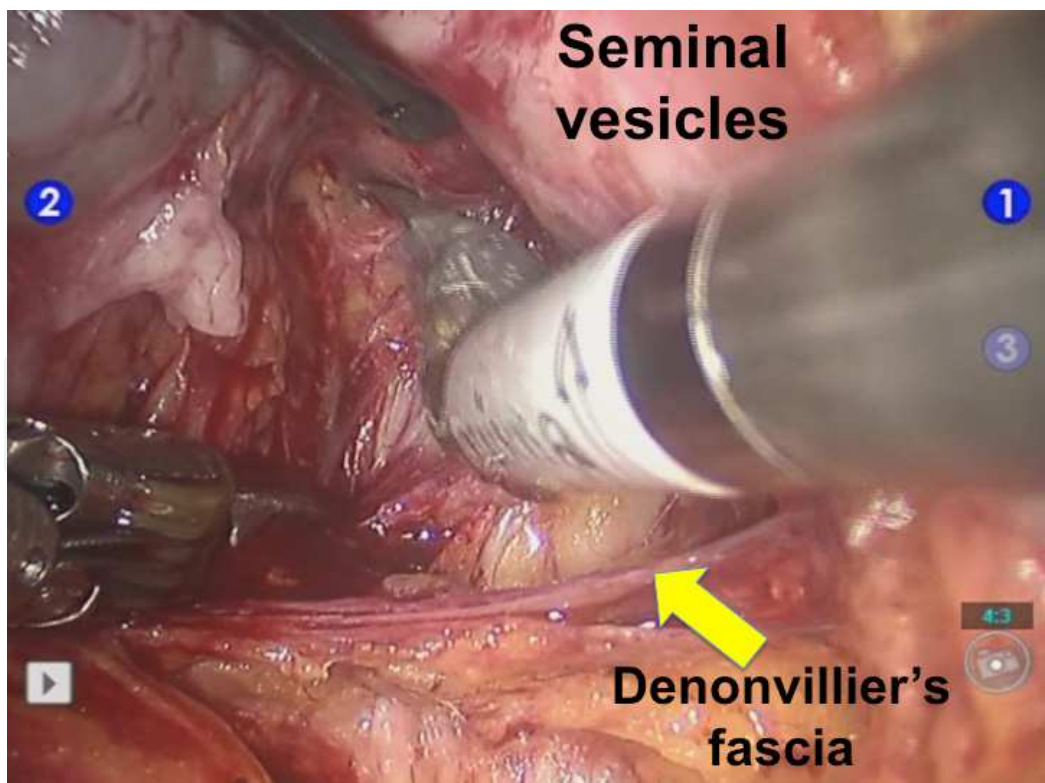


Fig. 4. Opening Denonvilliers' fascia (arrow). (Archive of Ankara Atatürk Training and Research Hospital, 1st Urology Clinic, Ankara, Turkey)

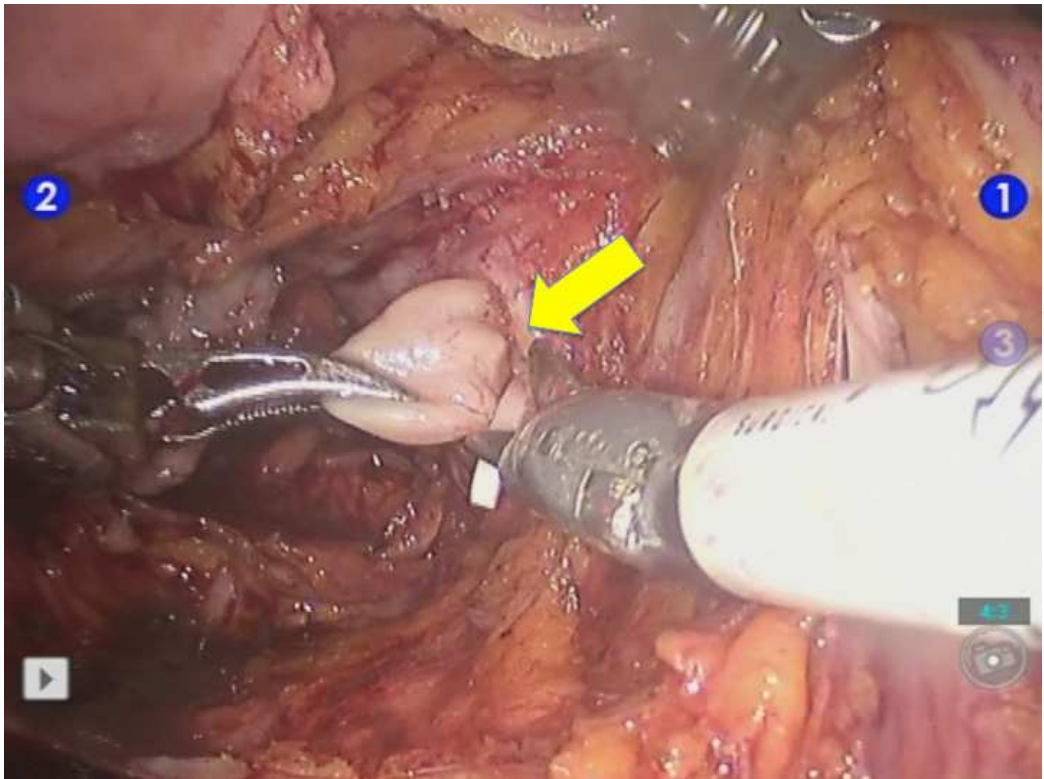


Fig. 5. Tip of the seminal vesicle is marked with a Hem-o-lok® clip and cut (arrow). (Archive of Ankara Atatürk Training and Research Hospital, 1st Urology Clinic, Ankara, Turkey)

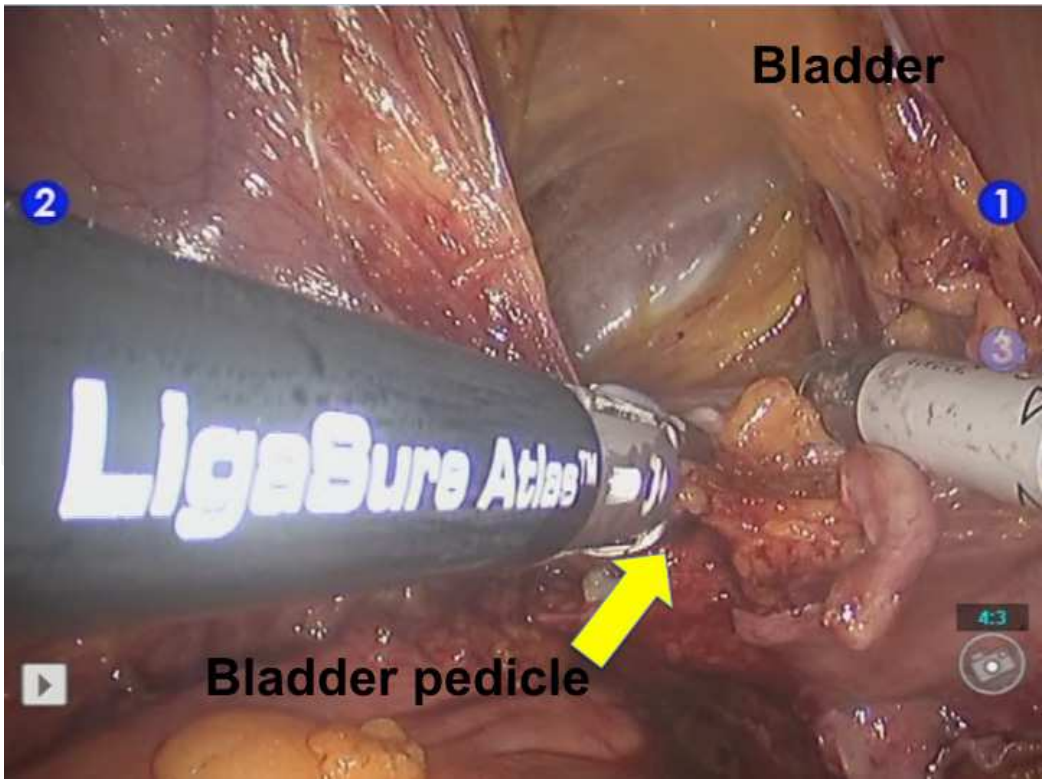


Fig. 6. Severence of lateral bladder pedicles with vessel sealing system (arrow). (Archive of Ankara Atatürk Training and Research Hospital, 1st Urology Clinic, Ankara, Turkey)

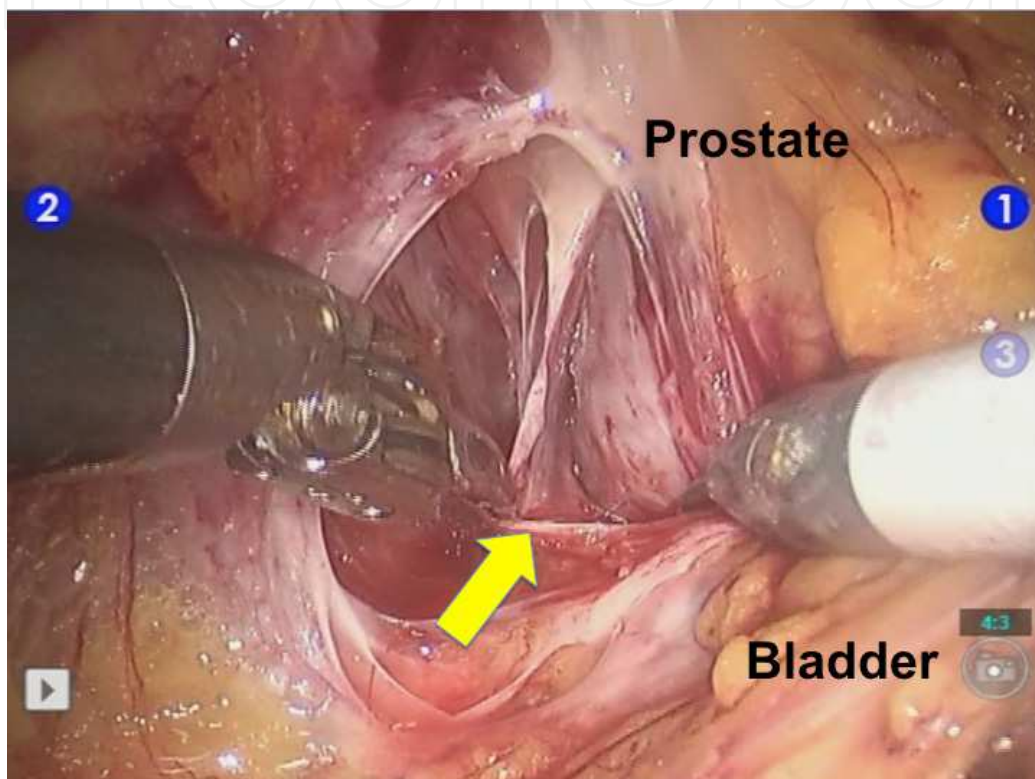


Fig. 7. High anterior release of the periprostatic fascia (arrow) over the prostatic capsule alongside the prostate in preserving neurovascular bundles on the left side. (*Archive of Ankara Atatürk Training and Research Hospital, 1st Urology Clinic, Ankara, Turkey*)

Starting from the umbilical level, urachus is dissected by incising lateral to the medial umbilical ligaments on the anterior abdominal wall. Puboprostatic ligaments are cut. Ligated dorsal venous complex (Figure 8) and ligated membranous urethra (Figure 9) with 0/0 vicryl (40 mm $\frac{1}{2}$ RB needle) to prevent tumor spillage are cut. Cystoprostatectomy is completed (Figure 10) and specimen is put into the endobag. Urethral stump is sampled for frozen section analysis.

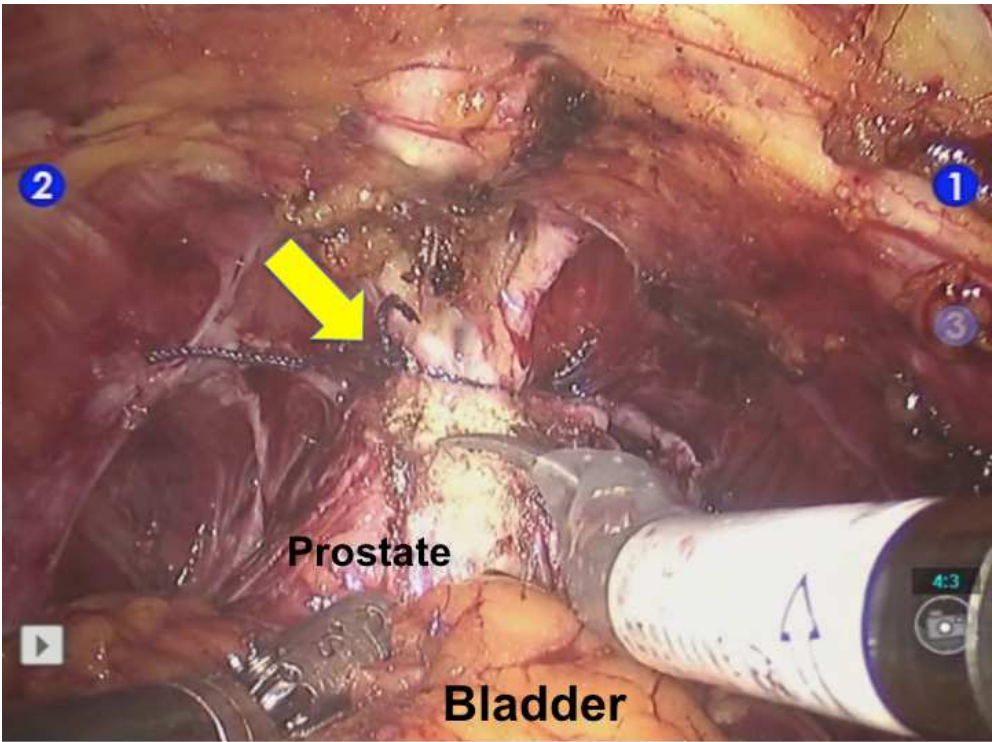


Fig. 8. Dorsal venous complex is ligated and cut (arrow). (Archive of Ankara Atatürk Training and Research Hospital, 1st Urology Clinic, Ankara, Turkey)

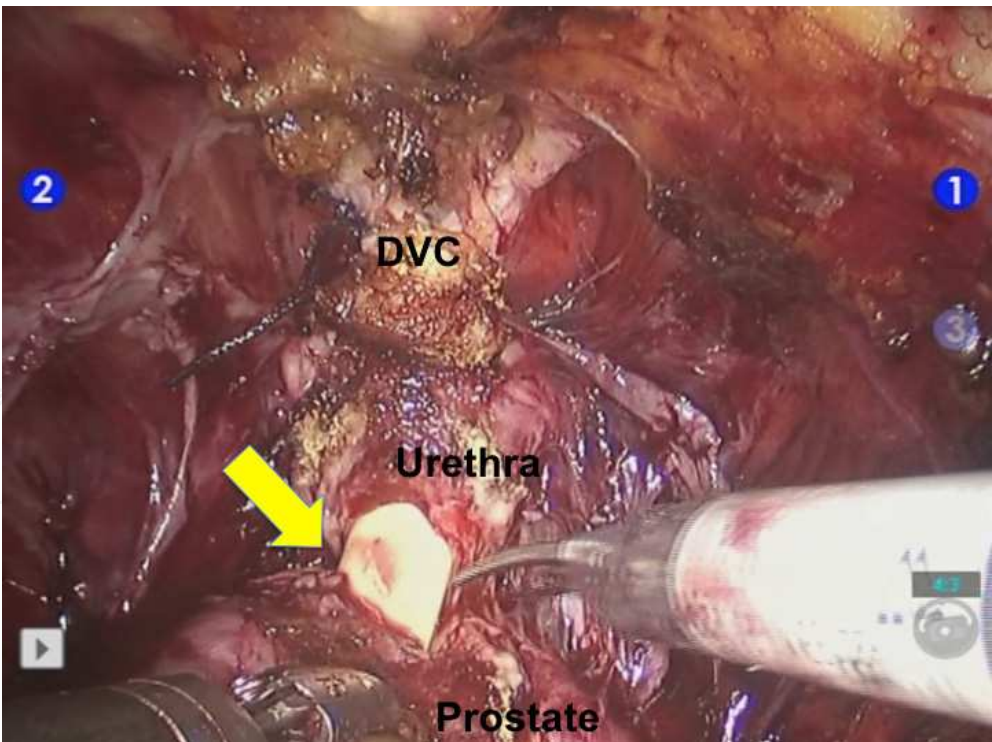


Fig. 9. Membraneous urethra is cut after being ligated and foley catheter is inserted back in until its tip reaches the specimen to show the anatomic details apparently. Arrow: appearance of the urethral catheter. DVC: dorsal venous complex (ligated and cut) (Archive of Ankara Atatürk Training and Research Hospital, 1st Urology Clinic, Ankara, Turkey)

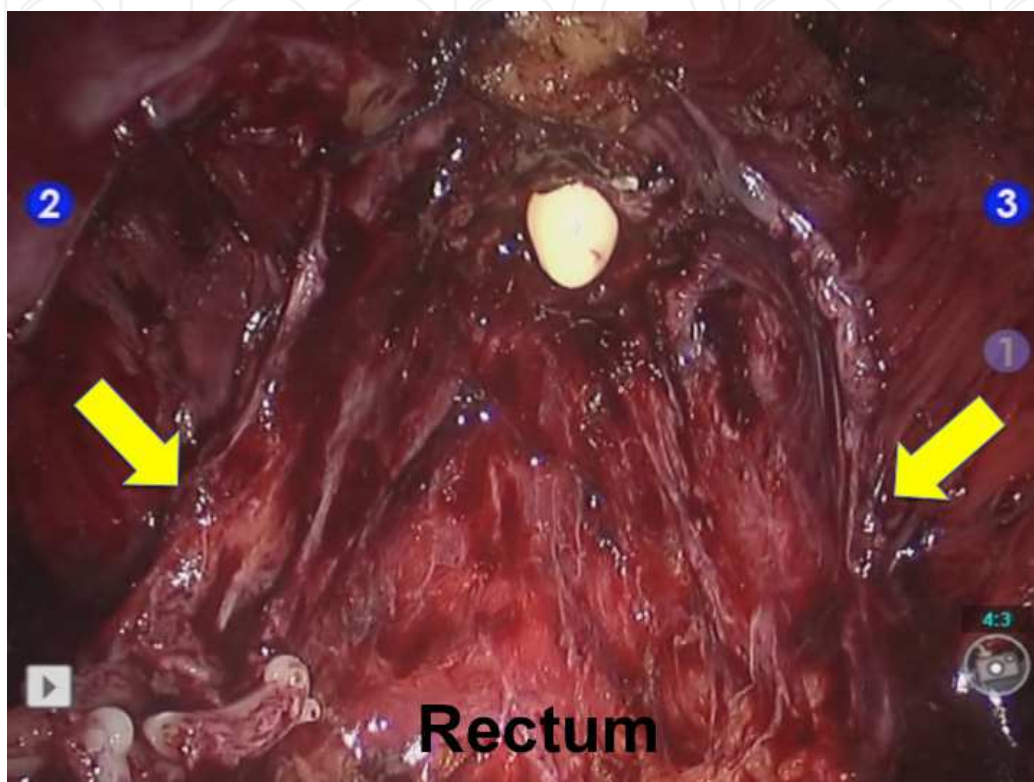


Fig. 10. Bilaterally preserved neurovascular bundles following the removal of the cystoprostatectomy specimen into the endobag (arrows). (*Archive of Ankara Atatürk Training and Research Hospital, 1st Urology Clinic, Ankara, Turkey*)

6.4 Robot assisted laparoscopic bilateral extended lymph node dissection (Canda et al., 2011; Akbulut et al., 2010; Akbulut et al., 2011)

We use the landmarks below during performing robot assisted laparoscopic bilateral extended lymph node dissection:

Superior border: inferior mesenteric artery and accompanying vena cava superior

Inferior border: node of Cloquet and circumflex iliac vein

Medial border: cut edge of the endopelvic fascia over the neurovascular bundles and internal iliac vessels

Lateral border: genitofemoral nerves, psoas muscles and ureters

Initially, starting from the genitofemoral nerve lymphatic tissue around external iliac artery & vein are removed until the obturator nerve is seen (Figure 11).

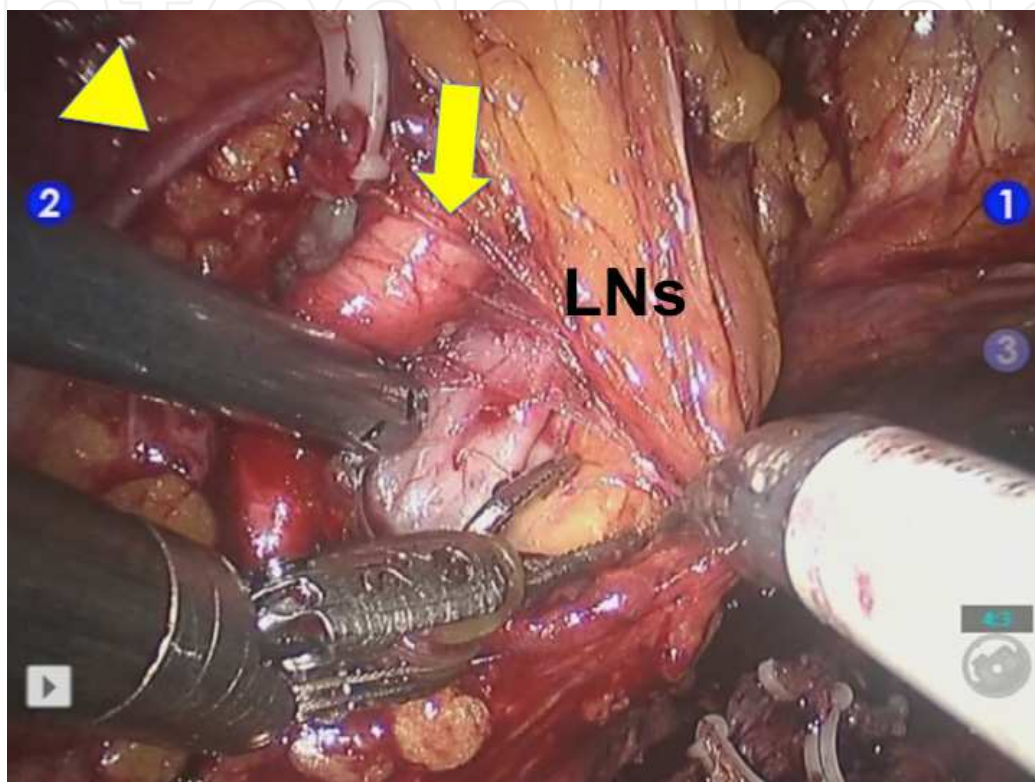


Fig. 11. Arrowhead: Genitofemoral nerve (left). Arrow: External iliac artery (left). LNs: Lymph node tissue. (Archive of Ankara Atatürk Training and Research Hospital, 1st Urology Clinic, Ankara, Turkey)

Then, bifurcation of common iliac artery are identified and lymphatic tissues located below the obturator nerve and surrounding the internal iliac artery are removed. Later, lymphatic tissues medial to the genitofemoral nerve and around the common iliac artery are dissected until the aortic bifurcation. Same lymphatic dissection is performed on the other side. Then, lymphatic tissues which are located distal to the aortic bifurcation, overlying and distally located to the vena caval bifurcation and common iliac arteries and veins are removed followed by presacral lymph nodes anterior to the sacrum. Lastly, preaortic and paracaval lymphatic dissections are performed. Inferior mesenteric artery on the aorta makes the most proximal end of the extended lymphatic dissection (Figure 12). Hem-o-lok® clips are used in order to tie off the most distal parts of the lymphatic vessels draining the limbs to prevent or reduce lymphatic leakage and lymphocele formation.

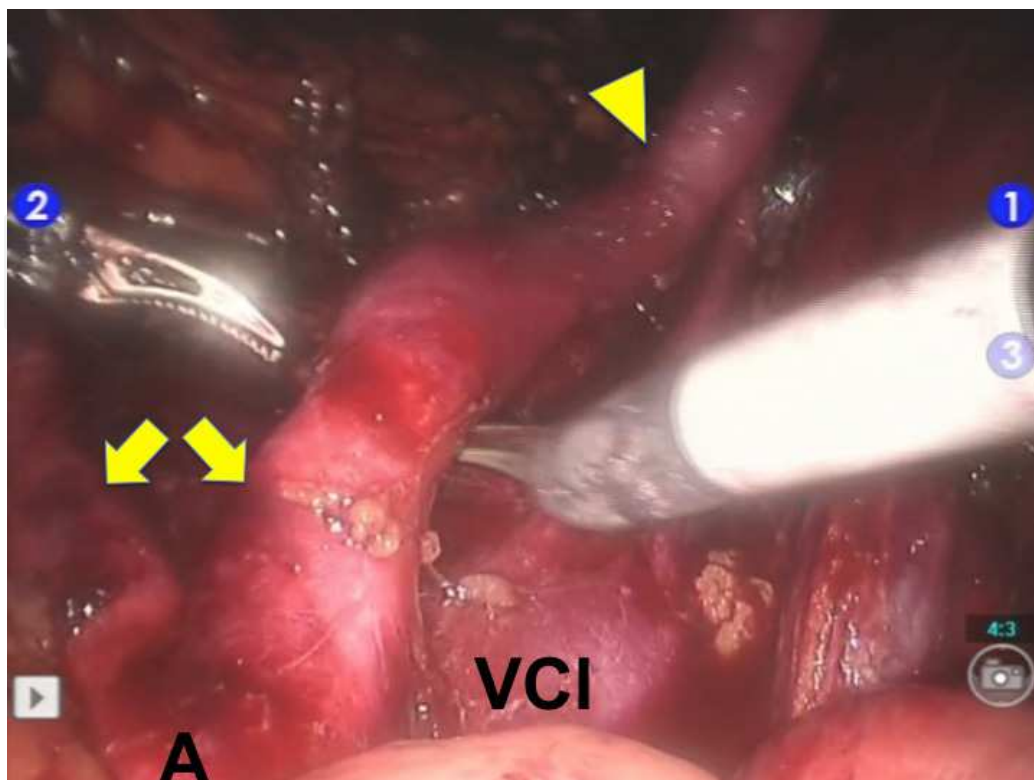


Fig. 12. Completed bilateral extended lymph node dissection and appearance of the major abdominal vasculature that are skeletonized. A: abdominal aorta, VCI: vena cava inferior, Arrows: right and left common iliac arteries, Arrowhead: right external iliac artery. (Archive of Ankara Atatürk Training and Research Hospital, 1st Urology Clinic, Ankara, Turkey)

Having completed the extended lymph node dissection, sigmoid colon is mobilized and left ureter is transposed to the right gutter underneath the sigmoid colon above the vasculature.

6.5 Robot assisted laparoscopic intracorporeal Studer pouch reconstruction (Canda et al., 2011; Akbulut et al., 2010; Akbulut et al., 2011)

Using a double armed 3/0 monocryl (17 mm ½c RB needle) urethral remnant is anastomosed to the assigned 1 cm opening on the antimesenteric wall of the most dependent part of the segregated ileum, initially (Figures 13,14). A 10 cm ileal segment on the right and a 40 cm ileal segment on the left side of urethroileal anastomosis are assigned for the pouch sparing the distal 20 cm ileal segment adjacent to the ceacum. Laparoscopic intestinal staplers are introduced through the 15 mm assistant port on the left side and placed perpendicular across the ileum and adjacent mesointestinum of approximately 2 cm (Figure 15). Side-to-side ileoileostomy is performed using two additional laparoscopic intestinal staplers between proximal and distal ends of the ileum (Figure 16).

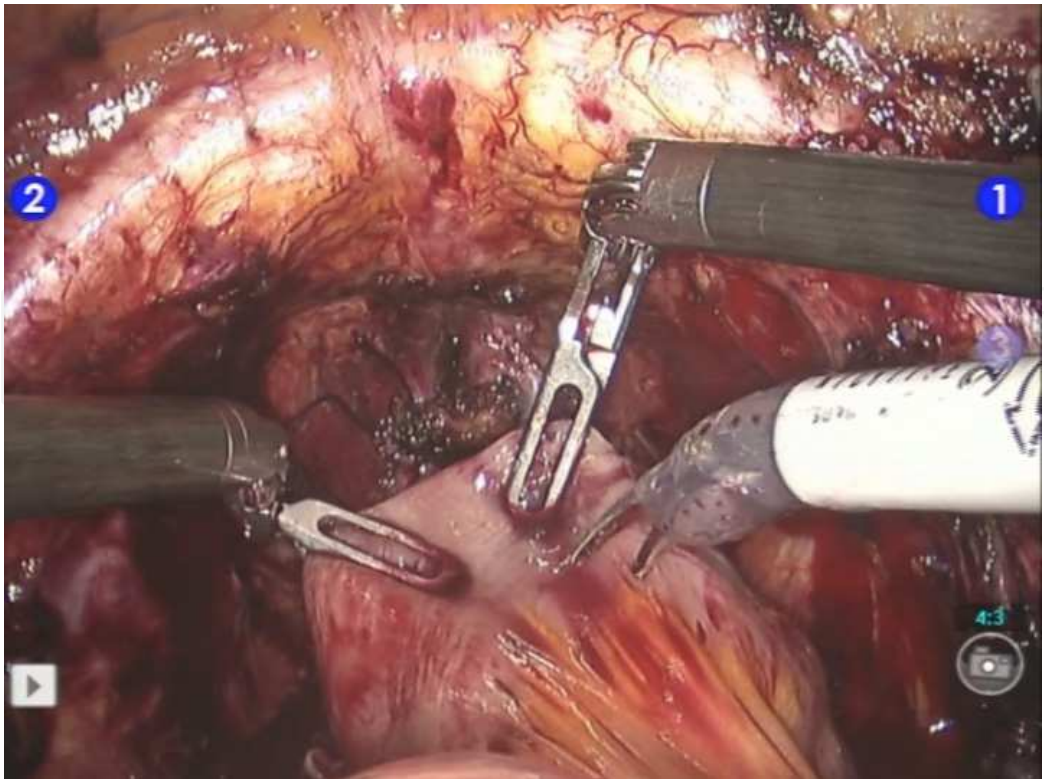


Fig. 13. Segregated antimesenteric ileal wall. (Archive of Ankara Atatürk Training and Research Hospital, 1st Urology Clinic, Ankara, Turkey)

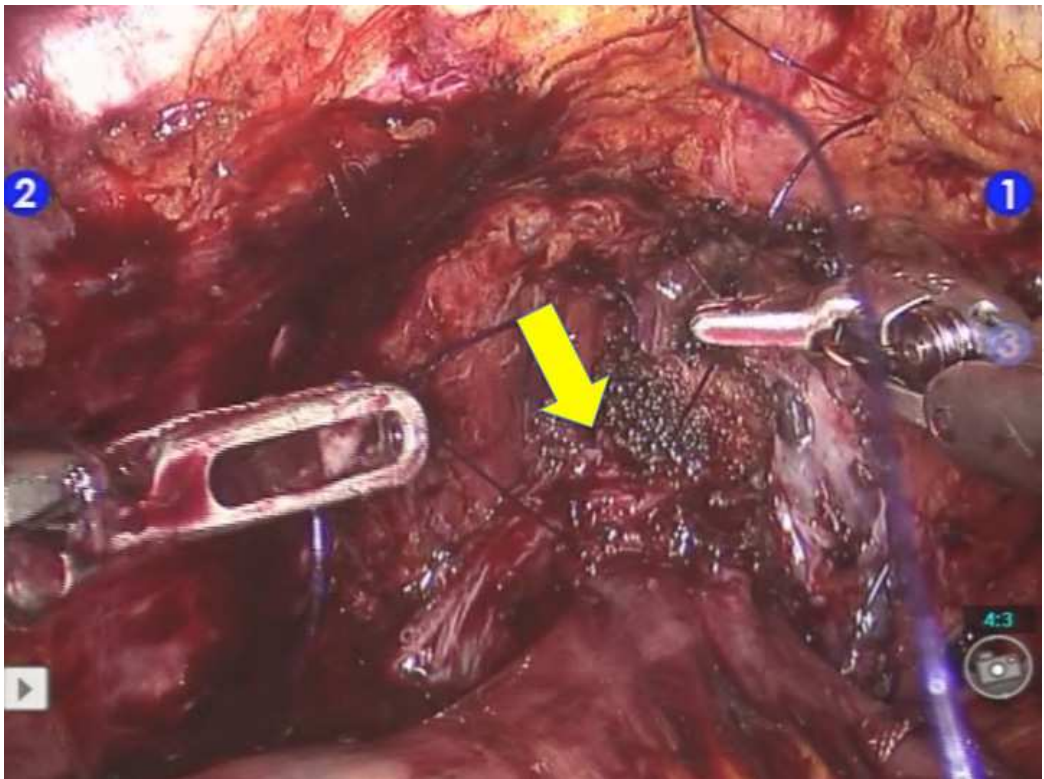


Fig. 14. Urethral remnant is sutured to the assigned antimesenteric ileal wall which is segregated. (Archive of Ankara Atatürk Training and Research Hospital, 1st Urology Clinic, Ankara, Turkey)

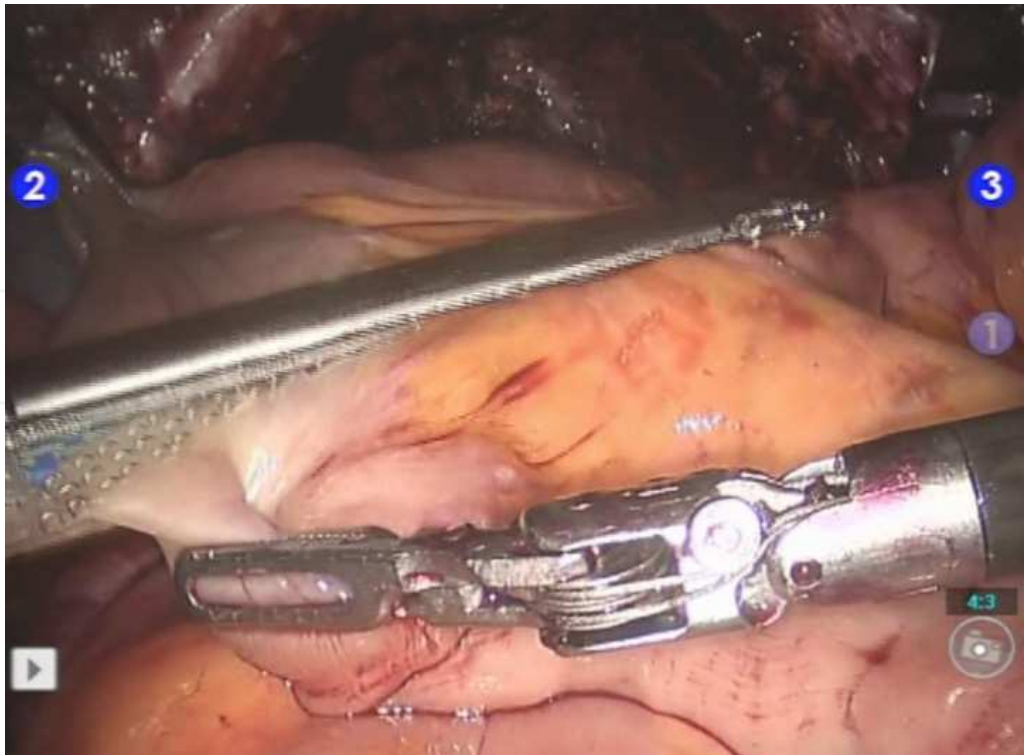


Fig. 15. Laparoscopic intestinal stapler introduced through the 15 mm assistant port on the left side and placed perpendicular across the ileum with adjacent 2 cm of mesentery included. (Archive of Ankara Atatürk Training and Research Hospital, 1st Urology Clinic, Ankara, Turkey)

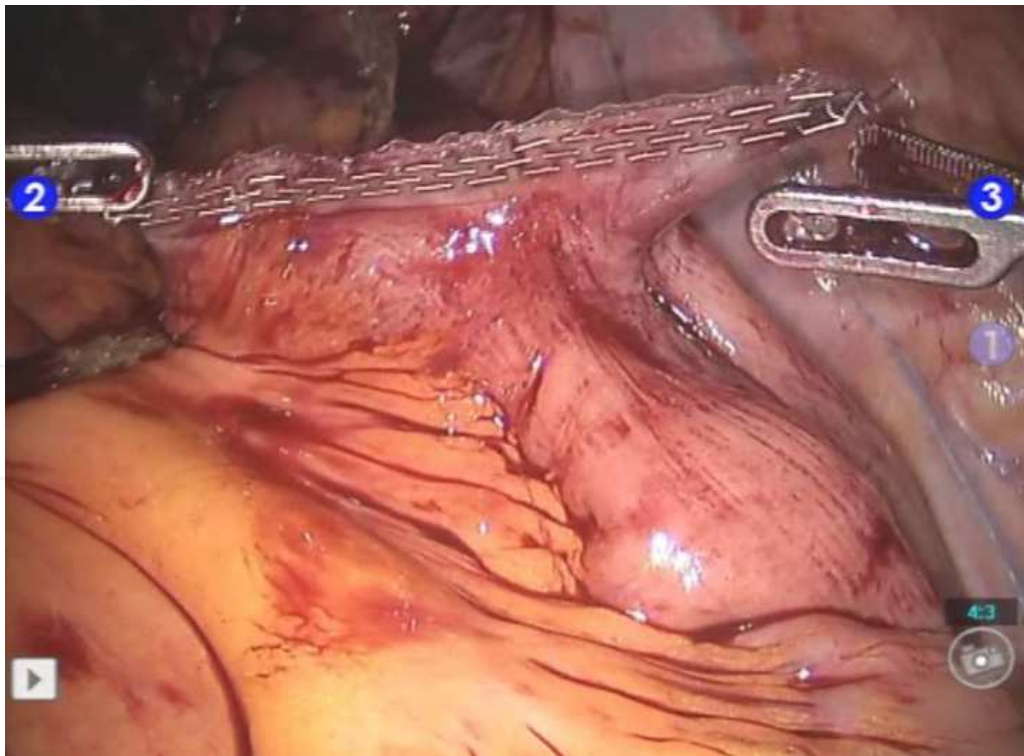


Fig. 16. Formation of side-to-side ileoileostomy by using laparoscopic intestinal staplers between proximal and distal ends of the ileum. (Archive of Ankara Atatürk Training and Research Hospital, 1st Urology Clinic, Ankara, Turkey)

Proximal 10 cm segment of the segregated ileum is spared as afferent loop. Then, a 60 cm feeding tube is inserted through the urethra and advanced within the lumen of the ileal segment until the proximal end of the afferent loop. Next, sparing the afferent loop, anti-mesenteric border of the remaining ileal segment is incised. Asymmetric closure of the posterior wall is accomplished with interrupted 2/0 vicryl (30 mm $\frac{1}{2}$ c RB needle) sutures followed by a running suture of 3/0 monocryl (26 mm $\frac{1}{2}$ c RB needle). Anterior wall anastomosis is accomplished using a running 3/0 monocryl (26 mm $\frac{1}{2}$ c RB needle) (Figure 17).

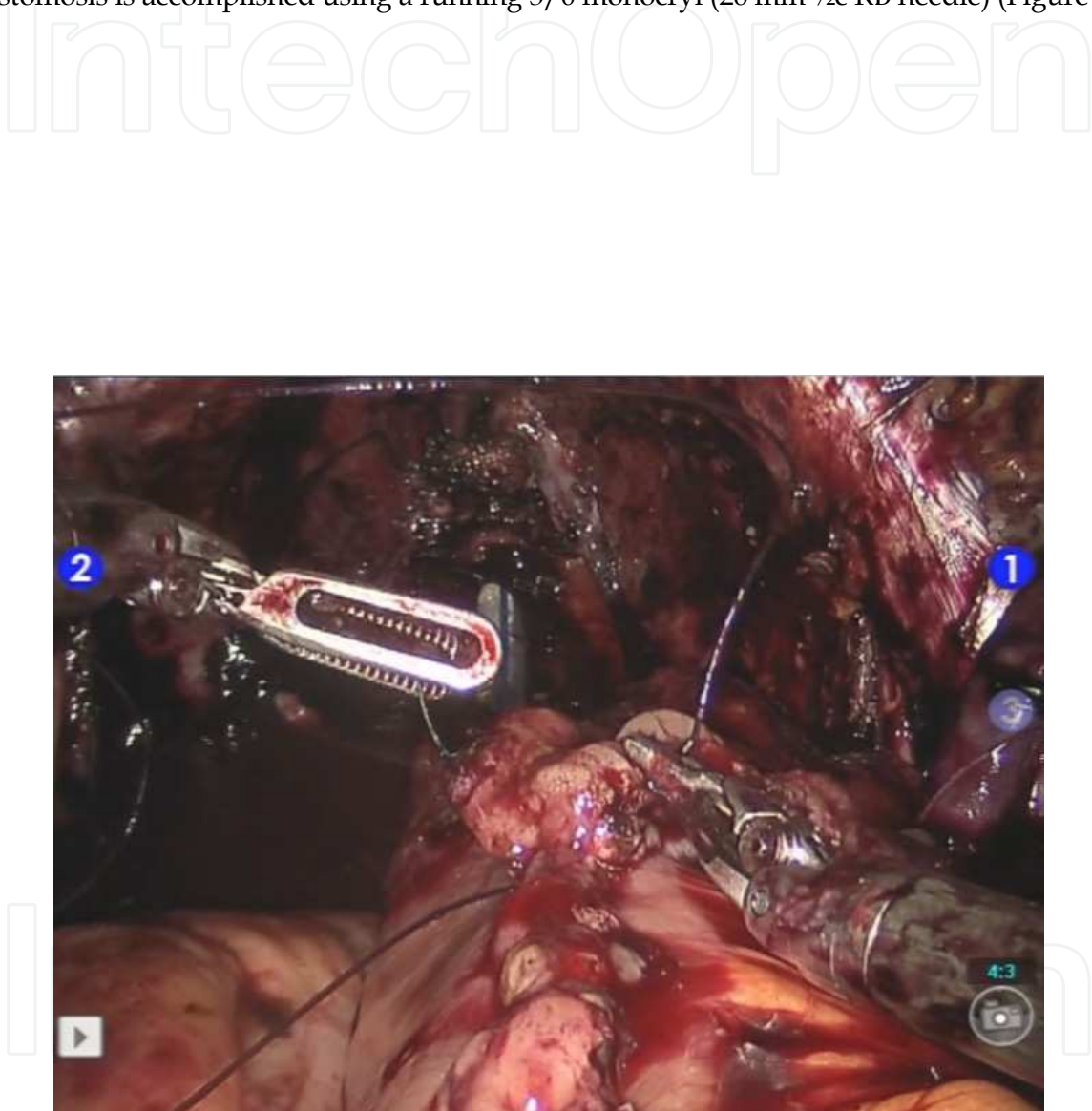


Fig. 17. Anterior wall closure. (Archive of Ankara Atatürk Training and Research Hospital, 1st Urology Clinic, Ankara, Turkey)

Distal ureteric ends are spatulated and anastomosed to each other at their medial edges in order to develop a common ureteral duct (Figure 18).

IntechOpen

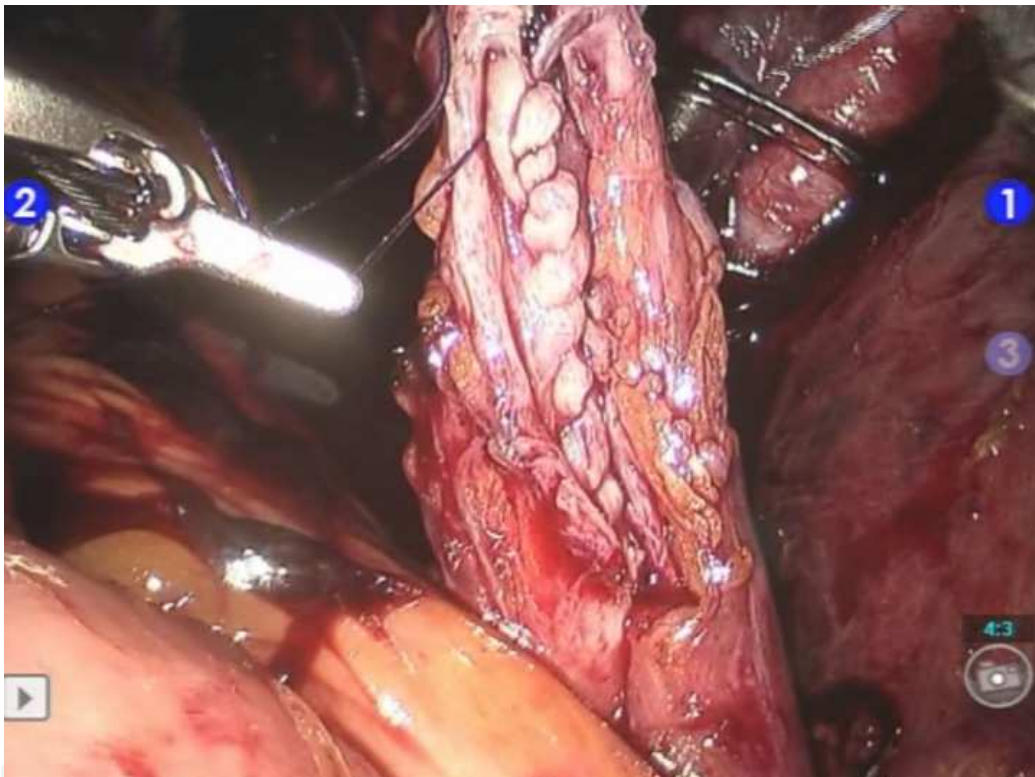


Fig. 18. Distal ureteric ends are spatulated and anastomosed to each other at their medial edges in order to develop a common ureteral duct before reconstruction of a Wallace type uretero-ureteral and intestinal anastomosis. (*Archive of Ankara Atatürk Training and Research Hospital, 1st Urology Clinic, Ankara, Turkey*)

Double J stents with long strings at their distal ends are passed through inside the feeding tube over a guide wire to the uretero-intestinal anastomosis site and fed up to the ureters and renal pelves (Figure 19). Distal tips of the stents are tied to the tip of a 22F urethral catheter outside the body, which will then be passed through the urethra into the completed Studer pouch over a guide-wire.

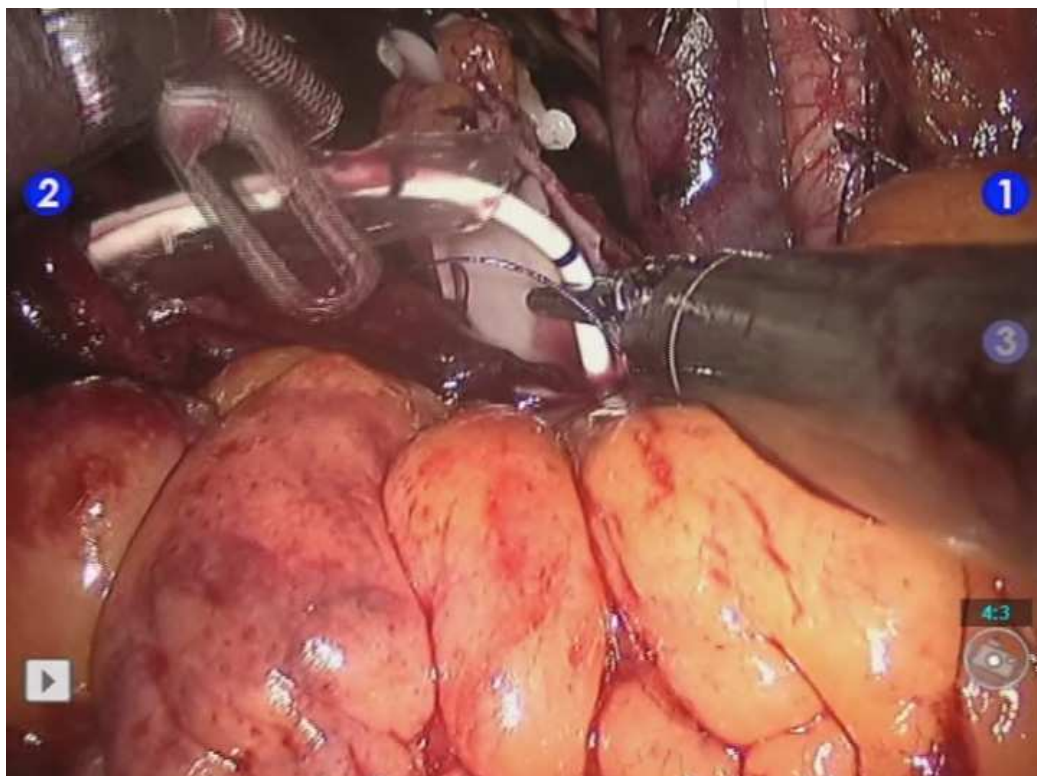


Fig. 19. Use of a feeding tube for inserting the double J catheters through the urethra, within the lumen of the ileum and into the ureters up to the renal pelvis. (*Archive of Ankara Atatürk Training and Research Hospital, 1st Urology Clinic, Ankara, Turkey*)

A Wallace type uretero-intestinal anastomosis is performed between common ureteral duct and proximal end of the afferent loop. To do this anastomosis, medial edge of the ureteral duct is sutured to the medial edge of the ileal wall with a double armed 4/0 monocryl (22 mm ½c RB needle) running suture. After internalization of the double-J stents, rest of the ureteroileal anastomosis is completed (Figure 20). Ureteroileal anastomosis is retroperitonealized by using several interrupted sutures in the right gutter laterally.

IntechOpen

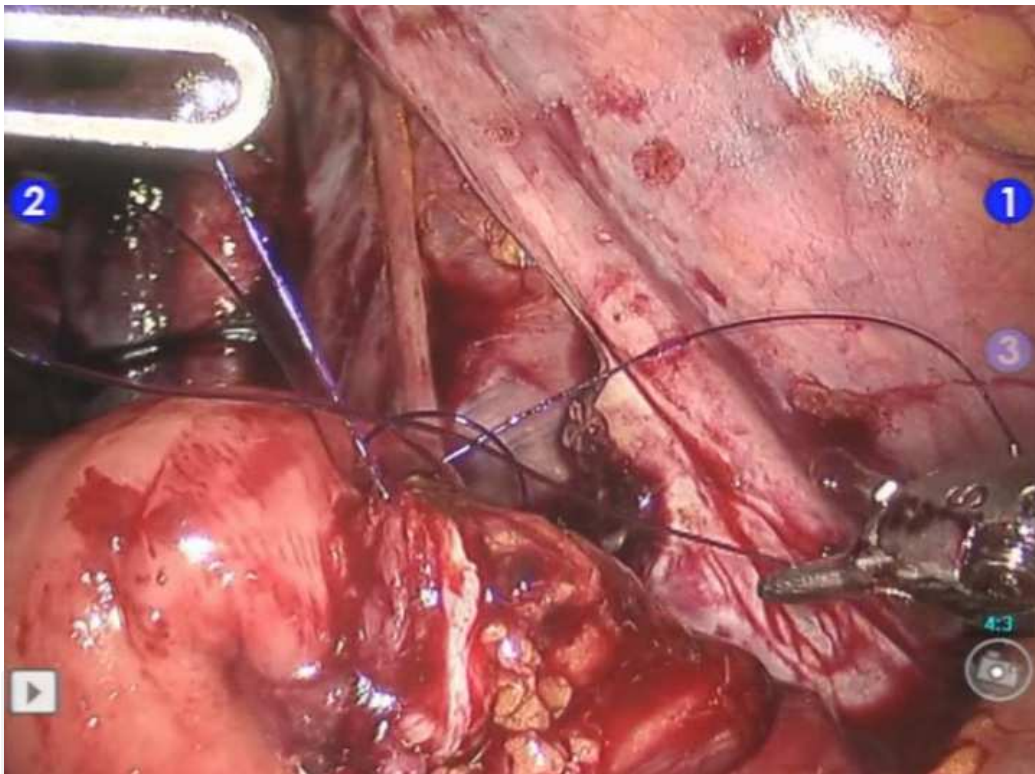


Fig. 20. Stapler line is excised at the proximal end of the afferent loop and posterior wall is anastomosed halfway between the ileal wall and medial edge of the uretero-ureteric anastomosis with a double armed 4/0 monocryl (22 mm $\frac{1}{2}$ c RB needle) running suture. (Archive of Ankara Atatürk Training and Research Hospital, 1st Urology Clinic, Ankara, Turkey)

Watertightness of the created Studer pouch is tested filling it with 150 cc of saline (Figure 21).

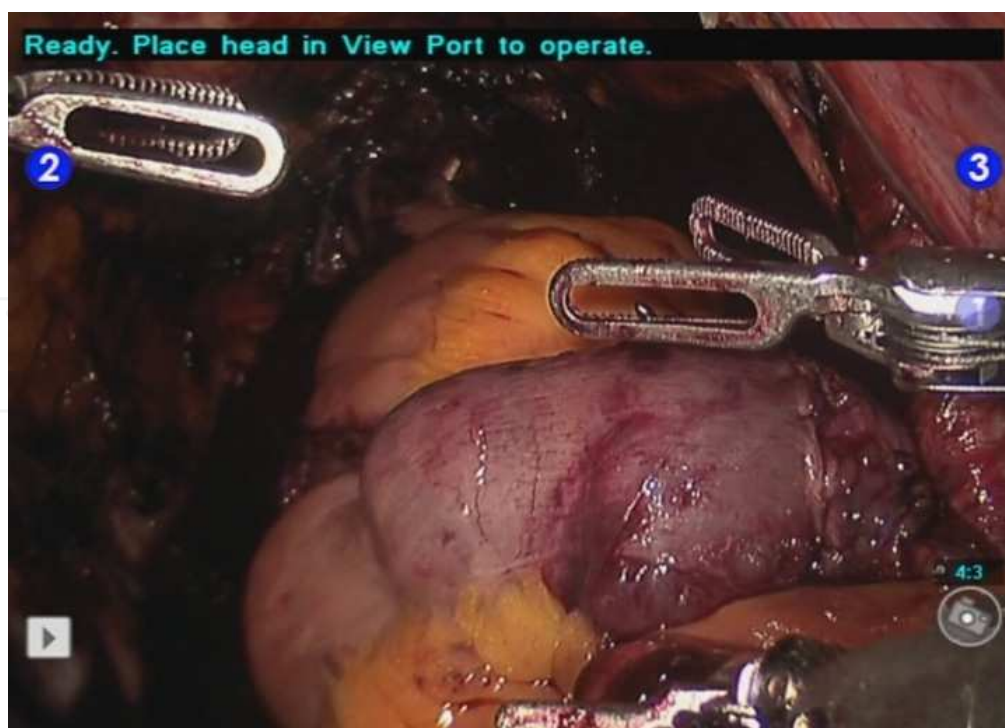


Fig. 21. Completed intracorporeal Studer pouch. (Archive of Ankara Atatürk Training and Research Hospital, 1st Urology Clinic, Ankara, Turkey)

Robotic-assisted laparoscopic radical cystoprostatectomy with intracorporeal Studer urinary diversion leads to better wound healing with excellent cosmetic result (Figure 22).

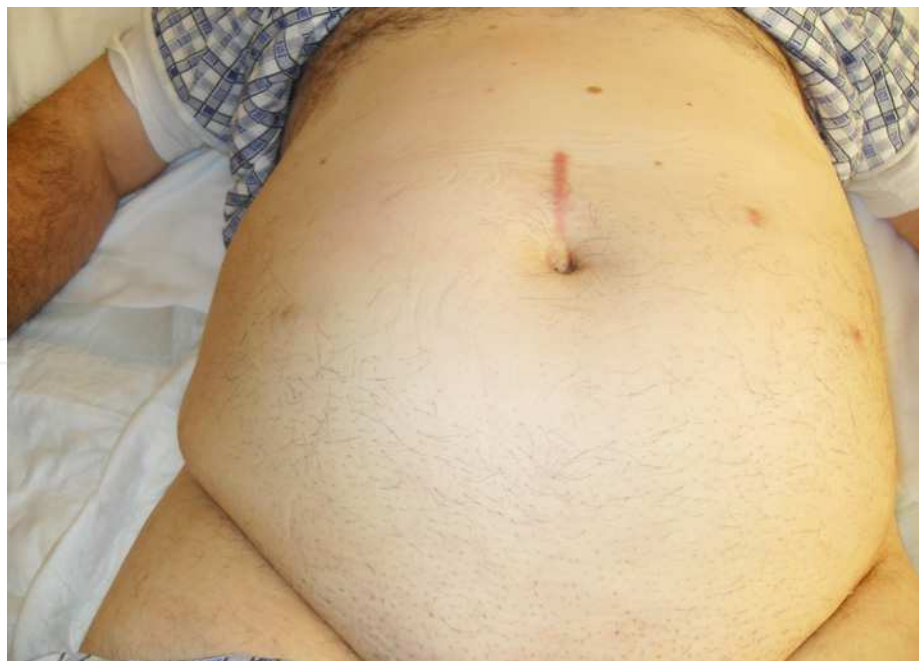

Fig. 22. Postoperative 6th-month abdominal appearance of a male patient who underwent robotic-assisted laparoscopic bilateral neurovascular bundle sparing radical cystoprostatectomy with bilateral extended lymph node dissection and intracorporeal Studer pouch formation for bladder cancer. (Archive of Ankara Atatürk Training and Research Hospital, 1st Urology Clinic, Ankara, Turkey)

Patients are discharged after tolerating an oral diet and sufficient ambulation following removal of the lodge drain. A cystography is done by filling the bladder with 200 cc of diluted contrast material on the postoperative 21st-day. When no leakage is seen, urethral catheter is removed. If leakage is detected, urethral catheter is kept for one more week and removed after another cystography.

6.6 Robotic-assisted laparoscopic intracorporeal ileal conduit formation (Canda et al., 2011)

Initially, sigmoid colon is mobilized and left ureter is transposed to the right gutter underneath the sigmoid colon above the vasculature. 20 cm ileal segment including the terminal ileum adjacent to the cecum is spared and a 15-20 cm of ileal segment is segregated by using tissue staplers.

A Wallace type uretero-ureteric anastomosis is performed as explained above. For inserting the JJ stents into the renal pelves, a feeding tube is passed through the urethra and advanced within the lumen of the ileal segment. Its tip is held close to anastomosed ureteral lumens and JJ stents are passed over a guide wire up to the renal pelves. Then, uretero-ileal anastomosis is performed by using a double armed running 3/0 monocryl suture (Figure 23). Ureteroileal anastomosis is retroperitonealized by using several interrupted sutures in the right gutter laterally.

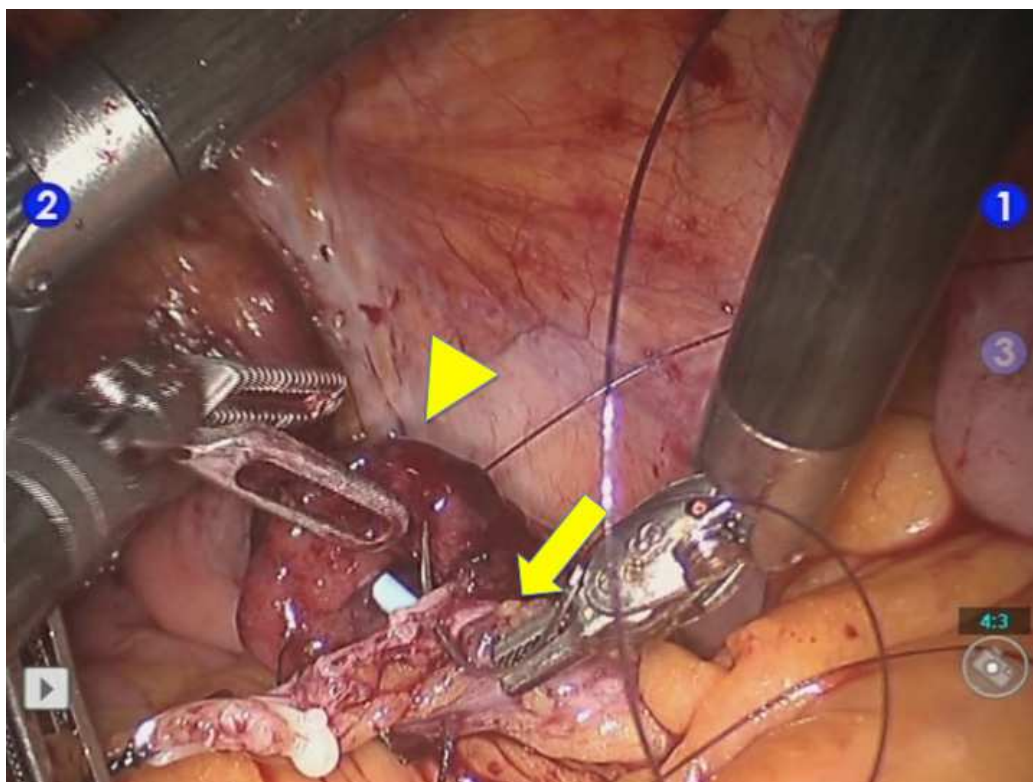


Fig. 23. Uretero-ileal anastomosis with JJ stents and intracorporeal ileal conduit. Arrowhead: ileal conduit, Arrow: Wallace type uretero-ureteric anastomosis. (Archive of Ankara Atatürk Training and Research Hospital, 1st Urology Clinic, Ankara, Turkey)

The 8-mm robotic trocar site opening located next to the supraumbilical camera port on right is used for ileal conduit stoma following its enlargement. Interrupted 2/0 vicryl sutures are used in order to fix the ileal loop serosa to the anterior rectus sheet. Ileal opening is everted by interrupted 2/0 vicryl sutures to create a nipple type stoma.

Patients are discharged after tolerating an oral diet and sufficient ambulation following removal of the lodge drains.


7. References

- Akbulut Z, Canda AE, Atmaca AF, Ozdemir AT, Asil E & Balbay MD. (2010) Robot assisted laparoscopic bilateral nerve-sparing radical cystoprostatectomy: Initial Ankara experience. *J Endourol* 24(Supplement 1):A360:VS8-14.
- Akbulut Z, Canda AE, Atmaca AF, Ozdemir AT, Asil E & Balbay MD. (2010) Robot assisted laparoscopic extended pelvic lymph node dissection during radical cystoprostatectomy: Initial Ankara experience. *Eur Urol Suppl* 9(5):521.
- Akbulut Z, Canda AE, Atmaca AF, Ozdemir AT, Asil E & Balbay MD. (2010) Robot assisted laparoscopic intracorporeal Studer pouch formation: Initial Ankara experience. *J Endourol* 24(Supplement 1):A359:VS8-12.
- Akbulut Z, Canda AE, Ozcan MF, Atmaca AF, Ozdemir AT & Balbay MD. (2011) Robot assisted laparoscopic nerve sparing radical cystoprostatectomy with bilateral extended lymph node dissection and intracorporeal Studer pouch construction: Outcomes of first 12 cases. *J Endourol* In Press.
- Canda AE, Atmaca AF, Altinova S, Akbulut Z, Balbay MD. (2011) Robot assisted nerve sparing radical cystectomy with bilateral extended lymph node dissection and intracorporeal urinary diversion for bladder cancer: Initial experience in 27 cases. *BJU Int* Accepted for publication.
- Canda AE, Asil E & Balbay MD. (2011) An unexpected resident in the ileum detected during robot assisted laparoscopic radical cystoprostatectomy and intracorporeal Studer pouch formation: *Taenia saginata* parasite. *J Endourol* 25(2):1-3.
- Canda AE, Dogan B, Atmaca AF, Akbulut Z & Balbay MD. (2011) Ureteric duplication is not a contraindication for robot assisted laparoscopic radical cystoprostatectomy and intracorporeal Studer pouch formation. *JSLS* In Press.
- Cancer Facts and Figures 2009. Atlanta: American Cancer Society 2009.
- Chade DC, Laudone VP, Bochner BH & Parra RO. (2010) Oncological outcomes after radical cystectomy for bladder cancer: open versus minimally invasive approaches. *J Urol* 183(3):862-69.
- Clinical Practice Guidelines in Oncology, version 1.2010. Bladder Cancer. National Comprehensive Cancer Network. Available at <http://www.nccn.org>. Accessed March 15, 2010.
- Guru KA, Perlmutter AE, Butt ZM, Piacente P, Wilding GE, Tan W, Kim HL & Mohler JL. (2009) The learning curve for robot-assisted radical cystectomy. *JSLS* 13(4):509-14.
- Guru KA, Sternberg K, Wilding GE, Tan W, Butt ZM, Mohler JL, et al. (2008) The lymph node yield during robot-assisted radical cystectomy. *BJU Int.* 102(2):231-4.
- Hayn MH, Hussain A, Mansour AM, Andrews PE, Carpentier P, Castle E, Dasgupta P, Rimington P, Thomas R, Khan S, Kibel A, Kim H, Manoharan M, Menon M, Mottrie A, Ornstein D, Peabody J, Pruthi R, Palou Redorta J, Richstone L, Schanne F,

- Stricker H, Wiklund P, Chandrasekhar R, Wilding GE & Guru KA. (2010) The learning curve of robot-assisted radical cystectomy: results from the International Robotic Cystectomy Consortium. *Eur Urol.* 58(2):197-202.
- Hellenthal NJ, Hussain A, Andrews PE, Carpentier P, Castle E, Dasgupta P, Kaouk J, Khan S, Kibel A, Kim H, Manoharan M, Menon M, Mottrie A, Ornstein D, Palou J, Peabody J, Pruthi R, Richstone L, Schanne F, Stricker H, Thomas R, Wiklund P, Wilding G & Guru KA. (2010) Surgical margin status after robot assisted radical cystectomy: results from the International Robotic Cystectomy Consortium. *J Urol.* 184(1):87-91.
- Hellenthal NJ, Hussain A, Andrews PE, Carpentier P, Castle E, Dasgupta P, Kaouk J, Khan S, Kibel A, Kim H, Manoharan M, Menon M, Mottrie A, Ornstein D, Palou J, Peabody J, Pruthi R, Richstone L, Schanne F, Stricker H, Thomas R, Wiklund P, Wilding G & Guru KA. (2011) Lymphadenectomy at the time of robot-assisted radical cystectomy: results from the International Robotic Cystectomy Consortium. *BJU Int.* 107(4):642-6.
- Herr H, Lee C, Chang S & Lerner S; Bladder Cancer Collaborative Group. (2004) Standardization of radical cystectomy and pelvic lymph node dissection for bladder cancer: a collaborative group report. *J Urol.* 171(5):1823-8.
- Huang GJ & Stein JP. (2007) Open radical cystectomy with lymphadenectomy remains the treatment of choice for invasive bladder cancer. *Curr Opin Urol* 17:369-8.
- Huang J, Lin T, Liu H, Xu K, Zhang C, Jiang C, Huang H, Yao Y, Guo Z & Xie W. (2010) Laparoscopic radical cystectomy with orthotopic ileal neobladder for bladder cancer: oncologic results of 171 cases with a median 3-year follow-up. *Eur Urol.* 58(3):442-9.
- Kasraeian A, Barret E, Cathelineau X, Rozet F, Galiano M, Sanchez-Salas R & Vallancien G. (2010) Robot-assisted laparoscopic cystoprostatectomy with extended pelvic lymphadenectomy, extracorporeal enterocystoplasty, and intracorporeal enterourethral anastomosis: initial Montsouris experience. *J Endourol.* 24(3):409-13.
- Kauffman EC, Ng CK, Lee MM, Otto BJ, Wang GJ & Scherr DS. (2011) Early oncological outcomes for bladder urothelial carcinoma patients treated with robotic-assisted radical cystectomy. *BJU Int.* 107(4):628-35.
- Lavery HJ, Martinez-Suarez HJ & Abaza R. (2010) Robotic extended pelvic lymphadenectomy for bladder cancer with increased nodal yield. *BJU Int.* 11. doi: 10.1111/j.1464-410X.2010.09789.x. [Epub ahead of print]
- Martin AD, Nunez RN, Castle EP. (2011) Robot-assisted Radical Cystectomy Versus Open Radical Cystectomy: A Complete Cost Analysis. *Urology.* 77(3):621-5.
- Menon M, Hemal AK, Tewari A, Shrivastava A, Shoma AM, El-Tabey NA, Shaaban A, Abol-Enein H & Ghoneim MA. (2003) Nerve-sparing robot-assisted radical cystoprostatectomy and urinary diversion. *BJU Int.* 92(3):232-6.
- Ng CK, Kauffman EC, Lee MM, Otto BJ, Portnoff A, Ehrlich JR, Schwartz MJ, Wang GJ & Scherr DS. (2010) A comparison of postoperative complications in open versus robotic cystectomy. *Eur Urol.* 57(2):274-81.
- Nieder AM, Mackinnon JA, Huang Y, Fleming LE, Koniaris LG & Lee DJ. (2008) Florida bladder cancer trends 1981 to 2004: minimal progress in decreasing advanced disease. *J Urol.* 179(2):491-5

- Nix J, Smith A, Kurpad R, Nielsen ME, Wallen EM & Pruthi RS. (2010) Prospective randomized controlled trial of robotic versus open radical cystectomy for bladder cancer: perioperative and pathologic results. *Eur Urol.* 57(2):196-201.
- Pruthi RS, Smith A & Wallen EM. (2008) Evaluating the learning curve for robot-assisted laparoscopic radical cystectomy. *J Endourol.* 22(11):2469-74.
- Pruthi RS, Nielsen ME, Nix J, Smith A, Schultz H & Wallen EM. (2010) Robotic radical cystectomy for bladder cancer: surgical and pathological outcomes in 100 consecutive cases. *J Urol.* 183(2):510-4.
- Rehman J, Sangalli MN, Guru K, de Naeyer G, Schatteman P, Carpentier P & Mottrie A. (2011) Total intracorporeal robot-assisted laparoscopic ileal conduit (Bricker) urinary diversion: technique and outcomes. *Can J Urol.* 18(1):5548-56.
- Schumacher MC, Jonsson MN & Wiklund NP. (2009) Robotic cystectomy. *Scand J Surg.* 98(2):89-95
- Skinner EC, Stein JP & Skinner DG. (2007) Surgical benchmarks for the treatment of invasive bladder cancer. *Urol Oncol.* 25(1):66-71.
- Shamim Khan M, Elhage O, Challacombe B et al: (2010) Analysis of early complications of robotic-assisted radical cystectomy using a standardized reporting system. *Urology.* Sep 7. [Epub ahead of print]
- Smith A, Kurpad R, Lal A, Nielsen M, Wallen EM & Pruthi RS. (2010) Cost analysis of robotic versus open radical cystectomy for bladder cancer. *J Urol.* 183(2):505-9.
- Stein JP, Cai J, Groshen S & Skinner DG. (2003) Risk factors for patients with pelvic lymph node metastases following radical cystectomy with en bloc pelvic lymphadenectomy: concept of lymph node density. *J Urol.* 170(1):35-41.

IntechOpen



Bladder Cancer - From Basic Science to Robotic Surgery

Edited by Dr. Abdullah Canda

ISBN 978-953-307-839-7

Hard cover, 460 pages

Publisher InTech

Published online 01, February, 2012

Published in print edition February, 2012

This book is an invaluable source of knowledge on bladder cancer biology, epidemiology, biomarkers, prognostic factors, and clinical presentation and diagnosis. It is also rich with plenty of up-to-date information, in a well-organized and easy to use format, focusing on the treatment of bladder cancer including surgery, chemotherapy, radiation therapy, immunotherapy, and vaccine therapy. These chapters, written by the experts in their fields, include many interesting, demonstrative and colorful pictures, figures, illustrations and tables. Due to its practicality, this book is recommended reading to anyone interested in bladder cancer.

How to reference

In order to correctly reference this scholarly work, feel free to copy and paste the following:

Abdullah Erdem Canda, Ali Fuat Atmaca and Mevlana Derya Balbay (2012). Robotic-Assisted Laparoscopic Radical Cystoprostatectomy and Intracorporeal Urinary Diversion (Studer Pouch or Ileal Conduit) for Bladder Cancer, Bladder Cancer - From Basic Science to Robotic Surgery, Dr. Abdullah Canda (Ed.), ISBN: 978-953-307-839-7, InTech, Available from: <http://www.intechopen.com/books/bladder-cancer-from-basic-science-to-robotic-surgery/robot-assisted-laparoscopic-radical-cystoprostatectomy-and-urinary-diversion-for-bladder-cancer>

INTeCH
open science | open minds

InTech Europe

University Campus STeP Ri
Slavka Krautzeka 83/A
51000 Rijeka, Croatia
Phone: +385 (51) 770 447
Fax: +385 (51) 686 166
www.intechopen.com

InTech China

Unit 405, Office Block, Hotel Equatorial Shanghai
No.65, Yan An Road (West), Shanghai, 200040, China
中国上海市延安西路65号上海国际贵都大饭店办公楼405单元
Phone: +86-21-62489820
Fax: +86-21-62489821

© 2012 The Author(s). Licensee IntechOpen. This is an open access article distributed under the terms of the [Creative Commons Attribution 3.0 License](#), which permits unrestricted use, distribution, and reproduction in any medium, provided the original work is properly cited.

IntechOpen

IntechOpen