

# We are IntechOpen, the world's leading publisher of Open Access books Built by scientists, for scientists

6,900

Open access books available

186,000

International authors and editors

200M

Downloads

Our authors are among the

154

Countries delivered to

TOP 1%

most cited scientists

12.2%

Contributors from top 500 universities



WEB OF SCIENCE™

Selection of our books indexed in the Book Citation Index  
in Web of Science™ Core Collection (BKCI)

Interested in publishing with us?  
Contact [book.department@intechopen.com](mailto:book.department@intechopen.com)

Numbers displayed above are based on latest data collected.  
For more information visit [www.intechopen.com](http://www.intechopen.com)



# The Laparoscopic Appendectomy – A Recent Trend

Arshad M. Malik

*Liaquat University of Medical and Health Sciences, Jamshoro (Sindh),  
Pakistan*

## 1. Introduction

Acute appendicitis is one of the commonest surgical problems afflicting a major population all over the world. No age is immune to it but it is most prevalent during adolescent and child hood. The outcome can be very serious at both extremes of life and there is a life time risk of developing acute appendicitis in about 5-8% nothing. An early surgical removal after diagnosis is the most preferred and agreeable treatment. Appendectomy through grid iron incision has enjoyed a unique reputation of a standard operation globally. It is one of the most common abdominal operations performed all over the world. The open appendectomy through right grid iron incision was introduced by Mc Burney (Mc Burney 1894) and this technique enjoyed decades of un-opposed reputation and widespread use globally because of its proven safety and efficacy. The introduction of laparoscopy has brought a major change in the field of surgery. The laparoscopic appendectomy is gradually gaining popularity over the past 10-15 years by way of proving improved diagnostic outcome and decreased rate of wound problems. It was way back in 1983 when a first laparoscopic surgery for acute appendicitis was performed by a German Gynaecologist Semm (Semm K 1983). There are a number of reports published in favour of laparoscopic approach in terms of rapid recovery, a faster wound healing, lowered rate of complications, and an early resumption of oral intake (Martin LC et al 1995) while others (John Brenden Hansen 1996) claimed that though it takes a comparatively longer time but yet is safe and effective way of treating acute appendicitis as it reduces post-operative stay substantially and would help the patient return to work earlier. An almost similar recommendation came from many similar studies in a very short span of time comparing laparoscopic versus open appendectomy, claiming substantial advantage over open technique (Rober Globus et al 1998). A superiority in terms of cosmetic results and cost-effectiveness was another reason that majority favoured this recently introduced technique. A recent study claims it to be a safe option in children compared to the open operation (Lee SL 2011). There were however a lot of reservations as to the safety and applicability of this procedure as elaborated by many studies (Ingraham et al 2010) (Yano H et al 2004) (Kamal M 2003). There is a limitation to the use of this laparoscopic approach in third world countries where the economical constraints, lack of facility and a general fear keeps them from getting operated (Saunders S 2002). Despite all the limitations ,the scope of laparoscopic appendectomy is on the rise and although it has not yet achieved the status of a “Gold Standard ” treatment as enjoyed by laparoscopic cholecystectomy, there is a gradual acceptance of this procedure all over the

world based on various factors in favour of laparoscopic approach. The main advantages reported over open appendectomy include an accuracy of diagnosis especially in females when various other conditions can mimic acute appendicitis, an excellent cosmetic outcome, minimal tissue trauma, substantially reduced operative and post operative complications, and an early return to work. Ulrich Guller et al 2004 proposed that laparoscopic appendectomy decreases in-hospital admission, in hospital mortality, and post operative complications. Despite innumerable reports favouring laparoscopic appendectomy, the technique is really slow to gain popularity and not many centres are doing this procedure regularly. There seems to be no obvious reasons for this. The uptake of laparoscopic technique for appendicitis is slow to evolve all over the world. Ioannis Kehagias et al 2008 reported recently very promising results of laparoscopic appendectomy emphasizing availability of the sophisticated instruments as well as adequate experience of the surgeon to play a key role for a successful laparoscopic appendectomy. The elderly patients are thought to be at a higher risk of developing complications following acute appendicitis and there are reports claiming that laparoscopic appendectomy is a presumably superior option for the elderly victims of acute appendicitis (Wu SC et al 2011). Despite of lots of benefits elaborated in many randomized trials and other similar studies talking high of laparoscopic approach, a number of critics have shown a marginal benefit of the laparoscopic approach over open conventional technique (Jane Garbutt 1999, Kathouda N 2005, Oannis Kehagias 2008, Olmi S 2995, Lee SL 2011, Saunders S 2002, Martin LC, 1995,). The adequate data in favour of this technique has not really brought a significant change of mind as yet and there is a clear split of opinion as to the optimum method of treatment of acute appendicitis. There is a school of thought which considers this mode of treatment to be time consuming, but shorter hospital stay, better cosmetic results and cost effective. This is contrary to the belief of many surgeons who continue to practice open appendectomy by the same conventional method considering it to be the standard operation for acute appendicitis. The real challenge in laparoscopic approach is considered to be those patients where the appendix is severely inflamed, twisted, retro-caecal or is in pelvis or there are firm adhesions making its skeletonization difficult by laparoscopic means. It is claimed that the commonest problems faced are in the complicated appendicitis where even the experts feel difficulty. A number of conflicting results negating the advocates were published making its feasibility questionable in complicated cases of acute appendicitis (Ortega AE et al 1995) (Bresciani et al 2005) (Katkhuda N 2005). Yoshiwa et al claim lack of proper training and lack of knowledge about basic technique to be responsible for its limited use presently. An extended and undue prolonged operative time taken in laparoscopic approach has been reported to be one of the disadvantages of this technique (Reiertsen O et al 1997). This has been attributed to the learning curve of the surgeons and it was believed that with experience the difference in operative time of the two techniques becomes almost negligible (Kehagias I et al 2008). Similarly, the cost effectiveness can be achieved by decreasing the operative time and a high level of skill to make it more feasible for the developing countries (Ali R et al 2010). The laparoscopic procedure is still under evaluation and a number of changes are made in the original procedure. Vipul D et al introduced a two port technique instead of three port technique introduced, (Song Yi Kim et al 2010). This report was carried out by a trainee and there was a learning curve of thirty patients. (Ulritch Guller et al 2004) proposed laparoscopic appendectomy to be much superior than the open technique in terms of hospital stay, cosmetics, early return to work and post-operative mortality. There are reports questioning its cost as there is longer operative time and use of disposable

instruments, multiplying the actual cost manyfolds compared to the open appendectomy (Ignacio RC 2004). This is contrary to the belief of others (Neendham PJ et al 2009) who claim that laparoscopic appendectomy can be performed in a reasonable cost despite use of disposable items. Despite accumulation of substantial data favouring laparoscopic appendectomy, there continues an expanding controversy as to the safety if this procedure in patients with complicated appendicitis as well as post-operative recovery and operative time.

## **2. Guidelines for laparoscopic appendectomy**

There are certain guidelines as laid down by the experts who are considered pioneers of various laparoscopic procedures. These guidelines would help the beginners to follow so as to avoid any undue stress and mistakes during the early phase of their training. These guidelines are based on the existing data coupled with individual experiences formed into consensus. These guidelines help the beginners to have a better understanding of the procedure as to the proper selection of the patients, the indications of laparoscopic appendectomy, various complications that might develop and thus to select the most appropriate operative procedure under a given situation. The best guidelines in this regard are provided by the society of American Gastro-intestinal and Endoscopic Surgeons (SAGES). A similar guideline focussing on diagnosis and treatment of acute appendicitis is provided by SSAT (Society for the surgery of alimentary tract).

## **3. Verities of laparoscopic appendectomy**

The laparoscopic appendectomy is divided into two basic approaches as under

1. Intra-corporeal Laparoscopic appendectomy
2. Extra-Corporeal appendectomy.

The intra-corporeal variety involves the creation of pneumo-peritoneum by a 10mm supra-umbilical port followed by the insertion two 5mm working ports well outside the midline. A thorough inspection of the abdominal cavity is followed by identification, skeletonization and removal of the appendix after ligation/clipping of the meso-appendix intra-corporeally. This approach is adopted and practiced at a number of centres and is gradually gaining reputation as a good alternative to the open appendectomy.

The extra-corporeal video assisted appendectomy is another type of laparoscopic appendectomy which involves the initial steps of intracorporeal appendectomy up till creation of pneumo-peritoneum, identification and skeletonization of appendix same as in the case of intra-corporeal appendectomy. The following steps differ in that the appendix is brought out on the surface through a 10 mm port in right iliac fossa and then further steps are just the same as in open appendectomy. This technique usually involves 2-3 ports (Konstadoulakis MM et al 2004) but a number of studies have recently published using the same technique with a single peri-umbilical port (Koontz CS et al 2006). The author compared video-assisted extra-corporeal appendectomy with conventional open appendectomy believing that this method has an advantage over open appendectomy of having less chances of diagnostic error as well as it has the advantages of open appendectomy of feeling the appendix, ligating the appendix manually outside on the surface. This has an additional advantage of having a secure ligation

of meso- appendix to avoid cystic arterial bleeding. Before displaying the results of the study, a brief introduction to the basic technique of video-assisted extra-corporeal appendectomy (VAECA) is given below.

### 3.1 Technique of video-assisted laparoscopic appendectomy ( Malik et al 2009 )

This is a modified form of laparoscopic appendectomy where we combine the steps of both open and intra-corporeal techniques of appendectomy. The surgeon stands on left side of the supine patient. A 10 mm sub-umbilical port is made for the camera while another 10 mm port is made in the right iliac fossa. Both of these ports can be interchanged for camera as and when needed. The identification and skeletonization of the appendix is much easier because of video-scopic vision where surgeon can actually visualize if there are any adhesions and a finger guided adhesiolysis can be done under vision. Once the appendix is identified and isolated, a grasper is introduced to get hold of the organ and the abdominal cavity is deflated and appendix is drawn on the surface. The remaining steps are just as the way we perform open appendectomy. Once the meso-appendix is ligated and appendix removed, the appendicular stump is returned back and ports are closed after a final look inside the abdominal cavity. Some of the steps of this procedure are highlighted below by the following operative pictures

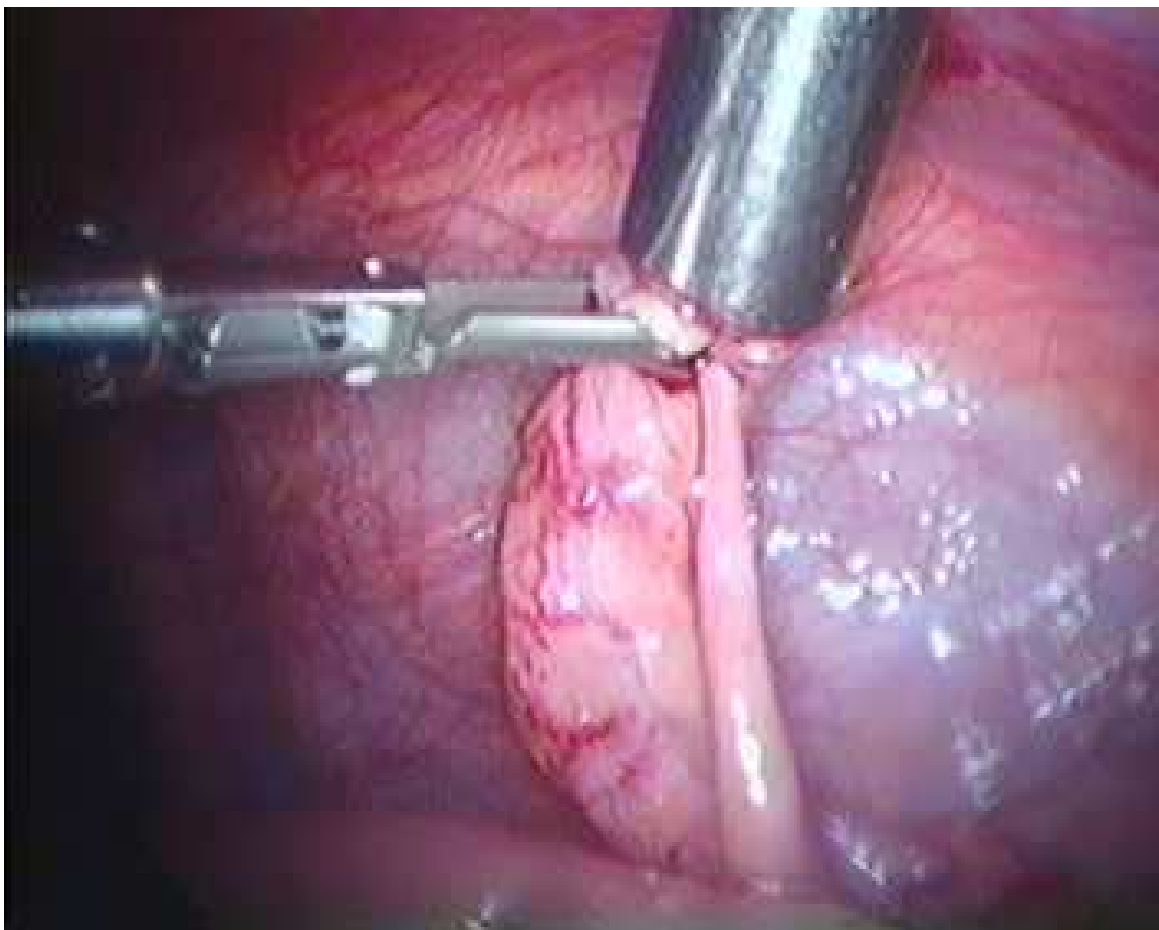


Fig. 1. Appendix drawn into sheath of 10mm trocar

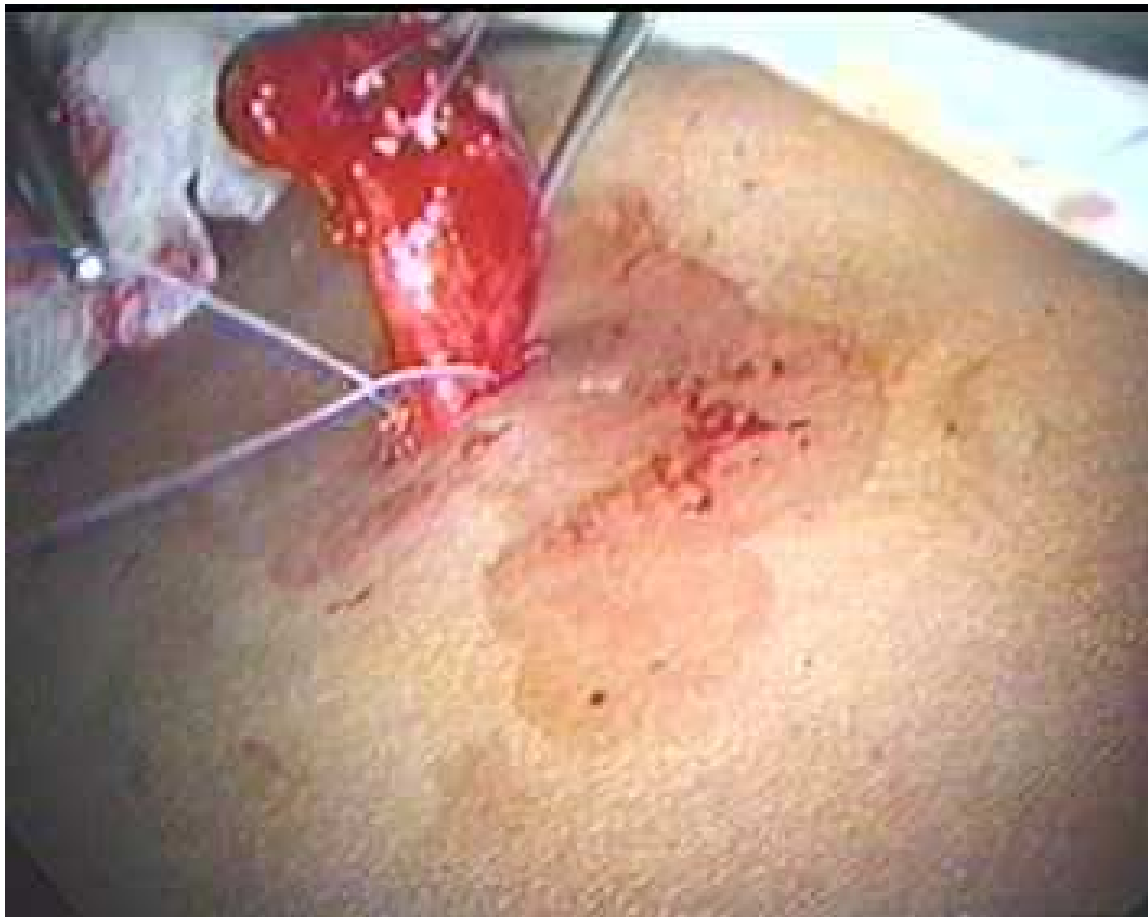

Fig. 2. Appendix drawn out on surface and meson-appendix legated.

### 3.2 Authors study

Author conducted a study in 2009 comparing the open appendectomy (OA) versus Video assisted extra-corporeal appendectomy (VAECA) wherein a total number of 283 patients of acute appendicitis were split into two groups. We explained this newly emerging technique as well as the conventional appendectomy to all the patients as and when they were diagnosed. The intended operative techniques were fully explained to the patients in terms of merits and demerits of the operative technique. The grouping of the patients was based on their own choice and by coin toss when patients did not show any preference for any particular technique. Of the total number, 150(53%) were operated by open Technique while 133(47%) by video-assisted extracorporeal technique of appendectomy. Majority of patients (89%) in the VAECA group were operated by three port technique while few (11%) could be successfully completed by two ports only. All patients below 10 years and those with suspected appendicular mass were excluded from the study. This was an initial study on the video assisted technique and we had promising results to conclude that VAECA could be a better alternate to open appendectomy in a majority of patients with acute appendicitis without complications. Some of the results are shown below showing comparison of the two techniques.

The results in our study were very promising in terms of safety, reliability and feasibility. The major advantages that we could conclude was fewer wound infections, less severe post-



operative pain, better cosmesis, shorter operative time and early recovery. It was also compared in terms of cost as we found out that there is reasonable reduction in the total cost of operation in VAECA group because we ligated the mesoappendix and appendicular stump by a suture in place of metal clips usually applied in intracorporeal technique of laparoscopic appendectomy. The magnificent telescopic vision of whole abdomen makes identification and dissection of inflamed appendix reasonably easier compared to open appendectomy. It is claimed that VAECA combines safety and efficiency of both intracorporeal laparoscopic appendectomy and conventional open appendectomy ( Valioulis I et al 2001 ). Any associated pathology can also be identified by using video assisted technique and this is of particular significance when diagnosis of acute appendicitis is doubtful (Mayer A et al 2004). The lowered rate of wound sepsis in our study are because of least contact of infected appendix with the surrounding walls of the port as it is fully drawn into the sheath of the trocar before its retrieval. This is contrary to the belief of Suttie SA and Seth S who claim an increased rate of wound infection in video-assisted extra-corporeal appendectomy compared to conventional open appendectomy (Suttie SA and Seth S 2004). Author continued the same study and a total number of the study subjects has reached to 1700 of which only 625(36.76%) gave consent for open appendectomy while remaining (63.23%, n=1075) patients were willing for video-assisted laparoscopic appendectomy. This clearly shows that the results of video-assisted laparoscopic appendectomy are more acceptable to the patients. There was a gross difference in the total operative time compared to the open conventional appendectomy as well as intra-corporeal appendectomy. The diagnostic error as well as confirmation of the diagnosis is more reliable in the video-assisted extra-corporeal appendectomy. The total cost is reduced in VAECA due to use of suture in place of clips and reduced operative time also adds reducing the cost of operation. Post-operative complications are reasonably less in VAECA compared to other two techniques of appendectomy. Author is convinced that video-assisted approach of laparoscopic appendectomy is a better alternative procedure that can be effective when there is simple acute appendicitis without mass formation or many adhesions. Further RCT's on this technique of VAECA can help establishing this technique as a better alternate in un-complicated patients of acute appendicitis and more so in young adult females where the diagnosis of acute appendicitis cannot be established with certainty.

	Type of operation (n = 283)		P value
	OA n (%)	VAECA n (%)	
<b>Operative time:</b>			
• Up to 30 minutes	14(9.3%)	95(71.4%)	
• 31-60 minutes	99(66.0%)	33(24.8%)	
• 61-90 minutes	31(20.7%)	3(2.3%)	
• Over 90 minutes	6(4.0%)	2(1.5%)	

\*P value is <0.001 for all groups and is statistically highly significant  
N= Number of the patients

Table 1. Comparison of mean operative time in both groups.

	Type of operation (n = 283)		P-Value
	OA n (%)	VAECA n (%)	
<b>Operative problems:</b>			
• Bleeding from appendicular artery		3(2.0%)	7(5.3%)
• Perforation of appendix during mobilization		6(4.0%)	9(6.8%)
• Lengthening of incision		32(21.3%)	4(3.0%)
• Minor trauma to neighboring structures		2(1.3%)	5(3.8%)
• Difficulty in mobilization		17(11.3%)	23(17.3%)
• Difficulty in localization of appendix		19(12.7%)	7(5.3%)

\* *P value* is statistically highly significant for all groups  
N= Number of patients

Table 2. Comparison of operative complications in both groups

	Type of operation (n = 283)		P value
	OA n (%)	VAECA n (%)	
Minor wound /port infection	13(8.7%)	7(5.3%)	< 0.01*
Partial wound dehiscence	9(6.0%)	0	
Wound/port bleeding	3(2.0%)	5(3.8%)	
Respiratory tract infection	13(8.7%)	7(5.3%)	
Residual abscess	5(3.3%)	2(1.5%)	

\* *P value* is statistically significant  
N= Number of patients

Table 3. Postoperative complications

	Type of operation (n = 283)		P value
	OA n (%)	VAECA n (%)	
1-2 days	66(44.0%)	128(96.2%)	< 0.001*
3-4 days	42(28.0%)	1(0.8%)	
5-6 days	42(28.0%)	4 (3.0%)	

\* *P value* is statistically highly significant  
N= Number of patients

Table 4. Hospital stays in both groups



#### 4. Recent advances in laparoscopic appendectomy

During the last few years there has been a dramatic improvement in the techniques of gaining access to the abdominal cavity minimizing the number of ports to a single incision in order to improve the cosmetic results. A number of techniques such as single incision laparoscopic surgery (SILS) and natural orifice transluminal surgery (NOTES) are introduced to improve the outcome of minimal access surgery and to make it still further less traumatic to the patients. The same advancements also apply to the laparoscopic appendectomy to make it more and less traumatic by way of reducing the number of ports. Initially both intra-corporeal and extra-corporeal techniques were performed by two to three ports. Recently a single incision, multi-luminal port appendectomy is introduced. The safety and efficacy of these newer techniques is yet to be established as there are no Randomized control studies to claim their benefits over multi port laparoscopic appendectomy (Rehman H 2011). Roberts KE (2009) described a true single port appendectomy (TSPA) by a new technique which he describes as "puppeteer technique" using single port and a pulley of thread pulling the appendix. He claims this technique to be first of its kind which reduces the minimal access surgery to a further minimum level. Ates et al 2007 described a similar single port technique successfully and claim that this single port technique further makes minimally invasive surgery a better and safe option with minimal tissue trauma. Natural orifice transluminal endoscopic surgery (NOTES) is the most recent advancement in laparoscopic surgery. A cadaveric model appendectomy using NOTES technique by Santos BF et al 2011 via anterior transrectal route is found to be feasible, time saving and easier to perform compared to posterior rectal approach. Eung Jin Shin et al 2010 reported transvaginal appendectomy using NOTES indicating many limitations to its use in human beings. Although there has been a tremendous improvement and advancement in minimally invasive surgical techniques to improve the outcome of different surgical procedures in terms of cosmetic results and cost effectiveness but the final word about their efficacy and effectiveness is yet to be established.


#### 5. References

- Ali R, Khan MR, Pishori T, Tayyab M. Laparoscopic appendectomy for acute appendicitis. Is this a feasible option for developing countries? *Saudi J Gastroenterol* 2010; 16(1):25-29.
- Ates O, Hakguder G, Olguner M, Akgur FM. Single-port laparoscopic appendectomy conducted intra-corporeally with the aid of a transabdominal sling suture. *J Pediatr Surg* 2007;42(6):1071-4.
- Bresciani C, Perez RO, Habr-gama A, Jacob CE, Ozaki A, Batagello C et al. Laparoscopic versus standard appendectomy outcomes and cost comparison in the private sector. *J gastrointestinal Surg* 2005; 9:1174-80.
- Chung RS, Rowland DY, Li P, Diaz J. A metaanalysis of randomized controlled trials of laparoscopic versus convention appendectomy. *Am J Surg* 1999; 177:250-53
- Emple LK, Litwin DE, McLeods RS. A Meta analysis of laparoscopic versus open appendectomy inpatients suspected of having acute appendicitis. *Ca J Surg* 1999; 42: 377-83.
- Heinzelmann M, Simmen HP, Cummins, Laeriader F. Is laparoscopic appendectomy the new Gold standard? *Arch surg* 1995; 130(70); 782-85.

- Hansen JB, , Smithers BM, Schache D, Wall DR Miller BM, Schache, Wall Dr. Laparoscopic versus open appendectomy. A randomized trial. *World J Surg* 1996; 20(1):17-21.
- Ignacio Rc, Burke R, Spencer D, Bissel C, Dorsainvi C, Lucha PA. Laparoscopic versus open appendectomy. What is the real difference? Results of a prospective randomized double blinded trial. *Surg Endos* 2004; 18:334-337.
- Ingraham AM, Cohen ME, Bjilimoria KY, Pritts Ta, Ko CY, Esposito TJ. Comparison of outcomes after laparoscopic versus open appendectomy for acute appendicitis at 222 ACS NSQIP hospitals. *Surgery* 2010; 148(4):625-35.
- Jane Garbutt, Jane MBCh, Soper Nathaniel j, Shannon, William D, Botero Anna, et al. Meta analysis of Randomized controlled trials comprising Laparoscopic and open appendectomy. *Surgical laparoscopy and endoscopy* 1999; 9(1): 17-26.
- Kamal M, Qureshi KH. Laparoscopic versus open appendectomy. *Pak J Med Scein*: 42: 23 - 26.
- Kathouda N, Mason RJ, Towfigh S, GeyorgyannA, Essani R. Laparoscopic versus open appendectomy: a prospective randomized double blind study. *Ann Surg* 2005; 242:439-448.
- Konstadoulakis MM, Gomatos IP, Antonakis PT, Manouras A, Albanopoulos K, Nikiteas N, Leandros E, Bramis J. Two-trocar Laparoscopic assisted appendectomy versus conventional laparoscopic appendectomy in patients with acute appendicitis. *J laparoendosc adv surg tech* 2006; 16:27-32.
- Koontz CS, Smith LA, Burkholder HC, Higdon K, Aderhold R, Carr M. Video assisted trans-umbilical appendectomy in children. *J Pediatr Surg* 2006; 41:710-712.
- Kehagias I, Karamanakis SN, Panagiotopoulos S, Panagopoulos K, Kalfarentzos F. Laparoscopic versus open appendectomy. Which way to go? *World J Gastroenterol* 2008; 14:4909-4914.
- Lee SL, Yaqhoubian A, Kaji A. Laparoscopic versus open appendectomy in children: Outcomes comparison based on age, sex and perforation status.. *Arch Surg* 2011 [ Epub ahead of print].
- Malik AM, Talpur AH, Laghari AA. Video-assisted laparoscopic extra-corporeal appendectomy versus open appendectomy. *J Laparoendosc Adv Surg Tech* 2009; 19(3):355-9.
- Mayer A, Preuss M, Roesler S, Lainka M, Omlor G. Transumbilical laparoscopic-assisted one-trocar appendectomy – TULAA – as an alternative operation method in the treatment of appendicitis. *Zentralbl Chir* 2004; 129(5): 391-5.
- Ortega AE, Hunter JG, Peters JH, Swanstorm LL, Schirmer B. A prospective, randomized comparison of Laparoscopic appendectomy with open appendectomy. Laparoscopic appendectomy group. *Am J Surg* 1995; 169:20812?
- Oannis Kehagias, stavros Nikolas Karanamanakos , Sypros Panagiotopoulos, Konstatinos Panagopoulos , Fotis Kalfarentzos. Laparoscopic versus open appendectomy: which way to go? *World J Gastroenterol* 2008; 14(31):4909-4914.
- Olmi S, Magnone S, Bertolini A, Croce E. Laparoscopic versus open appendectomy in an acute appendicitis: a randomized prospective study. *Surg Endosc*. 2005; 19: 1193-95.
- Pitfalls in laparoscopic appendectomy. *J abdominal Emerg* 2002; 22(6):889-894.
- Rehman H, Rao AM, Ahmed. Single incision versus conventional multi-incision appendectomy for suspected appendicitis. *Cochrane database syst Rev* 2011; 6; 7: CD009022.

- Reiertsen O, Larsen S, Trondsen E, Edwin B, Faerden AE et al. Randomized controlled trial with sequential design of laparoscopic versus conventional appendectomy. *Br J Surg* 1997;84: 842-7.
- Roberts KE. True single-port appendectomy: first experience with the "Puppeteer technique". *Surg endosc* 2009;23(8):1825-30.
- Shin EJ, Jeong GA, Jung JC, Cho GS, Lim CW et al. Transvaginal appendectomy. *J Korean Soc Coloproctology* 2010; 26(6): 429-32.
- Santos BF, Hungness ES, Boller AM. Development of a feasible transrectal natural endoscopic surgery (NOTES) approach in a cadaveric appendectomy model: anterior is better. *Surg Endosc* 2011; {Epub ahead of print}.
- Saunders S, Lefering R, Neuqubauer EA. Laparoscopic versus open surgery for suspected appendicitis. *Chochrane database sys rev* 2002 ;( 1): CD 00 1546.
- Martin LC, Puente I, Sosa JL, Bassin A, Breslaw R, McKenney MG, E Ginzburg, Saleeman D. Open versus laparoscopic appendectomy. A prospective randomized comparison. *Ann Surg* 1995; 222(3):256-262.
- Semm K. Endoscopic appendectomy. *Endoscopy* 1983; 15:59-64.
- Suttie SA, Seth S, Driver CP, Mahomed AA. Outcome after intra-and -extra-corporeal laparoscopic appendectomy techniques. *Surg Endosc* 2004; 18(7): 1123-5.
- Vipul D. Yagnik Jignesh B, Rathod, Ajay G Phatak. A retrospective study of two-port appendectomy and its comparison with open appendectomy and three port appendectomy. *Saudi J Gastroenterol* 2010; 16(4):268-271.
- Valioulis I, Hameury F, Dahmani L, Levard G. Laparoscope-assisted appendectomy in children: the two trocar technique. *Eur J pediatr Surg* 2001; 11(6):391-4.
- Wu SC, Wang YC, Fu CY, Chen RJ, Huang JC, Lu CW et al. Laparoscopic appendectomy provides better outcomes than open appendectomy in elderly patients. *Am Surg* 2011; 77(4):466-70.
- Yano H, Murakami M, Nakano Y, Tone T, Ohnishi T, Iwazawa T et al. Laparoscopic treatment for perforated appendicitis with pelvic abscess. *Digestive endoscopy* 2004; 16:: 343-6.
- Yoshikawa Seiichiro, Kidokoro Iba Tishiaki, Sugiyama Kazuyushai, Fukunaga Tetsu et al.

IntechOpen



## **Advances in Laparoscopic Surgery**

Edited by Dr Arshad Malik

ISBN 978-953-307-933-2

Hard cover, 148 pages

**Publisher** InTech

**Published online** 01, February, 2012

**Published in print edition** February, 2012

Laparoscopic surgery, also called minimal access surgery, has revolutionized the field of surgery over the past few years. It has gained worldwide popularity and acceptance by surgeons and patients alike. Minimal scarring, less pain, and shorter hospital stay are the main reasons behind the global appeal of this novel technique. There has been a tremendous improvement in the technique, as well as in the instruments. The technique has passed through the stages of simple laparoscopic surgery to advanced levels, where more complicated procedures are being successfully attempted. The recent introduction of robotic surgery is also gaining popularity, in addition to single port laparoscopic surgery (SILS), which can be scarless surgery. Most of the surgical procedures, which were considered contraindication for the laparoscopic approach, have eventually become the most common and acceptable indications today. This book is intended to provide an overview of the most common procedures performed laparoscopically, as well as some recent advancements in the field.

### **How to reference**

In order to correctly reference this scholarly work, feel free to copy and paste the following:

Arshad M. Malik (2012). The Laparoscopic Appendectomy – A Recent Trend, *Advances in Laparoscopic Surgery*, Dr Arshad Malik (Ed.), ISBN: 978-953-307-933-2, InTech, Available from:  
<http://www.intechopen.com/books/advances-in-laparoscopic-surgery/the-laparoscopic-appendectomy-a-recent-trend->

**INTECH**  
open science | open minds

### **InTech Europe**

University Campus STeP Ri  
Slavka Krautzeka 83/A  
51000 Rijeka, Croatia  
Phone: +385 (51) 770 447  
Fax: +385 (51) 686 166  
[www.intechopen.com](http://www.intechopen.com)

### **InTech China**

Unit 405, Office Block, Hotel Equatorial Shanghai  
No.65, Yan An Road (West), Shanghai, 200040, China  
中国上海市延安西路65号上海国际贵都大饭店办公楼405单元  
Phone: +86-21-62489820  
Fax: +86-21-62489821

© 2012 The Author(s). Licensee IntechOpen. This is an open access article distributed under the terms of the [Creative Commons Attribution 3.0 License](https://creativecommons.org/licenses/by/3.0/), which permits unrestricted use, distribution, and reproduction in any medium, provided the original work is properly cited.

IntechOpen

IntechOpen