

We are IntechOpen, the world's leading publisher of Open Access books Built by scientists, for scientists

6,900

Open access books available

186,000

International authors and editors

200M

Downloads

Our authors are among the

154

Countries delivered to

TOP 1%

most cited scientists

12.2%

Contributors from top 500 universities



WEB OF SCIENCE™

Selection of our books indexed in the Book Citation Index
in Web of Science™ Core Collection (BKCI)

Interested in publishing with us?
Contact book.department@intechopen.com

Numbers displayed above are based on latest data collected.
For more information visit www.intechopen.com



IVUS Role in Studies Assessing Atherosclerosis Development

T. Kovarnik¹, A. Wahle², R.W. Downe² and M. Sonka²

¹*2nd Department of Medicine - Department of Cardiovascular Medicine,
First Faculty of Medicine, Charles University in Prague and
General University Hospital in Prague,*

²*Dept. of Electrical and Computer Engineering,
The University of Iowa, Iowa City IA,*

¹*Czech Republic*

²*USA*

1. Introduction

Atherosclerosis is known as a chronic progressive disease with accumulation of atherosclerotic plaque inside the vessel wall. Angiography studies revealed small (1-2%) increase of lumen during high dose lipid-lowering therapy, but angiography is not the appropriate tool for plaque analysis and has many limitations for precise lumen measurement due to its projective nature. In contrast, intravascular ultrasound or IVUS can accurately measure lumen and vessel diameters, and consequently determine local plaque burden. Careful mechanical pullback allows volume measurements of the lumen, vessel and plaque over a vessel segment. Serial measurements (baseline and follow-up after several months, typically 12±3 months) allow to evaluate changes of these volumes, thus to search for plaque progression or plaque regression and assess their mechanisms (for example decrease of plaque volume or increase of vessel volume), type of vessel reaction (positive and negative remodeling), development of risky plaque features like plaque ulceration and plaque ruptures.

Studies with intravascular ultrasound have shown that disease progression can be stopped (GAIN¹, REVERSAL²) or reversed (ASTEROID³, ESTABLISH⁴, COSMOS⁵), especially in response to aggressive lipid-lowering treatment. The mean changes of plaque volume in the treated groups were quite small; on the other hand, large scale lipid-lowering trials have shown significant reduction of ischemic events. This discrepancy between the clinical benefits and the small changes in plaque mass can be explained by plaque stabilization (changes of plaque composition from a high risk profile to a low risk profile). However, conventional grayscale IVUS has significant limitations in the assessment of plaque composition. Virtual histology (VH) based on spectral analysis of IVUS radiofrequency data was developed to quantify coronary plaque components⁶.

Risk factors for atherosclerosis are same for all coronary arteries, but some regions are more affected than others like the proximal third of the arteries, ostial regions, and bifurcations. There must be some local factor playing an important role. Local wall shear stress has been

identified as such a factor, which is caused by friction between virtual layers of blood inside arteries (the velocity of blood flow is maximal in the middle part of arteries and minimal just next to the endothelium). Shear stress induces deformation of endothelial cells and activates many pro-atherosclerotic genes (VCAM, ICAM, endothelin etc).

This chapter summarizes results of several aforementioned studies and their impact on routine daily practice. Further, it explains how to perform serial IVUS study with precise measurement of plaque volume changes and plaque risk feature changes. Second part of this chapter is focused on 3D vessel reconstruction based of angiography, IVUS, virtual histology and shear stress analysis fusion, which is the technique used for better detailed analyses of the atherosclerotic development.

2. Atherosclerosis

2.1 Atherosclerosis development

Atherosclerosis and its complications are the most frequent causes of mortality and morbidity in the developed countries. The atherosclerotic research made a great progress in investigation of atherosclerosis development, but the regression of atherosclerosis is still a process, which is not well understood.

The best description of atherosclerosis development was proposed by H. Stary et al.⁷, who recognized eight stages of atherosclerotic plaque maturation:

- type I - *initial lesion* (adaptive intimal thickening)
- type II - fatty streaks (intimal xanthomas, intima is infiltrated by macrophages, which change their phenotype into foam cells)
- type III - preatheroma (pathologic intimal thickening, lysis of foam cells and extracellular accumulation of lipid droplets and lipid pools)
- type IV - *atheroma* (formatting of lipid core)
- type V - *fibroatheroma* (lipid core is covered by a fibrous cap)
- type VI - *complicated lesion* (development of plaque fissures and plaque rupture, bleeding to plaque from vasa vasorum)
- type VII - calcified lesion
- type VIII - fibrous lesion

Types I-II are also called initial lesions, types IV and V developed lesion, type VI is called a complicated lesion and types VII and VIII chronic lesions⁸. This description of atherosclerosis development was done by examinations of post mortem specimens from adults and children. One of the most important findings is that the atherosclerotic mass is located in the vessel wall, and that the lumen area is preserved by positive remodeling up to a specific threshold when luminal narrowing starts to occur. This finding was also confirmed *in vivo* by IVUS⁹. The process of remodeling cannot be observed during coronary angiography, given that only the lumen is visualized and its patency is originally retained. While positive remodeling preserves the lumen, at the same time it constitutes a risk factor for development of an acute coronary syndrome. A likely common pathway is the effect of metalloproteases (enzymes which can breakdown collagen). They allow vessel enlargement, but also increase risk of plaque rupture due to the decrease of collagen amount inside the plaque¹⁰.

Further morphologic features indicating vulnerable plaque are plaque rupture and higher content of necrotic tissue. A very specific type of the rupture-prone plaque is called thin cap fibroatheroma (TCFA). Pathologic description of this type of plaque consist of a large necrotic core with an overlying thin and disrupted fibrous cap infiltrated by macrophages. The smooth

muscle cell components within the cap are absent or sparse. The thickness of such a thin fibrous cap is less than $65\text{ }\mu\text{m}$ ^{11,12}, so thin that it may not be identifiable even with IVUS.

2.2 Shear stress

While the entire coronary arteries are exposed to the systemic risk factors, atherosclerotic lesions frequently form at specific regions such as at the vicinity of side branches, along the outer wall of bifurcations, and on the inner wall of curved vessels. An important local factor contributing to lesion formation in these locations is the effective endothelial shear stress (ESS)¹³, also called wall shear stress (WSS). Many studies confirmed the mechanistic role of low ESS in the development of atherosclerosis¹⁴⁻¹⁷. ESS is the tangential force derived from the friction of the flowing blood on the endothelial surface of the arterial wall and is proportional to the product of the blood viscosity (μ) and the spatial gradient of blood velocity at the wall.

Viscosity can be measured or calculated from the measured hematocrit. Intracoronary blood flow can be calculated directly from the time required for the volume of blood contained within the vascular section to leave this section and be displaced by radio-opaque material during a contrast injection¹⁸.

Normal ESS is pulsatile and unidirectional with magnitude that vary within a range of 15-70 dyne/cm² over the cardiac cycle¹⁷. Stone et al.¹⁹ published that plaque progression in minimally diseased coronary artery subsegments occurs almost exclusively in the areas of low ESS. At the same time, the vessels react on plaque progression by positive remodeling in the regions with a low ESS. However, the positive remodeling was also found in regions with high ESS with no plaque progression. It is important to keep in mind that imaging may be performed at a time when the ESS distribution, which leads to a specific plaque development, may have already been altered by plaque development at this or an adjacent location²⁰. There are likely multiple stimuli and mechanistic pathway responsible for such positive remodeling. Low ESS contributes not only to plaque progression, but also increases the plaque vulnerability²¹. On the contrary, Helderma et al.²² found higher numbers of macrophages and higher metalloproteases activity in the region with high ESS. The question how the low ESS contributes to the plaque vulnerability has not been reliably answered yet. The mechanisms how low ESS influences local atherosclerosis likely includes activation of mechanoreceptors in the membrane of the endothelial cells and this signal activates or inhibits mechanosensitive genes. The atheroprotective genes are suppressed, whereas the pro-atherogenic genes are upregulated in the regions with a low ESS²³.

2.3 Atherosclerosis regression

The atherosclerosis was thought to be a one-way process for many years. However, atherosclerosis regression was seen in autopsy findings from children, in angiographic studies and in studies conducted with IVUS.

Fatty streaks in the aorta and the coronary arteries can be seen even in one year old children. These changes disappear at the age of four years and have an unquestionable relationship with breast feeding. Until now, it is not clear whether these findings reflect normal physiologic changes or whether they exhibit signs of premature atherosclerosis²⁴.

2.4 Angiographic studies

Several angiographic studies assessing effects of statins on plaque progression have been published. The main target was the assessment of the minimal lumen diameter or mean

lumen diameter, differences between 0.03-0.08 mm were reported. It is questionable whether the angiography can precisely detect these negligible differences. Furthermore, these lumen changes are only indirect markers of plaque changes. The overview of angiographic studies is provided in Table 1.

| | study | change of MLD | change of LDLc |
|--------------------|-----------------------|-----------------------|----------------|
| <i>simvastatin</i> | SCAT ²⁵ | - 0.07 mm / 3-5 years | - 30% |
| | MASS ²⁶ | - 0.08 mm / 4 years | - 31.4% |
| <i>lovastatin</i> | CCAIT ²⁷ | - 0.05 mm / 2 years | - 29% |
| <i>pravastatin</i> | REGRESS ²⁸ | - 0.03 mm / 2 years | - 25% |
| | PLAC-1 ²⁹ | - 0.03 mm / 1 year | - 28 |
| <i>fluvastatin</i> | LCAS ³⁰ | - 0.028mm / 2.5 years | - 22.5% |

Abbreviations: MLD = minimal lumen diameter, LDLc = low density lipoprotein cholesterol

Table 1. Angiographic studies with statins.

2.5 Studies with intravascular ultrasound - Methodology

IVUS can precisely measure lumen, vessel and plaque volumes and therefore is an ideal tool for performing follow-up studies assessing changes of these volumes during lipid lowering therapy. Two different IVUS designs can be used: Rotating element IVUS catheters operating at frequencies of 40 MHz, or electronic phased array catheters operating at a frequency of 20 MHz. Automatic motorized pullback is mandatory at a rate of 0.5 or 1.0 mm/s for reliable three-dimensional imaging. There are several important factors which influence the pullback quality³¹

1. Adequate battery power in battery controlled pullback device. Using a battery at the end of its life produces a non-continuous pullback with a decreasing speed.
2. Opening of the Y connector before starting the pullback. It causes small bleeding, but the movement of IVUS catheter is significantly smoother and thus more accurate.
3. Straightening of the IVUS catheter before pullback, otherwise the speed of the IVUS catheter is not continuous/constant-speed at the beginning of the acquisition
4. Even if the catheter is straightened, the pullback is the least accurate at the beginning of pullback and most accurate in the proximal part of image vessel. For this reason, it is recommended to start the IVUS pullback about 10 mm distal to the location of interest.

Patients suitable for a plaque regression study are usually admitted for stable angina pectoris and undergo diagnostic angiography in the majority of cases. Patients with normal findings on coronary angiography are excluded. For some research protocols, patients with a left main stenosis or a significant stenosis of all three coronary arteries may also be excluded because they will require revascularization and would not be suitable for a follow-up study. It is questionable whether patients with one significant stenosis should or should not be included. From our point of view, symptomatic patients with at least one significant stenosis should undergo revascularization and not be included in a medication-based plaque regression study.

The ideal situation would be to perform IVUS in all three coronary arteries and to follow all identified plaques. However, such a design would be time consuming and complicated for the analysis and therefore, in a majority of trials, only one vessel is investigated at a time.

The inclusion criterion is typically the identification of at least one location with the luminal stenosis > 20% by angiography, another useful criterion is may be plaque burden > 40% assessed by IVUS. In case of similar findings in more than one coronary artery during angiography, the artery with the longer plaque, or in case of several stenoses present in any single artery, the plaque with the most severe plaque burden should be selected for the IVUS analysis. The recommended segment length is greater than 30 mm with at least two clear landmarks (fiducial points) in the proximal and distal parts of the analyzed segment. An obvious proximal landmark in the left coronary artery is the left main bifurcation. Further landmarks may be clearly defined side branches (conus branch or proximal atrial branch in the right coronary artery) or some recognizable calcifications. Despite the clear landmarks and identical conditions of the pullbacks during the baseline and follow-up, the baseline/follow-up pullback lengths represented by frame counts will not be identical in the majority of cases. Possible reasons for this situation are technical errors while performing of pullback (low battery power, not straightened IVUS catheter before pullback, tight Y connector), or a slightly different trajectory of the IVUS catheters due to different positions of guide wires inside the coronary artery. Differences between the baseline and follow-up in the number of frames may be up to 15%, which is considered acceptable. Consequently, volumes may have to be calculated using the mean length between landmarks from the two studies³¹.

Several automatic border detection software applications were developed to decrease the necessity of manual tracing. However, according to our experiences, careful inspection of all acquired frames and providing manual correction of almost all frames is frequently necessary during baseline/follow-up trials. The presence of calcium further complicates adventitial border detection. Heavily calcified lesions should be avoided for these types of trials due to a high risk of inaccuracy of volume measurements. Using cross sectional analysis, a single deposit with an arc of calcium < 45 degrees or multiple small arcs of up to 180 degrees can be acceptable since they can be extrapolated. Another challenging part of a vessel when performing vessel wall border detection are regions with originating side branches. Several rules are recommended unless the branch is specifically modeled as such as described in the next paragraphs: The EEM contour should be interpolated to follow the main vessel cross-sections immediately proximal and distal to the side branch and the lumen contour should be drawn on top of the EEM contour at the mouth of the side branch³¹.

The parameters, which may be calculated include total atheroma volume (TAV) counted as $\Sigma(\text{EEM}_{\text{CSA}} - \text{Lumen}_{\text{CSA}})$ and percent atheroma volume PAV counted as $(\Sigma(\text{EEM}_{\text{CSA}} - \text{Lumen}_{\text{CSA}}) / \Sigma \text{EEM}_{\text{CSA}}) \times 100$. Note that the presented simple calculation of TAV would not represent a true volume and would only be valid for comparisons if the inter-frame distance stays constant across all analyses. Therefore, TAV should be normalized with respect to the lesion length as described earlier: $\text{TAV} / \text{lesion length}$ or normalized as $\Sigma(\text{EEM}_{\text{CSA}} - \text{Lumen}_{\text{CSA}}) / (\text{number of analyzed frames per patient})$ and multiplied by mean/median no. of analyzed frames in the population³¹⁻³³. For expressing of changes between baseline and follow-up, the absolute change of TAV or PAV (follow-up minus baseline) can be used and the percent change of TAV can be expressed as $(\text{TAV}_{\text{follow up}} - \text{TAV}_{\text{baseline}} / \text{TAV}_{\text{baseline}} \times 100)$ ³¹. The same approach to quantifying changes is possible for lumen volumes and vessel volumes.

Another set of interesting and important parameters is describes the vessel remodeling. For serial studies, it is recommended to calculate a remodeling index as $(\text{vessel volume}_{\text{follow up}} - \text{vessel volume}_{\text{baseline}})$, in which a positive value means positive remodeling and conversely a negative value represents negative remodeling. Furthermore, vessels with the positive

remodeling should be subdivided into expansive (over compensatory) where $\Delta EEM / \Delta atheroma$ is > 1 or incomplete where $\Delta EEM / \Delta atheroma$ is between 0 and 1.³¹

More sophisticated assessment of plaque behavior is enabled by 3D reconstruction of vessels, which is done by fusion of angiography and IVUS. This technique builds geometrically correct 3-D or 4-D (i.e., 3-D over all phases of the cardiac cycle) reconstructions of coronary arteries and computes quantitative indices of coronary lumen and wall morphology. The reconstructions may also serve as input for hemodynamic and morphologic analyses and allow for interactive visualization³⁴ (Figure 1).

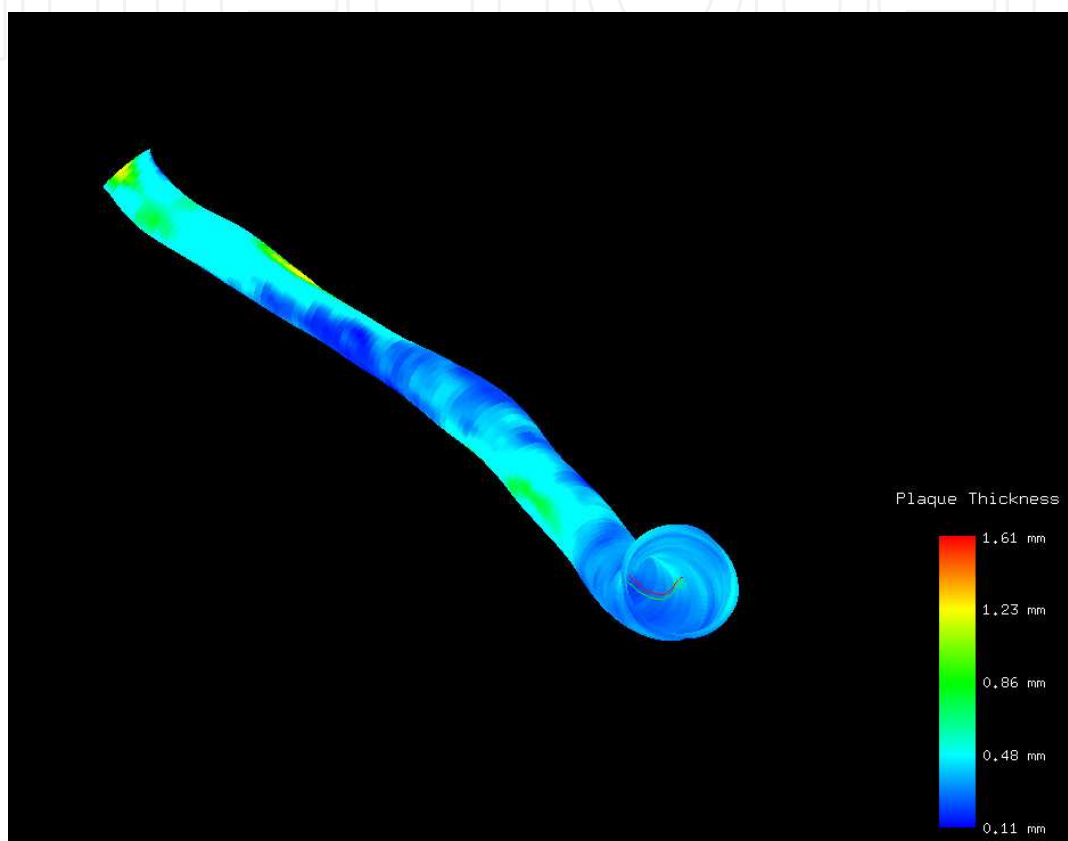


Fig. 1. Plaque thickness assessment with local plaque thickness indicated by color coding on the lumen surface.

In general, vessel curvature and torsion are derived from biplane (or a pair of single-plane) X-ray angiograms, and the cross-sectional information is obtained from IVUS. Thus, the resulting model accurately reflects the spatial geometry of the vessel and includes any accumulated plaque. Fusion leads to a 3-D or 4-D model, consisting of the lumen/plaque and media/adventitia contours oriented relative to the IVUS catheter. This may result in a surface mesh, which can include any branches segmented along with the main vessel to the extent visible in the IVUS (Figure 2). After proper meshing, this model is suitable for hemodynamic analyses.

Morphologic analyses are performed following the resampling of the cross sections orthogonal to the vessel centerline, to eliminate distortions from the position of the IVUS catheter within the vessel. The quantitative results may annotate this resampled contour model, which is then used for visualization and further analysis.

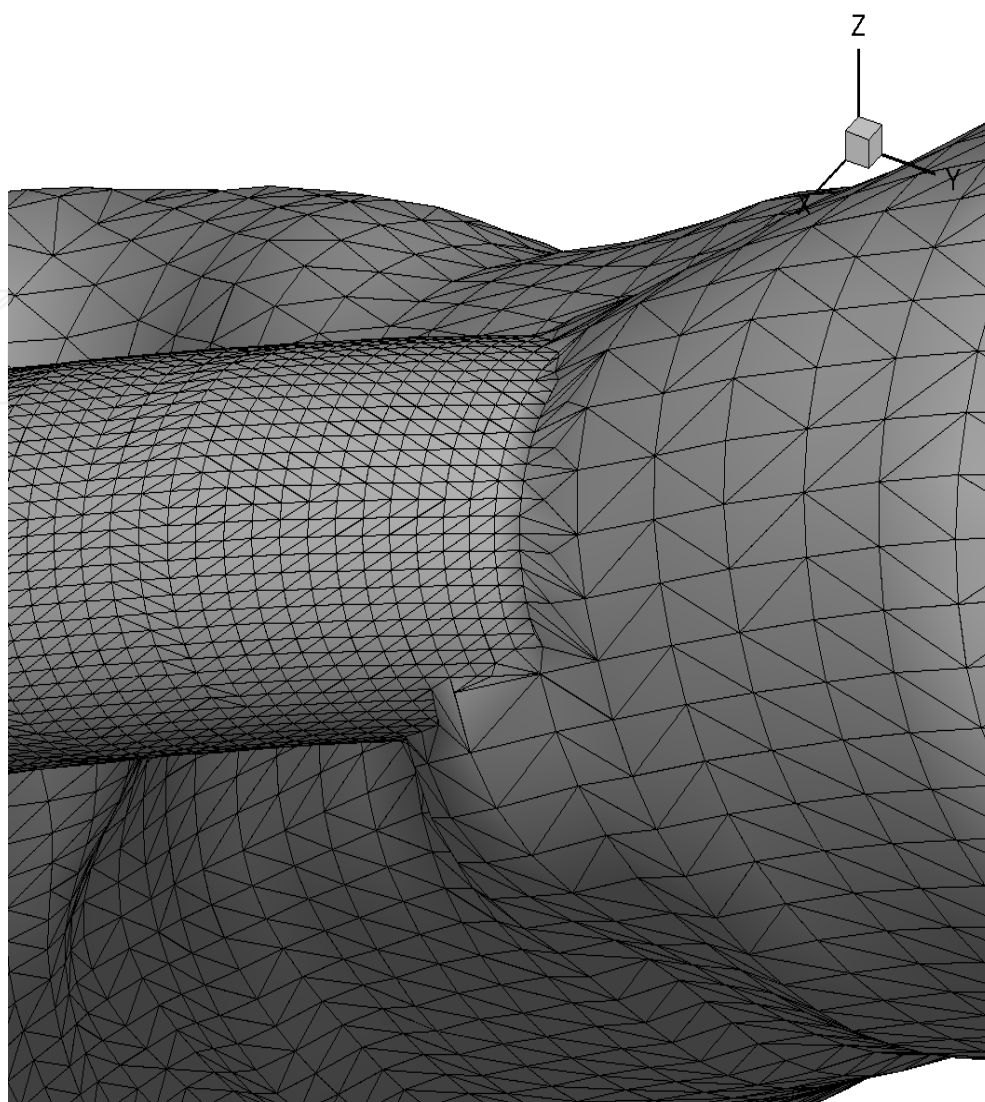


Fig. 2. Meshing of the luminal surface obtained from a geometrically-correct 3D reconstruction depicting a side branch.

The estimation of the absolute orientation of the IVUS frames in 3-D is a non-trivial issue and is usually resolved by using the angiographic lumen as a reference. The outline of the vessel lumen is visible in both angiographic projections when a small amount of contrast dye is injected. This is utilized to establish the orientation of the IVUS frames by finding their best fit with the angiographic outline. Using differential geometry, only the relative orientation changes from frame to frame can be established, the absolute orientation of the frame set yet needs to be determined at this stage. For this, a 3-D elliptical lumen outline is reconstructed from the angiograms and compared with the IVUS lumen outline, mapped into 3-D using an arbitrary initial orientation. This allows a non-iterative approach in which a single correction angle is calculated from an initial orientation and then applied to the entire frame set. The reconstructed vascular model provides 3-D locations for detected circumferential vertices (72 in our case) on both lumen/plaque and media/adventitia contours, oriented with respect to the IVUS catheter path. The blood flow through the coronary arteries is simulated and the wall shear stress distribution determined using computational fluid dynamics (CFD) methodology.

During the CFD, blood is treated as an incompressible, homogenous, and Newtonian fluid. Since the flow rate are difficult to be measured in each of the coronary arteries during data acquisition for each patient due to procedural limitations, a flow rate of 100 ml/min is sometimes assumed for all the coronary arterial segments employed in this analysis. Positive and negative wall shear stress values are determined at each circumferential lumen location and mapped onto the lumen vertices for each contour of the perpendicularly oriented 3-D model³⁵ (Figure 3).

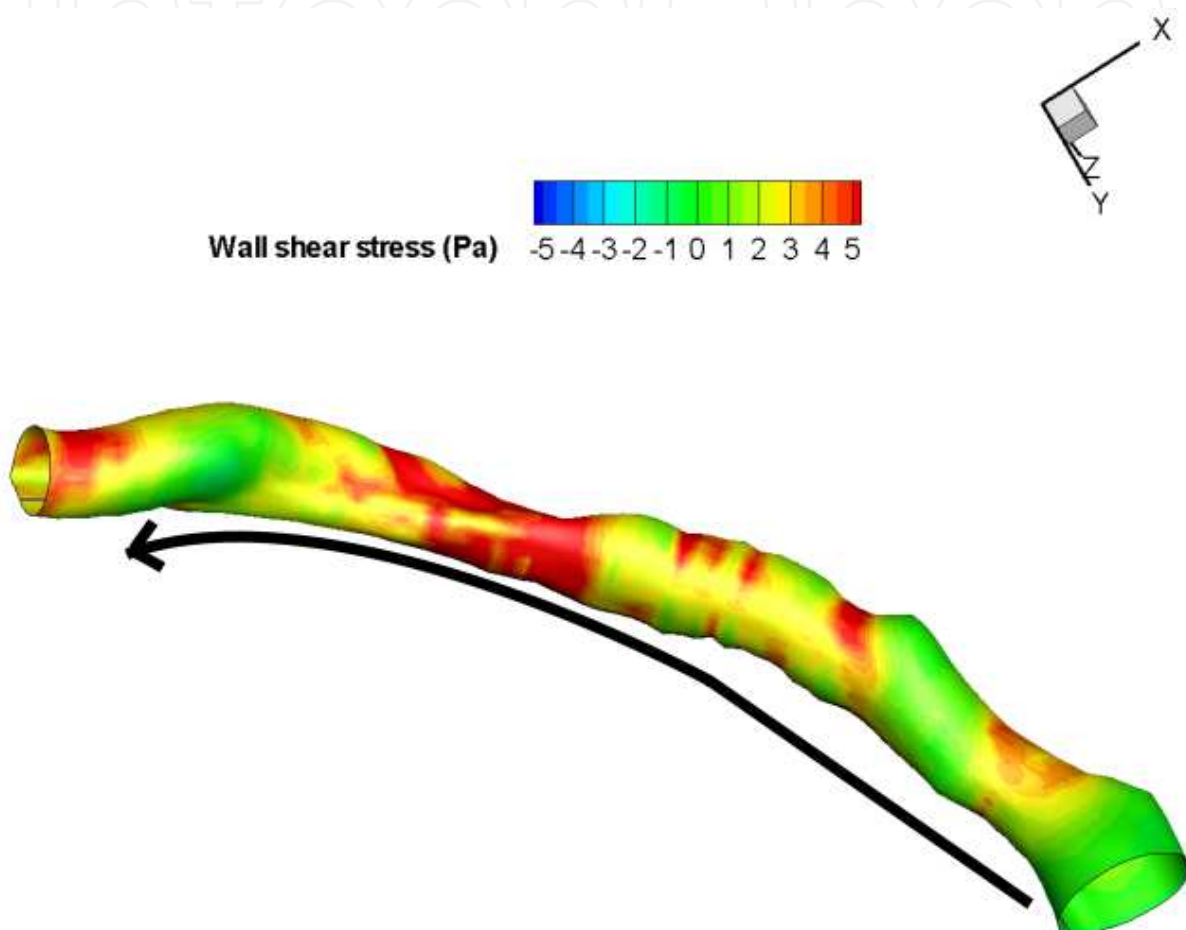


Fig. 3. Shear stress assessment on a 3-D reconstructed coronary artery (the arrow indicates the direction of blood flow).

2.6 Studies with intravascular ultrasound – Overview

Studies with intravascular ultrasound have shown that disease progression can be stopped (GAIN¹, REVERSAL²) or reversed (ASTEROID³, ESTABLISH⁴, COSMOS⁵) during lipid lowering therapy, as summarized in Table 2. The promising drug torcetrapib - inhibitor of cholesteryl ester transfer protein (CETP), which facilitates the transfer of cholesteryl ester from HDL cholesterol to LDL cholesterol and VLDL cholesterol did not decrease percent atheroma volume. Furthermore, it increased the mortality (cardiovascular and all cause mortality) in ILLUMINATE trial³⁶. The reason was increasing of blood pressure together with decreasing of potassium level (aldosterone like action). However, new CETP inhibitor without these effects is tested in preclinical trials.

| study | study design | number of patient | results | change of lipids |
|--------------------------------|---|-------------------|---|---|
| <i>Takagi</i> . ³⁷ | pravastatin 10mg vs. dietary stabilization | 25 | decrease of plaque area in pravastatin group, no volumetric analysis | LDLc: -27% vs.-9% HDLc: +29% vs. +17% |
| <i>Ishikawa</i> ³⁸ | pravastatin 10-20 mg | 40 | relative change of TAV 20% | LDLc : -23.5% HDLc : +9.3% |
| <i>GAIN</i> ¹ | atorvastatin 20-80 mg vs. standard therapy, | 131 | relative change of TAV 2.5% vs. + 11.8% | LDLc: -42% vs. -16% HDLc: +9% vs. + 12% |
| <i>REVERSAL</i> ² | 80 mg atorvastatin vs. 40 mg pravastatin | 502 | TAV: - 0.4mm ³ vs. + 5.1mm ³ , relative change of TAV: + 4.1 vs. + 5.4% PAV: + 0.6% vs. + 1.9% | LDLc: -46.3% vs. -25.2 HDLc: +2.9 vs. +5.6% |
| <i>ASTEROID</i> ³ | rosuvastatin 40 mg | 349 | PAV: -0.98%, TAV in worst 10 mm segment: -6.1mm ³ , 9.1% relative changes and - 14.7mm ³ of normalized TAV | LDLc: -53.2% HDLc: +14.7% |
| <i>COSMOS</i> ⁵ | rosuvastatin 2.5-20mg | 126 | relative change of TAV: -5.1% | LDLc: -38.6% HDLc: +19.8% |
| <i>ESTABLISH</i> ^{4*} | atorvastatin vs. dietary treatment or cholesterol absorption inhibitors | 70 | TAV: - 8.3mm ³ vs. + 4.2mm ³ relative changes of TAV -13.1% vs. + 8.7 | LDLc: -43.8% vs. -3.6% HDLc: +2.4% vs. +7.0% |
| <i>JAPAN-ACS</i> ³⁹ | pitavastatin 4gm vs. atorvastatin 20mg | 252 | TAV: - 8,2mm ³ and - 10,6 mm ³ PAV: -5,7% vs. - 6,3% patients with CAD and polyvascular extent of atherosclerosis had smaller regression compared to patients with CAD only ⁴⁰ | LDLc -36.2% vs.- 35.8% HDLc +9.9% vs.+8% |
| <i>Jensen</i> ⁴¹ | simvastatin 40mg | 40 | TAV or PAV are not available, authors found plaque regression | LDLc: -13,6% HDLc: +7% |

| study | study design | number of patient | results | change of lipids |
|---------------------------------|---|-------------------|---|--|
| <i>Nissen</i> ⁴² ▽ | recombinant ApoA-I Milano vs. placebo | 57 | PAV -1.1% vs + 0,14% | not available |
| <i>REACH</i> ⁴³ | atorvatatin 10-20mg vs. usual care | 58 | TAV -1,4 mm ³ vs. +7,6 mm ³ PAV - 1,95 % vs. +1,6% | LDLc: -34% vs. 0% HDLc: -1% vs +1% |
| <i>ILLUSTRATE</i> ⁴⁴ | torcetrapib♣+ atorvastatin vs-. atorvastatin | 910 | normalized TAV - 9.4 vs- - 6.3mm ³ , p=0.02 PAV + 0.12% vs. + 0.19%, p=0.72 | LDLc: -13.3% vs. +6.6% HDLc: +58.6% vs. +2.2% |
| <i>ACTIVATE</i> ³² | pactimibe* vs. placebo | ??? | normalized TAV: -1.3 mm ³ vs. - 5.6 mm ³ PAV: +0.8% vs. +0.6% | not available |
| <i>Nakayama</i> ⁴⁵ | pioglitazon 15mg vs. standard therapy in diabetic patients | 26 | TAV - 6.7 vs. 2.3 mm ³ | not available |
| <i>HEAVEN</i> ⁴⁶ | atorvastatin+ezetrol vs. standard care | 89 | PAV - 0.4% vs. + 1.4%, p=0.01 | LDLc: -28.6% vs. - 1.9% HDLc: +4,5% vs. -1.3% |
| <i>Clementi</i> ⁴⁷ | Atorvastatin 80mg + 30mg pioglitazone for 6 month, no control group | 25 | TAV -12.7 | not available |
| <i>Nasu</i> ⁴⁸ | Fluvastatin vs. control according to LDLc | 80 | TAV - 36.4 vs. + 11.2 mm ³ , p<0.0001 | LDL -47.7% vs. -1.1 HDL +2.2% vs. - 0.6% |

* patiens with ACS, ▽ 2 weeks after ACS with repeated IVUS after two weeks, ♣ torcetrapib is an inhibitor for cholesteryl ester transfer protein , its development was stopped due to severe side effects (increase of blood pressure), * ACAT inhibitor (acyl-coenzyme A:cholesterol acyltransferase, which esterifies cholesterol in a variety of cells and tissues, CAD coronary artery disease

Table 2. IVUS controlled progression / regression studies

The changes of plaque volume were also examined in trials focusing on plaque composition. Decrease of plaque volume was found in HEAVEN⁴⁶ (percent atheroma volume), IBIS 2⁴⁹ (total atheroma volume) and studies done by Clementi⁴⁷ (total atheroma volume) and Nasu⁴⁷ Only non-significant changes of plaque volume were found in studies done by Kawasaki⁵⁰, Hong⁵¹.
The changes of plaques composition during lipid-lowering therapy are not clear, because aforesaid studies found different results. Decrease of fibrous (F) tissue and fibro-fatty (FF)

tissue and increase of necrotic core (NC) and calcification (DC) were found in HEAVEN and in IBIS 2 (non-darapladib arm) studies. Nasu found decrease of NC and FF and increase of F and DC tissues, Kawasaki published decrease of lipid and fibrous tissues, Clementi found increase of NC and Hong increase of F and FF and decrease of NC and DC.

However, there are a lot of substantial differences among these studies. They are comparing patients with or without lipid-lowering pretreatment, analyzing the whole examined segment or only the worst part of vessel and they are using different techniques for plaque composition assessment: VH-IVUS (Volcano Therapeutics), iMAP-IVUS (Boston Scientific), Integrated Backscatter IVUS and automated differential echogenicity⁵².

2.7 Regresion of atherosclerosis as a surrogate study endpoint

Every new drug or new therapeutic approach must demonstrate a significant clinical benefit in terms of a reduction in cardiovascular morbidity and mortality. Due to the high standard of care in modern era, it becomes more and more difficult to find significant differences between new and previous treatments. The assessment of plaque volume changes can be used as an alternative end point instead of “hard” clinical endpoints, because both angiographic⁵³ and IVUS assessed plaque progression^{54,55} correlate with coronary events. This strategy enables to decrease a number of patients and duration of study⁵⁶.

3. Conclusion

Studies with intravascular ultrasound confirmed the existence of atherosclerosis regression. This process can be started by high dose of lipid lowering drugs in combination with changing the life style, more recently also with ACAT inhibitors. To date, changes of plaque composition during development and regression of atherosclerosis have not been precisely described, and conflicting results continue being published in the literature.

Recent regression/progression studies performed with intravascular ultrasound have a well-defined methodology, which must be fully respected to obtain reliable and comparable results. In addition to plain 2D IVUS studies, more comprehensive studies can be performed with high-tech vessel analysis in terms of 3D/4D reconstruction with a full-range of descriptions of the observed atherosclerotic processes including volume measurements, assessments of plaque composition and computing functional aspects such as the luminal shear stress. This concept allows a more complex assessment of atherosclerosis development and can reveal additional relationships among the morphologic and functional factors.

4. References

- [1] Scharf M, Bocksch W, Koschik D, et al. Use of Intravascular Ultrasound to Compare Effects of Different Strategies of Lipid-Lowering Therapy on Plaque Volume and Composition in Patients With Coronary Artery Disease. *Circulation* 2001;104:387-392
- [2] Nissen S, Tuzescu M, Schoenhagen P, et al. Effect of Intensive Compared With Moderate Lipid-Lowering Therapy on Progression of Coronary Atherosclerosis. *JAMA* 2004;291:1071-1080
- [3] Nissen SE, Nicholls SJ, Sipahi I, Libby P, Raichlen JS, Ballantyne CM. Effect of very high-intensity statin therapy on regression of coronary atherosclerosis: The ASTEROID trial. *JAMA* 2006;295:1556-1565

- [4] Okazaki S, Yokoyama T, Miyauchi K, Shimada K, Kurata T, Sato H. Early statin treatment in patients with acute coronary syndrome: Demonstration of beneficial effect on atherosclerotic lesion by serial volumetric intravascular ultrasound analysis during half a year after coronary event: The ESTABLISH study. *Circulation* 2004;110:1061-1068
- [5] Takayama T, Hiro T, Yamahishi M, Daida H, Hirayama H, Saito S, Yamaguchi T, Matsuzaki M, for the COSMOS Investigators. Effect of rosuvastatin on coronary atheroma in stable coronary artery disease. Multicenter coronary atherosclerosis study measuring effects of rosuvastatin using of intravascular ultrasound in Japanese subjects COSMOS. *Circ J*;2009;73:2110-2117
- [6] Nair A, Klingensmith JD, Vince DG. Real-time plaque characterization and visualization with spectral analysis of intravascular ultrasound data. *Stud Health Technol Inform.* 2005;113:300-20
- [7] Stary HC. The Histological Classification of Atherosclerotic lesions in Human Coronary Arteries. In: V.Fuster, R.Ross and E.J. Topol. *Atherosclerosis and Coronary Disease. Lippincott-Raven Publishers, Philadelphia* 1996: 272-28
- [8] Stary HC, Chandler AB, Dinsmore RE et al. A definition of advanced types of atherosclerotic lesions and histological classification of atherosclerosis: a report from the Committee on Vascular Lesions of the Council of Arteriosclerosis, American Heart Association. *Circulation* 1995;92: 1355-1374
- [9] Glagov S, Weisenberg E, Zarins C, et al. Compensatory enlargement of human atherosclerotic coronary arteries. *N Engl J Med* 1987;316:1371-1375
- [10] Libby P. The molecular base of the acute coronary syndromes. *Circulation* 1995;91:2844-2850
- [11] Virmani R, Narula J, Leon MB, Willerson JT. *The Vulnerable atherosclerotic plaque. Strategies for diagnosis and management.* Blackwell Publishing 2007.
- [12] Burke AP, Farb A, Malcom GT, et al. Coronary risk factors and plaque morphology in men with coronary disease who died suddenly. *N Engl J Med* 1997;336:1276-1282
- [13] Chatzizisis YS, Coskun AU, Jonas M, Edelman ER, Feldman CL, Stone PH. Role of endothelial shear stress in the natural history of coronary atherosclerosis and vascular remodeling. *JACC* 2007;49:2379
- [14] Stone PH, Coskun AU, Kinlay S, Clark M, Sonka M, Wahle A, Illegbusi O, Yeghiazarians Y, Popma J, Orav J, Kuntz R, Feldman CL. Effect of endothelial shear stress on the progression of coronary artery disease, vascular remodeling, and in-stent restenosis in humans: in vivo 6-month follow-up study. *Circulation* 2003;108:438-444
- [15] Wentzel JJ, Corti R, Fayad ZA et al. Does shear stress modulate both plaque progression and regression in the thoracic aorta? Human study using serial magnetic resonance imaging. *J Am Coll Cardiol* 2005;45:846-854
- [16] Chatzizisis YS, Jonas M, Coskun AU, et al. Low endothelial shear stress (ESS) is responsible for the heterogeneity and severity of coronary atherosclerotic plaques: an in-vivo IVUS natural history study (abstr). *Circulation* 2006;114:II23
- [17] Coskun U, Voskuj A, Yeghiazarians Y, Inlay S, Clark M, Illegbusi O, Wahle A, Sonka M, Popma J, Kuntz R, Feldman CL, Stone PH. Reproducibility of Coronary Lumen, Plaque, and Vessel Wall Reconstruction and of Endothelial Shear Stress Measurements In Vivo in Humans. *Cathet and Cardiovasc Interv* 2003; 60:67-78

- [18] Stone PH, Coskun AU, Kinlay S, Popma J, Sonka M, Wahle A, Yeghiazarians Y, Maynard Ch, Kuntz R, Feldman Ch. Regions of low endothelial shear stress are the sites where coronary plaque progress and vascular remodeling occurs in humans: an in vivo serial study. *Eur. Heart J.* 2007;28:705-710
- [19] Wahle A, Lopez JJ, Olszewski ME, Vigmostad SC, Chandran KB, Rossen JD, Sonka M. Plaque Development, Vessel Curvature, and Wall Shear Stress in Coronary Arteries assessed by X-ray Angiography and Intravascular Ultrasound. *Medical Image Analysis* 2006;10:615-631
- [20] Cheng C, Tempel D, van Haperen R, et al. Atherosclerotic lesion size and vulnerability are determined by patterns of fluid shear stress. *Circulation* 2006;113:2744-2753
- [21] Helderma F, Segers D, de Crom R, Hierck BP, Poelmann RE, Evans PC, Krams R. Effect of shear stress on vascular inflammation and plaque development. *Curr Opin Lipidol.* 2007;18:527-33
- [22] Resnicks N, Yahav H, Shay-Salit A, et al. Fluid shear stress and the vascular endothelium: for better and for worse. *Prog Biophys Mol Biol* 2003;81:177-199
- [23] Stary HC. Macrophages, macrophage foam cells, and eccentric intimal thickening in the coronary arteries of young children. *Atherosclerosis* 1987;64:91-108
- [24] Teo K, Burton J, Buller Ch, et al. Long term Effects of Cholesterol Lowering and Angiotensin-Converting Enzyme Inhibition on Coronary Atherosclerosis. The simvastatin/Enalapril Coronary Atherosclerosis Trial (SCAT). *Circulation* 2000;102:1748-1754
- [25] MASS investigators. Effect of simvastatin on coronary atheroma: the Multicentre Anti-Atheroma Study (MASS). *Lancet* 1994;344:633-638
- [26] Waters D, Higginson L, Gladstone P, et al. Effects of cholesterol lowering on the progression of coronary atherosclerosis in women. A Canadian Coronary Atherosclerosis Intervention Trial (CCAIT) substudy. *Circulation* 1995;92:2404-10
- [27] Jukema W, Bruschke A, van Boven A, et al. Effects of Lipid Lowering by Pravastatin on Progression and Regression of Coronary Artery Disease in Symptomatic Men With Normal to Moderately Elevated Serum Cholesterol Levels. The Regression Growth Evaluation Statin Study (REGRESS). *Circulation* 1995;91:2528-2540
- [28] Pitt B, Mancini J, Ellis S, et al. Pravastatin Limitation of Atherosclerosis in the Coronary Arteries (PLAC I): Reduction in Atherosclerosis Progression and Clinical Events. *J Am Coll Cardiol* 1995;26:1133-1139
- [29] Herd JA, Ballantyne CM, Farmer JA, et al. Effects of fluvastatin on coronary atherosclerosis in patients with mild to moderate cholesterol elevations (Lipoprotein and Coronary Atherosclerosis Study [LCAS]). *Am J Cardiol* 1997;80:278-286
- [30] Mintz GS, Garcia-Gracia HM, Nicholls SJ, Weissman NJ, Bruining N, Crowe T, Tardif JC, Serruys PW. Clinical expert consensus document on standards for acquisition, measurement and reporting of intravascular ultrasound regression/progression studies. *Eurointervention* 2011;6:1123-1130
- [31] Nissen SE, Tuzcu EM, Brewer HB, et al. Effect of ACAT inhibition on the progression of coronary atherosclerosis. *N Engl J Med.* 2006;354:1253-1263
- [32] Gogas BD, Farooq V, Serruys PW, Garcia-Garcia HM. Assessment of coronary atherosclerosis by IVUS and IVUS-based imaging modalities: progression and

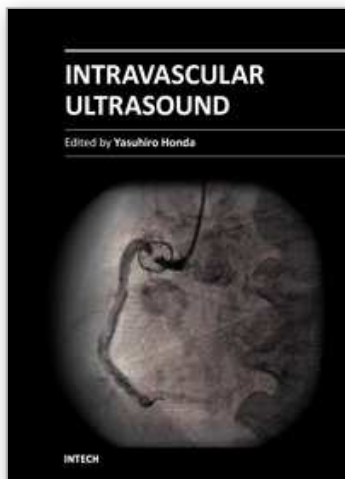
- regression studies, tissue composition and beyond. *Int J Cardiovasc Imaging* 2011;27:225-237
- [33] Wahle, A., Prause, GPM, DeJong, SC, Sonka, M. Geometrically correct 3-D reconstruction of intravascular ultrasound images by fusion with biplane angiography - methods and validation. *IEEE Transactions on Medical Imaging* 1999;18:686-699
- [34] Wahle A, Lopez J, Olszewski M, Vigmostad S, Chandran K, Rossen J, Sonka M. Plaque development, vessel curvature, and wall shear stress in coronary arteries assessed by X-ray angiography and intravascular ultrasound. *Medical Image Analysis* 2006;10: 615-631
- [35] Barter PJ, Caulfield M, Eriksson M, Grundy SM, Kastelein JJ, Komajda M, Lopez-Sendon J, Mosca L, Tardif JC, Waters DD, Shear CL, Revkin JH, Buhr KA, Fisher MR, Tall AR, Brewer B; ILLUMINATE Investigators. Effects of torcetrapib in patients at high risk for coronary events. *NEJM* 2007;357:2109-2022
- [36] Takagi T, Yoshida K, Akasaka T, et al. Intravascular Ultrasound Analysis of Reduction in Progression of Coronary Narrowing by Treatment With Pravastatin. *Am J Cardiol* 1997;79:1673-1676.
- [37] Ishikawa K, Tani S, Watanabe I, Matsumoto M, Furukawa K, Nomoto K, Nomoto K, Kushihiro T, Nagao K, Kanmatsuse K. Effect of Pravastatin on Coronary Plaque Volume. *Am J Cardiol* 2003;92:975-977
- [38] Hiro T, Kimura T, Morimoto T, Miyauchi K, Nakagawa Y, Yamagishi M, Ozaki Y, Kimura K, Saito S, Yamaguchi T, Daida H, Matsuzaki M, for the JAPAN-ACS Investigators. Effect of Intensive Statin Therapy on Regression of Coronary Atherosclerosis in Patients With Acute Coronary Syndrome. *J Am Coll Cardiol* 2009;54:293-302
- [39] Hibi K, Kimura T, Kimura K, Morimoto T, Hiro T, Miyauchi K, Nakagawa Y, Yamagishi M, Ozaki Y, Saito S, Yamaguchi T, Daida H, Matsuyaki M; for the JAPAN-ACS Investigators. Clinically evident polyvascular disease and regression of coronary atherosclerosis after intensive statin therapy in patients with acute coronary syndrome: Serial intravascular ultrasound from the Japanese assessment of pitavastatin and atorvastatin in acute coronary syndrome (JAPAN-ACS) trial. *Atherosclerosis* 2011 ahead of print
- [40] Jensen L, MD, Thayssen P, Pedersen K, Stender S, Haghfelt T. Regression of Coronary Atherosclerosis by Simvastatin A Serial Intravascular Ultrasound Study. *Circulation* 2004;110:265-270
- [41] Nissen S, Tsunoda T, Tuzcu M, Schoenhagen P, Cooper Ch, Yasin M, Eaton G, Lauer M, Sheldon S, Grines C, Halpern S, Crowe T, Blankenship J, Kerensky R. Effect of recombinant ApoA-I Milano on coronary atherosclerosis in patients with acute coronary syndromes. A randomized controlled trial. *JAMA* 2003;290:2292-2300
- [42] Yamada T, Azuma A, Sasaki S, Sawada T, Matsubara H, on behalf of REACH study group. Randomized evaluation of atorvastatin in patients with coronary heart disease. A serial intravascular ultrasound study. *Circ J* 2007;71:1845-1850
- [43] Nissen S, Tardif JD, Nicholls S, Revkin J, Shear Ch, Duggan W, Ruzyllo W, Bachinsky W, Lasala G, Tuzcu M, for the ILLUSTRATE Investigators. Effect of Torcetrapib on the Progression of Coronary Atherosclerosis. *N Engl J Med* 2007;356:1304-16

- [44] Nakayamaa T, Komiyamab N, Yokoyamaa M, Namikawaa S, Kurodaa N, Kobayashia Y, Komuroa I. Pioglitazone induces regression of coronary atherosclerotic plaques in patients with type 2 diabetes mellitus or impaired glucose tolerance: A randomized prospective study using intravascular ultrasound. *Int J Cardiol.* 2010;138:157-65
- [45] Kovarnik T, Mintz GS, Skalicka H, Kral A, Horak J, Skulec R, Uhrova J, Martasek P, Downe RW, Wahle A, Sonka M, Mrazek V, Aschermann M, Linhart A. Virtual histology evaluation of atherosclerosis regression during atorvastatin and ezetimibe administration - HEAVEN study. *Circulation Journal* 2011; ahead of print
- [46] Clementi F, Luoizzo M, Mango R, Luciani G, Trivisonno A, Pizzuto F, Martuscelli E, Mehta JL, Romeo F. Regression and shift in composition of coronary atherosclerosis plaques by pioglitazone: insight from an intravascular ultrasound analysis. *J Cardiovasc Med* 2009;10:231-237
- [47] Nasu K, Tsuchikane E, Katoh O, Tanaka N, Kimura M, Ehara M, Kinoshita Y, Matsubara Matsuo T, Asakura K, Asakura Y, Terashima M, Takayama T, Honye J, Hirayama A, Saito S, Suzuki T. Effect of Fluvastatin on Progression of Coronary Atherosclerotic Plaque Evaluated by Virtual Histology Intravascular Ultrasound. *JACC Cradiovasc Interv.* 2009;2:689-969
- [48] Serruys PW, García-García HM, Buszman P, Erne P, Verheye S, Aschermann M, Duckers H, Bleie O, Dudek D, Bøtker HE, von Birgelen C, Don D'Amico, MA, Hutchinson T, Zambanini A, Mastik F, van Es GA, van der Steen A, Vince G, Ganz, Hamm ChW, Wijns W, Zalewski A, for the Integrated Biomarker and Imaging Study-2 Investigators. Effects of the Direct Lipoprotein-Associated Phospholipase A2 Inhibitor Darapladib on Human Coronary Atherosclerotic Plaque. *Circulation* 2008;118:1172-1182
- [49] Kawasaki M, Sano K, Okubo M, Yokoyama H, Ito Y, Murata I, Tsuchiya K, Minatoguchi S, Zhou X, Fujita H, Fujiwara H. Volumetric Quantitative Analysis of Tissue Characteristics of Coronary Plaques After Statin Therapy Using Three-Dimensional Integrated Backscatter Intravascular Ultrasound. *J Am Coll Cardiol* 2005;45: 1946-53
- [50] Hong MK, Park DW, Lee ChW, Lee SW, Kim YH, Kang DH, et al. Effect of statin treatment on coronary plaques assessed by volumetric virtual histology intravascular ultrasound analysis. *J Am Coll Intv* 2009;2:679-688
- [51] Garcia-Garcia HM, Gogas BD, Serruys PW, Bruining N. IVUS-based imaging modalities for tissue characterization: similarities and differences. *Int J Cardiovasc Imaging* 2011;27:215-224
- [52] Azen SP, Mack WJ, Cashin-Hemphill L et al. Progression of coronary artery disease predicts clinical coronary events. Long-term follow-up from the Cholesterol Lowering Atherosclerosis Study. *Circulation* 1996;93:34-41
- [53] von Birgelen C, Hartmann M, Mintz GS et al. Relationship between cardiovascular risk as predicted by established risk scores versus plaque progression as measured by serial intravascular ultrasound in left main coronary arteries. *Circulation* 2004;110:1579-1585

- [54] Ricciardi MJ, Meyers S, Choi K, Pang JL, Goodreau L, Davidson CJ. Angiographically silent left main disease detected by intravascular ultrasound: a marker for future adverse cardiac events. *Am Heart J* 2003;146:507-12
- [55] Bose D, von Birgelen C, Erbel R. Intravascular ultrasound for the evaluation of therapies targeting coronary atherosclerosis. *J Am Coll Cardiol* 2007;49:925-932

IntechOpen

IntechOpen



Intravascular Ultrasound

Edited by Dr. Yasuhiro Honda

ISBN 978-953-307-900-4

Hard cover, 207 pages

Publisher InTech

Published online 01, February, 2012

Published in print edition February, 2012

Intravascular ultrasound (IVUS) is a cardiovascular imaging technology using a specially designed catheter with a miniaturized ultrasound probe for the assessment of vascular anatomy with detailed visualization of arterial layers. Over the past two decades, this technology has developed into an indispensable tool for research and clinical practice in cardiovascular medicine, offering the opportunity to gather diagnostic information about the process of atherosclerosis in vivo, and to directly observe the effects of various interventions on the plaque and arterial wall. This book aims to give a comprehensive overview of this rapidly evolving technique from basic principles and instrumentation to research and clinical applications with future perspectives.

How to reference

In order to correctly reference this scholarly work, feel free to copy and paste the following:

T. Kovarnik, A. Wahle, R.W. Downe and M. Sonka (2012). IVUS Role in Studies Assessing Atherosclerosis Development, Intravascular Ultrasound, Dr. Yasuhiro Honda (Ed.), ISBN: 978-953-307-900-4, InTech, Available from: <http://www.intechopen.com/books/intravascular-ultrasound/ivus-role-in-studies-assessing-atherosclerosis-development>

INTECH
open science | open minds

InTech Europe

University Campus STeP Ri
Slavka Krautzeka 83/A
51000 Rijeka, Croatia
Phone: +385 (51) 770 447
Fax: +385 (51) 686 166
www.intechopen.com

InTech China

Unit 405, Office Block, Hotel Equatorial Shanghai
No.65, Yan An Road (West), Shanghai, 200040, China
中国上海市延安西路65号上海国际贵都大饭店办公楼405单元
Phone: +86-21-62489820
Fax: +86-21-62489821

© 2012 The Author(s). Licensee IntechOpen. This is an open access article distributed under the terms of the [Creative Commons Attribution 3.0 License](https://creativecommons.org/licenses/by/3.0/), which permits unrestricted use, distribution, and reproduction in any medium, provided the original work is properly cited.

IntechOpen

IntechOpen