

# We are IntechOpen, the world's leading publisher of Open Access books Built by scientists, for scientists

6,900

Open access books available

185,000

International authors and editors

200M

Downloads

Our authors are among the

154

Countries delivered to

TOP 1%

most cited scientists

12.2%

Contributors from top 500 universities



WEB OF SCIENCE™

Selection of our books indexed in the Book Citation Index  
in Web of Science™ Core Collection (BKCI)

Interested in publishing with us?  
Contact [book.department@intechopen.com](mailto:book.department@intechopen.com)

Numbers displayed above are based on latest data collected.  
For more information visit [www.intechopen.com](http://www.intechopen.com)



## Surface Replacement of Hip Joint

Hiran Amarasekera and Damian Griffin

<sup>1</sup>Orthopaedic Research Fellow/PhD Student, Warwick Orthopaedics  
University of Warwick Medical School

<sup>2</sup>Professor of Trauma and Orthopaedics, Warwick Orthopaedics  
University of Warwick Medical School  
United Kingdom

### 1. Introduction

Surface hip replacement more commonly known as hip resurfacing arthroplasty is a type of a hip replacement that is different to a total hip replacement. In a total hip replacement femoral head and neck are removed and a metal stem is inserted to the femoral shaft. In hip resurfacing articular surface is shaved and a metal cap (Fig 1) is inserted preserving most of the bone in femoral head and neck.

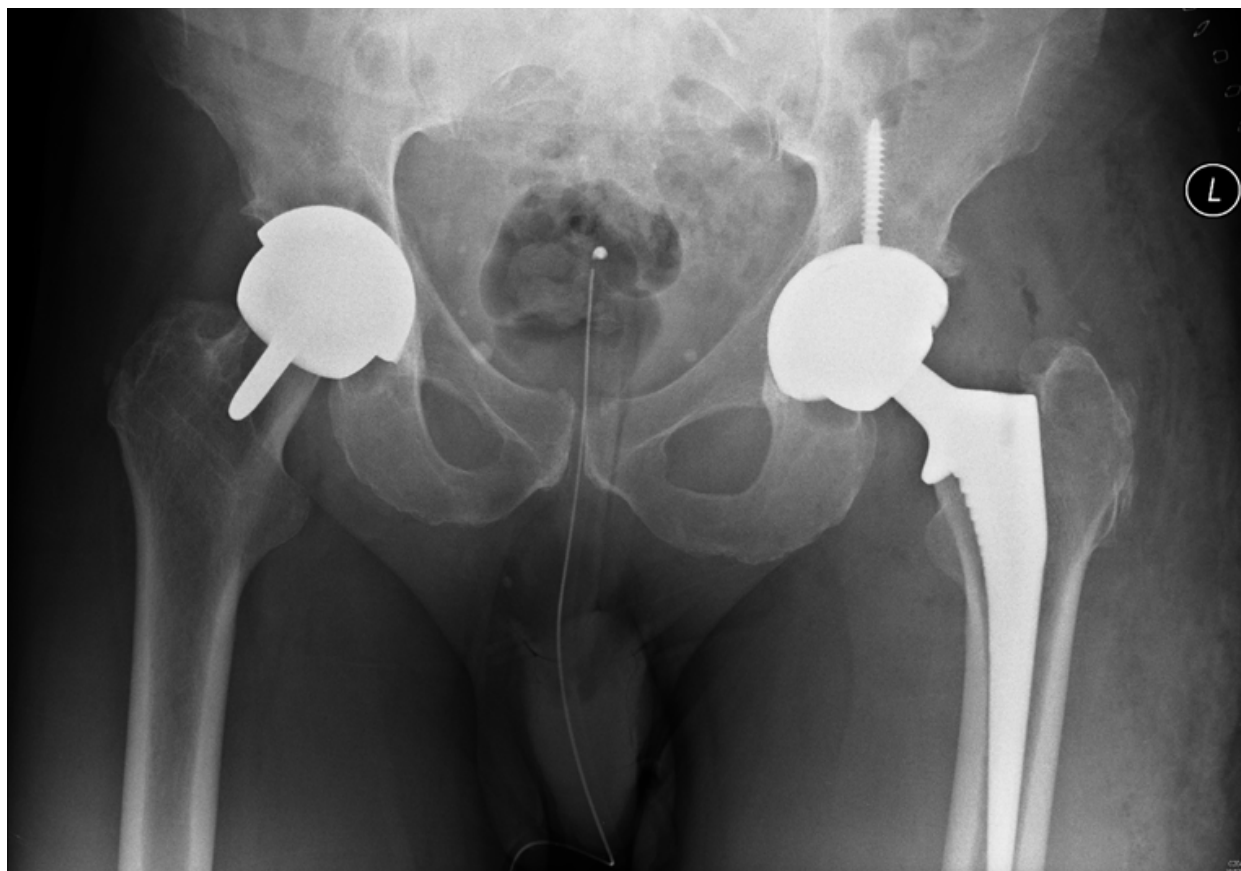


Fig. 1. X Ray shows a Hip Resurfacing arthroplasty (Right) and a Total Hip Replacement (Left)

Compared to the total hip replacement resurfacing arthroplasty preserves more bone on the femoral side (Fig.1). Acetabular replacement is similar to both procedures. Main advantages of surface replacement include preservation of femoral bone stock; increase degree of motion, and easier conversion to a total hip replacement during revision. All these make resurfacing arthroplasty an attractive alternative to a total hip replacement especially in the young active adults.

## 2. History

Professor Sir John initially introduced hip resurfacing early in 1950s. (Charnley 1960; McMinn and Daniel 2006) The initial designs were uncemented PTFE (polytetrafluoroethylene) on metal. All early implants had an acetabular component made of softer material such as PTFE and femoral component made of metal. This combination of hard on soft surface caused many problems.

The previous designs failed due to two main reasons. Firstly combination of hard on soft surfaces and large diameter heads lead to increase wear, wear particle accumulation, osteolysis of the bone.

Secondly posterior approach used during the procedure damaged the blood supply to the femoral head. This lead to reduced femoral head vascularity, osteonecrosis, femoral neck fractures, and aseptic loosening of the implant.

Due to these problems hip resurfacings in the 50s through 80s were not a popular option to treat arthritis in the young adult. However in early 1990s McMinn *et al* (McMinn *et al*. 1996) introduced the modern hip resurfacing which used metal on metal bearings with improved instrumentation for precision placement of implants. It was believed metal on metal reduce the wear and tear of the implanted hip. Vascularity too was addressed by proposing many surgical approaches such as the trochanteric flip (Ganz *et al*. 2001) antero-lateral (Jacobs, Goytia, and Bhargava 2008) or direct-lateral (Hardinge 1982) as alternative approaches to the conventional posterior approach which is widely used in total hip replacement.

Hip resurfacings has been conducted in many centres since early 1990 as popular option in treating young active adults with hip problems. However with time long term results from the modern surface replacements has identified it's own set of complications (Shimmin, Bare, and Back 2005) such as femoral neck fractures aseptic loosening, avascular necrosis, osteolysis of head and increase metal ions levels. (Hing, Back, and Shimmin 2007)

Due to these factors the selection criteria for surface replacement has changed from a much broader set to a narrow and a limited set, over the last decade. (Nunley, Della Valle, and Barrack 2009)

At present even-though the selection criteria is narrowed it still remains a key alternative to the conventional hip replacements.

## 3. Indications for hip resurfacing

When surface replacement was re introduced in early 1990 s the ideal candidate for the procedure was a young active adult with good hip morphology and a reasonably good bone quality, with osteoarthritis of the hip. (McMinn *et al*. 2011)

With a high range of motion and a low dislocation rate surface replacement seem to be the ideal option for a young adult who could have a near normal range of motion following resurfacing arthroplasty. If the patient requires a revision to total hip replacement then this could be delayed and a second revision delayed even further. As people live longer with an increasing life expectancy rate this enables the orthopaedic surgeon to delay the first total hip replacement. (Della Valle, Nunley, and Barrack 2008; Hing, Back, and Shimmin 2007)

However with the availability of the long-term complications of hip resurfacing arthroplasty the initial interest that prevailed in early 1990s has waned over the last few years and, many surgeons have narrowed selection criteria down.

### **3.1 Selection criteria**

#### **3.1.1 Age**

55 years for women 65 years for men.(Corten et al. 2011)

#### **3.1.2 Sex**

Resurfacing is better tolerated by men than women. Pre-menopausal women have a better chance than the post menopausal women as the femoral neck fracture rate increases after menopause.(Shimmin and Back 2005) Some studies suggest that surgical technique, implant selection, and implant positioning should be modified according to the gender. If this is done there is a high possibility that gender specific bias can be eliminated, as this is a common problem in surface replacement.(Amstutz, Wisk, and Le Duff 2011; Jameson et al. 2008)

#### **3.1.3 Pathology of the hip**

Ideal candidate for a hip resurfacing is a patient with primary osteoarthritis. However most patients do not develop primary osteoarthritis at an early age. Younger patients developing osteoarthritis is mostly due to secondary causes. Surface replacement of the hip has been performed in many pathological conditions that eventually lead to secondary osteoarthritis. However conditions in which the bone may be weak such as osteoporosis, resurfacings should be avoided as this can lead to high incidence of femoral neck fractures. Avascular necrosis (AVN) is a relative contraindication for hip resurfacing. Even though some surgeons have performed hip resurfacing in AVN patients most surgeons believe that resurfacing should not be done on these patients. Partial hip resurfacing/hemi resurfacing seems to be the popular treatment option for patients with Avascular Necrosis. In partial resurfacing only the necrotic area of the articular surface is removed and replaced (Fig 2).(Siguier et al. 2001; Ushio et al. 2003) Partial resurfacing is also done for localised osteochondral defects. (Van Stralen et al. 2009)

The indications for hip resurfacing has changed during the past decade as high failure rates were observed among certain patient groups.(McMinn et al. 2011)

This has lead to a re think and development of more stringent patient selection criteria.

### **3.2 Surgical techniques**

Surgical approach to the hip is similar to the approaches done when performing a total hip replacement. However there are many additional considerations to be kept in mind when

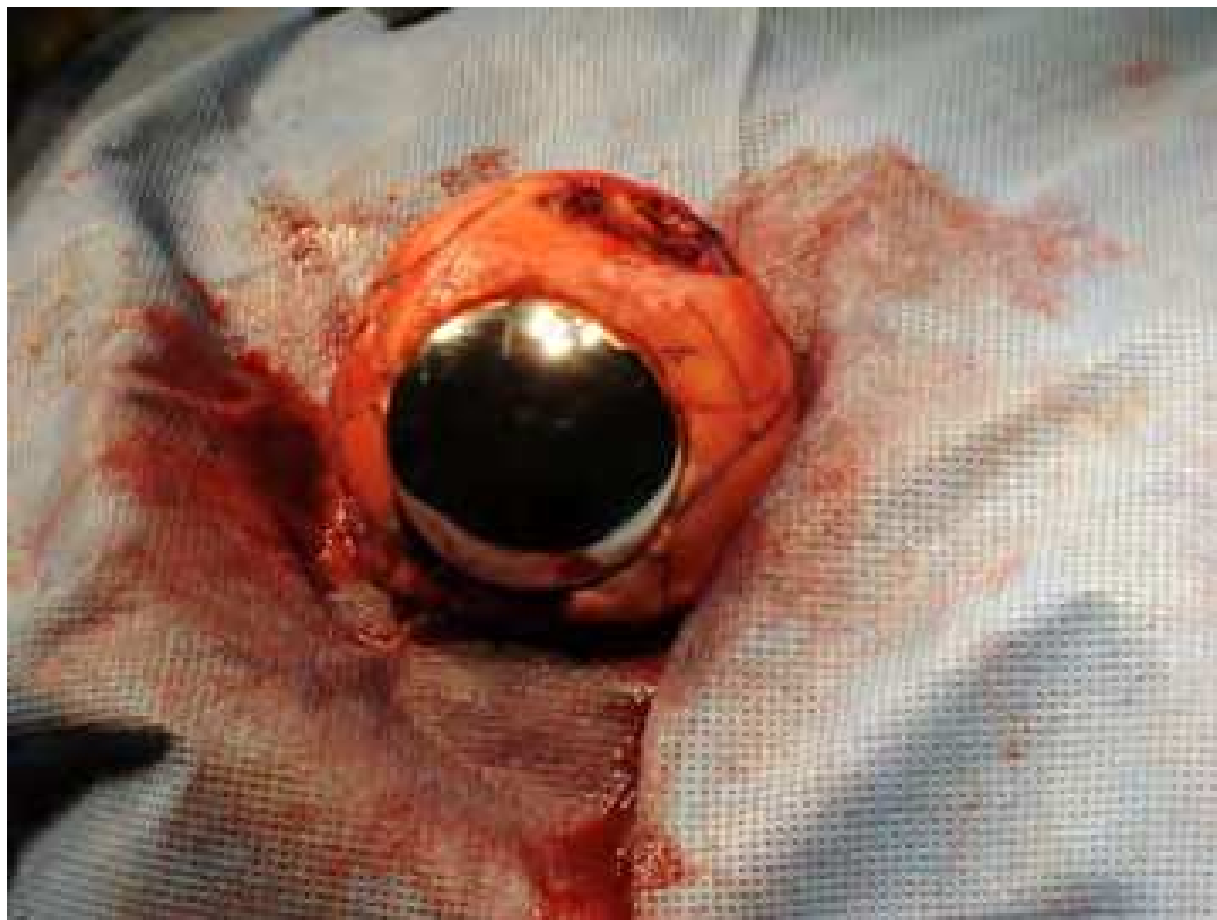

Fig. 2. Partial resurfacing done on a patient with an osteochondral defect

performing a resurfacing arthroplasty. As more bone is preserved in femoral head and the neck preserving the vascularity is a key issue. (McBryde et al. 2008) Therefore some surgeons do not use the traditional posterior approach when performing a hip resurfacing. This is because the posterior approach cuts the medial circumflex femoral artery (MCFA) main artery supplying of the femoral head and neck. This damage is believed to cause AVN of femoral head. Most studies demonstrated a fall in blood supply during posterior approach compared to other surgical approaches.(Beaule, Campbell, and Shim 2006; Bradley, Freeman, and Revell 1987; Howie, Cornish, and Vernon-Roberts 1993) However some authors including us have questioned the clinical significance of this drop as we are not clear whether the drop is transient or permanent and whether it is below the critical ischaemic level to cause the death of osteocytes in the femoral head.(Amarasekera et al. 2008)

Common alternative approach that is described to preserve blood flow was described by Ganz *et al* as the trochanteric flip approach.(Ganz et al. 2001) This is an anterior type of approach done by doing a trochanteric flip osteotomy. This approach preserves the MCFA and the main blood supply to the femoral head. Therefore it is believed in theory that the vascularity is better preserved by this approach as compared to the posterior approach. However the key disadvantage of this approach is that the patient has to be non weight bearing for four to six weeks until the trochanteric flip osteotomy heals. The other approaches describe for resurfacing include(Gerdesmeyer et al. 2008) antero lateral



approach, direct lateral approach(Hardinge 1982), and minimally invasive approaches. (McMinn et al. 2005; Mont, Ragland, and Marker 2005)

Studies have been done not only to evaluate intra-operative (Amarasekera et al. 2008) as well as post-operative blood supply (Forrest et al. 2006) following different surgical approaches in resurfacing arthroplasty patients.

Post-operative vascularity has been studied using SPECT (Single Positron Emission Computed Tomography) scanning. The attenuation factor affecting the accuracy of the results in the presence of metal implants has been addressed by performing phantom studies. (Amarasekera et al. 2011)

Once a suitable surgical approach is chosen the next steps in the surgery are fairly straightforward. The acetabular replacement is similar to a THR. However the femoral head replacement is far more a demanding task as the placement of the cup is crucial and needs accuracy. This is a technically demanding procedure compared to a placing the femoral component in a THR. Poorly positioned components will lead to high wear rates, impingement and dislocations. Due to the technically demanding nature of the procedure training surgeons is challenging and has a to slow learning curve.(Berend et al. 2011) Due to this using navigation to position implants has been tried but does not appear to have an advantage over the learning curve.(Saithna and Dekker 2009; Shields et al. 2009)

To cement or not to cement the implants is another point that has been debated over the years.

When surface replacements were re introduced most implants were cemented. Therefore cementing technique and the type of cement used, area of the component cemented, all seem to contribute to the success of surgery.(Bitsch and Schmalzried 2008; Bitsch et al. 2008) Specific cementing techniques have been described when cementing the femoral component. (Bitsch et al. 2008; Bitsch et al. 2007; Chandler et al. 2006) Achieving the correct cement mantle is a technically challenging procedure. Too much cement can cause thermal necrosis while too little cement can cause a poor penetration and femoral loosening where as an extreme thin mantle can cause mechanical failure leading to high wear particles further leading to osteolysis.(Scheerlinck, Delpont, and Kiewitt 2010)

Due to these controversies some surgeons adapt partially cementing the component avoiding the pin, (Schlegel et al. 2011) and some surgeons have totally stopped using cement. This lead to development of uncemented hip resurfacings and has become the procedure of choice among some surgeons.

#### **4. Complications of surface replacements**

It is worth mentioning that all general complications associated with hip surgery such as infection, bleeding, DVT, are seen with hip resurfacings. Apart from these there is a set of complications that is unique to this procedure. These are outlined below.

##### **4.1 Avascular necrosis of femoral head (Bradley, Freeman, and Revell 1987; Little et al. 2005)**

As described earlier avascular necrosis of the femoral head and neck is a potential complication that can result in failure of the implant. The main reason for this is the damage to blood supply that occurs during posterior approach. (Amarasekera et al. 2008)Avoiding posterior approach and adapting other approaches such as antero-lateral or trochanteric flip approaches(Ganz et al. 2001, 2001) will minimise this.

4.2 Femoral neck fractures

This is a known complication that can range between 0- up to 1.8% after hip resurfacing. (Steffen et al. 2009) Avascular necrosis (Steffen et al. 2010), mechanical factors such as notching, femoral neck lengthening, and varus mal alignment of the femoral component has been attributed as contributory causes for femoral neck fractures.. Some studies suggest females (3%) have a higher incidence than males (1.3%) (Jameson et al. 2008) while other studies do not find any difference between the sexes. (Steffen et al. 2009) Failure rate and revision rate too seem to be higher in females as compared to males. (Carrothers et al. 2010)

4.3 Aseptic loosening of components, osteolysis, pseudo tumours, and ALVAL (Aseptic Lymphocytic Vasculitis Associated Lesions), (Zustin et al. 2009)

Large head size in hip resurfacing causes increase wear and tear leading to high metal particles. Some escape to blood flow causing high metal ion levels in blood. Some trigger an immune response leading to metallosis, aseptic loosening, lymphocytic infiltration, and osteolysis and bone resorption. It is less clear whether this same reaction can be triggered by cement particles. Developing a proper cementing technique (Campbell et al. 2009) or considering uncemented implants may help to minimise these complications. However dealing with increase wear metal particles remains a challenging problem. These complications are due to series of immune reactions that occur as the body respond to large number of wear particles or cement. In early sixties these were common when metal on plastic implants were used it was a major cause for failure but with metal on metal it was thought that these would be minimal. (Zustin et al. 2010) However long term results of modern hip resurfacings suggest that the problem still exists. Recent systematic review suggests aseptic loosening to be the most common complication reported in hip resurfacing. (van der Weegen et al. 2011) (Zustin et al. 2009)

4.4 Persistent groin pain (Bin Nasser et al. 2010; Bartelt et al. 2010; Campbell et al. 2008; Nikolaou et al. 2009) and femoroacetabular impingement (Lim et al. 2011; Yoo et al. 2011)

These are mainly caused by mechanical problems such as poor positioning of implants. (Bin Nasser et al. 2010) Carrothers et al reported prevalence of complications following surface replacement of 5000 hips in a multi surgeon series involving 141 surgeons. (Carrothers et al. 2010) These are given below (Table 1)

Complication	Number of hips	Prevalence
Fracture Neck of femur	54	1.1%
Loosening -Acetabular	32	0.6%
Femoral head AVN	30	0.6%
Loosening-Femoral	19	0.4%
Infection	17	0.3%
ALVAL/Metallosis	15	0.3%
Loosening-Both	05	0.1%
Dislocation	05	0.1%
Revision rate	182	3.6%

Table 1. Complications reported by Carrothers et al

## 5. Conclusion

When resurface was first done initial complications were due to high wear between metal and plastic surface. This is because the surface area of the resurfacing femoral head is much larger than the surface area of a THR implant. This causes more frictional forces between the acetabular and femoral components producing increase wear particles. When the head was metal and the cup was plastic the wear rate was even higher and this led to initial failure of the original designs. To avoid this problem the modern implants were designed as metal on metal expecting the wear to be a less significant. Recent evidence suggests collection of metal particles within the tissues causes metallosis and leaking metal to the blood stream has caused high metal ion levels, (Clarke et al. 2003; Vendittoli et al. 2010; Vendittoli, Ganapathi, and Lavigne 2007) metal allergies, and metallosis. This has been attributed to triggering immunological reactions such as ALVAL, Pseudo tumour formations, resorption of head finally leading to loosening and implant failure.

Due to all these complications resurfacing arthroplasty has fallen out of favour as the automatic procedure of choice to treat young active patient with hip problems.

This has re opened the debate on how best to treat young active adults with hip problems. Uncemented hip replacement, minimal invasive techniques, and arthroscopic hip procedures are a few options that should be considered as an alternative to hip resurfacing in selected patients.

Nevertheless surface replacement done on a carefully selected patient by a highly trained surgeon taking in to consideration the surgical approach, cementing technique, implant selection and implant positioning will increase the success rate of the procedure.

## 6. References

- Amarasekera, H. W., M. L. Costa, P. Foguet, S. J. Krikler, U. Prakash, and D. R. Griffin. 2008. The blood flow to the femoral head/neck junction during resurfacing arthroplasty: A COMPARISON OF TWO APPROACHES USING LASER DOPPLER FLOWMETRY. *J Bone Joint Surg Br* 90 (4):442-5.
- Amarasekera, H. W., M. L. Costa, N. Parsons, J. Achten, D. R. Griffin, S. Manktelow, and N. R. Williams. 2011. SPECT/CT bone imaging after hip resurfacing arthroplasty: is it feasible to use CT attenuation correction in the presence of metal implants? *Nucl Med Commun* 32 (4):289-97.
- Amstutz, H. C., L. E. Wisk, and M. J. Le Duff. 2011. Sex as a patient selection criterion for metal-on-metal hip resurfacing arthroplasty. *J Arthroplasty* 26 (2):198-208.
- Bartelt, R. B., B. J. Yuan, R. T. Trousdale, and R. J. Sierra. 2010. The prevalence of groin pain after metal-on-metal total hip arthroplasty and total hip resurfacing. *Clin Orthop Relat Res* 468 (9):2346-56.
- Beaule, P. E., P. Campbell, and P. Shim. 2006. Femoral Head Blood Flow during Hip Resurfacing. *Clin Orthop Relat Res*.
- Berend, K. R., A. V. Lombardi, Jr., J. B. Adams, and M. A. Sneller. 2011. Unsatisfactory surgical learning curve with hip resurfacing. *J Bone Joint Surg Am* 93 Suppl 2:89-92.
- Bin Nasser, A., P. E. Beaule, M. O'Neill, P. R. Kim, and A. Fazekas. 2010. Incidence of groin pain after metal-on-metal hip resurfacing. *Clin Orthop Relat Res* 468 (2):392-9.
- Bitsch, R. G., C. Heisel, M. Silva, and T. P. Schmalzried. 2007. Femoral cementing technique for hip resurfacing arthroplasty. *J Orthop Res* 25 (4):423-31.

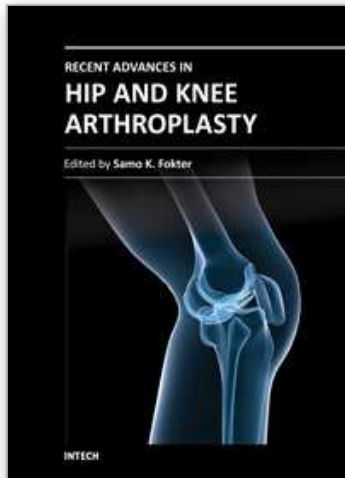


- Bitsch, R. G., T. Loidolt, C. Heisel, and T. P. Schmalzried. 2008. Cementing techniques for hip resurfacing arthroplasty: development of a laboratory model. *J Bone Joint Surg Am* 90 Suppl 3:102-10.
- Bitsch, R. G., and T. P. Schmalzried. 2008. [Cementing techniques for hip resurfacing arthroplasty. What do we know?]. *Orthopade* 37 (7):667-71.
- Bradley, G. W., M. A. Freeman, and P. A. Revell. 1987. Resurfacing arthroplasty. Femoral head viability. *Clin Orthop Relat Res* (220):137-41.
- Campbell, P., A. Shimmin, L. Walter, and M. Solomon. 2008. Metal sensitivity as a cause of groin pain in metal-on-metal hip resurfacing. *J Arthroplasty* 23 (7):1080-5.
- Campbell, P., K. Takamura, W. Lundergan, C. Esposito, and H. C. Amstutz. 2009. Cement technique changes improved hip resurfacing longevity - implant retrieval findings. *Bull NYU Hosp Jt Dis* 67 (2):146-53.
- Carrothers, A. D., R. E. Gilbert, A. Jaiswal, and J. B. Richardson. 2010. Birmingham hip resurfacing: the prevalence of failure. *J Bone Joint Surg Br* 92 (10):1344-50.
- Chandler, M., R. S. Kowalski, N. D. Watkins, A. Briscoe, and A. M. New. 2006. Cementing techniques in hip resurfacing. *Proc Inst Mech Eng H* 220 (2):321-31.
- Charnley, J. 1960. Surgery of the hip-joint: present and future developments. *Br Med J* 1 (5176):821-6.
- Clarke, M. T., P. T. Lee, A. Arora, and R. N. Villar. 2003. Levels of metal ions after small- and large-diameter metal-on-metal hip arthroplasty. *J Bone Joint Surg Br* 85 (6):913-7.
- Corten, K., R. Ganz, J. P. Simon, and M. Leunig. 2011. Hip resurfacing arthroplasty: current status and future perspectives. *Eur Cell Mater* 21:243-58.
- Della Valle, C. J., R. M. Nunley, and R. L. Barrack. 2008. When is the right time to resurface? *Orthopedics* 31 (12 Suppl 2).
- Forrest, N., A. Welch, A. D. Murray, L. Schweiger, J. Hutchison, and G. P. Ashcroft. 2006. Femoral head viability after Birmingham resurfacing hip arthroplasty: assessment with use of [18F] fluoride positron emission tomography. *J Bone Joint Surg Am* 88 Suppl 3:84-9.
- Ganz, R., T. J. Gill, E. Gautier, K. Ganz, N. Krugel, and U. Berlemann. 2001. Surgical dislocation of the adult hip a technique with full access to the femoral head and acetabulum without the risk of avascular necrosis. *J Bone Joint Surg Br* 83 (8):1119-24.
- — —. 2001. Surgical dislocation of the adult hip: A TECHNIQUE WITH FULL ACCESS TO THE FEMORAL HEAD AND ACETABULUM WITHOUT THE RISK OF AVASCULAR NECROSIS. *J Bone Joint Surg Br* 83-B (8):1119-1124.
- Gerdesmeyer, L., H. Gollwitzer, R. Bader, and M. Rudert. 2008. [Surgical approaches in hip resurfacing]. *Orthopade* 37 (7):650-8.
- Hardinge, K. 1982. The direct lateral approach to the hip. *J Bone Joint Surg Br* 64 (1):17-9.
- Hing, C., D. Back, and A. Shimmin. 2007. Hip resurfacing: indications, results, and conclusions. *Instr Course Lect* 56:171-8.
- Howie, D. W., B. L. Cornish, and B. Vernon-Roberts. 1993. The viability of the femoral head after resurfacing hip arthroplasty in humans. *Clin Orthop Relat Res* (291):171-84.
- Jacobs, M. A., R. N. Goytia, and T. Bhargava. 2008. Hip resurfacing through an anterolateral approach. Surgical description and early review. *J Bone Joint Surg Am* 90 Suppl 3:38-44.

- Jameson, S. S., D. J. Langton, S. Natsu, and T. V. Nargol. 2008. The influence of age and sex on early clinical results after hip resurfacing: an independent center analysis. *J Arthroplasty* 23 (6 Suppl 1):50-5.
- Lim, S. J., J. H. Kim, Y. W. Moon, and Y. S. Park. 2011. Femoroacetabular Cup Impingement After Resurfacing Arthroplasty of the Hip. *J Arthroplasty*.
- Little, C. P., A. L. Ruiz, I. J. Harding, P. McLardy-Smith, R. Gundle, D. W. Murray, and N. A. Athanasou. 2005. Osteonecrosis in retrieved femoral heads after failed resurfacing arthroplasty of the hip. *J Bone Joint Surg Br* 87 (3):320-3.
- McBryde, C. W., M. P. Revell, A. M. Thomas, R. B. Treacy, and P. B. Pynsent. 2008. The influence of surgical approach on outcome in Birmingham hip resurfacing. *Clin Orthop Relat Res* 466 (4):920-6.
- McMinn, D., and J. Daniel. 2006. History and modern concepts in surface replacement. *Proc Inst Mech Eng H* 220 (2):239-51.
- McMinn, D. J., J. Daniel, P. B. Pynsent, and C. Pradhan. 2005. Mini-incision resurfacing arthroplasty of hip through the posterior approach. *Clin Orthop Relat Res* 441:91-8.
- McMinn, D. J., J. Daniel, H. Ziaee, and C. Pradhan. 2011. Indications and results of hip resurfacing. *Int Orthop* 35 (2):231-7.
- McMinn, D., R. Treacy, K. Lin, and P. Pynsent. 1996. Metal on metal surface replacement of the hip. Experience of the McMinn prosthesis. *Clin Orthop Relat Res* (329 Suppl):S89-98.
- Mont, M. A., P. S. Ragland, and D. Marker. 2005. Resurfacing hip arthroplasty: comparison of a minimally invasive versus standard approach. *Clin Orthop Relat Res* 441:125-31.
- Nikolaou, V., S. G. Bergeron, O. L. Huk, D. J. Zukor, and J. Antoniou. 2009. Evaluation of persistent pain after hip resurfacing. *Bull NYU Hosp Jt Dis* 67 (2):168-72.
- Nunley, R. M., C. J. Della Valle, and R. L. Barrack. 2009. Is patient selection important for hip resurfacing? *Clin Orthop Relat Res* 467 (1):56-65.
- Saithna, A., and A. P. Dekker. 2009. The influence of computer navigation on trainee learning in hip resurfacing arthroplasty. *Comput Aided Surg* 14 (4-6):117-22.
- Scheerlinck, T., H. Delpont, and T. Kiewitt. 2010. Influence of the cementing technique on the cement mantle in hip resurfacing: an in vitro computed tomography scan-based analysis. *J Bone Joint Surg Am* 92 (2):375-87.
- Schlegel, U. J., J. Siewe, R. G. Bitsch, J. Koebke, P. Eysel, and M. M. Morlock. 2011. Influence of cementing the pin on resistance to fracture in hip resurfacing. *Clin Biomech (Bristol, Avon)* 26 (2):136-40.
- Shields, J. S., T. M. Seyler, C. Maguire, and R. H. Jinnah. 2009. Computer-assisted navigation in hip resurfacing arthroplasty - a single-surgeon experience. *Bull NYU Hosp Jt Dis* 67 (2):164-7.
- Shimmin, A. J., and D. Back. 2005. Femoral neck fractures following Birmingham hip resurfacing: a national review of 50 cases. *J Bone Joint Surg Br* 87 (4):463-4.
- Shimmin, A. J., J. Bare, and D. L. Back. 2005. Complications associated with hip resurfacing arthroplasty. *Orthop Clin North Am* 36 (2):187-93, ix.
- Siguiier, T., M. Siguiier, T. Judet, G. Charnley, and B. Brumpt. 2001. Partial resurfacing arthroplasty of the femoral head in avascular necrosis. Methods, indications, and results. *Clin Orthop Relat Res* (386):85-92.
- Steffen, R. T., N. A. Athanasou, H. S. Gill, and D. W. Murray. 2010. Avascular necrosis associated with fracture of the femoral neck after hip resurfacing: histological

- assessment of femoral bone from retrieval specimens. *J Bone Joint Surg Br* 92 (6):787-93.
- Steffen, R. T., P. R. Foguet, S. J. Krikler, R. Gundle, D. J. Beard, and D. W. Murray. 2009. Femoral neck fractures after hip resurfacing. *J Arthroplasty* 24 (4):614-9.
- Ushio, K., M. Oka, S. H. Hyon, S. Yura, J. Toguchida, and T. Nakamura. 2003. Partial hemiarthroplasty for the treatment of osteonecrosis of the femoral head. An experimental study in the dog. *J Bone Joint Surg Br* 85 (6):922-30.
- van der Weegen, W., H. J. Hoekstra, T. Sijbesma, E. Bos, E. H. Schemitsch, and R. W. Poolman. 2011. Survival of metal-on-metal hip resurfacing arthroplasty: a systematic review of the literature. *J Bone Joint Surg Br* 93 (3):298-306.
- Van Stralen, R. A., D. Haverkamp, C. J. Van Bergen, and H. Eijer. 2009. Partial resurfacing with varus osteotomy for an osteochondral defect of the femoral head. *Hip Int* 19 (1):67-70.
- Vendittoli, P. A., M. Ganapathi, and M. Lavigne. 2007. Blood and urine metal ion levels in young and active patients after Birmingham hip resurfacing arthroplasty. *J Bone Joint Surg Br* 89 (7):989; author reply 989-90.
- Vendittoli, P. A., A. Roy, S. Mottard, J. Girard, D. Lusignan, and M. Lavigne. 2010. Metal ion release from bearing wear and corrosion with 28 mm and large-diameter metal-on-metal bearing articulations: a follow-up study. *J Bone Joint Surg Br* 92 (1):12-9.
- Yoo, M. C., Y. J. Cho, Y. S. Chun, and K. H. Rhyu. 2011. Impingement between the acetabular cup and the femoral neck after hip resurfacing arthroplasty. *J Bone Joint Surg Am* 93 Suppl 2:99-106.
- Zustin, J., M. Amling, M. Krause, S. Breer, M. Hahn, M. M. Morlock, W. Ruther, and G. Sauter. 2009. Intraosseous lymphocytic infiltrates after hip resurfacing arthroplasty : a histopathological study on 181 retrieved femoral remnants. *Virchows Arch* 454 (5):581-8.
- Zustin, J., M. Hahn, M. M. Morlock, W. Ruther, M. Amling, and G. Sauter. 2010. Femoral component loosening after hip resurfacing arthroplasty. *Skeletal Radiol* 39 (8):747-56.

IntechOpen



## **Recent Advances in Hip and Knee Arthroplasty**

Edited by Dr. Samo Fokter

ISBN 978-953-307-841-0

Hard cover, 452 pages

**Publisher** InTech

**Published online** 27, January, 2012

**Published in print edition** January, 2012

The purpose of this book is to offer an exhaustive overview of the recent insights into the state-of-the-art in most performed arthroplasties of large joints of lower extremities. The treatment options in degenerative joint disease have evolved very quickly. Many surgical procedures are quite different today than they were only five years ago. In an effort to be comprehensive, this book addresses hip arthroplasty with special emphasis on evolving minimally invasive surgical techniques. Some challenging topics in hip arthroplasty are covered in an additional section. Particular attention is given to different designs of knee endoprostheses and soft tissue balance. Special situations in knee arthroplasty are covered in a special section. Recent advances in computer technology created the possibility for the routine use of navigation in knee arthroplasty and this remarkable success is covered in depth as well. Each chapter includes current philosophies, techniques, and an extensive review of the literature.

### **How to reference**

In order to correctly reference this scholarly work, feel free to copy and paste the following:

Hiran Amarasekera and Damian Griffin (2012). Surface Replacement of Hip Joint, Recent Advances in Hip and Knee Arthroplasty, Dr. Samo Fokter (Ed.), ISBN: 978-953-307-841-0, InTech, Available from:

<http://www.intechopen.com/books/recent-advances-in-hip-and-knee-arthroplasty/surface-replacement-of-hip-joint>

**INTech**  
open science | open minds

### **InTech Europe**

University Campus STeP Ri  
Slavka Krautzeka 83/A  
51000 Rijeka, Croatia  
Phone: +385 (51) 770 447  
Fax: +385 (51) 686 166  
[www.intechopen.com](http://www.intechopen.com)

### **InTech China**

Unit 405, Office Block, Hotel Equatorial Shanghai  
No.65, Yan An Road (West), Shanghai, 200040, China  
中国上海市延安西路65号上海国际贵都大饭店办公楼405单元  
Phone: +86-21-62489820  
Fax: +86-21-62489821

© 2012 The Author(s). Licensee IntechOpen. This is an open access article distributed under the terms of the [Creative Commons Attribution 3.0 License](https://creativecommons.org/licenses/by/3.0/), which permits unrestricted use, distribution, and reproduction in any medium, provided the original work is properly cited.

IntechOpen

IntechOpen