

We are IntechOpen, the world's leading publisher of Open Access books Built by scientists, for scientists

6,900

Open access books available

186,000

International authors and editors

200M

Downloads

Our authors are among the

154

Countries delivered to

TOP 1%

most cited scientists

12.2%

Contributors from top 500 universities



WEB OF SCIENCE™

Selection of our books indexed in the Book Citation Index
in Web of Science™ Core Collection (BKCI)

Interested in publishing with us?
Contact book.department@intechopen.com

Numbers displayed above are based on latest data collected.
For more information visit www.intechopen.com



Why Minimally Invasive Surgery in Hip Arthroplasty?

Antonio Silvestre, Fernando Almeida, Pablo Renovell,
Raúl López, Laura Pino and Luis Puertes
*School of Medicine Valencia/Hospital Clínico Valencia
Spain*

1. Introduction

Hip replacement surgery is a successful procedure since its commencement. Special attention to minimally invasive access in hip reconstruction has been paid by orthopedic community, implant manufactures, mass media and patients for the last ten years. Nowadays though there is controversy about clinical effectiveness and cost-effectiveness of minimally invasive surgery (MIS) approaches (De Verteuil et al., 2008), many surgeons are using MIS for hip replacement. MIS means tissue sparing, gentle maneuvers, concern about muscles, sheaths, insertions, bone and of course the skin, in a word “preserve tissues”. These techniques have supposed an effort for the surgeons to place hip prosthesis with the accuracy of standard reproducible approaches and with a similar rate of complications.

We went through the boom of minimally invasive prosthetic surgery in our Institution seven years ago. Encouraging results obtained by other authors drove us to cadaveric and laboratory training before using this technique in patients.

In the beginning we started with the mini-posterior approach as posterior access to the hip was the most commonly used in our Hospital. We thought benefits for the patients could be obtain from reducing surgical access in terms of accelerated rehabilitation program, analgesic control, blood loss, hospital stay and economic impact, without consequences in long-term results. Good outcomes shown in this paper strengthen our daily work. Four years later in an attempt to reduce posterior dislocation rate after hip prosthesis (around 4.5% in our media and up to 10% in some reports) according to our principle of “preserve tissues”, we started using the direct anterior approach with a fracture table (AMIS) in order to perform a muscle sparing procedure that showed a lower posterior dislocation rate than the mini-posterior and standard posterior approaches.

This practice leads us to this retrospective paper that compares our results among these approaches.

2. Material and methods

We evaluated 199 hips (187 patients) which received reconstructive surgery in our Institution. Surgery was performed by three senior surgeons of our Hospital since May 2004 until December 2009. We selected only patients with analogous demographic data and surgeries done by these three senior physicians to homogenize results and implants. No hip fracture was

included in this series and diagnosis was primary osteoarthritis in 118 hips and secondary osteoarthritis due to osteonecrosis in 31 hips, rheumatoid arthritis in 26 hips, Perthes disease in 11 hips, mild hip dysplasia in 12 hips and pigmented villonodular synovitis in one hip. The exclusion criteria were severe DDH (different implants are needed) and history of previous surgery on the operated hip that affects functional recovery after hip surgery. Patients were distributed in three groups according to the surgery performed. Group A included 92 patients (99 hips) who received hip prosthesis through a standard posterolateral approach. Group B included 46 patients (49 hips) who were operated by a posterior mini invasive access and group C was formed by 49 patients (51 hips) who received a direct anterior approach with the help of a fracture table. Group B and C were performed by the two senior surgeons who got cadaver and laboratory training before clinical use of this technique in patients. Demographic data are shown in table 1. Implants used in all cases were versafit cup CC and quadra system stem (cementless implants in 73 hips and hybrid hip in 11 hips) [Medacta® International SA; Italy] and bihapro cup and 3-V cementless system stem or PMB cemented system stem (cementless in 98 hips and hybrid in 17 cases) [Biomet; Warsaw, IN]. Bearing surfaces were choose depending on the age of the patients, as we prefer ceramic on ceramic bearing surface for young active patients (under 65 years of age) and metal or ceramic on PE for older people.

	GROUP A	GROUP B	GROUP C
Number of hips	99 (92 patients)	49 (46 patients)	51 (49 patients)
Age	66.19±10.99	66.32±11.72	65.19±13.19
Sex (M/F)	53/39	25/21	29/20
Body Weight (Kg)	81.5±1.7	76±1.9	77.2±1.2
Height (cm)	163.5±2.3	163.4±1.8	162.7±0.7
Body mass index (Kg/m²)	30.6±1.3	27.8±1.6	29.3±1.1
Preoperative diagnosis			
Osteoarthritis	60	28	32
Osteonecrosis	12	8	11
RA	14	6	4
Perthes	6	3	2
Hip displasia	7	4	1
Pigmented villonodular synovitis			1
Preoperative HSS	57.010 (SD 4.09)	57.959 (SD 6.26)	56.606 (SD 6.16)

Table 1. Demographic data of the patients

Institutional approval was obtained from the Hospital for the new techniques. Learning curve affected results in the beginning of the procedure and fluoroscopy was used during the beginning of these series to aid in implant position and anatomic referencing. No great changes were adopted for the mini invasive posterior access, as patient position is similar to the conventional posterolateral approach. A more straight oblique and proximal incision was employed for the mini-posterior access. Specific devices designed for the different approaches were used in order to get proper placement of the implants. The cup was inserted in 40-45° abduction angle in the different groups but a bigger anteversion angle was applied to the acetabulum in the posterior approaches to avoid posterior dislocation of the hip. Femoral reaming, broaching and stem implantation were resumed in the mini-

posterior access as in conventional postero-lateral approach with the aid of some devices developed to bring up proximal femur into the incision.

Our operative technique for direct anterior approach (AMIS) was the same that described F. Laude (Laude, 2006). Patients were placed in supine position on an orthopaedic table with the foot of the operated leg secured in a traction device (Medacta®). The operation table was positioned in horizontal condition to the floor and the pelvis was checked to be set in neutral angle tilting angle. Towel pads were placed under the buttock to stabilize pelvic movement and to bring up proximal femur into the incision during flexion and adduction of the leg. The cup was inserted in 40-45° inclination angle by referring alignment rod to the interconnecting line of bilateral ASIS and 10° anteversion angle by referring the rod to the operation table. Controls by image intensifier were used during first cases to estimate inclination and anteversion angle. After cup placement, traction and gentle external rotation was applied to the operated leg. The supero-lateral capsule and the pubo-femoral ligament were released for appropriate femoral exposure and preparation. Femoral reaming, broaching and stem implantation were performed after verifying the direction of the femoral axis and anterior bow of the femur.

Full weight bearing was allowed from the second-third postoperative day depending on laboratory results and need of red cell transfusion, except in complicated cases. Walking with a walker or crutches was started from the second day after surgery. Patients were permitted to go up and down the stair using handrail from the fifth day after surgery. Using a cane or a walker was based on patient's ability. Physical therapists instructed gait training and ambulation during patient's hospital stay. Patients left the hospital when they get sufficient hip function for their activity of daily living.

Operative time (skin incision to skin closure) and intraoperative and postoperative blood loss volume were evaluated as indices of operative invasion. Intraoperative blood loss volume was estimated by using the volume in the suction device adding up the weight of compresses used during surgery. Postoperative blood loss volume was measured by drain output postoperatively, which was removed 48 h after surgery. Laboratory tests were used to determine haemoglobin concentration and haematocrit (HCT) 36-48 h after surgery to get a more real scene of the patient's hemodynamic status.

Standard protocol during the time of this study for all the patients was low molecular-weight heparin for 28 days postoperatively. Elastic stocking was applied to both legs for intraoperative deep venous thrombosis until first outpatient visit. Ultrasound was obtained only in patients with symptoms of deep vein thrombosis. Cefazolin (Kefol®) two grams were given intravenously an hour before surgery, followed by 1 gr/8h for two days after surgery. Analgesic drugs were given during hospital stay but no morphic therapy was used in the immediate postoperative.

Patients were assessed preoperatively and postoperatively at 6 weeks, 3 months and annually thereafter with clinical evaluation including gait, need for assistance devices, ROM and visual analog pain score. Standard radiographs of the operated hip were taken at 6 weeks, 3 months and at annual review. Radiological assessment was performed by measuring cup inclination, cup anteversion angle and positioning of cup within the safe zone of Lewinnek (Lewinnek et al., 1978). Stem alignment of varus or valgus positioning of less than 3° was considered neutral position on AP X-ray. Hip function was assessed clinically using the Harris Hip Score at 6 weeks, 3 months, and annually. Data are collected pre and postoperatively from patient questionnaires and from an independent senior orthopaedic surgeon (R.L.) assessment at each visit. All known complications were captured and collected for descriptive study.

Differences in laboratory levels, drain output measures, length of hospital stay, visual analog pain score and gait parameters between groups were examined using an unpaired Student's t-test with the aid of SPSS-15. The significance level was set at $P < .05$ for all analysis.

3. Results

Three groups were established depend on the access employed to the hip joint. Underlying diagnosis was ortheoarthritis and osteonecrosis in 74.87% of cases.

Mean operative time was longer in first cases after introduction of the new techniques (mini posterior and AMIS) due to our learning curve, but this rate returns to equivalent operative time value as the standard postero-lateral approach after our fifteen surgeries. Hip access has no significant difference in surgery time [$P = 0.44$]. The average blood loss during the surgery was 162.4 ± 57.7 ml for group A, 149.4 ± 57.3 ml for group B and 141.5 ± 54.2 ml for group C as meticulous hemostasis was applied in all cases and a sealer device was used in the last group. Measurement of blood loss in drain output shows a significant difference between group C and A [$P = 0.04$] but no between group B and A. The overall risk of red cell transfusion was bigger in group A than in the rest of groups. Average length of the hospital stay that shows significant differences between minimally invasive procedures and standard access of the hip [$P = 0.023$] could be explained by other facts as introduction of accelerate rehabilitation programmes linked to the new techniques. However, absence of skilled nursing or extended-care facilities affects patients discharge to home in our environment. Other indices of operative invasion, hip stability and walking ability are reported in table 2. Five posterior hip dislocations were observed in group A and two in group B. No hip dislocation has been assessed in group C.

Analyzing hip recovery we checked that time required to single-leg stance for more than 5 seconds was 21.3 days in group A (range 12-76 days), 20.9 (range 10-75 days) and 17.1 days (range 5-75 days) in group C. There were no significant differences in the single-leg stance between anterior and posterior approaches. However this competence depends on patient's age, therapist's cooperation and previous functional status. Positive Trendelenburg's sign was identified in mostly all the patients before surgery, but at six weeks it was recognized in only 3.92 % of hips in group C. Negative Trendelenburg's sign was acquired in this group at 17.3 days (range 5-75 days). There were significant differences between anterior and posterior approaches [$P = 0.048$].

In our series required time up to walking by two canes or a walker was 3.494 ± 1.163 for group A, 2.571 ± 0.912 for group B and 2.262 ± 0.68 for group C. No significant differences have been found among the different approaches. Patients from group C were able to walk by a single cane more than 250 meters at 15.0 days (range 3-35 days) and fifty-six percent of these patients were capable to walk without the use of assistive walking aids at three weeks postoperatively. On the opposite patients from group A and B were able to walk by a single cane more than 250 meters at 19.4 days (range 5-41 days). There were significant differences between posterior and anterior access to the hip [$P = 0.039$] (table 3).

Harris hip score results are shown in table 2, but no significant differences were observed among the three groups. Visual analog pain score after surgery improved to 3.030 ± 0.984 in group A, 2.489 ± 0.71 in group B and 2.213 ± 0.798 in group C. Significant differences were detected when comparing group C with the others groups [$P < 0.05$] (table 3). Three patients (two in group A and one in group C) developed inguinal pain three months after surgery. An infiltration of the ileopectineus bursa resolved their symptoms.

Ninety-six cups (96.07%) had been implanted within the safe zone of the Lewinnek method in this series (Lewinnek et al., 1978). Less anteversion angle was applied to the cups in the

anterior approach to avoid anterior dislocation. On the other hand anteversion angle was bigger in group A and B (posterior access) to prevent from posterior dislocation of the hip. Stem alignment in anteroposterior radiograph was 178.56 ± 0.97 in group A, 179.23 ± 1.13 in group B and 179.85 ± 1.94 in group C with no cases or varus o valgus position (more than 3° in the A-P X-ray).

	GROUP A	GROUP B	GROUP C
<i>Operative time(minutes)</i>	79.25±18.90	84.61±16.47	87.24±30.51
<i>Blood loss (drain ouput)</i>	624.64±10.62 ml	595.91±13.21 ml	579.01±14.91
<i>Need transfusión</i>	22.77%	16.21%	14.75%
<i>Preoperative Hb</i>	13.45±1.32 g/dl	13.58±1.07 g/dl	13.38±1.39 g/dl
<i>Postoperative Hb</i>	8.89±0.69 g/dl	9.3±0.78 g/dl	9.76±1.16 g/dl
<i>Preoperative HTO</i>	39.35±3.64	39.61±3.13	39.06±4.14
<i>Postoperative HTO</i>	26.51±2.14	27.96±2.40	28.38±3.12
<i>Lenght of hospital stay after surgery</i>	7.35±2.04 days (84.8%)	6±1.81 days (83.6%)	4.78±1.23 days (83.6%)
<i>Presence of Trendelenburg's sign</i>			
1 week	87 hips (87.87%)	43 hips (87.75%)	41 hips (80.39%)
3 weeks	44 hips (44.44%)	21 hips (42.85%)	14 hips (27.65%)
6 weeks	13 hips (13.13%)	6 hips (12.24%)	2 hips (3.92%)
<i>Average time to single-leg stance > 5''</i>	21.3 days	20.9 days	17.1 days
<i>No assistive walking aids (3 weeks)</i>	47 hips (47.47%)	24 hips (48.97%)	29 hips (56.82%)
<i>HHS</i>			
6 weeks	72.61±3.23	73.74±3.23	79.27±7.45
3 months	83.82±4.20	84.91±4.96	88.08±6.09
1 year	90.74±6.16	91.15±6.04	91.34±6.07

Table 2. Indices of operative invasion, hip stability and walking ability

Intraoperative and postoperative complications are shown in Table 4. Main surgical complications were observed in our learning curve (15 first cases) of the minimally invasive techniques as we think these are demanding procedures which require experience in hip surgery. Intraoperative complications were detected and settled during surgery. Proximal femoral perforations identified during broaching and reaming the femur in the AMIS procedure (group C) did not alter the procedure. Periprosthetic fractures were fixed with cerclage cable fixation and major throchanteric fractures require cerclage cable fixation in posterior approaches (group A and B) but no fixation was used in the anterior access (group C). A femoral shaft fracture was confirmed during preparation for the insertion of the stem in group C; enlarging of the exposure in zigzag way allowed us to reduce and fixed the fracture with a femoral plate with screws and cables. The case requiring acute revision was cup dislodgment checked with X-ray control that needed re-operation two days after first surgery. Deep infections needed two-stage revision of the hips; the average interval between first-stage resection and reimplantation was 5.2 months. On the other hand superficial wound infections were resolved by superficial debridement and irrigation with wound closure. Lateral femoral cutaneous nerve paresthesias verified in group C improved six months after

surgery. The cases of clinically evident deep-vein thrombosis were treated with pharmacological therapy. A young patient of group C died two days after surgery due to a fatal embolism. All cases of length leg discrepancy were less than 1 cm and well tolerated by the patients, so we do not include as complications.

	Hb decrease	HTO decrease	Blood loss (drain output)	Lenght of hospital stay	Visual analog score	Walk by a single cane 250 m
Group B-A	P= 0.058	P= 0.2	P> 0.05	P= 0.02	P> 0.05	P> 0.05
Group C-A	P= 0.0001	P= 0.08	P= 0.04	P= 0.02	P=0.02	P= 0.03
Group C-B	P= 0.0001	P= 0.3	P= 0.33	P= 0.007	P= 0.008	P= 0.03

Table 3. Comparative of some results between groups (P values)

	Group A	Group B	Group C
	Cases (number) and treatment	Cases (number) and treatment	Cases (number) and treatment
Femoral shaft fracture	0	0	1 <i>Femoral plate (screws and cable fixation)</i>
Periprosthetic fracture	2 <i>Cerclage cable fixation</i>	2 <i>Cerclage cable fixation</i>	1 <i>Cerclage cable fixation</i>
Proximal femoral perforation	0	3 <i>No treatment</i>	2 <i>No treatment</i>
Major throchanteric fracture	3 <i>Cerclage cable fixation</i>	3 <i>Cerclage cable fixation</i>	4 <i>No treatment</i>
Cup dislodgment	0	0	1 <i>Acute revision</i>
Posterior dislocation	5 <i>Closed reduction</i>	2 <i>Closed reduction</i>	0
Deep infection	4 <i>Two-stage revision</i>	2 <i>Two-stage revision</i>	0
Superficial infection	5 <i>Debridement</i>	2 <i>Debridement</i>	2 <i>Debridement</i>
Nonfatal DVT	6 <i>Pharmacological therapy</i>	3 <i>Pharmacological therapy</i>	2 <i>Pharmacological therapy</i>
Stem subsidence	2 <i>Well tolerated</i>	0	1 <i>Well tolerated</i>
Paresthesias of the lateral aspect of the thigh	0	0	4
Fatal embolism. RIP	0	0	1

Table 4. Complications in our series

4. Discussion

Access to hip joint for placing a THA has been gained by different approaches along history. Each one has advantages and disadvantages but nevertheless we can assume total hip replacement is a successful procedure. Different viewpoints and discussions persist nowadays regarding fixation procedures, gliding couples and materials. In this context appeared years ago the concept of “minimally invasive surgery” that must be distinguished from less invasive surgery (Judet, 2006). This background supposed a breeding soil to show immeasurable advantages of these techniques. Plenty of reports were published describing its benefits in terms of economy, accelerated rehabilitation and comfort for the patients. These encouraging results explained the anxiety of the people about this useful surgery. However time has put these procedures in his place (Goosen et al., 2011; Maffiuletti et al., 2009; Nakata et al., 2009; Pospischill et al., 2010; Roy et al., 2010; Sugano et al., 2009). However there are some evidences of benefits reported by minimally invasive procedures (Berend et al., 2009; Duwelius & Dorr, 2008; Khan et al., 2006; Lamontagne et al., 2011; Matziolis et al., 2011; Müller et al., 2011; Nakata et al., 2009; Stehlík et al., 2008; Varela et al., 2010). We believe that with a good selection of the patients and after an education and training schedule these techniques are safe and reproducible.

Muscle damage and blood loss was two our main concerns in hip surgery. We have not established a pre-donation autologous blood protocol at our Institution and economic analysis of this practice was no cost-benefit in our environment. In order to lessen red cell transfusion we start the mini-posterior approach delighted with encouraging reports from other authors (Khan et al., 2006; Mazoochian et al., 2009; Sculco & Boettner, 2006). Though we reduced red cell transfusion with our mini-posterior access (group B) compare to the standard approach (group A) 16.32% vs 22.77% no significant differences were found in blood loss in the drain output, haemoglobin and HTO decrease [$P>0.05$].

It is believed that muscle protection enables the patient to start the rehabilitation program earlier and to reduce the length of his/her hospital stay (Goosen et al., 2011; Nakata et al., 2009; Palieri et al., 2011; Stehlík et al., 2008; Varela et al., 2010). Our plan was to minimize injure to muscles and/or bone to accelerate rehabilitation but we were not so worried about short scars. We had no doubt in enlarging the incision if it was required during our performances to be confident with the stem or cup position or to avoid damaging soft tissues. After introduction of the mini-posterior approach (group B) decrease in length hospital stay was observed with significant differences to standard access (group A) [$P=0.02$], but usually when new techniques are introduced more attention is paid to questions as rehabilitation programmes and shortening hospital stay. We have also found in our series an improving in HHS and visual analog score for the first three months, however without significant differences with the standard approach.

Once the two of our main concerns were improved, we focused our attention in posterior dislocation. The posterior approach, the most commonly used at our Institution and all around the world has a high hip dislocation rate, up to 10 % in some reports (around 4.5% in our media) (Berry et al., 2004; Heithoff et al., 2001; Khan et al., 2006; Peters et al., 2007). In an attempt to prevent dislocations (none in group C in this series), being respectful with soft tissues we looked for news approaches as the AMIS, three and a half years ago. We believe this direct anterior approach, classically known as “Smith-Peterson” but initially described by the German surgeon Carl Hueter, provides an excellent exposure of the hip, is a muscle sparing procedure and has a lower dislocation rate than the posterior approach (Matta et al.,

2005; Siguier et al., 2004). We have no great experience with the antero-lateral approach but even though its dislocation rate is low, we have found more limping after THA in patients with the lateral approach.

As well as lessening the rate of posterior hip dislocations this technique allows a proper exposure of the acetabulum (Mast & Laude 2011) and it is widely accepted. In the current literature few reports have compared the extent and location of muscle damage between posterior and the direct anterior approaches (Nakata et al., 2009; Meneghini et al., 2005). Only Meneghini and colleagues reported a comparative cadaveric study about muscle damage evaluation with both approaches (Meneghini et al., 2005). He concluded that main differences related to injured muscle were in the gluteus minimus, being less harmful the anterior approach (8.5% vs 18%). Another comparative study shows that more patients could walk without assistive devices 3 weeks after surgery with the anterior direct approach (34%) than with the posterior one (Nakata et al., 2009). For that reasons, we started using the AMIS approach that let us get access to the hip through an inter-muscular (sartorius muscle and tensor fascia lata muscle) and inter-nervous (femoral nerve and superior gluteal nerve) portal. The anterior approach, which remains as the standard approach to the hip in paediatric orthopaedic surgery (Berger et al., 2004) regained popularity in adult procedures with the outbreak of the minimally invasive surgeries.

The principal advantage of this portal is that even an extensile exposure was required the gluteal muscles were kept intact. We agree with the idea that “minimally invasive surgery” does not imply short scars but require paying attention to soft tissues (Barton & Kim, 2009; Sculco, 2004; Waldman, 2003; Wojciechowski et al., 2007). Injuries to a muscle or its attachments impair muscle proprioception and reduce its strength. Preventing muscle or attachments injury helps restoring normal muscular tension and improve stabilization of the hip joint.

Haemoglobin decreases after anterior minimally invasive procedure shows significant differences comparing this group with the mini posterior and standard approach [$P=0.0001$], but no significant results were obtained with HTO. Blood loss in the drain output also reflects significant differences making the comparison to standard approach (group A) [$P=0.04$] but not with the mini-posterior access (group B) [$P=0.33$]. The reduction in blood loss was attributed to meticulous care with haemostasis to avoid wound hematomas as the only layer was closed was the sheath of the TFL (Morris et al., 2010), however most of the bleeding in hip replacement depends on bone bed not on the size of the wound. It is admitted that wound hematoma formation may be greater in the direct anterior approach as the incision is anterior and there is less inherent pressure on the wound that may aid in hemostasis. We believe that meticulous haemostasis is required to obtain a good view of the joint, so we prefer to use bipolar sealer to avoid bleeding (Morris et al., 2010). These details allow us to control blood loss, give us a neat exposure of the hip joint and let us take anatomic references for accurate component placement.

We found an improvement in HHS (Klausmeier et al., 2010; Lugade et al., 2010; Matziolis et al., 2011) and Trendelenburg's test (Nakata et al., 2009) with the AMIS. Visual analog pain score also improved with significant differences related to group A and B [$P=0.02$ and $P=0.008$]. Walking ability and length of hospital stay show significant differences comparing results to group A and B [$P<0.05$] (Berend et al., 2009; Khan et al., 2006; Lamontagne et al., 2011; Maffiuletti et al., 2009; Morris et al. 2010; Nakata et al., 2009; Seng et al. 2009). Patients in group C were in hospital for a mean 4.78 days with the majority discharged to home (83.6%). Lower blood loss and muscle sparing that allowed the patients an accelerated

program of rehabilitation made them more confident after surgery to start walking, sitting or getting out of bed. Our patients used assistive devices as crutches or walkers during their hospital stay.

The concept of tissue sparing surgery has been an important fact in surgical techniques for the last ten years. It includes reduced incisions with small scars, but the real point toward these procedures attempt is preserving soft tissues. These techniques are as much careful as possible with muscles, sheaths, insertions, bone and of course the skin. They suppose new exposure techniques and of course new instruments to place the same prosthesis with the accuracy of the standard approaches and with few complications. Manufactures, tribologists and engineers have done a great effort to make possible these techniques but some of the advantages found in the current paper in terms of patient comfort, anaesthetic parameters, related costs, length of hospital stay, analgesic use, blood loss and patient rehabilitation explain the enthusiasm of orthopaedic surgeons in these procedures. According to the classification of Duncan in 2006, based on approach to the skin, number of skin incisions and technique of dissection the anterior direct approach is an “intermuscular approach” meanwhile the lateral and posterior approaches, with a standard or mini-incision, are classified as “transmuscular approaches” as they include an invasive operating step with muscle and tendon sectioning. Only the double access can be considered as a tissue sparing surgery but sometimes requires new design for the implants and prolonged use of an x-ray C-arm to check component placement. Besides these facts, cadaveric studies suggest greater muscle damage occurs with the two-incision technique than with the direct anterior approach (Mardones et al., 2005; Meneghini et al., 2005).

Zati (Zati et al., 1997) and He (He et al., 1988) concluded that, in early post-operative time, the afferent nerves to the muscle are more important than hip capsule receptors. Accepting that hypothesis tendon sectioning should be avoided because this gesture can affect sensomotory capacity of the joint so rehabilitation programme will be longer and worse functional scores will be obtained. This could explain better early functional outcome scores and visual analog score pain in the anterior direct approach compared to posterior procedures.

Every time a new procedure is established, great concern about possible complications arises in surgeons' mind. Minimally invasive approaches are related to longer surgery time and recommended in selected patients (Vail & Callaghan, 2007). However, a learning curve is necessary to take a new surgical access into practice. We have checked longer operating time in group B and C particularly in our first cases, but no significant differences were found [$P = 0.44$].

D'Arrigo (D'Arrigo et al., 2009) reported the rate of complications is not reduced along a geometric pattern during the learning curve of the anterior minimally invasive surgery, whereas surgical time was significantly correlated with this learning curve, so longer time was required in their first ten cases than in the rest. The idea of preserving muscles and tendons and absence of own experience in this approach made us to be carefully with the method of dissection, lengthening surgery time. All that measures applied in the present report have given 6-week HHS and visual analog pain scores significantly better than in posterior approaches (standard and mini-incision). This experience agrees the reports of Kim (Kim, 2006) and Ogonda (Ogonda et al., 2005) as mini-incision posterior approach implies direct muscle transection and remarks the difference between a small-incision and a tissue sparing surgery.

Minimally invasive techniques require some training and experience in hip surgery, especially for cup placement and femoral exposure. We verified our complications with the use of these techniques and how complications rate changed over time related to surgeons' experience. Of course this is a descriptive not comparative study within all surgeries done by a reduced group of surgeons, so complication rates may not be widespread.

Intraoperative major trochanteric fractures seen in our series related to femoral exposure didn't need fixation in group C as abductor mechanism was not damage. No restrictions were placed on patients postoperatively and no loss of strength, disturbance of gait or pain was notice with these trochanteric avulsions at latest follow-up. Better understanding of the tension applied on the femur and improving in our superior capsular release during exposure resolved this problem. Beside these facts, the stem we have used in group C and some hips of group B (quadra, Medacta®, IT) has a wide proximal section that requires invasion of the inner part of the major trochanter and places it at risk of fracture. On the opposite major throchanteric fractures of group A and B were fixed with cerclage band and gait restrictions were used though not affecting outcomes.

Proximal femoral perforations due to hard reaming of the proximal femur, mainly in muscular male patients with a short varus femoral neck, were our more frequent obstacle to get an accurate stem placement with minimally invasive procedures, mainly in AMIS group. Sariali (Sariali et al., 2008) reported 7 falses reamings of the proximal femur, all noted intra-operatively and without consequences. We noticed this complication in difficult femoral exposures that did not let external rotation and lateral displacement of the proximal femur. All femoral perforations occurred in our learning curve in muscle male patients with severe flexion contractures and have been avoided by improving our technique during femoral broaching. A more horizontal insertion angle of the starting broach is required in these cases for femoral reaming. Careful exposure of the proximal femur and enough releasing of the posterior capsule and pubo-femoral ligament must be done to move the femur in front of the incision.

Periprosthetic fracture and femoral shaft fracture happened after adjusting the bigger stem to a Dorr type C femur and they were detected and resolved intraoperative. We don't agree the idea of higher prevalence of varus stem in minimally invasive procedures (Bernasek et al., 2010) as we have not found outliers in our series (Hart et al., 2005). Cup placement in anterior hip access is another challenge to surgeons familiarized with posterior incision as the pelvis tilt in fracture table. Cup dislodgment reported was a mistake of the surgeon and not a real complication of the technique as he felt self-confident with the acetabulum purchase without testing the grip of the cup.

Rapid early return to function related to minimally invasive surgery (Duwelius & Dorr, 2008; Khan et al., 2006; Seng et al., 2009) has been reported in many papers but these techniques have shown increase complications, especially with the two-incision technique (Desser et al., 2010; Pagnano et al., 2005; Tanavalee et al., 2006). Mini-posterior and direct anterior approach report show rapid recovery function for patients (Duwelius & Dorr, 2008; Klausmeier et al., 2010; Lin et al., 2007; Mardones et al., 2005; Procyk, 2007; Stehlík et al., 2008) but these were limited to the early experience of a few surgeons.

Medical complications encountered in our series were similar to other large series of THAs (Clohisy & Harris, 1999; Duwellius et al., 2007). Paresthesias of the lateral aspect of the thigh (group C) were observed in four cases as we place the incision two finger breadths lateral from ASIS to avoid injuring of the lateral femoral cutaneous nerve.

We can conclude that minimally invasive procedures confer rapid functional recovery of the hip (Bhandari et al., 2009; Fink et al., 2010; Lin et al., 2007; Matta et al., 2005; Pospischill et al., 2010; Varela et al., 2010) and our data suggest that after an education and training schedule for hip experienced surgeons, they could be a safe and reproducible technique. Efforts should focus on how to prevent complications particularly during the learning curve. Moreover, a new spatial guidance for cup and stem placement in anterior hip access should be assumed by surgeons used to lateral and posterior approaches.

5. References

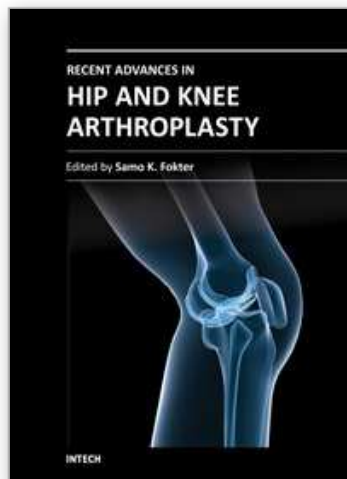
- Barton C, Kim PR. Complications of the direct anterior approach for total hip arthroplasty. *Orthop Clin North Am* 2009; 40 (3): 371- 5
- Berend KR, Lombardi AV Jr., Seng BE, Adams JB. Enhanced early outcomes with the anterior supine intermuscular approach in primary total hip arthroplasty. *J Bone Joint Surg Am* 2009; 91 Suppl 6: 107-20
- Berger R, Jacobs JJ, Meneghini RM et al. Rapid rehabilitation and recovery with minimally invasive total hip arthroplasty. *Clin Orthop Relat Res* 2004; 429: 239-47
- Bernasek TL, Lee WS, Lee HJ, Lee JS, Kim KH, Yang JJ. Minimally invasive primary THA: anterolateral intermuscular approach versus lateral transmuscular approach. *Arch Orthop Trauma Surg*. 2010 Nov; 130(11): 1349-54. Epub 2010 Jan 13
- Berry DJ, von Knoch M, Schleck CD, et al. The cumulative long-term risk of dislocation after primary Charnley total hip arthroplasty. *J Bone Joint Surg* 2004; 86A (1): 9-14
- Bhandari M, Matta JM, Dodgin D, Clark C, Kregor P, Bradley G, Little L. Outcomes following the single incision anterior approach to total hip arthroplasty: a multicenter observational study. *Orthop Clin North Am*. 2009; 40: 329-42
- Clohisey JC, Harris WH. The Harris-Galante porous coated acetabular component with screw fixation: an average ten-year follow-up study. *J Bone Joint Sur Am* 1999; 81: 66-73
- D'Arrigo C, Speranza A, Monaco E, Carcangiu A, Ferretti A. Learning curve in tissue sparing total hip replacement: comparison between different approaches. *J Orthopaed Traumatol* (2009) 10:47-54
- De Verteuil R, Imamura M, Zhu S, Glazener C, Fraser C, Munro N, Hutchison J, Grant A, Coyle D, Coyle K, Vale L. A systematic review of the clinical effectiveness and cost-effectiveness and economic modelling of minimal incision total hip replacement approaches in the management of arthritic disease of the hip. *Health Technol Assess*. 2008 Jun; 12(26): iii-iv, ix-223.
- Desser DR, Mitrick MF, Ulrich SD, Delanois RE, Mont MA. Total hip arthroplasty: comparison of two-incision and standart techniques at an AOA-accredited community hospital. *J Am Osteopath Assoc*. 2010; 110 (1): 12-5
- Duncan CP (2006) Minimally invasive or limited incision hip replacement classification. In: *Proceedings, MIS meet CAOS symposium*, Scottsdale, pp 26-28
- Duwelius PJ, Dorr LD. Minimally invasive total hip arthroplasty: an overview of the results. *Instr Course Lect*. 2008; 57: 215-22
- Duwellius PJ, Burkhart RL, Hayhurst JO, Moller H, Butler JB. Comparison of the 2-incision and mini-incision posterior total hip arthroplasty technique: a retrospective match-pair controlled study. *J Arthroplasty* 2007; 22: 48-56

- Fink B, Mittelstaedt A, Schulz MS, Sebens P, Singer J. Comparison of a minimally invasive posterior approach and the standard posterior approach for total hip arthroplasty. A prospective and comparative study. *J Orthop Surg Res*. 2010 Jul 27; 5: 46
- Goosen JH, Kollen BJ, Castelein RM, Kuipers BM, Verheyen CC. Minimally invasive versus classic procedures in total hip arthroplasty: a double-blind randomized controlled trial. *Clin Orthop Relat Res*. 2011 Jan; 469(1): 200-8. Epub 2010 Mar 30
- Hart R, Stipčák V, Janecek M, Visna P. Component position following total hip arthroplasty through a miniinvasive posterolateral approach. *Acta Orthop Belg*. 2005 Feb; 71(1): 60-4
- He XH, Tay SS, Ling EA (1988) Sensory nerve endings in monkey hip joint capsule: a morphological investigation. *Clin Anat* 11(2): 81-85
- Heithoff BE, Callaghan JJ, Goetz DD, et al. Dislocation after total hip arthroplasty: a single surgeon's experience. *Orthop Clin North Am* 2001; 32(4): 587-91
- Judet T. Revolution, progression or illusion. Does minimally invasive surgery exist for hip arthroplasty. *Interact Surg*; 2006; 1: 3-4
- Khan RJ, Fick D, Khoo P, Yao F, Nivbrant B, Wood D. Less invasive total hip arthroplasty: description of a new technique. *J Arthroplasty* 2006 Oct; 21(7): 1038-46
- Kim YH. Comparison of primary total hip arthroplasties performed with a minimally invasive technique or standard technique. *J Arthroplasty* 2006; 21: 1092-8
- Klausmeier V, Lugade V, Jewett BA, Collis DK, Chou LS. Is there faster recovery with an anterior or anterolateral THA? A pilot study. *Clin Orthop Relat Res*. 2010 Feb; 468(2): 533-41. Epub 2009 Sep 10
- Lamontagne M, Varin D, Beaulé PE. Does the anterior approach for total hip arthroplasty better restore stair climbing gait mechanics? *J Orthop Res* 2011 Mar 15. doi: 10.1002/jor.21392. [Epub ahead of print]
- Laude F. Total hip arthroplasty through an anterior Hueter minimally invasive approach. *Interact Surg* 2006; 1: 5-11
- Lewinnek GE, Lewis JL, Tarr R, et al. Dislocations after total hip-replacement arthroplasties. *J Bone Jt Surg* 1978; 60A: 217-20
- Lin DH, Jan MH, Liu TK, Lin YF, Hou SM. Effects of anterolateral minimally invasive surgery in total hip arthroplasty on hip muscle strength, walking speed, and functional score. *J Arthroplasty*. 2007 Dec; 22(8): 1187-92
- Lugade V, Wu A, Jewett B, Collis D, Chou LS. Gait asymmetry following an anterior and anterolateral approach to total hip arthroplasty. *Clin Biomech (Bristol, Avon)*. 2010 Aug; 25(7): 675-80. Epub 2010 Jun 9
- Maffiuletti NA, Impellizzeri FM, Widler K, Bizzini M, Kain MS, Munzinger U, Leunig M. Spatiotemporal parameters of gait after total hip replacement: anterior versus posterior approach. *Orthop Clin North Am*. 2009 Jul; 40(3): 407-15
- Mardones R, Pagnano MW, Nemerish JP, et al. Muscle damage after total hip arthroplasty done with two-incision and mini-posterior techniques. *Clin Orthop* 2005; 441: 63-7
- Mast NH, Laude F. Revision total hip arthroplasty performed through the Hueter interval. *J Bone Joint Surg Am*. 2011 May; 93 Suppl 2:143-8
- Matta JM, Shahrddar C, Ferguson T. Single-incision anterior approach for total hip arthroplasty on an orthopaedic fracture table. *Clin Orthop Relat Res* 2005; 441: 115-24

- Matziolis D, Wassilew G, Strube P, Matziolis G, Perka C. Differences in muscle trauma quantifiable in the laboratory between the minimally invasive anterolateral and transgluteal approach. *Arch Orthop Trauma Surg.* 2011 May; 131(5): 651-5. Epub 2010 Oct 17
- Mazoochian F, Weber P, Schramm S, Utzschneider S, Fottner A, Jansson V. Minimally invasive total hip arthroplasty: a randomized controlled prospective trial. *Arch Orthop Trauma Surg.* 2009 Dec; 129(12): 1633-9. Epub 2009 May 8
- Meneghini RM, Pagnanno MW, Trousdale RT, et al. Muscle damage during MIS total hip arthroplasty: Smith-Petersen versus posterior approach. *Clin Orthop Relat Res* 2005; 453: 292-8
- Morris MJ, Berend KR, Lombardi AV Jr. Hemostasis in anterior supine intermuscular total hip arthroplasty: pilot study comparing standart electrocautery and a bipolar sealer. *Surg Technol Int* 2010; 20: 352-6
- Müller M, Tohtz S, Dewey M, Springer I, Perka C. Muscle trauma in primary total hip arthroplasty depending on age, BMI, and surgical approach : Minimally invasive anterolateral versus modified direct lateral approach. *Orthopade.* 2011 Mar; 40(3): 217-223
- Nakata K, Nishikawa M, Yamamoto K, Hirota S, Yoshikawa H. A clinical comparative study of the direct anterior with mini-posterior approach: two consecutive series. *J Arthroplasty* 2009 Aug; 24(5): 698-704. Epub 2008 Jun 13
- Ogonda L, Wilson R, Archibold P, et al. A minimally-incision technique in total hip arthroplasty does not improve early postoperative outcomes. *J Bone Joint Surg Am* 2005; 87: 701-10
- Pagnano MW, Leone J, Lewallen DG, Hanssen AD. Two-incision THA had modest outcomes and some substantial complications. *Clin Orthop Relat Res* 2005; 441: 86-90
- Palieri G, Vetrano M, Mangone M, Cereti M, Bemporad J, Roselli G, D'Arrigo C, Speranza A, Vulpiani MC, Ferretti A. Surgical access and damage extent after total hip arthroplasty influence early gait pattern and guide rehabilitation treatment. *Eur J Phys Rehabil Med.* 2011 Mar; 47(1): 9-17. Epub 2010 Oct 8
- Peters CL, McPherson E, Jackson JD, et al. Reduction in early dislocation rate with large-diameter femoral heads un primary total hip arthroplasty. *J Arthroplasty* 2007; 22 (6 Suppl-2) 140-4
- Pospischill M, Kranzl A, Attwenger B, Knahr K. Minimally invasive compared with traditional transgluteal approach for total hip arthroplasty: a comparative gait analysis. *J Bone Joint Surg Am.* 2010 Feb; 92(2): 328-37
- Procyk S. Initial results with a mini-posterior approach for total hip arthroplasty. *Int Orthop.* 2007 Aug; 31 Suppl 1: S17-20
- Roy L, Laflamme GY, Carrier M, Kim PR, Leduc S. A randomised clinical trial comparing minimally invasive surgery to conventional approach for endoprosthesis in elderly patients with hip fractures. *Injury.* 2010 Apr; 41(4): 365-9. Epub 2009 Nov 1
- Sariali E, Leonard P, Marnoudy P. Dislocation after total hip arthroplasty using Hueter anterior approach. *J Arthroplasty* 2008; 23: 266-72
- Sculco TP, Boettner F. Minimally invasive total hip arthroplasty: the posterior approach. *Instr Course Lect.* 2006; 55: 205-14

- Sculco TP. Minimally invasive total hip arthroplasty. In the affirmative. *J Arthroplasty* 2004; 19 (4 Suppl 1): 78-80
- Seng BE, Berend KR, Ajluni AF, Lombardi AV Jr. Anterior-supine minimally invasive total hip arthroplasty: defining the learning curve. *Orthop Clin North Am.* 2009 Jul; 40(3): 343-50
- Siguiier T, Siguiier M, Brumpt B. Mini-incision anterior approach does not increase dislocation rate: a study of 1307 total hip replacement. *Clin Orthop Relat Res* 2004; 426: 164-73
- Stehlík J, Musil D, Held M, Stárek M. Minimally invasive total hip replacement--one-year results. *Acta Chir Orthop Traumatol Cech.* 2008 Aug; 75(4): 262-70
- Sugano N, Takao M, Sakai T, Nishii T, Miki H, Nakamura N. Comparison of mini-incision total hip arthroplasty through an anterior approach and a posterior approach using navigation. *Orthop Clin North Am.* 2009 Jul; 40(3): 365-70
- Tanavalee A, Jaruwannapong S, Yuktanandana P, Itiravivong P. Early outcomes following minimally invasive total hip arthroplasty using a two-incision approach versus a mini-posterior approach. *Hip Int* 2006; 16 Suppl 4: 17-22
- Vail TP, Callaghan JJ. Minimal incision total hip arthroplasty. *J Am Acad Orthop Surg.* 2007 Dec; 15(12): 707-15
- Varela Egocheaga JR, Suárez-Suárez MÁ, Fernández-Villán M, González-Sastre V, Varela-Gómez JR, Murcia-Mazón A. Minimally invasive posterior approach in total hip arthroplasty. Prospective randomised trial. *An Sist Sanit Navar.* 2010 May-Aug; 33(2): 133-43
- Waldman BJ. Advancements in minimally invasive total hip arthroplasty. *Orthopaedics* 2003; 26 (8 Suppl): s 833-6
- Wojciechowski O, Kusz D, Kopec K et al. Minimally invasive approaches in total hip arthroplasty. *Orthop Traumatol Rehabil* 2007; 9(1): 1-7
- Zati A, Degli Esposti S, Spagnoletti C et al (1997) Does total hip arthroplasty mean sensorial and proprioceptive lesion? A clinical study. *Chir Organi Mov* 82(3): 239-247

IntechOpen



Recent Advances in Hip and Knee Arthroplasty

Edited by Dr. Samo Fokter

ISBN 978-953-307-841-0

Hard cover, 452 pages

Publisher InTech

Published online 27, January, 2012

Published in print edition January, 2012

The purpose of this book is to offer an exhaustive overview of the recent insights into the state-of-the-art in most performed arthroplasties of large joints of lower extremities. The treatment options in degenerative joint disease have evolved very quickly. Many surgical procedures are quite different today than they were only five years ago. In an effort to be comprehensive, this book addresses hip arthroplasty with special emphasis on evolving minimally invasive surgical techniques. Some challenging topics in hip arthroplasty are covered in an additional section. Particular attention is given to different designs of knee endoprotheses and soft tissue balance. Special situations in knee arthroplasty are covered in a special section. Recent advances in computer technology created the possibility for the routine use of navigation in knee arthroplasty and this remarkable success is covered in depth as well. Each chapter includes current philosophies, techniques, and an extensive review of the literature.

How to reference

In order to correctly reference this scholarly work, feel free to copy and paste the following:

Antonio Silvestre, Fernando Almeida, Pablo Renovell, Raúl López, Laura Pino and Luis Puertes (2012). Why Minimally Invasive Surgery in Hip Arthroplasty?, Recent Advances in Hip and Knee Arthroplasty, Dr. Samo Fokter (Ed.), ISBN: 978-953-307-841-0, InTech, Available from: <http://www.intechopen.com/books/recent-advances-in-hip-and-knee-arthroplasty/why-minimally-invasive-surgery-in-hip-arthroplasty->

INTECH
open science | open minds

InTech Europe

University Campus STeP Ri
Slavka Krautzeka 83/A
51000 Rijeka, Croatia
Phone: +385 (51) 770 447
Fax: +385 (51) 686 166
www.intechopen.com

InTech China

Unit 405, Office Block, Hotel Equatorial Shanghai
No.65, Yan An Road (West), Shanghai, 200040, China
中国上海市延安西路65号上海国际贵都大饭店办公楼405单元
Phone: +86-21-62489820
Fax: +86-21-62489821

© 2012 The Author(s). Licensee IntechOpen. This is an open access article distributed under the terms of the [Creative Commons Attribution 3.0 License](https://creativecommons.org/licenses/by/3.0/), which permits unrestricted use, distribution, and reproduction in any medium, provided the original work is properly cited.

IntechOpen

IntechOpen