

# We are IntechOpen, the world's leading publisher of Open Access books Built by scientists, for scientists

6,900

Open access books available

185,000

International authors and editors

200M

Downloads

Our authors are among the

154

Countries delivered to

TOP 1%

most cited scientists

12.2%

Contributors from top 500 universities



WEB OF SCIENCE™

Selection of our books indexed in the Book Citation Index  
in Web of Science™ Core Collection (BKCI)

Interested in publishing with us?  
Contact [book.department@intechopen.com](mailto:book.department@intechopen.com)

Numbers displayed above are based on latest data collected.  
For more information visit [www.intechopen.com](http://www.intechopen.com)



## Hip Arthroplasty

N. A. Sandiford<sup>1</sup>, U. Alao<sup>1</sup>, J. A. Skinner<sup>2</sup> and S. R. Samsani<sup>3</sup>

<sup>1</sup>*Specialist Registrar, Kent and Sussex Hospital, Mount Ephraim,  
Tunbridge Wells, Kent*

<sup>2</sup>*Consultant Orthopaedic surgeon Royal National Orthopaedic  
Hospital Brockley Hill, Stanmore*

<sup>3</sup>*Consultant Orthopaedic surgeon, Medway Maritime Hospital,  
Windmill Road, Gillingham, Kent  
United Kingdom*

### 1. Introduction

#### 1.1 History

Total Hip Arthroplasty (THA) has been hailed the 'The operation of the century.' (1) While the prevalence of coxarthrosis is relatively unchanged from ancient times, attempt at surgical treatment are relatively recent Themistocles Gluck is credited with performing the first hip arthroplasty in Germany in 1891. It was a hemi arthroplasty and he used an ivory femoral head. Early attempts at the turn of the 20<sup>th</sup> century focused on interpositional arthroplasty using a variety of tissues which included skin, fascia lata, and pig's bladder (1)! Also during this period Dr Ban saw, then chief of orthopaedics at the Mandalay General hospital in Burma, used hand made ivory components for patients with femoral neck fractures. He presented a report of his first 300 cases in 1969. His patients were aged between 24 and 87 years old. Eighty eight per cent returned to sports and bicycle riding within weeks post surgery.

The dawn of the modern era of hip arthroplasty was heralded by the vitallium mould design of Smith-Petersen. Wiles subsequently developed and inserted the first THA in 1938 in the UK.

The next most significant step was made by British surgeon Sir John Charnley. In the 1960's he introduced several pivotal concepts including the low friction arthroplasty, the use of polymethyl methacrylate cement as a grout and the use of high density polyethylene as a bearing surface. While several of Charnley's principles and techniques have evolved, the principles he proposed remain relatively unchallenged.

Arguably the most important modern advancement in arthroplasty surgery has been the establishment of joint registries. These provide invaluable data on survival, complications and can help to establish standards for practice. The Swedish joint registry is the most established of these. Much of the long term survival data for specific types of implants and fixation methods are extracted from this database. Registries are now in existence in most countries including the UK. The American Joint Replacement Registry (AJRR) is currently in the process of being formalised.

## 2. Indications

The main indication for total hip arthroplasty is pain secondary to primary or secondary osteoarthritis (2), and has remained largely unchanged for the past few decades. Results from the Swedish Registry show the mean age for THR was about 70 years old with a decrease in age seen in men while an increase was noted in women. Recent trends have seen a widening of the indications for performing total hip arthroplasty to include rheumatoid arthritis in cases of failed medical management. Such patients are often younger compared with elderly patients who commonly present with osteoarthritis and trauma (2). Other indications include avascular necrosis, metastatic disease and ankylosing spondylitis.

The use of total hip arthroplasty in treating femoral neck fractures has, and continues to generate controversy. There is a move towards basing the surgical management on patient-related, rather than diagnosis related approach as a reflection of this heterogeneous group of patients. For example, fit elderly patients with pre-existing symptomatic osteoarthritis who sustain a femoral neck fracture should be considered for total hip arthroplasty rather than internal fixation.

There are a number of studies that support this approach. Blomfeldt et al (3) conducted a randomised control trial comparing the outcome of patients with displaced neck of femur fractures, who are relatively fit, active and indecently mobile, treated with internal fixation or total hip arthroplasty. They treated one hundred and two patients with a mean age of eighty years. Forty nine patients were randomised to THR and fifty three underwent internal fixation. Their results showed similar mortality rate of 25% at four year follow-up but a better functional outcome, lower complication and re-operation rate in the total hip arthroplasty group compared to the internal fixation group. Another randomized prospective trial involving two hundred and seven patients by Keating et al (4), treated patients with internal fixation, hemiarthroplasty and total hip arthroplasty. Their results showed better functional outcome in the THA group in comparison to the other groups. Cost analysis also showed a higher rate for the internal fixation group due to higher re-operation rate but no difference between the THR group and hemiarthroplasty group.

## 3. Patient expectations

The widening indications for surgery have influenced the demographics of patients undergoing total hip arthroplasty and thus, their expectations. More and more young patients are being considered for total hip arthroplasty. These subgroups of patients generally tend to be very active and as result place more demands on the replaced hip. Even the modern day 'elderly' patient has higher expectations in comparison to previous decades as patients are offered surgery far earlier owing to improvement in technology and surgical technique. This emphasis on meeting patient's expectation and optimizing subsequent function has led to objective scoring systems such as the Oxford Hip Score (OHS), Harris Hip Scores (HHS), the Western Ontario and McMaster University (WOMAC) scoring systems being developed and more recently in the UK patient related outcome measures. A study by Mancuso et al looking at the fulfilment of patient's expectation showed that only 43% patients (of 405) thought their pre-operative expectations were fulfilled fully. They showed that younger patients and those with a BMI of lower than 35kg/m<sup>2</sup> had a greater proportion of their expectations fulfilled (5).

The modern day THR, however, patient is more likely to be obese compared to previous generations and may develop early failure as a result. However, advances in implant design and tribology have increased the Orthopaedic Surgeon's armamentarium in facing these challenges.

#### 4. Surgical technique

While the ideal approach for THA is as yet undecided, several approaches have been described and are used in routine practice. While no revolutionary changes have been made to the classically described techniques, significant refinements and advances have occurred particularly with the development of minimally invasive approaches for THA and the instruments to facilitate these approaches.

Previous techniques described include the lateral (Hardinge) (6), anterior (Smith-Petersen) (7), posterior (Moore or southern) and medial approaches (8), each with its unique risks and benefits. The approach most commonly used in the UK is the posterior (57%) followed by the anterolateral approach (37%) according to the United Kingdom National Joint Registry (UK NJR) (9). Personal communication with members of the British Hip Society has revealed that the posterior approach is favoured by the majority of specialist hip surgeons.

Results from the Swedish Arthroplasty Register (10) have suggested that the posterior approach is being performed less frequently (52% in 2008 vs 65% in 1992) likely due to an increased incidence of dislocation particularly with the minimally invasive posterior approach. The surgical approach used in our unit is the posterior approach which is described below after a description of the original procedure:

This approach, popularised by Moore, is also called the southern approach. It consists of a 10-15 cm incision centered on the posterior aspect of the greater trochanter. This is deepened through the fascia lata. The gluteus maximus is split along the line of the incision. This along with internal rotation of the hip allows visualisation of the common insertion of the short external rotators on the posterior aspect of the proximal femur. Also visible is a layer of fat which contains the sciatic nerve at its center. This must be protected. Internally rotating the hip moves this nerve out of the operative field.

Once the tendons are identified, stay sutures are placed in the tendons of the piriformis and obturator internus. These are then detached from the femur at their point of attachment. Deep to this layer is the posterior capsule. Once this is incised further internal rotation will lead to dislocation of the hip joint. Repair of the posterior structures is not routinely recommended with this description.

Early criticism of the posterior approach stemmed from several reports of higher dislocation rates in patients treated with this technique (11, 12). Many authors using this contemporary posterior approach have recorded very low dislocation rates and addition of posterior capsular repair has reduced the dislocation rates to <2% (13). Also when compared to the lateral approach, the incidence of postoperative abductor lurch is very low with posterior approach.

#### 5. Dislocation rates

Despite early reports, studies over the last decade have shown that the incidence of dislocation decreases substantially if a posterior capsular repair is performed.

Masonis and Bourne (14) reviewed fourteen studies comprising 13,203 patients. Overall there was a six times increased rate of dislocation in patients treated with a posterior approach when compared to the trans trochanteric, anterolateral and direct lateral approaches. In the group which had a posterior approach dislocation rates among those patients who had a capsular repair was 2.03% compared to 3.95% in the group which had no repair performed. These results were pooled from multiple surgeons however and such heterogeneity has been associated with poor results, particularly among junior surgeons (15).

In a well designed single surgeon series Wilson et al (16) showed that dislocation rates reduced from 3.1% to 0.7% after a posterior repair was performed. Similar results have been reported by other authors (17, 18, 19) including Suh et al who reported that repair of the posterior structures reduced their dislocation rates in revision THA from 10% to 1.9% (13). These results are summarised in Table 1.

Authors	Date	Number in study	Dislocation rates related to approach			
			Posterior	Anterolateral	Posterior with repair	Direct Lateral
Palan et al	2009 (Prospective)	1089	2.3%	2.1%	–	–
Tsai et al	2008 (Retrospective)	204	6.38%	–	0%	–
Kwon et al	2006 (meta analysis)	–	4.46%	0.75	0.49%	0.43%
Wilson et al	2005 (Retrospective)	2213	3.9%	–	0.9%	–
Suh et al	2004 (Prospective)	346	6.4%	–	1%	–
Masonis and Bourne	2002 (Review)	13,203	3.95%	2.18	2.03	0.55

Table 1. Dislocation rates after the posterior approach- Summary of results

6. Our current technique (figures 1-5)

In our unit the posterior approach is used for both primary and revision THA. For primary THA a minimally invasive technique is routinely performed and is described below. The patient is placed in a lateral decubitus position. The tip of the greater trochanter and the posterior boarder of the proximal femur are identified. A 10 to 12cm incision centered on the posterior one third of the tip of the greater trochanter is made which extends 5cm above and 5cm below this point. The incision proximal to the greater trochanter is angled backwards by 30 to 40 degrees. The incision is deepened to the level of the fascia lata which is also incised. The gluteus maximus is split along the line of the incision revealing the trochanteric bursa which is divided in line with the incision but preserved. Internal rotation of the hip at this stage brings the posterior aspect of the greater trochanter with its attached short external rotators into the operative field. At this stage we use a gauze swab to wipe the bursal tissue and fat off of the short external rotators (SER) attachment gently downward. This action exposes the tendons of short external rotators- from proximal to distal piriformis, superior gemellus, obturator internus, inferior gemellus and quadratus femoris- and moves the sciatic nerve away from the operative field. Next superior border piriformis tendon is identified and a curved retractor is placed under the gluteus minimus but above the superior border of piriformis tendon. Stay sutures are placed in the common tendon of the SER muscles and the underlying capsule (Figure 3). The short external rotators, along with posterior capsule, is then divided with diathermy at its point of attachment to the greater trochanter. Then posterior dislocation of the hip is performed by adduction, flexion



and internal rotation of femur. Once the procedure is completed the short external rotators and the capsule is reattached via drill holes to the posterior part of greater trochanter.

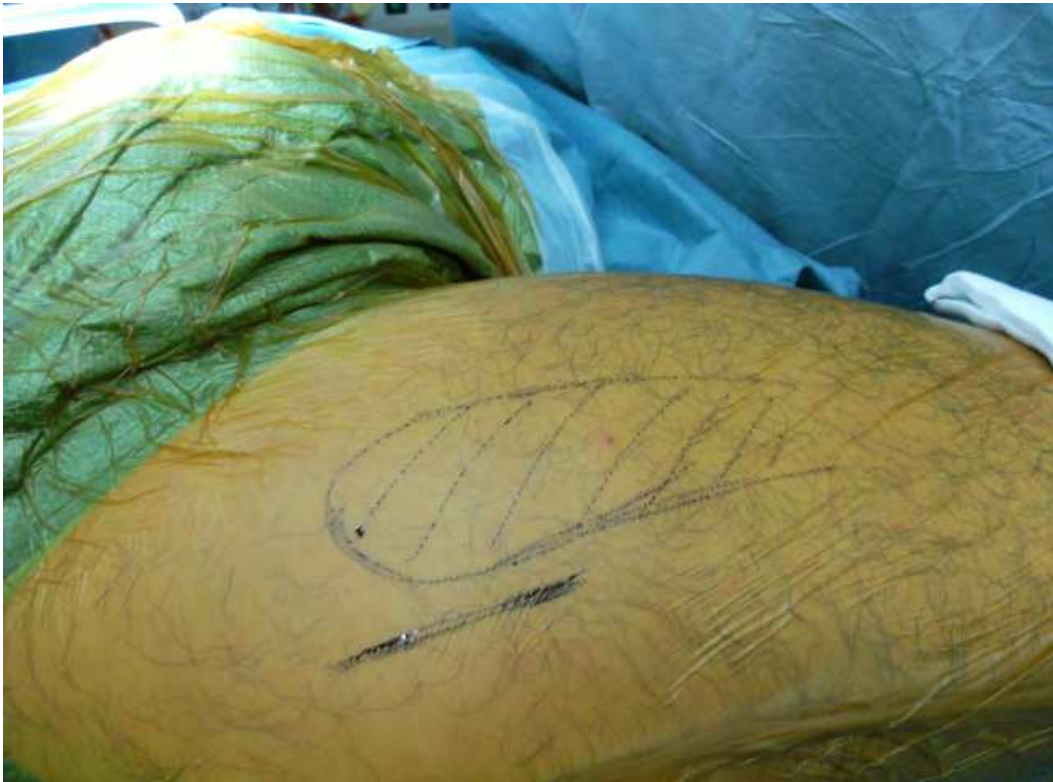

Fig. 1. Landmarks for the skin incision

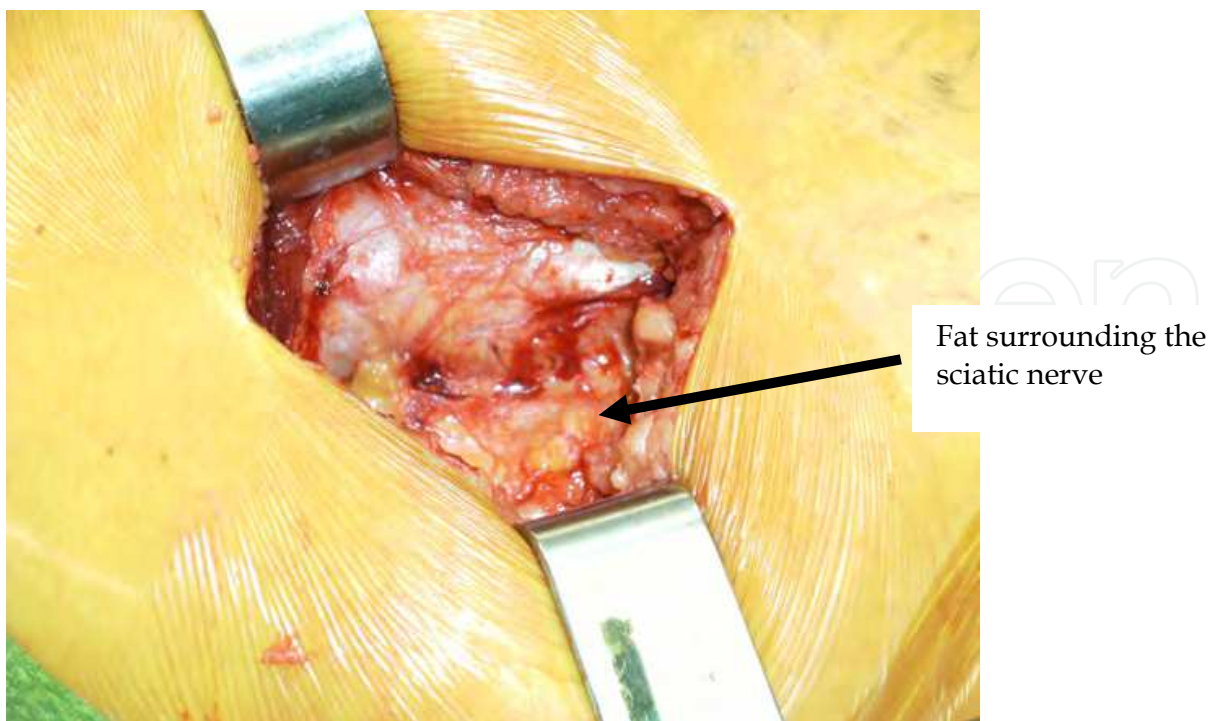


Fig. 2. Fat and bursa moved away from operative field. This protects the sciatic nerve.

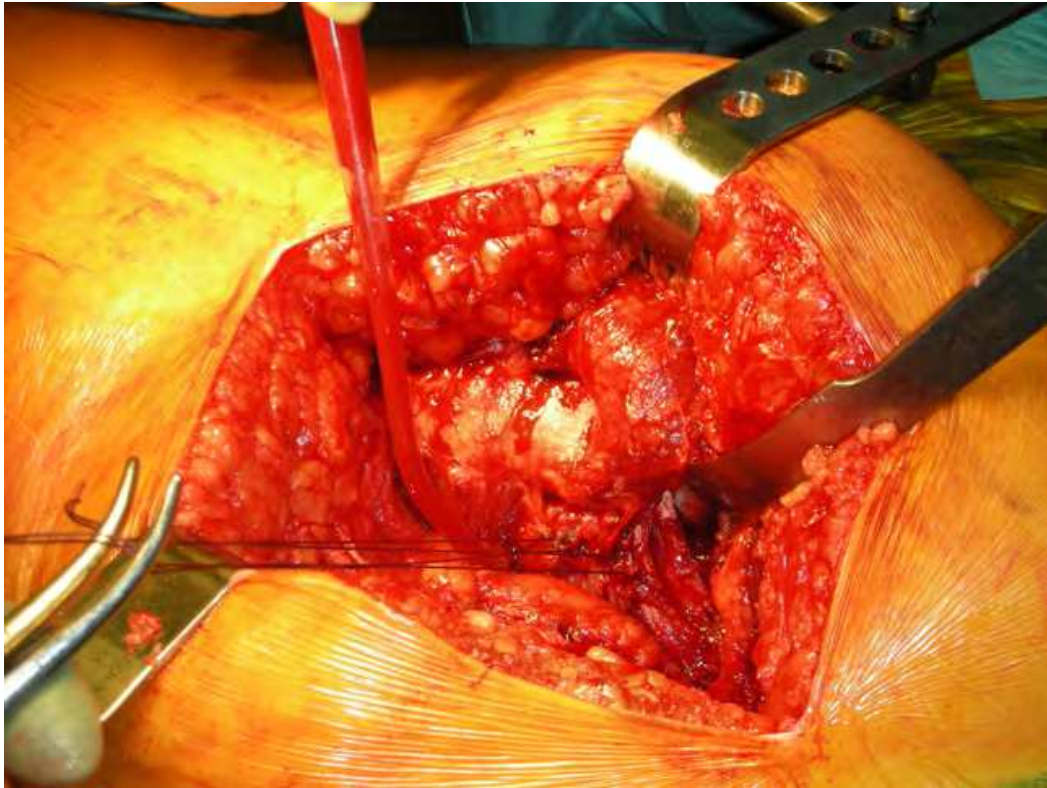


Fig. 3. Stay sutures in the short external rotator (SER) tendons

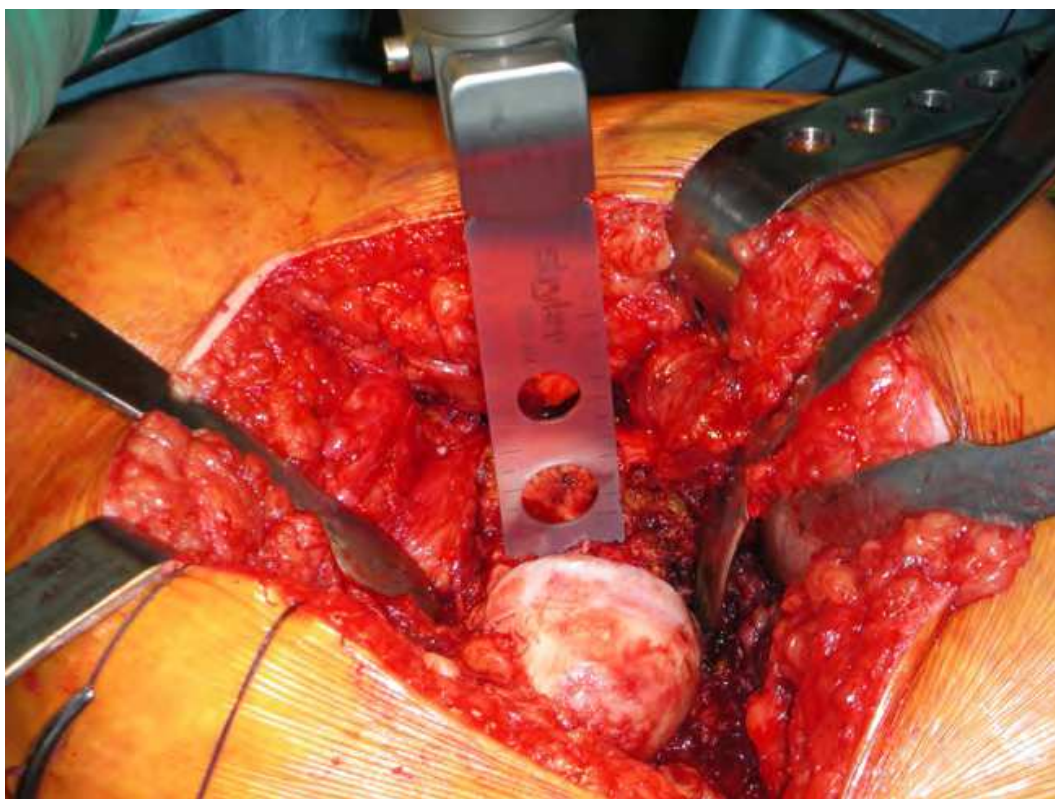


Fig. 4. Dislocated femoral head



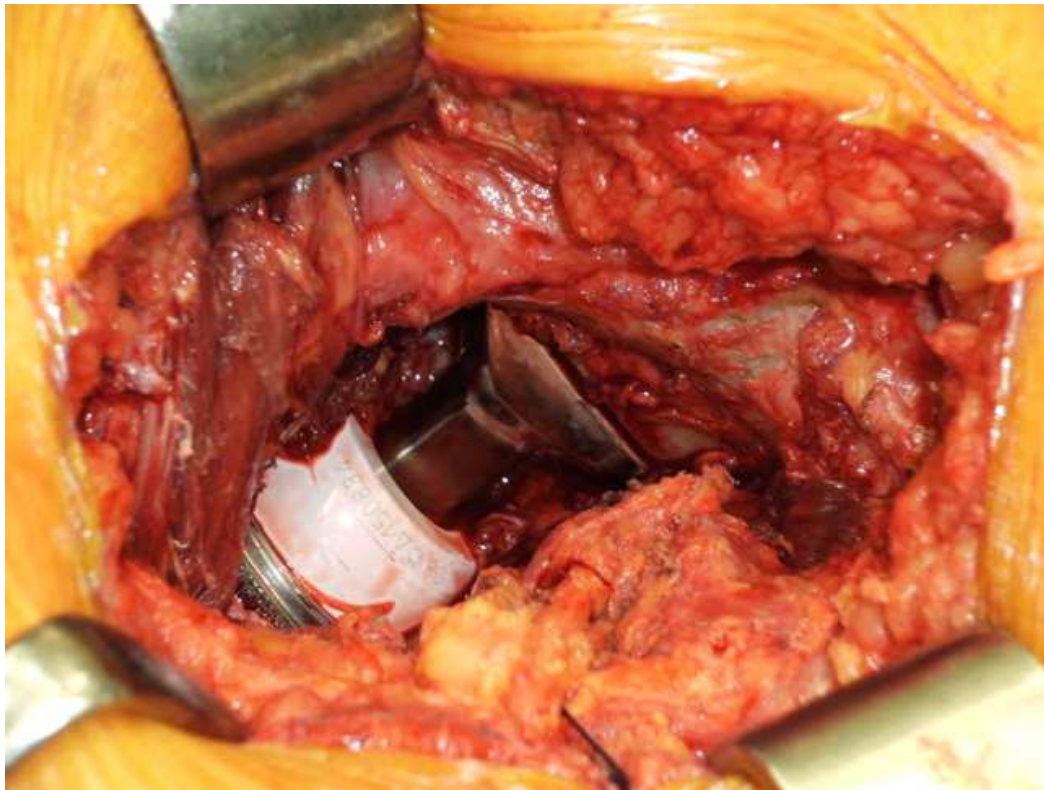


Fig. 5. Post reduction of THA

## 7. Minimally Invasive Surgical (MIS) approaches

Over the last decade minimally invasive techniques have drawn much attention. These methods represent a refinement rather than a revolution of standard approaches. They have been described for the anterior, posterior and lateral approaches. By definition a minimally invasive approach infers an incision length of  $\leq 10$ cm.

Views and conclusions about MIS THA are conflicting but overall this is accepted as safe, but not better nor a replacement for established surgical approaches. This view is supported by level I evidence. In the UK the National Institute for Health and Clinical Evidence has recommended that the MIS posterior approach is safe but the Swedish Registry suggests that there is an increased incidence of dislocations with this approach which accounts for its decreasing use.

MIS THA has been extensively studied in the literature. Dorr et al (20) showed that while immediate post operative pain control and mobility were improved in the MIS group, there was no difference between this group and those in whom a conventional approach was used at 6 weeks and beyond. Recent level 1 evidence (21) has revealed that when comparing the MIS anterolateral, classic posterior and MIS posterior approaches found similar results. This study also found that patients who had the posterior MIS approach had favourable outcomes when compared to the MIS anterolateral approach. Pagnano et al (22) also found that patients receiving the posterior MIS approach walked, achieved independence from assistive devices and returned to activities of daily living before those treated using a 2 incision approach.

While opinions on the clinical benefits of MIS THA seem to be in agreement, these differ on the overall benefits of this approach. Reininga et al (23) in their review, concluded that MIS



THA is a safe procedure although there is no firm evidence of functional benefit. Smith et al (24) reviewed 2849 hips, however, and found a significantly elevated risk of transient lateral femoral cutaneous nerve palsy in the group treated with the MIS technique, again with no functional benefits.

What has not been clarified in this area is the 'ideal' MIS approach, whether specialised instruments help, the group of patients best suited for this procedure and the learning curve for this technique.

## 8. Technology

A number of advances have been made since Sir John Charnley pioneered the Low Friction Arthroplasty in the 1960s. His design consisted of a stainless steel mono polar femoral stem and a polyethylene acetabular cup both fixed using polymethyl methacrylate bone cement. There are currently more than 100 hip stems and cups respectively submitted to the Orthopaedic Data Evaluation Panel (ODEP) for assessment, all of which has variable designs and choices of bearing surfaces.

The National Institute of Clinical Excellence (NICE) which issues guidance on selection of prosthesis advises that the best prosthesis should have a revision rate of 10% or less at ten years, demonstrable by long term viability studies. Cemented prosthesis has the longest viability studies but a number of uncemented prosthesis have passed the ten year mark with good results.

The trend is to use cemented prosthesis in elderly patients with poor bone quality, while uncemented stems are more commonly used in younger more active patients or those with good bone quality in general.

Well fixed cemented components depend primarily on two interfaces; implant cement interface and cement-bone interface. Adequate fixation of both interfaces is crucial to the long term survival of the prosthesis as the load is transmitted via the prosthesis to the cement-bone interface. Any weakness in either may lead to early failure. Considerable advancement has been made from the first generation cementing technique (finger packing, no cement gun, no cement restrictor or canal pressurization) to the third generation (elimination of air bubbles via vacuum preparation, stem centralizer and femoral canal pressurization) thus improving the stability of well fixed cemented implants. In addition, modern day cemented stems are modular, allowing for a range of femoral heads to be fixed for optimal soft tissue balancing and stability.

Uncemented implants coated with hydroxyapatite have either porous coated or grit-blasted surfaces and depend on 'biologic' fixation of bone by bony interdigitation into the stem. A well fixed uncemented stem requires cortical seating into the femoral canal. Some uncemented acetabular implants offer added security of screw fixation for improved stability.

## 9. Bearing surfaces

An ideal bearing surface has the following characteristics. (25)

1. low coefficient of friction
2. resistant to third body damage and wear
3. generates small amount of particles
4. has low cellular reaction to wear debris

A variety of significant advancements in bearing surfaces has been made since the dawn of modern era of hip arthroplasty. Figure 6 outlines the major advances. Bearing surfaces can be split into two broad groups:

- 1. Hard on soft bearings
- 2. Hard on hard bearings

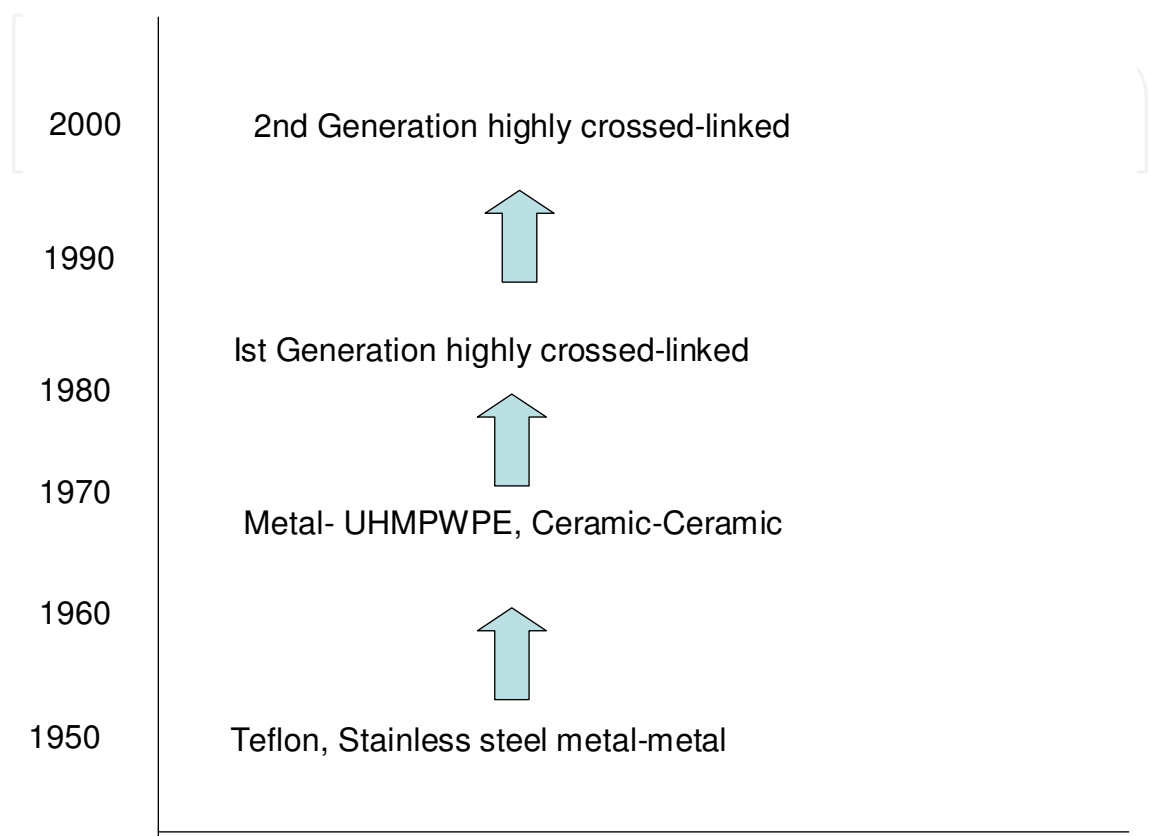


Fig. 6. Major advances in bearing surfaces.

10. Hard on soft bearings

The ultra high molecular weight polyethylene (UHMWPE) acetabular cup was introduced in 1962 coupled with metallic heads to form hard-on-soft bearing surface. UHMWPE consists of several long chains of monomer ethylene which serves to transfer load more effectively to the polymer backbone by strengthening intermolecular interactions. Early wear was a major problem with the early prostheses, particularly with larger bearing surfaces. The third body particle thus generated enters the effective joint space and stimulates a foreign body response resulting in osteolysis which is mainly mediated by macrophages (26). PE wear is related to three main factors; implant geometry and material properties, sterilization and shelf-life. Initially, it was widely accepted that the osteolysis was due to delayed reaction to bone cement (PMMA), this erroneous belief lead to the development of uncemented prosthesis such as the Austin Moore prosthesis. This change did not positively affect the wear profile of the PE cup.

One of the best advances to UHMPE liner use was the advent of highly crossed linked PE liner introduced in 1998. This is achieved by low dose gamma or electron beam radiation

and thermal treatment to increase their oxidation resistance. Its advantages include increasing resistance to abrasive and adhesive wear thereby improving bearing wear rates. Another example of a hard-on-soft surface is ceramic on PE but is not a widely used combination.

## 11. Hard on hard bearings

Wear-particle related osteolysis around THA components and subsequent failure rates lead to the development of other bearing surfaces such as metal-on-metal articulations. Cobalt-Chrome is the commonest metal alloy used. One of the main theoretical advantages of hard on hard bearing surfaces is reduction in osteolysis (27) by generating less wear particles. In addition, the particle size generated is also smaller (0.015-0.12µm) compared to the particle size range (0.2-7µm) that has been shown to trigger osteolysis. The first generation metal-on-metal hip arthroplasty showed a low rate of wear and long term results demonstrated that failure was due implant design rather than wear particles (28).

Other advantages of metal on metal surfaces include a higher scratch resistance and larger bearing components which increases the excursion distance, the distance needed to travel before the neck impinges and dislocate, due to the increase in head to neck ratio. This is particularly advantageous in revision surgery for dislocation.

Metal on metal bearings, however, are not completely biologically inert. A number of soft tissue reactions have limited its use. These include metallosis and aseptic lymphocytic vasculitis associated response (ALVAL). There is an increased risk for these adverse tissue reactions in females, smaller femoral head bearings and obesity (29).

Another type of hard on hard surfaces are ceramic bearings, first introduced in the mid 60s. They are harder than metal and have a lower wear rate especially when coupled with its self. In addition, the wear particles generated are biologically inert, eliminating the concerns of soft tissue reactions seen with metal on metal bearings. The main disadvantage, however, is its low resistance to fracture and squeaking, particularly seen in the taller, younger and heavier patients. Like polyethylene bearings, ceramic bearing surfaces have improved since the first generation implants which were more susceptible to fracture.

There are two types of ceramic bearings; alumina and zirconia. Zirconia femoral heads coupled with PE leads to accelerated wear and early failure and is thus not recommended coupling these two components.

## 12. Results

Total hip arthroplasty remains one of most successful operations in terms of cost effectiveness and symptom relief for patients.

The best prosthesis should have a demonstrable long survivorship and low revision rates. These attributes are best shown by National Joint Registries which not only provide early warning of failures but show cumulative experience of surgeons while eliminating potential bias by the innovator. The main goals of national joint registry is three fold; defining the epidemiology of a particular patient population, providing timely information about outcome and identifying risk factors for poor outcomes (30). The Swedish hip registry was the first national joint registry introduced in 1979. Its main goal was to describe the outcomes of primary hip replacements and to report complications. Since its inception, many other countries have started national joint registries. Many of these registries provide



the Orthopaedic community with the results of the oldest and newest prosthesis in the market while keeping track of modifications and innovations.

Charnley's cemented femoral stem has undergone a number of modifications since its inception, including changing from a monoblock to modular stem while retaining the stem geometry. The stem was later modified into the Elite-plus stem (Depuy, Warsaw, Indiana, USA) by undercutting the flange, reducing the diameter and addition of a stem centralizer.

Data for the Swedish hip registry shows favorable results for the original stems; the cohort operated on from 1979 to 1989 had a twenty-one-year survival rate of 81.7% based on 18,607 observations. The more recent cohort, (1990 to 2000), had a ten-year survival rate of 93% based on 20,162 observations (2). Similar results have been reproduced in other centres. Shculte et al showed 90% survivorship of the stem using revision as endpoint in 322 hips (31). The modern day Charnley Elite Plus stem also has favourable medium term results as shown in Kim YH et al prospective study in 194 young hips, with a mean age of 49.1 which demonstrated a 12 years survivorship of 99% using revision surgery as end point (32).

The Exeter femoral stem was introduced around the same time as the Charnley prosthesis and has also undergone a number of modifications since its inception. It is a double tapered, highly polished stem. The Swedish hip register showed a 7 year survival of 98.1% in 4,769 implants. While Carrington et al showed 100% and 90.4% for the femoral and acetabular components, respectively at 17 years using aseptic loosening as an endpoint (33).

Some uncemented femoral prosthesis, such as the Furlong hip replacement (Joint replacement Instrumentation limited, London, United Kingdom) also have favourable results. The Furlong stem is titanium, hydroxyapatite ceramic coated stem first introduced in 1985. Good short to medium term results has been reported in literature (34). The longest follow-up in literature is 21yrs which shows comparable results to previously mentioned cemented stems, 97.4% with revision for any reason as endpoint.

The Corail stem is another uncemented stem with long term results. First introduced in 1986, it is tapered HP coated stem made from titanium alloy. Since inception, it had been modified to a collarless stem and recently (2004) the neck was made slimmer and the taper shortened. The Norwegian Hip Registry shows 97% survivorship at 15 years using revision for any cause as endpoint (35).

These comparable results show that both cemented and uncemented stems can achieve good longevity. It is likely that these results do not only reflect good implant design but also increased familiarity with use over the past number of years. Analysis of national hip registries show that most of the implants that fail to pass the 10 year mark or with survivorship of less than 90% tend to do so early (2 to 3 years) or at medium term (5-8 years).

### 13. Current controversies

A review of current orthopaedic literature would reveal many issues of debate and uncertainty. Two issues which currently attract much debate are those of Metal on Metal hip resurfacing (MoM HR) and the subject of thromboprophylaxis after THA. These are discussed below.

#### 13.1 Metal on Metal hip resurfacing (MoM HR)

Resurfacing affected joint surfaces has always intuitively seemed to be correct when contemplating surgery for the arthritic hip joint. The Smith Peterson cup arthroplasty is considered by some the earliest attempt at surface replacement. Charnley in the early 1950's

performed surface replacements using thin shells of Teflon. Good function was briefly restored but severe osteolysis occurred in response to high Teflon wear.

The next main thrust came in 70's after THA with conventional stemmed components had been introduced and took the form of metal femoral components with high density polyethylene sockets. Memorable examples were the ICLH developed in UK by Freeman, Wagner contribution from Germany and the THARIES from the USA. Initial results were again spectacular but failure developed because of the large amounts of polyethylene debris.

The poor results of all these attempts led to the concept of resurfacing being abandoned. A British surgeon, Derek McMinn, aware of how well metal on metal bearing surfaces had performed based on the results of late revision of both McKee Farrar, Stanmore and Ring hips replacements in Birmingham designed a new resurfacing with a metal on metal bearing surface with the metallurgy based on the results that had been learnt from these earlier metal on metal designs.

Contemporary MoM HR was thus pioneered in the UK by McMinn. Improved design, metallurgy and advances in engineering resulted in the design of the Birmingham Hip Resurfacing prosthesis. Original designs have been used in the UK since 1991 and approved by the United States Food and Drug Administration in 2006. Proposed advantages of this prosthesis include improved stability due to its large diameter, improved proprioception, improved range of motion and return to function, bone conservation and relative ease of revision. Early results have been encouraging but data from the UK National Joint Registry (NJR) suggest that MoM HR prostheses have relatively high early failure in certain groups and therefore revision rates. There have been concerns about increases blood levels of cobalt and chromium ions in patients with these prostheses in situ as well as the occurrence of periarticular destructive soft tissue lesions- so called pseudotumors.

Revision of failed MoM HR to stemmed modular MoM THA has also occurred with increasing frequency as a result of the proposed 'ease of revision.' These prostheses pose a new and unique issue to the arthroplasty community as there seems to be concerns with these components which are similar to those for MoM HR. Recent guidance from the British Hip Society (March 2011) has suggested that patients with these components be followed more closely than those with standard THA as the risk of adverse effects seem to be similar to hip resurfacing components. This is currently an area of intense controversy.

### **13.2 Thromboprophylaxis after THA**

This is the 2<sup>nd</sup> area of significant controversy with unique issues in the UK and USA. This issue creates such debate that we have presented a brief review of current evidence before discussing the controversy surrounding it.

### **13.3 Deep vein thrombosis (DVT) and Pulmonary embolism (PE) after THA**

The incidence of radiologically detected DVT after lower limb arthroplasty surgery is 30-60% (for the entire limb) and 10-20% for proximal segment veins. Symptomatic PE occurs in 1-2% of this group (36). The rate of fatal PE is 0.1-0.2% (37). Risk factors for DVT and PE include obesity, American Society of Anaesthesiologist's grade 3 or above, revision surgery, dementia and renal and cardiovascular disease.

A meta analysis of DVT prophylaxis regimens found that the rate of DVT's increased 2-3 fold if no thromboprophylaxis was used. The lowest rates of proximal DVT's occurred when warfarin and low molecular weight heparin (LMWH) were used. The incidence of symptomatic PE's was decreased by warfarin, pneumatic compression devices (PCD's) and

LMWH. The rate of fatal PE was unaffected. Major bleeding occurred in patients who received low dose heparin (38). This review concluded that warfarin was the best overall single agent.

When used as part of a multimodal approach aspirin has been found to have the same efficacy as warfarin (39). Multimodal approaches address each aspect of Virchow's Triad. It includes the use of regional anaesthesia, PCD's, chemical agents and early patient mobilisation. This approach has reduced the rate of asymptomatic and symptomatic DVT to 5.2% and 0.4% respectively (20). These authors found that patients on warfarin had a significantly increased incidence of wound haematomas compared to those on aspirin. Sharrock et al (40) reviewed >15000 patients and found a higher all cause mortality and increased incidence of non fatal PE's in those receiving contemporary potent anticoagulants (including LMWH, Fondaparinux and Rivaroxiban) and Warfarin than groups who received multimodal therapy.

This evidence seems to suggest that potent anticoagulants are not ideal in patients undergoing THA and conflicts with national guidance in the United Kingdom. It must be emphasized that patients should undergo pre operative assessment prior to a decision on the choice of thromboprophylaxis agent is made.

## 14. United Kingdom

A House of Commons Select Committee Report 2004- 2005 suggested that 2500 preventable deaths occurred annually as a result of deep venous thrombosis (DVT). It led to the publication of guidance by the National Institute for Health and Clinical Excellence (NICE) on thromboprophylaxis after THA in 2007. Challenges to these guidelines have arisen and include:

- The mortality figures stated in the parliamentary white paper have overestimated the number of deaths
- Using DVT as a surrogate end point for fatal PE has contributed to this inaccuracy
- Members of the guidance committee were linked to the pharmaceutical industry
- Recent evidence has suggested that since the implementation of these guidelines, both the amount and duration of pharmacological prophylaxis has increased along with the incidence of DVTs and their complications (41).

## 15. United States

In 2004, the American College of Chest Physicians (ACCP) made several recommendations for prevention of DVTs and pulmonary embolism which extended to include the orthopaedic community. The recommendations included aggressive prophylaxis regimens, but were based on the incidence of venographically detected DVTs and used this as a 'surrogate' for fatal pulmonary emboli. In their review process, the ACCP did not consider death and fatal PE as suitable end-points.

Subsequent to the implementation of their guidelines, several centres reported increases in their incidences of major complications, symptomatic DVT, PE, wound problems and re-operation rates, post THA (42).

These reports led to the development of separate guidelines by the American Academy of Orthopaedic Surgeons taskforce in 2006. This group shows prevention of symptomatic PE as



opposed to reduction of prevalence of DVT as their end-point. Their guidelines have been considered to be much more relevant, and safer, for orthopaedic patients.

This issue is still unresolved in both regions and continues to elicit debate.

## 16. Conclusion

In summary, total hip arthroplasty is a highly successful procedure in decreasing pain and improving activity across all age groups, genders and geographic regions. Patient expectations and demands have increase since the advent of the first generation THA but technological advancement is constantly trying to meet this demand. However, there will continue to be controversies regarding the 'ideal' prosthesis, bearing surface and method of fixation. Such controversies may encourage further technical and technological innovations as well as an improved understanding of peri-operative issues such as the optimal method of VTE prophylaxis.

Overall, THA will continue to be a highly successful procedure.

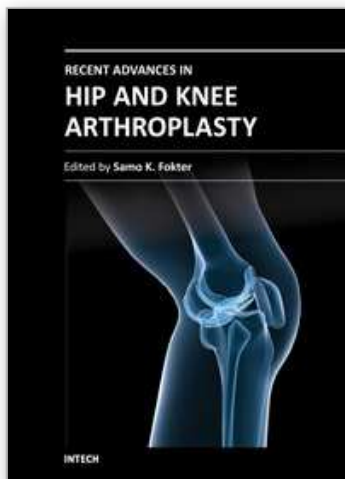
## 17. References

- [1] Learmonth ID, Young C, Rorabeck C. The operation of the century: total hip replacement. *Lancet*. 2007 Oct 27; 370(9597):1508-19.
- [2] Henrik Malchau, Peter Herberts, Thomas Eisler, Göran Garellick and Peter Söderman. The Swedish total hip replacement register. *J Bone Joint Surg Am*. 2002; 84:2-20.
- [3] Blomfeldt R, Törnkvist H, Eriksson K, Söderqvist A, Ponzer S, Tidermark J. A randomised controlled trial comparing bipolar hemiarthroplasty with total hip replacement for displaced intracapsular fractures of the femoral neck in elderly patients. *J Bone Joint Surg Br*. 2007 Feb; 89(2):160-5.
- [4] Keating JF, Grant A, Masson M, Scott NW, Forbes JF. Randomized comparison of reduction and fixation, bipolar hemiarthroplasty, and total hip arthroplasty. Treatment of displaced intracapsular hip fractures in healthy older patients. *J Bone Joint Surg Am*. 2006 Feb; 88(2):249-60.
- [5] Mancuso CA, Jout J, Salvati EA, Sculco TP. Fulfilment of patient's expectation for total hip arthroplasty. *J Bone Joint Surg Am*. 2009; 91:2073-2078
- [6] Hardinge K. The direct lateral approach to the hip. *J Bone Joint Surg Br*. 1982; 64(1):17-9
- [7] SMITH-PETERSEN MN. Approach to and exposure of the hip joint for mold arthroplasty. *J Bone Joint Surg Am*. 1949 Jan; 31A (1):40-6.
- [8] Hoppenfeld S, de Boer P. *Surgical Exposures in Orthopaedics: The Anatomical Approach*. 3<sup>rd</sup> Ed. Philadelphia, PA: Lippincott, Williams and Wilkins; 2003.
- [9] <http://www-new.njrcentre.org.uk/njrcentre/Default.aspx>
- [10] <http://www.jru.orthop.gu.se/>
- [11] Mallory TH, Lombardi AV Jr, Fada RA, Herrington SM, Eberle RW. Dislocation after total hip arthroplasty using the anterolateral abductor split approach. *Clin Orthop Relat Res*. 1999 Jan; (358):166-72.
- [12] Ritter MA, Harty LD, Keating ME, Faris PM, Meding JB. A clinical comparison of the anterolateral and posterolateral approaches to the hip. *Clin Orthop Relat Res*. 2001 Apr; (385): 95-9.

- [13] Suh KT, Roh HL, Moon KP, Shin JK, Lee JS. Posterior approach with posterior soft tissue repair in revision total hip arthroplasty. *J Arthroplasty*. 2008 Dec; 23 (8):1197-203. Epub 2008 Mar 4.
- [14] Masonis JL, Bourne RB. Surgical approach, abductor function, and total hip arthroplasty dislocation. *Clin Orthop Relat Res*. 2002 Dec;(405):46-53.
- [15] Unwin AJ, Thomas M. Dislocation after hemiarthroplasty of the hip: a comparison of the dislocation rate after posterior and lateral approaches to the hip. *Ann R Coll Surg Engl*. 1994 Sep;76(5):327-9.
- [16] R K Wilson; B Mohan; and D E Beverland. REPAIR OF THE SHORT EXTERNAL ROTATORS FOLLOWING POSTERIOR APPROACH TO TOTAL HIP REPLACEMENT AND ITS EFFECT ON DISLOCATION RATE. *Journal of Bone and Joint Surgery - British Volume*, Vol 87-B, Issue SUPP\_III, 268.
- [17] Kwon MS, Kuskowski M, Mulhall KJ, Macaulay W, Brown TE, Saleh KJ. Does surgical approach affect total hip arthroplasty dislocation rates? *Clin Orthop Relat Res*. 2006 Jun;447:34-8.
- [18] Suh KT, Park BG, Choi YJ. A posterior approach to primary total hip arthroplasty with soft tissue repair. *Clin Orthop Relat Res*. 2004 Jan;(418):162-7.
- [19] Van Stralen GM, Struben PJ, van Loon CJ. The incidence of dislocation after primary total hip arthroplasty using posterior approach with posterior soft-tissue repair. *Arch Orthop Trauma Surg*. 2003 Jun;123(5):219-22. Epub 2003 Apr 9.
- [20] Dorr LD, Maheshwari AV, Long WT, Wan Z, Sirianni LE. Early pain relief and function after posterior minimally invasive and conventional total hip arthroplasty. A prospective, randomized, blinded study. *J Bone Joint Surg Am*. 2007 Jun;89(6):1153-60.
- [21] Goosen JH, Kollen BJ, Castelein RM, Kuipers BM, Verheyen CC. Minimally invasive versus classic procedures in total hip arthroplasty: a double-blind randomized controlled trial. *Clin Orthop Relat Res*. 2011 Jan;469(1):200-8. Epub 2010 Mar 30.
- [22] Pagnano MW, Trousdale RT, Meneghini RM, Hanssen AD. Slower recovery after two-incision than mini-posterior-incision total hip arthroplasty. *Surgical technique*. *J Bone Joint Surg Am*. 2009 Mar 1;91 Suppl 2 Pt 1:50-73.
- [23] Reininga IH, Zijlstra W, Wagenmakers R, Boerboom AL, Huijbers BP, Groothoff JW, Bulstra SK, Stevens M. Minimally invasive and computer-navigated total hip arthroplasty: a qualitative and systematic review of the literature. *BMC Musculoskelet Disord*. 2010 May 17;11:92.
- [24] Smith TO, Blake V, Hing CB. Minimally invasive versus conventional exposure for total hip arthroplasty: a systematic review and meta-analysis of clinical and radiological outcomes. *Int Orthop*. 2011 Feb;35(2):173-84. Epub 2010 Jun 18.
- [25] Minakawa H, Stone MH, Wroblewski BM, et al. Quantification of third-body damage and its effect on UHMWPE wear with different types of femoral head. *JBJS Br* 1998; 80-B: 894-9.
- [26] YH Zhu, KY Chiu and WM Tang. Review Article: Polyethylene wear and osteolysis in total hip arthroplasty. *Journal of Orthopaedic Surgery*. Vol. 9 No. 1, June 200, 91-99.
- [27] Michael H. Huo, Javad Parvizi, Nathan F. Gilbert. What's new in hip arthroplasty? *J Bone Joint Surg Am*. 2006; 88:2100-2113

- [28] Schmalzried TP, Peters PC, Maurer BT, Bragdon CR, Harris WH. Long-duration metal-on-metal total hip arthroplasties with low wear of the articulating surfaces. *J Arthroplasty* 1996; 11:322-31.
- [29] Ollivere B, Darrah C, Barker T, Nolan J, Porteous MJ. Early clinical failure of the Birmingham metal-on-metal hip resurfacing is associated with metallosis and soft tissue necrosis. *J Bone Joint Surg [Br]* 2009; 91-B: 1025-30.
- [30] William J. Maloney National Joint Replacement Registries: Has the Time Come? *J Bone Joint Surg Am.* 2001; 83:1582-1585.
- [31] KR Schulte, JJ Callaghan, SS Kelley and RC Johnston. The outcome of Charnley total hip arthroplasty with cement after a minimum twenty-year follow-up. The results of one surgeon. *J Bone Joint Surg Am.* 1993; 75:961-975.
- [32] Kim YH, Kim JS, Yoon SH. Long-term survivorship of the Charnley Elite Plus femoral component in young patients. *J Bone Joint Surg [Br]* 2007; 89-B: 449-54.
- [33] N. C. Carrington, R. J. Sierra, G. A. Gie, M. J. W. Hubble, A. J. Timperley, J. R. Howell. The Exeter Universal cemented femoral component at 15 to 17 years, an update of the first 325 hips. *J Bone Joint Surg [Br]* 2009; 91-B: 730-7.
- [34] Singh S, Trikha SP, Edge AJ. Hydroxyapatite ceramic-coated femoral stems in young patients, a prospective 10 year study. *J Bone Joint Surg [Br]* 2004; 86-B: 1118-23.
- [35] Hallan G, Lie SA, Furnes O, Engesaeter LB, Vollset SE, Havelin LI. Medium- and long-term performance of 11 516 uncemented primary femoral stems from the Norwegian arthroplasty register. *J Bone Joint Surg [Br]* 2007;89-B:1574-80.
- [36] Gillespie W, Murray D, Gregg PJ, Warwick D. Risks and benefits of prophylaxis against venous thromboembolism in orthopaedic surgery. *J Bone Joint Surg Br.* 2000 May;82(4):475-9.
- [37] Murray DW, Britton AR, Bulstrode CJ. Thromboprophylaxis and death after total hip replacement. *J Bone Joint Surg Br.* 1996 Nov;78(6):863-70.
- [38] . Freedman KB, Brookenthal KR, Fitzgerald RH Jr, Williams S, Lonner JH. Ameta-analysis of thromboembolic prophylaxis following elective total hip arthroplasty. *J Bone Joint Surg Am.* 2000 Jul;82-A(7):929-38.
- [39] Beksaç B, González Della Valle A, Anderson J, Sharrock NE, Sculco TP, Salvato EA. Symptomatic thromboembolism after one-stage bilateral THA with a multimodal prophylaxis protocol. *Clin Orthop Relat Res.* 2007 Oct;463:114-9.
- [40] Sharrock NE, Gonzalez Della Valle A, Go G, Lyman S, Salvati EA. Potent anticoagulants are associated with a higher all-cause mortality rate after hip and knee arthroplasty. *Clin Orthop Relat Res.* 2008 Mar;466(3):714-21.
- [41] Jameson SS, Bottle A, Malviya A, Muller SD, Reed MR. The impact of national guidelines for the prophylaxis of venous thromboembolism on the complications of arthroplasty of the lower limb. *J Bone Joint Surg Br.* 2010 Jan;92(1):123-9
- [42] Burnett RS, Clohisy JC, Wright RW, McDonald DJ, Shively RA, Givens SA, Barrack RL. Failure of the American College of Chest Physicians-1A protocol for lovenox in clinical outcomes for thromboembolic prophylaxis. *J Arthroplasty.* 2007 Apr; 22(3):317-24.





## **Recent Advances in Hip and Knee Arthroplasty**

Edited by Dr. Samo Fokter

ISBN 978-953-307-841-0

Hard cover, 452 pages

**Publisher** InTech

**Published online** 27, January, 2012

**Published in print edition** January, 2012

The purpose of this book is to offer an exhaustive overview of the recent insights into the state-of-the-art in most performed arthroplasties of large joints of lower extremities. The treatment options in degenerative joint disease have evolved very quickly. Many surgical procedures are quite different today than they were only five years ago. In an effort to be comprehensive, this book addresses hip arthroplasty with special emphasis on evolving minimally invasive surgical techniques. Some challenging topics in hip arthroplasty are covered in an additional section. Particular attention is given to different designs of knee endoprostheses and soft tissue balance. Special situations in knee arthroplasty are covered in a special section. Recent advances in computer technology created the possibility for the routine use of navigation in knee arthroplasty and this remarkable success is covered in depth as well. Each chapter includes current philosophies, techniques, and an extensive review of the literature.

### **How to reference**

In order to correctly reference this scholarly work, feel free to copy and paste the following:

N. A. Sandiford, U. Alao, J. A. Skinner and S. R. Samsani (2012). Hip Arthroplasty, Recent Advances in Hip and Knee Arthroplasty, Dr. Samo Fokter (Ed.), ISBN: 978-953-307-841-0, InTech, Available from: <http://www.intechopen.com/books/recent-advances-in-hip-and-knee-arthroplasty/hip-arthroplasty>

**INTech**  
open science | open minds

### **InTech Europe**

University Campus STeP Ri  
Slavka Krautzeka 83/A  
51000 Rijeka, Croatia  
Phone: +385 (51) 770 447  
Fax: +385 (51) 686 166  
[www.intechopen.com](http://www.intechopen.com)

### **InTech China**

Unit 405, Office Block, Hotel Equatorial Shanghai  
No.65, Yan An Road (West), Shanghai, 200040, China  
中国上海市延安西路65号上海国际贵都大饭店办公楼405单元  
Phone: +86-21-62489820  
Fax: +86-21-62489821

© 2012 The Author(s). Licensee IntechOpen. This is an open access article distributed under the terms of the [Creative Commons Attribution 3.0 License](https://creativecommons.org/licenses/by/3.0/), which permits unrestricted use, distribution, and reproduction in any medium, provided the original work is properly cited.

IntechOpen

IntechOpen