

We are IntechOpen, the world's leading publisher of Open Access books Built by scientists, for scientists

6,900

Open access books available

186,000

International authors and editors

200M

Downloads

Our authors are among the

154

Countries delivered to

TOP 1%

most cited scientists

12.2%

Contributors from top 500 universities



WEB OF SCIENCE™

Selection of our books indexed in the Book Citation Index
in Web of Science™ Core Collection (BKCI)

Interested in publishing with us?
Contact book.department@intechopen.com

Numbers displayed above are based on latest data collected.
For more information visit www.intechopen.com



Hip-Spine Relations: An Innovative Paradigm in THR Surgery

Jean Yves Lazennec^{1,2}, Adrien Brusson¹ and Marc-Antoine Rousseau^{1,2}

¹*Department of Orthopaedic Surgery, Hôpital Pitié Salpêtrière
Assistance Publique - Hôpitaux de Paris (AP-HP), Paris*

²*Biomechanics Lab, Arts et Métiers ParisTech, Centre National de la Recherche
Scientifique (CNRS), Unités Mixtes de Recherche (UMR), Paris
France*

1. Introduction

The sagittal balance of the trunk is considered to be a key point for spinal fusion and disc replacement. This balance is the manifestation of a postural strategy conditioned by anatomic and functional characteristics that can differ greatly from one person to another (Duval-Beaupere et al., 1992). The role of the pelvic area is evident for spinal surgeons in their planning and analyses; they pay special attention to the sacral slope, which is closely related to the pelvic tilt (Chanplakorn et al., 2011; Dorr et al., 1983; Jackson & McManus, 1994; Kobayashi et al., 2004; Murray, 1993; Vialle et al., 2005). Dubousset underlined this concept as early as 1984, in treating the pelvis as a "pelvic vertebra" (Dubousset, 1984).

Although the concept of spinopelvic balance is well accepted today (Lazennec et al., 2004), conventional imagery underestimates the influence of the coxofemoral joint and explains it inadequately. The EOS imaging system (Dubousset et al., 2008), by optimizing radiologic data in functional situations, is revolutionizing our understanding of hip-spine relations (Lazennec et al., 2011b).

These anatomic and functional considerations often remain foreign to hip surgeons, who focus on the bone landmarks of the pelvis for their navigation, individualized adjustments, and failure analyses (Woo & Morrey, 1982; Woolson & Rahimtoola, 1999). Although the hip is a highly mobile joint, surgical concepts are still based on the static AP view of the pelvis in standing or supine position to assess cup orientation, which is an essential risk factor for prosthesis instability and wear (Kennedy et al., 1998). Influenced by the classic anatomic culture of cross-sectional slices, they consider the CT scan a reference tool for the "horizontal" assessment of the coxofemoral joints (Ackland et al., 1986; Dorr et al., 1983; Kennedy et al., 1998; Murray, 1993; Seki et al., 1998; Wan et al., 2009). Nonetheless, as this chapter will show, lateral views of the hips and the evaluation of sitting position provide new information about "normal" hip function and THR failures.

The concept of cumulative anteversion between the acetabular cup and the femur is considered a key factor in the stability of the hip prosthesis. This concept, however, is based on the measurements taken by computed tomography in a supine position, which do not take into account the functional dimension of the problem.

Degeneration of the spinopelvic balance, often associated with spinal aging or hip dysfunction, can generate a cascade of mechanical events that involve the relation between the hips and spine and in particular the adaptive capacities of the hips (Itoi, 1991). These problems have become more acute today, with patients' ever greater functional demands after hip arthroplasty (**Fig. 1**). Hip-spine relations must therefore be better investigated in planning total hip arthroplasties (THAs), as lumbosacral orientation plays a critical role in the function of the hip joints.

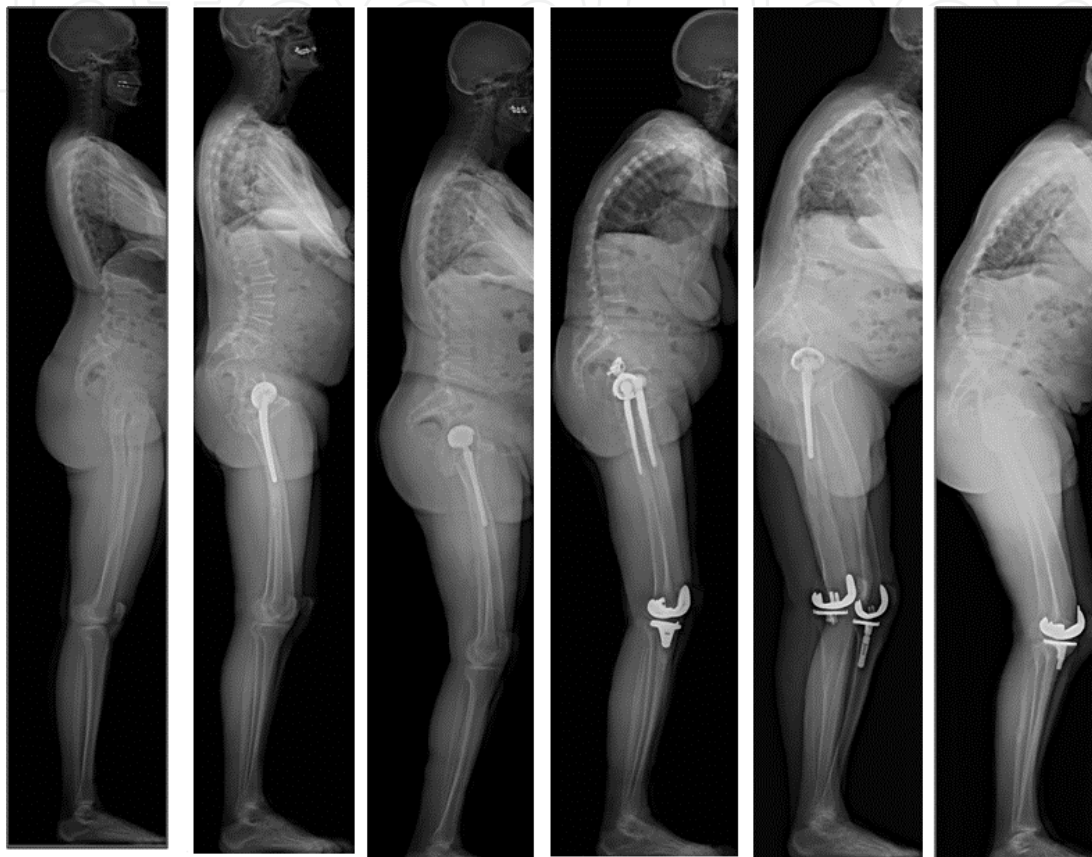


Fig. 1. Degeneration of the sagittal spinopelvic balance : loss of spinal curvatures and modifications of pelvis orientation

2. Anatomic bases of lumbopelvic balance: The importance of sagittal spinopelvic balance in standing position

The most important radiographic parameters of spinopelvic balance in upright posture have been well defined (Tassin, 2004; Vaz et al., 2002; Vialle et al., 2005). The sacral slope (SS, $41^{\circ} \pm 8.4^{\circ}$) is the angle between the horizontal line and the cranial sacral endplate tangent (Vialle et al., 2005).

The pelvic tilt (PT, $13^{\circ} \pm 6^{\circ}$) is the angle between the vertical line and the line joining the middle of the sacral endplate and the center of the bicoxofemoral axis (the line between the geometric center of both femoral heads) (Vialle et al., 2005).

The pelvic incidence (I, $55^{\circ} \pm 10.6^{\circ}$) is the angle between the line perpendicular to the middle of the cranial sacral endplate and the line joining the middle of this endplate to the center of the bicoxofemoral axis (Vialle et al., 2005).

Each subject is characterized by this "morphologic" parameter, which schematically represents pelvic thickness. The adaptation of other functional factors, such as pelvic tilt, and the spinal parameters (sacral slope, lumbar lordosis, and thoracic kyphosis) makes it possible to position the center of gravity of the component specifically so that it is supported by the femoral heads relative to the pelvic base, to maintain balance with only a minimal muscular effort (Duval-Beaupere et al., 1992; Legaye et al., 1998; Rillardon et al., 2003; Roussouly et al., 2005) (**Fig. 2**).

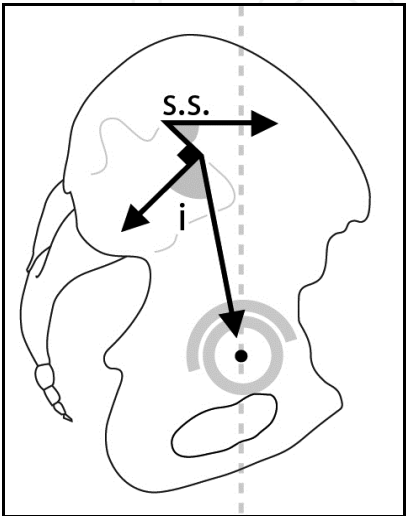


Fig. 2. Definition of sacral slope (S.S.) and pelvic incidence angle (i)

Pelvic incidence (I, a morphologic and anatomical parameter) is associated with the sacral slope (SS) and pelvic tilt (PT) (positional parameters) in a geometric relation: $I = SS + PT$ (1) (**Fig. 3**). A sequence of significant correlations has been reported between pelvic incidence and the functional indicators, sacral slope ($r = 0.98$) and lordosis ($r = 0.9$) (Boulay et al., 2006; Rillardon et al., 2003; Vialle et al., 2005). A high pelvic incidence corresponds to a sharp sacral slope and strong lordosis, while a small pelvic incidence corresponds to a low sacral slope and flatter lordosis. The borderline balance conditions and spinopelvic balance in seated positions are less known, in particular, for patients with hip prostheses.

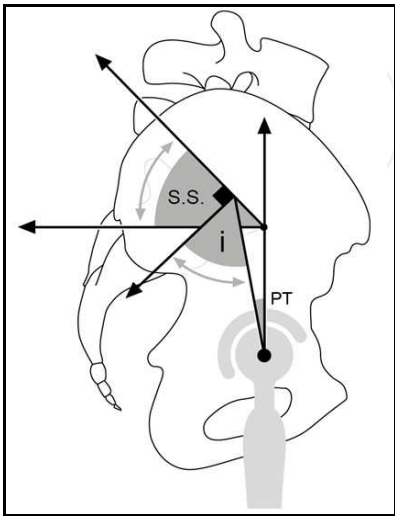


Fig. 3. Pelvic incidence (I) is associated with the sacral slope (S.S.) and pelvic tilt (PT) in a geometric relation: $I = SS + PT$

The pelvis moves, rotating around the bicoxofemoral axis, leading to both anterior tilt (where the upper portion of the pelvis tips forward) and posterior tilt (upper portion of the pelvis tips backward). The variations in the angles of the sacral slope determine the range of this pelvic tilt, and its variations in turn influence the orientation of the anterior pelvic plane or the Lewinnek plane classically used as a reference for navigation of the acetabular components in THAs (Fig. 4) (Lewinnek et al., 1978). The surprising consequences of some spinal arthrodeses or stiffening on the hips and the difficulties of adjusting prostheses below stiffened spines illustrate the importance of these anatomic-functional parameters.

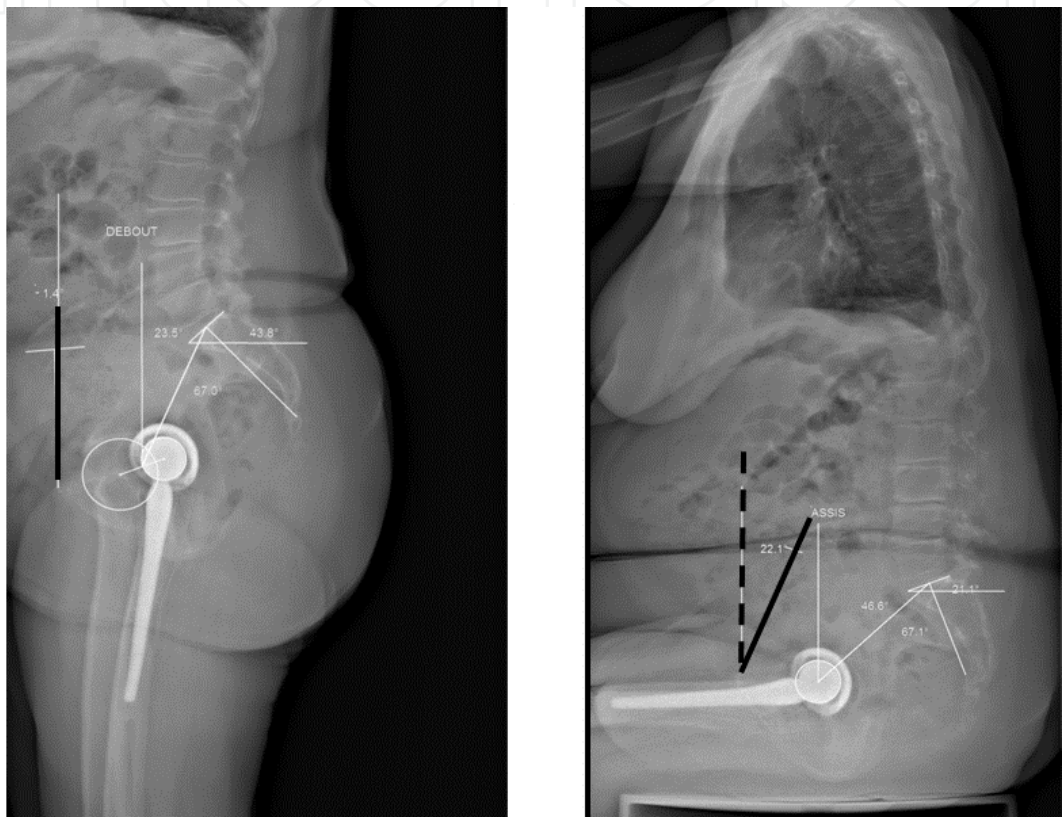


Fig. 4. The pelvis moves, rotating around the bicoxofemoral axis, the anterior tilt (where the upper portion of the pelvis tips forward) is observed in standing position and posterior tilt (upper portion of the pelvis tips backward) in seated position.

2.1 The standing position

Fig. 5 corresponds to a forward tilt of the pelvis as a whole. In this situation, the upper endplate of S1, viewed laterally, makes an angle of approximately 35° to 45° between the sacral slope and the horizontal (Lazennec et al., 2000; Lazennec et al., 2011c). Some subjects have a small sacral slope angle in standing position: we talk then about posterior pelvic tilt (or pelvic retroversion or pelvic extension) and the sacrum seen on a lateral image appears more vertical than usual (Fig. 6a). On the contrary, other subjects have a very horizontal sacrum in standing position with a sacral slope angle sometimes much greater than 50° (anterior pelvic tilt, pelvic anteversion or pelvic flexion) (Fig. 6b).

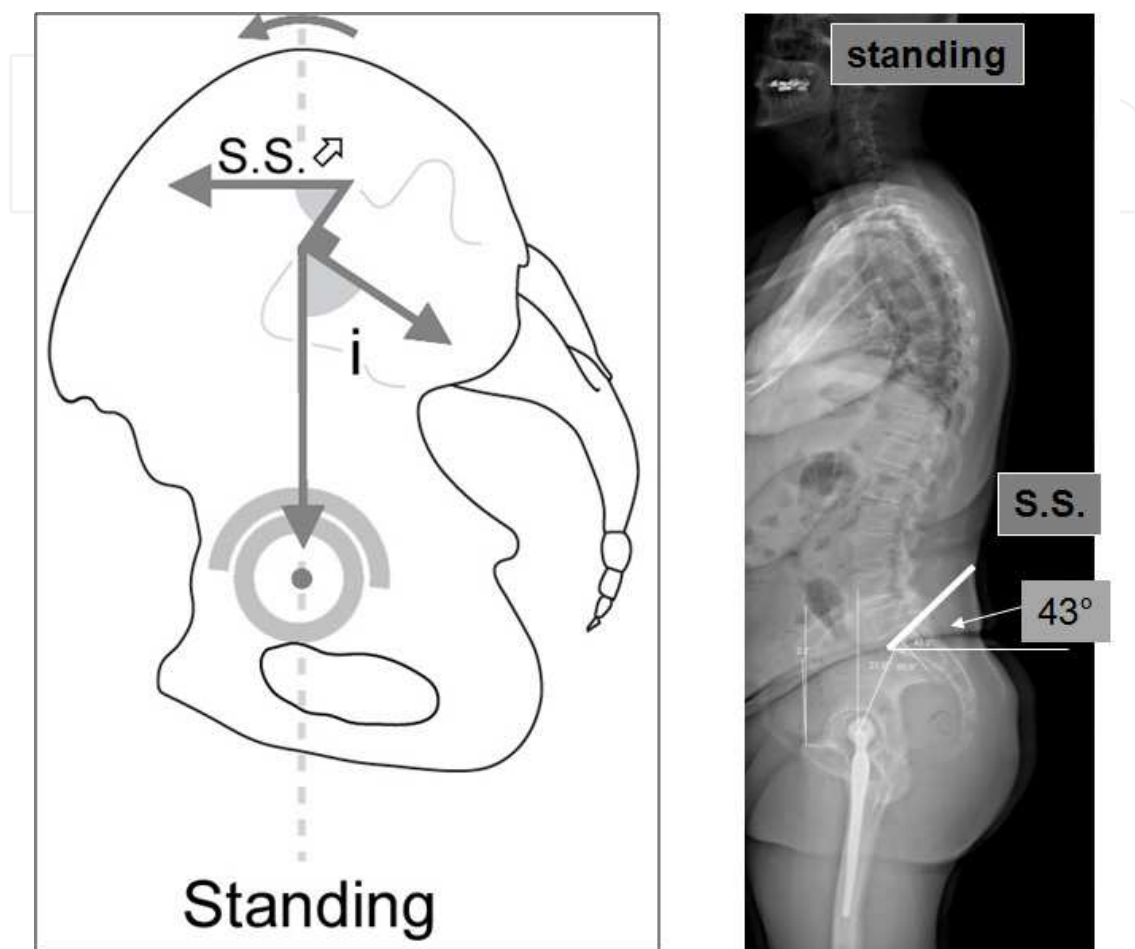


Fig. 5. The standing position corresponds to a forward tilt of the pelvis: the upper endplate of S1, viewed laterally, makes an angle of approximately 35° to 45° between the sacral slope and the horizontal

2.2 In the supine position

When the lower limbs are extended, the sacral slope is often greater than in standing position. The measurement of its angle with the vertical often exceeds 45° (Lazennec et al., 2011a; Lazennec et al., 2004). This can be seen on scout views of pelvic CT scans. This additional pelvic tilt may not be well tolerated in the case of a stiff or deformed spine since the dorsal decubitus position deepens lumbar lordosis. Sometimes a limitation of the available extension of the hips or posterior osteoarthritis makes a strict decubitus position unbearable, at least without a slight compromise flexion of the coxofemoral joints.

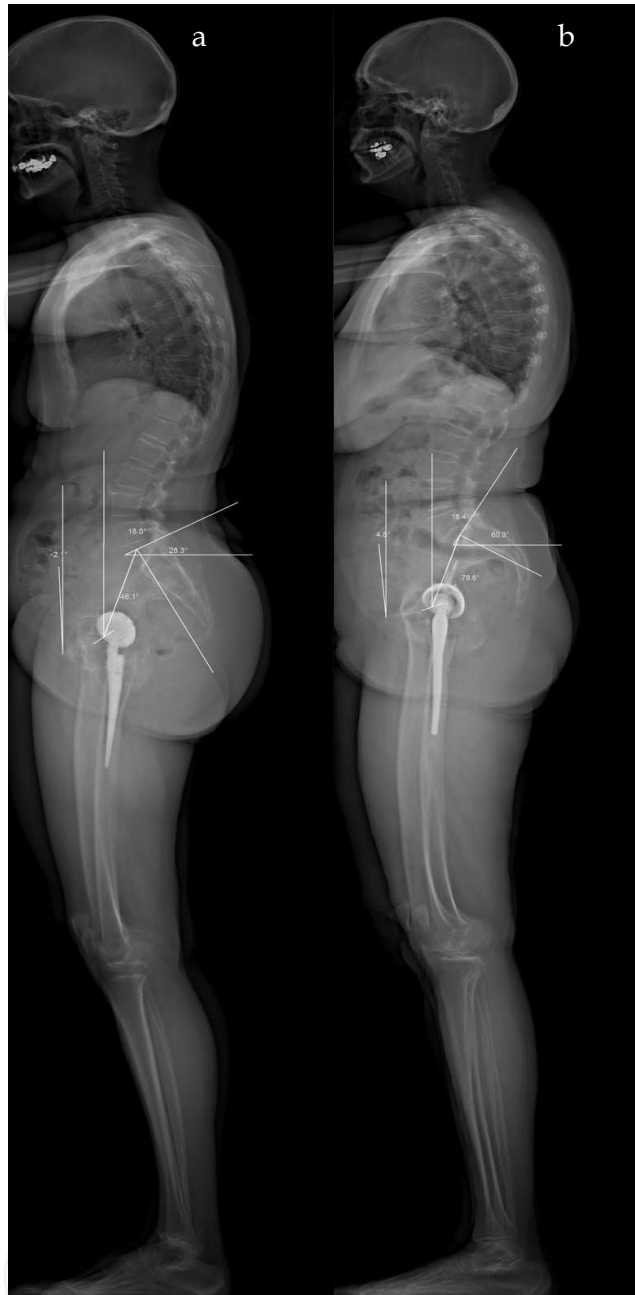


Fig. 6. a: Some subjects have a small sacral slope angle in standing position: the sacrum appears more vertical than usual (posterior pelvic tilt, pelvic retroversion or pelvic extension), 6. b: Some subjects have a very horizontal sacrum in standing position with a greater sacral slope angle (anterior pelvic tilt, pelvic anteversion or pelvic flexion)

2.3 In a sitting position

The phenomenon is inversed (**Fig. 7**). The pelvis tilts backwards as it progresses toward a sitting position. The sacral slope diminishes, to values of 20° to 25° on average (Lazennec et al., 2011a; Lazennec et al., 2011c). This slope may still be slightly positive (by 5 to 10°) or even sometimes negative. As a function of the height of the seat, the subject's morphology or

any associated spinal disease, we observe pelvic posterior tilt (pelvic retroversion or pelvic extension) more or less accentuated with a sacrum more or less vertical. The difference in the values of the sacral slope between standing and seated positions makes it possible to define the available flexion associated with the lumbosacral joint (extrinsic available pelvic flexion) by opposition to the potential for flexion associated with the coxofemoral joint (intrinsic available pelvic flexion).

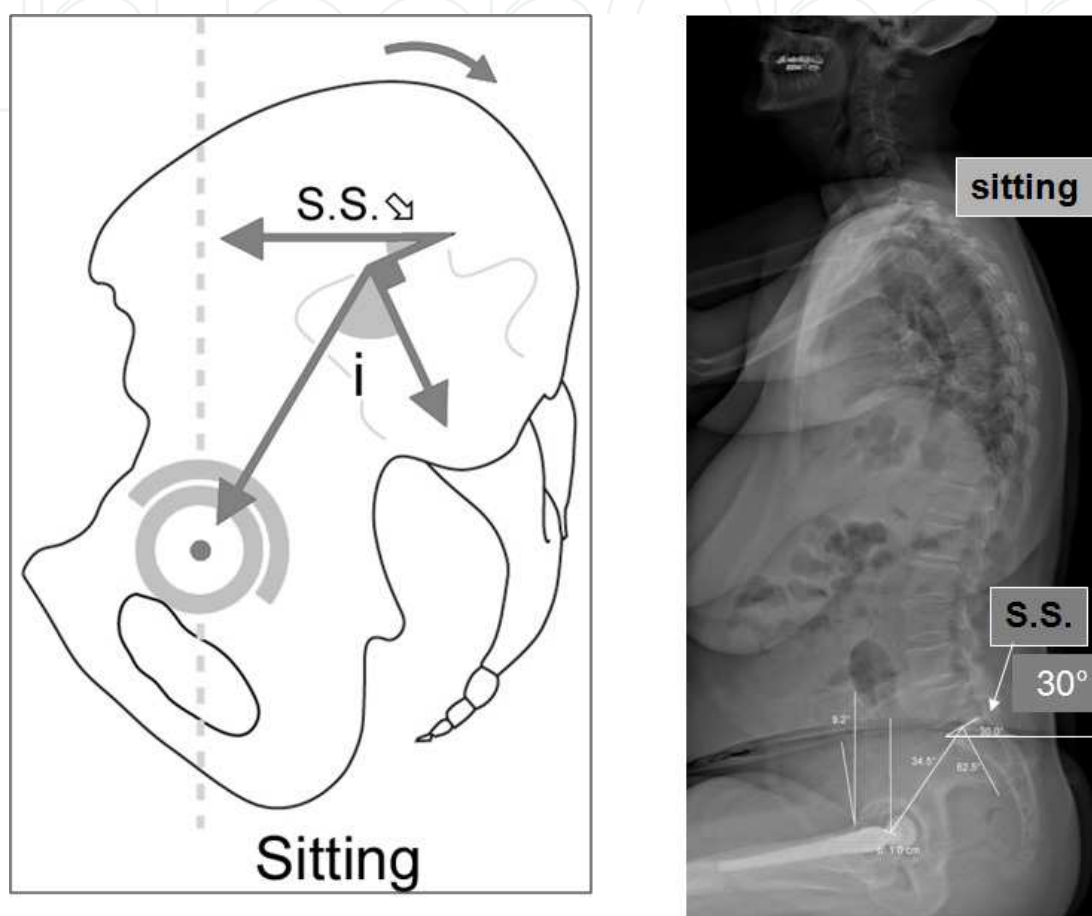


Fig. 7. In sitting position, the pelvis tilts backwards. The sacral slope diminishes. The difference in the values of the sacral slope between standing and seated positions is about 20°

2.4 Progression from standing to sitting positions

Causes considerable modification in the orientation of the anterior pelvic plane, today considered the reference for adjusting the acetabular cups (D'Lima et al., 2000; Herrlin et al., 1988; Rousseau et al., 2009). These variations must concern us. Lewinnek's plane (the anterior pelvic plane) is evaluated in the dorsal decubitus position to collect morphologic data for planning the hip prosthesis (Lewinnek et al., 1978). The information obtained must extrapolated prudently because it is not necessarily vertical in standing positions, and its tilt is highly variable in sitting positions (Philippot et al., 2009; Rousseau et al., 2009). Accordingly, for mean values of 3° in standing positions, the values reported while sitting were 17.5° (Lazennec et al., 2011c) (Fig. 8).

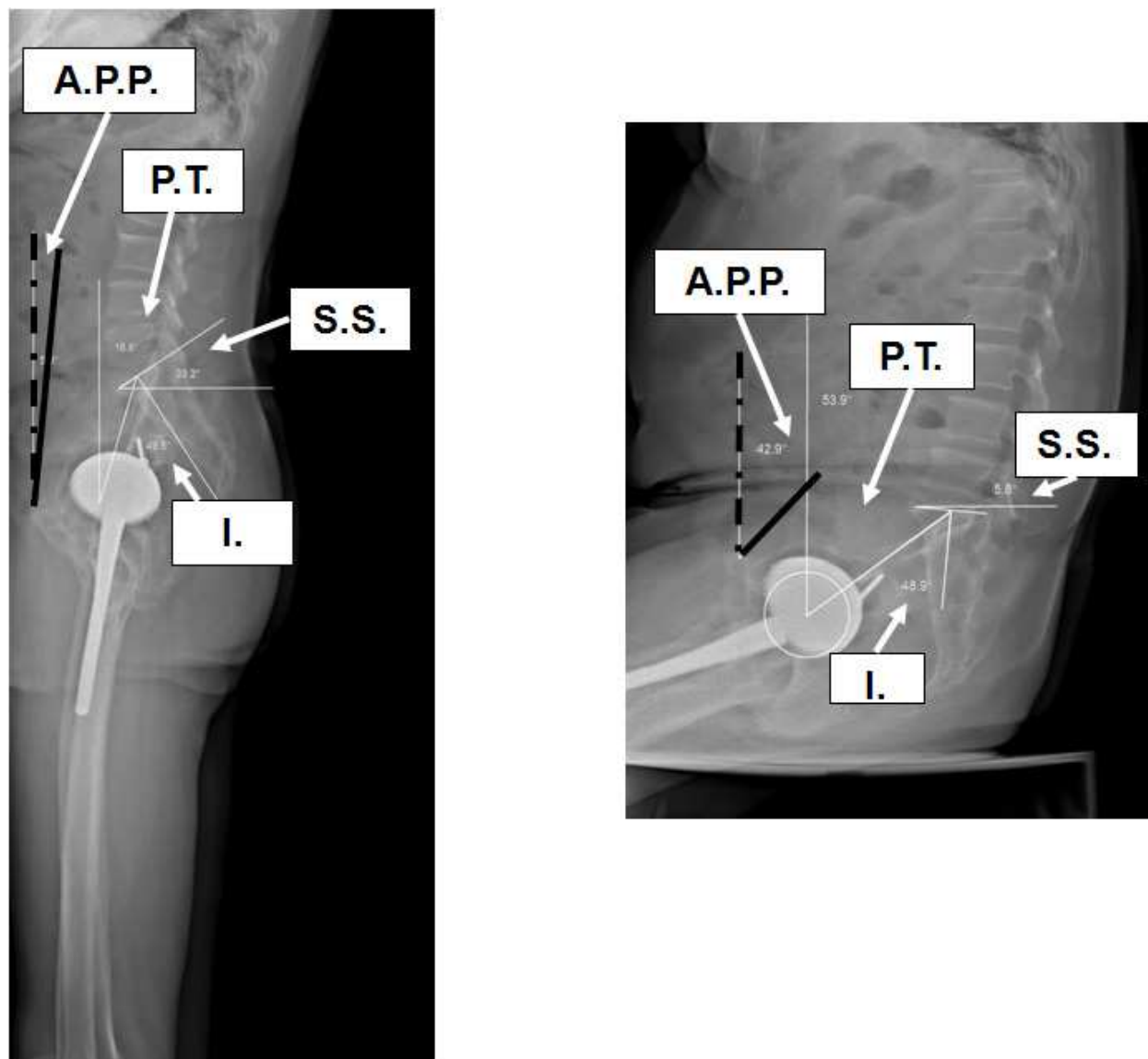


Fig. 8. Progression from standing to sitting positions causes considerable modification in the orientation of the anterior pelvic plane (A.P.P. or Lewinnek plane)

3. Influence of sagittal posture on the frontal and sagittal acetabular orientation in functional situations

3.1 Anatomic foundations

Most surgeons use only AP X radiograms of the pelvis to assess the cup orientation in standing position, measuring the frontal inclination angle or abduction angle (AA). The lateral view is little used in the literature. Acetabular tilt is assessed by the SIA (sagittal inclination angle between the horizontal and the axis of the cup ellipse, also called the sagittal tilt (Lazennec et al., 2011a) (Fig. 9).

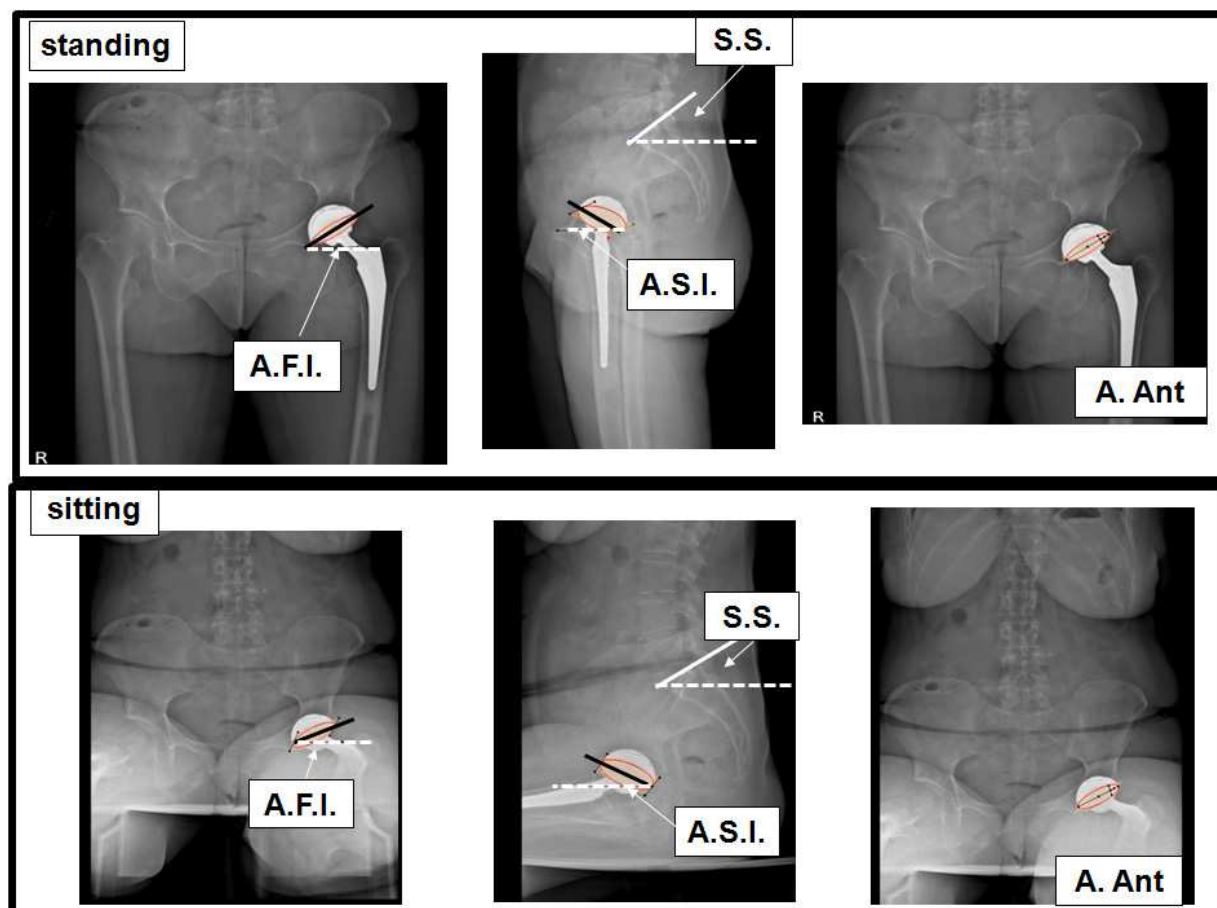


Fig. 9. AP and lateral images provide a global evaluation of the pelvis and cup orientations in standing or seated positions

Because of basic trigonometric relations in three dimensions, the SIA has the same value as the operative anteversion described by Murray (Murray, 1993), although it is a different angle. But sitting and even squatting are critical positions, as they address most of instability or impingement situations. The abduction and sagittal inclination angles of the cup are functional parameters with significant variations between the standing, sitting, and supine positions (Lazennec et al., 2011b). The interdependence between the sagittal tilt or **AST** of the cup and the sacral slope is obvious when reading lateral images, seated or standing, of the lumbosacral joint (Bolger et al., 2007). This interrelation is expressed by the value of the sacroacetabular angle (**SAA**), defined by the axis of the acetabular ellipse viewed laterally (which defines the acetabular sagittal tilt, **AST**, with the horizontal) and the tangent to the sacral endplate. This is a fixed angle, imposed by the surgeon empirically at implantation (Lazennec et al., 2007) (**Fig. 10**).

In a standing position, the value of the sacral slope is high and the angle of the acetabular tilt is small. Inversely, in a seated position, the sacral slope diminishes and the acetabular tilt increases. From both AP and lateral positions, the THA cup appears more vertical in seated than in standing positions. Observational series of THA from diverse institutions (Lazennec et al., 2011a; Lazennec et al., 2011c) report mean values of 49° to 52° for the frontal cup inclination in standing position and 57° to 64° while seated. At the same time the sagittal inclination is 36° to 47° standing and 51° to 58° seated. These variations in acetabular tilt

contribute to modifying the “anterior opening” of the acetabulum and therefore the orientation of the functional “mobility cone” generated by the coxofemoral joint (**Fig. 11 a and b**) (Kummer et al., 1999; Lazennec et al., 2011a) (Pradhan, 1999).

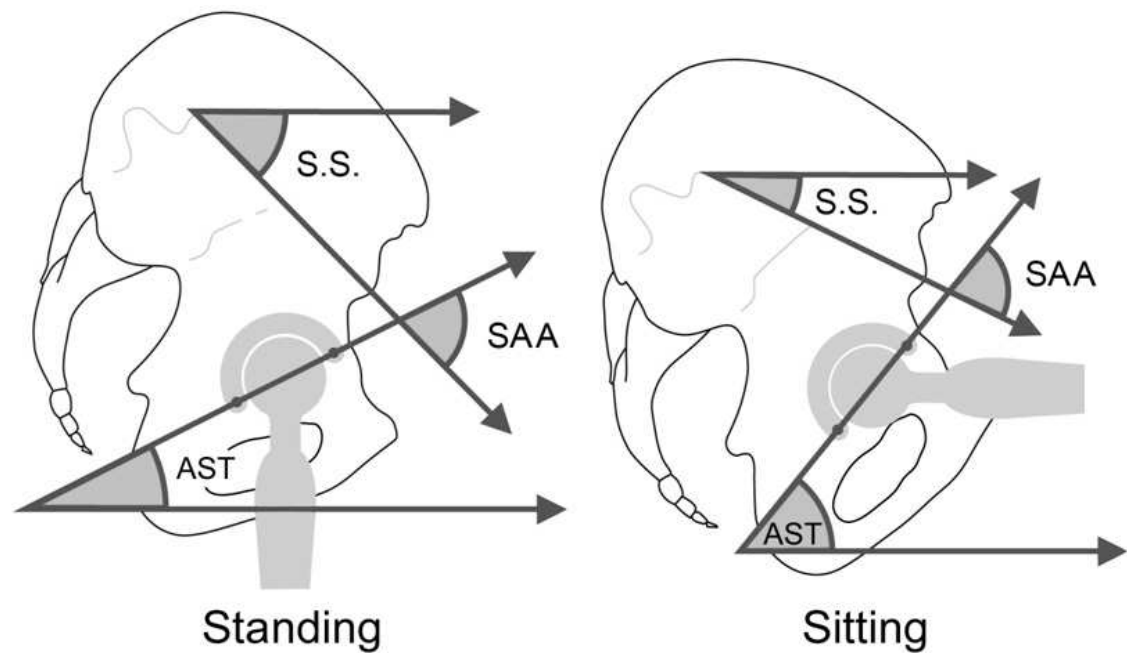


Fig. 10. The interdependence between the sagittal tilt or AST of the cup and the sacral slope is expressed by the value of the sacroacetabular angle (SAA)

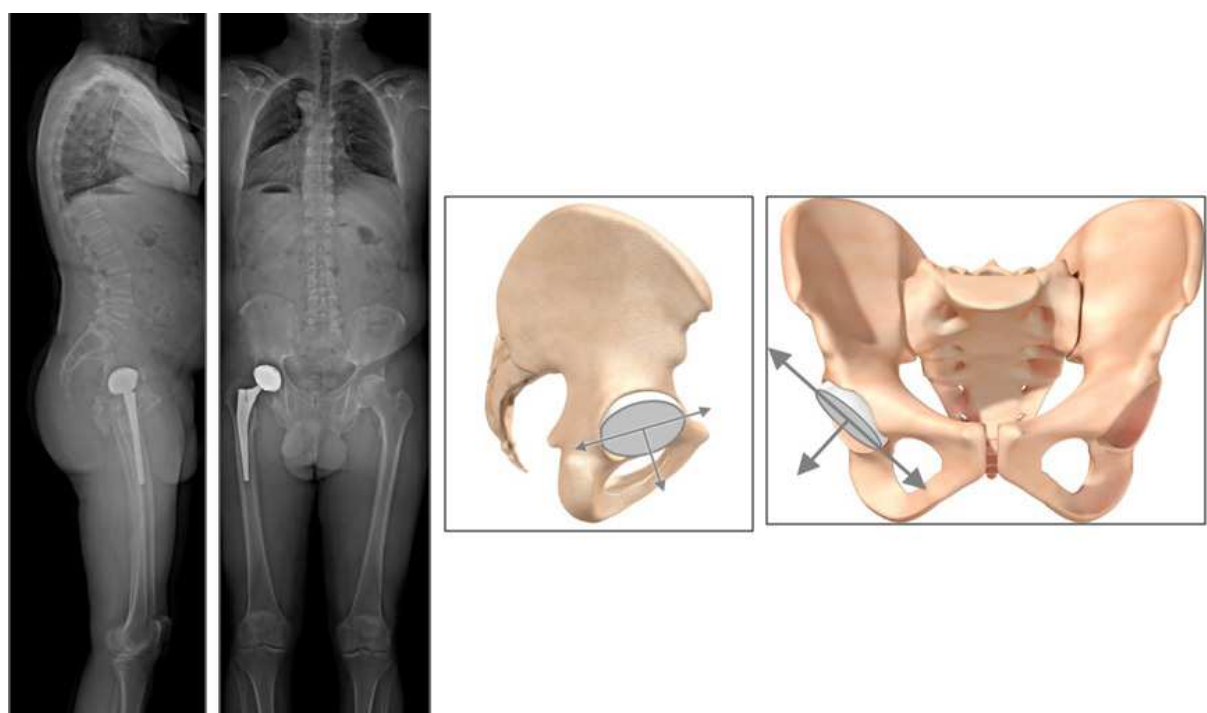


Fig. 11. a: The variations in acetabular tilt in standing and seated positions contribute to modifying the “anterior opening” of the acetabulum and therefore the orientation of the functional “mobility cone” generated by the coxofemoral joint

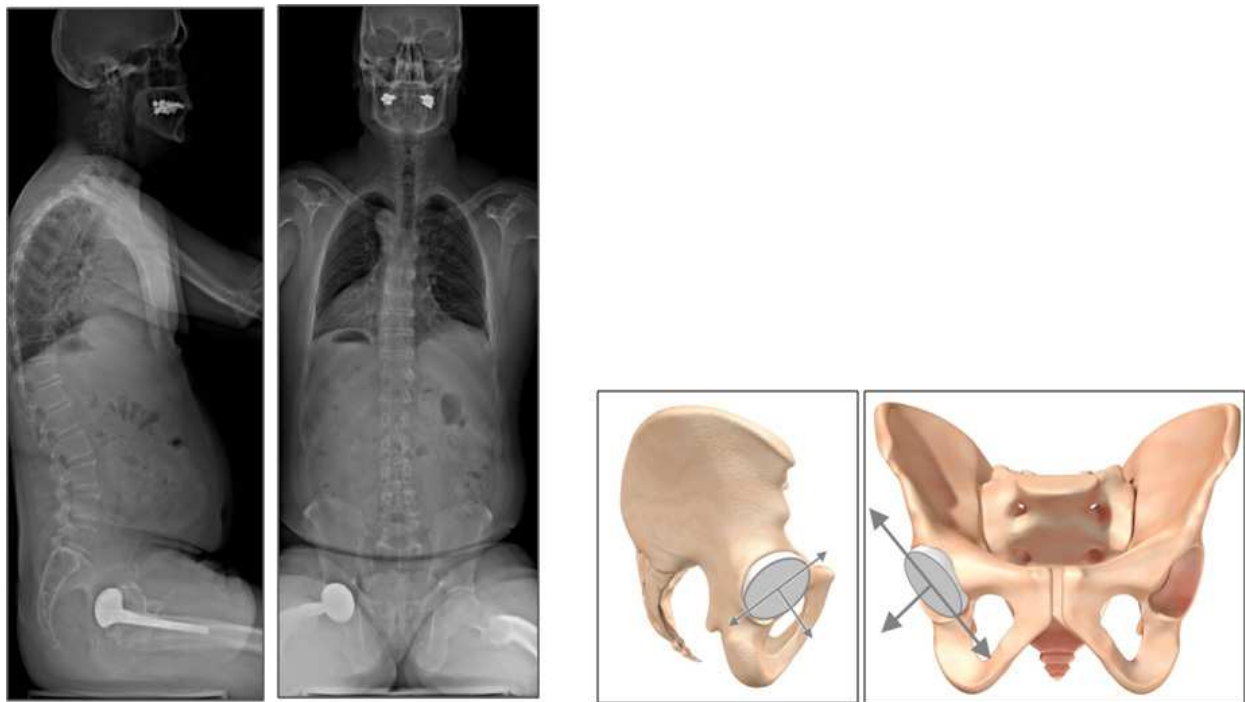


Fig. 11. b: The variations in acetabular tilt in standing and seated positions contribute to modifying the “anterior opening” of the acetabulum and therefore the orientation of the functional “mobility cone” generated by the coxofemoral joint

Modifications in the acetabular orientation produce consequences for the stability of hip arthroplasties and for all aspects of their tribology in the intermediate and long term (Lazennec et al., 2007; von Knoch et al., 2002; Woo & Morrey, 1982; Yamaguchi et al., 1997). The acetabular parameters in a supine position are highly correlated with those in a standing position but poorly correlated with those in a sitting position (Lazennec et al., 2011a). These correlations underline the importance of specific studies of the seated position in work-ups of prostheses that malfunction and of screening subjects at risk before surgery.

3.2 Disruptions can come from atypical postures

These considerations illustrate the consequences of spinal fusions regarding hip function and the possible difficulties in adjusting acetabular cup implantation in cases of an unusually stiff or unbalanced spine (Watanabe et al., 2002). Excess posterior tilt of the pelvis is often associated with postural imbalance to compensate for a forward tilt of the entire trunk. This postural adaptation verticalizes the cup from both the AP and lateral views and places the hips in a hyperextended position when standing. This solicitation of the available hip extension can lead to a posterior impingement. A typical example is posterior impingement of the hip prosthesis in standing position even though the cup was placed perfectly in accordance with the pelvic bone landmarks (**Fig. 12**). This situation can be encountered in native hips in the case of excessive posterior tilt of the pelvis (abnormal posture, trunk aging and induced posterior coxarthrosis) (Hammerberg & Wood, 2003; Itoi, 1991; Lafage et al., 2009; Offierski & MacNab, 1983).

Analysis of these situations can be difficult because they involve simultaneously diseases of the spine and hips. Assessment of the available hip extension is thus essential to distinguish true and false inability to extend the hip fully (**Fig. 13**). This analysis can be performed easily with EOS® technology, which makes it possible to individualize the available extension associated with the lumbosacral joint, that is, the extrinsic available extension, as well as the intrinsic available extension of each coxofemoral joint. Inversely, excess anterior tilt of the pelvis in a seated position can cause anterior impingement (**Fig. 14**). In some cases, the anterior tilt of the acetabulum is also excessive in a standing position: the acetabulum is “horizontalized” from both AP and lateral views, as if the hips are permanently flexed when the subject is standing. This type of mechanism is suggested on native hips in anterior impingements, especially in some repetitive athletic or occupational movements.

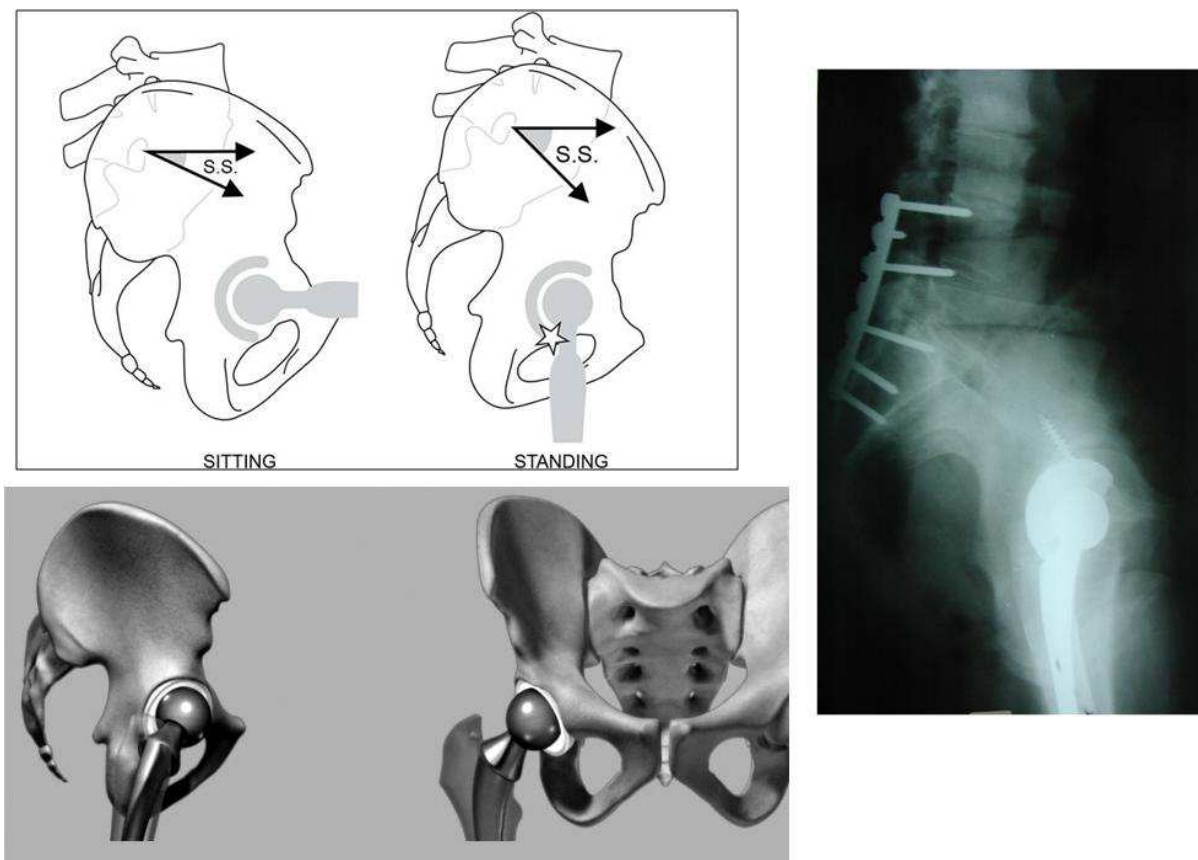


Fig. 12. Excess posterior tilt of the pelvis is often associated with postural imbalance to compensate for a forward tilt of the entire trunk. A typical example is posterior impingement of the hip prosthesis in standing position even though the cup was placed perfectly in accordance with the pelvic bone landmarks (no impingement in sitting position).

We also observed a mechanism of specific adaptation in hips that could not be fully extended secondary to coxarthrosis. The loss of range of motion of the abnormal hip results in a forward tilt of the pelvis when the patient tries to straighten up. When possible, the spine adapts by increasing lumbar lordosis, thus causing low back pain. Frequently, only one hip is involved. The test for available extension allows us to assess the phenomenon selectively.

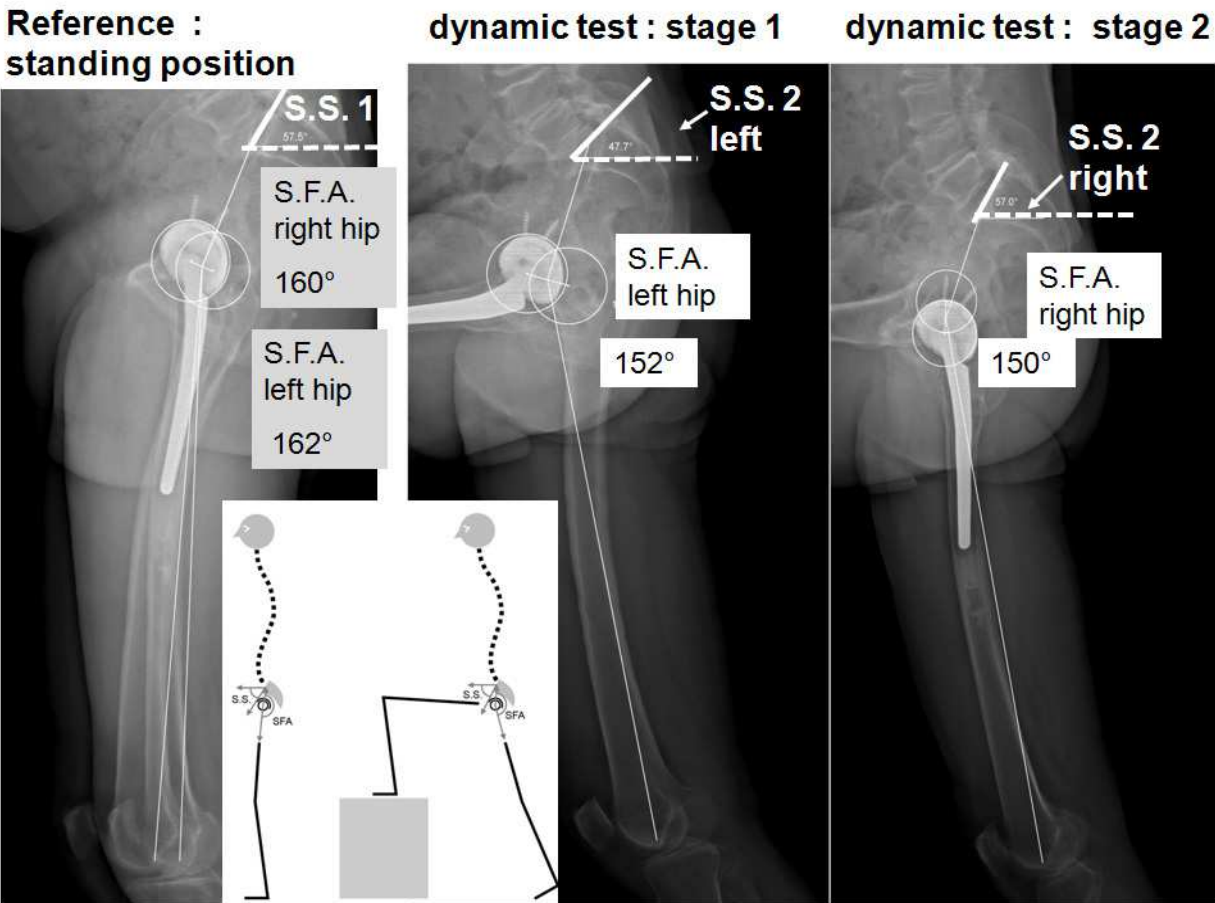


Fig. 13. EOS® technology makes it possible to individualize the available extension associated with the lumbosacral joint (the extrinsic available extension) as well as the intrinsic available extension of each coxofemoral joint. Each hip is assessed in its maximum range of extension in standing position, placing the contralateral lower limb on a step such that it is in a position of maximum flexion of the coxofemoral joint. The extrinsic available extension is measured by the capacity to increase the sacral slope (SS 2 – SS 1). The intrinsic available extension is measured by the variation of the sacro-femoral angle (SFA). In this example: the available extension is 10° for the 2 hips.

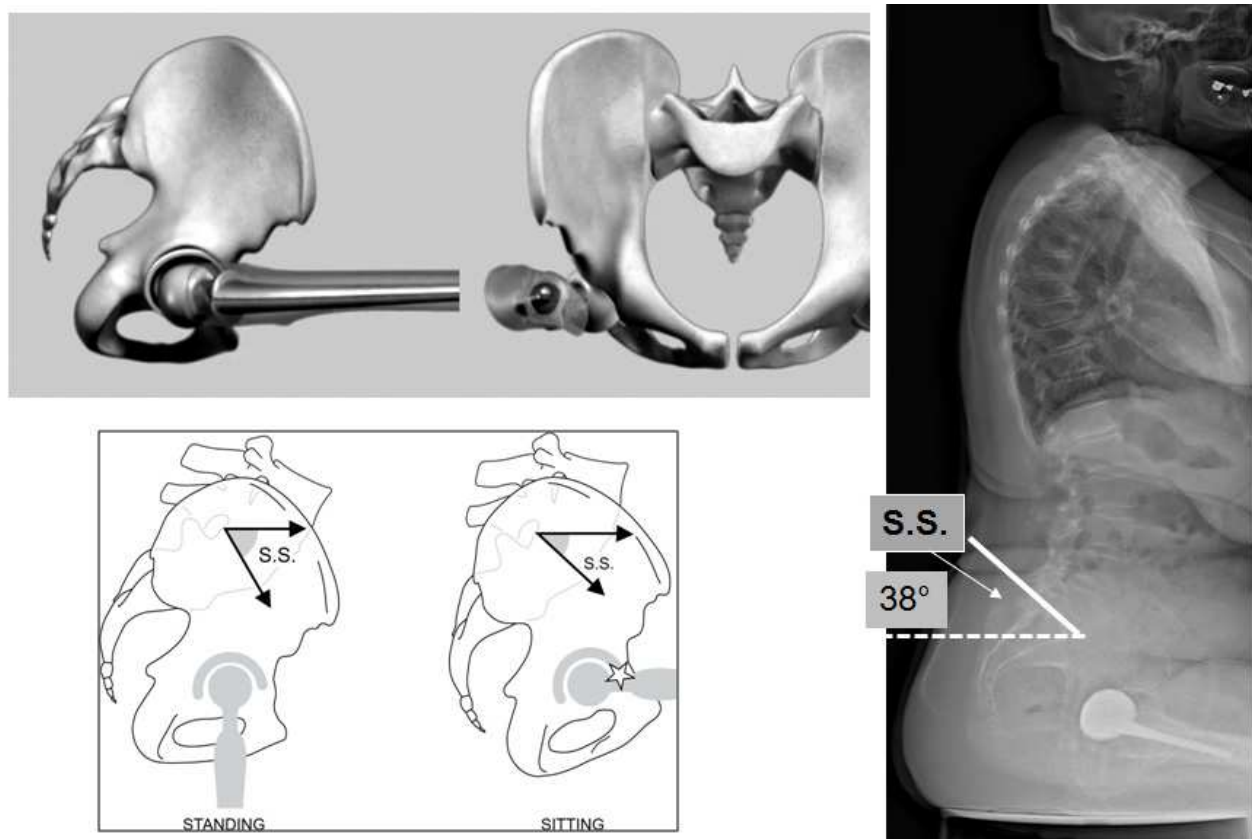


Fig. 14. Excess anterior tilt of the pelvis in a seated position can cause anterior impingement; no impingement in standing position

3.3 Disturbances can come from atypical morphotypes

The angle of incidence is the morphologic parameter determinant for the adaptation of sagittal spinopelvic balance. Two types of population require specific attention relative to those with a normal incidence. In subjects with a high angle of pelvic incidence, theoretical lumbar lordosis is greater as the range of adaptation of the sacral slope may also be, according to the formula $I = SS + PT$. The femoral heads are projected forward relative to the sacrum and the acetabular anterior opening is less marked. The coxofemoral joints of these subjects have a greater theoretical available extension and therefore a better ability to adapt. The range of pelvic tilt and sacral slope adaptation is higher. On the other hand, these patients are risky for spine surgeons in cases of spinal arthrodesis: the surgical achievement of adequate lordosis is technically challenging and tolerance of residual flat back is very poor.

Inversely, in subjects with a low pelvic incidence angle, there is less theoretical lumbar lordosis and the adaptability of the sacral slope and pelvic tilt may be more limited. The femoral heads are embedded under the sacrum and the anterior opening of the acetabulum is more marked. Theoretically, these subjects have less available hip extension and a weaker capacity to adapt to sagittal imbalance (**Fig. 15**). In standing position, their hips are naturally in extension, which means they cannot increase the posterior range of motion significantly. Due to potential posterior impingements, these patients can experience anterior dislocation or subluxation in standing position. Compensatory mechanisms may involve hips and knee flexion (Vialle et al., 2005). Accordingly, these subjects are more easily subject to a global and unstable imbalance because of their small margin for adaptation.

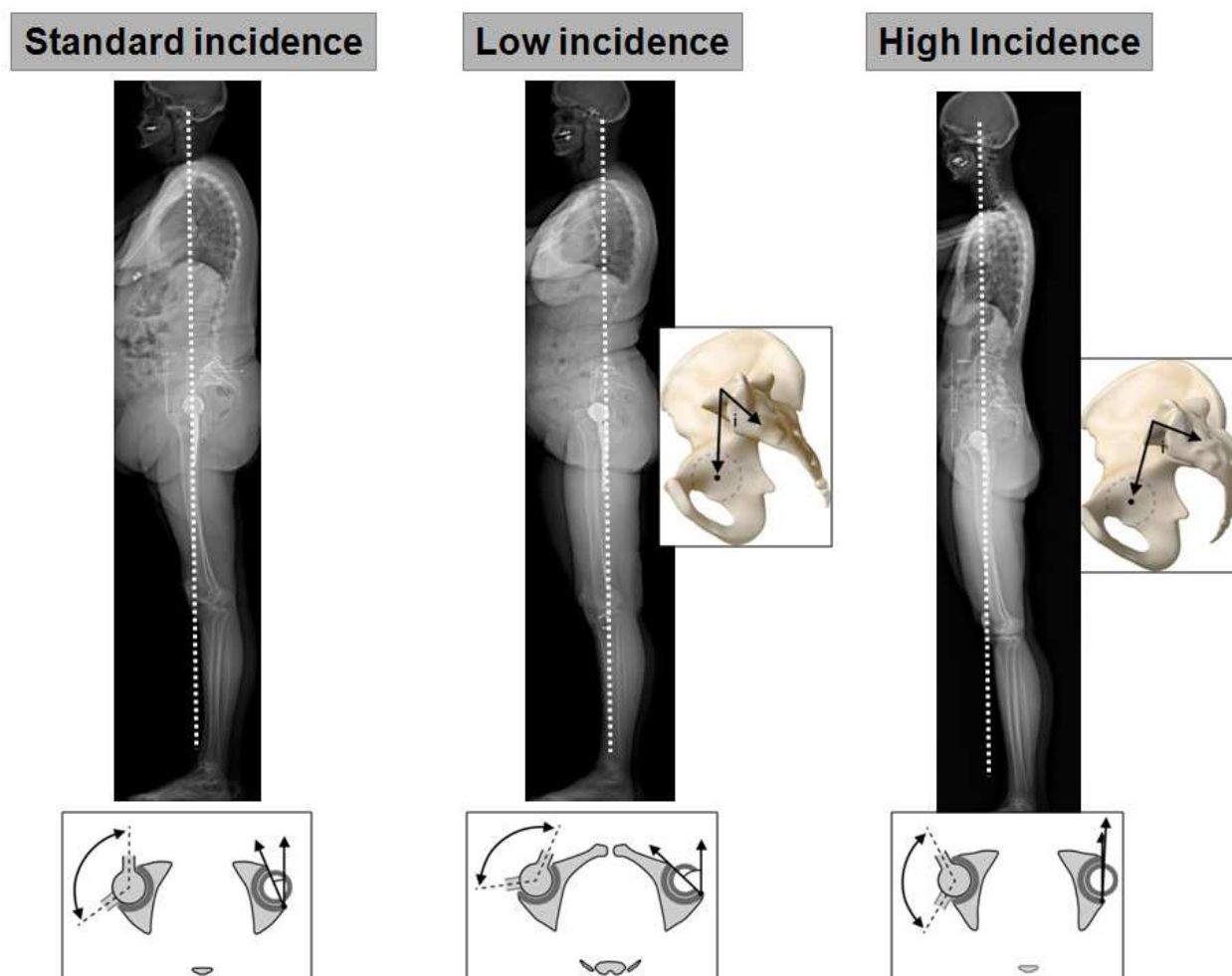


Fig. 15. In subjects with a high angle of pelvic incidence, lumbar lordosis is greater and the coxofemoral joints have a greater theoretical available extension and a better ability to adapt. In subjects with a low pelvic incidence angle, there is less lumbar lordosis and the adaptability of the sacral slope and pelvic tilt may be more limited

4. Influence of sagittal posture on cross-sectional acetabular cup orientation: Anatomic and functional anteversion

4.1 Standard data

The transverse orientation of the acetabulum is expressed by its anterior opening angle or anteversion. Anatomical acetabular anteversion is a restrictive concept as it is defined as the anterior opening according to the pelvic frame. According to Murray, “anatomical” or “morphological” anteversion is the angle between the AP pelvic axis and the acetabular axis when this is projected on to the transverse reference plane perpendicular to the longitudinal axis and the midsagittal plane of the pelvis (Murray, 1993).

In current practice, anteversion is measured on CT scans: this angle is often considered to be anatomical anteversion, leading to some confusion because the angle value depends on the pelvic orientation in the lying position.

That is, the orientation of the cross-sectional slices in relation to the sagittal plane is left to radiologists to assess without any specific criterion for standardization, although it has a critical effect on the values of the angles measured. Fortunately, they can be strictly

perpendicular to the longitudinal axis of the pelvic bone frame. Most of the time these slices, perpendicular to the plane of the examination table, do not correspond to the anatomic plane because the position of the supine subject has a more or less marked sagittal pelvic tilt (Lazennec et al., 2011a). Therefore this angle is only a “functional” supine anteversion, reflecting the projected anterior opening of the acetabulum in a specific position.

The variation in the anteversion measured is approximately 0.5° for 1° of rotation of the plane of the slice in relation to the pelvis (Anda et al., 1990; Lazennec et al., 2004; Muller et al., 2005). The literature also reports measurements of anatomic acetabular anteversion on CT, according to a plane perpendicular to the anterior pelvic plane (Lewinnek's plane)(McKibbin, 1970). In this case, the cut plane analyzes the acetabulum according to the same orientation, regardless of the subject's position. The anteversion value measured refers exclusively to the pelvic bone landmarks without taking into account the variations of position in standing, seated and squatting positions. It is fixed, regardless of the subject's position (**Fig. 16**).

Anatomic or morphologic anteversion can also be measured reliably relative to the table or machine stand by using the reference transverse plane (Aubry et al., 2005; Lazennec et al., 2004; Lazennec et al., 2007) through the upper sacral endplate (the sacral transverse plane). This technique is easier to implement than the preceding method, but the acetabulum is not analyzed according to the same angle, and the angle values are different (**Fig. 17**).

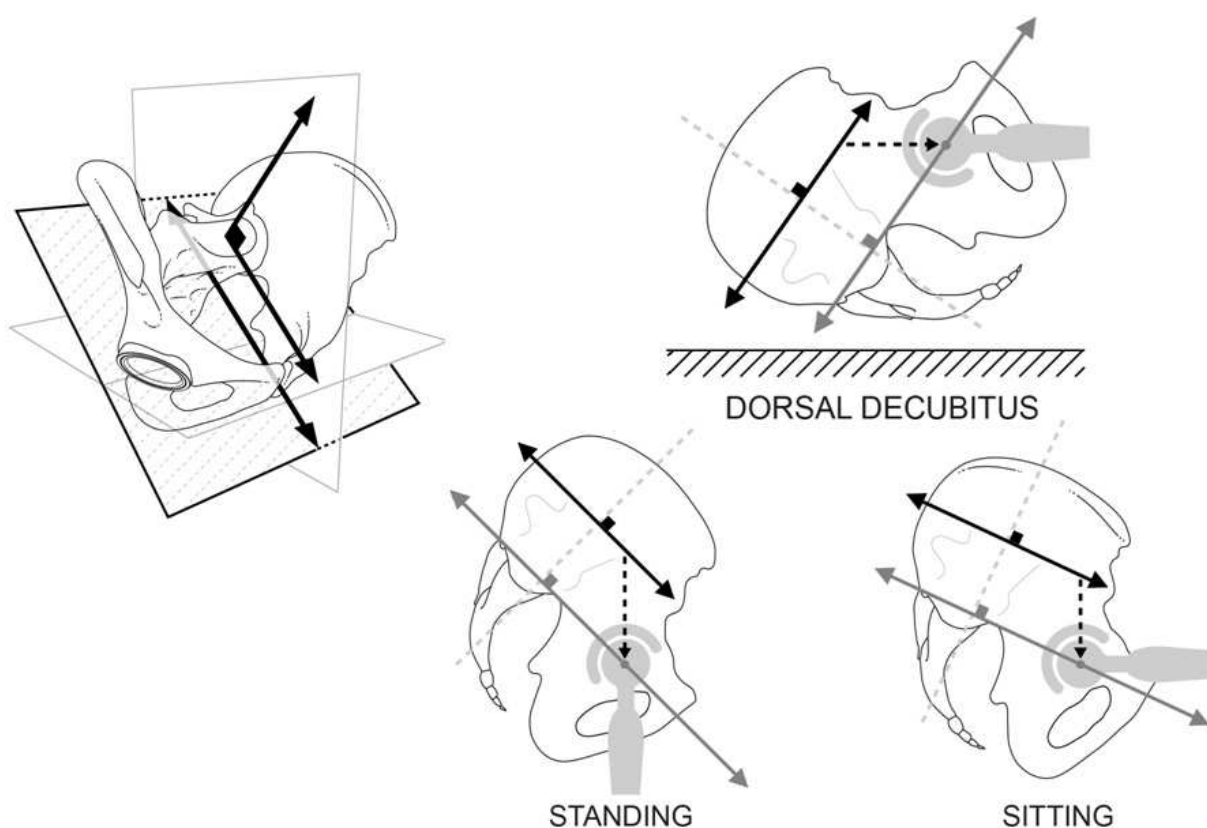


Fig. 16. Anatomic acetabular anteversion can be measured on CT scans according to a plane perpendicular to the anterior pelvic plane (Lewinnek's plane): the cut plane analyzes the acetabulum according to the same orientation, regardless of the subject's position. The anteversion value is the same in all of the positions

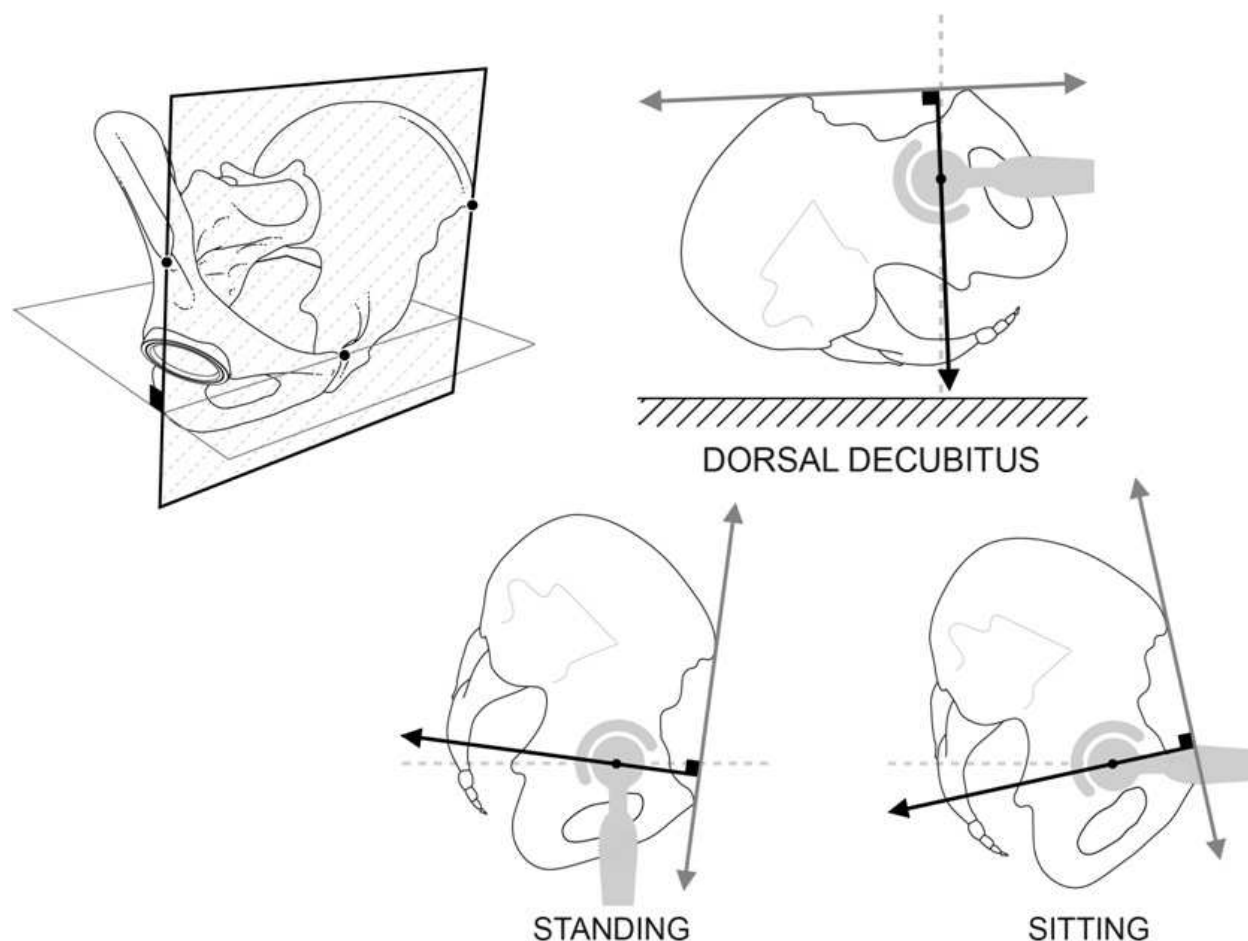


Fig. 17. Anatomic or morphologic anteversion can be measured reliably by using the reference transverse plane through the upper sacral endplate (the sacral transverse plane): the anteversion value refers exclusively to the pelvic bone landmarks without taking into account the variations of position. The anteversion value is the same in all of the positions

4.2 The concept of functional anteversion

An accurate understanding of lumbosacral posture and its influence on cup tilt shows us that the measurement of anteversion must not be linked to an arbitrary orientation of the slices to the machine stand (Anda et al., 1990). This point is essential for assessing the real acetabular anteversion of THA in terms of instability, especially when the lumbosacral joint is stiffened or in an atypical position (Eddine et al., 2001; Lembeck et al., 2005; Terver et al., 1982). The concept of functional standing and sitting anteversion has been defined to address this problem. The functional anteversion values are the projected angles measured in the horizontal transverse plane, for any of the positions of the pelvis, reflecting the different amount of anterior opening which varies as a function of pelvic tilt (Fig. 18a and b).

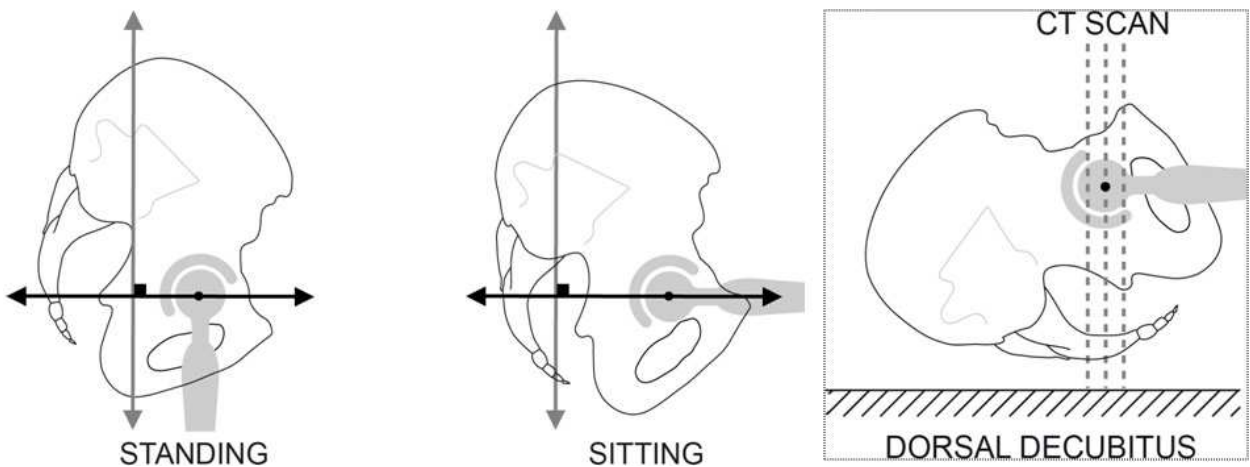


Fig. 18. a: The horizontal transverse plane can be used as a reference plane; the relation with the acetabulum is different according to the standing or seated positions. In current practice, anteversion is measured on CT scans but the angle value depends on the pelvic orientation in the lying position. Fortuitously, the cross-sectional slices, perpendicular to the plane of the examination table, can also be strictly perpendicular to the longitudinal axis of the pelvic bone frame. But, most of the time, these slices do not correspond to this anatomic plane because the position of the supine subject has a more or less marked sagittal pelvic tilt

It is calculated from the CT scan slices taken as a function of the sacral slope measured on the initial standard lateral image. In a plane with the upper sacral endplate, these slices reconstitute the sacral tilt angle, measured in a standing, sitting, or supine position. They make it possible to observe important changes in the cup orientation and improve our understanding of some coxofemoral joint dysfunctions.

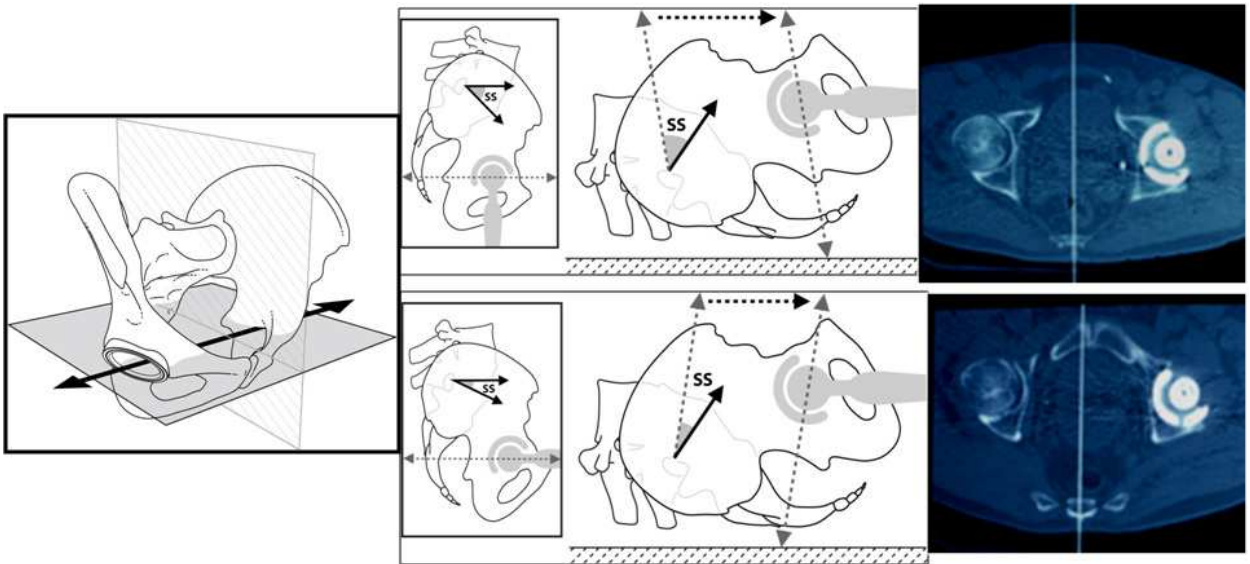


Fig. 18. b: The functional anteversion values are the projected angles measured in the horizontal transverse plane, for any of the positions of the pelvis, reflecting the different amount of anterior opening which varies as a function of pelvic tilt. The measurement of the functional anteversion corresponding to standing and sitting positions can be done using CT scan : it requires an adjustment of the sectional plane following the value of the SS on lateral radiographs with the patients in standing and sitting positions

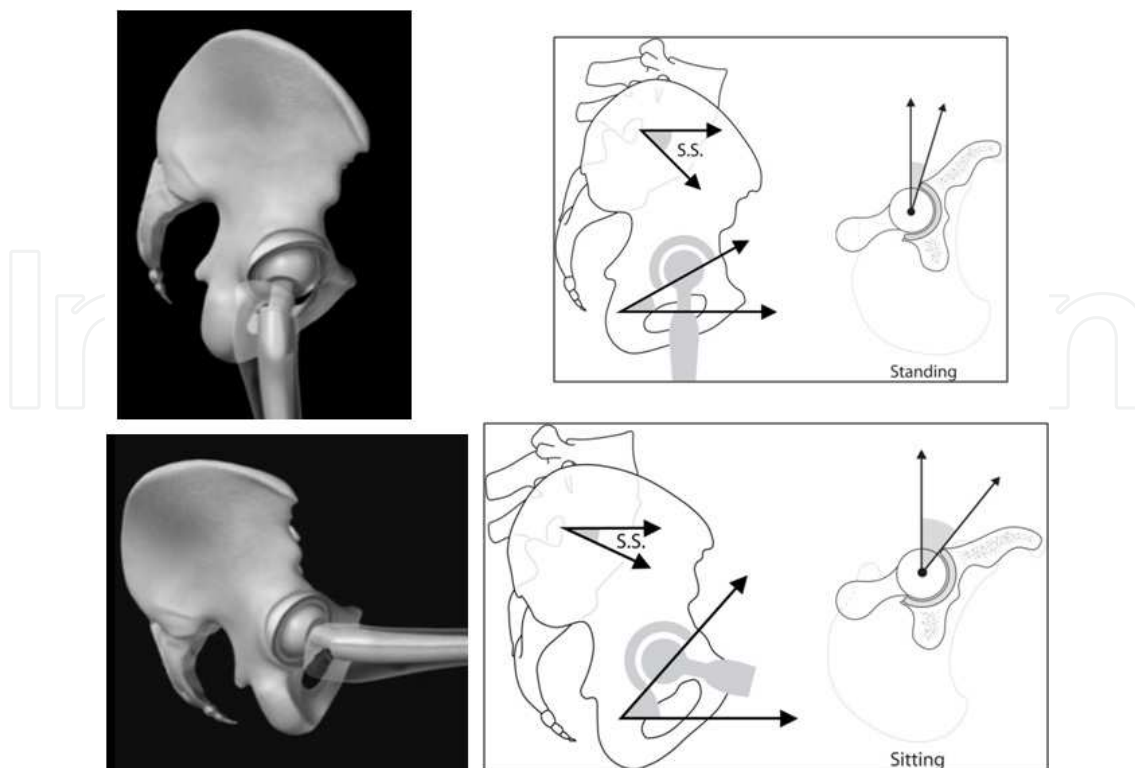


Fig. 19. In standing positions, there is less cross-sectional anteversion than in sitting positions, where the cup opens completely forward, thus favoring flexion of the hip and avoiding impingement at the femoral neck

In standing positions, there is less cross-sectional anteversion than in sitting positions, where the cup opens completely forward, thus favoring flexion of the hip and avoiding impingement at the femoral neck (**Fig. 19**). In supine positions, with the lower limbs extended, the pelvic tilt is often greater than in standing positions, lordosis more accentuated and anteversion still more reduced than when standing. In a series of 328 THAs, we reported a mean anteversion of 31.7° standing, 38.8° seated, and 24.2° supine (Lazennec et al., 2011a). The strong correlation observed between the supine and standing measurements suggests that the classic CT assessment of the anatomic acetabular anteversion is still a relevant source of information in cases of anterior THA dislocation and subluxation. But poor correlations have been reported between the supine and sitting positions; they demonstrate that the usual CT scan protocol is biased and not fully appropriate in an investigation of posterior THA dislocation, which occurs in hip flexion (Lazennec et al., 2011a).

Globally, the "standard" CT scan measurements tend to overestimate anteversion in standing positions and to underestimate it in seated positions. More or less, 1° of pelvic tilt affects acetabular anteversion by 0.5 to 1° , depending on the specific study (Anda et al., 1990; Lazennec et al., 2004). Some subjects have completely stiff lumbosacral joints, and this significantly reduces the variations in acetabular anteversion between seated and standing positions. Such stiffening of the pelvis, in either a relative anterior or posterior tilt, may lead to a reproducible impingement situation. This phenomenon has been documented in the literature for deformities of the sagittal plane in spondylarthritis, in poorly adjusted lumbosacral arthrodesis (flat back), and especially in spinal aging (During et al., 1985; Fogel & Esses, 2003; Hammerberg & Wood, 2003; Itoi, 1991; Lazennec et al., 1997; Offierski &

MacNab, 1983). In these cases, we observed a reduction in lordosis and the appearance of an adaptive posterior pelvic tilt. The patient is standing, as if he were seated. This phenomenon reduces adaptation in the lumbosacral area and deviates the functional mobility cone of the coxofemoral joints towards flexion. The cup is permanently in hyper-anteversion, which is not bothersome during hip flexion but creates a problem of posterior impingement, especially in a standing position: the person progressively loses his or her available extension (**Fig. 20**).

The compensating hyperextension of the hips often has a limited impact in these patients, especially those who are elderly or have hip disorders. The last adaptation to attempt to improve balance is thus flexion of the knees, which enables additional posterior tilt of the pelvis. This phenomenon explains prosthesis dislocation after several years, following an overall sagittal disruption of the lumbo-pelvic-femoral complex (Legaye, 2009; Rousseau et al., 2009; Tang et al., 2007).

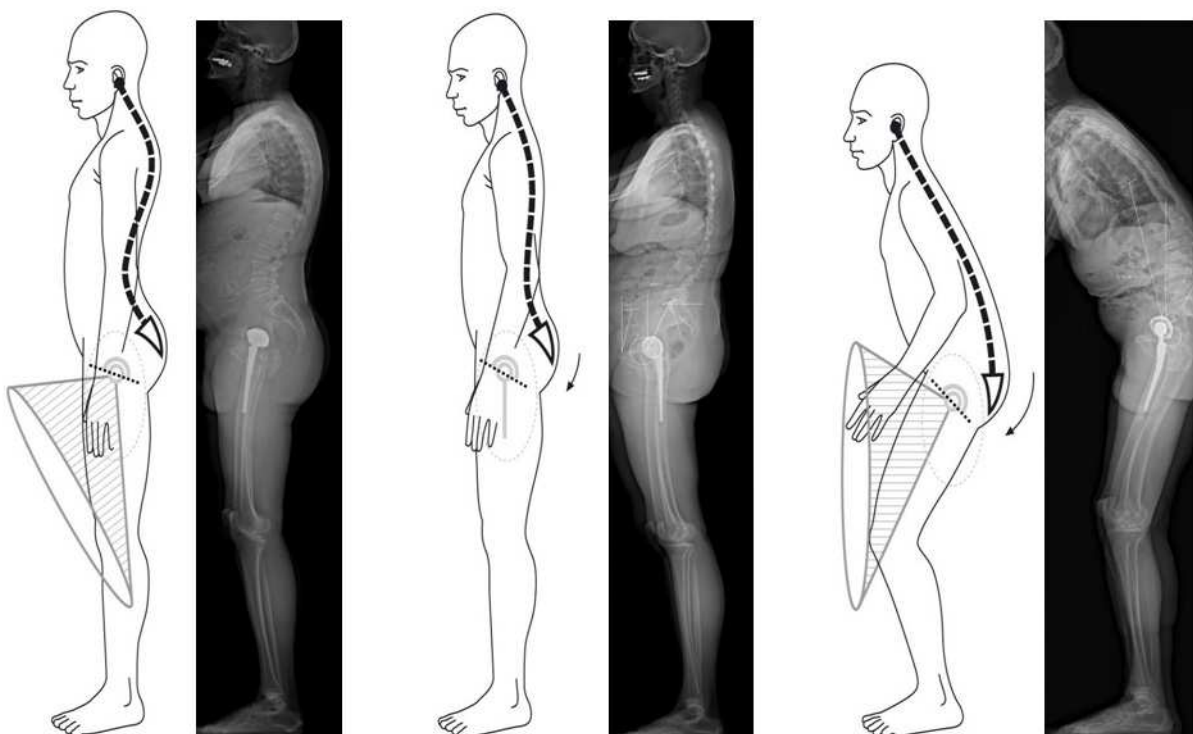


Fig. 20. Reduction in lordosis and the appearance of an adaptive posterior pelvic tilt has been documented in deformities of the sagittal plane in spondylarthritis, in poorly adjusted lumbosacral arthrodesis (flat back), and especially in spinal aging : This phenomenon reduces adaptation in the lumbosacral area and deviates the functional mobility cone of the coxofemoral joints towards flexion

5. Influence of axial rotation of the pelvis and the lumbopelvic region

Hip surgeons define a "normal" pelvic posture for imaging work-ups of subjects in a strictly anatomic position, with the two iliac wings projecting exactly and symmetrically, compared with the longitudinal axis of the trunk. Spine surgeons have been made aware of the three-dimensional view of the spine and the phenomenon of vertebral rotation that disturbs analysis of the lateral view. In this framework, the concept of the pelvic vertebra leads us to

integrate pelvic rotation into the analysis of the overall trunk posture (Dubousset et al., 2007). The use of standing and seated EOS® images in the subject's "usual" position is particularly instructive. Our database of complete EOS® acquisitions, both standing and seated, from more than 2500 patients reveals the frequency of cases involving a forward hemipelvis and therefore a backward contralateral hemipelvis. This is expressed on the AP image by asymmetry of the projection of the iliac wings; the "forward" wing appears thinner than the other. Laterally, the two femoral heads and the two iliac wings are not superimposed (**Fig. 21**).

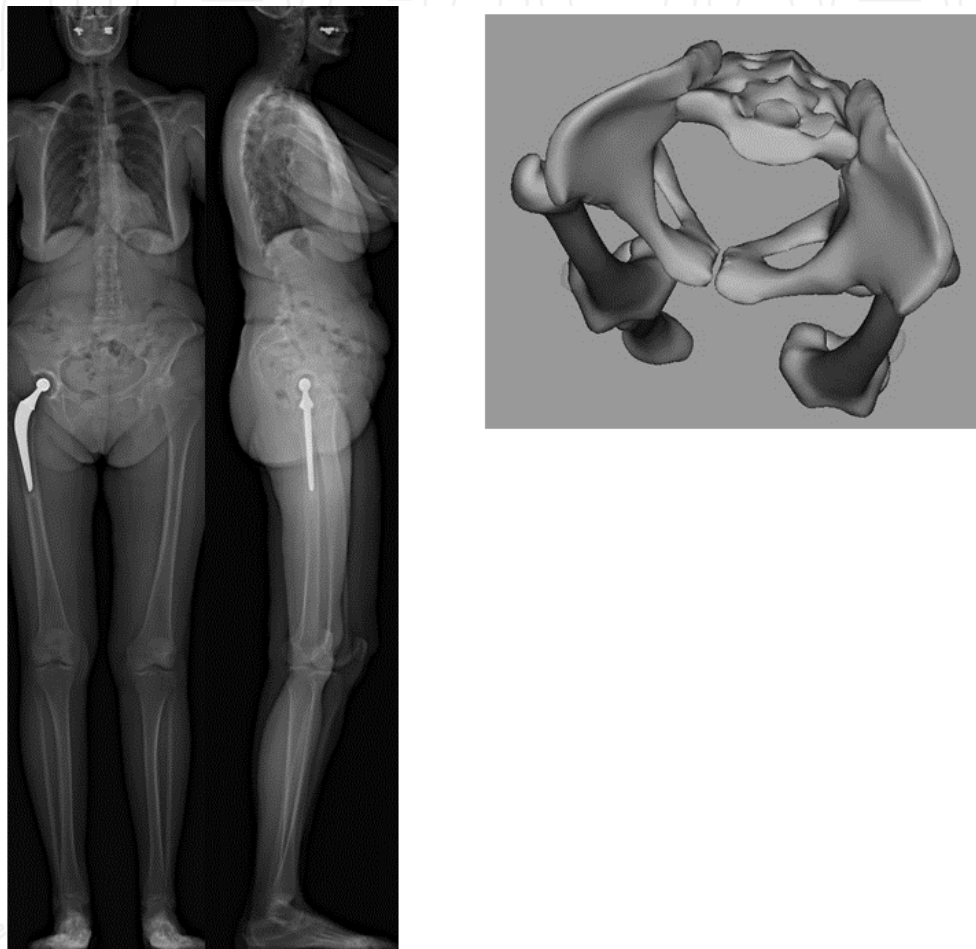


Fig. 21. This "twisting" phenomenon of the pelvis is expressed on the AP image by asymmetry of the projection of the iliac wings; the "forward" wing appears thinner than the other. Laterally, the two femoral heads and the two iliac wings are not superimposed

This "twisting" phenomenon is difficult to quantify with standard radiography because of the cone-shaped distribution of X-rays, which distorts interpretation of the image of the femoral head furthest from the scanner source. On the other hand, it is well analyzed by EOS® images in both the standing and seated positions, and 3D visualization of the pelvic position is possible. This situation of pelvic rotation is pushed to extremes in cases of scoliosis with the pelvic vertebrae included in the deformity (**Fig. 22**). The consequences on cup orientation can be significant, in particular for patients with THA, because of the induction of changes in functional anteversion, in both standing and seated positions (Tannast et al., 2005).

The impact of pelvic rotation and of the pelvic tilt on acetabular orientation raises the question of the choices of guidelines for pre- and postoperative evaluation in cases of hip replacement surgery. The use of guidelines depending on the pelvic bone (anterior pelvic plane, sacral transverse plane, axis through the femoral heads) neglects these two essential phenomena (Lazennec et al., 2007; Tannast et al., 2005). The use of the horizontal transverse plane (or the horizontal plane in space) makes it possible to integrate pelvic tilt into the assessment of acetabular anteversion, which can thus be envisioned "functionally" and not only restrictively as a simple fixed morphologic parameter. Pelvic rotation must be considered and assessed just like vertebral rotation, as analyzed by spine surgeons, compared with a vertical plane of reference perpendicular to the horizontal transverse plane.

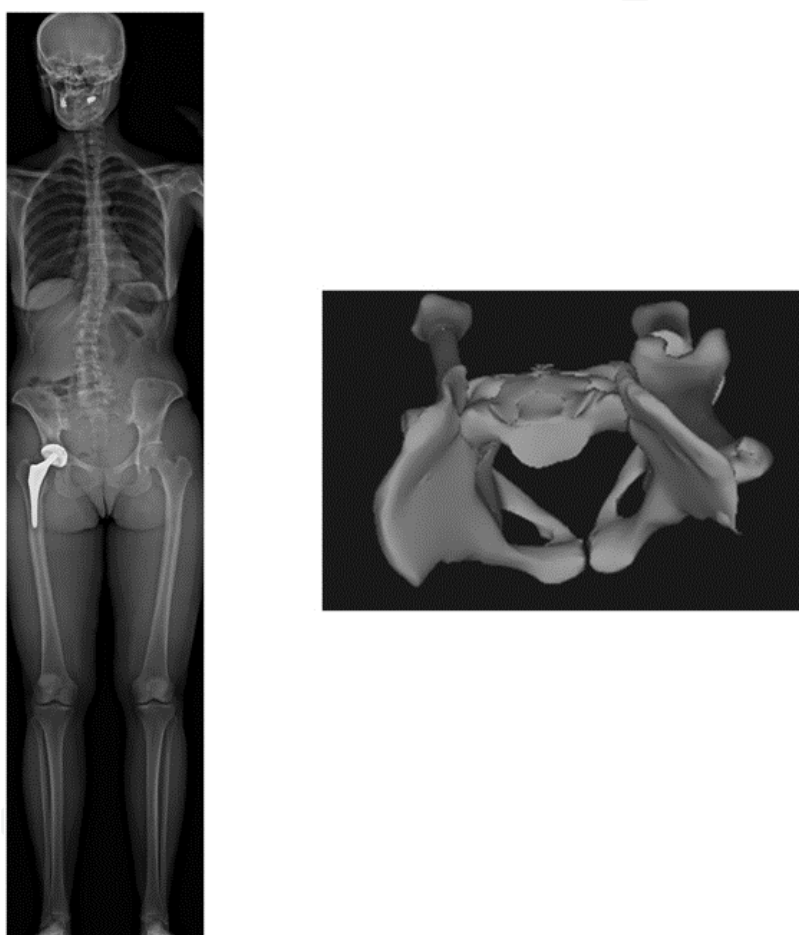

Fig. 22. Pelvic rotation is pushed to extremes in cases of scoliosis with the pelvic vertebrae included in the deformity

6. Conclusions

Comprehensive analysis of the pelvic and subpelvic sectors as part of the sagittal, frontal and cross-sectional balance of the trunk sheds new light on some spinal diseases and their relation to the pelvis. Stiffness in the lumbar spine and lumbosacral fusion, both seen in everyday practice, are significant risk factors for THA subluxation and dislocation due to the lack of variation in the acetabular anteversion from a standing to a sitting position. This

concept is not yet well defined, but our data suggest that taking spinal flexibility into account is important when planning a THA implantation, or at least identifying the unusual patients who have an abnormal pelvic (i.e. acetabular) posture.

Knowledge of the biomechanics of the lumbosacral joint is relevant for the hip surgeon performing hip replacements in elderly subjects or in those with abnormal sagittal, frontal or rotational posture and/or a large reduction in functional range of motion. Analysis of sagittal balance must therefore be individual and integrated into the comprehensive evolution of the subject over time, because the phenomenon of an aging spine is frequently associated with the process of aging hips.

The analysis of acetabular orientation cannot be limited to the frontal orientation of the acetabular cup on the AP view and the lateral view of the hip should be considered: standing, sitting, and squatting positions correspond to changes in spinal orientation and acetabular sagittal tilt. The relation between the position of the spine and the acetabulum has a direct influence on the real functional range of motion of the hips. Anterior pelvic plane, pelvic tilt and sacral slope variations are relevant parameters for planning and navigation.

The mobility of the lumbosacral junction is a crucial parameter in the mechanical function and the stability of THAs, especially in elderly populations. With the increase of the survival of THA, spinal aging and progressive pelvic posterior version must now to be taken into account. Late dislocations of mechanical origin have been reported: modifications of the biomechanics of the spine, transmitted to the hip, may be responsible. The standard measurement of anatomic acetabular anteversion on CT scan images in a supine position should be carefully interpreted as it can induce a false or approximate analysis of the acetabular cup position from a functional standpoint. The analysis of pelvic morphology based on the incidence angle may provide new information about THR dysfunction and abnormal wear, especially in patients with unusual postures.

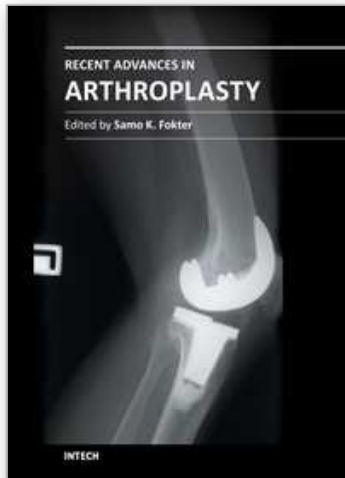
7. References

- Ackland, M.K., Bourne, W.B., & Uthoff, H.K. (1986). Anteversion of the acetabular cup. Measurement of angle after total hip replacement. *J Bone Joint Surg Br*, 68, 409-413.
- Anda, S., Svenningsen, S., Grontvedt, T., & Benum, P. (1990). Pelvic inclination and spatial orientation of the acetabulum. A radiographic, computed tomographic and clinical investigation. *Acta Radiol*, 31, 389-394.
- Aubry, S., Marinescu, A., Forterre, O., Runge, M., & Garbuio, P. (2005). [Definition of a reproducible method for acetabular anteversion measurement at CT]. *J Radiol*, 86, 399-404.
- Bolger, C., Kelleher, M.O., McEvoy, L., Brayda-Bruno, M., Kaelin, A., Lazennec, J.Y., et al. (2007). Electrical conductivity measurement: a new technique to detect iatrogenic initial pedicle perforation. *Eur Spine J*, 16, 1919-1924.
- Boulay, C., Tardieu, C., Hecquet, J., Benaim, C., Mouilleseaux, B., Marty, C., et al. (2006). Sagittal alignment of spine and pelvis regulated by pelvic incidence: standard values and prediction of lordosis. *Eur Spine J*, 15, 415-422.
- Chanplakorn, P., Wongsak, S., Woratanarat, P., Wajanavisit, W., & Laohacharoensombat, W. (2011). Lumbopelvic alignment on standing lateral radiograph of adult volunteers and the classification in the sagittal alignment of lumbar spine. *Eur Spine J*, 20, 706-712.

- D'Lima, D.D., Urquhart, A.G., Buehler, K.O., Walker, R.H., & Colwell, C.W., Jr. (2000). The effect of the orientation of the acetabular and femoral components on the range of motion of the hip at different head-neck ratios. *J Bone Joint Surg Am*, 82, 315-321.
- Dorr, L.D., Wolf, A.W., Chandler, R., & Conaty, J.P. (1983). Classification and treatment of dislocations of total hip arthroplasty. *Clin Orthop Relat Res*, 151-158.
- Dubousset, J. (1984). Le bassin « os intercalaire ». . *Monographie du GES*, 15-22.
- Dubousset, J., Charpak, G., Skalli, W., de Guise, J., Kalifa, G., & Wicart, P. (2008). [Skeletal and spinal imaging with EOS system]. *Arch Pediatr*, 15, 665-666.
- Dubousset, J., Charpak, G., Skalli, W., Kalifa, G., & Lazenec, J.Y. (2007). [EOS stereo-radiography system: whole-body simultaneous anteroposterior and lateral radiographs with very low radiation dose]. *Rev Chir Orthop Reparatrice Appar Mot*, 93, 141-143.
- During, J., Goudfrooij, H., Keessen, W., Beeker, T.W., & Crowe, A. (1985). Toward standards for posture. Postural characteristics of the lower back system in normal and pathologic conditions. *Spine (Phila Pa 1976)*, 10, 83-87.
- Duval-Beaupere, G., Schmidt, C., & Cosson, P. (1992). A Barycentremetric study of the sagittal shape of spine and pelvis: the conditions required for an economic standing position. *Ann Biomed Eng*, 20, 451-462.
- Eddine, T.A., Migaud, H., Chantelot, C., Cotten, A., Fontaine, C., & Duquenois, A. (2001). Variations of pelvic anteversion in the lying and standing positions: analysis of 24 control subjects and implications for CT measurement of position of a prosthetic cup. *Surg Radiol Anat*, 23, 105-110.
- Fogel, G.R., & Esses, S.I. (2003). Hip spine syndrome: management of coexisting radiculopathy and arthritis of the lower extremity. *Spine J*, 3, 238-241.
- Hammerberg, E.M., & Wood, K.B. (2003). Sagittal profile of the elderly. *J Spinal Disord Tech*, 16, 44-50.
- Herrlin, K., Selvik, G., Pettersson, H., Kesek, P., Onnerfalt, R., & Ohlin, A. (1988). Position, orientation and component interaction in dislocation of the total hip prosthesis. *Acta Radiol*, 29, 441-444.
- Itoi, E. (1991). Roentgenographic analysis of posture in spinal osteoporotics. *Spine (Phila Pa 1976)*, 16, 750-756.
- Jackson, R.P., & McManus, A.C. (1994). Radiographic analysis of sagittal plane alignment and balance in standing volunteers and patients with low back pain matched for age, sex, and size. A prospective controlled clinical study. *Spine (Phila Pa 1976)*, 19, 1611-1618.
- Kennedy, J.G., Rogers, W.B., Soffe, K.E., Sullivan, R.J., Griffen, D.G., & Sheehan, L.J. (1998). Effect of acetabular component orientation on recurrent dislocation, pelvic osteolysis, polyethylene wear, and component migration. *J Arthroplasty*, 13, 530-534.
- Kobayashi, T., Atsuta, Y., Matsuno, T., & Takeda, N. (2004). A longitudinal study of congruent sagittal spinal alignment in an adult cohort. *Spine (Phila Pa 1976)*, 29, 671-676.
- Kummer, F.J., Shah, S., Iyer, S., & DiCesare, P.E. (1999). The effect of acetabular cup orientations on limiting hip rotation. *J Arthroplasty*, 14, 509-513.
- Lafage, V., Schwab, F., Patel, A., Hawkinson, N., & Farcy, J.P. (2009). Pelvic tilt and truncal inclination: two key radiographic parameters in the setting of adults with spinal deformity. *Spine (Phila Pa 1976)*, 34, E599-606.

- Lazennec, J.Y., Boyer, P., Gorin, M., Catonne, Y., & Rousseau, M.A. (2011a). Acetabular Anteversion with CT in Supine, Simulated Standing, and Sitting Positions in a THA Patient Population. *Clin Orthop Relat Res*, 469, 1103-1109.
- Lazennec, J.Y., Charlot, N., Gorin, M., Roger, B., Arafati, N., Bissery, A., et al. (2004). Hip-spine relationship: a radio-anatomical study for optimization in acetabular cup positioning. *Surg Radiol Anat*, 26, 136-144.
- Lazennec, J.Y., Ramare, S., Arafati, N., Laudet, C.G., Gorin, M., Roger, B., et al. (2000). Sagittal alignment in lumbosacral fusion: relations between radiological parameters and pain. *Eur Spine J*, 9, 47-55.
- Lazennec, J.Y., Riwan, A., Gravez, F., Rousseau, M.A., Mora, N., Gorin, M., et al. (2007). Hip spine relationships: application to total hip arthroplasty. *Hip Int*, 17 Suppl 5, S91-104.
- Lazennec, J.Y., Rousseau, M.A., Rangel, A., Gorin, M., Belicourt, C., Brusson, A., et al. (2011b). Pelvis and total hip arthroplasty acetabular component orientations in sitting and standing positions: Measurements reproductibility with EOS imaging system versus conventional radiographies. *Orthop Traumatol Surg Res*.
- Lazennec, J.Y., Rousseau, M.A., Rangel, A., Gorin, M., Belicourt, C., Brusson, A., et al. (2011c). Pelvis and total hip arthroplasty acetabular component orientations in sitting and standing positions: Measurements reproductibility with EOS imaging system versus conventional radiographies. *Orthop Traumatol Surg Res*, 97, 373-380.
- Lazennec, J.Y., Saillant, G., Saidi, K., Arafati, N., Barabas, D., Benazet, J.P., et al. (1997). Surgery of the deformities in ankylosing spondylitis: our experience of lumbar osteotomies in 31 patients. *Eur Spine J*, 6, 222-232.
- Legaye, J. (2009). Influence of the sagittal balance of the spine on the anterior pelvic plane and on the acetabular orientation. *Int Orthop*, 33, 1695-1700.
- Legaye, J., Duval-Beaupere, G., Hecquet, J., & Marty, C. (1998). Pelvic incidence: a fundamental pelvic parameter for three-dimensional regulation of spinal sagittal curves. *Eur Spine J*, 7, 99-103.
- Lembeck, B., Mueller, O., Reize, P., & Wuelker, N. (2005). Pelvic tilt makes acetabular cup navigation inaccurate. *Acta Orthop*, 76, 517-523.
- Lewinnek, G.E., Lewis, J.L., Tarr, R., Compere, C.L., & Zimmerman, J.R. (1978). Dislocations after total hip-replacement arthroplasties. *J Bone Joint Surg Am*, 60, 217-220.
- McKibbin, B. (1970). Anatomical factors in the stability of the hip joint in the newborn. *J Bone Joint Surg Br*, 52, 148-159.
- Muller, O., Lembeck, B., Reize, P., & Wulker, N. (2005). [Quantification and visualization of the influence of pelvic tilt upon measurement of acetabular inclination and anteversion]. *Z Orthop Ihre Grenzgeb*, 143, 72-78.
- Murray, D.W. (1993). The definition and measurement of acetabular orientation. *J Bone Joint Surg Br*, 75, 228-232.
- Offierski, C.M., & MacNab, I. (1983). Hip-spine syndrome. *Spine (Phila Pa 1976)*, 8, 316-321.
- Philippot, R., Wegrzyn, J., Farizon, F., & Fessy, M.H. (2009). Pelvic balance in sagittal and Lewinnek reference planes in the standing, supine and sitting positions. *Orthop Traumatol Surg Res*, 95, 70-76.
- Pradhan, R. (1999). Planar anteversion of the acetabular cup as determined from plain anteroposterior radiographs. *J Bone Joint Surg Br*, 81, 431-435.

- Rillardon, L., Levassor, N., Guigui, P., Wodecki, P., Cardinne, L., Templier, A., et al. (2003). [Validation of a tool to measure pelvic and spinal parameters of sagittal balance]. *Rev Chir Orthop Reparatrice Appar Mot*, 89, 218-227.
- Rousseau, M.A., Lazennec, J.Y., Boyer, P., Mora, N., Gorin, M., & Catonne, Y. (2009). Optimization of total hip arthroplasty implantation: is the anterior pelvic plane concept valid? *J Arthroplasty*, 24, 22-26.
- Roussouly, P., Gollogly, S., Berthonnaud, E., & Dimnet, J. (2005). Classification of the normal variation in the sagittal alignment of the human lumbar spine and pelvis in the standing position. *Spine (Phila Pa 1976)*, 30, 346-353.
- Seki, M., Yuasa, N., & Ohkuni, K. (1998). Analysis of optimal range of socket orientations in total hip arthroplasty with use of computer-aided design simulation. *J Orthop Res*, 16, 513-517.
- Tang, W.M., Chiu, K.Y., Kwan, M.F., & Ng, T.P. (2007). Sagittal pelvic mal-rotation and positioning of the acetabular component in total hip arthroplasty: Three-dimensional computer model analysis. *J Orthop Res*, 25, 766-771.
- Tannast, M., Langlotz, U., Siebenrock, K.A., Wiese, M., Bernsmann, K., & Langlotz, F. (2005). Anatomic referencing of cup orientation in total hip arthroplasty. *Clin Orthop Relat Res*, 144-150.
- Tassin (2004). Equilibre sagittal du rachis. *Cahier d'enseignement de la SOFCOT*, 85, 241-269.
- Terver, S., Dillingham, M., Parker, B., Bjorke, A., Bleck, E.E., Levai, J.P., et al. (1982). [True orientation of the acetabulum as determined by CAT scan. Preliminary results (author's transl)]. *J Radiol*, 63, 167-173.
- Vaz, G., Roussouly, P., Berthonnaud, E., & Dimnet, J. (2002). Sagittal morphology and equilibrium of pelvis and spine. *Eur Spine J*, 11, 80-87.
- Vialle, R., Levassor, N., Rillardon, L., Templier, A., Skalli, W., & Guigui, P. (2005). Radiographic analysis of the sagittal alignment and balance of the spine in asymptomatic subjects. *J Bone Joint Surg Am*, 87, 260-267.
- von Knoch, M., Berry, D.J., Harmsen, W.S., & Morrey, B.F. (2002). Late dislocation after total hip arthroplasty. *J Bone Joint Surg Am*, 84-A, 1949-1953.
- Wan, Z., Malik, A., Jaramaz, B., Chao, L., & Dorr, L.D. (2009). Imaging and navigation measurement of acetabular component position in THA. *Clin Orthop Relat Res*, 467, 32-42.
- Watanabe, W., Sato, K., Itoi, E., Yang, K., & Watanabe, H. (2002). Posterior pelvic tilt in patients with decreased lumbar lordosis decreases acetabular femoral head covering. *Orthopedics*, 25, 321-324.
- Woo, R.Y., & Morrey, B.F. (1982). Dislocations after total hip arthroplasty. *J Bone Joint Surg Am*, 64, 1295-1306.
- Woolson, S.T., & Rahimtoola, Z.O. (1999). Risk factors for dislocation during the first 3 months after primary total hip replacement. *J Arthroplasty*, 14, 662-668.
- Yamaguchi, M., Bauer, T.W., & Hashimoto, Y. (1997). Three-dimensional analysis of multiple wear vectors in retrieved acetabular cups. *J Bone Joint Surg Am*, 79, 1539-1544.



Recent Advances in Arthroplasty

Edited by Dr. Samo Fokter

ISBN 978-953-307-990-5

Hard cover, 614 pages

Publisher InTech

Published online 27, January, 2012

Published in print edition January, 2012

The purpose of this book was to offer an overview of recent insights into the current state of arthroplasty. The tremendous long term success of Sir Charnley's total hip arthroplasty has encouraged many researchers to treat pain, improve function and create solutions for higher quality of life. Indeed and as described in a special chapter of this book, arthroplasty is an emerging field in the joints of upper extremity and spine. However, there are inborn complications in any foreign design brought to the human body. First, in the chapter on infections we endeavor to provide a comprehensive, up-to-date analysis and description of the management of this difficult problem. Second, the immune system is faced with a strange material coming in huge amounts of micro-particles from the tribology code. Therefore, great attention to the problem of aseptic loosening has been addressed in special chapters on loosening and on materials currently available for arthroplasty.

How to reference

In order to correctly reference this scholarly work, feel free to copy and paste the following:

Jean Yves Lazennec, Adrien Brusson and Marc-Antoine Rousseau (2012). Hip-Spine Relations: An Innovative Paradigm in THR Surgery, Recent Advances in Arthroplasty, Dr. Samo Fokter (Ed.), ISBN: 978-953-307-990-5, InTech, Available from: <http://www.intechopen.com/books/recent-advances-in-arthroplasty/hip-spine-relations-an-innovative-paradigm-in-thr-surgery>

INTech
open science | open minds

InTech Europe

University Campus STeP Ri
Slavka Krautzeka 83/A
51000 Rijeka, Croatia
Phone: +385 (51) 770 447
Fax: +385 (51) 686 166
www.intechopen.com

InTech China

Unit 405, Office Block, Hotel Equatorial Shanghai
No.65, Yan An Road (West), Shanghai, 200040, China
中国上海市延安西路65号上海国际贵都大饭店办公楼405单元
Phone: +86-21-62489820
Fax: +86-21-62489821

© 2012 The Author(s). Licensee IntechOpen. This is an open access article distributed under the terms of the [Creative Commons Attribution 3.0 License](https://creativecommons.org/licenses/by/3.0/), which permits unrestricted use, distribution, and reproduction in any medium, provided the original work is properly cited.

IntechOpen

IntechOpen