

We are IntechOpen, the world's leading publisher of Open Access books Built by scientists, for scientists

6,900

Open access books available

185,000

International authors and editors

200M

Downloads

Our authors are among the

154

Countries delivered to

TOP 1%

most cited scientists

12.2%

Contributors from top 500 universities



WEB OF SCIENCE™

Selection of our books indexed in the Book Citation Index
in Web of Science™ Core Collection (BKCI)

Interested in publishing with us?
Contact book.department@intechopen.com

Numbers displayed above are based on latest data collected.
For more information visit www.intechopen.com



Abnormal Electrocardiogram in Patients with Acute Aluminum Phosphide Poisoning

Amine Ali Zeggwagh and Maha Louriz

*Medical Intensive Care Unit - Faculty of Medicine and Pharmacy,
University Mohamed V, Rabat,
Morocco*

1. Introduction

Aluminum phosphide (AIP) is used throughout the world as pesticides to protect stored grains from rodents and other pests (**Cienki, 2001**). The chemical is usually formulated in pellets, granules or as a dust. Upon contact with moisture in the environment, AIP undergoes a chemical reaction yielding phosphine gas (PH_3), which is the active pesticidal component and a very toxic system poison, makes acute AIP poisoning (AAIPP) extremely dangerous (**Sasser et al., 1998**).

AAIPP has been reported in literature since 1985. The majority of cases of AIP poisoning involving intentional suicide acts. It is a major health problem with a high mortality rate especially in developing countries where AIP is low cost and easily accessible (**Mehpour et al., 2008; Louriz et al., 2009**). Patients who intend to commit suicide take tablets. Once mixed with hydrochloric acid in the stomach, PH_3 is immediately released and absorbed rapidly via the lungs causing systemic poisoning (**Proudfoot, 2009**). However, accidental exposure to AIP is a relatively common cause of poisoning from agriculture chemical exposure in many countries. The manufacture and application of AIP fumigants pose risks of inhalation exposure to PH_3 (**Sudakin, 2005**).

During the past 35 years, high mortality rates have been reported following significant exposures to aluminum phosphide. This mortality rates vary from 40% to 80% (**Chugh et al., 1991**).

2. Toxicology of phosphine gas

The toxicity of AIP is attributed to the liberation of PH_3 gas which is cytotoxic and causes free radical mediated injury (**Sudakin, 2005**).

PH_3 a nucleophile, acts as a strong reducing agent capable of inhibiting cellular enzymes involved in several metabolic processes. Early studies on PH_3 demonstrated specific inhibitory effects on mitochondrial cytochrome c oxidase. Experimental and observational studies have subsequently demonstrated that the inhibition of cytochrome c oxidase and other enzymes leads to the generation superoxide radicals and cellular peroxides. Cellular

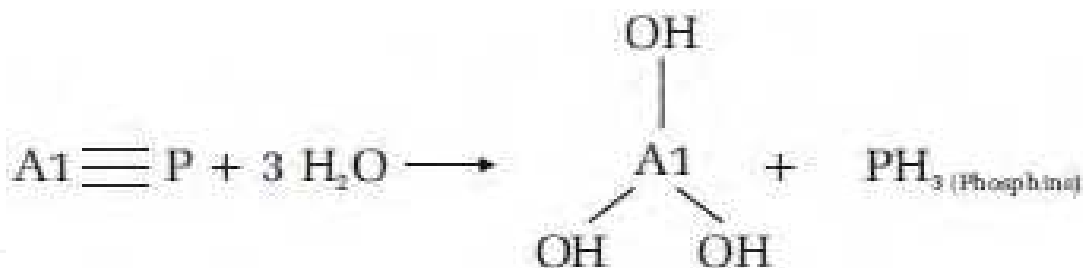


Fig. 1. Aluminum phosphide and liberation of phosphine gas. $\text{Al} \equiv \text{P}$: aluminum phosphide ; PH_3 : phosphine gas

injury subsequently occurs through lipid peroxidation and other oxidant mechanisms (Chugh et al., 1996). Indeed, significant decreases in glutathione concentrations were shown in different tissues during ALP poisoning (Hsu et al., 2002). Glutathione is known to be an important factor protecting against oxidation by catalyzing the reduction of the oxygen peroxide in O_2 and H_2O .

Mutagenic effects resulting from oxidative damage to DNA have been reported in vitro. A cytogenetic study of phosphide fumigant applicators reported a significantly higher incidence of chromatid gaps and deletions in comparison to controls (Hsu et al., 1998).

Very little information is available relating to the toxicokinetics of PH_3 in humans. In an investigation of a series of patients with acute ALP poisoning, indicators of oxidative stress (malonydialdehyde levels, superoxide dismutase and catalase activity) appeared to peak within 48 hours of exposure, with normalization of most indicators occurring by day 5 (Chugh et al., 1996a). Chugh et al. reported that, serum PH_3 levels correlate positively with the severity of poisoning and levels equal to or less than $1.067 \pm 0.16 \text{ mg \%}$ appear to be the limit of PH_3 toxicity (Chugh et al., 1996b).

A bedside test has been described for the diagnosis of ALP ingestion, using gastric aspirates and paper strips impregnated with silver nitrate. The test was found to be positive in 100% of cases of ALP ingestion (Chugh et al., 1994). The same test was also investigated to detect PH_3 gas in the exhaled air of patients with intoxication with ALP ingestion, and the results were positive in 50 % of cases.

3. Acute aluminum phosphide poisoning

3.1 Clinical features of AAIPP

AAIPP results in the rapid onset of gastrointestinal signs and symptoms, including epigastric pain and recurrent, profuse vomiting. Characteristic garlic smell of PH_3 in the patient's expired breath. Cardiovascular manifestations include hypotension and profound circulatory collapse. Neurological manifestations following acute poisoning include headache, anxiety and dizziness, frequently accompanied by a normal mental state (National Institute of occupational Safety and Health [NIOSH], 2003). Pulmonary injury and oedema have been described. Acute renal and liver injury can also develop. The prognosis from suicidal ingestion of ALP is poor.

The major lethal consequence of AAIPP, myocardial suppression with profound circulatory collapse, is reportedly secondary to toxins generated, which lead to direct effects on cardiac myocytes, fluid loss induced by several episodes of vomiting and adrenal gland damage. The AAIPP is involving young patients without history of cardiac diseases. However,

clinical, biological, electrical and histological observations suggest that myocardial involvement is responsible for the acute circulatory insufficiency (Lall et al., 1997).

3.2 Biological abnormalities in AAIPP

Increased CK with raised cardiac marker CK-MB fraction has been previously reported point to severe myocardial damage (Nakakita et al., 2009). Controversies exist about the magnesium level and prognosis of AAIPP. Some studies seem to suggest that there is hypomagnesaemia associated with AAIPP and that there is a direct relationship between abnormal electrocardiographic findings and low magnesium levels. They report reduced mortality rates with magnesium therapy in these patients (Chugh et al., 1991). However other studies have shown no such benefits and some have even demonstrated hypermagnesaemia in patients with AAIPP (Singh et al., 1991). The pathogenesis of magnesium level abnormalities was not clear.

3.3 Histological injury in AAIPP

PH₃ also has corrosive effects on tissues. Louriz et al investigated microscopic changes in vital organs of the body, liver, heart and kidneys (Louriz et al., 2009). These changes were found to be suggestive of cellular hypoxia. Other recent studies with more patients were performed and showed congestion, edema and leukocyte or leukocyte infiltration in the liver, kidneys, heart, stomach, lungs, brain and adrenals (Arora et al., 1995; Sinha et al., 2005).

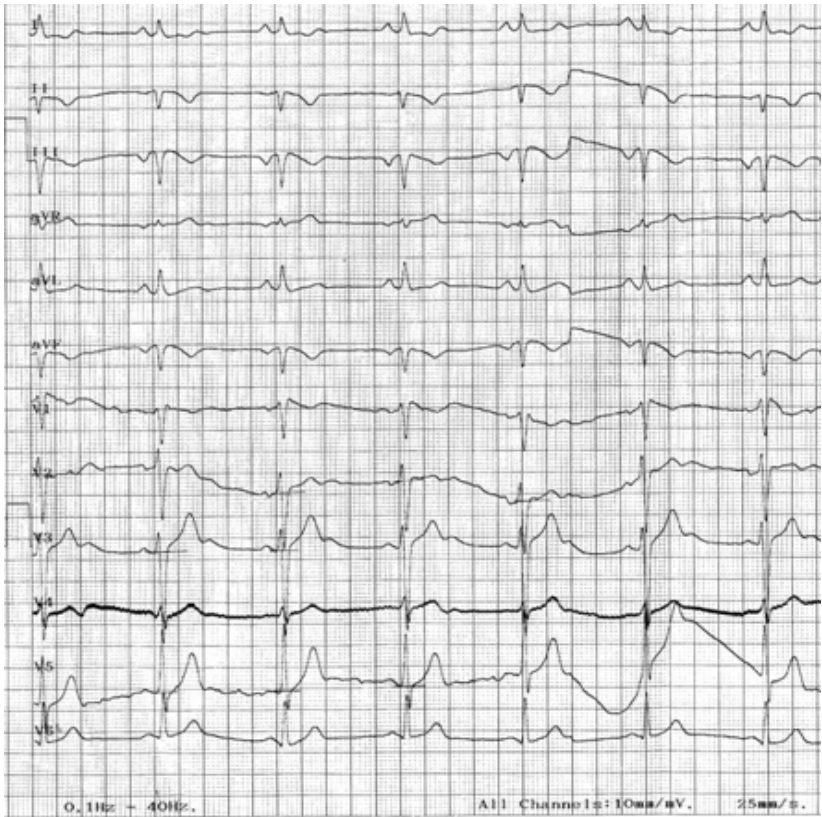
Nakakita studied the histology of the heart. Histopathological finding of myocyte vacuolation and myocytolysis and degeneration are both suggestive of myocardial injury. The areas of increased waviness of myocardial fibers indicate an episode of myocardial infarction (Nakakita et al., 2009).

3.4 Cardiotoxicity of AIP

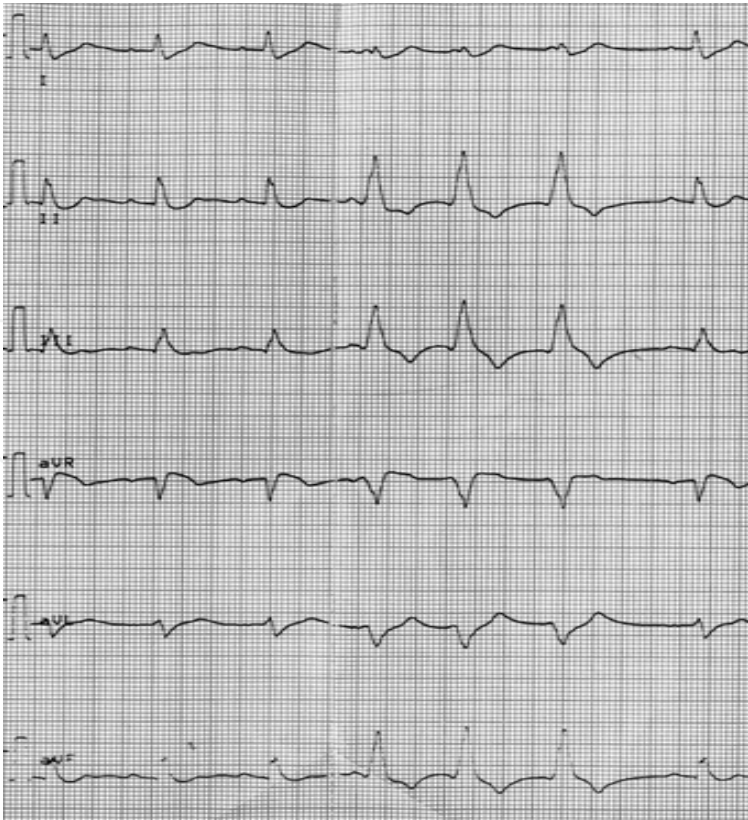
The toxicity of AIP is systemic and can affect all organs, but particularly cardiac and vascular tissues. Myocardial injury following AIP poisoning has been documented on electrocardiograms in several studies. AIP induced cardiotoxicity was responsible for a high level of mortality. Cardiac toxicity due to AIP and PH₃ exposure is represented by a depression in myocardial cellular metabolism, as well as myocardial necrosis due to the release of reactive oxygen intermediates.

Several studies noted electric abnormalities in 38% to 91% of cases (Chugh et al., 1991; Karla et al., 1991). There are conduction disorders such as right and left bundle branch block (25%), atrioventricular block (8%) and rarely, sinoatrial block (Karla et al., 1991). On the other hand, cardiac dysrhythmias were described as atrial fibrillation (4% to 61%), junctional rhythm (4% to 100%), ventricular and atrial extrasystoles (18%) and ventricular fibrillation (2%) (Gupta et al., 1995; Louriz et al., 2009). Finally, re-polarization disorders were also reported, such as ST segment depression (12% to 65%), ST segment elevation (4% to 65%) and T wave inversion (36%) induced by AAIPP (Lall et al., 1997).

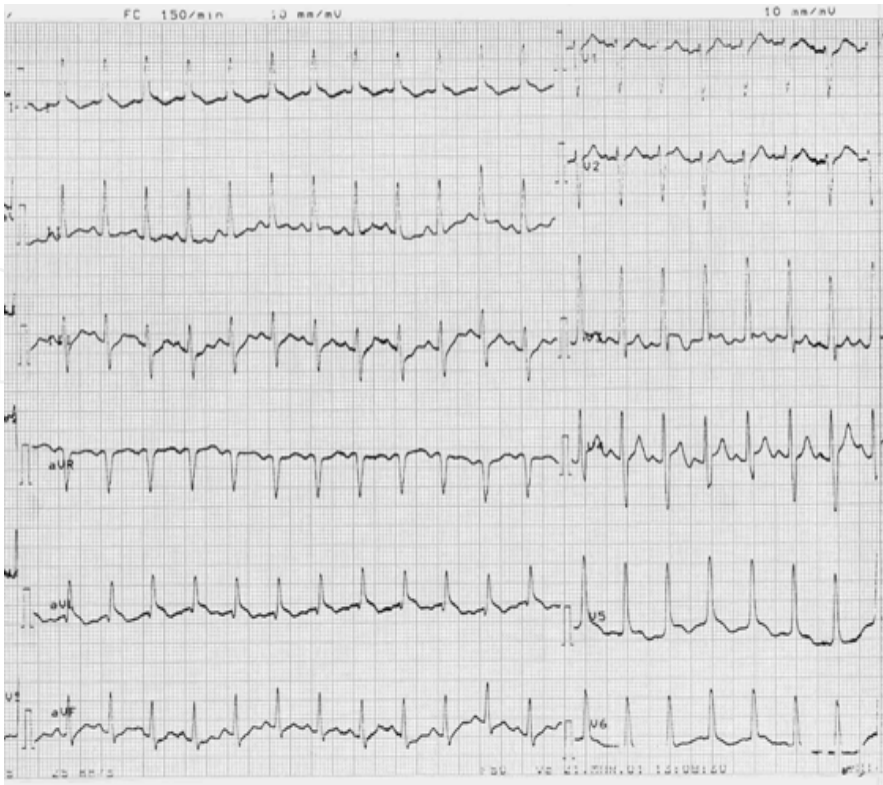Indeed, in Shadnia's study, 39 patients admitted to the ICU with AAIPP were studied. Average time elapsed between poisoning and admission at the hospital was 3.4 ± 3.5 hours. Average ingested amount was 1.4 ± 0.9 tablets. ECG abnormalities were found in 17 (43.6%) cases at the time of admission with ST-T changes in 8 cases. Ischemic change in 3 cases and dysrhythmias in 6 cases. The nature of these dysrhythmias was not described. The mortality rate was high, about 67%. In this study, ECG abnormalities were a prognostic factor (Shadnia et al., 2010).



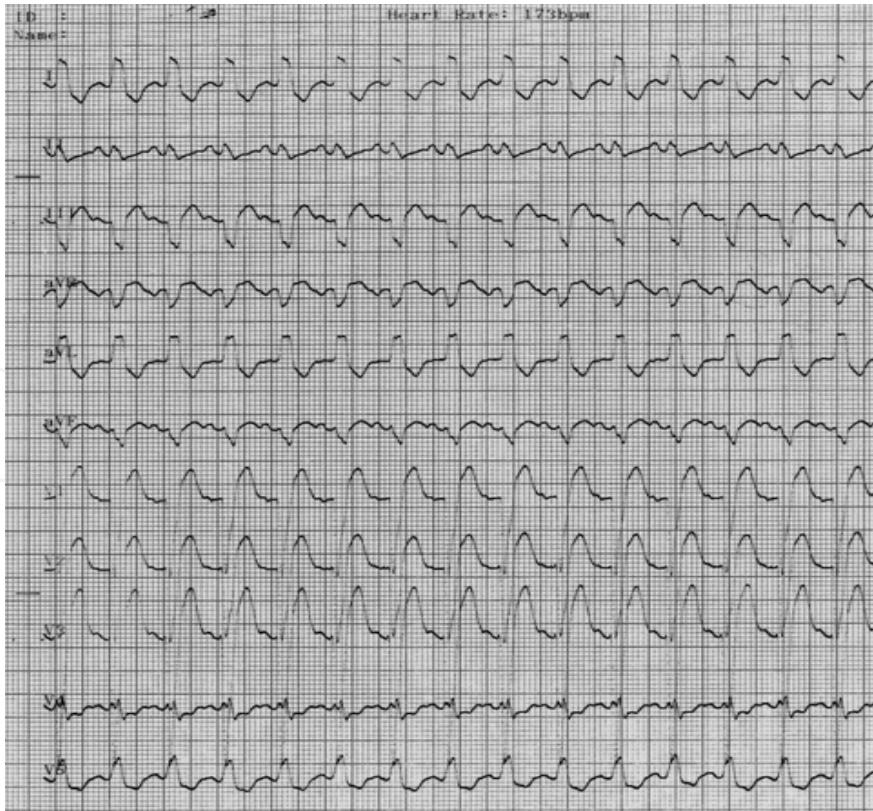
A)



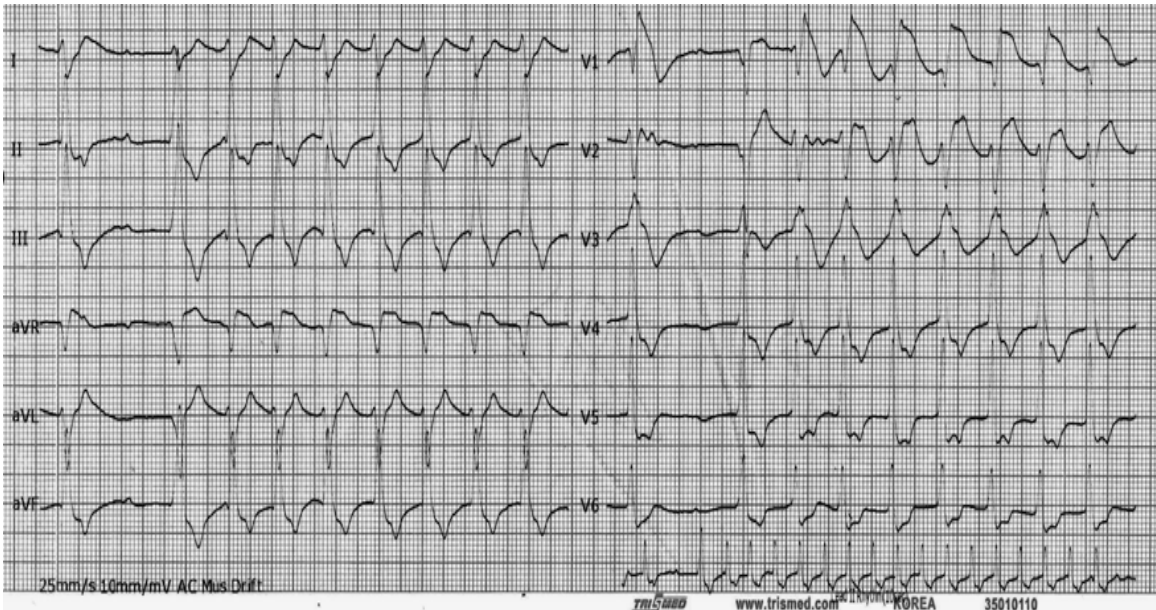
B)



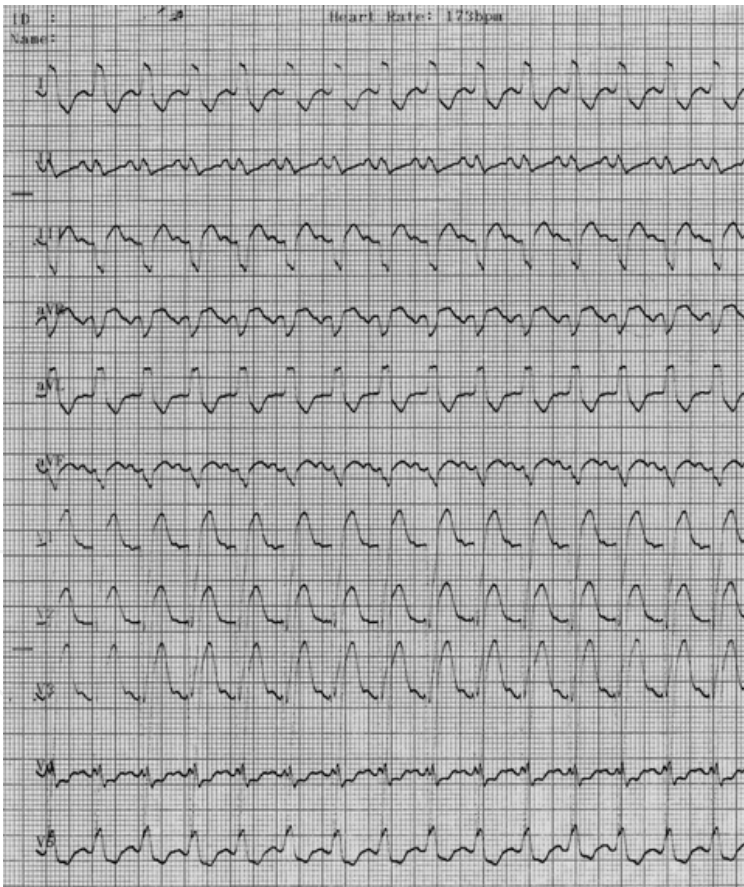
C)



D1)



D2)



D3)

Fig. 2. Electrocardiographic changes following aluminium phosphide poisoning. 12-leads surface ECG recorded on admission showing: (A) Sinusal bradycardia (B) Ventricular extrasystoles (C) Sinusal tachycardia with ST segment depression in the leads D₁, aVL, V₅ and V₆ (D1, D2 &D3) Sinusal tachycardia with ST-T changes.

In Louriz’s study, 49 patients were enrolled. The ingested dose was 1.2 ± 0.7 grams. The time between ingestion and admission to the medical ICU was 9.1 ± 10.7 hours. The ECG was abnormal in 28 cases (58.7%) at the time of admission with myocardial ischemia in 21 cases, atrial fibrillation in 6 cases, ventricular extrasystoles in 9 cases and ventricular fibrillation in one case. The mortality rate was 49%. In this study, ECG abnormalities were also a prognostic factor (Louriz et al., 2009).

In Mathai’s study, 27 patients with AAlPP were admitted into the ICU. One and half grams of poison was consumed. There was a mean delay of 2.1 ± 1.55 hours before presenting to the hospital. Thirteen (48.1%) patients had dysrhythmia at admission of which the majority (69%) of supraventricular origin. Ventricular arhythmias was found in 4 cases. The mortality rate was 59.3%. In this study, the presence of ECG abnormalities did not predict mortality (Mathai et al., 2010).

In these 3 studies cited above, there wasn’t any association between the dose of poison consumed or the time delay in presentation to the hospital with the mortality. All the ECG abnormalities found in these studies were recorded at the admission to the hospital. However, other ECG changes could be found during the hospitalization.

Indeed, Bogle et al described a case of a lethal AAlPP caused by deliberate ingestion of AIP. ECG showed a sinus tachycardia 2 hours after ingestion of a 10 g sachet of pesticide with 56% of AIP. ECG recorded 12 hours after ingestion showed extreme widening of the QRS complexe despite amiodarone therapy. The rate of ECG abnormalities resulting of AAlPP might be under estimated (Bogle et al., 2006).

Some electrical abnormalities noted in our practice are reported in Figure 2.

In several studies, echocardiography showed a global hypokinesis of the left ventricle (Akkaoui et al., 2007; Bajaj et al., 1988) (Figure 3).

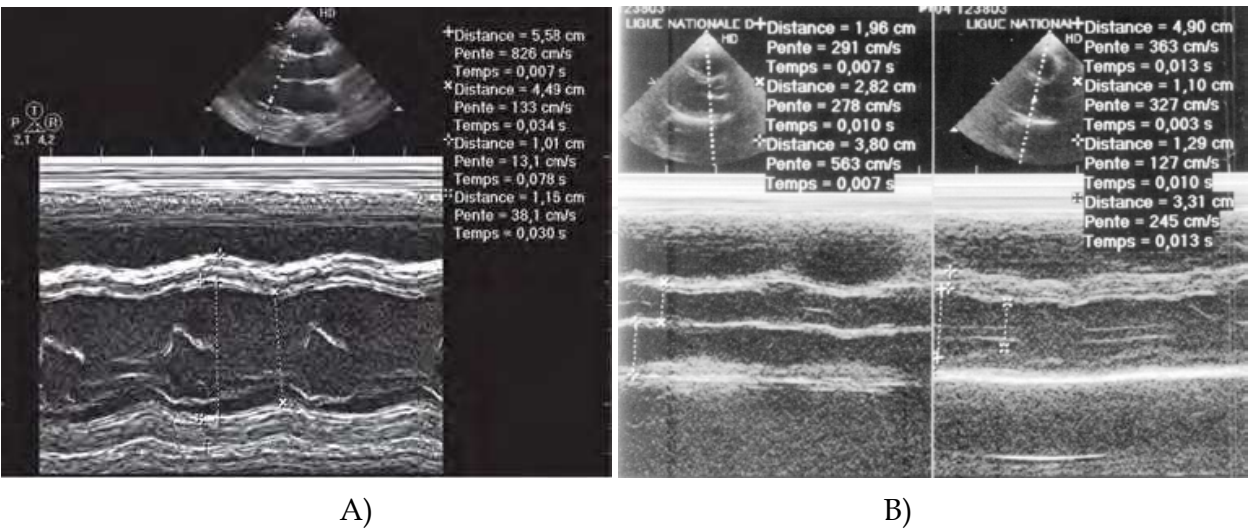


Fig. 3. Echocardiographically parasternal long axis depicted improvement of ventricle function following aluminum phosphide poisoning . A) Echocardiogram obtained on the second day after admission depicts global hypokinesis with LVEF of 30% and dilatation of LV. B) Echocardiogram taken eight days after admission showed improvement of ventricle function.

Indeed, Bahsin et al showed a generalized hypokinesis of left ventricle wall and interventricular septum in 80% of their cases. This study revealed akinesis and pericarditis in 3% and 35% of the cases, respectively (Bhasin et al., 1991). Thus, Bajaj et al showed a global hypokinesis of the left ventricle in the three patients that underwent serial ventriculography (Bajaj et al., 1988). However, other authors have described a focal myocardial necrosis (Singh et al., 1991; Wilson et al., 1980). At a patient hospitalized in our intensive care unit, we observed an unusual and important dilation of right cardiac cavities explained partially by hypokinesia of the left ventricle but probably also by the direct toxicity of the AIP on the right ventricle (Figure 4).

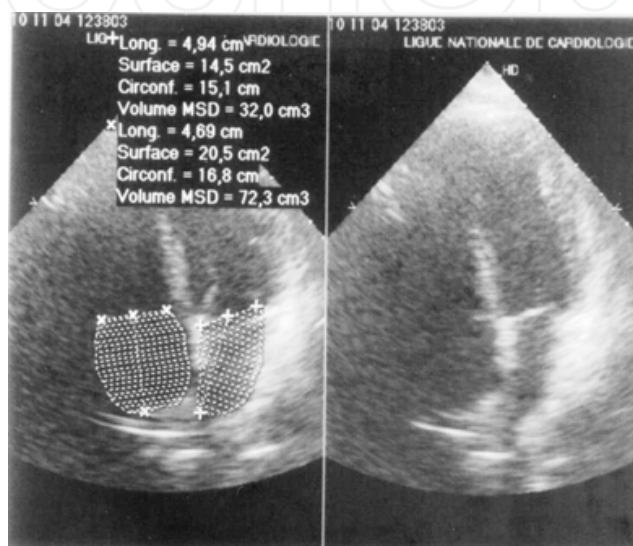


Fig. 4. Echocardiography parasternal long axis depicted improvement of ventricle function. Echocardiogram obtained at admission depicts global hypokinesis with left ventricle ejection fraction (LVEF) of 40% and important dilation of right ventricle and auricle.

4. Conclusion

The severity of the poisoning is judged by the cardiac failure and the unavailability of an antidote. Myocardial injury following AAIPP is responsible for significant mortality. Despite all intensive medical care efforts in supportive therapy, the prognosis of AAIPP is poor. Therefore the use and availability of the pesticide aluminium phosphide should be restricted as much as possible.


5. References

- Abder-Rahman H. (1999). Effect of aluminum phosphide on blood glucose level. *Vet Human Toxicol*, No.41, pp.31-32
- Akkaoui M, Achour S, Abidi K, Himdi B, Madani N, Zeggwagh AA & Abouqal R. (2007). Reversible myocardial injury associated with aluminum phosphide poisoning. *Clin Toxicol*, No.45, pp. 728-31
- Arora B, Punia RS, Karla R, Chugh SN & Arora DR. (1995). Histopathological changes in aluminum phosphide poisoning. *J Indian Med Assoc*, No. 93, pp. 380-81.

- Bajaj R, Wasir HS, Agarwal R, Malhotra A, Chopra P & Bhatia ML. (1988). Aluminum phosphide poisoning. Clinical toxicity and outcome in eleven intensively monitored patients. *Natl Med J India*, No.1, pp. 270-274
- Bogle RG, Theron P, Brooks P, Dargan PI & Redhead J. (2006). Aluminium phosphide poisoning. *Emerg Med J*, No.23, pp.e3
- Chugh SN, Dushyant K, Ram S & Arora B. (1991). Incidence and outcome of aluminum phosphide poisoning in a hospital study. *Indian J Med Res*, No.94, pp. 232-35.
- Chugh SN, Chung K, Ram S & Malhotra KC. (1991). Electrocardiographic abnormalities in aluminum phosphide poisoning with special reference to its incidence, pathogenesis, mortality and histopathology. *J Indian Med Assoc*, No.89, pp. 32-35
- Chugh SN, Jaggal KL, Sharma A, Arora B & Malhotra KC. (1991). Magnesium levels in acute cardiotoxicity due to aluminum phosphide poisoning. *Indian J Med Res*, No.94, pp. 437-9.
- Chugh SN, Kamar P, Sharma A, Chugh K, Mittal A & Arora B. (1994). Magnesium status and parenteral magnesium sulphate therapy in acute aluminium phosphide intoxication. *Magnes Res*, No. 7, pp. 289-94.
- Chugh SN, Arora V, Sharma A & Chugh K (1996). Free radical scavengers and lipid peroxidation in acute aluminum phosphide poisoning. *Indian J Med Res* 1996a, No104, pp. 190-3.
- Chugh SN, Pal R, Singh V & Seth S. (1996). Serial blood phosphine levels in acute aluminum phosphide poisoning. *J Assoc Physicians India* 1996b, No.44, pp. 184-5
- Cienki JJ. (2001). *Non-anticoagulant rodenticides*. (Ford MD, Delaney KA, Ling LJ, Erickson T). *Clinical Toxicology*, 858. Philadelphia.
- Gupta MS, Malik A & Shama VK. (1995). Cardiovascular manifestations in aluminum phosphide poisoning with especial reference to echocardiographic changes. *J Assoc Physicians India*, No.43, pp. 774-780
- Hsu CH, Quistad GB & Casida JE. (1998). Phosphine-induced oxidative stress in Hepa 1c1c7 cells. *Toxicol Sci*, No.46, pp. 204
- Hsu C-H, CHiB-C, Liu J-H, Chen C-J & Chen R-Y. (2002). phosphine induced oxidative damage in rats: Role of glutathione. *Toxicology*, No.179, pp.1-8
- Karla GS, Anand IS, Jit I, Bushnurmah B & Wahi PL. (1991) Aluminum phosphide poisoning haemodynamic observations. *Indian Heart J*, No.43, pp. 175-8
- Lall SB, Sinha K, Mittra S & Seth SD. (1997). An experimental study on cardiotoxicity of aluminum phosphide. *Indian J Exp Biol*, No.35, pp. 1060-1064
- Louriz M, Dendane T, Abidi K, Madani N, Abouqal R & Zeggwagh AA. (2009). Prognostic factors of acute aluminum phosphide poisoning. *Indian J Med Sci*, No.63, pp. 227-34
- Mathai A & Bhanu MS. (2010). Acute aluminium phosphide poisoning: can we predict mortality? *Indian J Anaesth*, No.54, pp. 302-307
- Mehrpour O, Alfred S, Shadnia S, Keyler DE, Soltaninejad K & Chalaki N. (2008). Hyperglycemia in acute aluminum phosphide poisoning as a potential prognostic factor. *Hum Exp Toxicol*, No.27, pp.591-5.
- Nakakita, H.a, Katsumata, Y.b & Ozawa, T.b. (2009). The effect of phosphine on respiration of rat liver mitochondria. *Indian Journal of Critical Care Medicine*, No.13, pp. 41-43
- National Institute of occupational Safety and Health. NIOSH alert: preventing phosphine poisoning and explosions during fumigation. Columbus, OH: NIOSH, 2003:99-

- 126,1-16 Proudfoot AT. (2009). Aluminum and Zinc phosphide poisoning. *Clin Toxicol*, No.47, pp. 89-100
- Sasser SM. (1998). Rodenticides. In: Viccellio P, Bania T, Brent J, Hoffman RS, Kulig KW, Mofenson HC, et al, editors. Emergency toxicology. 2nd ed. Philadelphia, PA: Lippincott-Raven; P. 433.
- Shadnia S, Mehrpour O & Soltaninejad K. (2010). A simplified acute physiology score in the prediction of acute aluminium phosphide poisoning outcome. *Indian J Med Sci*, No.64, pp. 532-539
- Sinha US, Kapoor AK, Singh AK, Gupta A & Mehrotra R. (2005). Histopathological changes in cases of aluminum phosphide poisoning. *Indian J Pathol Microbiol*, No.48, pp. 177-180
- Singh RB, Singh RG & Singh U. (1991). Hyperglycemia following aluminum phosphide poisoning. *Int J Clin Pharmacol Ther Toxicol*, No.29, pp. 82-85
- Sudakin DL. (2005). Occupational exposure to aluminum phosphide and phosphine gas ? A suspected case report and review of the literature. *Human and experimental toxicology*, No.24, pp. 27-33
- Wilson R, Lovejoy FH, Jaeger RJ & Landrigan PL. (1980). Acute phosphine poisoning aboard a grain freighter Epidemiologic, clinical and pathological finding. *JAMA*, No.244, pp. 148-150

IntechOpen



Advances in Electrocardiograms - Clinical Applications

Edited by PhD. Richard Millis

ISBN 978-953-307-902-8

Hard cover, 328 pages

Publisher InTech

Published online 25, January, 2012

Published in print edition January, 2012

Electrocardiograms have become one of the most important, and widely used medical tools for diagnosing diseases such as cardiac arrhythmias, conduction disorders, electrolyte imbalances, hypertension, coronary artery disease and myocardial infarction. This book reviews recent advancements in electrocardiography. The four sections of this volume, Cardiac Arrhythmias, Myocardial Infarction, Autonomic Dysregulation and Cardiotoxicology, provide comprehensive reviews of advancements in the clinical applications of electrocardiograms. This book is replete with diagrams, recordings, flow diagrams and algorithms which demonstrate the possible future direction for applying electrocardiography to evaluating the development and progression of cardiac diseases. The chapters in this book describe a number of unique features of electrocardiograms in adult and pediatric patient populations with predilections for cardiac arrhythmias and other electrical abnormalities associated with hypertension, coronary artery disease, myocardial infarction, sleep apnea syndromes, pericarditides, cardiomyopathies and cardiotoxicities, as well as innovative interpretations of electrocardiograms during exercise testing and electrical pacing.

How to reference

In order to correctly reference this scholarly work, feel free to copy and paste the following:

Amine Ali Zeggwagh and Maha Louriz (2012). Abnormal Electrocardiogram in Patients with Acute Aluminum Phosphide Poisoning, *Advances in Electrocardiograms - Clinical Applications*, PhD. Richard Millis (Ed.), ISBN: 978-953-307-902-8, InTech, Available from: <http://www.intechopen.com/books/advances-in-electrocardiograms-clinical-applications/abnormal-electrocardiogram-in-patients-with-acute-aluminum-phosphide-poisoning>

INTECH
open science | open minds

InTech Europe

University Campus STeP Ri
Slavka Krautzeka 83/A
51000 Rijeka, Croatia
Phone: +385 (51) 770 447
Fax: +385 (51) 686 166
www.intechopen.com

InTech China

Unit 405, Office Block, Hotel Equatorial Shanghai
No.65, Yan An Road (West), Shanghai, 200040, China
中国上海市延安西路65号上海国际贵都大饭店办公楼405单元
Phone: +86-21-62489820
Fax: +86-21-62489821

© 2012 The Author(s). Licensee IntechOpen. This is an open access article distributed under the terms of the [Creative Commons Attribution 3.0 License](https://creativecommons.org/licenses/by/3.0/), which permits unrestricted use, distribution, and reproduction in any medium, provided the original work is properly cited.

IntechOpen

IntechOpen