

We are IntechOpen, the world's leading publisher of Open Access books Built by scientists, for scientists

6,900

Open access books available

185,000

International authors and editors

200M

Downloads

Our authors are among the

154

Countries delivered to

TOP 1%

most cited scientists

12.2%

Contributors from top 500 universities



WEB OF SCIENCE™

Selection of our books indexed in the Book Citation Index
in Web of Science™ Core Collection (BKCI)

Interested in publishing with us?
Contact book.department@intechopen.com

Numbers displayed above are based on latest data collected.
For more information visit www.intechopen.com



Human Ovarian Tissue Cryopreservation as Fertility Reserve

Elena Albani¹, Graziella Bracone¹, Sonia Di Biccari³,
Domenico Vitobello², Nicola Fattizzi² and Paolo Emanuele Levi-Setti¹

¹*U.O. di Ginecologia e Medicina della Riproduzione*

²*U.O. di Ginecologia*

³*Laboratorio di Medicina Quantitativa - Direzione Scientifica
Istituto Clinico Humanitas IRCCS – Cancer Center-Rozzano (MI)
Italy*

1. Introduction

Oocytes designed for reproductive function in women are the largest cell in the human body. They are surrounded by granulosa cells to form the follicles that in various stages of development are present in the ovarian cortex (Fig. 1).

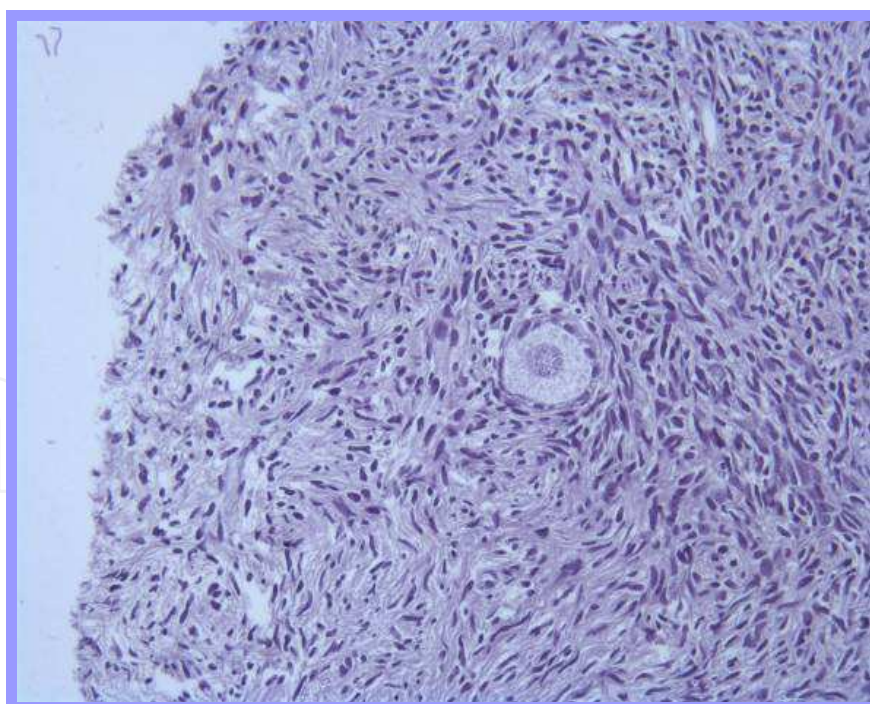


Fig. 1. Primary follicle in frozen/thawed human ovarian cortex (20X magnification)

The ovary of a healthy woman contains a finite number of follicles that decreases over time. The peak number is reached in the fifth month of gestation with approximately 7 million follicles. This number reduces progressively due to atresia, so at birth there are only 1-2

million follicles that, at puberty, become 300,000. Approximately, 400 of these follicles become mature oocytes and ovulate during the fertile life of the female.

At the age of 37, there is usually an acceleration of follicular loss, which is correlated with an increase in follicle-stimulating hormone (FSH) level.

Last year Wallace reported with a mathematical model combined with histological evidence, the establishment and decline of non-growing follicles (NGFs) in the human ovary. Wallace shows for the first time that the rate of NGF recruitment increases from birth to age 14 years and then declines with age until menopause (Fig. 2) (Wallace & Kelsey, 2010).

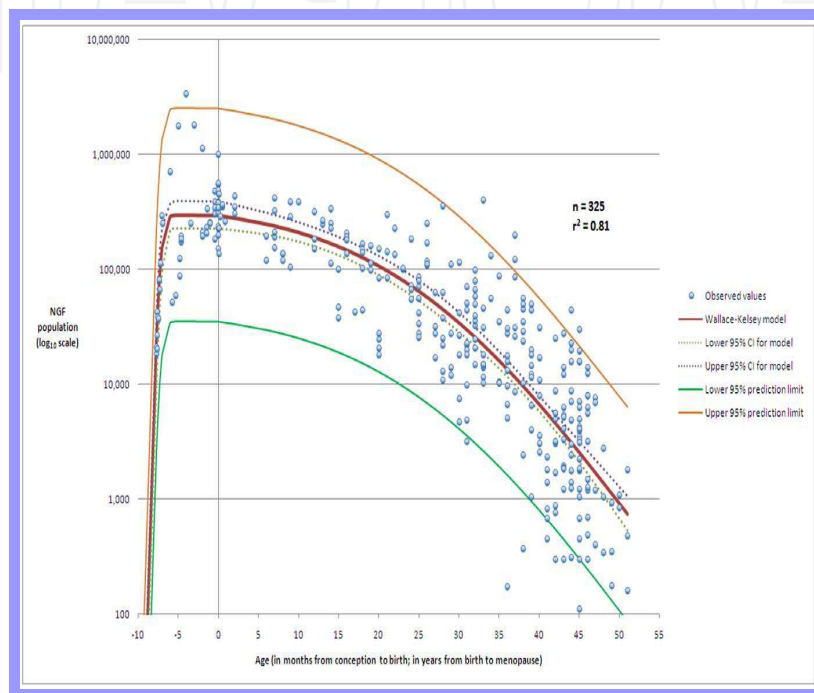


Fig. 2. The best histological model for the establishment of the NGF population after conception and the subsequent decline until menopause (Kindly provided by Professor Wallace).

However, the central dogma of ovarian biology has been questioned by new discoveries. Johnson in 2004 reported that germline stem cells (GSCs) are present in the mouse ovary, and could become new follicles (Johnson et al., 2004). It seems that female germline stem cells reside in an extragonadal location, the bone marrow, and reach the ovary through the circulatory system (Johnson et al., 2005; Lee et al., 2007). De Felici reported that germline stem cells exist in adult mouse ovaries but are quiescent under physiological conditions, contributing to the oocyte reserve only in response to ovotoxic damage (De Felici, 2010). Recently, Bukovsky showed the production of new eggs in cultures derived from premenopausal and postmenopausal human ovaries (Bukovsky et al., 2009).

Despite these exciting new prospects to indicate that oocytes are continuously formed in the female adult, at the present it is known that the pool of follicles is limited, so in case of toxic ovarian events that may affect the ovary, opportune measures should be considered to preserve the fertility of young women. According to the law in different countries regulating assisted reproductive technologies, approaches to fertility preservation include embryo, oocyte cryopreservation, or ovarian tissue banking followed by ovarian tissue transplant or in in-vitro culture.

However, cryopreservation of ovarian tissue may be the only acceptable method to preserve fertility for prepubertal girls, for women who cannot delay the start of cancer treatment for ovarian stimulation, and probably for women with hormone-sensitive malignancies. All these situations make ovarian tissue freezing the only option for female fertility preservation.

Therefore, an entire ovary or part of it, is removed laparoscopically, frozen and stored in liquid nitrogen at -196°C . After complete recovery of the patient, the tissue can be used to restore gametogenic and/or steroidogenic function.

Potential indications for ovarian tissue cryopreservation are patients diagnosed with malignant (extra-pelvic diseases: bone cancer, thyroid cancer, kidney cancer, breast cancer, melanoma, neuroblastoma; pelvic diseases: non-gynecological malignancy, gynaecological malignancy; systemic diseases: Hodgkin's disease, non-Hodgkin's lymphoma, leukaemia, melanoblastoma) or benign diseases (recurrent ovarian cysts, etc), or with non malignant autoimmune diseases (systemic lupus erythematosus, rheumatoid arthritis, autoimmune thrombocytopenia or other haematological diseases). These patients are being treated successfully with chemotherapy and/or radiotherapy or repeated surgery, greatly improved in recent years, but all these therapies can be toxic to the ovary. So, it is important to focus attention on the quality of life, including fertility preservation, as well as on survival of these young women.

2. Effect of radiotherapy, chemotherapy, or other toxic drugs on female reproduction

The risk of ovarian failure after anticancer treatments is assessed in relation to patient's age, treatment protocol and type of cancer as reported by Meirow (Meirow and Nugent, 2001).

High-dose ionizing radiation is used to treat many types of cancer and hematologic malignancies. Ovarian transposition is not possible in case of total irradiation as is required for bone marrow transplantation (Meirow et al., 2010). The estimated dose at which half of the follicles are lost in humans (LD_{50}) is 4 Gy (Wallace et al., 1989), but is age-dependent. Lashbaugh reported that the toxic ovarian dose, which leads to permanent loss of fertility is higher in young women (20 Gy) than older (6 Gy) (Lushbaugh & Casarett, 1976).

Chemotherapeutic agents can be grouped into five classes of drugs based on their mode of action (alkylating agents, aneuploidy inducers, topoisomerase II inhibitors, antimetabolites and radiomimetics) as summarized by Meirow. It was found that alkylating agents imposed the highest risk in causing ovarian failure with an odd ratio (OR) of 3,98, followed by cisplatin with an OR of 1.77 (Meirow and Nugent, 2001).

Schmidt, reported that the ovaries of healthy young girls contain a higher number of follicles than ovaries from older women, meaning young girls are more resistant to chemotherapy. Even if chemotherapeutic agents differ in their ovarian toxicity (Schmidt et al., 2010), they are often used in combination, so their adverse effects are increased and cannot always be easily evaluated.

In 2007, Oktem and Oktay, published an interesting paper on ovarian damage from chemotherapy. They present the first quantitative evidence in humans, by histological evaluation, that alkylating agents can significantly reduce ovarian reserve, and may affect stromal cell function (Oktem & Oktay, 2007). Meirow also reported that injury from chemotherapy is in stromal cells as well as in follicles and blood vessels (Meirow, 2010).

3. Ovarian tissue cryopreservation

To preserve ovarian tissue for a lengthy period of time, it should be stored in liquid nitrogen at a temperature of -196°C . However, ovarian tissue cryopreservation is complex and requires preservation of multiple cell types, thus the ability to successfully cryopreserve would be a powerful clinical tool in an assisted reproductive laboratory.

As reported by Bakhach in 2009, is easy to imagine the cell damage when temperatures fall from $+37^{\circ}\text{C}$ to -196°C . There is a loss of about 95% of intracellular water, an increase of electrolyte concentrations in both intra and extracellular media, and ice formation in the intracellular spaces that deform cells and destroy intracellular structures (Bakhach, 2009).

Hovatta in 2005 published an interesting work on the different methods of ovarian tissue freezing which emphasizes the importance of trying to preserve most of the cellular tissue components, including even the small proportion of ovarian medulla which contain blood vessels and nerves so important for ovarian tissue function recovery after reimplantation (Hovatta, 2005). Recently, Donnez reported that revascularization of grafts depends also on the preservation of vessels in grafted tissue, and not only on neoangiogenesis from the host (Donnez et al., 2011-b).

It should be stressed that the protocol of ovarian tissue freezing is still not standardized. So, there are several freezing procedures that range from slow freezing/rapid thawing, vitrification or ultrarapid-freezing. Freezing protocols differ also depending on the cryoprotectants used, dehydration/rehydration time and temperature, different protein support, and on the containers used for storage such as cryovials, strips or other tubes.

Approaches to human ovarian tissue cryopreservation are currently characterised by the use of slow freezing/rapid thawing methods using dimethylsulphoxide (DMSO) or propanediol (PROH) as a cryoprotectant. The slow freezing requires the use of a machine that slowly decreases the temperature, so the freezing programme so takes a few hours. This procedure has the disadvantage that it can lead to the formation of ice crystals, affecting correct tissue preservation. This disadvantage is avoided by using the protocol of vitrification, where high concentrations of cryoprotectants are used, which increased ovarian toxicity too. Ultra-rapid freezing should be a method somewhere between the previous two using the advantages given by vitrification with a lower concentration of cryoprotectant to act on increasing the cooling rate.

In 2003 Shaw published an interesting paper on the terminology associated with equilibrium cooling procedures or 'slow cooling' and non-equilibrium protocols such as 'vitrification', 'rapid cooling' and 'ultrarapid cooling' that is helpful in clarifying the terms often used inappropriately (Shaw & Jones, 2003).

The positive results achieved by oocyte vitrification, has been discussed in recent years, but at the present time this procedure applied to ovarian tissue has given conflicting results.

Isachenko has worked extensively on the ovarian tissue vitrification. Her paper of 2007 showed a better preservation of ovarian tissue by slow freezing in which the quality of follicles was higher compared to the rapid freezing (Isachenko et al., 2007; Isachenko et al., 2009).

In 2007 Li demonstrated that the vitrification method for cryopreservation of human ovarian tissue is effective and simple (Li et al., 2007). Kagawa in 2009 found no difference in oocyte viability between fresh and vitrified human ovarian cortical tissue (kagawa, 2009). In another paper ovarian stroma was shown to be significantly better preserved by vitrification compared to slow freezing (Keros et al., 2009).

However, data on cryopreservation of human ovarian tissues by vitrification are still modest and controversial. This may be due to the fact that the same cryopreservation procedure is often used, such as slow freezing or vitrification, but different freezing protocol (types of cryoprotectant, concentration used and time of diffusion, etc.), this creates significant bias that must be considered.

In addition vitrification presupposes direct contact with liquid nitrogen, which is a potential source of microbial contamination, as reported by Isachenko (Isachenko et al., 2009).

In conclusion, an ideal ovarian cryopreservation method has not yet been established.

4. How to use

After 4 or 5 years when the patient is considered oncologically cured, the ovarian tissue stored in liquid nitrogen can be used. There are several ways to use tissue after thawing, such us reimplantation in various anatomic sites in the same patient or in a host animal or in vitro culture to grow primordial follicles present in large number (Fig. 3).

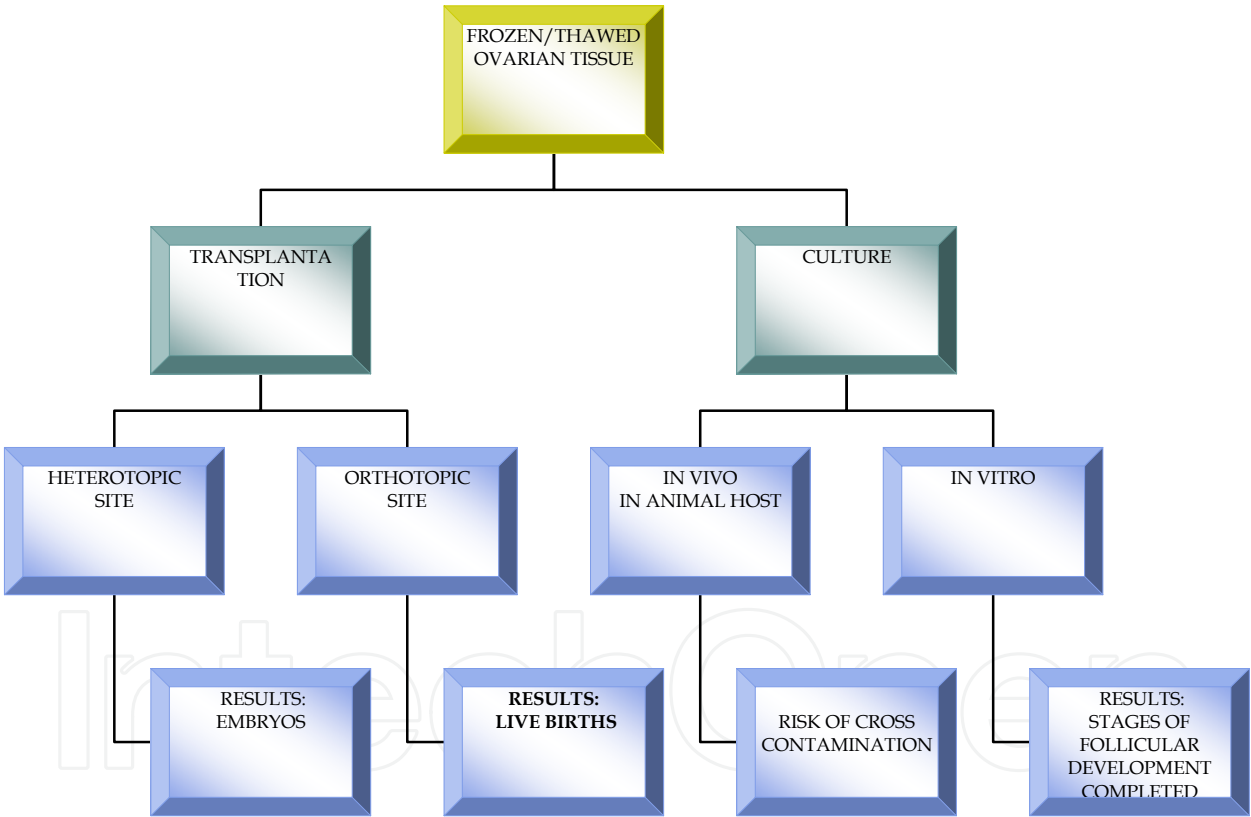


Fig. 3. Techniques using human cryopreserved ovarian tissue.

4.1 Ovarian tissue culture

When dealing with tumours that can metastasize to the ovary, ovarian tissue reimplantation should be avoided due to the risk of retransmitting cancer cells. In these cases the only option is to develop other methods in which the primordial follicles are matured in vitro within ovarian tissue pieces. Only in mice was the full maturation of primordial follicles with livebirths achieved (Eppig et al., 1996), this is difficult to replicate in large animals and humans.

In 2008 Picton published an interesting review on in vitro growth and maturation of follicles, which showed a number of different culture systems. It showed that culture of thin cortical strips has many advantages such as avoiding the damage caused by mechanical or enzymatic recovery of follicle present in the cortex, and provides a complex support system that resembles the ovary in vivo as the follicles also remain in contact with the surrounding stromal cells. This contact is very important at least until development of secondary follicles, when the follicles from the surrounding stroma should be left to facilitate further development. Thus, a multi-step strategy for the complete in vitro growth and maturation of follicles is promoted (Picton et al., 2008).

Recently another interesting review was published by Fabbri which summarizes the most relevant literature of the last ten years on in vitro cultures of ovarian cortical pieces. The conclusion was that the current optimal method for growing and maturing human follicles remains whole tissue culture. The authors underline the difficulty of graduating nutrient concentration and especially what is best to add to the culture media and when (Fabbri et al., 2009).

In conclusion the culture of ovarian cortex strips is under development and currently not applicable to the human species, owing to the long period necessary for the follicle to complete development, almost six months compared to the couple of weeks in mice.

However, as suggested by Picton before these strategies can be utilised therapeutically, extensive testing is required to confirm the epigenetic health and genetic normality of in vitro growth derived oocytes (Picton et al., 2008).

We must not forget that oocytes are matured in vitro, after full development of follicles in vitro for a period exceeding 90 days, with the addition of nutrients that are not exactly what you get in their natural anatomic site, both as concentration and as timing of administration. So, even if complete follicle development in vitro is far from being clinically applicable, this does not mean that patients with malignancies that metastasize to the ovary should be excluded from the eventuality of cryopreserved tissue. We cannot know whether the study of in vitro cultures will make progress in a few years time.

4.2 Ovarian tissue reimplantation

The main option of this strategy is to transplant cortical ovarian tissue into the pelvic cavity, into its original location (orthotopic site) or in a different site, such as forearm, arm, abdominal wall, etc. (heterotopic site) when anticancer treatment is completed and the patient is disease-free.

Human transplantation history begins in the heterotopic site, such as the arm or the forearm. First studies on heterotopic reimplantation of an organ date back to 1975 and were applied to parathyroid gland. Several authors demonstrated that parathyroid autografts secrete hormone and maintain normal serum calcium in the host (Wells et al., 1975; Hickey & Samaan, 1975). Oktay was the first to begin reimplanting of heterotopic tissue in the forearm, paving the way to human reimplantation history. In 2004 Oktay published a paper on the first embryo development after heterotopic transplantation of cryopreserved ovarian tissue (Oktay et al., 2004).

Successful orthotopic transplantation of ewe cryopreserved ovarian tissue was first performed by Gosden in 1994 (Gosden et al., 1994). The orthotopic transplantation is the site most suitable compared to the heterotopic site, because it is the natural environment, with comfortable temperatures and pressures for proper follicular development.

After several animal studies, ten years later, the first live human birth after frozen-thawed ovarian cortex orthotopic reimplantation was achieved by the Belgian group led by Donnez

(Donnez et al., 2004), followed recently by other live births (Donnez et al., 2011-a; Donnez et al., 2011-b; Meirow & Levron, 2005; Meirow et al., 2007; Demeestere et al., 2007; Demeestere et al., 2009; Anderson et al., 2008; Ernst et al., 2010; Silber et al., 2010; Piver et al., 2009; Sanchez-Serrano et al., 2010; Revel et al., 2011; Roux et al., 2010), as shown in table 1.

The major disadvantage of transplanting ovarian cortical strips is that revascularization of the graft needs several days, according to the species. So, revascularization occurs within 48h after transplantation in rats and within 1 week of grafting in sheep. This leads to great loss of follicles from the grafts in transplantation due to ischemic injury, which can however be avoided by performing a whole ovarian transplantation thus providing immediate revascularization of the transplant (Onions et al., 2009; Bedaiwy & Falcone, 2004; Bedaiwy et al., 2006; Bromer & Patrizio, 2009). However, whole ovarian transplantations have a high rate of vascular complication, such as risk of thrombosis. Therefore, further work is needed before whole ovarian tissue transplantation can be considered a viable option for fertility preservation.

Exogenous factors such as antioxidants, growth factors or hormones have been tested to improve follicular survival in ovarian grafts by reducing ischaemia-reperfusion injury (Nugent et al., 1998; Torrents et al., 2003; Demeestere et al., 2009).

Until now, slow programmed ovarian tissue freezing is the only procedure that has resulted live births following orthotopic transplantation of frozen/thawed human ovarian tissue slices, but it is unknown or difficult to quantify how many women have attempted ovarian tissue reimplant.

The risk of ovarian tissue reimplantation includes transplantation of the primary tumour. However, most malignant diseases encountered during the reproductive years do not metastasize to the ovaries, except blood-borne malignancies such as leukemias, neuroblastoma and Burkitt's lymphoma. In the 1996 Shaw reported the transmission of lymphoma from a donor to a graft recipient (Shaw et al., 1996). Recently, Dolmans demonstrated, by quantitative RT-PCR, ovarian contamination by malignant cells by reimplant cryopreserved ovarian tissue in acute and chronic leukaemia patients (Dolmans et al., 2011).

So, it is highly recommended to use the best assessment to detect micro-metastases on a small portion of the harvested tissue before cryopreservation, it is also useful to freeze a less valuable part of the cortex, such as ovarian medulla.

As suggested by Von Wolff, sophisticated techniques are required to exclude first macroscopic ovarian pathology, such as ovarian metastasis, using imaging (sonography, CT scan, etc.). Then immunohistochemistry and polymerase chain reaction (PCR) to exclude single malignant cells, and identified minimal residual disease (MRD) by highly sensitive RT-PCR. Another effective method is xenotransplant small sample of ovarian tissue in a immunodeficient animal host (Von Wolff et al., 2009).

4.3 Xenotransplantation

Xenotransplantation falls between reimplantation and in vitro culture, so the follicles within the tissue are growing in vivo in an animal host (T-and B-cell-deficient SCID mice). It has been applied to assess the risk of reimplanting malignant cells after human ovarian tissue reimplantation, and to observe follicle development.

Last year Dath compared four grafting (intraperitoneal, ovarian bursa, sub-cutaneous, and intramuscular) sites for xenotransplantation of human ovarian tissue to nude mice, concluding that all four sites equally supported early follicular growth and preserved some

quiescent follicles (Dath et al., 2010). However, Sonmezer reported an asynchrony between oocytes and granulosa cell development (Sonmezer & Oktay, 2010).

FIRST AUTHOR YEAR	WHERE	DIAGNOSIS	AGE at cryo	FRESH or CRYO-PRESERVED	SLICES or WHOLE	REIMPLANTATION SIDE	OUTCOME
Donnez, 2004	Belgium	Stage IV Hodgkin's lymphoma	25	Frozen/thawed	Slices	Orthotopic: ovarian fossa peritoneum	Spontaneous pregnancy: live birth
Donnez, 2011-a	Belgium	Neuroectodermic tumour	17	Frozen/thawed	Slices	Orthotopic: ovary	Spontaneous pregnancy: live birth
Meirow, 2005, 2007	Israel	Non Hodgkin's lymphoma	28	Frozen/thawed	Slices	Orthotopic: ovary	Mild ovarian stimulation - IVF: live birth
Demeester e, 2007, 2010	Belgium	Stage IV Hodgkin's lymphoma	24	Frozen/thawed	Slices	Orthotopic (+ heterotopic)	Spontaneous pregnancy: live birth in 2007 live birth in 2009
Andersen, 2008	Denmark	Hodgkin's lymphoma	27	Frozen/thawed	Slices	Orthotopic: ovary	Ovarian stimulation - IVF: live birth
Andersen, 2008; Ernst, 2010	Denmark	Ewing sarcoma	27	Frozen/thawed	Slices	Orthotopic: ovary	Mild ovarian stimulation - IVF: 1 live birth. Spontaneous pregnancy: 1 live birth
A- Silber, 2010 B- (Donnez, 2011 b)	USA	Stage IIIb Hodgkin's lymphoma	20	Frozen/thawed	Slices	Orthotopic	A- Ongoing pregnancies B -live birth
Silber, 2010	USA		24	Frozen/thawed	Slices	Orthotopic	1 live birth + 1 live birth
Piver, 2009	France	Microscopic polyangiitis	27	Frozen/thawed	Slices	Orthotopic	IVF: live birth
Sanchez-Serrano, 2010	Spain	Breast cancer	36	Frozen/thawed	Slices	Orthotopic	Ovarian stimulation, IVF: 2 live births (twins)
Revel, 2011	Israel	Thalassemia major	19	Frozen/thawed	Slices	Orthotopic	IVF: live birth
Roux, 2010	France	Homozygous sickle cell anemia	20	Frozen/thawed	Slices	Orthotopic: ovary and few strips deposited in the peritoneal window	Spontaneous pregnancy: live birth

Table 1. Live births after frozen/thawed orthotopic transplantation of human ovarian tissue.

In conclusion, xenotransplantation should be carefully considered in its human clinical application because of the risk of cross-species retroviral infection.

5. Conclusion

As reported by Maltaris it is important to assess the 'ovarian reserve' that is the available pool of primordial follicles in the ovary and is a major determinant of female fertility potential. This information is important for a correct strategy of fertility preservation before cancer treatment. In general, ovarian reserve tests are either biochemical or biophysical (Maltaris et al., 2006), but new methods are required.

In conclusion, a common goal of life-saving methods must be to protect the fertility of young women to this aim it is important to form a closely collaborative team comprising gynaecologists, surgeons, oncologists, haematologists, biologists and psychologists. Specifically, it is important that the oncologist gives an assessment of the degree of ovarian damage in order to decide how much ovarian tissue to retrieve and store.

It is known that for each malignant disease only few protocols are commonly used, so it is possible to analyse the risk of ovarian failure. Meirrow reported that the ovarian failure rate was 50% for breast cancer, 44% for non-Hodgkin's lymphoma, and 32% for Hodgkin's disease (Meirrow & Nugent, 2001).

Before proceeding to cryopreserve ovarian tissue, it is important to identify a series of tests for morphological analyses (such as staining with hematoxylin and eosin for observation by an optical microscope, or a more thorough evaluation of cell components by electron microscopy), for functional analyses (such as immunohistochemistry), or for viability analyses (such as trypan blue); in order to assess the degree of overall tissue preservation with the procedure adopted in the laboratory.

In addition, it is also important to put an age limit to the preservation of ovarian tissue. The patient can use it only after cancer remission, therefore not before few years, so the cryopreservation of ovarian tissue of a patient older than 38 years old may be a useless procedure but could give psychological support to women. In any case, patients should be properly informed about the real possibility of recovering fertility and be able to get pregnant.

In conclusion, we agree with Donnez that ovarian tissue cryopreservation should be offered before anticancer treatments in all cases where there is a high risk of premature ovarian failure and where emergency in vitro fertilization is not possible (Donnez et al., 2011-c).

If the dogma of reproductive biology is that of a finite number of follicles in the ovary which, moreover, undergo atresia during reproductive life, all procedures to preserve fertility should be carried out before acting on the ovary with drugs, therapies, surgery or potentially toxic treatments. Therefore, live births after cryopreserved ovarian tissue transplantation opened up new chapter in the field of infertility preservation.

6. Acknowledgment

The authors thank Rosalind Roberts for reviewing the English language, and Elena Gismano (biologist) for assistance with chapter preparation.


7. References

Andersen CY, Rosendahl M, Byskov AG, Loft A, Ottosen C, et al. (2008) Two successful pregnancies following autotransplantation of frozen/thawed ovarian tissue. *Hum Reprod.*;23(10):2266-72.

- Bakhach J. (2009) The cryopreservation of composite tissues. Principles and recent advancement on cryopreservation of different type of tissues. *Organogenesis* 5(3):119-126.
- Bedaiwy MA, Falcone T. (2004) Ovarian tissue banking for cancer patients: reduction of post-transplantation ischaemic injury: intact ovary freezing and transplantation. *Hum Reprod.*;19(6):1242-4.
- Bedaiwy MA, Hussein MR, Biscotti C, Falcone T. (2006) Cryopreservation of intact human ovary with its vascular pedicle. *Hum Reprod.*;21(12):3258-69.
- Bromer JG, Patrizio P. (2009) Fertility preservation: the rationale for cryopreservation of the whole ovary. *Semin Reprod Med.*;27(6):465-71.
- Bukovsky A, Caudle MR, Virant-Klun I, Gupta SK, Dominguez R, Svetlikova M, Xu F. (2009) Immune physiology and oogenesis in fetal and adult humans, ovarian infertility, and totipotency of adult ovarian stem cells. *Birth Defects Res C Embryo Today.*;87(1):64-89.
- Dath C, Van Eyck AS, Dolmans MM, Romeu L, Delle Vigne L, et al. (2010) Xenotransplantation of human ovarian tissue to nude mice: comparison between four grafting sites. *Hum Reprod.*;25(7):1734-43.
- De Felici M. (2010) Germ stem cells in the mammalian adult ovary: considerations by a fan of the primordial germ cells. *Mol Hum Reprod.*;16(9):632-6.
- Demeestere I, Simon P, Emiliani S, Delbaere and Englert Y. (2007) Fertility preservation: Successful transplantation of cryopreserved ovarian tissue in a young patient previously treated for Hodgkin's disease. *The Oncol.*; 12:1437-1442.
- Demeestere I, Simon P, Emiliani S, Delbaere A, Englert Y. (2009) Orthotopic and heterotopic ovarian tissue transplantation. *Hum Reprod Update.*;15(6):649-65.
- Demeestere I, Simon P, Moffa F, Delbaere A, and Englert Y. (2010) Birth of a second healthy girl more than 3 years after cryopreserved ovarian graft. Letter to the Editor, *Hum Reprod* 1590-1591.
- Dolmans MM, Marinescu C, Saussoy P, Van Langendonck A, Amorim C and Donnez J. (2011) Reimplantation of cryopreserved ovarian tissue from patients with acute lymphoblastic leukaemia is potentially unsafe. *Blood*; 116(16):2908-2914.
- Donnez J, Dolmans MM, Demylle D, Jadoul P, Pirard C. (2004) Live birth after orthotopic transplantation of cryopreserved ovarian tissue. *Lancet*. 16-22;364(9443):1405-10.
- Donnez J, Squifflet J, Jadoul P, Demylle D, Cheron AC et al. (2011-a) Pregnancy and live birth after autotransplantation of frozen-thawed ovarian tissue in a patient with metastatic disease undergoing chemotherapy and hematopoietic stem cell transplantation. *Fert Steril.*; 95(5):1787.e1-1787.e4.
- Donnez J, Silber S, Andersen CY, Demeestere I, Piver P, Meirow D, Pellicer A, Dolmans MM. (2011-b) Children born after autotransplantation of cryopreserved ovarian tissue. A review of 13 live births. *Ann Med*, 1-14.
- Ernst E, bergholdt S, Jørgensen JS, Andersen CY (2010) The first woman to give birth to two children following transplantation of frozen/thawed ovarian tissue. *Hum Reprod*, 25(5):1280-1.
- Eppig JJ, O'Brien M and Wigglesworth K.; (1996) Mammalian oocyte growth and development in vitro. *Mol Reprod Dev*, 44(2):260-273.
- Fabbri R, Pasquinelli G, Keane D, Mozzanega B, Magnani V, et al. (2009) Culture of cryopreserved ovarian tissue: state of the art in 2008. *Fertil Steril.*;91(5):1619-29.
- Gosden RG, Baird DT, Wade JC, Webb R. (1994) Restoration of fertility to oophorectomized sheep by ovarian autografts stored at -196 degrees C. *Hum Reprod.*;9(4):597-603.

- Hickey RC, Samaan NA. (1975) Human parathyroid autotransplantation: proved function by radioimmunoassay of plasma parathyroid hormone. *Arch Surg*;110(8):892-5.
- Hovatta O. (2005) Methods for cryopreservation of human ovarian tissue. *Reprod Biomed Online*;10(6):729-34
- Isachenko V, Isachenko E, Reinsberg J, Montag M, van der Ven K, et al. (2007) Cryopreservation of human ovarian tissue: comparison of rapid and conventional freezing. *Cryobiology*. 55(3):261-8.
- Isachenko V, Lapidus I, Isachenko E, Krivokharchenko A, Kreienberg R, et al. (2009) Human ovarian tissue vitrification versus conventional freezing: morphological, endocrinological, and molecular biological evaluation. *Reproduction*. 138(2):319-27.
- Johnson J, Canning J, Kaneko T, Pru JK, Tilly JL. (2004) Germline stem cells and follicular renewal in the postnatal mammalian ovary. *Nature*.11;428(6979):145-50.
- Johnson J, Bagley J, Skaznik-Wikiel M, Lee HJ, Adams GB, et al. (2005) Oocyte generation in adult mammalian ovaries by putative germ cells in bone marrow and peripheral blood. *Cell*. 29;122(2):303-15.
- Kagawa N. Successful vitrification of bovine and human ovarian tissue. (2009) *RBM Online*, 18(4):568-577.
- Keros V, Xella S, Hultenby K, Pettersson K, Sheikhi M, et al. (2009) Vitrification versus controlled-rate freezing in cryopreservation of human ovarian tissue. *Hum Reprod*, 24(7):1670-1683.
- Lee HJ, Selesniemi K, Niikura Y, Niikura T, Klein R, et al. (2007) Bone marrow transplantation generates immature oocytes and rescues long-term fertility in a preclinical mouse model of chemotherapy-induced premature ovarian failure. *J Clin Oncol*. 1;25(22):3198-204.
- Li YB, Zhou CQ, Yang GF, Wang Q, Dong Y. (2007) Modified vitrification method for cryopreservation of human ovarian tissues. *Chin Med J (Engl)*. 20;120(2):110-4.
- Lushbaugh CC, Casarett GW. (1976) The effects of gonadal irradiation in clinical radiation therapy: a review. *Cancer*; 37(2 Suppl):1111-25.
- Maltaris T, Koelbl H, Seufert R, Kiesewetter F, Beckmann MW, et al. (2006) Gonadal damage and options for fertility preservation in female and male cancer survivors. *Asian J Androl*;8(5):515-33.
- Meirow D. and Nugent D. (2001) The effect of radiotherapy and chemotherapy on female reproduction. *Hum Reprod Update*, 7(6):535-543.
- Meirow D and Levron J. (2005) Pregnancy after transplantation of cryopreserved ovarian tissue in a patient with ovarian failure after chemotherapy. *The New Eng J Med*, 353(3):318-321.
- Meirow D, Levron J, Eldar-Geva T, Hardan I, Fridman E et al. (2007) Monitoring the ovaries after autotransplantation of cryopreserved ovarian tissue: endocrine studies, in vitro fertilization cycles, and live birth. *Fertil Steril*, 87(2):418.e7-418.e15.
- Meirow D, Biederman H, Anderson RA, Wallace WH. (2010) Toxicity of chemotherapy and radiation on female reproduction. *Clin Obstet Gynecol*;53(4):727-39.
- Nugent D, Newton H, Gallivan L, Gosden RG. (1998) Nugent D et al. Protective effect of vitamin E on ischaemia-reperfusion injury in ovarian grafts. *J Reprod Fertil*;114(2):341-6.
- Oktay K, Buyuk E, Veeck L, Zaninovic N, Xu K, et al. (2004) Embryo development after heterotopic transplantation of cryopreserved ovarian tissue. *Lancet*. 13;363(9412):837-40.

- Oktem O, Oktay K. (2007) Quantitative assessment of the impact of chemotherapy on ovarian follicle reserve and stromal function. *Cancer*. 15;110(10):2222-9.
- Onions VJ, Webb R, McNeilly AS, Campbell BK. (2009) Ovarian endocrine profile and long-term vascular patency following heterotopic autotransplantation of cryopreserved whole ovine ovaries. *Hum Reprod.*;24(11):2845-55.
- Picton HM, Harris SE, Muruvi W, Chambers EL. (2008) The in vitro growth and maturation of follicles. *Reproduction*.;136(6):703-15.
- Piver P, Amiot C, Agnani G, Pech JC, Rohrlich PS et al. (2009). Two pregnancies obtained after a new technique of autotransplantation of cryopreserved ovarian tissue. Abstract of the 25th Annual Meeting of ESHRE, Amsterdam, the Netherlands, 28 June-1 July, *Hum Reprod*, vol. 24 suppl. 1, session 2.
- Revel A, Laufer N, Meir AB, Lebovich M and Mitrani E. (2011) Micro-organ ovarian transplantation enables pregnancy: a case report. *Hum Rep*, March 18, pp1-7.
- Roux C, Amiot C, Agnani G, Aubard Y, Rohrlich PS, et al. (2010) Live birth after ovarian tissue autograft in a patient with sickle cell disease treated by allogeneic bone marrow transplantation. *Fertil Steril.*. 1;93(7):2413.e15-9.
- Sánchez-Serrano M, Crespo J, Mirabet V, Cobo AC, Escribá MJ, et al. (2010) Twins born after transplantation of ovarian cortical tissue and oocyte vitrification. *Fertil Steril.*;93(1):268.e11-3.
- Schmidt KT, Larsen EC, Andersen CY, Andersen AN. (2010) Risk of ovarian failure and fertility preserving methods in girls and adolescents with a malignant disease. *BJOG*.;117(2):163-74.
- Shaw JM, Bowles J, Koopman P, Wood EC and Trounson AO. (1996). Fresh and cryopreserved ovarian tissue samples from donors with lymphoma transmit the cancer to graft recipients. *Hum Reprod.*; 11(8):1668-1673.
- Shaw JM, Jones GM. (2003) Terminology associated with vitrification and other cryopreservation procedures for oocytes and embryos. *Hum Reprod Update*.;9(6):583-605.
- Silber S, Kagawa N, Kuwayama M, Gosden R. (2010) Duration of fertility after fresh and frozen ovary transplantation. *Fertil Steril* 94(6):2191-2196.
- Sonmezer M and Oktay K. (2010) Orthotopic and heterotopic ovarian tissue transplantation. *Best Pract Res Clin Obstet Gynaecol.*;24(1):113-26.
- Torrents E, Boiso I, Barri PN, Veiga A. (2003) Applications of ovarian tissue transplantation in experimental biology and medicine. *Hum Reprod Up*, 9(5):471-481.
- Von Wolff M, Donnez J, Hovatta O, Keros V, Maltaris T et al. (2009) Cryopreservation and autotransplantation of human ovarian tissue prior to cytotoxic therapy - A technique in its infancy but already successful in fertility preservation. *Eu J Canc* 45:1545-1553.
- Wallace WH, Shalet SM, Hendry JH, Morris-Jones PH, Gattamaneni HR. (1989) Ovarian failure following abdominal irradiation in childhood: the radiosensitivity of the human oocyte. *Br J Radiol.*;62(743):995-8.
- Wallace WH, Kelsey TW. (2010) Human ovarian reserve from conception to the menopause. *PLoS One*. 27;5(1):e8772.
- Wells SA Jr, Gunnells JC, Shelburne JD, Schneider AB, Sherwood LM. (1975) Transplantation of the parathyroid glands in man: clinical indications and results. *Surgery*.;78(1):34-44.



Topics in Cancer Survivorship

Edited by Prof. Ravinder Mohan

ISBN 978-953-307-894-6

Hard cover, 290 pages

Publisher InTech

Published online 27, January, 2012

Published in print edition January, 2012

Cancer is now the leading cause of death in the world. In the U.S., one in two men and one in three women will be diagnosed with a non-skin cancer in their lifetime. Cancer patients are living longer than ever before. For instance, when detected early, the five-year survival for breast cancer is 98%, and it is about 84% in patients with regional disease. However, the diagnosis and treatment of cancer is very distressing. Cancer patients frequently suffer from pain, disfigurement, depression, fatigue, physical dysfunctions, frequent visits to doctors and hospitals, multiple tests and procedures with the possibility of treatment complications, and the financial impact of the diagnosis on their life. This book presents a number of ways that can help cancer patients to look, feel and become healthier, take care of specific symptoms such as hair loss, arm swelling, and shortness of breath, and improve their intimacy, sexuality, and fertility.

How to reference

In order to correctly reference this scholarly work, feel free to copy and paste the following:

Elena Albani, Graziella Bracone, Sonia Di Biccari, Domenico Vitobello, Nicola Fattizzi and Paolo Emanuele Levi-Setti (2012). Human Ovarian Tissue Cryopreservation as Fertility Reserve, Topics in Cancer Survivorship, Prof. Ravinder Mohan (Ed.), ISBN: 978-953-307-894-6, InTech, Available from:
<http://www.intechopen.com/books/topics-in-cancer-survivorship/human-ovarian-tissue-cryopreservation-as-fertility-reserve>

INTECH
open science | open minds

InTech Europe

University Campus STeP Ri
Slavka Krautzeka 83/A
51000 Rijeka, Croatia
Phone: +385 (51) 770 447
Fax: +385 (51) 686 166
www.intechopen.com

InTech China

Unit 405, Office Block, Hotel Equatorial Shanghai
No.65, Yan An Road (West), Shanghai, 200040, China
中国上海市延安西路65号上海国际贵都大饭店办公楼405单元
Phone: +86-21-62489820
Fax: +86-21-62489821

© 2012 The Author(s). Licensee IntechOpen. This is an open access article distributed under the terms of the [Creative Commons Attribution 3.0 License](https://creativecommons.org/licenses/by/3.0/), which permits unrestricted use, distribution, and reproduction in any medium, provided the original work is properly cited.

IntechOpen

IntechOpen