

# We are IntechOpen, the world's leading publisher of Open Access books Built by scientists, for scientists

6,900

Open access books available

186,000

International authors and editors

200M

Downloads

Our authors are among the

154

Countries delivered to

TOP 1%

most cited scientists

12.2%

Contributors from top 500 universities



WEB OF SCIENCE™

Selection of our books indexed in the Book Citation Index  
in Web of Science™ Core Collection (BKCI)

Interested in publishing with us?  
Contact [book.department@intechopen.com](mailto:book.department@intechopen.com)

Numbers displayed above are based on latest data collected.  
For more information visit [www.intechopen.com](http://www.intechopen.com)



# Interdisciplinary Treatment of Aggressive Periodontitis: Three-Dimensional Cone-Beam X-Ray Computed Tomography Evaluation

Tetsutaro Yamaguchi<sup>1</sup>, Kazushige Suzuki<sup>2</sup>,  
Yoko Tomoyasu<sup>1</sup>, Matsuo Yamamoto<sup>2</sup> and Koutaro Maki<sup>1</sup>

<sup>1</sup>*Department of Orthodontics, Showa University School of Dentistry, Tokyo,*

<sup>2</sup>*Department of Periodontology, Showa University School of Dentistry, Tokyo,  
Japan*

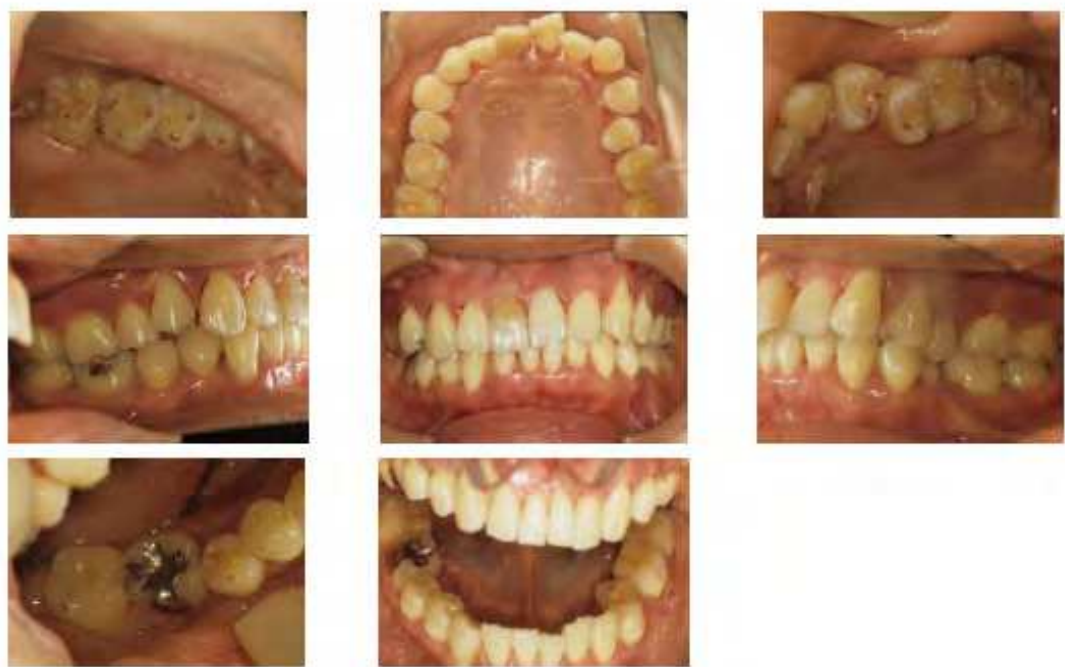## 1. Introduction

Periodontitis is characterized by an inflammatory reaction that affects tooth attachment tissues and can be classified as chronic periodontitis or aggressive periodontitis (AgP) according to clinical characteristics and rate of progression. The current classification of periodontal disease describes two clinically distinct forms of periodontitis. AgP is characterized by rapid progression and severe periodontal destruction, mainly seen in younger individuals (Meng et al., 2007). Chronic periodontitis is characterized by a lower rate of progression (Schätzle et al., 2009). AgP constitutes a group of rare and rapidly progressing forms of periodontitis that are frequently characterized by an early age of clinical onset (Genco et al., 1986). AgP is defined as a destructive periodontal disease affecting more than 14 teeth in young individuals. Its etiology has been linked to the presence of *Aggregatibacter actinomycetemcomitans* (Fine et al., 2007; Haraszthy et al., 2000; Di Rienzo et al., 1994), host response defects (Page et al., 1984, 1985; Lavine et al., 1979), and possibly to genetic inheritance (Hart & Kornman, 1997; Kinane et al., 2000; Boleghman et al., 1992; Beaty et al., 1987; Hart et al., 1992; Melnick et al., 1976; Page et al., 1985). In contrast, chronic periodontitis is characterized by a lower rate of progression (Schätzle et al., 2009), although like AgP it can reach a severe stage, leading to tooth loss and edentulism. Many clinicians report difficulty in establishing a differential diagnosis for AgP and chronic periodontitis due to an overlapping “gray area” that often negates a clear-cut diagnosis. Such issues raise the question of whether these are actually two distinct clinical entities.

In AgP, comprehensive mechanical/surgical and antimicrobial therapy is usually required for long-term stabilization of periodontal health (Buchmann et al., 2002). Enamel matrix proteins have been proposed to promote regeneration of the lost periodontal tissues when used during periodontal surgery (Gestrelius et al., 2000; Hammarström, 1997). Indeed, clinical studies showed that applying the commercially available enamel matrix derivative (EMD) to deep intrabony defects during periodontal flap surgery



A



B

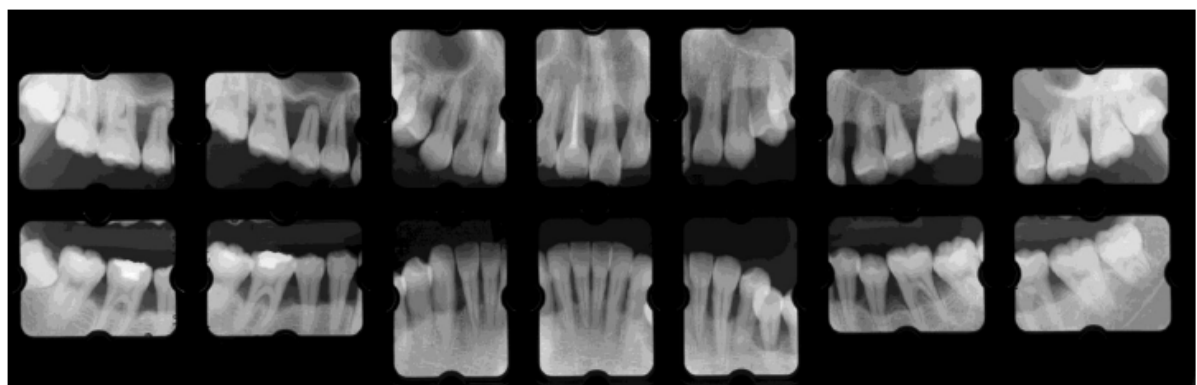
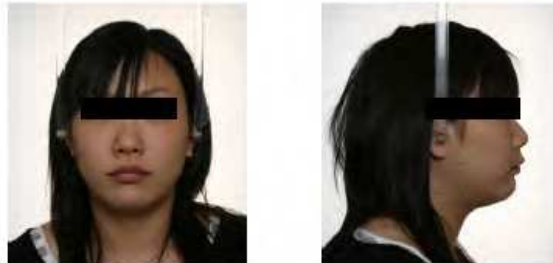

Fig. 1. Oral photographs at initial presentation (A) and dental X-rays at initial presentation (B).

Prior to commencing orthodontic treatment, the patient underwent periodontal treatment. Periodontal treatment involved oral hygiene instructions, scaling, root planing, temporary fixation using 4-META/MMA-TBB resin, occlusal adjustment, and periodontal surgery. After periodontal treatment the patient was introduced to the Department of Orthodontics at Showa University School of Dentistry for tooth alignment. She presented with a Class II malocclusion. Cone-beam CT (CBCT) imaging confirmed aggressive horizontal and vertical alveolar bone resorption throughout the whole area. Facial photographs before orthodontic treatment are presented in Fig. 2A. The maxillary central incisors were crowded (Fig. 2B). The patient's chief concerns for orthodontic treatment were the longevity of her front teeth and the possibility of enhancing aesthetics.

A



B

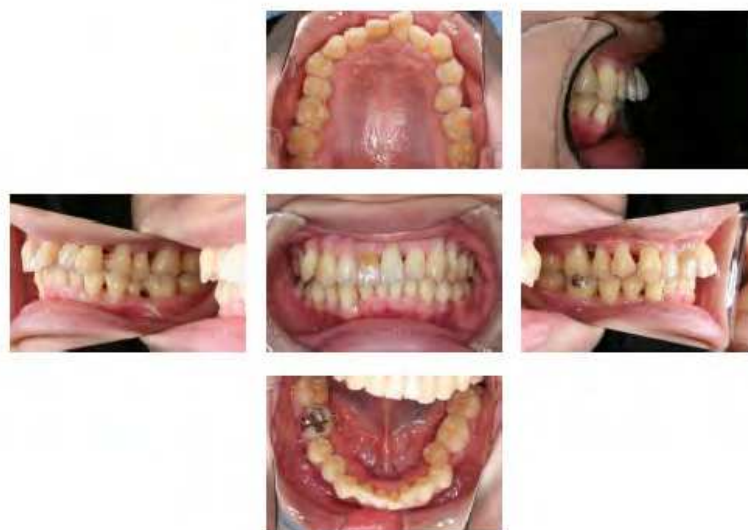

Fig. 2. Facial photographs before orthodontic treatment (A) and oral photographs before orthodontic treatment (B).

### 3. Treatment objectives

The clinical objectives of treatment were as follows: (1) to achieve adequate daily plaque control and clinically healthy gingiva, (2) to avoid occlusal trauma, and (3) to correct the planarization of the alveolar bone level. Furthermore, orthodontic treatment was also planned with the patient's expectations regarding with the longevity of her teeth and enhanced aesthetics.

### 4. Treatment results

Prior to commencing orthodontic treatment, the patient underwent periodontal treatment by a periodontist for 20 months. The primary goal in the treatment of this patient was to control her periodontal infection. Periodontal treatment was started by oral hygiene instruction and subsequent scaling and root planing under local anesthesia. Manual and ultrasonic instruments were used for scaling and root planing. Then, temporary fixation using 4-META/MMA-TBB resin (teeth numbers 16, 15, 14, 13, 23, 24, 25, 26, 33, 34, 35, 36, and 37) and occlusal adjustment were performed with the goals of reducing occlusal interferences in lateral excursions and improving canine guidance. Following the reevaluation after this initial treatment phase, periodontal surgery was performed. The bone defects at the maxillary right second premolar were subjected



to regenerative periodontal surgery. Intrabony defects and root surfaces were degranulated and cleaned with curettes, rinsed with saline, and dried with cotton swabs. The exposed root surfaces were demineralized using EDTA for 2 minutes. After thorough rinsing with saline, EMD (Emdogain; Institut Straumann, Basel, Switzerland) was applied to the root surfaces. The autogenous bone was then blended with EMD, and the osseous defect was grafted. The autogenous bone was harvested using a trephine bar from the extraction fossa around the right third molar in the mandible and crushed using a bone mill (Fig. 3A, B). Radiographs obtained 3 years after surgery showed marked filling of the defects and sharp contours of the hard tissue that had developed (Fig. 4A, B).

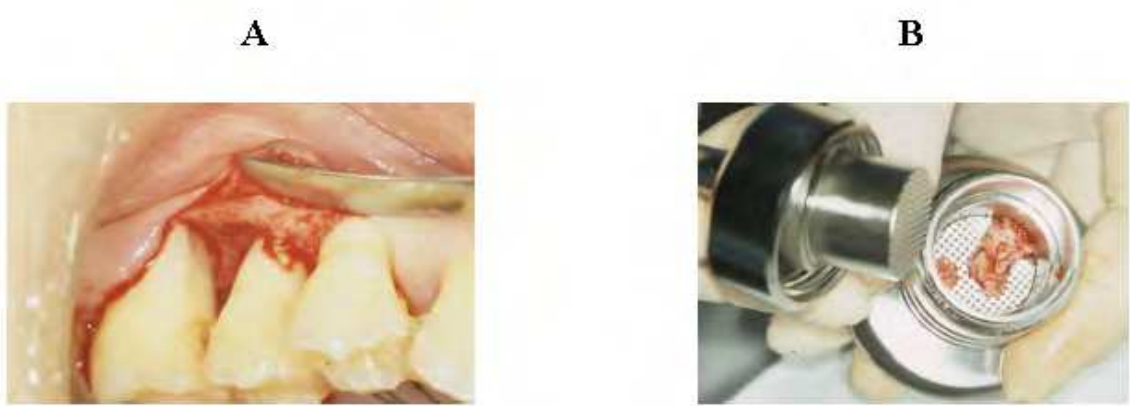

Fig. 3. Buccal view of the surgical wound after a full-thickness flap was reflected, granulation tissue was removed, and the root surfaces and bone defect were conditioned with EDTA. After thorough rinsing with saline, EMD was applied (A). The autogenous bone was harvested using a trephine bar from the extraction fossa around the right third molar in the mandible and crushed using a bone mill (B).

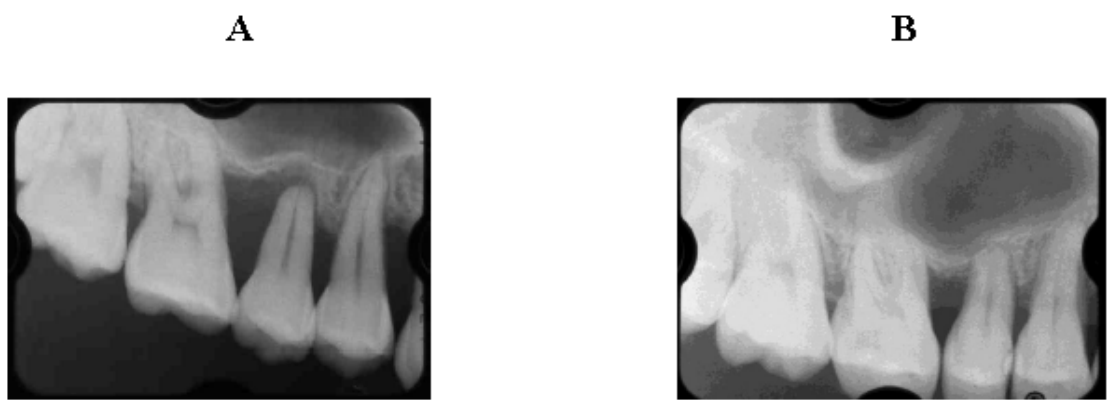


Fig. 4. Radiographs obtained 3 years after surgery showing a marked filling of the defects and sharp contours of the hard tissues gained through therapy.

The right first molar in the mandible had class I furcation involvement at the lingual sites. The furcation involvement was treated by a flap operation with furcation plasty (odontoplasty and osteoplasty) (Fig. 5). Clinical examination showed improved probing depths after periodontal treatment (Table 1B).

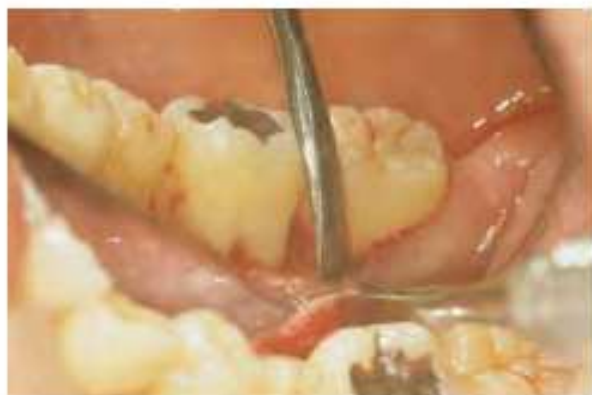

Fig. 5. The mandibular right first molar had class I furcation lesion at the lingual site. The furcation lesion was treated with furcation plasty.

All teeth were sequentially bonded or banded with 0.018- × 0.025-in standard edgewise brackets. For the upper teeth, a 0.012-in round stainless steel archwire was initially placed, followed by a 0.014-in round stainless steel archwire. By 6 months, the incisors were leveled by the use of a 0.016-in round stainless steel archwire. The alignment proceeded until a 0.016- × 0.016-in rectangular archwire was placed. For the lower teeth, the initial archwires consisted of the following: 0.012-in round stainless steel, 0.013- and 0.014-in nickel titanium, followed by 0.016- × 0.016-in nickel titanium archwires by the 9<sup>th</sup> month of treatment. The alignment proceeded until a 0.016- × 0.016-in rectangular archwire was placed. The patient was instructed to carefully clean around the orthodontic appliances and was monitored for gingival and tooth mobility changes at every orthodontic visit. The patient compliance was good throughout the orthodontic treatment period with regular periodontal maintenance appointments. Scaling, localized root planing, polishing, and follow-up examinations of plaque control were performed at each maintenance visit. After 12 months of orthodontic treatment, a removable Hawley retainer for the maxilla and mandible was recommended for nighttime use over the course of a year.

Post-treatment facial photographs are shown in Fig. 6A. Intraoral views (Fig. 6B) showed an acceptable occlusion in which a normal overbite and overjet were achieved. However, the intraoral view also showed that the midlines of the incisors were not coincident. We avoided aggressive tooth movement concerning to the damage of tooth root and periodontal tissue. This resulted in dis-coincident of midline. Cephalometric superimpositions (Fig. 7, Table 2) showed that the incisors were retracted 2 to 3 mm with a slight reduction in protrusion. After full orthodontic treatment, the left central incisor and canine in the maxilla were treated with a connective tissue graft (Fig. 8).

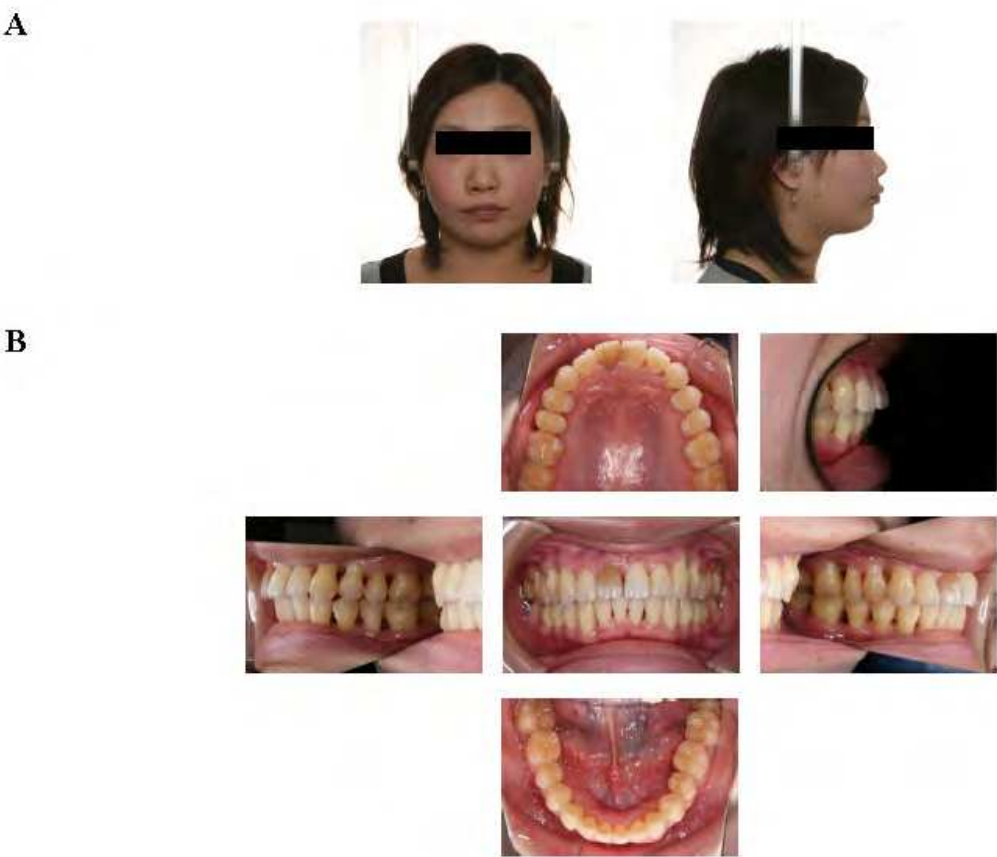


Fig. 6. Facial photographs (A) intraoral photographs (B) after orthodontic treatment.

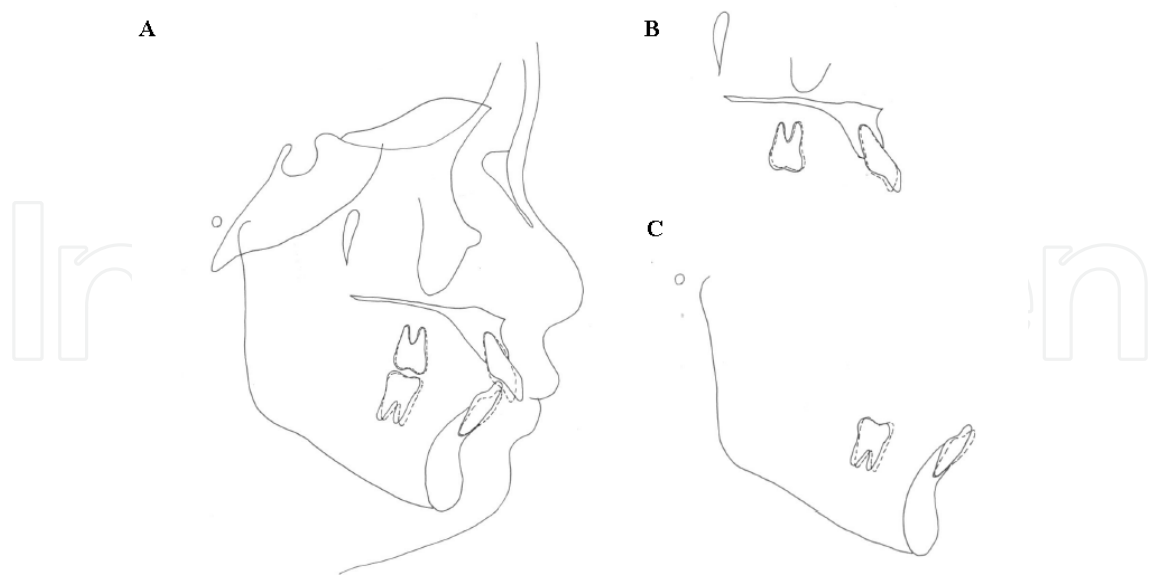


Fig. 7. Superimposed cephalometric tracings, pretreatment (solid line) and post-treatment (dotted line). (A) Superimposed on the SN plane registered at S. (B) Superimposed on the palatal plane registered at ANS. (C) Superimposed on the mandibular plane registered at Me.



Angular (°)	PRE-Tx		POST-Tx	
	Mean	SD	Mean	SD
SNA	83.1	+1	82.9	+1
SNB	78.1	-1	78.2	-1
ANB	5.0	+1	4.7	+1
Mandibular plane angle	33.4	-1	33.5	-1
Gonial angle	121.4	+1	121.7	+1
Ramus inclination	85.2	-1	85.3	-1
U1 to FH plane angle	121.5	+2	117.1	-1
L1 to Mandibular plane angle	102.8	+2	106.1	+2
FMIA	50.7	-1	54.0	-1

The data indicate mean and standard deviation (SD).

Table 2. Cephalometric analysis of patient pre- and post-treatment.

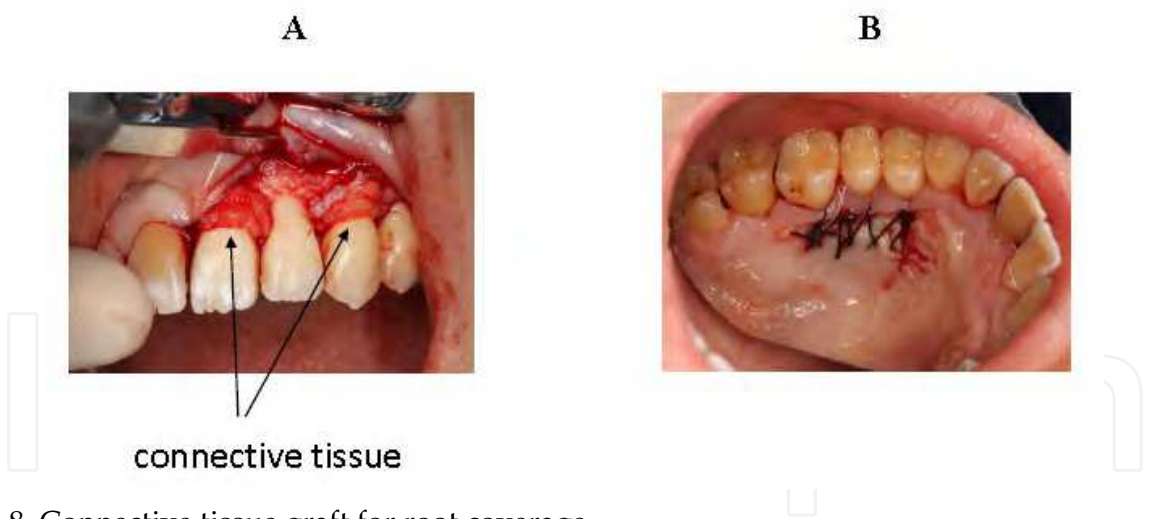


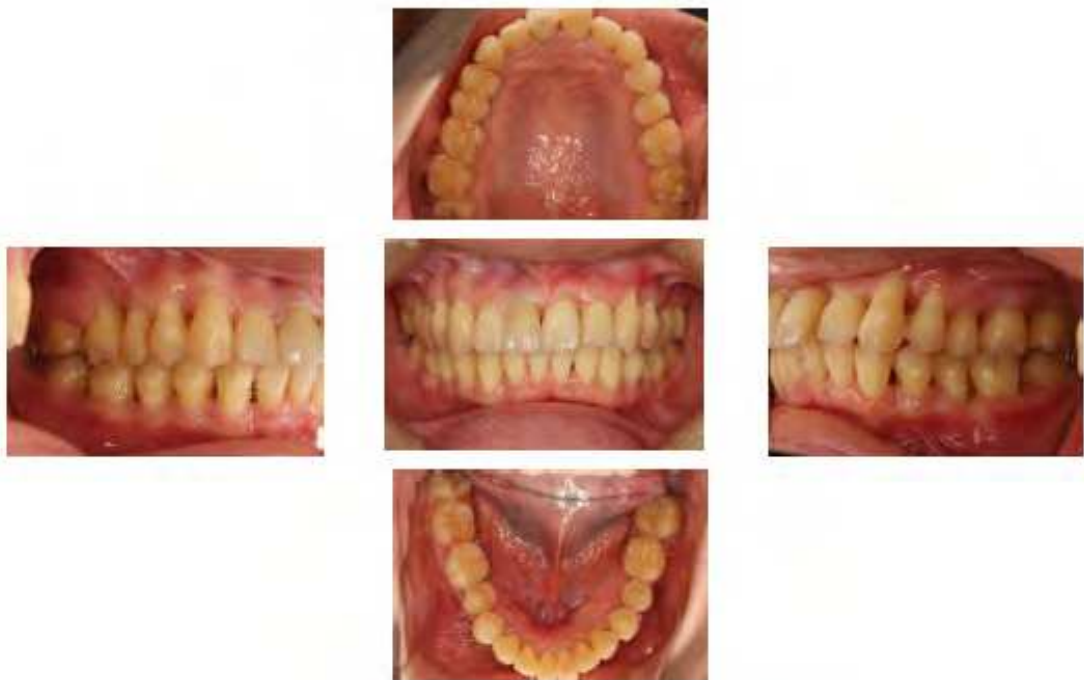Fig. 8. Connective tissue graft for root coverage.

The satisfactory clinical results including the reduction in mean pocket depth from  $3.9 \pm 2.3$  mm to  $2.1 \pm 0.6$  mm and flattening of the alveolar bone level were achieved. Clinical examination showed appreciable gains in clinical attachment levels and improved probing depths from 1 to 4 mm at all sites after periodontal and orthodontic treatment (Table 1C). Radiographic analysis showed improvement in bone height at all sites. Overall, full mouth radiographs showed significant changes in the crater-like bone defects on teeth numbers 21, 23, 35, and 46 (Fig. 9A), and intraoral views showed aesthetic improvement by prosthetic treatment of the central incisor on the upper right side. Tooth mobility was also significantly

reduced compared with pretreatment values. A complete blood count including differential blood counts also improved compared with pretreatment levels.

3D CT allows for precise assessment of bone defects caused by periodontal disease (Naito et al., 1998). In this study, CBCT (CB MercuRay; Hitachi Medical Technology, Tokyo, Japan) was performed prior to orthodontic treatment (Fig. 10, Fig. 12A) and during retention phases (Fig. 11, Fig. 12B). It was confirmed that all teeth were positioned appropriately in alveolar bone.

A



B

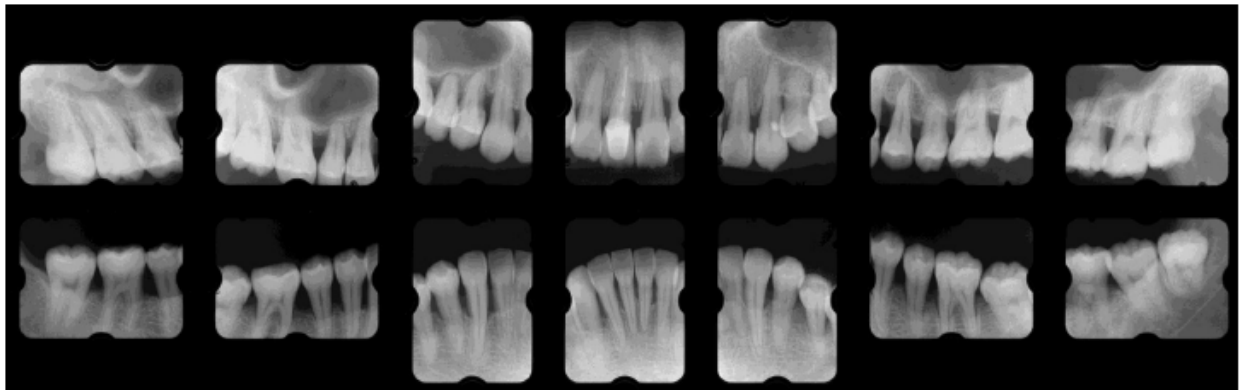


Fig. 9. Oral photographs after prosthetic treatment (A) and dental X-rays at retention (B).

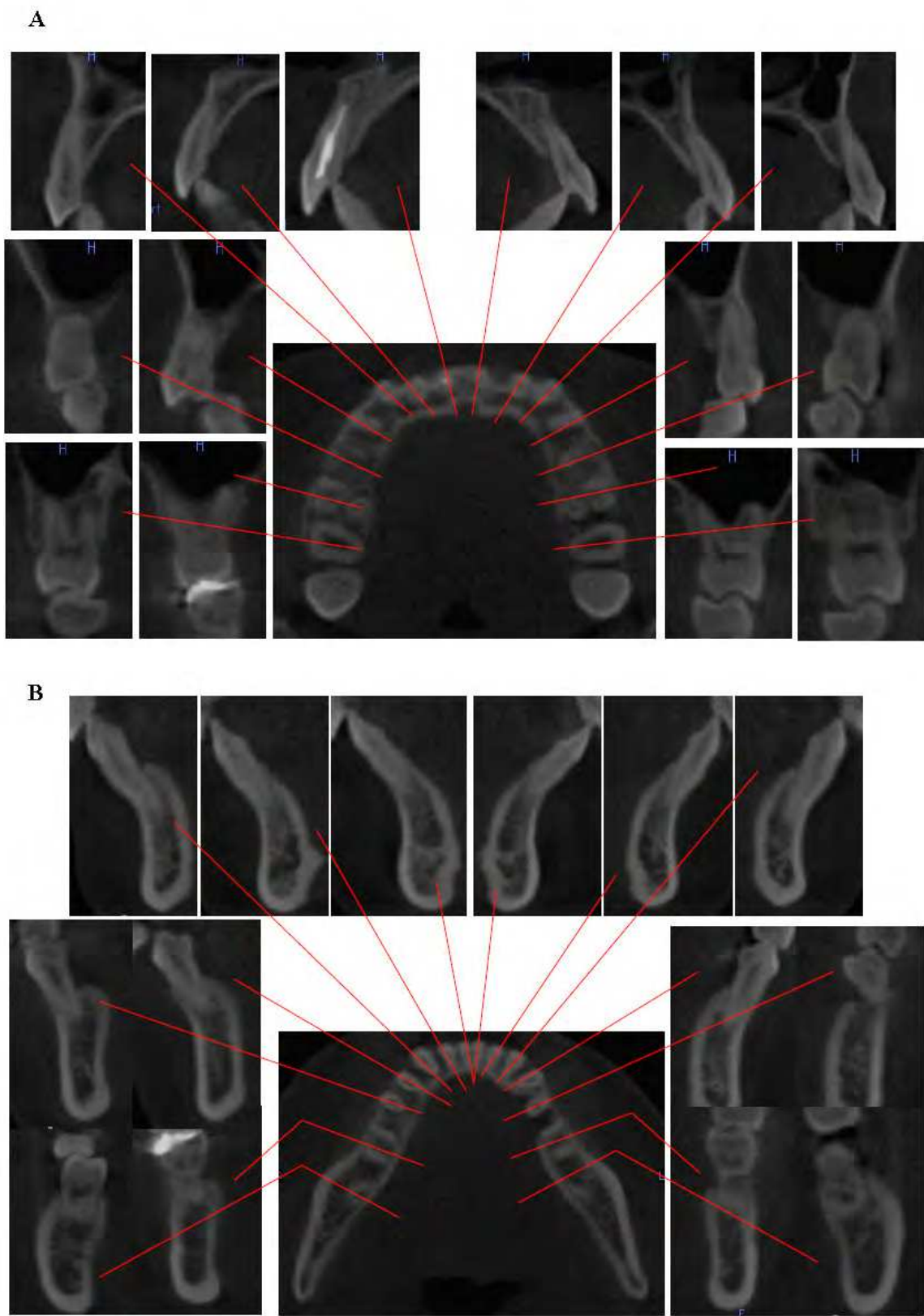


Fig. 10. Cone-beam X-ray computed tomography (CBCT) images of the upper arch in pre-orthodontic treatment (A) and CBCT images of the lower arch in pre-orthodontic treatment (B).

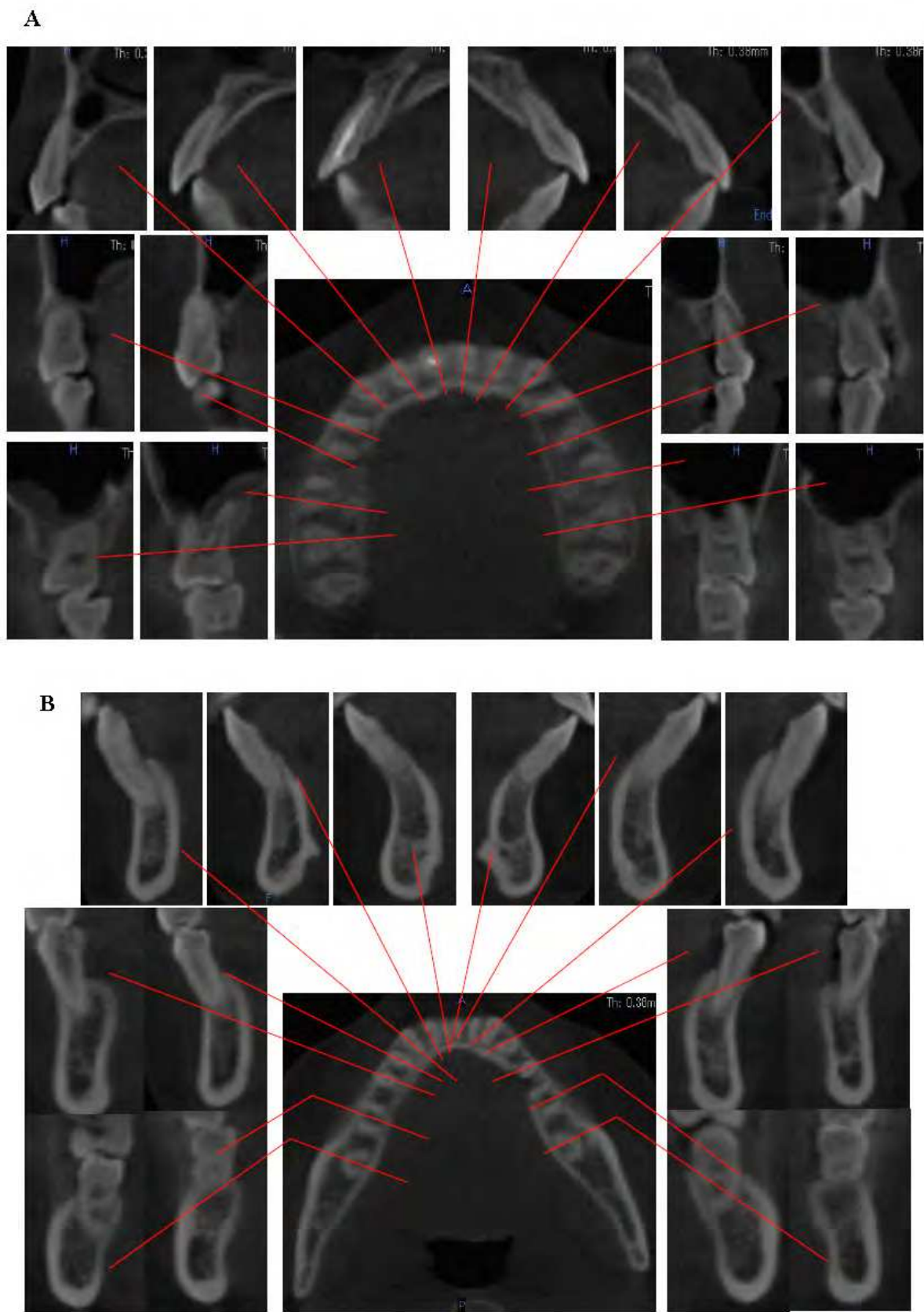
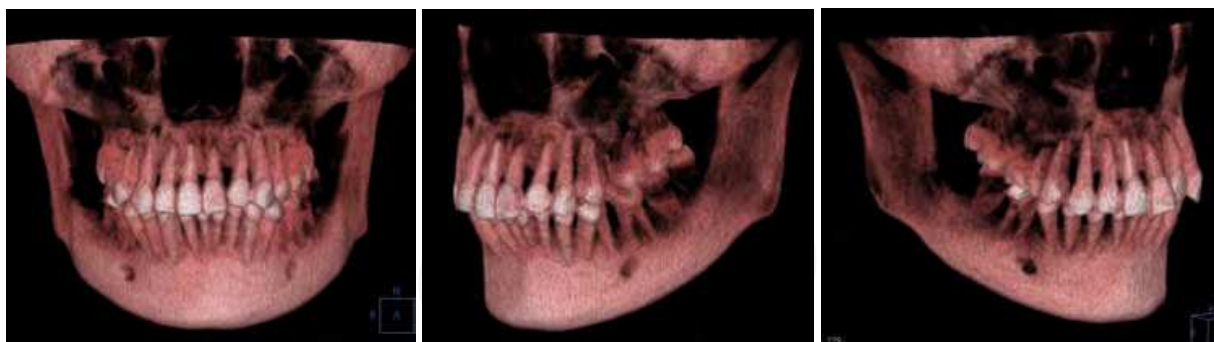

Fig. 11. Cone-beam X-ray computed tomography (CBCT) images of the upper arch during retention phases (A) and CBCT images of the lower arch during retention phases (B).



A



B

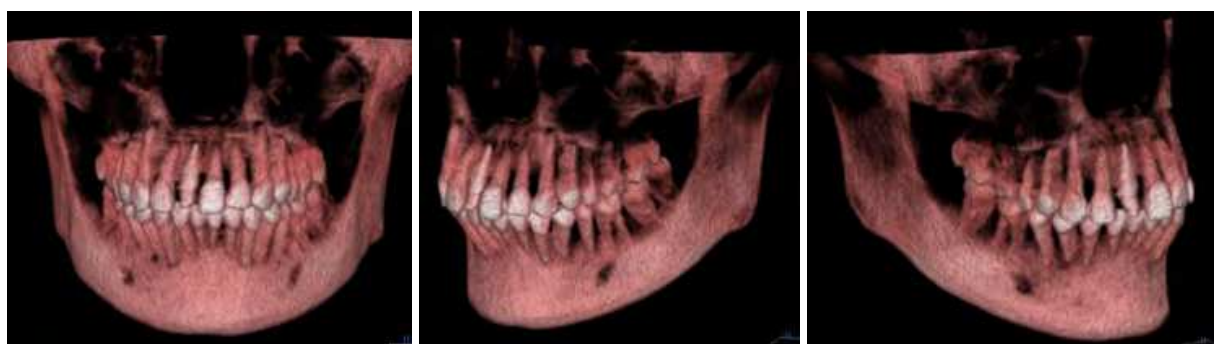

Fig. 12. Volumetric rendering in pre-orthodontic treatment (A) and in pre-orthodontic treatment (B)

## 5. Discussion

Rescala et al. (2010) reported similar microbiological and immunological parameters for subjects with chronic periodontitis and AgP who showed comparable periodontal disease severity. Herein we report dental management of an otherwise healthy patient diagnosed with generalized AgP and rapidly progressing bone loss throughout the mouth. Generalized AgP features loss of supporting tissues in addition to changes in tooth mobility and pathological tooth movement that are associated with sustained periodontal tissue destruction. In such cases, a comprehensive and effective treatment plan often includes periodontal therapy to relieve inflammation and orthodontic treatment to correct malocclusion. Comprehensive periodontal therapy is also often necessary in severe chronic periodontitis. The present patient showed a successful periodontal response with no progressive bone loss during or after treatment.

The strategy of treatment planning for periodontitis patients with aggressive or chronic periodontitis is well established. For patients with aggressive or chronic periodontitis, phases of treatment - systemic, initial, re-evaluation, surgical, maintenance, and restorative - are generally accepted. The amount of active planning required at each step may be greater for the patient with aggressive periodontal disease. To retain teeth cannot help but complicate the treatment-planning process. Therefore, the patient with aggressive periodontitis to have experienced attachment loss would be expected at a younger age, at a



faster rate and to a greater extent than the patient with chronic periodontitis (Deas et al., 2010).

Some authors reported that tooth intrusion might deepen the defect and improve blood circulation (Vandevska-Radunovic et al., 1994; Ericsson et al., 1977), suggesting that this provides a better environment for guided tissue regeneration procedures (Rabie et al., 1996). In the presence of osteoinductive factors, mesenchymal cells differentiate into cells capable of regenerating the periodontal structures. This procedure is an alternative to rebuilding the bone and the original periodontal architecture. It therefore seems reasonable to manage a patient with compromised periodontal dentition using an interdisciplinary approach consisting of both orthodontic and periodontal treatment strategies.

In this study, the initial periodontal treatment was followed by periodontal regeneration therapy using EMD for the maxillary right second premolar. The bone defect involved one to two wall defects and the radiographic bone gain was 4-5 mm in the 3 year follow-up evaluation after surgery. In prospective controlled clinical trials using EMD therapy, clinical attachment gains of 2.2-3.4 mm have been observed in addition to bone growth (Pontoriero et al., 1999; Sculean et al., 2001; Heijl et al., 1997). Thus, the clinical findings presented herein are equal to or better than those in previous reports, and there are a number of clinical scenarios associated with this therapy: (1) EMD only, if the defect is well contained, i.e., two- and three-walled intrabony defects and craters; (2) a combination of EMD and graft material, as in cases of moderate to deep, non-contained intraosseous defects; and (3) a combination of EMD, graft material, and barrier membrane, as in supracrestal cases with shallow intraosseous defects. In each case, a coronally advanced flap procedure must be performed (Froum et al., 2001). Because the patient in this report presented with a non-contained intraosseous bone defect of the maxillary right second premolar, we performed combination therapy of EMD and autogenous grafting, which resulted in a satisfactory and uneventful treatment outcome.

Meticulous initial therapy and good oral hygiene are considered prerequisites for successful regenerative periodontal surgery (Cortellini et al., 1994). In studies reporting the best regenerative outcomes, patients with chronic periodontitis were carefully selected regarding oral hygiene performance, the proportion of bleeding sites remaining after initial periodontal therapy, as well as smoking habits (Cortellini & Tonetti, 2005; Wachtel et al., 2003). In agreement with these reports, the present patient with AgP qualified for periodontal regeneration therapy using EMD as a nonsmoker with low plaque levels and minimal bleeding scores.

Early comparisons of imaging techniques have shown that CT yields more detailed information than conventional radiography for visualizing bone (Sarikaya et al., 2002; Ericson & Kurol, 1988). Consequently, CT is now frequently used to qualitatively and quantitatively assess potential implant sites (Fuhrmann et al., 1995), instead of conventional dental radiographs, which do not allow for the evaluation of dehiscence at the implant site. Cone Beam CT (CBCT) and other such 3D technologies compare well with traditional methods, with the additional advantage that periodontal defects can be observed in all directions (Misch et al., 2006). It is clinically important to determine the direction of orthodontic movement and the groups of teeth with higher risks of dehiscence and

fenestration. In the present case, all teeth were appropriately maintained in alveolar bone, and the recovery of such bone in molar regions was also investigated using CBCT.

An important factor underlying the successful periodontal outcome and lack of progressive bone loss during and after treatment in the present case was the patient's strict adherence to regular periodontal maintenance at 3-monthly intervals. A recent longitudinal study indicated that patients with reduced, but healthy periodontal tissues (after successful periodontal treatment) undertook a full course of orthodontic treatment with fixed appliances without the occurrence of additional bone loss, provided that plaque removal was effective and a 3-monthly periodontal maintenance schedule was followed (Boyd et al., 1989). Periodontal disease progression was successfully arrested in 95% of the initially compromised lesions, while 2-5% of patients experienced discrete or recurrent episodes of loss of periodontal support (Buchmann et al., 2002). It is therefore clear that periodontal follow-up is crucial for successful treatment. In many patients with a periodontally involved dentition, pathological tooth migration can create serious functional and aesthetic problems. The coordination of proper orthodontic and periodontal therapies has proven to be effective in such situations, with long-term stability of the results obtained. A key point for achieving therapeutic success is therefore the patient's periodontal health status prior to and during the orthodontic treatment. Because periodontal health is essential for any form of dental treatment, good oral hygiene at home and professional maintenance care are important during and after active orthodontic treatment.

## 6. Conclusion

Prior to the commencement of orthodontic treatment, periodontal inflammation should be appropriately addressed by eliminating calculus and overhanging restorations, scaling, root planing, and instructing patients on proper oral hygiene. Deep pockets must be eliminated before orthodontic treatment to avoid apical displacement of plaque to avoid establishing progressive periodontal lesions.

Unlike other imaging methods, CBCT allows detailed imaging of periodontal defects to be gathered from a number of directions. The application of this technology is highly relevant for oral health professionals because it potentially provides the necessary information on tooth movement to the treating orthodontist and allows the periodontist to make treatment plans for periodontal disease.

## 7. Acknowledgment

We would like to acknowledge the clinically relevant technical advice given by Professor Hajime Miyashita.

## 8. References

- Beaty, T.H., Boleghman, J.A., Yang, P., et al. (1987). Genetic analysis of juvenile periodontitis in families ascertained through an affected proband. *Am J Hum Genet*, Vol.40, No.5, (May 1987), pp. 443-452, ISSN 0002-9297

- Bolegelman, J.A., Astemborski, J.A., Suzuki, J.B. (1992). Phenotypic assessment of early onset periodontitis in sibships. *J Clin Periodontol*, Vol.19, No.4, (April 1992), pp. 233-239, ISSN 0303-6979
- Boyd, R.L., Leggott, P.J., Quinn, R.S., et al. (1989). Periodontal implications of orthodontic treatment in adults with reduced or normal periodontal tissues versus those of adolescents. *Am J Orthod Dentofacial Orthop*, Vol.96, No.3, (September 1989), pp. 191-198, ISSN 0889-5406
- Buchmann, R., Nunn, M.E., Van Dyke, T.E., et al. (2002). Aggressive periodontitis: 5-year follow-up of treatment. *J Periodontol*, Vol.73, No.6, (June 2002), pp. 675-683, ISSN 0022-3492
- Cortellini, P., Pini-Prato, G., Tonetti, M. (1994). Periodontal regeneration of human infrabony defects (V). Effect of oral hygiene on long-term stability. *J Clin Periodontol*, Vol.21, No.9, (October 1994), pp. 606-610, ISSN 0303-6979
- Cortellini, P., Tonetti, M.S. (2005). Clinical performance of a regenerative strategy for intrabony defects: Scientific evidence and clinical experience. *J Periodontol*, Vol.76, No.3, (March 2005), pp. 341-350, ISSN 0022-3492
- Deas, D.E., Mealey, B.L. (2010). Response of chronic and aggressive periodontitis to treatment. *Periodontol 2000*, Vol.53, (June 2010), pp. 154-166, ISSN 1600-0757
- Di Rienzo, J.M., Slots, J., Sixou, M., et al. (1994). Specific genetic variants of *Actinobacillus actinomycetemcomitans* correlate with disease and health in a regional population of families with localized juvenile periodontitis. *Infect Immun*, Vol.62, No.8, (August 1994), pp. 3058-3065, ISSN 0019-9567
- Ericsson, I., Thilander, B., Lindhe, J., et al. (1977). The effect of orthodontic tilting movements on the periodontal tissues of infected and non-infected dentitions in dogs. *J Clin Periodontol*, Vol.4, No.4, (November 1977), pp. 278-293., ISSN 0303-6979
- Ericson, S., Kurol, J. (1988) CT diagnosis of ectopically erupting maxillary canines--a case report. *Eur J Orthod*, Vol.10, No.2, (May 1988), pp. 115-121, ISSN 0141-5387
- Ferrario, V.F., Sforza, C., Puleo, A., et al. (1996). Three-dimensional facial morphometry and conventional cephalometrics: a correlation study. *Int J Adult Orthodon Orthognath Surg*, Vol.11, No.4, (1996), pp. 329-338, ISSN 0742-1931
- Fine, D., Markowitz, K., Furgang, D., et al. (2007). *Aggregatibacter actinomycetemcomitans* and its relationship to initiation of localized aggressive periodontitis: Longitudinal cohort study of initially healthy adolescents. *J Clin Microbiol*, Vol.45, No.12, (December 2007), pp. 3859-3869, ISSN 0095-1137
- Froum, S., Lemler, J., Horowitz, R., et al. (2001). The use of enamel matrix derivative in the treatment of periodontal osseous defects: a clinical decision tree based on biologic principles of regeneration. *Int J Periodontics Restorative Dent*, Vol.21, No.5, (October 2001), pp. 437-449, ISSN 0198-7569
- Fuhrmann, R.A., Wehrbein, H., Langen, H.J., et al. (1995). Assessment of the dentate alveolar process with high resolution computed tomography. *Dentomaxillofac Radiol*, Vol.24, No.1, (February 1995), pp. 50-54, ISSN 0250-832X

- Genco, R.J., Christersson, L.A., Zambon, J.J. (1986). Juvenile periodontitis. *Int Dent J*, Vol.36, No.3, (September 1986), pp. 168-176, ISSN 0020-6539
- Gestrelus, S., Lyngstadaas, S.P., Hammarström, L. (2000). Emdogain--periodontal regeneration based on biomimicry. *Clin Oral Investig*, Vol.4, No.2, (June 2000), pp. 120-125, ISSN 1432-6981
- Gold, L., Nazarian, L.N., Johar, A.S., et al. (2003). Characterization of maxillofacial soft tissue vascular anomalies by ultrasound and color Doppler imaging: an adjuvant to computed tomography and magnetic resonance imaging. *J Oral Maxillofac Surg*, Vol.61, No.1, (January 2003), pp. 19-31, ISSN 0278-2391
- Hammarström, L. (1997). Enamel matrix, cementum development and regeneration. *J Clin Periodontol*, Vol.24, No.9 Pt 2, (September 1997), pp. 658-668, ISSN 0303-6979
- Haraszthy, V.I., Hariharan, G., Tinoco, E.M., et al. (2000). Evidence for the role of highly leukotoxic *Actinobacillus actinomycetemcomitans* in the pathogenesis of localized juvenile and other forms of early-onset periodontitis. *J Periodontol*, Vol.71, No.6, (June 2000), pp. 912-922, ISSN 0022-3492
- Hart, T.C., Kornman, K.S. (1997). Genetic factors in the pathogenesis of periodontitis. *Periodontol 2000*, Vol.14, (June 1997), pp. 202-215, ISSN 0906-6713
- Hart, T.C., Marazita, M.L., Schenkein, H.A., et al. (1992). Re-interpretation of the evidence for X-linked dominant inheritance of juvenile periodontitis. *J Periodontol*. Vol.63, No.3, (March 1992), pp. 169-173, ISSN 0022-3492
- Heden, G., Wennström, J.L. (2006). Five-year follow-up of regenerative periodontal therapy with enamel matrix derivative at sites with angular bone defects. *J Periodontol*, Vol.77, No.2, (February 2006), pp. 295-301, ISSN 0022-3492
- Heijl, L., Heden, G., Svärdröm, G., et al.. (1997) Enamel matrix derivative (EMDOGAIN) in the treatment of intrabony periodontal defects. *J Clin Periodontol*. Vol.24, No.9 Pt 2, (September 1997), pp. 705-714, ISSN 0303-6979
- Kinane, D.F., Shiba, H., Hart, T.C. (2005). The genetic basis of periodontitis. *Periodontol 2000*, Vol.39, (2005), pp. 91-117, ISSN 0906-6713
- Lavine, W.S., Maderazo, E.G., Stolman, J., et al. (1979). Impaired neutrophil chemotaxis in patients with juvenile and rapidly progressing periodontitis. *J Periodontal Res*, Vol.14, No.1, (January 1979), pp. 10-19, ISSN 0022-3484
- Maki, K., Inou, N., Takanishi, A., et al. (2003). Computer-assisted simulations in orthodontic diagnosis and the application of a new cone beam X-ray computed tomography. *Orthod Craniofac Res*, Vol.6, Suppl 1, (2003), pp. 95-101, ISSN 1601-6335
- McLain, J.B., Proffit, W.R., Davenport, R.H. (1983). Adjunctive orthodontic therapy in the treatment of juvenile periodontitis: report of a case and review of the literature. *Am J Orthod*, Vol.83, No.4, (April 1983), pp. 290-298, ISSN 0002-9416
- Melnick, M., Shields, E.D., Bixler, D. (1976). Periodontosis: A phenotypic and genetic analysis. *Oral Surg Oral Med Oral Pathol*, Vol.42, No.1, (July 1976), pp. 32-41, ISSN 0030-4220



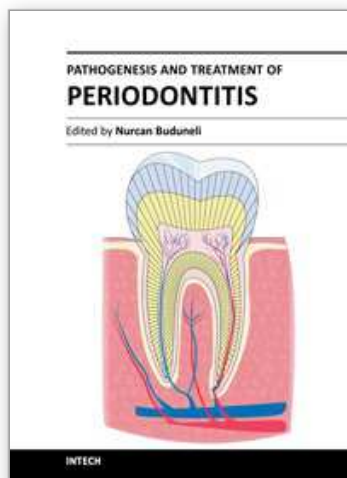
- Meng, H., Xu, L., Li, Q., et al. (2007). Determinants of host susceptibility in aggressive periodontitis. *Periodontol 2000*, Vol.43, (2007), pp. 133-159, ISSN 0906-6713
- Misch, K.A., Yi, E.S., Sarment, D.P. (2006). Accuracy of cone beam computed tomography for periodontal defect measurements. *J Periodontol*, Vol.77, No.7, (July 2006), pp. 1261-1266, ISSN 0022-3492
- Naito, T., Hosokawa, R., Yokota, M. (1998). Three-dimensional alveolar bone morphology analysis using computed tomography. *J Periodontol*. Vol.69, No.5, (May 1998), pp. 584-589, ISSN 0022-3492
- Page, R.C., Sims, T.J., Geissler, F., et al. (1984). Abnormal leukocyte motility in patients with early-onset periodontitis. *J Periodontal Res*, Vol.19, No.6, (November 1984), pp. 591-594, ISSN 0022-3484
- Page, R.C., Sims, T.J., Geissler, F., et al. (1985). Defective neutrophil and monocyte motility in patients with early onset periodontitis, *Infect Immun*, Vol.47, No.1, (January 1985), pp. 169-175, ISSN 0019-9567
- Page, R.C., Vandestein, G.E., Ebersole, J.L., et al. (1985). Clinical and laboratory studies of a family with a high prevalence of juvenile periodontitis. *J Periodontol*. Vol.56, No.10, (October 1985), pp. 602-610, ISSN 0022-3492
- Pontoriero, R., Wennström, J., Lindhe, J. (1999). The use of barrier membranes and enamel matrix proteins in the treatment of angular bone defects. A prospective controlled clinical study. *J Clin Periodontol*, Vol.26, No.12, (December 1999), pp. 833-840, ISSN 0303-6979
- Rabie, A.B., Dan, Z., Samman, N. (1996). Ultrastructural identification of cells involved in the healing of intramembranous and endochondral bones. *Int J Oral Maxillofac Surg*, Vol.25, No.5, (October 1996), pp. 383-388, ISSN 0901-5027
- Rescala, B., Rosalem, W. Jr., Teles, R.P., et al. (2010). Immunologic and microbiologic profiles of chronic and aggressive periodontitis subjects. *J Periodontol*, Vol.81, No.9, (2010), pp. 1308-1316, ISSN 1943-3670
- Sarikaya, S., Haydar, B., Ciger, S., et al. (2002). Changes in alveolar bone thickness due to retraction of anterior teeth. *Am J Orthod Dentofacial Orthop*, Vol.122, No.1, (July 2002), pp. 15-26, ISSN 0889-5406
- Schätzle, M., Faddy, M.J., Cullinan, M.P., et al. (2009). The clinical course of chronic periodontitis: V. Predictive factors in periodontal disease. *J Clin Periodontol*, Vol.36, No.5, (2009), pp. 365-371, ISSN 1600-051X
- Sculean, A., Windisch, P., Chiantella, G.C., et al. (2001). Treatment of intrabony defects with enamel matrix proteins and guided tissue regeneration. A prospective controlled clinical study. *J Clin Periodontol*, Vol.28, No.5, (May 2001), pp. 397-403, ISSN 0303-6979
- Wachtel, H., Schenk, G., Böhm, S., et al. (2003). Microsurgical access flap and enamel matrix derivative for the treatment of periodontal intrabony defect: A controlled clinical study. *J Clin Periodontol*, Vol.30, No.6, (June 2003), pp. 496-504, ISSN 0303-6979



Vandevska-Radunovic, V., Kristiansen, A.B., Heyeraas, K.J., et al. (1994). Changes in blood circulation in teeth and supporting tissues incident to experimental tooth movement. *Eur J Orthod*, Vol.16, No.5, (October 1994), pp. 361-369, ISSN 0141-5387

IntechOpen

IntechOpen



## **Pathogenesis and Treatment of Periodontitis**

Edited by Prof. Nurcan Buduneli

ISBN 978-953-307-924-0

Hard cover, 200 pages

**Publisher** InTech

**Published online** 20, January, 2012

**Published in print edition** January, 2012

Pathogenesis and Treatment of Periodontitis includes comprehensive reviews on etiopathogenic factors of periodontal tissue destruction related to microbial dental plaque and also host response components. Adjunctive treatment modalities are also addressed in the book. Topics covered range from microbial pathogenic factors of *P. gingivalis* to the relationship between metabolic syndrome and periodontal disease, and from management of open gingival embrasures to laser application in periodontal treatment.

### **How to reference**

In order to correctly reference this scholarly work, feel free to copy and paste the following:

Tetsutaro Yamaguchi, Kazushige Suzuki, Yoko Tomoyasu, Matsuo Yamamoto and Koutaro Maki (2012). Interdisciplinary Treatment of Aggressive Periodontitis: Three-Dimensional Cone-Beam X-Ray Computed Tomography Evaluation, Pathogenesis and Treatment of Periodontitis, Prof. Nurcan Buduneli (Ed.), ISBN: 978-953-307-924-0, InTech, Available from: <http://www.intechopen.com/books/pathogenesis-and-treatment-of-periodontitis/interdisciplinary-treatment-of-aggressive-periodontitis-three-dimensional-cone-beam-x-ray-computed-t>

**INTECH**  
open science | open minds

### **InTech Europe**

University Campus STeP Ri  
Slavka Krautzeka 83/A  
51000 Rijeka, Croatia  
Phone: +385 (51) 770 447  
Fax: +385 (51) 686 166  
[www.intechopen.com](http://www.intechopen.com)

### **InTech China**

Unit 405, Office Block, Hotel Equatorial Shanghai  
No.65, Yan An Road (West), Shanghai, 200040, China  
中国上海市延安西路65号上海国际贵都大饭店办公楼405单元  
Phone: +86-21-62489820  
Fax: +86-21-62489821

© 2012 The Author(s). Licensee IntechOpen. This is an open access article distributed under the terms of the [Creative Commons Attribution 3.0 License](https://creativecommons.org/licenses/by/3.0/), which permits unrestricted use, distribution, and reproduction in any medium, provided the original work is properly cited.

IntechOpen

IntechOpen