

We are IntechOpen, the world's leading publisher of Open Access books Built by scientists, for scientists

6,900

Open access books available

185,000

International authors and editors

200M

Downloads

Our authors are among the

154

Countries delivered to

TOP 1%

most cited scientists

12.2%

Contributors from top 500 universities



WEB OF SCIENCE™

Selection of our books indexed in the Book Citation Index
in Web of Science™ Core Collection (BKCI)

Interested in publishing with us?
Contact book.department@intechopen.com

Numbers displayed above are based on latest data collected.
For more information visit www.intechopen.com



Implications of Human Papillomavirus Infections in the Biology of Head and Neck Cancers

Descamps Géraldine¹, Duray Anaëlle¹,
Delvenne Philippe² and Saussez Sven¹

¹Laboratory of Anatomy, Faculty of Medicine and Pharmacy,
University of Mons

²Department of Pathology, CHU Sart-Tilman, University of Liège
Belgium

1. Introduction

1.1 Epidemiology

Head and neck squamous cell carcinomas (HNSCCs) remain a significant cause of morbidity worldwide, with as many as 466831 and 168368 cases diagnosed in 2008 among men and women, respectively (Globocan, 2008; Grandis et al., 2004; Shah et al., 2003). HNSCCs constitute a collection of diseases that, despite their shared location and histology, can become different types of tumors that differ in pathogenesis, biology, sub-location and treatment and that can affect quality of life, including survival (Grandis et al., 2004; Shah et al., 2003). HNSCC patients in the early clinical stages (stages I and II) have similar survival rates, with a five-year survival between 70 and 90%, independent of the sub-location (Forastiere & Trotti, 1999). In contrast, HNSCC patients in the advanced clinical stages (stages III and IV) display completely different survival rates depending on the histological type of the tumor and its sub-location (Denis et al., 2004; Forastiere & Trotti, 1999). In 2008, Globocan data indicated that HNSCCs constituted the sixth and eighth most frequent cancer among men and women, respectively. Their frequency has varied over the last 20 years, with an increasing prevalence in women, which is highest in Europe, and a decreasing prevalence in men, which is highest in the USA. A comparison of global statistics with official data from Belgium reveals a strikingly increased incidence of HNSCCs in both sexes, with important regional differences. Indeed, Belgium has a higher incidence of HNSCC associated with smoking and alcohol consumption compared with other countries. In 2005, HNSCCs were the fourth most common cancer in men after prostate, lung and colorectal cancers and the eighth most common cancer in women after breast, colorectal, uterine, lung, melanoma, ovarian cancers and non-Hodgkin's lymphoma (Filleul et al., 2011). We can also observe inter-regional heterogeneity; in fact, the incidence is higher in men in Wallonia than in the Brussels region where the incidence of HNSCC in women rose. Finally, when we compare Belgian and French data, these cancers seem more frequent in French men than in

Belgian men, but there is an opposite trend among women, in which carcinomas of the larynx are more frequent in Belgium than in France.

1.2 Treatments of HNSCCs

The treatment of HNSCC patients in advanced disease stages combines surgery, radiation oncology, medical oncology, medical imaging and clinical pathology (Denis et al., 2004; Forastiere & Trotti, 1999; Grandis et al., 2004; Shah et al., 2003). This type of collaborative medical approach was initiated as early as 1970 when Fletcher and Evers reported the first convincing evidence showing the benefits of combining radiotherapy with surgery (Adelstein et al., 2003). In this context, cisplatin was investigated for the treatment of HNSCC in the early 1970s, and, from the late 1970s to the early 1990s, promising results were obtained with the use of various combinations of postoperative chemotherapy with radiotherapy in randomized (Al-Sarraf et al., 1998) and non-randomized studies (Jeremic et al., 2000). In the early 2000s, the Radiation Therapy Oncology Group (Denis et al., 2004) and the European Organization for Research and Treatment of Cancer (EORTC) (Cooper et al., 2004) conducted two randomized studies to test the relative efficacy of concurrent postoperative cisplatin administration and radiotherapy in the treatment of HNSCC. These two studies demonstrated that local control of the disease was significantly higher in the combined therapy group than in the group that received radiotherapy alone. Unfortunately, these combined treatments were frequently associated with adverse side effects. Although significant progress has been observed after combined treatments, a number of statements concerning HNSCCs currently remain valid: (i) almost two-thirds of HNSCC patients have advanced forms (stages III and IV) of the disease at diagnosis, (ii) 50% of HNSCC patients die within the two years following the initial diagnosis, and (iii) every year, 5% of the patients develop additional primary tumors. Therefore, novel approaches seem to be required to provide head and neck oncologists with a more effective armamentarium against this challenging disease (Bernier et al., 2004; Lang et al., 2004).

1.3 Risk factors for the development of HNSCC

Tobacco use and alcohol consumption are now well-established risk factors for the development of HNSCC; however, a proportion of HNSCC patients (15–20%) develop tumors even in the absence of exposure to these agents (Gillison et al., 2000). Moreover, Sturgis and Cinciripini reported that the overall incidence of HNSCC has declined in the United States over the past 20 years, which has been attributed to a decrease in smoking. Nevertheless, the study also demonstrated an increase in the frequency of tongue and pharyngeal cancers (Sturgis & Cinciripini, 2007). These findings suggest the importance of other risk factors, such as human papillomavirus (HPV), in the development of oropharyngeal and oral carcinomas.

2. HNSCC and HPV: incidence, biological pathways and impact on prognosis

Currently, persistent high-risk HPV (hr HPV) infection is widely accepted as the major cause of uterine cervical carcinoma with HPV 16 and 18 being the two most implicated types. These oncogenic papillomaviruses have also been related to others lesions, such as vulvar, vaginal, penile, anal and more recently, head and neck squamous cell carcinomas

(Chung & Gillison, 2009). Since 1983 when Syrjänen published the first study analyzing HPV infection in HNSCCs, the etiological role of HPV has become increasingly accepted. Indeed, although tobacco and alcohol exposure are established risk factors for HNSCCs, HPV infection may act synergistically with these carcinogenic agents. Presently, more than 120 human papillomaviruses have been identified by complete DNA sequence analysis. They are classified by family, genus, species and types according to several criteria. More precisely, types are determined on the basis of sequence homology to the gene encoding the L1 protein, which is the most conserved gene in the HPV genome (Aubin et al., 2007; de Villiers et al., 2004; de Villiers & Gunst, 2009). The genotypes are also more commonly used to refer the different types. However, in clinical practice, distinctions between HPV types include the type of epithelium infected (cutaneous *vs.* mucosal HPV) and the ability to effect cellular transformation. The capacity to transform epithelial cells is divided into high risk and low risk HPV: a benign proliferation is associated with the low-risk (lr) HPV type, and malignancy is associated with the high-risk (hr) HPV type (Nebesio et al., 2001; Syrjänen et al., 2011).

The human papillomavirus belongs to the highly diverse *Papillomaviridae* family. The HPV virion has a diameter of 55 nm and consists of circular double-stranded DNA containing approximately 8000 base pairs (bp). The HPV genome is encapsulated in a proteic capsid of 72 capsomers. Notably, the lack of envelope makes this virus resistant to environmental conditions, infectious for years and resistant to many therapeutics agents. The HPV genome consists of three major regions. The non-coding long control region (LCR) of 1000 bp contains the p97 promoter controlling E6 and E7 transcription, transcriptional regulatory elements and the binding sites for the E2 and E1 gene products (Neufcoeur et al., 2009; Ragin et al., 2007). The 3000bp region encodes two structural capsid proteins, namely, the late proteins L1 and L2. The icosahedral capsid can be constituted of L1 proteins alone or together with L2. The L1 capsid is comprised of 360 L1 molecules assembled as 72 pentameric capsomers, and the L1-L2 capsid contains 12 additional L2 molecules (Ishii et al., 2005). The six early proteins are encoded by a 4000bp region: two of the early proteins, E1 and E2, are regulatory proteins that modulate the replication and transcription of viral DNA and the expression of the other early genes; the early protein E4 acts in association with keratin filaments in host epithelial cells; the remaining three early proteins, E5, E6, and E7, are oncogenes involved in cellular transformation and maintenance of the malignant phenotype (Chung & Gillison, 2009; Doorbar & Myers, 1996).

2.1 Life cycle of the human papillomaviruses and molecular mechanisms of head and neck HPV carcinogenesis

The HPV life cycle is particularly complex. HPV infection requires abrasion in the stratified epithelium, providing access to the basal layer. Attachment of the virus to the host cell may be achieved through cell surface receptors or glycosaminoglycans, such as heparin sulfate. After this attachment, virions can be internalized via clathrin-dependent endocytosis and, after uncoating, the viral DNA is transported into the nucleus by the cytoskeleton. During this early infection, the virus maintains its genome as a nuclear episome at a low copy number (10-200 copies per cell) in the basal cell of the epithelium. This slight proliferation is limited in the basal cell layers, due to the expression of E1 and E2 proteins, which maintain the viral DNA as an episome (Chung & Gillison, 2009; Doorbar, 2005; Monsonégo, 2007). E1 is an ATP-dependent helicase initiating the viral replication in cooperation with E2 (Hughes & Romanos, 1993).

Moreover, E2 can act as a transcriptional repressor of E6 and E7 expression by binding to the non-coding region LCR, and it has a crucial role in the segregation of the viral genome during cell division (P syrri & Dimaio, 2008; You et al., 2004). This initial infection is followed by a proliferative phase corresponding to an increased number of viral episomes. Indeed, normal epithelial cells differentiate from the basement membrane toward the apical surface. During this proliferative phase, the HPV genome may remain episomal or become integrated into the host genome. Next, the HPV DNA replicates to a high copy number and is encapsidated to produce virions only in terminally differentiated epithelial cells. Integration of the HPV genome into the host chromosome is thought to be a late event and to occur at random with a predilection for fragile chromosomal sites. This integration also leads to the loss of the E1 and E2 genomic sequences, releasing the HPV oncogenes from repression (Ragin et al., 2007). Overexpression of both E6 and E7 stimulate cell cycle progression with S-phase entry, leading to proliferation of squamous epithelial cells of the upper aerodigestive tract. These two oncogenes alter key tumor suppressor pathways. The third oncogene, E5, exerts its carcinogenic effects only during the early stages of infection because its gene sequence is deleted when HPV integrates the host genome (zur Hausen & de Villiers, 1994). However, this protein stimulates cell growth through binding to the epidermal growth factor receptor (EGFR), initiating cascades leading to upregulation of proto-oncogenes. The association of E7 with the retinoblastoma protein (pRb) is now well characterized. The pRb protein is a negative regulator of the cell cycle that prevents S-phase entry under normal conditions by associating with the E2F transcription factor. The association between pRb and E2F is broken upon HPV infection: E7 binds to pRb, leading to its degradation and the subsequent release of E2F, which stimulates cell proliferation. Note that the inactivation of pRb results in a reciprocal overexpression of the p16 protein, which is an inhibitor of cyclin-dependent kinases. Indeed, the Rb gene also regulates p16 by a negative feedback mechanism; consequently, the inactivation of pRb leads to p16 upregulation. The expression of this protein is elsewhere considered as a surrogate marker for HPV infection in both cervical and head and neck cancer (Klozar et al., 2010; Li et al., 1994). The E6 protein of hr HPVs binds simultaneously to a cellular ubiquitin ligase, known as the E6-associated protein (E6-AP), and to the tumor suppressor protein p53, resulting in its ubiquitination and subsequent proteolytic degradation. Normally, p53 regulates growth arrest and apoptosis after DNA damage and, depending on the damage incurred; p53 induces a prolonged cell cycle arrest or triggers apoptosis. Moreover, HPV infected cells avoid this process of cell death by E6-mediated inactivation of p53. This oncogene interferes with other pro-apoptotic proteins of both extrinsic and intrinsic apoptotic pathways, such as Bak, FADD and pro-caspase 8 (Garnett et al., 2006; Narisawa-saito & Kiyono, 2007; Thomas & Bank, 1999). Thus, these two oncoproteins are essential factors for HPV-induced cellular immortalization, transformation and carcinogenesis. Finally, expression of the late proteins L1 and L2 occurs in the upper layer, as cells differentiate and allow the encapsidation of the genome and the production of new infectious virions, which are released into the extracellular environment to re-initiate infection.

2.2 Epidemiology and incidence of HPV infection in head and neck region

In recent years, the relation between the presence of HPV DNA and the development of head and neck tumors from different anatomical sites was analyzed. Differences in prevalence were found from one site to another. For example, the meta-analysis directed by Kreimer considered more than 5000 tumors from 60 studies conducted on five continents; the authors showed that

oropharyngeal tumors had the highest HPV prevalence (35.6%). Oral and laryngeal (including hypopharyngeal) carcinomas were infected in 23.5% and 24% of cases, respectively (Kreimer et al., 2005). Note that HPV16 accounted for 86.7% of all HPV-positive oropharyngeal tumors, compared with 68.2% in oral and 69.2% in laryngeal squamous cell carcinomas. Recently, Laco and colleagues also demonstrated this higher proportion in their study: 24 oral SCCs and 22 oropharyngeal SCCs (OPSCCs) were analyzed for HPV presence using the polymerase chain reaction (PCR). The results indicated that 82% of OPSCCs were HPV-positive, compared with 13% of OSCCs (Laco et al., 2011). The biological explanation for this higher HPV prevalence in tumors arising in oropharynx is becoming clearer. Both the tonsils and the base of tongue are lymphoid tissues that produce cytokines, which may affect HPV transcription and promote cell transformation (Klussmann et al., 2001). Furthermore, the tonsil epithelium presents morphological similarities to those of genital epithelia, such as deep invaginations of the tonsil surface that may facilitate viral particle retention. These invaginations, also called crypts, are flanked by stratified squamous epithelium, which facilitate viral access to basal cells. Additionally, both genital and tonsillar epithelia derive from the same endodermal embryonic layer (Ernoux et al., 2009).

As previously mentioned, reported rates of HPV positivity in HNSCCs vary widely. This inconsistency will be discussed with respect to anatomical site in a later chapter. However, this widespread variability must be interpreted with caution, but may be partially explained notably by differences in methodology of HPV detection. Indeed, according to several studies, multiple HPV detection methods are used, such as the polymerase chain reaction (PCR), *in situ* hybridization (ISH) and Southern hybridization. Among these techniques, numerous studies agree that PCR is the most sensitive. In fact, a review of the literature by Miller and White showed that HPV was identified with a higher frequency by using PCR (37.1%) than by using moderate- or low-sensitivity assays, such as Southern hybridization (27.2%) or ISH and immunohistochemistry (25.2%) (Miller & White, 1996). However, despite an increase in the use of PCR to detect HPV, variability in prevalence still exists and may be attributed to differences in the sensitivity of the PCR primer sets. Different consensus primer sets are used to detect and amplify HPV DNA, but the two most frequently used are the GP5+/GP6+ and the MY09/11 primers. Moreover, it seems that GP5+/GP6+ primers are more sensitive than MY09/11 for HPV detection in oral samples. Remmerbach also recommends the PCR approach with nested GP5+/GP6+ primers (Remmerbach et al., 2004). Other explanations for the varying rates of prevalence could be the sample sources and collection methods (scalpel biopsy, swabs, brushings, and mouthwash). The geographical locations of the studies may also contribute to variations in HPV prevalence. Indeed, HPV prevalence in OSCCs is similar in Europe (16%) and North America (16.1%) but significantly greater in Asia (33%). For OPSCCs, the prevalence is significantly higher in North America (47%) compared with Europe (28.2%) (Kreimer et al., 2005). Finally, patient profiles, such as smokers *vs.* non-smokers and/or drinkers *vs.* non-drinkers, could also contribute to some variations. It turns out that the literature presents conflicting accounts of the association between smoking and/or drinking and HPV in the development of HNSCCs. Indeed, we can distinguish three distinct categories: studies showing that HPV is clearly associated with an increased risk of HNSCC in non-smokers, studies finding no difference in HPV-related carcinoma between smokers and non-smokers and studies providing evidence of an additive or synergistic effect between smoking and HPV-related HNSCC (Sinha et al., 2011). Fouret observed a higher prevalence of HPV in non-smokers, while an additive interaction

was observed by Smith. HPV-positive smokers presented a greater risk of HNSCC compared with HPV-negative smokers or HPV-positive non-smokers (Fouret et al., 1997; Smith et al., 2004a). On the other hand, Paz found no statistical association between tumor HPV status and tobacco use (Paz et al., 1997). Biologically, smoking and alcohol can cause cellular and structural modifications in oral epithelia, which potentially increase the permeability to viral infection. These environmental agents are also known to suppress mediators of immune functions, facilitating HPV infection persistence (Pannone et al., 2011; Ragin et al., 2007; Sinha et al., 2011).

2.3 Prognosis of HPV positive head and neck squamous cell carcinoma

The significance of hr HPV infection and its impact on patient prognosis remains an important matter of debate, although a majority of studies have now confirmed an improved survival of HPV-positive patients compared with HPV-negative patients (Fakhry et al., 2008; Lindel et al., 2001; Lindquist et al., 2007). However, this strong positive prognostic factor is often confirmed in tonsillar and oropharyngeal carcinomas. Notably, the majority of studies that demonstrated increased survival were reporting on patients with oropharyngeal and/or tonsillar tumors (Ang et al., 2010; Lindel et al., 2001; Sedaghat et al., 2009). The meta-analysis by Ragin et al. examining the relationship between HPV and overall survival did not show any survival differences between HPV-positive and HPV-negative patients with cancer in non-oropharyngeal sites (Ragin et al., 2007). The same observation was made by Gillison et al., suggesting that these tumors may have an etiology distinct from that of tumors in non-oropharyngeal sites (Gillison et al., 2000). In fact, this subset of oropharyngeal HPV-positive cancers possesses distinct clinical features and outcomes, and it is particularly common in individuals who lack the traditional risk factors of tobacco and alcohol abuse. While it is unclear whether tobacco is a risk factor for HPV-induced oropharyngeal tumors, it seems that smoking has a negative impact on the survival of patients with HPV-positive tumors (Hafkamp et al., 2008). Nevertheless, there are reports in the literature on the prognostic significance of HPV infection describing a reduced influence on prognosis and other reports demonstrating no influence on prognosis. Indeed, two Swedish studies demonstrated that oral HPV infection was associated with a dramatically increased risk of OSCC development (Hansson et al., 2005; Rosenquist et al., 2007). Additionally, in 1994, Clayman et al. also showed that HPV detection significantly correlated with decreased survival (Clayman et al., 1994). On the other hand, other studies have failed to demonstrate an association between HPV positivity and prognosis (Duray et al., 2011a; Ernoux et al., 2011; Koskinen et al., 2003; Morshed et al., 2010). From a biological point of view, it is difficult to explain why patients with HPV infections have a worse survival than HPV-negative patients. One possible explanation is that HPV infected cells in locations with inflammatory activity may be stimulated to divide, facilitating tumor development (Dahlgren et al., 2004). Another hypothesis is that immunosuppression may favor HPV infection (Duray et al., 2010). In 2004, Kreimer reported that tonsillar HPV infection was strongly associated with HIV co-infection and immunosuppression (Kreimer et al., 2004). Recently, herpes simplex virus-2 (HSV2) infection was demonstrated to increase the risk of HPV infection (Moscicki et al., 2001). Furthermore, a study performed by Tung et al. reported the presence of HPV-16 or -18 and Epstein-Barr virus (EBV) in 80% of nasopharyngeal carcinoma samples (Tung et al., 1999). These co-infections might play an important role in the initiation of neoplastic transformation in human oral epithelial cells. HPV infections have also been implicated in several tumor cell immune escape mechanisms,

such as the absence of an inflammatory response against tumor cells, the production of regulatory cytokines and the downregulation of Toll-like receptor 9 (Lepique et al., 2009).

3. HPV related head and neck carcinomas *versus* HPV non-related head and neck carcinomas: two different tumor entities

Head and neck tumors are now defined as two separate clinical entities: HPV-positive tumors and HPV-negative tumors. The tumors differ both clinically and molecularly. HPV-positive tumors present distinct histopathological features, including notably non-keratinizing basal cells and a prominent “koilocytic” morphology. These features were also associated with a basaloid morphology that is a morphologic variant of HNSCC (Williams et al., 1996). These HPV-positive tumors are also known to occur in a younger age group, to originate more frequently in the oropharynx (especially in the palatine tonsils and at the base of tongue), to be poorly differentiated because patients present with later-stage disease and to have a lower T-stage than HPV-negative tumors (Marur & Forastière, 2008). Another particularity concerns the overall survival, which seems to be better for HPV-infected patients. Indeed, the majority of studies agree with that of Gillison and colleagues, who found that the risk of dying from disease was reduced in patients with HPV-positive HNSCC (Gillison et al., 2000). HPV-positive and HPV-negative tumors also exhibit differences in tumor biology with HPV-positive tumors having fewer p53 mutations and displaying reduced association with tobacco and alcohol consumption. In fact, approximately one-third of the tumors harbor p53 mutations, but a marked difference in p53 mutation frequency is generally found when comparing HPV-positive and HPV-negative oropharyngeal tumors. Thus, this inverse association between p53 mutations and HPV detection in the oropharynx further suggests that HPV-positive and HPV-negative HNSCCs should be considered to be two distinct cancers with two parallel pathways: one driven by environmental agents (tobacco and alcohol) and another driven by infectious agents (high-risk HPVs). However, these two pathologic agents may interact and act synergistically to lead to the development of HNSCCs. All these observations frequently focus on the oropharynx, strengthening the etiologic role of HPV in oropharyngeal carcinomas. Nevertheless, the implication of HPV in non-oropharyngeal tumors is less firmly established (Gillison et al., 2000). Indeed, among HNSCC biopsies, the real HPV prevalence remains uncertain, due to the varying incidence rates reported in different studies.

4. Incidence of HPV in the general population and modalities of transmission

HPV infection of the oral cavity has not been studied extensively. In fact, the majority of studies on the oral and oropharyngeal cavities considered patients with benign or malignant lesions and did not include healthy patients. However, to establish the etiology and pathogenesis of HPV-associated lesions, it is important to investigate the prevalence of HPV in normal tissues. An overview of the literature describing HPV detection in normal head and neck mucosa in children and adults is shown in Table 1.

4.1 Incidence of HPV in normal oral mucosa

The prevalence of HPV DNA in normal oral mucosa ranges from 0% to 56.7% in healthy adults (Table 1). To date, several studies have also evaluated the presence of HPV infection in the healthy oral cavity of children. In fact, it is important to know the prevalence of HPV

infections in childhood because HPV infection early in life could represent a risk factor for the development of head and neck cancer later in life. A prevalence of HPV infection in the oral cavities of children aged 0.3-11.6 years ranging from 0% to 47% has been reported (Syrjänen, 2010). The highest HPV prevalence rates by age group are detected before 1 year of age; the second peak occurs in adolescents aged 13-20 years (Smith et al., 2004b, 2007, 2010; Summersgill et al., 2001). According to the age studied, there are variations in the prevalence rate. In nasopharyngeal aspirates collected immediately after birth, the detection rate of HPV varies from 1.5% to 37% (Cason et al., 1995; Castellsague et al., 2009; Mazzatenta et al., 1996; Puranen et al., 1996, 1997; Rintala et al., 2005a, 2005b; Rombaldi et al., 2008; Sedlacek et al., 1989; Tenti et al., 1997, 1999; Watts et al., 1998). At the age of 1-4 days, Smith et al. in two studies found a low HPV incidence (from 0.9% to 1%) in the buccal swabs of neonates, whereas other studies showed a higher prevalence varying from 40% to 56% (Cason et al., 1995; Kaye et al., 1994; Pakarian et al., 1994; Tseng et al., 1998; Smith et al., 1995, 2004b). Similarly, the detection rate of HPV in infants between 6 weeks and 6 months after delivery varied between 0% and 62% (Cason et al., 2005; Fredericks et al., 1993; Kaye et al., 1994; Pakarian et al., 1994; Watts et al., 1998) and among 3-year-old children varied between 10% and 40% (Kojima et al., 2003; Puranen et al., 1996, 1997; Szydlowski et al., 2004). Mant et al. studied the acquisition and the clearance of HPV in the buccal mucosa of 4- to 9-year-old children and showed that, during a 30-month follow-up, 63% of 19 initially HPV-negative children acquired new HPV16 infection, while 40% of 22 initially HPV-positive children cleared the virus (Mant et al., 2003). In contrast, the Finnish Family HPV study found lower rates, which may be due to the fact that the children were younger and the detection method less sensitive. In fact, they found that, during the three-year follow-up, 42% of the children acquired incident infection, while 11% cleared their infection and 10% had persistent oral HPV infection (Rintala et al., 2005a, 2005b).

4.2 Incidence of HPV in normal tonsil

Regarding the literature, only a few studies have assessed the presence of HPV DNA in normal tonsillar tissues, with HPV detection rates varying from 0% to 24.4% in children/adolescents and 0% to 100% in adults (Table 1). In order to understand the epidemiology of HPV in the healthy population, we detected HPV in the palatine tonsils of children and adults who underwent tonsillectomy (recurrent tonsillitis, n=64) or sleep surgery (apnea: n=9; snoring: n=7). Among our series of 80 disease-free tonsils, 12.5% (10 cases) tested positive for hr HPV types [HPV16 (8 cases), HPV18 (1 case) and HPV31 (1 case)], 15% (12 cases) were positive for lr HPV types and 72.5% (58 cases) were negative. Among the hr HPV-positive tonsils, five were from children/adolescents and five were from adults (Duray et al., 2011b). By the end of 2002, Syrjänen compiled several studies from the United States, Japan, and Western Europe. In total, he determined an 8.5% (17 of 200) HPV positivity rate, either type 16 (12 cases) or type 6/11 (5 cases) (Syrjänen, 2004). A Greek study determined the presence of HPV DNA in children. They found 9 of 106 tonsils to be HPV-positive, with six cases having HPV-16, two cases having HPV-11 and one case having an untyped HPV (Mammas et al., 2006). Another study reported HPV-16 infection in 13 of 206 tonsils (6.3%) with 11 cases from children or young adults aged less than 25 years (Chen et al., 2005). These findings differed from those of several other studies in which low

prevalence or no prevalence of oncogenic and non-oncogenic HPV was identified in the specimens studied (Brandsma & Abramson, 1989; Ernster et al., 2009; Klingenberg et al., 2010; Klusmann et al., 2001; Niedobitek et al., 1990; Ribeiro et al., 2006; Sisk et al., 2006; Snijders et al., 1992). In these anatomical sites, HPV-6 and -11 and HPV-16 and -18 were the most common types of lr and hr HPV, respectively (Table 1). According to the literature, prevalence rates of oral HPV in normal individuals vary substantially. It is believed that this great variation in HPV prevalence rates found in head and neck studies may be due to several factors, including the anatomical site, ethnic and geographical differences, the size of the cohorts, the sample collection methods (i.e., biopsy, lavages, scrapes), the materials used for testing (i.e., formalin-fixed biopsies, frozen or fresh biopsies, exfoliated fresh cells), and, probably most importantly, the HPV detection methods used (PCR, in situ hybridization, Southern blot hybridization). For example, using PCR and DNA hybridization techniques, the results showed a prevalence ranging from 0% to 81% (Castro et al., 2009; Ribeiro et al., 2006) in oral mucosa swabs of adults, whereas in biopsies, the rate was less variable with detection of HPV in 0% to 55% (Table 1). The disadvantages of oral rinsing and cytological scraping or brushing are that they collect superficial epithelial cells and that no additional tests were performed for validation (Klingenberg et al., 2010). Moreover, no viruses from latent infections in the basal or suprabasal layer cells are removed (Esquenazi et al., 2010).

4.3 Modalities of transmission of HPV

4.3.1 Sexual mode of transmission

It is now well established that, in the case of cervical cancer, HPV infection is a sexually transmitted disease, but little is known about transmission of oral HPV infection in the general population. In the literature, the majority of the studies evaluated the prevalence of HPV and the risk of sexual transmission in HNSCCs, but few studies tried to determine the frequency and the modalities of sexual and nonsexual HPV transmission in other groups, such as normal children and adult. In fact, Gillison and colleagues conducted a case-control study that compared 100 patients with oropharyngeal SCCs and 200 control patients, and they demonstrated that oral HPV infection was strongly associated with oropharyngeal carcinoma among patients who did not have the classical risk factors of tobacco and alcohol use. Moreover, these authors also demonstrated that a high lifetime number of oral sex or vaginal sex partners, engagement in casual sex, an early age at first intercourse, and the infrequent use of condoms were all associated with HPV-16-positive oropharyngeal cancer. These findings suggest that oral HPV infection is sexually acquired and is involved in the carcinogenesis of oropharyngeal cancer (D'Souza et al., 2007). More recently, they explored whether these sexual behaviors were associated with oral HPV infection in two distinct populations (a control patient population and a population of college-aged men). The first population (control group), which was enrolled in two case-control studies nested within a prospective cohort with HNSCC, consisted of patients at the Johns Hopkins outpatient otolaryngology clinic who were ≥ 18 years of age and had no history of cancer. The second population (college-aged men population) included male students who were > 17 years (women were excluded because some might have received the HPV quadrivalent vaccine). Oral HPV infection was detected in 4.8% of 332 control patients

and in 2.9% of 210 college-aged men. Among the control group, the odds of developing oral HPV infection were significantly greater with increases in the lifetime number of oral or vaginal sex partners, whereas among the college-aged men, the odds of developing oral HPV infection were significantly greater with increases in the lifetime number of oral sex or open-mouth kissing partners, but not with increases in the lifetime number of vaginal sex partners. They concluded that oral HPV infection is sexually acquired and is transmitted by behaviors such as oral sex and open-mouth kissing (D'Souza et al., 2009). However, Smith et al. examined the prevalence of HPV in a large series of pregnant women to evaluate the concordance between infection of the cervix and the oral cavity. The lack of concordance in HPV types in either of the mucosal sites in pregnant women, between detection in the cervix and oral contact, and between females and males, suggests that the transmission of infection by auto-inoculation or by oral-genital sex between partners is low, suggesting that a number of issues remain unclear about the mechanisms of HPV transmission (Smith et al., 2004c). Another study also showed that despite a high frequency of oral-penile contact among young adults, the detection of oral HPV was rare, and no association between oral-penile contact and oral HPV infection was found (Winer et al. 2003).

4.3.2 Nonsexual mode of transmission

In children, the modalities of HPV transmission are difficult to explain. Gutman and colleagues described anogenital HPV disease in children after abusive sexual contact (Gutman et al., 1993). However, the high incidence of HPV infection observed in healthy children indicates that the transmission need not be sexual. To explain these pediatric HPV infections, several nonsexual modes of transmission can be proposed, including vertical transmission, horizontal transmission and autoinoculation. It can be due to a vertical transmission, which is divided into three subtypes depending on the assumed time of HPV transmission: (1) peri-conceptual transmission (time around fertilization) occurs theoretically via the infected oocyte or spermatozoon. Several studies showed the presence of HPV DNA in 8 to 64% of semen samples from asymptomatic men and also in seminal plasma and spermatozoa (Syrjänen, 2010). (2) Prenatal transmission (during pregnancy) has been proposed by studies reporting HPV DNA in amniotic fluid, placenta and cord blood samples. In placental samples, the rate of HPV DNA detection varied from 0% to 42.5% (Syrjänen, 2010). Rombaldi et al. observed an HPV infection in 23.3% of the cases studied and transplacental transmission in 12.2%. A significant correlation was also observed between placental HPV and the immunosuppressive status of the mother (Rombaldi et al., 2008). Furthermore, Sarkola and colleagues found that HPV DNA was three times more prevalent among women who had smoked compared with never-smokers (Sarkola et al., 2008a). In amniotic fluid and cord blood, the prevalence of HPV varied from 15% to 65% and 0% to 13.5%, respectively. (3) Perinatal transmission occurs during birth and immediately thereafter. HPV transmission may be the result of close contacts between the fetus and infected cervical and vaginal cells of the mother during delivery. Using DNA sequencing, several authors have shown that the mother is the source of infection with evidence of virus transcription in some children (Cason et al., 1995; Kaye et al., 1996). Vertical transmission was considered when the maternal HPV

type matches the HPV type isolated from the newborn/child. In 1989, Sedlacek et al. were the first to demonstrate HPV DNA in the nasopharyngeal secretions of infants delivered vaginally by mothers with genital HPV infection (Sedlacek et al., 1989). Since then, several authors evaluated the rate at which HPV is transmitted from mother to newborn/child, but this rate is extremely variable among studies. Medeiros and colleagues proposed the first systematic review on vertical HPV transmission, which included 2111 pregnant women and their 2113 newborns. They showed that pooled mother-to-child HPV transmission was 6.5% and was higher after vaginal delivery than after cesarean section. The authors also showed that the combined relative risk of mother-to-child HPV transmission was 7.3 (Medeiros et al., 2005). Rombaldi et al. determined the rate of maternal HPV transmission using PCR and nested multiple PCR on maternal cervical swabs and neonatal nasopharyngeal specimens. They reported that the perinatal transmission of HPV DNA occurred in 24.5% of the cases studied (Rombaldi et al., 2009). Other studies also suggest that vertical transmission is common, occurring in 40% to 80% of cases (Puranen et al., 1996; Rintala et al., 2005b; Tseng et al., 1998). These high rates of vertical HPV transmission were not confirmed by several studies, which found that the risk of vertical transmission to the oral or genital mucosa of newborns was rare (1-5%) (Smith et al., 1995, 2004b, 2010; Syrjänen & Puranen, 2000; Tenti et al., 1999; Watts et al., 1998). In two previous studies by Smith et al., only one mother/newborn pair was concordant for an HPV type, and among 203 infants, two had detectable HPV in oral or genital swabs (Smith et al., 1995, 2004b). Studies on persistent HPV infection showed that the concordance between mother/newborn infections was maintained between 37% to 83% at six weeks to six months after birth (Cason et al., 1995; Fredericks et al., 1993; Kaye et al., 1996), whereas Rintala et al. found that the prevalence declined to 10% in infants at 24 months of follow-up. This prospective cohort study assessed the dynamics of HPV transmission between parents and infants. They showed that the most common HPV profile was hr HPV in all family members, followed by HPV-positive mother-infant pairs, whereas HPV-positive father-infant pairs were less frequent. No such independent risk could be attributed to subclinical HPV infection in the father, but oral and genital HPV in the mother affected the risk of infant HPV (Rintala et al., 2005b). Thus, our results support the possibility of vertical transmission during pregnancy or perinatal transmission at the time of delivery. In other studies, the non-concordance of type-specific HPV between mother and newborn or the presence of oral HPV DNA in young children who were born to HPV-negative mothers suggest the existence of other transmission routes, such as the horizontal transmission of HPV. In these cases, HPV infection can be transmitted by milk during breastfeeding, by siblings via kissing, and by householders and friends via digital contacts (Syrjänen, 2010). There is one recent article showing the presence of HPV in 4% of 223 breast milk samples 3 days postpartum, regardless of the mother's oral or cervical HPV status (Sarkola et al., 2008b). Transmission via infected surfaces or other fomites, such as clothes, toys or eating utensils, is also possible. Autoinoculation can occur by scratching from one site of the body to another or by bathing (Myhre et al., 2003; Syrjänen & Puranen, 2000). HPV is known to multiply locally at the site of entry on the skin or mucous membranes; by deduction (logically) there is no viremia and no blood spread, but one study showed the presence of HPV in peripheral blood mononuclear cells (PBMCs) from HIV-infected pediatric patients and from healthy blood donors (Bodaghi et al., 2005).

Reference (year) (country)	Age range	Collected material (type of lesion)	Collection method	Technique(s)	Sample size	HPV positivity n (%)	Frequency LR (%) (type LR*)	Frequency HR (%) (type HR*)	Undetermined Type
Ernster et al. (2009) (USA)	Adults (≥21 years)	Tonsils (chronic tonsillitis, obstructive adenotonsillar hypertrophy, obstructive sleep apnea)	Tonsillectomy	PCR (type- specific HPV-16, -18)	226	0 (0%)	0 (0%)	0 (0%)	/
Mammas et al. (2006) (Greece)	Children (age ranged from 2 to 14 years)	Tonsils and adenoids (tonsillar and/or adenoid hyperplasia)	Tonsillectomy	PCR (GP5+/GP6+), HPV typing	106	9 (8.5%)	2/9 (22.2%) (11)	6/9 (66.7%) (16, 18, 33)	1/9 (11.1%)
Sisk et al. (2006) (USA)	Children (age range from 3 to 12 years)	Tonsils (hypertrophy or chronic tonsillitis)	Tonsillectomy	PCR (MY09/11), HPV typing	50	1 (2%)	1/50 (2%) (11)	0 (0%) (n.a.)	/
Chen et al. (2005) (Finland)	Young adults/adults (age ranged from 17 to 72 years) and children (age ranged from 1.5 to 16 years)	Tonsils (tonsillitis or tonsillar hypertrophy)	Tonsillectomy	PCR (MY09/11 and GP5+/GP6+)	206	13 (6.3%) (6 cases<17 years, 7 cases≥17 years)	n.a.	13/13 (100%) (16)	/
	Young adults/adults (age ranged from 18 to 74 years) and children (age ranged from 2 to 15 years)	Tonsillar exfoliated cells	Scrapes	PCR (MY09/11 and GP5+/GP6+)	174	1 (0.6%) (46 years)	n.a.	1/1 (100%) (58)	/
Strome et al. (2002) (USA)	Children (±5years)	Tonsils (tonsillar hyperplasia)	Biopsy	SB	48	3 (6.25%)	n.a.	3/3 (100%) (16)	/
Fukushima et al. (1994) (Japan)	Adults and children (age ranged from 1 to 82 years)	Tonsils (chronic tonsillitis)	Biopsy	PCR	38	5 (13.2%) (4, 19, 22, 24 and 41 years)	n.a.	5/5 (100%) (16, 18)	/
Smith et al. (1993) (USA)	n.a.	Tonsils (normal posterior tonsillar pillar)	Biopsy	PCR, SB	3	1 (33.3%)	1/1 (100%) (6, 11)	0 (0%)	/

Reference (year) (country)	Age range	Collected material (type of lesion)	Collection method	Technique(s)	Sample size	HPV positivity n (%)	Frequency LR (%) (type LR*)	Frequency HR (%) (type HR*)	Undetermined Type
Watanabe et al. (1993) (Japan)	Adults and children (age ranged from 4 to 46 years)	Tonsils (chronic tonsillitis)	Biopsy	PCR, SB	28	4 (14.3%)	n.a.	4/4 (100%) (16, 18)	/
Ribeiro et al. (2006) (Brazil)	Children (age ranged from 2 to 13 years)	Tonsils	Tonsillectomy	PCR (MY09/11)	100	0 (0%)	0 (0%)	0 (0%)	/
Tominaga et al. (1996) (Japan)	Adult (21 years)	Tonsillar condyloma acuminatum	Tonsillectomy	PCR	1	1 (100%)	1/1 (100%) (6/11)	0 (0%)	/
		Normal tonsillar mucosa	Tonsillectomy	PCR	3	3 (100%)	3/3 (100%) (6/11)	0 (0%)	/
Klussmann et al. (2001) (Germany)	Adults (age ranged from 20 to 65 years)	Tonsils (chronic tonsillitis)	Tonsillectomy	PCR	14	0 (0%)	0 (0%)	0 (0%)	/
Snijders et al. (1992) (Amsterdam)	n.a.	Tonsils (tonsillitis)	Biopsy	PCR	7	0 (0%)	0 (0%)	0 (0%)	/
Niedobitek et al. (1990) (The Netherlands)	Adults (age ranged from 47 to 80 years)	Tonsils (chronic inflammator disease)	Tonsillectomy	ISH	30	0 (0%)	0 (0%)	0 (0%)	/
Brandsma and Abramson (1989) (USA)	Adults (>35 years)	Tonsils (tonsillitis)	Tonsillectomy	SB	20	0 (0%)	0 (0%)	0 (0%)	/
Klingenberg et al. (2010) (Germany)	Adults and children (age ranged from 12 to 70 years)	Tonsils (chronic tonsillitis or snoring problems)	Biopsy	PCR	195	2 (1%)	0 (0%)	2/2 (100%) (16/18)	/
Kim et al. (2007) (Korea)	n.a.	Tonsils (chronic follicular tonsillitis)	Tonsillectomy	Real-time PCR	69	8 (11.6%)	n.a. (6, 11, 84)	3/8 (37.5%) (16, 58)	/

Reference (year) (country)	Age range	Collected material (type of lesion)	Collection method	Technique(s)	Sample size	HPV positivity n (%)	Frequency LR (%) (type LR*)	Frequency HR (%) (type HR*)	Undetermined Type
Duray et al. (2011) (Belgium)	Adults (age ranged from 18 to 57 years) and children/adolescents (age ranged from 1 to 17 years)	Tonsils (recurrent tonsillitis or apnea)	Tonsillectomy	PCR (GP5+/ GP6+), real-time quantitative PCR	80	22 (27.5%) (11/35 adults, 11/45 children/adolescents)	12/22 (54.5%) (n.a.)	10/22 (45.5%) (16, 18, 31)	/
Giraldo et al. (2005) (Brazil)	Adults (women mean age 27.7±6.5 years)	Oral mucosa	Scrapes	PCR (MY09/11)	140	29 (20.7%)	n.a.	n.a.	/
Terai et al. (1999) (Japan)	Adults (age ranged from 22 to 48 years)	Oral mucosa	Scrapes	PCR, RFLP	30	17 (56.7%)	n.a.	n.a.	
Castro et al. (2009) (Brazil)	Women (age ranged from 14 to 51 years)	Oral mucosa	Scrapes	PCR (MY09/11)	30	0 (0%)	0 (0%)	0 (0%)	/
van Doornum et al. (1992) (The Netherlands)†	Adults	Buccal mucosa	Scrapes	PCR	176	0 (0%)	0 (0%)	0 (0%)	/
Badaracco et al. (1998) (Italy)†	Adults (women age ranged from 21 to 48 years)	Oral mucosa	Scrapes	PCR	29	11 (37.9%)	n.a.	n.a.	/
Cañadas et al. (2004) (Spain)	Women (sex workers)	Oral mucosa	Scrapes	PCR	188	15 (7.9%)	6/15 (40%) (6, 11)	4/15 (26.7%) (16, 18, 31, 33, 39)	5/15 (33.3%)
Rice et al. (2000) (United Kingdom)	Children (age ranged from 3 to 11 years)	Oral mucosa	Scrapes	PCR (MY09/11), HPV-16 nested PCR	267	157 (58.8%)	0 (0%)	157/157 (100%) (16)	/

Reference (year) (country)	Age range	Collected material (type of lesion)	Collection method	Technique(s)	Sample size	HPV positivity n (%)	Frequency LR (%) (type LR*)	Frequency HR (%) (type HR*)	Undetermined Type
Llamas- Martínez et al. (2008) (Spain)	Adults (mean age 42.8±16.7 years)	Oral mucosa	n.a.	PCR	30	7 (23.3%)	7/7 (100%) (6, 11)	0 (0%) /	/
Saini et al. (2010) (Malaysia)	Adults (age ranged from 30 to 60 years & above) and children (age ranged from 1 to 18 years)	Oral mucosa	Scrapes	Hc2 HR-HPV detection system	116 (70 women and 46 children)	5 (4.3%) (4 women, 5.7% ; 1 children, 2.2%)	0 (0%)	5/5 (100%) (n.a.)	/
Kellokoski et al. (1992a) (Finland)†	Adults	Oral mucosa	Scrapes	Dot blot hybridization	309	12 (3.8%)	n.a. (2, 6, 7, 11, 13)	n.a. (16)	/
Kellokoski et al. (1992b) (Finland)†	Adults	Oral mucosa	Biopsy	Southern blot hybridization, PCR	212 and 78	33 (15.6%) and 18 (23.1%)	n.a. (6, 11)	n.a. (16, 18)	/
Koch et al. (1997) (Denmark)	Children (age ranged from 0 to 17 years)	Oral mucosa	Scrapes	PCR	392	1 (0.25%)	0 (0%)	0 (0%) 1/1 (100%)	
Esquenazi et al. (2010) (Brazil)	Adults (age ranged from 20 to 31 years)	Oral mucosa	Scrapes	PCR (GP5+/GP6+, MY09/11)	100	0 (0%)	0 (0%)	0 (0%) /	
Maitland et al. (1987) (United Kingdom)	Adults	Buccal mucosa	Biopsy	Hybridization	12	5 (41.6%)	0 (0%)	5/5 (100%) (16)	/
Scully et al. (1987) (United Kingdom)†	Adults	Oral mucosa	Biopsy	Hybridization	12	4 (41%)	n.a.	n.a.	/

Reference (year) (country)	Age range	Collected material (type of lesion)	Collection method	Technique(s)	Sample size	HPV positivity n (%)	Frequency LR (%) (type LR*)	Frequency HR (%) (type HR*)	Undetermined Type
Jenison et al. (1990) (Seattle)†	Adults and children	Oral mucosa	Scrapes	PCR	35 adults and 21 children	14 (40%) (adults), 9 (43%) (children)	6/14 (43%), 5/9 (55.5%) (6)	8/14 (57%), 4/9 (45.5%) (16)	/
Yeudall & Campo (1991) (United Kingdom)	Adults	Oral mucosa	Biopsy	PCR	25	2 (8%)	0/2 (0%)	2/2 (100%) (16, 18)	/
Jalal et al. (1992) (England)†	Adults	Oral mucosa	Scrapes	PCR	48	25 (52%)	0 (0%)	25/25 (100%) (16)	/
Cruz et al. (1996) (The Netherlands)†	Adults	Normal gingiva	Biopsy	PCR	12	0 (0%)	0 (0%)	0 (0%)	/
Schwartz et al. (1998) (USA)	Adults (age ranged from 18 to 65 years)	Oral mucosa	Scrapes	PCR (MY09/11) and sequencing	435	40 (9.2%)	19/40 (47.5%) (6, 11)	18/40 (45%) (16, 18, 31/33/35)	3/40 (7.5)
Smith et al. (1998) (USA)	Adults	Oral mucosa	Lavage	PCR	205	10 (4.8%)	n.a.	n.a.	
Hansson et al. (2005) (Sweden)	Adults (age ranged from 33 to 89 years)	Oral cavity	Mouthwash	PCR (MY09/11 and GP5+ /6+) and DNA sequencing	320	14 (4.4%)	12/14 (85.7%) (13, 32, 54, 55, 62, 18, 33, 45, 87, 10, 25, 75, 58, 59, 67, 76, RTRX9)	2/14 (14.3%) (16, 32, 54, 55, 62, 18, 33, 45, 87, 10, 25, 75, 58, 59, 67, 76, RTRX9)	/
Sugiyama et al. (2003) (Japan)†	Adults	Oral mucosa	Biopsy	PCR	44	16 (36.4%)	0 (0%)	16/16 (100%) (16)	/
Kansky et al. (2003) (Slovenia)†	Adults	Oral mucosa	Biopsy	PCR	61	4 (6.6%)	1/4 (25%) (11)	3/4 (75%) (16, 31, 68)	/

Reference (year) (country)	Age range	Collected material (type of lesion)	Collection method	Technique(s)	Sample size	HPV positivity n (%)	Frequency LR (%) (type LR*)	Frequency HR (%) (type HR*)	Undetermined Type
Zhang et al. (2004) (China)†	Adults	Oral mucosa	Biopsy	PCR	40	22 (55%)	0 (0%)	22/22 (100%) (16/18)	/
Smith et al. (2007) (USA)	Children/adolescents (age ranged from 2 weeks to 20 years)	Oral cavity/oropharynx	Scrapes	PCR, dot blot hybridization	1235	23 (1.9%)	13/23 (56.5%) (n.a.)	10/23 (43.5%) (n.a.)	/
Summersgill et al. (2001) (USA)	Children (≤ 20 years)	Oral mucosa	Scrapes (for younger children) or lavage	PCR (MY09/11), dot blot hybridization, sequencing	268	16 (6%) (11<7years and 5 between 13 and 20 years)	3/16 (18.75%) (6)	9/16 (56.25%) (16)	4/16 (25%)
Kurose et al. (2004) (Japan)	Adults and children (age ranged from 0 to ≥ 60 years)	Oral mucosa	Scrapes	PCR (MY09/11) and sequencing	662	4 (0.6%) (24, 48, 71 and 76 years)	2/4 (50%) (12, 71)	2/4 (50%) (16, 53)	/
Giovannelli et al. (2002) (Italy)	Adults (age ranged from 20 to 76 years)	Oral mucosa	Scrapes	PCR (MY09/11 and GP5+/6+) and sequencing	90	5 (5.5%)	0 (0%)	5/5 (100%) (16, 18, 31, 33)	/
Cortezzi et al. (2004) (Brazil)	Adults (age ranged from 20 to 90 years)	Oral mucosa	Scrapes	PCR (GP5+/6+)	142	15 (10.6%)	1/15 (6.7%) (6/11)	14/15 (93.3%) (16, 51/45)	/
do Sacramento et al. (2006) (Brazil)	Adolescents/adults (age ranged from 16 to 52 years)	Oropharynx (tonsils, soft palate, base of the tongue, back wall of the pharynx)	Scrapes	PCR (MY09/11), dot blot hybridization	50	7 (14%)	2/7 (28.6%) (61)	5/7 (71.4%) (16, 18, 52)	/
Sedlacek et al. (1989) (USA)†	Neonates	Oral pharyngeal cavity	Aspirates	Southern blot hybridization	45	15 (33.3%)	n.a.	n.a.	/
Puranen et al. (1996) (Finland)†	Children (age ranged from 0.3 to 11.6 years)	Oral cavity	Scrapes	PCR (MY09/11)	98	31 (31.6%)	n.a.	n.a.	/

Reference (year) (country)	Age range	Collected material (type of lesion)	Collection method	Technique(s)	Sample size	HPV positivity n (%)
Smith et al. (2010) (USA)	Newborns	Oral cavity	Scrapes	PCR (MY09/11), DNA hybridization, HPV typing	333	3 (0.9%)
Kojima et al. (2003) (Japan)	Children (age ranged from 3 to 5 years)	Oral mucosa	Scrapes	PCR (consensus PCR L1C1/L1C2 and HPV-1003/1004), DNA sequencing	77	37 (48.1%)

LR, low risk HPV type; HR, high risk HPV type; n.a., data not available; PCR, polymerase chain reaction; SB, Scrapes, term used for scrapes, brushes, swabs and smears.
*Column shows analyzed HPV-types mentioned in study (HPV type in bold represents most frequently found)
**Data relate to # samples instead of subjects.
† Only abstract on free access

Table 1. Frequencies of HPV types present in normal head and neck mucosa (oral cavity and tonsils) in children and adults

5. Characteristics of infected benign and malignant head and neck lesions and prevalence site by site in head and neck region

5.1 The recurrent respiratory papillomatosis (RRP)

As briefly described previously, HNSCCs are characterized by varying rates of incidence and mortality around the world, such as higher rates in Southeast Asia and Eastern Europe (Kreimer et al., 2005). At present, it is known for certain that HPVs are the etiological agent of many benign and malignant tumors arising from epidermal tissues. Nearly thirty years ago, Gissmann and colleagues were the first team to detect DNA sequences from HPV types 6 and 11 in laryngeal papillomas (Gissmann et al., 1983). Laryngeal papillomatosis, also known as recurrent respiratory papillomatosis (RRP), is characterized by the recurrent growth of exophytic, wart-like lesions called papillomas, along the epithelium of the upper respiratory tract, such as the vocal cords, the arytenoids, the subglottis, the trachea and most commonly, the larynx (Lacey et al., 2006; Mammias et al., 2009). Although the RRP are benign, their recurrent nature and location in the airways require frequent surgical removal and can cause significant morbidity and occasional mortality secondary to airway obstruction. Smoking and low-risk or high-risk HPV infections have also been proposed to be cofactors in the conversion of laryngeal papillomas into carcinomas (Doyle et al., 1994). These lesions were first described in the late 1800s by Sir Morrell Mackenzie, who recognized papillomas as distinct lesions of the laryngo-pharynx in children. RRP are mostly caused by the low-risk HPV types 6 and 11, with a more aggressive disease course for the latter type. The disease is also categorized into juvenile onset (JORRP) and adult onset (AORRP) forms based on age at diagnosis. JORRP can be observed immediately during the postnatal period, but it is most commonly diagnosed between two and four years. In AORRP, the peak incidence ranges from 20 to 40 years of age, with dysphonia and hoarseness, and respiratory obstruction being the most common presenting symptoms in children and adults, respectively (Larson & Derkay, 2010). In cases of JORRP, lesions are suspected to originate from a perinatal infection of mothers with condylomatous lesions, which are an overwhelming risk factor. Thus, the virus is generally transmitted during gestation or during birth when the baby passes through the infected birth canal. In a Danish study, Silverberg and colleagues demonstrated that maternal condyloma during pregnancy increased the risk of JORRP in the child more than 200-fold (Silverberg et al., 2003). Moreover, 54% of childhood RRP patients were born to mothers with a history of vulvar condylomata at the time of delivery (Hallden & Majmudar, 1986). Among AORRP patients, the transmission mechanisms clearly vary. The infection probably results from sexual or non-sexual contact with an infected lesion. This evidence has been suggested by a case control study that showed AORRP patients were more likely to have more sexual partners and to have oral sex than controls (Kashima et al., 1992). Additionally, HPV is also able to form latent infections in healthy mucosa, suggesting that AORRP could be due to a reactivation of a latent HPV infection acquired during birth (Goon et al., 2007; Larson and Derkay, 2010). Thus, the relationship between HPV and laryngeal papillomatosis is well established. Indeed, it has been shown that 95% of solitary laryngeal papillomas in adults were positive for HPV (Lindeberg & Johansen, 1990). Moreover, Dickens et al. reported evidence that 59% of laryngeal papillomas showed the presence of the four most common subtypes, including the two low-risk dominant types 6 and 11 (Dickens et al., 1991). In general, the prevalence of RRP was estimated at between four to seven cases per million person-years, and the incidence is about 2 per 100,000 in adults and 4 per 100,000 in children

(Goon et al., 2007). A report in the United States estimated the number of new cases of childhood onset RRP was 1500 to 2500 each year (Derkay, 1995).

5.2 Implication of HPV in other benign lesions of the upper aerodigestive area

As in RRP, HPV is also involved in the development of different benign lesions occurring in the oral cavity, the pharynx, the larynx and the nasopharynx. Numerous studies have been conducted on benign tumors arising in the head and neck to evaluate the possible role of HPV in head and neck neoplasms. However, its implication in carcinogenesis is still controversial because of the different frequencies detected. Kashima et al. examined the diagnostic and prognostic relevance of HPV in 26 squamous papillomas and 29 inverted papillomas. They examined the presence of four HPV types using the PCR amplification technique. The proportion of tissue samples showing HPV infection was 15% and 24% for squamous papillomas and inverted papillomas, respectively, with HPV types 6 and 11 being the only two types detected in these lesions (Kashima et al., 1992). Four years later, HPV was detected with a prevalence of 81.8% in 22 cases of laryngeal squamous papillomas (LP) and 42.5% in 40 cases of nasal inverted papillomas (NIP). HPV types 6 and 11 were again implicated, with a slight bias for HPV 6 in LP and HPV 11 in NIP, suggesting that HPV may play a role in the development of both lesions, and that these viral types may exhibit relative differences in their tissue specificity (Shen et al., 1996). On the other hand, Hoffmann and colleagues had investigated whether HPV was implicated in sinunasal polyposis and found a positive signal in only 1 of the 39 investigated cases (2.6%) (Hoffmann et al., 2000). In oral and oropharyngeal areas, squamous cell papillomas are also benign tumors that occur mainly between 30 and 50 years of age but still represent about 8% of oral tumors in children (Castro & Filho, 2006). Many types of tumors can develop in the oropharynx and oral cavity, such as condiloma acuminata, the common wart and focal epithelial hyperplasia (FEH). Condiloma acuminata (CA) is often considered a sexually transmitted disease, but the trend is to consider that it may also be acquired by auto-inoculation or by maternal transmission (Castro & Filho, 2006; Syrjänen, 2003). HPV was detected in CA with a positivity rate varying between 75% to 85% for the two most frequent hr HPVs, HPV 6 and 11 (Chang et al., 1991; Syrjänen, 2003). Common warts, one of the most common skin lesions, are frequently located on the lips, hard palate, gums and tongue dorsum. HPV detection rates in oral warts have been shown to vary between 43% and 100% (Padayachee, 1994; Praetorius, 1997; Zeuss et al., 1991). Although the near 100% positivity of HPV 6 and 11 is well established for the majority of benign tumors, it has been shown that HPV 2 and HPV 57 were more prevalent in common oral warts (Padayachee, 1994). Finally, oral focal epithelial hyperplasia (FEH), also known as Heck's disease and characterized by multiple nodular elevations, is a third benign oral lesion that may be located in the oral mucosa, lower lips and tongue. Like for oral warts, HPV 6 and 11 are not the major types found in FEH. Indeed, HPV 13 and 32 have been identified in 75% to 100% of the cases (Praetorius, 1997). These two types were considered specific to focal epithelial hyperplasia, while HPV 32 was also found in other oral lesions (de Villiers, 1989). In 2002, Schwenger and colleagues showed that 100% of FEH cases tested were positive for HPV 13 and/or 32 (Schwenger et al., 2002). Moreover, in a recent Brazilian study, of sixteen benign tumors found among 86 examined oral lesions, 100% were positive for HPV (Lira et al., 2009). To

confirm the great prevalence of HPV in benign laryngeal lesions, Arndt et al. assessed the presence of HPV genomes 6, 11, 16, 18, 31, 33 and 35 in 17 juvenile laryngeal papillomas (JLP), 27 adult laryngeal papillomas (ALP), 15 oral papillomas (OP) and 11 laryngeal leukoplakias (LL). The results showed 100% positivity for HPV 6 and 11 in JLP and ALP, 87% in OP and 63% in LL, whereas hr HPV 16, 18 and 33 were found in 22% of ALP, 20% of OP and 36% of LL, suggesting that the role of HPV in malignant transformation is less clear than in benign tumors (Arndt et al., 1997). In 2005, a combination of PCR and nested PCR was applied to improve the detection level of infected samples. Among 27 biopsies from different head and neck regions, such as the larynx, nasal cavities and sinuses, pharynx and oral cavity, 16 showed a positive result in either PCR or nested PCR or both, suggesting that this PCR system is a reliable tool for the detection of HPV DNA in benign lesions of the upper aerodigestive tract (Fisher et al., 2005). Conversely, in a retrospective study, 36 head and neck papillomata were tested for HPV 6, 11, 16 and 18 using PCR, and the results were not consistent with a role for HPV infection in the etiology of head and neck papillomata in adult patients. In fact, only 20% of benign tumors were positive for an HPV type (Campos-Bañales et al., 1995). Finally, in 2011, we assessed the presence of HPV DNA in a series of 39 laryngeal benign lesions (LBLs) from 20 cases of vocal nodules, 13 cases of chronic laryngitis and 6 cases of papillomas. The analysis was performed by PCR using the GP5+/GP6+ primers that amplify a conserved sequence located within the L1 region of the HPV genome. Next, all DNA extracts were tested for the presence of 18 different HPV genotypes using TaqMan-based real-time quantitative PCR. Four out of 39 specimens had insufficient tissue quantities for DNA extraction after pathological evaluation and were, therefore, excluded from further analyses. Note that PCR was also performed using β -globin primers to demonstrate the presence of amplifiable DNA in the tissue extracts. All 35 LBLs gave positive signals for β -globin. Among these 35 cases, we identified 27 lesions (77%) that were positive for HPV 16. In the hr HPV-negative subgroup ($n=8$), two specimens tested positive for HPV using the GP5+/GP6+ consensus primers and were considered infected with lr HPV types (Fig. 1). Only six benign lesions were negative in both GP5+/GP6+ and type-specific HPV PCR analyses (17%). Among the 27 hr HPV-positive lesions, 12 were both positive for GP5+/GP6+ and type-specific HPV (hr HPV+ group), whereas 15 were negative for GP5+/GP6+ and positive for type-specific HPV, which corresponds to the integrated HPV-positive group (int. hr HPV+) (Fig. 1) (Duray et al., 2011a).

This discrepancy observed in varying rates of incidence is mainly attributed to a variation in the sensitivity of the methods employed and in the epidemiological factors related to the group of patients examined. Indeed, the different methods have been classified in three categories according to the detection threshold of viral DNA copy number in the cell: techniques having a low sensitivity, such as immunohistochemistry and in situ hybridization; techniques with moderate sensitivity, such as Southern blot, dot blot and reverse dot blot hybridizations; and techniques displaying high sensitivity, such as the polymerase chain reaction, which can detect the virus in less than one copy per cell (Castro & Filho, 2005). Nevertheless, each method is limited by its sensitivity, its specificity, its practice and its cost, among other limiting factors. In conclusion, it is important to assess the efficacy of the different HPV detection techniques in order to establish HPV etiology in oral lesions.

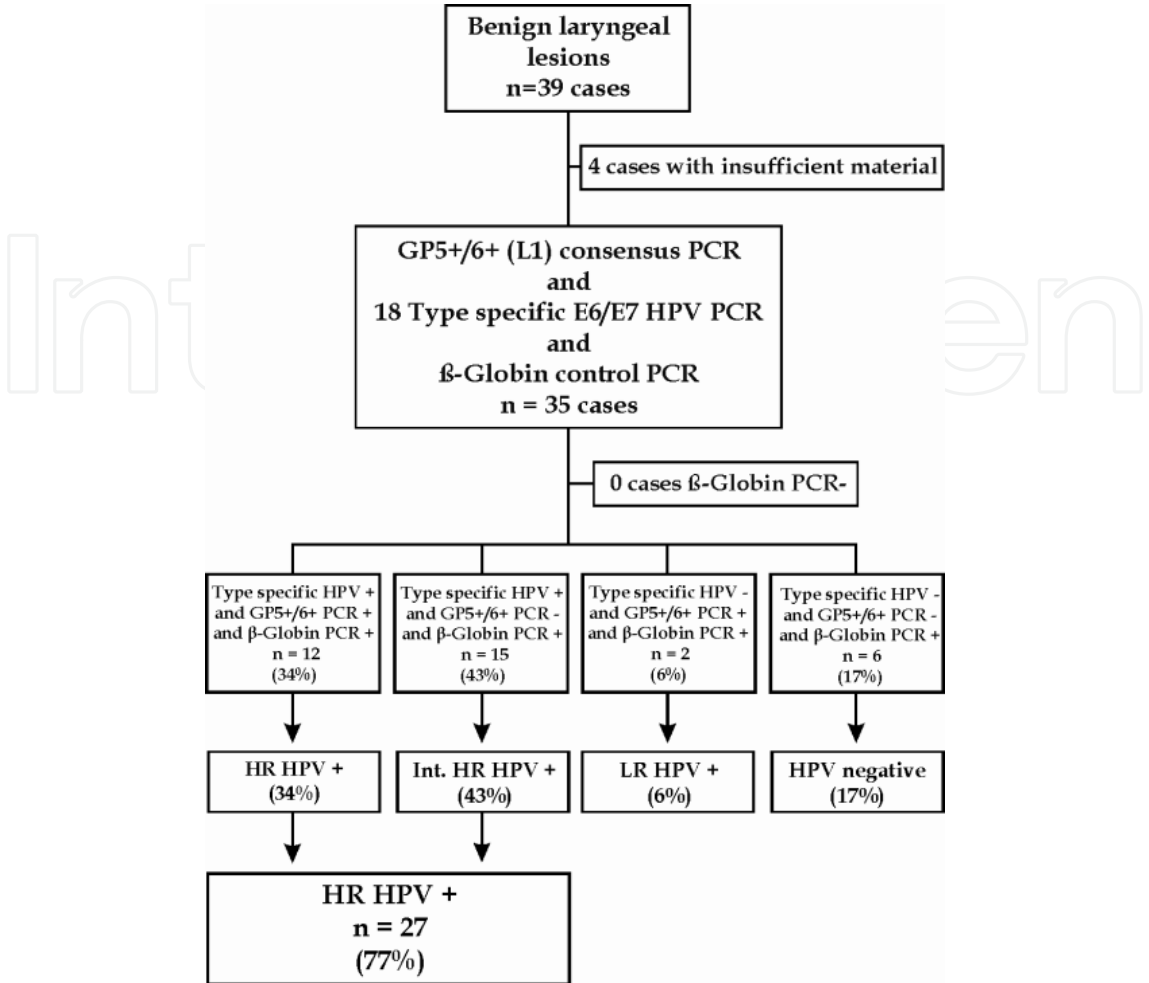


Fig. 1. HPV PCR results from 39 OSCC cases. Four samples could not be analyzed due to insufficient material, and β -globin could be amplified in all samples. Therefore, 35 cases in total were analyzed by type-specific real-time PCR and GP5+/GP6+ consensus PCR. Among these patients, 77% tested positive for infection with one or several types of hr HPV, 6% tested positive for lr HPV and 17% were HPV-negative.

5.3 Implication of HPV in malignant tumors of the upper aerodigestive area

5.3.1 Incidence in hypopharyngeal tumors

HNSCC represents the sixth most common malignancy with an annual incidence of more than 600,000 cases worldwide and is responsible for approximately 350,000 deaths each year (Parkin et al., 2005). These cancers mainly comprise the hypopharyngeal, laryngeal, oropharyngeal and oral cancers. Depending on the anatomical location of the primary tumor, HNSCCs show an HPV prevalence of between 20% and 30% for hypo-, laryngeal and oral carcinomas and up to over 50% for tonsillar squamous cell carcinomas, especially Waldeyer’s tonsillar ring (Deng et al., 2011). Furthermore, there is a persistent controversy on the role of HPV infection in HNSCC progression and on the influence of these infections on the final clinical outcome. Hypopharyngeal carcinoma is one of the less documented head and neck cancers in the literature. Indeed, few studies are exclusively devoted to hypopharyngeal cancers. Thus, the few cases available arise from certain studies that

sometimes include hypopharyngeal cases in their cohort. Based on the literature, we observed a prevalence ranging from 0% to 82% (Ernoux et al., 2011; Hafkamp et al., 2003; Ringström et al., 2002). In fact, some authors failed to show prevalence higher than 10% (Gillison et al., 2000; Hafkamp et al., 2003; Ribeiro et al., 2011; Ringström et al., 2002; Stremlau et al., 1987), whereas others found prevalence greater than 50% (Arndt et al., 1992; Ernoux et al., 2011; Kleist et al., 2000; Koskinen et al., 2003; Tyan et al., 1993). Recently, we examined the presence of HPV DNA in a series of 75 patients with stage IV hypopharyngeal SCC (Ernoux et al., 2011). The same methods used previously to detect the virus in our paraffin-embedded samples (PCR using GP5+/GP6+ primers and subsequent TaqMan-based real-time quantitative PCR targeting type-specific sequences of 18 HPV types) were employed in the study. Of the 75 specimens, 8 had insufficient tissue for DNA extraction or quantitative PCR and were, therefore, excluded from further analysis (Fig. 2). Of the remaining 67 cases, another 6 from which were β -globin PCR-negative were also excluded from further analysis. Ultimately, 61 β -globin PCR-positive specimens were typed by quantitative real-time PCR using primers for 18 different HPV types (Fig. 2).

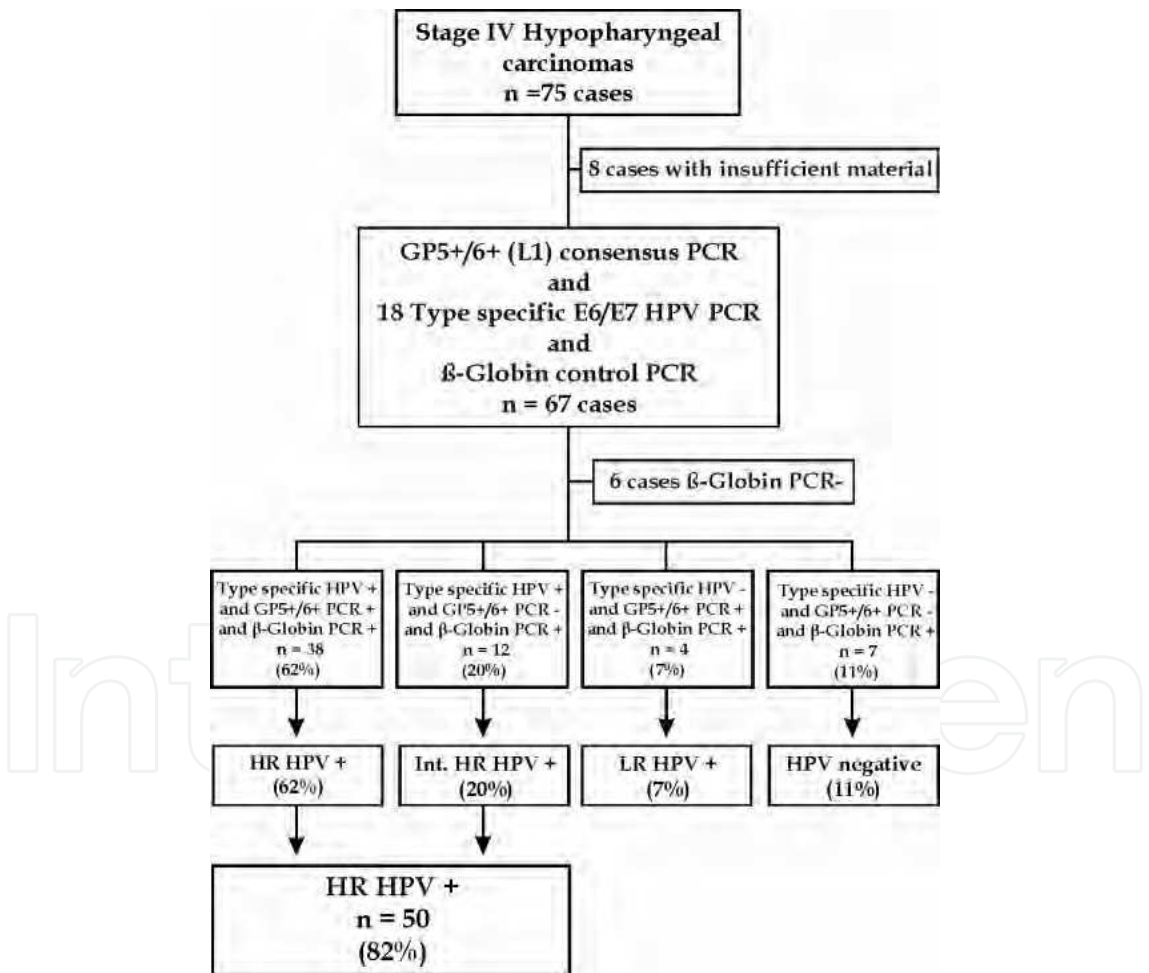


Fig. 2. HPV PCR results from 75 OSCC cases. Eight samples could not be analyzed due to insufficient material, and β -globin could not be amplified in six additional samples. Therefore, 61 cases in total were analyzed by type-specific real-time PCR and GP5+/GP6+ consensus PCR. Among these patients, 82% tested positive for infection with one or several types of hr HPV, 7% tested positive for lr HPV and 11% were HPV-negative.

From this homogeneous group of 61 HSCC tumor specimens, we identified 50 samples (82%) that tested positive for the following hr HPV types: HPV 16 (37 cases), 18 (4 cases), 33 (11 cases), 39 (1 case), 51 (5 cases), 53 (1 case), 58 (2 cases), 59 (1 case) and 66 (4 cases), four (7%) were positive for lr HPV types and seven (11%) were negative. Twelve samples were infected with multiple types of hr HPV. Among the 50 hr HPV-positive tumors, 38 were both GP5+/GP6+ positive and type-specific HPV-positive (hr HPV+ group). However, 12 tumors were GP5+/GP6+ negative and type-specific HPV-positive, corresponding to an integrated HPV+ group (int. hr HPV+) (Fig. 2).

This disagreement over HPV prevalence may be explained by the sensitivity of the methods used and the number of cases enrolled. Indeed, the use of different detection methods and HPV-specific probes, as well as varying numbers of tissue samples from different locations, has caused confusion over the frequency of HPV-positive lesions. Despite using the most sensitive method (PCR), we still observed a large variation in HPV detection rates, which can be explained by the relationship between results and sample sizes. In fact, the Kleist et al. study observed an 80% positivity among 5 samples, while Ribeiro et al. only detected HPV in 3.8% of cases among 78 tumors (Kleist et al., 2000; Ribeiro et al., 2011).

Concerning prognosis, statistical analysis did not reveal a significant correlation between hr HPV positivity and the proportion of disease-free patients. However, 32% (16/50 cases) of patients with hr HPV-positive tumors experienced relapse, compared with 8% of patients with HPV or lr HPV-positive tumors. The five-year disease-free survival was 88% in HPV negative and lr HPV-positive tumors *versus* 58% in hr HPV-positive tumors (Fig. 3).

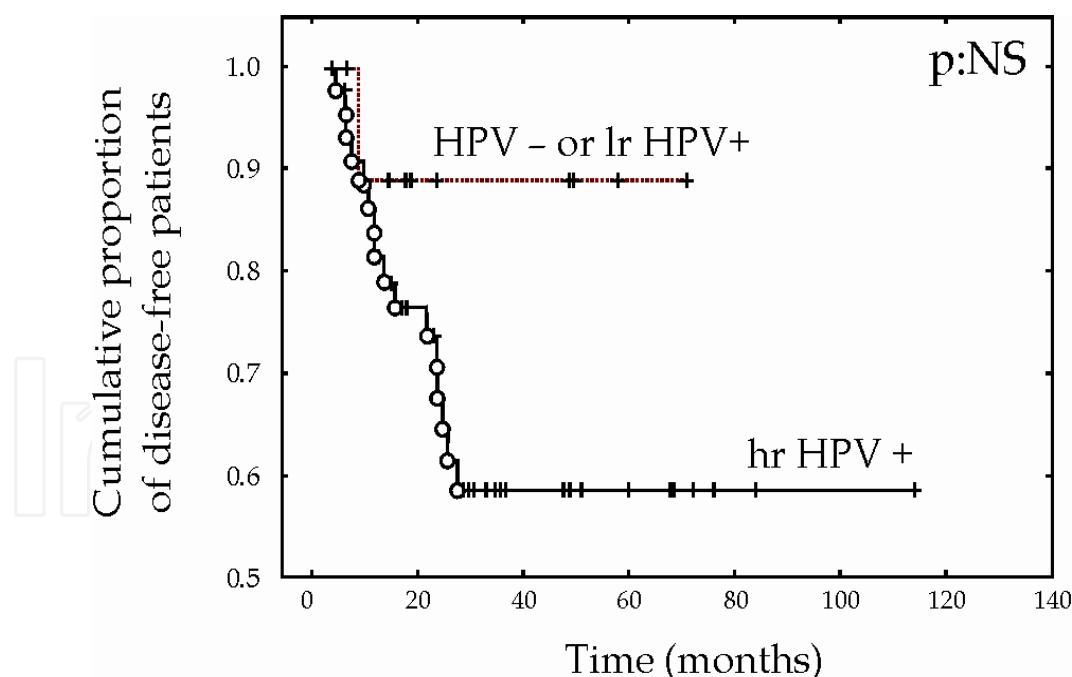


Fig. 3. Disease-free survival curves for high-risk HPV+ (hr HPV+) *versus* HPV negative and low-risk HPV+ (lr HPV+) patients. The *p*-value is not significant (NS)

As mentioned above, few publications have focused on HPV positivity in hypopharyngeal cancers. Evidently, our results are in accordance with a previous study by Morgan et al, who described for the first time that 75% of the 16 pharyngolaryngeal carcinomas in their series

were HPV-positive (Morgan et al., 1991). Another study found a lower HPV positivity rate (46%) in tumors from 78 previously untreated patients with laryngeal and hypopharyngeal carcinomas (Clayman et al., 1994). The authors concluded that HPV-positive tumors represented a biologically distinct subset of tumors that had a worse prognosis than HPV negative tumors (Clayman et al., 1994). In contrast to our results, Paz et al. did not identify any HPV-positive tumors in a small series of seven hypopharyngeal carcinoma patients (Paz et al., 1997). Indeed, conclusions are difficult to draw, given the lack of interest in the prognostic outcomes of these cancers, but it would seem that HPV-associated hypopharyngeal carcinomas are characterized by a poorer prognosis, or a tendency towards having a poorer prognosis, than HPV-negative hypopharyngeal carcinomas (Clayman et al., 1994; Ernoux et al., 2011). Thus, HPV infection may be closely associated with the development of some hypopharyngeal carcinomas.

5.3.2 Incidence in laryngeal tumors

Laryngeal squamous cell carcinoma (LSCC) is the most frequent malignant tumor in the upper aerodigestive tract and is found predominantly in males. Although the relationship of HPV with SCC in the larynx is not well established, oncogenic HPVs have been proposed to be potential pathogenic factors. Studies focusing on HPV infections in LSCCs have reported wide variations in infection frequency that range from 0% to 85% (Almadori et al., 1996; Boscolo-Rizzo et al., 2009; Gallo et al., 2009; García-Milián et al., 1998; Koskinen et al., 2007; Lindeberg & Krogdahl, 1999; Rees et al., 2004). The prevalence varied widely with individual investigations. More than ten years ago, Brandwein et al. and Lie et al. reported that only 8% of LSCCs in the USA and Norway contained HPV DNA (Brandwein et al., 1993; Lie et al., 1996). Other authors also showed prevalence lower than 10%. In 1999, Lindeberg and Krogdahl demonstrated HPV infection in only one of 30 laryngeal carcinomas (Lindeberg & Krogdahl, 1999). More recently, in a cohort of 69 LSCC patients, 3 (4.4%) had HPV-positive samples, whereas other investigators did not find any HPV-positive samples among 68 LSCCs (Gallo et al., 2009; Koskinen et al., 2007). These findings support the view that the role of HPV in LSCC is less important in the larynx and also suggest the existence of other factors that play a more important role than viral infection in the carcinogenesis of these lesions. However, when we examine the few studies considering more than 80 patients with PCR-based analytical techniques, we observe higher percentages than previously demonstrated. Reports that include small sample sizes are subject to a potential selection bias. Indeed, the prevalence detected by Morshed et al. rose to 35.5%, but they did not find any significantly improved overall or disease-specific survival compared to patients with HPV-negative tumors (Morshed et al., 2008). In the same manner, high-risk HPV was found in 41 out of 110 LSCCs (37.3%) in a Brazilian study (de Oliveira et al., 2006). Larger samples being better, Syrjänen analyzed 116 LSCCs using *in situ* hybridization to demonstrate the presence of HPV DNA from types 6, 11, 16 and 30 in paraffin-embedded biopsies. A total of 15 of 116 (12.9%) tumors were shown to contain HPV DNA of at least one type (Syrjänen et al., 1987). This low prevalence can be explained by the use of a technique with lower sensitivity than PCR, which has the greatest sensitivity. Additionally, our study focused on HPV detection in a sample of 67 laryngeal SCCs revealed a 75% prevalence of high-risk HPV, as shown in Figure 4 (Duray et al., 2011a). To prevent false positives, precautions were taken to prevent tissue contamination. Our results may be explained by the fact that we used a sensitive (10-100 copies per PCR reaction) and type-

specific real-time quantitative PCR analysis with a short amplification product (60-80 bp) that is more sensitive to the presence of degraded DNA, which is typically found in paraffin-embedded specimens.

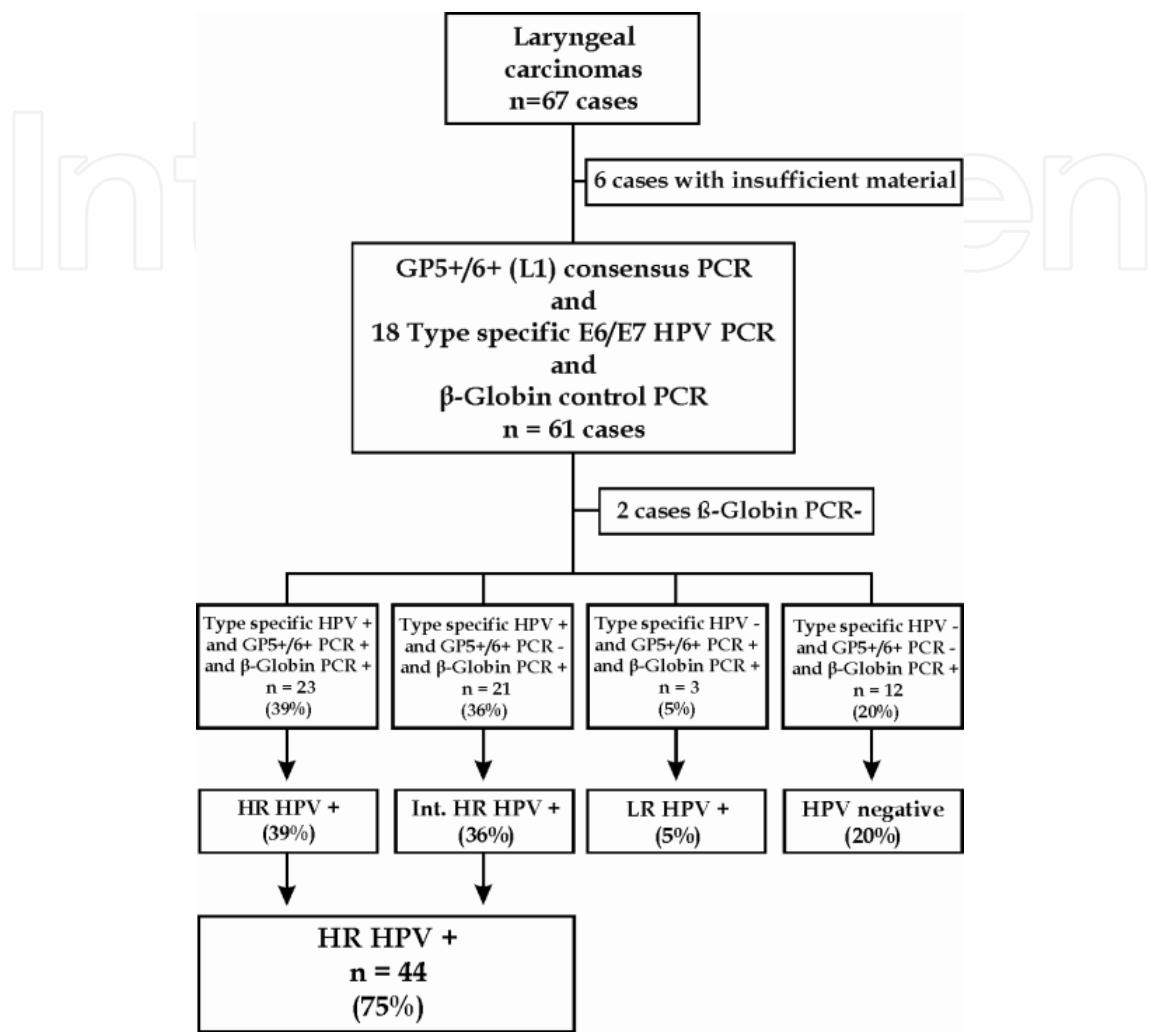


Fig. 4. HPV PCR results from 67 LSCC cases. Six samples could not be analyzed due to insufficient material, and β-globin could not be amplified in two additional samples. Therefore, 59 cases in total were analyzed by type-specific real-time PCR and GP5+/GP6+ consensus PCR. Among these patients, 75% tested positive for infection with one or several types of hr HPV, 5% tested positive for lr HPV and 20% were HPV-negative.

In this study, we also considered the prognostic value of the presence of hr HPV DNA in laryngeal carcinomas. We observed that positive hr HPV status did not correlate with the proportion of disease-free patients (Fig. 5). The five-year disease-free survival was 87% in HPV-negative or lr HPV-positive early-stage tumors *versus* 76% in hr HPV-positive early-stage tumors (Fig. 5A). The five-year disease-free survival was 60% in HPV-negative or lr HPV-positive late-stage tumors *versus* 58% in hr HPV-positive high-stage tumors (Fig. 5B). After grouping the early and late stages, the five-year disease-free survival was 77% in HPV-negative or lr HPV-positive laryngeal tumors *versus* 67% in hr HPV-positive laryngeal tumors (Fig. 5C). Similarly, Boscolo-Rizzo et al. found no significant differences in overall survival and disease-free survival between patients with HPV-positive tumors and patients

with HPV-negative tumors (Boscolo-Rizzo et al., 2008). Although there is strong support in the literature for the association between HPV-positive tumors and better prognosis, especially in oropharyngeal carcinomas, other studies did not find an improved prognosis for HPV-associated tumors (Clayman et al., 1994; Dahlstrand et al., 2008; Ernoux et al., 2011).

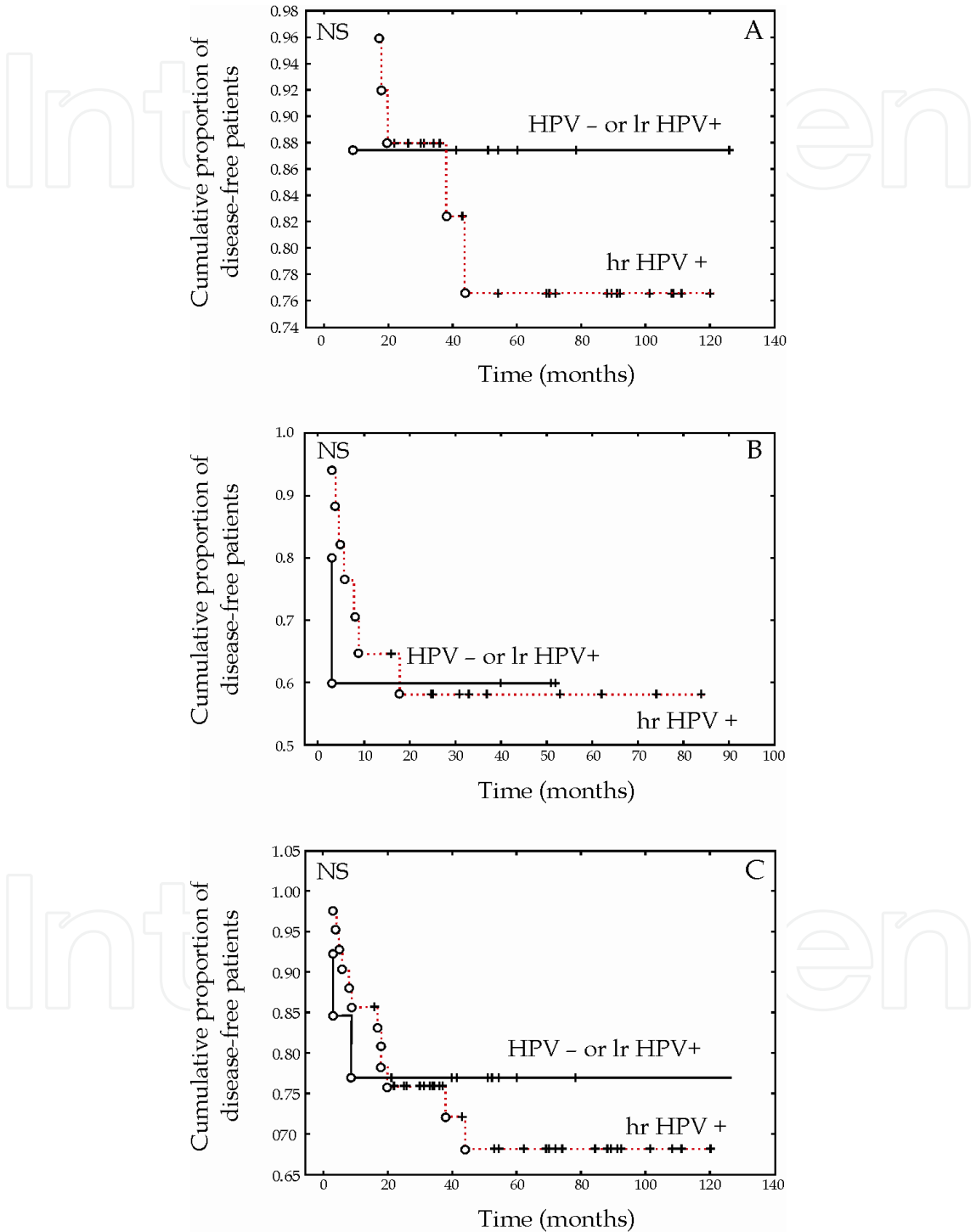


Fig. 5. Disease-free survival curves for high-risk HPV+ (hr HPV+) versus HPV- and low-risk HPV+ (lr HPV+) patients with low- (A) and high-stage (B) laryngeal carcinoma. (C) Disease-free survival curves for all stages together. The *p*-values were not significant (NS).

Although preliminary results may suggest biological oncogenic activity, the role of HPV infection in LSCCs has not been clearly established. Thus, in view of conflicting results, reports of the frequency of HPV infection in laryngeal carcinomas should be interpreted with caution, and despite low prevalence, there is no doubt that HPV is present in a subset of laryngeal carcinomas. Thus, we should not exclude the possibility of a causal relationship between HPV and some laryngeal tumors. Prospective studies with large numbers of patients and controls are required to confirm this hypothesis.

5.3.3 Incidence in oral tumors

Questions remain as to whether HPV is causally associated with cancer development at other sites in the upper aerodigestive tract. Its role continues to be a topic of debate, as a link with HNSCC was suggested more than 20 years ago (Syrjänen et al., 1983). Based on light microscopy examination, they observed koilocytosis, which is the presence of cytopathic HPV-induced alterations, in 35% of oral squamous cell carcinoma (OSCC) biopsies that were identical to those found in precancerous lesions and in uterine cervical carcinoma. Several meta-analyses have been dedicated to the relationship between HPV and OSCC (Kreimer et al., 2005; Miller & Johnstone, 2001; Syrjänen et al., 2011; Termine et al., 2008). The prevalence reported by these studies is quite different (23.5%, 33.7%, 38.1%, and 46.5%). This variability could be explained by different manner: Termine et al. included studies examining more than 40 specimens, and they calculated their prevalence exclusively on the basis of paraffin embedded (PE) specimens. On the other hand, Miller and Johnstone, similar to Kreimer et al., did not report HPV prevalence in PE and fresh frozen (FF) specimens separately. Miller and Johnstone were the first to publish a meta-analysis on HPV prevalence in normal and cancerous oral lesions. Pooled data from non-controlled studies published between 1982 and 1997 showed that HPV was 4.7 times more likely to be present in oral carcinomas when compared with normal mucosa (Miller & Johnstone, 2001). More recently, the interesting systematic review by Syrjänen et al. observed a pooled HPV detection rate of 33.7% in the OSCC group compared with 12% in the control group. The authors concluded that HPV infection significantly increases the risk for OSCC. It is important to note that the association of HPV with OSCC was significant only when HPV was detected in biopsy samples and that this significant association was completely lost when only exfoliated cells were used to analyze HPV in both cases and controls. Herrero et al. also showed that HPV DNA in exfoliated cells was not associated with HPV DNA detection in OSCC samples (Herrero et al., 2003). Thus, to obtain the most accurate results for the relationship between HPV and OSCC, future studies should only select biopsied tissues for HPV testing. In addition to the previously mentioned reviews, studies examining HPV infection in OSCC reported a wide range of detection rates from 0 to 61% (Herrero et al., 2003; Koskinen et al., 2003; Mishra et al., 2006; Ribeiro et al., 2011; Smith et al., 2004a). Varying sampling techniques together with widely divergent PCR methods across the studies explain most of this variability. Other criteria have also been considered: i) the specificity and size of PCR primers (e.g., GP5+/GP6+, MY09/11,...), ii) the geographical demographics, iii) the number of enrolled cases and iv) the prevalence of smoking and alcohol consumption in the studied population. A similar prevalence was detected by Zhao et al, who found 40.4% positivity (21 of 52 samples) with HPV 16 accounting for 63.5% and HPV 18 for 30.8%. Moreover, HPV had an independent prognostic effect on the overall survival of OSCC after adjusting for other

factors, such as histological grade, TNM stage and tobacco use. Another characteristic was the significant correlation with improved survival in OSCC patients (Zhao et al., 2009). In 2001, Schwartz et al. also demonstrated that HPV16 presence was independently related to a favorable prognosis in a population of 254 OSCC patients (Schwartz et al., 2001). Gillison's well-controlled study found that oral cancers containing oncogenic HPV types had 74% less risk of disease-specific mortality (Gillison et al., 2000). On the other hand, many studies have also demonstrated that the prevalence of high-risk HPV types was low in OSCCs. Indeed, recently, only 2% of the PE tissues analyzed tested positive in Lopes study (Lopes et al., 2011). Almost the same observation was made by several studies using qPCR techniques (Boy et al., 2006; Ha et al., 2002; Koskinen et al., 2003). Furthermore, a meta-analysis suggested that the association between HPV and cancer was strongest for the tonsils, intermediate for the oropharynx and weakest for the mouth and larynx (Hobbs et al., 2006). In contrast, a Hungarian study demonstrated that 31 of 65 (48%) oral cancer cases had evidence of HPV using qPCR methods, reflecting the impact of geographical variation (Szarka et al., 2009). In fact, geographical origin is a well-known variability factor regarding HPV prevalence, with Asia having the highest worldwide frequency and Africa having the lowest (Termine et al., 2008). A hypothesis was suggested that OSCC HPV prevalence could be biased and overestimated because of a non-precise assignment of the anatomical site resulting in a "contamination" of the OSCC cohort with oropharyngeal cancers (Lopes et al., 2011). Once again, the detection methods remain the argument of choice to compare the different results obtained. In fact, two teams recently proposed two methods for HPV detection: *in situ* PCR and *in situ* PCR ISH. These methods combine the sensitivity of solution PCR with the subcellular localization provided by traditional ISH (Koyama et al., 2007; Uobe et al., 2001). Nevertheless, there are currently insufficient data in the literature to support the adequacy of these techniques. Finally, in our study, the prevalence of HPV infection reached 70%, with 44% being hr HPV-positive and 26% being lr HPV-positive (Fig. 6) (Duray & Descamps et al., in revision). The high incidence of HPV in our samples may also be explained by the fact that a very sensitive PCR (GP5+/GP6+ primers: 10–100 copies per reaction) was combined with a type-specific real-time quantitative PCR analysis and a short amplification product (60–80 bp). To a similar end, Termine et al. demonstrated that PCR-based studies resulted in higher prevalence rates compared with studies using *in situ* hybridization (Termine et al., 2008). Our results confirmed this finding because almost 65% of HPV+ specimens were also positive using ISH, whereas the ISH/PCR correspondence was excellent for the negative specimens.

Moreover, high-risk HPV positivity was associated with shorter disease-free survival in our cohort of 147 OSCC patients. The five-year disease-free survival was 76% for patients with HPV-negative tumors versus 40% for patients with HPV-positive tumors ($p=0.007$) (Fig. 7A). Furthermore, the five-year disease-free survival was 48% for patients with lr HPV-positive tumors versus 37% for patients with hr HPV-positive tumors ($p=0.015$) (Fig. 7B). These data suggest that HPV infection was significantly associated with a worse prognosis. Moreover, Cox multivariate analyses combining the HPV status with clinical variables (TNM staging and node status) demonstrated that only HPV status had an independent impact on patient prognosis ($p=0.01$; hazard ratio=2.81). An analysis of viral loads in infected patients did not show any statistically significant relationship between TNM staging and risk of recurrence.

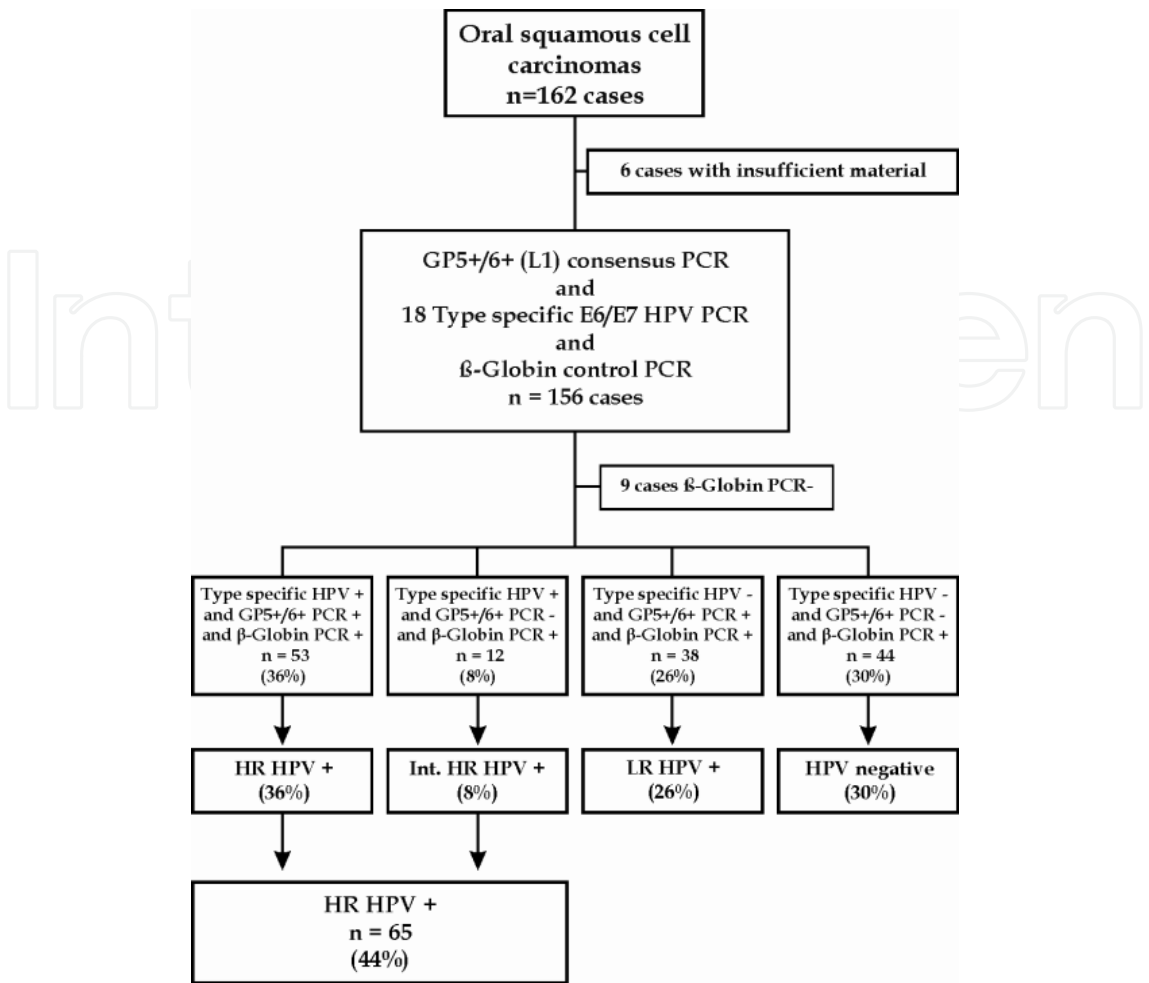


Fig. 6. HPV PCR results from 162 OSCC cases. Six samples could not be analyzed due to insufficient material, and β -globin could not be amplified in nine additional samples. Therefore, 147 cases in total were analyzed by type-specific real-time PCR and GP5+/GP6+ consensus PCR. Among these patients, 44% tested positive for infection with one or several types of hr HPV, 26% tested positive for lr HPV and 30% were HPV-negative.

Although a majority of studies demonstrated an improved outcome for OSCC patients, the meta-analysis by Ragin and Taioli examining the relationship between HPV and overall survival did not show any survival differences between HPV-positive and HPV-negative patients with cancers at non-oropharyngeal sites (Ragin & Taioli, 2007). The same observation was made by Gillison et al., suggesting that these tumors may have an etiology distinct from that of tumors at non-oropharyngeal sites (Gillison et al., 2008). The poor prognosis reported in the hr HPV-positive population in this study has been demonstrated in other studies. Indeed, two Swedish studies demonstrated that oral HPV infection was associated with a dramatically increased risk of developing OSCC (Hansson et al., 2005; Rosenquist et al., 2007). Additionally, in 1994, Clayman et al. also showed that HPV detection was significantly correlated with decreased survival (Clayman et al., 1994). Other studies have failed to demonstrate an association between HPV positivity and prognosis (Ernoux et al., 2011; Morshed, 2010). We hypothesize that immunosuppression may favor HPV infection (Duray et al., 2010). In 2004, Kreimer reported that tonsillar HPV infection was strongly associated with HIV co-infection and immunosuppression (Kreimer et al.,

2004). Recently, herpes simplex virus-2 (HSV2) infection was demonstrated to increase the risk of HPV infection (Moscicki et al., 2001). Furthermore, a study performed by Tung et al. reported the presence of HPV 16 or 18 and Epstein Barr virus (EBV) in 80% of nasopharyngeal carcinoma samples (Tung et al., 1999). These co-infections may play an important role in the initiation of neoplastic transformation in human oral epithelial cells. In conclusion, the effect of HPV on oral cancer remains contentious. Thus, to formally confirm the role of HPV as an etiological agent in OSCC, sample processing and PCR analysis protocols should be standardized to allow a more precise comparison of the results. Furthermore, future studies should report separately the type-specific prevalence rates. This information would be very useful in order to evaluate the long-term effects of the recent HPV vaccines.

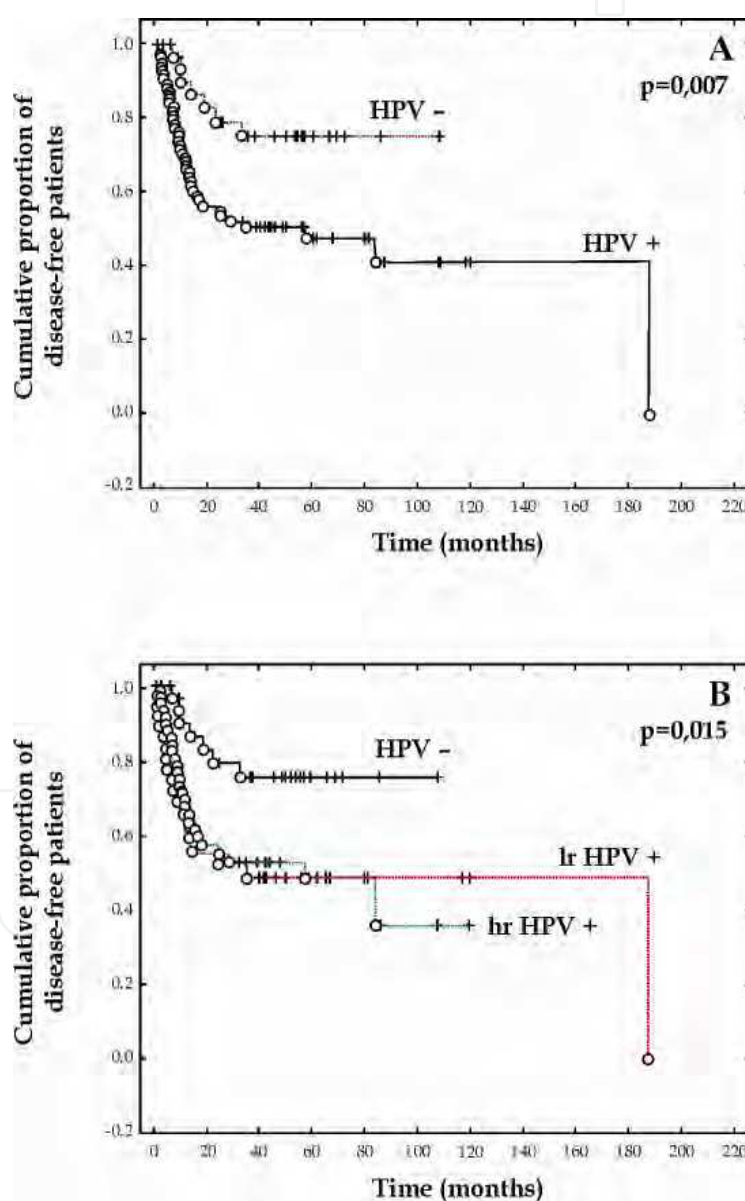


Fig. 7. The HPV+ subgroup (and specifically the hr HPV + subgroup) is associated with a worse prognosis ($p = 0.007$ and $p = 0.015$). Standard survival time analyses were performed using Kaplan-Meier curves, the Gehan-Wilcoxon test and the Log-rank test.

5.3.4 Incidence in oropharyngeal tumors

During the past several years, an increased incidence of oropharyngeal squamous cell carcinoma (OSCC), the head and neck cancer in which HPV is commonly found, was observed. In 2007, Sturgis and Cinciripini proposed a possible emerging epidemic of HPV-associated cancers (Sturgis & Cinciripini, 2007). Indeed, accumulating molecular and epidemiological data now show that hr HPV types are responsible for a subset of OSCCs (D'Souza et al., 2007; Lindquist et al., 2007). Therefore, the International Agency for Research on Cancer (IARC) recognized HPV as a risk factor for oropharyngeal cancer. In the United States, the prevalence of HPV in OSCC has evolved over the last 30 years. Based on data from Colorado, the percentage rose from 33% during the 1980s to 70% in the 1990s and 82% during 2000 to 2004 (Ernster et al., 2007). During the 2000s, different prevalence rates were reported, ranging from 63% to 92% among oropharynx, tongue and tonsil cases (Brown et al., 2011). Tonsillar cancer is the most common oropharyngeal cancer, followed by cancer of the base of the tongue, and these two cancers accounts for 90% of all OSCCs (Dahlstrand & Dalianis, 2005). In Stockholm, as in the USA, HPV prevalence among tonsil cases increased over the years from 23% in 1970 up to 83% in 2003 to 2007 (Nasman et al., 2009). In contrast, in Beijing, the prevalence of tonsillar cancers is particularly low, with rates of 0.1% in men and 0.0 in women. Interestingly, in places with a marked Western influence, such as Hong-Kong and Taiwan, rates of tonsillar cancer were 6 to 12 times higher than in Beijing (Marklund & Hammarstedt, 2011). Large variations in incidence rates are also observed. In Europe, the highest rates were seen in France, particularly in Somme region, where the rates were as high as 6.4% for men (Parkin et al., 2002). Similar to HNSCC, the prognosis for OSCC is generally low in the more advanced stages with an overall five-year survival rate of approximately 25% (Licitra et al., 2002). Nevertheless, in HPV infected OSCC, a major feature noted in almost all studies is that HPV is a favorable prognostic factor for clinical outcome independently of tumor stage, age, gender and grade of differentiation. In fact, patients with HPV DNA-positive tumors appear to have a significant prognostic advantage compared with patients having HPV-negative tumors (Ang et al., 2010). However, previous studies have suggested that the presence of HPV DNA in tumor tissue was not a sufficient factor to indicate an involvement of the viral genes in tonsillar carcinomas. Good indicators reflecting an active involvement of HPV are the levels of viral E6-E7 mRNA (Cuschieri et al., 2008). Thus, E6 and E7 expression are regularly assessed with success, suggesting an active involvement of HPV in the etiology of tumors (Lindquist et al., 2007). Recently, an interesting study provided strong evidence that HPV status was an independent prognostic factor for overall survival among patients with OSCC, which may confirm that HPV-positive and HPV-negative OSCC constitute two distinct clinical entities with different causes, risk factor profiles and survival outcomes. To validate this hypothesis, future clinical trials should be designed specifically for patients with HPV-positive or HPV-negative OSCC (Ang et al., 2010). Concerning this improved survival, Lindquist et al. observed a difference between HPV patients who smoked and did not smoke. In fact, patients with HPV-positive tonsillar cancer who had never smoked had a better prognosis than those who were smokers, which is in accordance with the studies of Ang and Rotnaglova (Ang et al., 2010; Lindquist et al., 2007; Rotnaglova et al., 2010). These observations may be explained by an immune response induced by HPV but abrogated by smoking. A different option, also suggested by Ang et al, is that smoking and HPV are associated with different categories of

tumors and that smoking induces additional genetic alterations in these tumors (Ramqvist & Dalianis, 2010, Ang et al., 2010). Some investigators have suggested that the better clinical outcome can be attributed either to higher radiosensitivity of HPV-positive tumors or to active antiviral cellular immune responses in infected patients (Dahlstrand & Dalianis, 2005). Treatment of patients with advanced disease often includes both oncological and surgical treatment, as both carry acute side effects, such as difficulties in swallowing or talking, dry mouth and jawbone necrosis. Oncological treatment has fortunately evolved towards the development of altered fractionation radiotherapy, integration of chemotherapy with radiotherapy and the introduction of targeted biological therapy. The combined modality treatment and the intensified fractionation have improved the outcome for head and neck cancer patients in general (Bourhis et al., 2006; Pignon et al., 2009). As a result of this intensified therapy, patients have substantial chronic side effects. It is therefore important to differentiate patients who do and do not need intensified treatment to increase patient survival times and quality of life. The improved response to oncological treatment for OSCC HPV-positive patients may also be explained by the presence of an intact p53-mediated apoptotic response in HPV-positive tumors and by immunological factors related to HPV infection (Spanos et al., 2009). In conclusion, HPV-positive OSCC is recognized as a distinct subset of head and neck squamous cell carcinomas having a favorable outcome. Patients with HPV-positive tonsillar carcinomas may also benefit from a less aggressive treatment, but this conclusion will need to be validated by further studies in order not to compromise existing, excellent treatment outcomes in patients with HPV-dependent tumors.

6. Impact of HPV on the immune system of head and neck cancers

6.1 The escape of HPV in the immune system

The contradiction between the studies examining the correlation between HPV infection and prognosis may result from differences in immune status among HNSCC patients. In fact, a persistent HPV infection that can lead to the development of cancer requires immune tolerance. Therefore, HPV has developed several mechanisms to avoid detection by the host immune defense system. In the case of infection by a virus, it is important to distinguish between the mechanisms used by tumor cells to evade immune attack and those used by HPV. The infectious cycle of HPV is itself an immune evasion mechanism because viral gene expression and viral protein synthesis are confined to keratinocytes, which are programmed to die; thus, HPV replication does not cause cell death and does not present a danger signal to the immune system (Stanley, 2006, 2009). Without cell lysis, there is little or no release of the proinflammatory cytokines important for the activation and migration of dendritic cells (Stanley, 2006, 2009). Even if there is no cell death, keratinocytes should be activated to induce type I interferon responses, which have anti-viral, anti-proliferative, anti-angiogenic and immune-stimulatory properties. Several data suggest that E6 and E7 oncogenes have evolved mechanisms to interact with components of the interferon pathway and to downregulate the effects of type I IFN (Stanley, 2009). For instance, the virus maintains a low level of viremia, there is no blood-borne phase and only minimal amounts of replicating virus are exposed to the immune system. As a result of these facts, the virus is practically invisible to the host (Kanodia et al., 2007; Stanley, 2009). HPV is able to dysregulate the

antigen processing machinery (APM) by downregulating peptide-MHC complexes, which are essential for recognition of infected cells by T cells. In particular, the E7 oncoprotein of HPV-16 and -18 repress the promoter for MHC class I heavy chain expression, and HPV-18 E7 is also able to repress the promoter that regulates expression of TAP1 (transporter associated with antigen protein 1) and LMP2 genes (Georgopoulos et al., 2000). HPV-16 E5 induces alkalinization of the Golgi complex, leading to disruption of trafficking, including transport of the MHC class I complex (Ashrafi et al., 2005). In HPV-positive benign laryngeal lesions, there is a decrease of MHC class I and TAP-1 expression, and the low expression of TAP-1 was associated with rapid recurrence of the disease (Bonagura et al., 1994; Vambutas et al., 2000). Another way in which HPV may suppress immune responses is via the modulation of chemokine (suppression of MCP-1 expression, downregulation of IL-8 expression) and pro-inflammatory cytokine (downregulation of IL-18 expression) expression and via skewing the cytokine profile in favor of a Th2 response (IL-4, -5, -6, -10, -13) instead of a Th1 cytokine expression (IL-2, IFN- γ) (Kanodia et al., 2007). Moreover, the E6 and E7 oncoproteins downregulate toll-like receptor 9 (TLR9), which induces proinflammatory genes essential for induction of immune responses (Hasan et al., 2007). The failure of the immune system to recognize HPV may also be explained by the fact that HPV16 E7 protein has widespread similarity to several human proteins, such as xeroderma pigmentosum group G complementing protein (XPGC) and the retinoblastoma binding protein 1 (RBP-1); thus, the immune system does not recognize them as foreign molecules but as self molecules (O'Donovan et al., 1993; Scherly et al., 1993).

6.2 Defects in the immune system of HNSCC patients

Patients suffering from head and neck cancers exhibit deficits in the humoral and cellular immune systems, which have been shown to be correlated with a worse prognosis. The strategies employed by head and neck cancers to escape the immune system are varied: they can directly inhibit the immune response by producing soluble mediators or they can target the APM via downregulation of HLA class I and/or other components of the APM (Duray et al., 2010). In the first steps of carcinogenesis, there is an increase of Langerhans cells, whereas in invasive carcinomas, a decrease was observed (Fig.8). The accumulation of macrophages in the peritumoral area seems to play a protumoral role by secreting VEGF and stimulating angiogenesis (Duray et al., 2010) (Fig.8). Antitumor responses of HNSCC patients are compromised in the presence of functional defects or apoptosis of T-cells, both circulating and tumor-infiltrating. Functional assays with tumor-infiltrating lymphocytes TILs isolated from the tumor bed have identified a number of defects, such as (i) absent or low expression of the CD3 zeta chain (CD3 ζ), which is the key signaling molecule in the T-cell receptor pathway (Whiteside, 2005), (ii) decreased proliferation in response to mitogens or IL-2 (Whiteside, 2005), (iii) the inability to kill tumor cell targets (Hathaway et al., 2005; Hoffmann et al., 2004), (iv) an imbalance in the cytokine profile, with a striking absence of IL-2 and/or IFN- γ production (Reichert et al., 1998a), and (v) evidence of pronounced apoptotic features in a considerable proportion of TILs (Whiteside, 2005; Young et al., 1996). Several studies demonstrated the involvement of the Fas/FasL signaling pathway, the mitochondrial pathway, TRAIL, and TNF- α in the apoptosis of T cells in HNSCC patients (Duray et al., 2010). Furthermore, changes in the expression of the ζ chain of TILs are

biologically significant because the absence or low expression of this chain in TILs in patients with stage III or IV HNSCC predicts a poor survival compared with patients expressing a normal ζ chain (Reichert et al., 1998b; Whiteside, 1999). Another study showed that patients with more aggressive tumors or with a recurrence within the preceding two years expressed the lowest levels of the ζ chain (Kuss et al., 1999). Various studies showed an increased abundance of T regulatory cells Tregs in TILs and peripheral blood, and their immunosuppressive action could be another mechanism employed by the tumor cells to escape antitumor immunity. Lau et al. demonstrated an increase of Tregs in patients with nasopharyngeal carcinoma, and their suppression of the proliferation of CD4-positive/CD25-negative T cells could explain the decreased antitumor immunity of T cells (Lau et al., 2007) (Fig.8).

6.3 Effects of HPV on the immune system of patients with benign or malignant lesions of the upper aerodigestive area

Considering the high HPV prevalence in the population, it remains unclear why a very small fraction of HPV-exposed individuals develop RRP. To better understand this result, Bonagura and colleagues studied the differences between RRP patients infected with HPV-6 or -11 and healthy individuals who were also infected with HPV but never developed RRP. They provided evidence that there are several immune alterations in patients with RRP, such as (i) an adaptative immune response induces a Th2-like/T-regulatory phenotype. In fact, patients with RRP displayed elevated levels of Th2-like chemokines (CCL17, CCL18, CCL22) and cytokines (IL-4, IL-10), whereas levels of TH1-like chemokines (CCL19, CCL21) and cytokines (IL-12, IL-18, IFN- γ) were downregulated. In papillomas, there is an enrichment of Tregs, which suppress Th1-like responses to HPV. (ii) Interestingly, the expression of IL-4 by CD4-positive T cells was increased in papillomas, whereas the expression of IFN- γ was reduced. An expression of IL-10 by CD4-positive T cells was also observed in the blood (PBMCs) of patients with RRP. These findings suggest that CD4-positive T cells express TH2-like cytokines and reduce Th1-like T-cell function. (iii) A decrease of CD4-positive and CD8-positive T cell V β repertoires. Moreover, they showed that HPV-11 E6 can suppress T-cell alloreactivity and that natural killer cells are dysfunctional in RRP. Furthermore, they also proposed an inhibitory cycle of immunocytes that support the development of RRP. In response to HPV proteins, memory Th2-like T cells express IL-4 and IL-10, and T-regulatory cells express IL-10 and TGF- β , inducing resting macrophages to become alternatively activated macrophages. These macrophages express TH2-like chemokines (CCL17, CCL18) and cytokine (IL-10) that induce naïve CD4-positive T cells to become Tregs and memory TH2-like T cells. Together, these cells form a cycle of inhibitory immunocytes that block the function of the effector helper type I CD4-positive T-cells (TH1-like). As a result, HPV infection is not cleared, and papillomas will recur (Bonagura et al., 2010). A correlation between the severity of laryngeal papillomas and an increase of CD83-positive dendritic cells exists, and this enhancement may be due to an impaired migration of matured DC (Kovalenko et al., 2009). These observations suggest that patients with RRP have a perturbation in their cellular immune response (or have a defect in their cellular immunity) and are, therefore, unable to eliminate their disease with an effective HPV-specific T-cell response. This immune imbalance may influence the development and severity of respiratory papillomatosis (Bonagura et al., 1999).

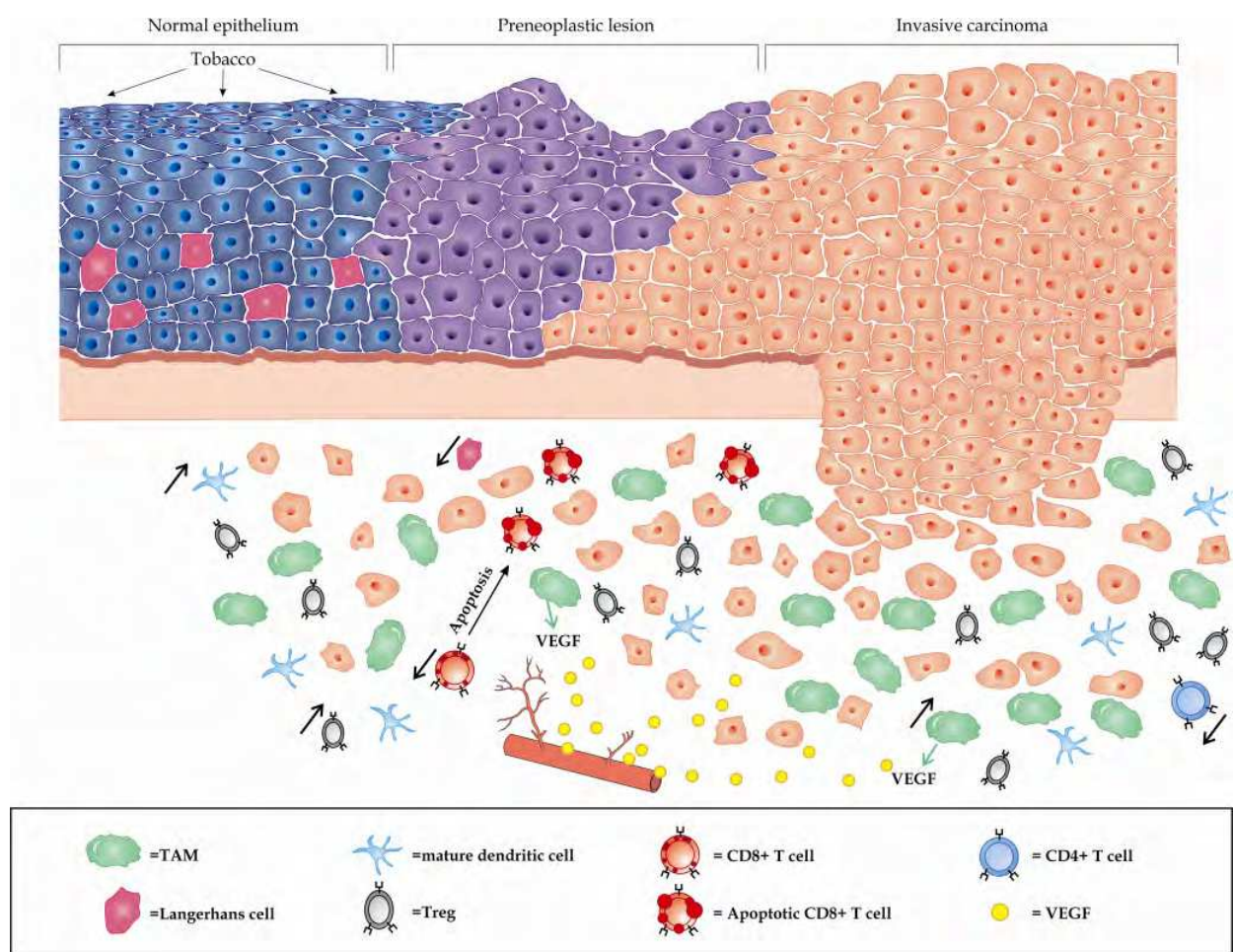


Fig. 8. Description of immunosuppressive mechanisms during the head and neck tumor progression: in the normal epithelia of the upper aerodigestive tracts, LCs are present in the suprabasal layers. When mucosae of these areas are exposed to tobacco, the number of LCs increases whereas these cells decrease in invasive carcinomas. The mature DCs are prominent in the peritumoral area and correlated positively with the expression of VEGF. DCs are also more abundant in patients with metastasis. A higher level of TAM is observed in HNSCCs and these cells constitute a source of VEGF which play a crucial role in angiogenesis. HNSCCs can induce the apoptosis of CD8+ T cells using the mitochondrial and/or Fas/FasL pathways. Tregs can induce apoptosis of CD8+ T cells and inhibition of the proliferation of CD4+ T cells.

There are few data on the interaction between the host immune system and HPV infection in HNSCCs, meaning that the role of innate and adaptative immunity in the development and progression of HPV-positive HNSCCs is largely unknown. As mentioned previously, in several studies, HPV positive HNSCC cancer was associated with a favorable outcome. From these results, some authors supported the hypothesis that the immune response may play a positive role in HPV-positive HNSCC prognosis, but in those cases, an intact immune system is necessary. An increased frequency of T cells specific for peptides derived from the oncogenic HPV E7 protein was observed in HNSCC patients positive for HPV16 compared with HNSCC patients negative for HPV or with healthy volunteers (Albers et al., 2005; Hoffmann et al., 2006). Therefore, antiviral immunity exists against E7 oncogenic protein,

but these T cells are unable to eliminate the tumor (Hoffmann et al., 2006), perhaps due to immune escape of tumor cells from cytotoxic T cells (CTL) recognition (Albers et al., 2005). In fact, using immunohistochemistry, a reduced expression of APM components and HLA class I antigens was observed in HPV16-positive HNSCCs compared with adjacent normal squamous epithelium, which is consistent with the suggestion of a phenomenon of immune escape during viral carcinogenesis (Albers et al., 2005). Thus, further studies are necessary to explain this type of tumor resistance. Williams et al. investigated whether HPV-specific immune mechanisms can result in tumor clearance. For that, they generated HPV-positive and HPV-negative tonsil cell lines by transducing primary mouse tonsil epithelial cells, which are able to form squamous cell cancers in mice. When they examined immune-competent and immune-incompetent mice with or without HPV, they observed a difference in growth and survival patterns. In fact, in the immune-competent mouse group, about one-third of the HPV-positive mice cleared their tumors, compared with none of the HPV-negative mice. Moreover, by comparing the survival of the mice that did not clear their tumors, they observed that mice injected with HPV-positive cells had a significantly better survival than mice injected with HPV-negative cells. In the mouse group lacking B- and T-cell immunity, there was no difference in the tumor growth pattern or survival between the HPV-positive and HPV-negative groups. Therefore, the difference in growth between HPV-positive and HPV-negative mice is immune mediated. The data indicated that CD4-positive and CD8-positive T cells were required to mount this immune response. They also showed that the immune clearance capacity could be transferred from a cleared mouse into an immunodeficient mouse. In fact, the splenocytes from cleared mice and HPV-positive tumor cells were injected into an immunodeficient mouse, and they observed that all treated mice developed and cleared tumors (Williams et al., 2009). In another animal model of HPV-associated cancer, the authors tried to better understand why HPV-positive cancer may represent an advantage in survival, as has been shown in several studies, and they compared how these cancers responded to therapies usually used for the treatment of HNSCC with responses of HPV-negative tumors. Thus, they looked at the effect of radiation and cisplatin co-therapy on HPV-positive and HPV-negative cancer cells *in vivo* and in immunocompetent and immunodeficient mouse models. *In vitro*, HPV-positive cells were more resistant to radiation and cisplatin therapy compared with HPV-negative cells, whereas *in vivo*, HPV-positive tumors were more sensitive to radiotherapy compared with HPV-negative tumors. Furthermore, cisplatin was able to clear HPV-positive tumors, but not HPV- tumors, in mice. In immunodeficient mice, neither radiation nor cisplatin was able to cure their tumors. They also showed that, after an adoptive transfer of wild-type immune cells into immunodeficient mice, the clearance of HPV-positive tumors was restored upon cisplatin therapy. These findings suggested that an intact immune system was essential for tumor clearance with radiation and cisplatin therapy. Moreover, the findings indicate that survival does not seem to be due to increased epithelial sensitivity to these therapies and that radiation and cisplatin induce an immune response to this antigenic cancer (Spanos et al., 2009). More recently, Wansom and collaborators tried to understand better the clinical importance of adaptive immunity in patients with HPV16-positive oropharyngeal cancer and to examine whether it affects patient outcome. They showed that the percentage of CD8 cells was significantly higher and the CD4:CD8 ratio was significantly lower in HPV16-positive oropharyngeal patients. In comparing smokers and nonsmokers, the percentage of

CD8 cells was similar in the two groups, suggesting that the difference in CD8 levels was associated with HPV status and not with tobacco consumption. This elevated percentage of CD8 cells was associated with a response to induction chemotherapy and complete tumor response after chemoradiotherapy. These results (high percentage of CD8 cells and low CD4:CD8 ratio) were also associated with an improved overall survival. The mechanism by which there is an increase of T cells in the peripheral blood of HPV-positive patients has not been elucidated. One hypothesis suggested by the authors is that HPV-16-positive tumors have increased antigenicity through the E7 antigen, causing enhanced stimulation of the immune system, which more readily identifies tumor cells as foreign. This hypothesis is supported by a study led by Smith et al., in which the intralymphatic immunization of mice bearing E7-expressing tumors with E7 peptide resulted in a considerable expansion of E7-specific CD8 cells, which are effective in suppressing disease progression (Smith et al., 2009). In another animal model, the DNA vaccine with HSP70 fused to HPV-16 E7 has been demonstrated to dramatically increase the frequency of E7-specific CD8-positive T cells and to enhance the antitumor effects against E7-expressing tumor cells (Chen et al., 2000). All of these data support the idea that the clearance of HPV-positive tumor cells is antigen-dependent. Thus, the authors concluded that circulating CD8 cell levels may be a prognostic factor, and improved adaptive immunity may play a favorable role in the prognosis of patients with HPV16-positive tumors (Wansom et al., 2010).

7. Acknowledgement

Students supported by a grant from the FNRS (Bourse Télévie)

GD and AD contributed equally.

8. References

- Adelstein, DJ., Li, Y., Adams, GL., Wagner, H Jr., Kish, JA., Ensley, JF., Schuller, DE. & Forastiere, AA. (2003). An intergroup phase III comparison of standard radiation therapy and two schedules of concurrent chemoradiotherapy in patients with unresectable squamous cell head and neck cancer. *Journal of Clinical Oncology*, Vol.21, No.1, (January 2003), pp. 92-98
- Albers, A., Abe, K., Hunt, J., Wang, J., Lopez-Albaitero, A., Schaefer, C., Gooding, W., Whiteside, TL., Ferrone, S., DeLeo, A. & Ferris, RL. (2005). Antitumor activity of human papillomavirus type 16 E7-specific T cells against virally infected squamous cell carcinoma of the head and neck. *Cancer Research*, Vol.65, No.23, (December 2005), pp. 11146-11155
- Almadori, G., Cadoni, G., Cattani, P., Posteraro, P., Scarano, E., Ottaviani, F., Paludetti, G. & Maurizi, M. (1996). Detection of human papillomavirus DNA in laryngeal squamous cell carcinoma by polymerase chain reaction. *European Journal of Cancer*, Vol.32A, No.5, (May, 1996), pp. 783-788
- Al-Sarraf, M., LeBlanc, M., Giri, PG., Fu, KK., Cooper, J., Vuong, T., Forastiere, AA., Adams, G., Sakr, WA., Schuller, DE. & Ensley, JF. (1998). Chemoradiotherapy versus radiotherapy in patients with advanced nasopharyngeal cancer: phase III randomized Intergroup study 0099. *Journal of Clinical Oncology*, Vol.16, No.4, (April 1998), pp. 1310-1317

- Ang, KK., Harris J., Wheeler, R., Weber, R., Rosenthal, DI., Nguyen-Tân, PF., Westra, WH., Chung, CH., Jordan, RC., Lu, C., Kim, H., Axelrod, R., Silverman, CC., Redmond, KP. & Gillison, ML. (2010). Human papillomavirus and survival of patients with oropharyngeal cancer. *The New England Journal of Medicine*, Vol.363, No.1, (July 2010), pp. 24-35
- Arndt, O., Zeise, K., Bauer, I. & Brock, J. (1992). Type 6/11 and 16/18 squamous epithelial cancers of the upper respiratory tract and digestive system. An in situ hybridization study. *Laryngo-Rhino-Otologie*, Vol.71, No.10, (October 1992), pp. 500-504
- Arndt, O., Johannes, A., Zeise, K. & Brock, J. (1997). High-risk HPV types in oral and laryngeal papilloma and leukoplakia. *Laryngo-Rhino-Otologie*, Vol.76, No.3, (March 1997), pp. 142-149
- Ashrafi, GH., Haghshenas, MR., Marchetti, B., O'Brien, PM. & Campo, MS. (2005). E5 protein of human papillomavirus type 16 selectively downregulates surface HLA class I. *International Journal of Cancer*, Vol.113, No.2, (January 2005), pp. 276-283
- Aubin, F., Pretet, JL., Mougin, C. & Riethmuller, D. (2007). Human papillomavirus infection. *Annales de Dermatologie et de Vénéréologie*, Vol.134, No.1, (January 2007), pp. 94-99
- Badaracco, G., Venuti, A., Di Lonardo, A., Scambia, G., Mozzetti, S., Benedetti Panici, P., Mancuso, S. & Marcante, ML. (1998). Concurrent HPV infection in oral and genital mucosa. *Journal of Oral Pathology & Medicine*, Vol.27, No.3, (March 1998), pp. 130-134
- Bernier, J., Domenge, C., Ozsahin, M., Matuszewska, K., Lefèbvre, JL., Greiner, RH., Giralt, J., Maingon, P., Rolland, F., Bolla, M., Cognetti, F., Bourhis, J., Kirkpatrick, A. & van Glabbeke, M. (2004). Postoperative irradiation with or without concomitant chemotherapy for locally advanced head and neck cancer. *The New England Journal of Medicine*, Vol.350, No.19, (May 2004), pp. 1945-1952
- Bodaghi, S., Wood, LV., Roby, G., Ryder, C., Steinberg, SM. & Zheng, ZM. (2005). Could human papillomaviruses be spread through blood? *Journal of Clinical Microbiology*, Vol.43, No.11, (November 2005), pp. 5428-5434
- Bonagura, VR., Siegal, FP., Abramson, AL., Santiago-Schwarz, F., O'Reilly, ME., Shah, K., Drake, D. & Steinberg, BM. (1994). Enriched HLA-DQ3 phenotype and decreased class I major histocompatibility complex antigen expression in recurrent respiratory papillomatosis. *Clinical and Diagnostic Laboratory Immunology*, Vol.1, No.3, (May 1994), pp. 357-360
- Bonagura, VR., Hatam, L., DeVoti, J., Zeng, F. & Steinberg, BM. (1999). Recurrent respiratory papillomatosis :altered CD8⁺ T-cell subsets and T_H1/T_H2 cytokine imbalance. *Clinical Immunology*, Vol.93, No.3, (December 1999), pp. 302-311
- Bonagura, VR., Hatam, LJ., Rosenthal, DW., DeVoti, JA., Lam, F., Steinberg, BM. & Abramson, AL. (2010). Recurrent respiratory papillomatosis : a complex defect in immune responsiveness to human papillomavirus-6 and -11. *Acta Pathologica, Microbiologica et Immunologica Scandinavica*, Vol.118, No.6-7, (June 2010), pp. 455-470
- Boscolo-Rizzo, P., Da Mosto, MC., Fuson, R., Frayle-Salamanca, H., Trevisan, R. & Del Mistro, A. (2008). HPV-16 E6 L83V variant in squamous cell carcinomas of the upper aerodigestive tract. *Journal of Cancer Research and Clinical Oncology*, Vol.135, No.4, (April 2009), pp. 559-566
- Bourhis, J., Overgaard, J., Audry, H., Ang, KK., Saunders, M., Bernier, J., Horiot, JC., Le Maître, A., Pajak, TF., Poulsen, MG., O'Sullivan, B., Dobrowsky, W., Hliniak, A.,

- Skladowski, K., Hay, JH., Pinto, LH., Fallai, C., Fu, KK., Sylvester, R. & Pignon, JP. (2006). Hyperfractionated or accelerated radiotherapy in head and neck cancer: a meta-analysis. *The Lancet*, Vol.368, No.9538, (September 2006), pp. 843-854
- Boy, S., Van Rensburg, EJ., Engelbrecht, S., Dreyer, L., van Heerden, M. & van Heerden, W. (2006). HPV detection in primary intra-oral squamous cell carcinomas--commensal, aetiological agent or contamination? *Journal of Oral Pathology & Medicine*, Vol.35, No.2, (February 2006), pp. 86-90
- Brandsma, JL. & Abramson, AL. (1989). Association of papillomavirus with cancers of the head and neck. *Archives of Otolaryngology-Head & Neck Surgery*, Vol.115, No.5, (May 1989), pp. 621-625
- Brandwein, MS., Nuovo, GJ. & Biller, H. (1993). Analysis of prevalence of human papillomavirus in laryngeal carcinomas. Study of 40 cases using polymerase chain reaction and consensus primers. *Annals of Otolaryngology, Rhinology and Laryngology*, Vol.102, No.4 Pt 1, (April 1993), pp. 309-313
- Brown, LM., Check, DP. & Devesa, SS. (2011). Oropharyngeal cancer incidence trends: diminishing racial disparities. *Cancer Causes & Control*, Vol.22, No.5, (May 2011), pp. 753-763
- Campos-Bañales, ME., Pérez-Piñero, B., Barrios del Pino, Y., Salido Ruiz, E., Rivero Suárez, J., Ruiz Casals, E. & López Aguado, D. (1995). DNA papillomavirus detection in head and neck benign proliferative lesions. *Anales otorrinolaringológicos ibero-americanos*, Vol.22, No.5, (1995), 487-494
- Cañadas, MP., Bosch, FX., Junquera, ML., Ejarque, M., Font, R., Ordoñez, E. & De Sanjosé, S. (2004). Concordance of prevalence of human papillomavirus DNA in anogenital and oral infections in a high-risk population. *Journal of Clinical Microbiology*, Vol.42, No.3, (March 2004), pp. 1330-1332
- Cason, J., Kaye, JN., Jewers, RJ., Kambo, PK., Bible, JM., Kell, B., Shergill, B., Pakarian, F., Raju, KS. & Best, JM. (1995). Perinatal infection and persistence of human papillomavirus types 16 and 18 in infants. *Journal of Medical Virology*, Vol.47, No.3, (November 1995), pp. 209-218
- Cason, J. & Mant, CA. (2005). High-risk mucosal human papillomavirus infections during infancy & childhood. *Journal of Clinical Virology*, Vol.32, Suppl.1, (March 2005), pp. S52-S58
- Castellsagué, X., Drudis, T., Cañadas, MP., Goncé, A., Ros, R., Pérez, JM., Quintana, MJ., Muñoz, J., Albero, G., de Sanjosé, S. & Bosch, FX. (2009). Human papillomavirus (HPV) infection in pregnant women and mother-to-child transmission of genital HPV genotypes: a prospective study in Spain. *BMC Infectious Diseases*, Vol.9, No.74, (May 2009), pp. 1-12
- Castro, TP. & Bussoloti, Filho I. (2005). Prevalence of human papillomavirus (HPV) in oral cavity and oropharynx. *Brazilian Journal of Otorhinolaryngology*, Vol.72, No.2, (March-April 2006), pp. 272-282
- Castro, TM., Bussoloti Filho, I., Nascimento, VX. & Xavier, SD. (2009). HPV detection in the oral and genital mucosa of women with positive histopathological exam for genital HPV, by means of the PCR. *Brazilian Journal of Otorhinolaryngology*, Vol.75, No.2, (March-April 2009), pp. 167-171
- Chang, F., Syrjänen, S., Kellokoski, J. & Syrjänen, K. (1991). Human papillomavirus (HPV) infections and their associations with oral disease. *Journal of Oral Pathology & Medicine*, Vol.20, No.7, (August 1991), pp. 305-317

- Chen, CH., Wang, TL., Hung, CF., Yang, Y., Young, RA., Pardoll, DM. & Wu, TC. (2000). Enhancement of DNA vaccine potency by linkage of antigen gene to an HSP70 gene. *Cancer Research*, Vol.60, No.4, (February 2000), pp. 1035-1042
- Chen, R., Sehr, P., Waterboer, T., Leivo, I., Pawlita, M., Vaheri, A. & Aaltonen, LM. (2005). Presence of DNA of Human papillomavirus 16 but no other types in tumor-free tonsillar tissue. *Journal of Clinical Microbiology*, Vol.43, No.3, (March 2005), pp. 1408-1410
- Chung, CH. & Gillison, ML. (2009). Human papillomavirus in head and neck cancer: its role in pathogenesis and clinical implications. *Clinical Cancer Research*, Vol.15, No.2, (November 2009), pp. 6758-6762
- Clayman, GL., Stewart, MG., Weber, RS., el-Naggar, AK. & Grimm, EA. (1994). Human papillomavirus in laryngeal and hypopharyngeal carcinomas. Relationship to survival. *Archives of Otolaryngology Head & Neck Surgery*, Vol.120, No.7, (July 1994), pp. 743-748
- Cooper, JS., Pajak, TF., Forastiere, AA., Jacobs, J., Campbell, BH., Saxman, SB., Kish, JA., Kim, HE., Cmelak, AJ., Rotman, M., Machtay, M., Ensley, JF., Chao, KS., Schultz, CJ., Lee, N. & Fu, KK. (2004). Postoperative concurrent radiotherapy and chemotherapy for high-risk squamous-cell carcinoma of the head and neck. *The New England Journal of Medicine*, Vol.350, No.19, (May 2004), pp. 1937-1944
- Cortezzi, SS., Provazzi, PJ., Sobrinho, JS., Mann-Prado, JC., Reis, PM., de Freitas, SE., Filho, JF., Fukuyama, EE., Cordeiro, JA., Cury, PM., Maniglia, JV., Villa, LL., Tajara, EH. & Rahal, P. (2004). Analysis of human papillomavirus prevalence and TP53 polymorphism in head and neck squamous carcinomas. *Cancer Genetics and Cytogenetics*, Vol.150, No.1, (April 2004), pp. 44-49
- Cruz, IB., Snijders, PJ., Steenbergen, RD., Meijer, CJ., Snow, GB., Walboomers, JM. & van der Waal, I. (1996). Age-dependence of human papillomavirus DNA presence in oral squamous cell carcinomas. *European Journal of Cancer Part B: Oral Oncology*, Vol.32B, No.1, (January 1996), pp. 55-62
- Cuschieri, K. & Wentzensen, N. (2008). Human papillomavirus mRNA and p16 detection as biomarkers for the improved diagnosis of cervical neoplasia. *Cancer Epidemiology, Biomarkers & Prevention*, Vol.17, No.10, (October 2008), pp. 2536-2545
- Dahlgren, L., Dahlstrand, HM., Lindquist, D., Högmö, A., Björnestål, L., Lindholm, J., Lundberg, B., Dalianis, T. & Munck-Wikland, E. (2004). Human papillomavirus is more common in base of tongue than in mobile tongue cancer and is a favorable prognostic factor in base of tongue cancer patients. *International Journal of Cancer*, Vol.112, Vol.6, (December 2004), pp. 1015-1019
- Dahlstrand, HM. & Dalianis, T. (2005). Presence and influence of human papillomaviruses (HPV) in Tonsillar cancer. *Advances in Cancer Research*, Vol.93, (2005), pp. 59-89
- Dahlstrand, H., Näsman, A., Romanitan, M., Lindquist, D., Ramqvist, T. & Dalianis, T. (2008). Human papillomavirus accounts both for increased incidence and better prognosis in tonsillar cancer. *Anticancer Research*, Vol.28, No.2B, (March-April 2008), pp. 1133-1138
- Deng, Z., Hasegawa, M., Matayoshi, S., Kiyuna, A., Yamashita, Y., Maeda, H. & Suzuki, M. (2011). Prevalence and clinical features of human papillomavirus in head and neck squamous cell carcinoma in Okinawa, southern Japan. *European Archives of Oto-Rhino-Laryngology*, ahead of print, (February 2011)

- Denis, F., Garaud, P., Bardet, E., Alfonsi, M., Sire, C., Germain, T., Bergerot, P., Rhein, B., Tortochaux, J. & Calais, G. (2003). Final results of the 94-01 French Head and Neck Oncology and Radiotherapy Group randomized trial comparing radiotherapy alone with concomitant radiochemotherapy in advanced-stage oropharynx carcinoma. *Journal of Clinical Oncology*, Vol.22, No.1, (January 2004), pp. 69-76
- de Oliveira, DE., Bacchi, MM., Macarengo, RS., Tagliarini, JV., Cordeiro, RC. & Bacchi, CE. (2006). Human papillomavirus and Epstein-Barr virus infection, p53 expression, and cellular proliferation in laryngeal carcinoma. *American Journal of Clinical Pathology*, Vol.126, No.2, (August 2006), pp. 284-293
- Derkay, CS. (1995). Task force on recurrent respiratory papillomas. A preliminary report. *Archives of Otolaryngology Head & Neck Surgery*, Vol.121, No.12, (December 1995), pp. 1386-1391
- de Villiers, EM. (1989). Heterogeneity of the human papillomavirus group. *The Journal of Virology*, Vol.63, No.11, (November 1989), pp. 4898-4903
- de Villiers, EM., Fauquet, C., Broker, TR., Bernard, HU. & zur Hausen H. (2004). Classification of papillomaviruses. *Virology*, Vol.324, No.1, (June 2004), pp. 17-27
- de Villiers, EM. & Gunst, K. (2009). Characterization of seven novel human papillomavirus types isolated from cutaneous tissue, but also present in mucosal lesions. *Journal of General Virology*, Vol.90, Pt8, (August 2009), pp. 1999-2004
- Dickens, P., Srivastava, G., Loke, SL. & Larkin, S. (1991). Human papillomavirus 6, 11, and 16 in laryngeal papillomas. *The Journal of Pathology*, Vol.165, No.3, (November 1991), pp. 243-246
- Doorbar, J. & Myers, G. (1996). The E4 protein, In: *Human papillomaviruses: a compilation and analysis of nucleic acid and amino acid sequences*, Myers, G., Delius, H., Icenogel, J., Bernard, H-U., Baker, C., Halpern, A., Wheeler, C., (Ed), pp. 58-80, Los Alamos National Laboratory, New Mexico
- Doorbar, J. (2005). The papillomavirus life cycle. *Journal of Clinical Virology*, Vol.32, Suppl 1, (March 2005), pp. S7-15
- do Sacramento, PR., Babeto, E., Colombo, J., Cabral Ruback, MJ., Bonilha, JL., Fernandes, AM., Pereira Sobrinho, JS., de Souza, FP., Villa, LL. & Rahal, P. (2006). The prevalence of human papillomavirus in the oropharynx in healthy individuals in a brazilian population. *Journal of Medical Virology*, Vol.78, No.5, (May 2006), pp. 614-618
- Doyle, DJ., Henderson, LA., Lejeune, FE Jr. & Miller, RH. (1994). Changes in human papillomavirus typing of recurrent respiratory papillomatosis progressing to malignant neoplasm. *Archives of Otolaryngology Head & Neck Surgery*, Vol.120, No.11, (November 1994), pp. 1273-1276
- D'Souza, G., Kreimer, AR., Viscidi, R., Pawlita, M., Fakhry, C., Koch, WM., Westra, WH. & Gillison ML. (2007). Case-control study of human papillomavirus and oropharyngeal cancer. *The New England Journal of Medicine*, Vol.356, No.19, (May 2007), pp. 1944-1956
- D'Souza, G., Agrawal, Y., Halpern, J., Bodison, S. & Gillison, ML. (2009). Oral sexual behaviors associated with prevalent oral human papillomavirus infection. *The Journal of Infectious Diseases*, Vol.199, No.9, (May 2009), pp. 1263-1269
- Duray, A., Demoulin, S., Hubert, P., Delvenne, P. & Saussez, S. (2010). Immune suppression in head and neck cancers: a review. *Clinical and Developmental Immunology*, (2010), pp. 1-15

- Duray, A., Descamps, G., Arafa, M., Decaestecker, C., Rimmelinck, M., Sirtaine, N., Ernoux-Neufcoeur, P., Mutijima, E., Somja, J., Depuydt, CE., Delvenne, P. & Saussez, S. (2011a). High incidence of high-risk HPV in benign and malignant lesions of the larynx. *International Journal of Oncology*, Vol.39, No.1, (July 2011), pp. 51-59
- Duray, A., Descamps, G., Bettonville, M., Sirtaine, N., Ernoux-Neufcoeur, P., Guenin, S., Mouallif, M., Depuydt, E., Delvenne, P. & Saussez, S. (2011b). High prevalence of high-risk human papillomavirus in palatine tonsils from healthy children and adults. *Otolaryngology-Head and Neck Surgery*, add Vol.145, No.2, (August 2011), pp. 230-235
- Duray, A., Descamps, G., Decaestecker, C., Rimmelinck, M., Sirtaine, N., Lechien, J., Ernoux-Neufcoeur, P., Bletard, N., Somja, J., Depuydt, C., Delvenne, P. & Saussez, S. (2011). HPV DNA strongly correlates with a poorer prognosis in oral cavity carcinoma. *The Laryngoscope*, in revision
- Ernoux-Neufcoeur, P., Arafa, M., Decaestecker, C., Duray, A., Rimmelinck, M., Leroy, X., Herfs, M., Somja, J., Depuydt, CE., Delvenne, P. & Saussez, S. (2010). Combined analysis of HPV DNA, p16, p21 and p53 to predict prognosis in patients with stage IV hypopharyngeal carcinoma. *Journal of Cancer Research & Clinical Oncology*, Vol.137, No.1, (January 2011), pp. 173-181
- Ernster, JA., Sciotto, CG., O'Brien, MM., Finch, JL., Robinson, LJ., Willson, T. & Mathews, M. (2007). Rising incidence of oropharyngeal cancer and the role of oncogenic human papilloma virus. *The Laryngoscope*, Vol.117, No.12, (December 2007), pp. 2115-2128
- Ernster, JA., Sciotto, CG., O'Brien, MM., Robinson, LJ. & Willson, T. (2009). Prevalence of oncogenic human papillomavirus 16 and 18 in the palatine tonsils of the general adult population. *Archives of Otolaryngology-Head & Neck Surgery*, Vol.135, No.6, (June 2009), pp. 554-557
- Esquenazi, D., Bussoloti Filho, I., Carvalho Mda, G. & de Barros, FS. (2010). The frequency of human papillomavirus findings in normal oral mucosa of healthy people by PCR. *Brazilian Journal of Otorhinolaryngology*, Vol.76, No.1, (February 2010), pp. 78-84
- Fakhry, C., Westra, WH., Li, S., Cmelak, A., Ridge, JA., Pinto, H., Forastiere, A. & Gillison, ML. (2008). Improved survival of patients with human papillomavirus-positive head and neck squamous cell carcinoma in a prospective clinical trial. *The Journal of the National Cancer Institute*, Vol.100, No.4, (February 2008), pp. 261-269
- Filleul, O., Preillon, J., Crompton, E., Lechien, J. & Saussez, S. (2011). Incidence of head and neck cancers in Belgium : comparison with worldwide and french data. *Bulletin du Cancer*, Vol.98, No.10, (October 2011), pp. 1173-1183
- Fischer, M. (2005). Investigation of a broad-spectrum PCR assay for human papillomaviruses in screening benign lesions of the upper aerodigestive tract. *ORL: Journal for Oto-Rhino-Laryngology and Its Related Specialties*, Vol.67, No.4, (November 2005), pp. 237-241
- Forastiere, AA. & Trotti, A. (1999). Radiotherapy and concurrent chemotherapy : a strategy that improves locoregional control and survival in oropharyngeal cancer. *Journal of the National Cancer Institute*, Vol.91, No.24, (December 1999), pp. 2065-2066
- Fouret, P., Monceaux, G., Temam, S., Lacourreye, L. & St Guily, JL. (1997). Human papillomavirus in head and neck squamous cell carcinomas in nonsmokers. *Archives of Otolaryngology Head and Neck Surgery*, Vol.123, No.5, (May 1997), pp. 513-516

- Fredericks, BD., Balkin, A., Daniel, HW., Schonrock, J., Ward, B. & Frazer, IH. (1993). Transmission of human papillomaviruses from mother to child. *Australian and New Zealand Journal of Obstetrics and Gynaecology*, Vol.33, No.1, (February 1993), pp. 30-32
- Fukushima, K., Ogura, H., Watanabe, S., Yabe, Y. & Masuda, Y. (1994). Human papillomavirus type 16 DNA detected by the polymerase chain reaction in non-cancer tissues of the head and neck. *European Archives of Oto-Rhino-Laryngology*, Vol.251, No.2, (1994), pp. 109-112
- Gallo, A., Degener, AM., Pagliuca, G., Pierangeli, A., Bizzoni, F., Greco, A. & de Vincentiis, M. (2009). Detection of human papillomavirus and adenovirus in benign and malignant lesions of the larynx. *Otolaryngology Head and Neck Surgery*, Vol.141, No.2, (August 2009), pp. 276-281
- García-Milián, R., Hernández, H., Panadé, L., Rodríguez, C., González, N., Valenzuela, C., Araña, MD. & Perea, SE. (1998). Detection and typing of human papillomavirus DNA in benign and malignant tumours of laryngeal epithelium. *Acta otolaryngologica*, Vol.118, No.5, (September 1998), pp. 754-758
- Garnett, TO., Filippova, M. & Duerksen-Hughes, PJ. (2006). Accelerated degradation of FADD and procaspase 8 in cells expressing human papilloma virus 16 E6 impairs TRAIL-mediated apoptosis. *Cell Death and Differentiation*, Vol.13, No.11, (November 2006), pp. 1915-1926
- Georgopoulos, NT., Proffitt, JL. & Blair, GE. (2000). Transcriptional regulation of the major histocompatibility complex (MHC) class I heavy chain, TAP1 and LMP2 genes by the human papillomavirus (HPV) type 6b, 16 and 18 E7 oncoproteins. *Oncogene*, Vol.19, No.42, (October 2000), pp. 4930-4935
- Gillison, ML., Koch, WM., Capone, RB., Spafford, M., Westra, WH., Wu, L., Zahurak, ML., Daniel, RW., Viglione, M., Symer, DE., Shah, KV. & Sidransky, D. (2000). Evidence for a causal association between human papillomavirus and a subset of head and neck cancers. *Journal of the National Cancer Institute*, Vol.92, No.9, (May 2000), pp. 709-720
- Gillison, ML., D'Souza, G., Westra, W., Sugar, E., Xiao, W., Begum, S. & Viscidi, R. (2008). Distinct risk factor profiles for human papillomavirus type 16-positive and human papillomavirus type 16-negative head and neck cancers. *Journal of the National Cancer Institute*, Vol.100, No.6, (March 2008), pp. 407-420
- Giovannelli, L., Campisi, G., Lama, A., Giambalvo, O., Osborn, J., Margiotta, V. & Ammatuna, P. (2002). Human papillomavirus DNA in oral mucosal lesions. *The Journal of Infectious Diseases*, Vol.185, No.6, (March 2002), pp. 833-836
- Giraldo, P., Gonçalves, AKS., Pereira, SAS., Barros-Mazon, S., Gondo, ML. & Witkin, SS. (2006). Human papillomavirus in the oral mucosa of women with genital human papillomavirus lesions. *European Journal of Obstetrics & Gynecology and Reproductive Biology*, Vol. 126, No.1, (May 2006), pp. 104-106
- Gissmann, L., Wolnik, L., Ikenberg, H., Koldovsky, U., Schnürch, HG. & zur Hausen, H. (1983). Human papillomavirus types 6 and 11 DNA sequences in genital and laryngeal papillomas and in some cervical cancers. *Proceedings of the National Academy of Sciences of the United States of America*, Vol.80, No.2, (January 1983), pp. 560-563
- Globocan 2008, In: *International Agency for Research on Cancer*, 16th May 2011, Available from: <http://globocan.iarc.fr/>.

- Goon, P., Sonnex, C., Jani, P., Stanley, M. & Sudhoff, H. (2007). Recurrent respiratory papillomatosis: an overview of current thinking and treatment. *European Archives of Oto-Rhino-Laryngology*, Vol.265, No.2, (February 2008), pp.147-151
- Grandis, JR., Pietenpol, JA., Greenberger, JS., Pelroy, RA. & Mohla, S. (2004). Head and neck cancer : meeting summary and research opportunities. *Cancer Research*, Vol.64, No.21, (November 2004), pp. 8126-8129
- Gutman, LT., Herman-Giddens, ME. & Phelps, WC. (1993). Transmission of human genital papillomavirus disease : comparison of data from adults and children. *Pediatrics*, Vol.91, No.1, (January 1993), pp. 31-38
- Ha, PK., Pai, SI., Westra, WH., Gillison, ML., Tong, BC., Sidransky, D. & Califano, JA. (2002). Real-time quantitative PCR demonstrates low prevalence of human papillomavirus type 16 in premalignant and malignant lesions of the oral cavity. *Clinical Cancer Research*, Vol.8, No.5, (May 2002), pp. 1203-1209
- Hafkamp, HC., Speel, EJ., Haesevoets, A., Bot, FJ., Dinjens, WN., Ramaekers, FC., Hopman, AH. & Manni, JJ. (2003). A subset of head and neck squamous cell carcinomas exhibits integration of HPV 16/18 DNA and overexpression of p16INK4A and p53 in the absence of mutations in p53 exons 5-8. *International Journal of Cancer*, Vol.107, No.3, (November 2003), pp. 394-400
- Hafkamp, HC., Manni, JJ., Haesevoets, A., Voogd, AC., Schepers, M., Bot, FJ., Hopman, AH., Ramaekers, FC. & Speel, EJ. (2008). Marked differences in survival rate between smokers and nonsmokers with HPV 16-associated tonsillar carcinomas. *International Journal of Cancer*, Vol.122, No.12, (June 2008), pp. 2656-2664
- Hallden, C. & Majmudar, B. (1986). The relationship between juvenile laryngeal papillomatosis and maternal condylomata acuminata. *The Journal of Reproductive Medicine*, Vol.31, No.9, (September 1986), pp. 804-807
- Hansson, BG., Rosenquist, K., Antonsson, A., Wennerberg, J., Schildt, EB., Bladström, A. & Andersson, G. (2005). Strong association between infection with human papillomavirus and oral and oropharyngeal squamous cell carcinoma: a population-based case-control study in southern Sweden. *Acta Oto-Laryngologica*, Vol.125, No.12, (September 2005), pp. 1337-1344
- Hasan, UA., Bates, E., Takeshita, F., Biliato, A., Accardi, R., Bouvard, V., Mansour, M., Vincent, I., Gissmann, L., Iftner, T., Sideri, M., Stubenrauch, F. & Tommasino, M. (2007). TLR9 expression and function is abolished by the cervical cancer-associated human papillomavirus type 16. *Journal of Immunology*, Vol.178, No.5, (March 2007) pp. 3186-3197
- Hathaway, B., Landsittel, DP., Gooding, W., Whiteside, TL., Grandis, JR., Siegfried, JM., Bigbee, WL. & Ferris, RL. (2005). Multiplexed analysis of serum cytokines as biomarkers in squamous cell carcinoma of the head and neck patients. *The Laryngoscope*, Vol.115, No.3, (March 2005) pp. 522-527
- Herrero, R., Castellsagué, X., Pawlita, M., Lissowska, J., Kee, F., Balaram, P., Rajkumar, T., Sridhar, H., Rose, B., Pintos, J., Fernández, L., Idris, A., Sánchez, MJ., Nieto, A., Talamini, R., Tavani, A., Bosch, FX., Reidel, U., Snijders, PJ., Meijer, CJ., Viscidi, R., Muñoz, N., Franceschi, S. & IARC Multicenter Oral Cancer Study Group. (2003). Human papillomavirus and oral cancer: the International Agency for Research on Cancer multicenter study. *Journal of the National Cancer Institute*, Vol.95, No.23, (December 2003), pp. 1772-1783

- Hobbs, CG., Sterne, JA., Bailey, M., Heyderman, RS., Birchall, MA. & Thomas, SJ. (2006). Human papillomavirus and head and neck cancer: a systematic review and meta-analysis. *Clinical Otolaryngology*, Vol.31, No.4, (August, 2006), pp. 259-266
- Hoffmann, M., Kahn, T., Goeroegh, T., Lohrey, C., Gottschlich, S., Meyer, J., Rudert, H. & Maune, S. (2000). Tracing human papillomavirus DNA in nasal polyps by polymerase chain reaction. *Acta oto-laryngologica*, Vol. 120, No.7, (October 2000), pp. 872-875
- Hoffmann, TK., Bier, H. & Whiteside, TL. (2004). Targeting the immune system: novel therapeutic approaches in squamous cell carcinoma of the head and neck. *Cancer Immunology*, Vol.53, No.12, (December 2004), pp. 1055-1067
- Hoffmann, TK., Arsov, C., Schirlau, K., Bas, M., Friebe-Hoffmann, U., Klussmann, JP., Scheckenbach, K., Balz, V., Bier, H. & Whiteside, T.L. (2006). T cells specific for HPV16 E7 epitopes in patients with squamous cell carcinoma of the oropharynx. *International Journal of Cancer*, Vol.118, No.8, (April 2006), pp. 1984-1991
- Hughes, FJ. & Romanos, MA. (1993). E1 protein of human papillomavirus is a DNA helicase/ATPase. *Nucleic Acids Research*, Vol.21, No.25, (December 1993), pp. 5817-5823
- Ishii, Y., Ozaki, S., Tanaka, K. & Kanda, T. (2005). Human papillomavirus 16 minor capsid protein L2 helps capsomeres assemble independently of intercapsomeric disulfide bonding. *Virus Genes*, Vol.31, No.3, (December 2005), pp. 321-328
- Jalal, H., Sanders, CM., Prime, SS., Scully, C. & Maitland, NJ. (1992). Detection of human papillomavirus type 16 DNA in oral squames from normal young adults. *Journal of Oral Pathology & Medicine*, Vol.21, No.10, (November 1992), pp. 465-470
- Jenison, SA., Yu, XP., Valentine, JM., Koutsky, LA., Christiansen, AE., Beckmann, AM. & Galloway, DA. (1990). Evidence of prevalent genital-type human papillomavirus infections in adults and children. *The Journal of Infectious Diseases*, Vol.162, No.1, (July 1990), pp. 60-69
- Jeremic, B., Shibamoto, Y., Milicic, B., Nikolic, N., Dagovic, A., Aleksandrovic, J., Vaskovic, Z. & Tadic, L. (2000). Hyperfractionated radiation therapy with or without concurrent low-dose daily cisplatin in locally advanced squamous cell carcinoma of the head and neck: a prospective randomized trial. *Journal of Clinical Oncology*, Vol.18, No.7, (April 2000), pp. 1458-1464
- Kanodia, S., Fahey, LM. & Kast, WM. (2007). Mechanisms used by human papillomaviruses to escape the host immune response. *Current Cancer Drug Targets*, Vol.7, No.1, (February 2007), pp. 79-89
- Kansky, AA., Poljak, M., Seme, K., Kocjan, BJ., Gale, N., Luzar, B. & Golouh, R. (2003). Human papillomavirus DNA in oral squamous cell carcinomas and normal oral mucosa. *Acta Virologica*, Vol.47, No.1, (2003), pp. 11-16
- Kashima, HK., Shah, F., Lyles, A., Glackin, R., Muhammad, N., Turner, L., Van Zandt, S., Whitt, S. & Shah, K. (1992). A comparison of risk factors in juvenile-onset and adult-onset recurrent respiratory papillomatosis. *The Laryngoscope*, Vol.102, No.1, (January 1992), pp. 9-13
- Kashima, HK., Kesis, T., Hruban, RH., Wu, TC., Zinreich, SJ. & Shah, KV. (1992). Human papillomavirus in sinonasal papillomas and squamous cell carcinoma. *The Laryngoscope*, Vol.102, No.9, (September 1992), pp. 973-976
- Kaye, JN., Cason, J., Pakarian, FB., Jewers, RJ., Kell, B., Bible, J., Raju, KS. & Best, JM. (1994). Viral load as a determinant for transmission of human papillomavirus type 16 from

- mother to child. *Journal of Medical Virology*, Vol.44, No.4, (December 1994), pp. 415-421
- Kaye, JN., Starkey, WG., Kell, B., Biswas, C., Shanti Raju, K., Best, JM. & Cason, J. (1996). Human papillomavirus type 16 in infants: use of DNA sequence analyses to determine the source of infection. *Journal of General Virology*, Vol.77, No.6, (June 1996), pp. 1139-1143
- Kellokoski, J., Syrjänen, S., Yliskoski, M. & Syrjänen, K. (1992a). Dot blot hybridization in detection of human papillomavirus (HPV) infections in the oral cavity of women with genital HPV infections. *Oral Microbiology and Immunology*, Vol.7, No.1, (February 1992), pp. 19-23
- Kellokoski, JK., Syrjänen, SM., Chang, F., Yliskoski, M. & Syrjänen, KJ. (1992b). Southern blot hybridization and PCR in detection of oral human papillomavirus (HPV) infections in women with genital HPV infections. *Journal of Oral Pathology & Medicine*, Vol.21, No.10, (November 1992), pp. 459-464
- Kim, SH., Koo, BS., Kang, S., Park, K., Kim, H., Lee, KR., Lee, MJ., Kim, JM., Choi, EC. & Cho, NH. (2007). HPV integration begins in the tonsillar crypt and leads to the alteration of p16, EGFR and c-myc during tumor formation. *International Journal of Cancer*, Vol.120, No.7, (April 2007), pp. 1418-1425
- Kleist, B., Poetsch, M., Bankau, A., Werner, E., Herrmann, FH. & Lorenz, G. (2000). First hints for a correlation between amplification of the Int-2 gene and infection with human papillomavirus in head and neck squamous cell carcinomas. *Journal of Oral Pathology & Medicine*, Vol.29, No.9, (October 2000), pp. 432-437
- Klingenberg, B., Hafkamp, HC., Haesevoets, A., Manni, JJ., Slootweg, PJ., Weissenborn, SJ., Klusmann, JP. & Speel, EJ. (2010). p16 INK4A overexpression is frequently detected in tumour-free tonsil tissue without association with HPV. *Histopathology*, Vol.56, No.7, (June 2010), pp. 957-967
- Klozar, J., Tachezy, R., Rotnáglová, E., Koslabová, E., Saláková, M. & Hamsíková, E. (2010). Human papillomavirus in head and neck tumors: epidemiological, molecular and clinical aspects. *Wiener Medizinische Wochenschrift*, Vol.160, No.11-12, (June 2010), pp. 305-309
- Klusmann, JP., Weissenborn, SJ., Wieland, U., Dries, V., Kolligs, J., Jungehuelsing, M., Eckel, HE., Dienes, HP., Pfister, HJ. & Fuchs, PG. (2001). Prevalence, distribution, and viral load of human papillomavirus 16 DNA in tonsillar carcinomas. *Cancer*, Vol.92, No.11, (December 2001), pp. 2875-2884
- Koch, A., Hansen, SV., Nielsen, NM., Palefsky, J. & Melbye, M. (1997). HPV detection in children prior to sexual debut. *International Journal of Cancer*, Vol.73, No.5, (November 1997), pp. 621-624
- Kojima, A., Maeda, H., Kurahashi, N., Sakagami, G., Kubo, K., Yoshimoto, H. & Kameyama, Y. (2003). Human papillomaviruses in the normal oral cavity of children in Japan. *Oral Oncology*, Vol.39, No.8, (December 2003), pp. 821-828
- Koskinen, WJ., Chen, RW., Leivo, I., Mäkitie, A., Bäck, L., Kontio, R., Suuronen, R., Lindqvist, C., Auvinen, E., Molijn, A., Quint, WG., Vaheri, A. & Aaltonen, LM. (2003). Prevalence and physical status of human papillomavirus in squamous cell carcinomas of the head and neck. *International Journal of Cancer*, Vol.107, No.3, (November 2003), pp. 401-406
- Koskinen, WJ., Brøndbo, K., Mellin Dahlstrand, H., Luostarinen, T., Hakulinen, T., Leivo, I., Molijn, A., Quint, WG., Røysland, T., Munck-Wikland, E., Mäkitie, AA., Pyykkö, I.,

- Dillner, J., Vaheri, A. & Aaltonen, LM. (2007). Alcohol, smoking and human papillomavirus in laryngeal carcinoma: a Nordic prospective multicenter study. *Journal of Cancer Research and Clinical Oncology*, Vol.133, No.9, (September 2007), pp. 673-678
- Kovalenko, S., Lukashenko, P., Romanovskaya, A., Soldatski, IL., Bakanov, SI., Pfister, H. & Gerein, V. (2008). Distribution and density of CD1a+ and CD83+ dendritic cells in HPV-associated laryngeal papillomas. *International Journal of Pediatric Otorhinolaryngology*, Vol.73, No.2, (February 2009), pp. 249-256
- Koyama, K., Uobe, K. & Tanaka, A. (2007). Highly sensitive detection of HPV-DNA in paraffin sections of human oral carcinomas. *Journal of Oral Pathology & Medicine*, Vol.36, No.1, (January 2007), pp. 18-24
- Kreimer, AR., Alberg, AJ., Daniel, R., Gravitt, PE., Viscidi, R., Garrett, ES., Shah, KV. & Gillison, ML. (2004). Oral human papillomavirus infection in adults is associated with sexual behavior and HIV serostatus. *American Journal of Infectious Diseases*, Vol.189, No.4, (February 2004), pp. 686-698
- Kreimer, AR., Clifford, GM., Boyle, P. & Franceschi, S. (2005). Human papillomavirus types in head and neck squamous cell carcinomas worldwide: a systematic review. *Cancer Epidemiology, Biomarkers & Prevention*, Vol.14, No.2, (February 2005), pp. 467-475
- Kurose, K., Terai, M., Soedarsono, N., Rabello, D., Nakajima, Y., Burk, RD. & Takagi, M. (2004). Low prevalence of HPV infection and its natural history in normal oral mucosa among volunteers on Miyako Island, Japan. *Oral Surgery, Oral Medicine, Oral Pathology, Oral Radiology & Endodontics*, Vol.98, No.1, (July 2004), pp. 91-96
- Kuss, I., Saito, T., Johnson, JT. & Whiteside TL. (1999). Clinical significance of decreased ζ chain expression in peripheral blood lymphocytes of patients with head and neck cancer. *Clinical Cancer Research*, Vol.5, No.2, (February 1999), pp. 329-334
- Lacey, CJ., Lowndes, CM. & Shah, KV. (2006). Chapter 4: Burden and management of non-cancerous HPV-related conditions: HPV-6/11 disease. *Vaccine*, Vol.24, No.3, (August 2006), pp. 35-41
- Laco, J., Vosmikova, H., Novakova, V., Celakovsky, P., Dolezalova, H., Tucek, L., Nekvindova, J., Vosmik, M., Cermakova, E., Ryska, A. (2011). The role of high-risk human papillomavirus infection in oral and oropharyngeal squamous cell carcinoma in non-smoking and non-drinking patients: a clinicopathological and molecular study of 46 cases. *Virchows Archiv*, Vol.458, No.2, (February 2011), pp. 179-187
- Lang, K., Menzin, J., Earle, CC., Jacobson, J. & Hsu, MA. (2004). The economic cost of squamous cell cancer of the head and neck: findings from linked SEER-Medicare data. *Archives of Otolaryngology Head & Neck Surgery*, Vol.130, No.11, (November 2004), pp. 1269-1275
- Larson, DA., & Derkay, CS. (2010). Epidemiology of recurrent respiratory papillomatosis. *Acta Pathologica, Microbiologica and Immunologica Scandinavica*, Vol.118, No.6-7, (June 2010), pp. 450-454
- Lau, KM., Cheng, SH., Lo, KW., Lee, SA., Woo, JK., van Hasselt, CA., Lee, SP., Rickinson, AB. & Ng, MH. (2007). Increase in circulating Foxp3+ CD4+ CD25high regulatory T cells in nasopharyngeal carcinoma patients. *British Journal of Cancer*, Vol.96, No.4, (February 2007), pp. 617-622

- Lepique, AP., Daghashtanli, KR., Cuccovia, IM. & Villa, LL. (2009). HPV16 tumor associated macrophages suppress antitumor T cell responses. *Clinical Cancer Research*, Vol.15, No.13, (July 2009), pp. 4391-4400
- Li, Y., Nichols, MA., Shay, JW. & Xiong, Y. (1994). Transcriptional repression of the D-type cyclin-dependent kinase inhibitor p16 by the retinoblastoma susceptibility gene product pRb. *Cancer Research*, Vol.54, No.23, (December 1994), pp. 6078-6082
- Licitra, L., Bernier, J., Grandi, C., Merlano, M., Bruzzi, P. & Lefebvre, JL. (2002). Cancer of the oropharynx. *Critical Reviews in Oncology/Hematology*, Vol.41, No.1, (January 2002), pp. 107-122
- Lie, ES., Karlsen, F. & Holm, R. (1996). Presence of human papillomavirus in squamous cell laryngeal carcinomas. A study of thirty-nine cases using polymerase chain reaction and in situ hybridization. *Acta oto-laryngologica*, Vol.116, No.6, (November 1996), pp. 900-905
- Lindeberg, H. & Johansen, L. (1990). The presence of human papillomavirus (HPV) in solitary adult laryngeal papillomas demonstrated by in-situ DNA hybridization with sulphonated probes. *Clinical Otolaryngology and Allied Sciences*, Vol.15, No.4, (August 1990), pp. 367-371
- Lindeberg, H. & Krogdahl, A. (1999). Laryngeal cancer and human papillomavirus: HPV is absent in the majority of laryngeal carcinomas. *Cancer Letters*, Vol.146, No.1, (September 1999), pp. 9-13
- Lindel, K., Beer, KT., Laissue, J., Greiner, RH. & Aebersold, DM. (2001). Human papillomavirus positive squamous cell carcinoma of the oropharynx: a radiosensitive subgroup of head and neck carcinoma. *Cancer*, Vol.92, No.4, (August 2001), pp. 805-813
- Lindquist, D., Romanitan, M., Hammarstedt, L., Näsman, A., Dahlstrand, H., Lindholm, J., Onelöv, L., Ramqvist, T., Ye, W., Munck-Wikland, E. & Dalianis, T. (2007). Human papillomavirus is a favourable prognostic factor in tonsillar cancer and its oncogenic role is supported by the expression of E6 and E7. *Molecular Oncology*, Vol.1, No.3, (December 2007), pp. 350-355
- Lira, RC., Miranda, FA., Guimarães, MC., Simões, RT., Donadi, EA., Soares, CP. & Soares, EG. (2009). BUBR1 expression in benign oral lesions and squamous cell carcinomas: correlation with human papillomavirus. *Oncology Reports*, Vol.23, No.4 (April 2010), pp. 1027-1036
- Llamas-Martínez, S., Esparza-Gómez, G., Campo-Trapero, J., Cancela-Rodríguez, P., Bascones-Martínez, A., Moreno-López, LA., García-Núñez, JA. & Cerero-Lapiedra, R. (2008). Genotypic determination by PCR-RFLP of human papillomavirus in normal oral mucosa, oral leukoplakia and oral squamous cell carcinoma samples in Madrid (Spain). *Anticancer Research*, Vol.28, No.6A, (November-December 2008), pp. 3733-3742
- Lopes, V., Murray, P., Williams, H., Woodman, C., Watkinson, J. & Robinson, M. (2011). Squamous cell carcinoma of the oral cavity rarely harbours oncogenic human papillomavirus. *Oral Oncology*, ahead of print, (June 2011)
- Maitland, NJ., Cox, MF., Lynas, C., Prime, SS., Meanwell, CA. & Scully, C. (1987). Detection of human papillomavirus DNA in biopsies of human oral tissue. *British Journal of Cancer*, Vol.56, No.3, (September 1987), pp. 245-250

- Mammas, IN., Sourvinos, G., Michael, C. & Spandidos, DA. (2006). Human papilloma virus in hyperplastic tonsillar and adenoid tissues in children. *The Pediatric Infectious Disease Journal*, Vol.25, No.12, (December 2006), pp. 1158-1162
- Mammas, IN., Sourvinos, G. & Spandidos, DA. (2009). Human papilloma virus (HPV) infection in children and adolescents. *European Journal of Pediatrics*, Vol.168, No.3, (March 2009), pp. 267-273
- Mant, C., Kell, B., Rice, P., Best, JM., Bible, JM. & Cason, J. (2003). Buccal exposure to human papillomavirus type 16 is a common yet transitory event of childhood. *Journal of Medical Virology*, Vol. 71, No.4, (December 2003), pp. 593-598
- Marklund, L. & Hammarstedt, L. (2010). Impact of HPV in Oropharyngeal Cancer. *Journal of Oncology*, (2011)
- Marur, S. & Forastiere, AA. (2008). Head and neck cancer: changing epidemiology, diagnosis, and treatment. *Mayo Clinic Proceedings*, Vol.83, No.4, (April 2008), pp. 489-501
- Mazzatenta, C., Fimiani, M., Rubegni, P., Andreassi, L., Buffi, P. & Messina, C. (1996). Vertical transmission of human papillomavirus in cytologically normal women. *Genitourin Medicine*, Vol.72, No.6, (December 1996), pp. 445-452
- Medeiros, LR., de Moraes Ethur, A.B., Hilgert, JB., Zanini, RR., Berwanger, O., Bozzetti, MC. & Mylius, LC. (2005). Vertical transmission of the human papillomavirus: a systematic quantitative review. *Cadernos Saude Publica*, Vol.21, No.4, (July-Augustus 2005), pp. 1006-1015
- Miller, CS. & White, DK. (1996). Human papillomavirus expression in oral mucosa, premalignant conditions, and squamous cell carcinoma: a retrospective review of the literature. *Oral Surgery, Oral Medicine, Oral Pathology, Oral Radiology & Endodontics*, Vol.82, No.1, (July 1996), pp. 57-68
- Miller, CS. & Johnstone, BM. (2001). Human papillomavirus as a risk factor for oral squamous cell carcinoma: a meta-analysis, 1982-1997. *Oral Surgery, Oral Medicine, Oral Pathology, Oral Radiology & Endodontics*, Vol.91, No.6, (June 2001), pp. 622-635
- Mishra, A., Bharti, AC., Varghese, P., Saluja, D. & Das, BC. (2006). Differential expression and activation of NF-kappaB family proteins during oral carcinogenesis: Role of high risk human papillomavirus infection. *International Journal of Cancer*, Vol.119, No.12, (December 2006), pp. 2840-2850
- Monsonégo, J. (2007). *Traité des infections et pathologies génitales à papillomavirus*, Springer, 9782287720642, Paris
- Morgan, DW., Abdullah, V., Quiney, R. & Myint, S. (1991). Human papilloma virus and carcinoma of the laryngopharynx. *The Journal of Laryngology and Otology*, Vol.105, No.4, (April 1991), pp. 288-290
- Morshed, K., Polz-Dacewicz, M., Szymański, M. & Polz, D. (2008). Short-fragment PCR assay for highly sensitive broad-spectrum detection of human papillomaviruses in laryngeal squamous cell carcinoma and normal mucosa: clinico-pathological evaluation. *European Archives of Oto-Rhino-Laryngology*, Vol.265, No.Suppl 1, (July 2008), pp. 89-96
- Morshed, K. (2010). Association between human papillomavirus infection and laryngeal squamous cell carcinoma. *Journal of Medical Virology*, Vol.82, No.6, (May 2010), pp. 1017-1023
- Moscicki, AB., Hills, N., Shiboski, S., Powell, K., Jay, N., Hanson, E., Miller, S., Clayton, L., Farhat, S., Broering, J., Darragh, T. & Palefsky, J. (2001). Risks for incident human

- papillomavirus infection and low-grade squamous intraepithelial lesion development in young females. *The Journal of the American Medical Association*, Vol.285, No.23, (June 2001), pp. 2995-3002
- Myhre, AK., Dalen, A., Berntzen, K. & Bratlid, D. (2003). Anogenital human papillomavirus in non-abused preschool children. *Acta Paediatrica*, Vol.92, No.12, (December 2003), pp. 1445-1452
- Narisawa-Saito, M. & Kiyono, T. (2007). Basic mechanisms of high-risk human papillomavirus-induced carcinogenesis: roles of E6 and E7 proteins. *Cancer Science*, Vol.98, No.10, (October 2007), pp. 1505-1511
- Näsman, A., Attner, P., Hammarstedt, L., Du, J., Eriksson, M., Giraud, G., Ahrlund-Richter, S., Marklund, L., Romanitan, M., Lindquist, D., Ramqvist, T., Lindholm, J., Sparén, P., Ye, W., Dahlstrand, H., Munck-Wikland, E. & Dalianis, T. (2009). Incidence of human papillomavirus (HPV) positive tonsillar carcinoma in Stockholm, Sweden: an epidemic of viral-induced carcinoma? *International Journal of Cancer*, Vol.125, No.2, (July 2009), pp. 362-366
- Nebesio, CL., Mirowski, GW. & Chuang, TY. (2001). Human papillomavirus: clinical significance and malignant potential. *International Journal of Dermatology*, Vol.40, No.6, (June 2001), pp. 373-379
- Neufcoeur, PE., Arafa, M., Delvenne, P. & Saussez, S. (2009). Involvement of human papillomavirus in upper aero-digestive tracts cancers. *Bulletin du Cancer*, Vol.96, No.10, (October 2009), pp. 941-950
- Niedobitek, G., Pitteroff, S., Herbst, H., Shepherd, P., Finn, T., Anagnostopoulos, I. & Stein, H. (1990). Detection of human papillomavirus type 16 DNA in carcinomas of the palatine tonsil. *Journal of Clinical Pathology*, Vol.43, No.11, (November 1990), pp. 918-921
- O'Donovan, A. & Wood, RD. (1993). Identical defects in DNA repair in xeroderma pigmentosum group G and rodent ERCC group 5. *Nature*, Vol.363, No.6425, (May 1993), pp. 185-188
- Padayachee, A. (1994). Human papillomavirus (HPV) types 2 and 57 in oral verrucae demonstrated by in situ hybridization. *Journal of Oral Pathology & Medicine*, Vol.23, No.9, (October 1994), pp. 413-417
- Pakarian, F., Kaye, J., Cason, J., Kell, B., Jewers, R., Derias, NW., Raju, KS. & Best, JM. (1994). Cancer associated human papillomaviruses: perinatal transmission and persistence. *British Journal of Obstetrics and Gynaecology*, Vol.101, No.6, (June 1994), pp. 514-517
- Pannone, G., Santoro, A., Papagerakis, S., Lo Muzio, L., De Rosa, G. & Bufo, P. (2011). The role of human papillomavirus in the pathogenesis of head & neck squamous cell carcinoma: an overview. *Infectious Agents and Cancer*, Vol.6, No.4, (March 2011)
- Parkin, DM., Whelan, SL., Ferlay, J., Teppo, L., Thomas, D. & Thomas, DM. (2002). *Cancer Incidence in Five Continents* (vol.8), IARC, 9283224272, Lyon
- Parkin, DM., Bray, F., Ferlay, J. & Pisani, P. (2005). Global cancer statistics, 2002. *CA: A Cancer Journal for Clinicians*, Vol.55, No.2, (March-April 2005), pp. 74-108
- Paz, IB., Cook, N., Odom-Maryon, T., Xie, Y. & Wilczynski, SP. (1997). Human papillomavirus (HPV) in head and neck cancer. An association of HPV 16 with squamous cell carcinoma of Waldeyer's tonsillar ring. *Cancer*, Vol.79, No.3, (February 1997), pp. 595-604

- Pignon, JP., le Maître, A., Maillard, E. & Bourhis, J. (2009). Meta-analysis of chemotherapy in head and neck cancer (MACH-NC): an update on 93 randomised trials and 17,346 patients. *Radiotherapy & Oncology*, Vol.92, No.1, (July 2009), pp. 4-14
- Praetorius, F. (1997). HPV-associated diseases of oral mucosa. *Clinics in Dermatology*, Vol.15, No.3, (May 1997), pp. 399-413
- Psyrrri, A. & DiMaio, D. (2008). Human papillomavirus in cervical and head-and-neck cancer. *Nature Clinical Practice Oncology*, Vol.5, No.1, (January 2008), pp. 24-31
- Puranen, M., Yliskoski, M., Saarikoski, S., Syrjänen, K. & Syrjänen, S. (1996). Vertical transmission of human papillomavirus from infected mothers to their newborn babies and persistence of the virus in childhood. *American Journal of Obstetrics & Gynecology*, Vol.174, No2, (February 1996), pp. 694-699
- Puranen, MH., Yliskoski, MH., Saarikoski, SV., Syrjänen, KJ. & Syrjänen, SM. (1997). Exposure of an infant to cervical human papillomavirus infection of the mother is common. *American Journal of Obstetrics & Gynecology*, Vol.176, No.5, (May 1997), pp. 1039-1045
- Ragin, CC., Modugno, F. & Gollin, SM. (2007). The epidemiology and risk factors of head and neck cancer: a focus on human papillomavirus. *Journal of Dental Research*, Vol.86, No.2, (February 2007), pp. 104-114
- Ragin, CC. & Taioli, E. (2007). Survival of squamous cell carcinoma of the head and neck in relation to human papillomavirus infection: review and meta-analysis. *International Journal of Cancer*, Vol.121, No.8, (October 2007), pp. 1813-1820
- Ramqvist, T. & Dalianis, T. (2010). Oropharyngeal cancer epidemic and human papillomavirus. *Emerging Infectious Diseases Journal*, Vol.16, No.11, (November 2010), pp. 1671-1677
- Rees, L., Birchall, M., Bailey, M. & Thomas, S. (2004). A systematic review of case-control studies of human papillomavirus infection in laryngeal squamous cell carcinoma. *Clinical Otolaryngology and Allied Sciences*, Vol.29, No.4, (August 2004), pp. 301-306
- Reichert, TE., Rabinowich, H., Johnson, JT. & Whiteside, TL. (1998a). Mechanisms responsible for signaling and functional defects. *Journal of Immunotherapy*, Vol.21, No.4, (July 1998), pp. 295-306
- Reichert, TE., Day, R., Wagner, EM. & Whiteside, TL. (1998b). Absent or low expression of the ζ chain in T cells at the tumor site correlates with poor survival in patients with oral carcinoma. *Cancer Research*, Vol.58, No.23, (December 1998), pp. 5344-5347
- Remmerbach, TW., Brinckmann, UG., Hemprich, A., Chekol, M., Kühndel, K. & Liebert, UG. (2004). PCR detection of human papillomavirus of the mucosa: comparison between MY09/11 and GP5+/6+ primer sets. *Journal of Clinical Virology*, Vol.30, No.4, (August 2004), pp. 302-308
- Ribeiro, KMX., Alvez, JM., Pignatari, SSN. & Weckx, LLM. (2006). Detection of human papilloma virus in the tonsils of children undergoing tonsillectomy. *The Brazilian Journal of Infectious Diseases*, Vol.10, No.3, (June 2006), pp. 165-168
- Ribeiro, KB., Levi, JE., Pawlita, M., Koifman, S., Matos, E., Eluf-Neto, J., Wunsch-Filho, V., Curado, MP., Shangina, O., Zaridze, D., Szeszenia-Dabrowska, N., Lissowska, J., Daudt, A., Menezes, A., Bencko, V., Mates, D., Fernandez, L., Fabianova, E., Gheit, T., Tommasino, M., Boffetta P., Brennan, P. & Waterboer, T. (2011). Low human papillomavirus prevalence in head and neck cancer: results from two large case-control studies in high-incidence regions. *International Journal of Epidemiology*, Vol.40, No.2, (April 2011), pp. 489-502

- Rice, PS., Mant, C., Cason, J., Bible, JM., Muir, P., Kell, B. & Best, JM. (2000). High prevalence of human papillomavirus type 16 infection among children. *Journal of Medical Virology*, Vol.61, No.1, (May 2000), pp. 70-75
- Ringström, E., Peters, E., Hasegawa, M., Posner, M., Liu, M. & Kelsey, KT. (2002). Human papillomavirus type 16 and squamous cell carcinoma of the head and neck. *Clinical Cancer Research*, Vol.8, No.10, (October 2002), pp. 3187-3192
- Rintala, MA., Grénman, SE., Järvenkylä, ME., Syrjänen, KJ. & Syrjänen, SM. (2005a). High-risk types of human papillomavirus (HPV) DNA in oral and genital mucosa of infants during their first 3 years of life : experience from the finnish HPV family study. *Clinical Infectious Diseases*, Vol.41, No.12, (December 2005), pp. 1728-1733
- Rintala, MA., Grénman, SE., Puranen, MH., Isolauri, E., Ekblad, U., Kero, PO. & Syrjänen. (2005b). Transmission of high-risk human papillomavirus (HPV) between parents and infant : a prospective study of HPV in families in Finland. *Journal of Clinical Microbiology*, Vol.43, No.1, (January 2005), pp. 376-381
- Rombaldi, RL., Serafini, EP., Mandelli, J., Zimmermann, E. & Losquiavo, KP. (2008). Transplacental transmission of human papillomavirus. *Virology Journal*, Vol.5, No.106, (September 2008), pp. 1-14
- Rombaldi, RL., Serafini, EP., Mandelli, J., Zimmermann, E. & Losquiavo, KP. (2009). Perinatal transmission of human papillomavirus DNA. *Virology Journal*, Vol.6, No.83, (June 2009), pp. 1-12
- Rosenquist, K., Wennerberg, J., Annertz, K., Schildt, EB., Hansson, BG., Bladström, A. & Andersson, G. (2007). Recurrence in patients with oral and oropharyngeal squamous cell carcinoma: human papillomavirus and other risk factors. *Acta Otolaryngologica*, Vol.127, No.9, (September 2007), pp. 980-987
- Rotnáglová, E., Tachezy, R., Saláková, M., Procházka, B., Košl'abová, E., Veselá, E., Ludvíková, V., Hamšíková, E. & Klozar J. (2011). HPV involvement in tonsillar cancer: prognostic significance and clinically relevant markers. *International Journal of Cancer*, Vol.129, No.1, (July 2011), pp. 101-110
- Saini, R., Khim, TP., Rahman, SA., Ismail, M. & Tang, TH. (2010). High-risk human papillomavirus in the oral cavity of women with cervical cancer, and their children. *Virology Journal*, Vol.16, No.7, (June 2010), pp. 1-7
- Sarkola, ME., Grénman, SE., Rintala, MA., Syrjänen, KJ. & Syrjänen, SM. (2008a). Human papillomavirus in the placenta and umbilical cord blood. *Acta Obstetrica et Gynecologica Scandinavica*, Vol.87, No.11, (2008), pp. 1181-1188
- Sarkola, M., Rintala, M., Grénman, S. & Syrjänen, S. (2008b). Human papillomavirus DNA detected in breast milk. *Pediatric Infectious Disease Journal*, Vol.27, No.6, (June 2008), pp. 557-558
- Scherly, D., Nospikel, T., Corlet, J., UCLA, C., Bairoch, A. & Clarkson, SG. (1993). Complementation of the DNA repair defect in xeroderma pigmentosum group G cells by a human cDNA related to yeast RAD2. *Nature*, Vol.363, No.6425, (May 1993), pp. 182-185
- Schwartz, SM., Daling, JR., Doody, DR., Wipf, GC., Carter, JJ., Madeleine, MM., Mao, EJ., Fitzgibbons, ED., Huang, S., Beckmann, AM., McDougall, JK. & Galloway, DA. (1998). Oral cancer risk in relation to sexual history and evidence of human papillomavirus infection. *Journal of the National Cancer Institute*, Vol.90, No.21, (November 1998), pp. 1626-1636

- Schwartz, SR., Yueh, B., McDougall, JK., Daling, JR. & Schwartz, SM. (2001). Human papillomavirus infection and survival in oral squamous cell cancer: a population-based study. *Otolaryngology Head and Neck Surgery*, Vol.125, No.1, (July 2001), pp. 1-9
- Schwenger, JU., von Buchwald, C. & Lindeberg, H. (2002). Oral focal epithelial hyperplasia. Any risk of confusion with oral condylomas? *Ugeskrift for Laeger*, Vol.164, No.37, (September 2002), pp. 4287-4290
- Scully, C., Maitland, NJ., Cox, MF. & Prime, SS. (1987). Human papillomavirus DNA and oral mucosa. *Lancet*, Vol.7, No.1(8528), (February 1987), pp. 336
- Sedaghat, AR., Zhang, Z., Begum, S., Palermo, R., Best, S., Ulmer, KM., Levine, M., Zinreich, E., Messing, BP., Gold, D., Wu, AA., Niparko, KJ., Kowalski, J., Hirata, RM., Saunders, JR., Westra, WH. & Pai, SI. (2009). Prognostic significance of human papillomavirus in oropharyngeal squamous cell carcinomas. *The Laryngoscope*, Vol.119, No.8, (August 2009), pp. 1542-1549
- Sedlacek, TV., Lindheim, S., Eder, C., Hasty, L., Woodland, M., Ludomirsky, A. & Rando, RK. (1989). Mechanism for human papillomavirus transmission at birth. *American Journal of Obstetrics & Gynecology*, Vol.161, No.1, (July 1989), pp. 55-59
- Shah, JP. & Patel, SG. (2003). *Head and neck surgery and oncology*. New York : Mosby, pp. 232-236, 352
- Shen, J., Tate, JE., Crum, CP. & Goodman, ML. (1996). Prevalence of human papillomaviruses (HPV) in benign and malignant tumors of the upper respiratory tract. *Modern Pathology*, Vol.9, No.1, (January 1996), pp. 15-20
- Silverberg, MJ., Thorsen, P., Lindeberg, H., Grant, LA. & Shah, KV. (2003). Condyloma in pregnancy is strongly predictive of juvenile-onset recurrent respiratory papillomatosis. *Obstetrics & Gynecology*, Vol.101, No.4, (April 2003), pp. 645-652
- Sinha, P., Logan, HL. & Mendenhall, WM. (2011). Human papillomavirus, smoking, and head and neck cancer. *American Journal of Otolaryngology*, ahead of print, (May 2011)
- Sisk, J., Schweinfurth, JM., Wang, XT. & Chong, K. (2006). Presence of human papillomavirus DNA in tonsillectomy specimens. *The Laryngoscope*, Vol.116, No.8, (August 2006), pp. 1372-1374
- Smith, EM., Pignatari, SS., Gray, SD., Haugen, TH. & Turek, LP. (1993). Human papillomavirus infection in papillomas and nondiseased respiratory sites of patients with recurrent respiratory papillomatosis using the polymerase chain reaction. *Archives of Otolaryngology-Head & Neck Surgery*, Vol.119, No.5, (May 1993), pp. 554-557
- Smith, EM., Johnson, SR., Cripe, T., Perlman, S., McGuinness, G., Jiang, D., Cripe, L. & Turek, LP. (1995). Perinatal transmission and maternal risks of human papillomavirus infection. *Cancer Detection and Prevention*, Vol.19, No.2, (1995), pp. 196-205
- Smith, EM., Hoffman, HT., Summersgill, KS., Kirchner, HL., Turek, LP. & Haugen, TH. (1998). Human papillomavirus and risk of oral cancer. *Laryngoscope*, Vol.108, No.7, (July 1998), pp. 1098-1013
- Smith, EM., Ritchie JM., Summersgill KF., Klusmann JP., Lee JH., Wang D., Haugen TH. & Turek LP. (2004a). Age, sexual behavior and human papillomavirus infection in oral cavity and oropharyngeal cancers. *International Journal of Cancer*, Vol.108, No.5, (February 2004), pp. 766-772


- Smith, EM., Ritchie, JM., Yankowitz, J., Swarnavel, S., Wang, D., Haugen, TH. & Turek, LP. (2004b). Human papillomavirus prevalence and types in newborns and parents : concordance and modes of transmission. *Sexually Transmitted Diseases*, Vol.31, No.1, (January 2004), pp. 57-62
- Smith, EM., Ritchie, JM., Yankowitz, J., Wang, D., Turek, LP. & Haugen, TH. (2004c). HPV prevalence and concordance in the cervix and oral cavity of pregnant women. *Infectious Diseases in Obstetrics and Gynecology*, Vol.12, No.2, (June 2004), pp. 45-56
- Smith, EM., Swarnavel, S., Ritchie, JM., Wang, D., Haugen, TH. & Turek, LP. (2007). Prevalence of human papillomavirus in the oral cavity/oropharynx in a large population of children and adolescents. *The Pediatric Infectious Disease Journal*, Vol.26, No.9, (September 2007), pp. 836-840
- Smith, KA., Meisenburg, BL., Tam, VL., Pagarigan, RR., Wong, R., Joea, DK., Lantzy, L., Carillo, MA., Gross, TM., Malyankar, UM., Chiang, CS., Da Silva, DM., Kündig, TM., Kast, WM., Qiu, Z. & Bot, A. (2009). Lymph node-targeted immunotherapy mediates potent immunity resulting in regression of isolated or metastatic human papillomavirus-transformed tumors. *Clinical Cancer Research*, Vol.15, No.19, (October 2009), pp. 6167-6176
- Smith, EM., Parker, MA., Rubenstein, LM., Haugen, TH., Hamsikova, E. & Turek, LP. (2010). Evidence for vertical transmission of HPV from mothers to infants. *Infectious Diseases in Obstetrics and Gynecology*, (2010), pp. 1-7
- Snijders, PJ., Cromme, FV., van den Brule, AJ., Schrijnemakers, HF., Snow, GB., Meijer, CJ. & Walboomers, JM. (1992). Prevalence and expression of human papillomavirus in tonsillar carcinomas, indicating a possible viral etiology. *International Journal of Cancer*, Vol.51, No.6, (July 1992), pp. 845-850
- Spanos, WC., Nowicki P., Lee, DW., Hoover, A., Hostager, B., Gupta, A., Anderson, ME. & Lee, JH. (2009). Immune response during therapy with cisplatin or radiation for human papillomavirus-related head and neck cancer. *Archives of Otolaryngology Head & Neck Surgery*, Vol.135, No.11, (November 2009), pp. 1137-1146
- Stanley, MA. (2006). Immune responses to human papillomavirus. *Vaccine*, Vol.24, Suppl1, (March 2006), pp. S1/16-S1/22
- Stanley, MA. (2009). Immune responses to human papilloma viruses. *Indian Journal of Medical Research*, Vol.130, No.3, (September 2009), pp. 266-276
- Stremlau, A., Zenner, HP., Gissmann, L. & zur Hausen, H. (1987). Demonstration and organizational structure of the DNA of human papillomaviruses in laryngeal and hypopharyngeal carcinomas. *Laryngologie, Rhinologie, Otologie*, Vol.66, No.6, (June 1987), pp. 311-315
- Strome, SE., Savva, A., Brissett, AE., Gostout, BS., Lewis, J., Clayton, AC., McGovern, R., Weaver, AL., Persing, D. & Kasperbauer, JL. (2002). Squamous cell carcinoma of the tonsils : a molecular analysis of HPV associations. *Clinical Cancer Research*, Vol.8, No.4, (April 2002), pp. 1093-1100
- Sturgis, EM. & Cinciripini, PM. (2007). Trends in head and neck cancer incidence in relation to smoking prevalence: an emerging epidemic of human papillomavirus-associated cancers? *Cancer*, Vol.110, No.7, (October 2007), pp. 1429-1435
- Sugiyama, M., Bhawal, UK., Dohmen, T., Ono, S., Miyauchi, M. & Ishikawa, T. (2003). Detection of human papillomavirus-16 and HPV-18 DNA in normal, dysplastic, and malignant oral epithelium. *Oral Surgery, Oral Medicine, Oral Pathology, Oral Radiology & Endodontics*, Vol.95, No.5, (May 2003), pp. 594-600

- Summersgill, KF., Smith, EM., Levy, BT., Allen, JM., Haugen, TH. & Turek, LP. (2001). Human papillomavirus in the oral cavities of children and adolescents. *Oral and Maxillofacial Pathology*, Vol.91, No.1, (January 2001), pp. 62-69
- Syrjänen, K., Syrjänen, S., Lamberg, M., Pyrhönen, S. & Nuutinen, J. (1983). Morphological and immunohistochemical evidence suggesting human papillomavirus (HPV) involvement in oral squamous cell carcinogenesis. *International Journal of Oral & Maxillofacial Surgery*, Vol.12, No.6, (December 1983), pp. 418-424
- Syrjänen, S., Syrjänen, K., Mäntyjärvi, R., Collan, Y. & Kärjä, J. (1987). Human papillomavirus DNA in squamous cell carcinomas of the larynx demonstrated by in situ DNA hybridization. *ORL: Journal for Oto-Rhino-Laryngology and Its Related Specialties*, Vol.49, No.4, (1987), pp. 175-186
- Syrjänen, S. & Puranen, M. (2000). Human papillomavirus infections in children: the potential role of maternal transmission. *Critical Reviews in Oral Biology & Medicine*, Vol.11, No.2, (2000), pp. 259-274
- Syrjänen, S. (2003). Human papillomavirus infections and oral tumors. *Medical Microbiology and Immunology*, Vol.192, No.3, (August 2003), pp. 123-128
- Syrjänen, S. (2004). HPV infections and tonsillar carcinoma. *Journal of Clinical Pathology*, Vol.57, No.5, (May 2004), pp. 449-455
- Syrjänen, S. (2010). Current concepts on human papillomavirus infections in children. *Acta Pathologica, Microbiologica et Immunologica Scandinavica*, Vol.118, No.6-7, (June 2010), pp. 494-509
- Syrjänen, S., Lodi, G., von Bültzingslöwen, I., Aliko, A., Arduino, P., Campisi, G., Challacombe, S., Ficarra, G., Flaitz, C., Zhou, HM., Maeda, H., Miller, C. & Jontell, M. (2011). Human papillomaviruses in oral carcinoma and oral potentially malignant disorders: a systematic review. *Oral Diseases*, Vol.17, Suppl.1, (April 2011), pp. 58-72
- Szarka, K., Tar, I., Fehér, E., Gáll, T., Kis, A., Tóth, ED., Boda, R., Márton, I. & Gergely, L. (2009). Progressive increase of human papillomavirus carriage rates in potentially malignant and malignant oral disorders with increasing malignant potential. *Oral Microbiology and Immunology*, Vol.24, No.4, (August 2009), pp. 314-318
- Szydlowski, J., Durzynski, L., Myga, M., Grzegorowski, M. & Gozdzicka-Józefiak, A. (2004). Human papillomavirus DNA presence of the upper respiratory tract mucosa of healthy children. *Otolaryngologia Polska*, Vol.58, No.1, (2004), pp. 211-215
- Tenti, P., Zappatore, R., Migliora, P., Spinello, A., Maccarini, U., De Benedittis, M., Vesentini, N., Marchitelli, G., Silini, E. & Carnevali, L. (1997). Latent human papillomavirus infection in pregnant women at term: a case-control study. *Journal of Infectious Diseases*, Vol.176, No.1, (July 1997), pp. 277-280
- Tenti, P., Zappatore, R., Migliora, P., Spinillo, A., Belloni, C. & Carnevali, L. (1999). Perinatal transmission of human papillomavirus from gravidas with latent infections. *Obstetrics & Gynecology*, Vol.93, No.4, (April 1999), pp. 475-479
- Terai, M., Hashimoto, K., Yoda, K. & Sata, T. (1999). High prevalence of human papillomaviruses in the normal oral cavity of adults. *Oral Microbiology and Immunology*, Vol.14, No.4, (August 1999), pp. 201-205
- Termine, N., Panzarella, V., Falaschini, S., Russo, A., Matranga, D., Lo Muzio, L. & Campisi, G. (2008). HPV in oral squamous cell carcinoma vs head and neck squamous cell carcinoma biopsies: a meta-analysis (1988-2007). *Annals of Oncology*, Vol.19, No.10, (October, 2008), pp. 1681-1690

- Thomas, M. & Banks, L. (1999). Human papillomavirus (HPV) E6 interactions with Bak are conserved amongst E6 proteins from high and low risk HPV types. *Journal of General Virology*, Vol.80, Pt 6, (June 1999), pp. 1513-1517
- Tominaga, S., Fukushima, K., Nishizaki, K., Watanebe, S., Masuda, Y. & Ogura H. (1996). Presence of human papillomavirus type 6f in tonsillar condyloma acuminatum and clinically normal tonsillar mucosa. *Japanese Journal of Clinical Oncology*, Vol.26, No.6, (December 1996), pp. 393-397
- Tseng, C.J., Liang, C.C., Soong, Y.K. & Pao, C.C. (1998). Perinatal transmission of human papillomavirus in infants: relationship between infection rate and mode of delivery. *Obstetrics & Gynecology*, Vol.91, No.1, (January 1998), pp. 92-96
- Tung, Y.C., Lin, K.H., Chu, P.Y., Hsu, C.C. & Kuo, W.R. (1999). Detection of human papilloma virus and Epstein-Barr virus DNA in nasopharyngeal carcinoma by polymerase chain reaction. *The Kaohsiung Journal of Medical Sciences*, Vol.15, No.5, (May 1999), pp. 256-262
- Tyan, Y.S., Liu, S.T., Ong, W.R., Chen, M.L., Shu, C.H. & Chang, Y.S. (1993). Detection of Epstein-Barr virus and human papillomavirus in head and neck tumors. *Journal of Clinical Microbiology*, Vol.31, No.1, (January 1993), pp. 53-56
- Uobe, K., Masuno, K., Fang, Y.R., Li, L.J., Wen, Y.M., Ueda, Y. & Tanaka, A. (2001). Detection of HPV in Japanese and Chinese oral carcinomas by in situ PCR. *Oral Oncology*, Vol.37, No.2, (February 2001), pp. 146-152
- Vambutas, A., Bonagura, V.R. & Steinberg, B.M. (2000). Altered expression of TAP-1 and major histocompatibility complex class I in laryngeal papillomatosis: correlation of TAP-1 with disease. *Clinical and Diagnostic Laboratory Immunology*, Vol.7, No.1, (January 2000), pp. 79-85
- Van Doornum, G.J., Hooykaas, C., Juffermans, L.H., van der Lans, S.M., van der Linden, M.M., Coutinho, R.A. & Quint, W.G. (1992). Prevalence of human papillomavirus infections among heterosexual men and women with multiple sexual partners. *Journal of Medical Virology*, Vol.37, No.1, (May 1992) pp. 13-21
- Wansom, D., Light, E., Worden, F., Prince, M., Urba, S., Chepeha, D.B., Cordell, K., Eisbruch, A., Taylor, J., D'Silva, N., Moyer, J., Bradford, C.R., Kurnit, D., Kumar, B., Carey, T.E. & Wolf, G.T. (2010). Correlation of cellular immunity with human papillomavirus 16 status and outcome in patients with advanced oropharyngeal cancer. *Archives of Otolaryngology-Head & Neck Surgery*, Vol.136, No.12, (December 2010), pp. 1267-1273
- Watanabe, S., Ogura, H., Fukushima, K. & Yabe, Y. (1993). Comparison of virapap filter hybridization with polymerase chain reaction and southern blot hybridization methods for detection of human papillomavirus in tonsillar and pharyngeal cancers. *European Archives of Oto-Rhino-Laryngology*, Vol.250, No.2, (1993), pp. 115-119
- Watts, D.H., Koutsky, L.A., Holmes, K.K., Goldman, D., Kuypers, J., Kiviat, N.B. & Galloway, D.A. (1998). Low risk of perinatal transmission of human papillomavirus: results from a prospective cohort study. *American Journal of Obstetrics and Gynecology*, Vol.178, No.2, (February 1998), pp. 365-373
- Whiteside, T.L. (1999). Signaling defects in T lymphocytes of patients with malignancy. *Cancer Immunology Immunotherapy*, Vol.48, No.7, (October 1999), pp. 346-352
- Whiteside, T.L. (2005). Immunobiology of head and neck. *Cancer and Metastasis Reviews*, Vol.24, No.1, (January 2005), pp. 95-105

- Williams, GR., Lu, QL., Love, SB., Talbot IC. & Northover, JM. (1996). Properties of HPV-positive and HPV-negative anal carcinomas. *The Journal of Pathology*, Vol.180, No.4, (December 1996), pp. 378-382
- Williams, R., Lee, DW., Elzey, BD., Anderson, ME., Hostager, BS. & Lee, JH. (2009). Preclinical models of HPV+ and HPV- HNSCC in mice : an immune clearance of HPV+ HNSCC. *Head and Neck*, Vol.31, No.7, (July 2009), pp. 911-918
- Winer, RL., Lee, S-K., Hughes, JP., Adam, DE., Kiviat, NB. & Koutsky, LA. (2003). Genital human papillomavirus infection : incidence and risk factors in a cohort of female university students. *American Journal of Epidemiology*, Vol.157, No.3, (February 2003), pp. 218-226
- Yeudall, WA. & Campo, MS. (1991). Human papillomavirus DNA in biopsies of oral tissues. *Journal of General Virology*, Vol.72, No.1, (January 1991), pp. 173-176
- You, J., Croyle, JL., Nishimura, A., Ozato, K. & Howley, PM. (2004). Interaction of the bovine papillomavirus E2 protein with Brd4 tethers the viral DNA to host mitotic chromosomes. *Cell*, Vol.117, No.3, (April 2004), pp. 349-360
- Young, MRI., Wright, MA., Lozano, Y., Matthews, JP., Benefield, J. & Prechel, MM. (1996). Mechanisms of immune suppression in patients with head and neck cancer: influence on the immune infiltrate of the cancer. *International Journal of Cancer*, Vol.67, No.3, (July 1996), pp. 333-338
- Zeuss, MS., Miller CS. & White DK. (1991). In situ hybridization analysis of human papillomavirus DNA in oral mucosal lesions. *Oral Surgery, Oral Medicine, Oral Pathology, Oral Radiology and Endodontology*, Vol.71, No.6, (June 1991), pp. 714-720
- Zhang, ZY, Sdek, P., Cao, J. & Chen, WT. (2004). Human papillomavirus type 16 and 18 DNA in oral squamous cell carcinoma and normal mucosa. *International Journal of Oral and Maxillofacial Surgery*, Vol.33, No.1, (January 2004), pp. 71-74
- Zhao, D., Xu QG., Chen XM. & Fan, MW. (2009). Human papillomavirus as an independent predictor in oral squamous cell cancer. *International Journal of Oral Science*, Vol.1, No.3, (September 2009), pp. 119-125
- zur Hausen, H. & de Villiers, EM. (1994). Human papillomaviruses. *Annual Review of Microbiology*, Vol.48, (1994), pp. 427-447

IntechOpen



Human Papillomavirus and Related Diseases - From Bench to Bedside - A Clinical Perspective

Edited by Dr. Davy Vanden Broeck

ISBN 978-953-307-860-1

Hard cover, 348 pages

Publisher InTech

Published online 20, January, 2012

Published in print edition January, 2012

Cervical cancer is the second most prevalent cancer among women worldwide, and infection with Human Papilloma Virus (HPV) has been identified as the causal agent for this condition. The natural history of cervical cancer is characterized by slow disease progression, rendering the condition, in essence, preventable and even treatable when diagnosed in early stages. Pap smear and the recently introduced prophylactic vaccines are the most prominent prevention options, but despite the availability of these primary and secondary screening tools, the global burden of disease is unfortunately still very high. This book will focus on the clinical aspects of HPV and related disease, highlighting the latest developments in this field.

How to reference

In order to correctly reference this scholarly work, feel free to copy and paste the following:

Descamps Géraldine, Duray Anaëlle, Delvenne Philippe and Saussez Sven (2012). Implications of Human Papillomavirus Infections in the Biology of Head and Neck Cancers, Human Papillomavirus and Related Diseases - From Bench to Bedside - A Clinical Perspective, Dr. Davy Vanden Broeck (Ed.), ISBN: 978-953-307-860-1, InTech, Available from: <http://www.intechopen.com/books/human-papillomavirus-and-related-diseases-from-bench-to-bedside-a-clinical-perspective/implications-of-human-papillomavirus-infections-in-the-biology-of-head-and-neck-cancers>

INTECH
open science | open minds

InTech Europe

University Campus STeP Ri
Slavka Krautzeka 83/A
51000 Rijeka, Croatia
Phone: +385 (51) 770 447
Fax: +385 (51) 686 166
www.intechopen.com

InTech China

Unit 405, Office Block, Hotel Equatorial Shanghai
No.65, Yan An Road (West), Shanghai, 200040, China
中国上海市延安西路65号上海国际贵都大饭店办公楼405单元
Phone: +86-21-62489820
Fax: +86-21-62489821

© 2012 The Author(s). Licensee IntechOpen. This is an open access article distributed under the terms of the [Creative Commons Attribution 3.0 License](https://creativecommons.org/licenses/by/3.0/), which permits unrestricted use, distribution, and reproduction in any medium, provided the original work is properly cited.

IntechOpen

IntechOpen