

We are IntechOpen, the world's leading publisher of Open Access books Built by scientists, for scientists

6,900

Open access books available

186,000

International authors and editors

200M

Downloads

Our authors are among the

154

Countries delivered to

TOP 1%

most cited scientists

12.2%

Contributors from top 500 universities



WEB OF SCIENCE™

Selection of our books indexed in the Book Citation Index
in Web of Science™ Core Collection (BKCI)

Interested in publishing with us?
Contact book.department@intechopen.com

Numbers displayed above are based on latest data collected.
For more information visit www.intechopen.com



Epidemiology of HPV in Head and Neck Cancer

Márcio Campos Oliveira, Maria da Conceição Andrade
and Fabrício dos Santos Menezes
*State University of Feira de Santana - Bahia/State
University of Southwest Bahia
Brazil*

1. Introduction

The Human papillomavirus (HPV) is etiologically related to the development of uterine cervical and other genital cancers (Bosch et al., 1995; Frisch et al., 1999; Melbye & Frisch, 1998), and may be involved also in the etiology of cancers of the upper aerodigestive tract comprising the head and neck (HN) tumors (Franceschi et al., 1996). Some molecular and epidemiological studies support such possibility, once that an increased risk of cancer of the oral cavity, pharynx and larynx subsequent to the occurrence of cancer of the cervix has been found. Moreover, the incidence of some head and neck tumors has been increasing around the world and this high prevalence was attributed to the influence of risk factors, being the human papillomavirus important in this role.

The present chapter aims at investigating epidemiologic features of HPV in head and neck cancer worldwide in order to determine the prevalence and the type distribution of HPV by means of a literature review of published studies.

2. Epidemiology of head and neck cancer

The head and neck cancer comprises malignancies arising in the upper respiratory and digestive tracts and is a relatively frequent type of cancer (Parkin et al., 2002). Thus, the term “head and neck cancer” includes lesions at several anatomic sites, such as the lip, oral cavity, nose and paranasal sinuses, naso-pharynx, oro-pharynx, hypo-pharynx, larynx, oesophagus, salivary glands, as well the soft tissues of the neck and ear. Unfortunately, many papers lack the exact location of the head and neck lesions, making the material poorly characterised. The human papillomavirus (HPV) detection rates reported in the so-called head and neck cancer do not give us a detailed view of the association of HPV in distinct entities, unless detailed anatomic locations are given (Syrjänen, 2005).

The malignant tumors of the head and neck consist of a rather heterogeneous group of neoplasias arising in the epithelium of the upper aerodigestive tract. The most common histologic type is squamous cell carcinomas (SCC), occurring in the oral cavity, pharynx (nasopharynx, oropharynx and hypopharynx) and larynx (Lassen, 2010).

Worldwide annually, over 650,000 patients are diagnosed with HNSCC and some 350,000 die from this disease every year (Ferlay et al., 2010; Syrjänen, 2010). Head and neck cancer is

the sixth most common cancer worldwide (Parkin et al., 2002), and the table 1 summarizes the global incidence and mortality of head and neck cancer per anatomic site.

CANCER	INCIDENCE	MORTALITY
Oral cavity and lip		
Male	170,496	83,109
Female	92,524	44,545
Total	263,020	127,654
Nasopharynx		
Male	57,852	35,984
Female	26,589	15,625
Total	84,441	51,609
Other pharynx		
Male	108,588	76,458
Female	28,034	19,092
Total	136,622	95,550
Larynx		
Male	129,651	70,336
Female	21,026	11,556
Total	150,677	81,892

Table 1. Global incidence and mortality of head and neck cancer per anatomic site (Ferlay et al., 2010). GLOBOCAN (IARC).

The rates of incidence and mortality around the world of head and neck squamous cell carcinomas have been broadly varying, with notably high rates in Southeast Asia and Eastern Europe (Franceschi et al., 1996). In addition, there is a considerable global variation in the incidence of the disease due to geographic differences in ethnicity, culture and socio-economics (Lassen, 2010). Figure 1, obtained through the Globocan project (Ferlay et al., 2010) illustrates the global incidence of head and neck cancer.

Incidence and survival trends have recently been reported in various types of cancer based on 1994–2003 data from cancer registries in a large number of European countries. Oral cavity and pharyngeal cancer were analysed as a group and divergent incidence trends were observed when different countries were compared. For some countries, there was an increase in incidence (England, Wales and Czech Republic), whereas for other countries there was no change (a.o. Switzerland and Denmark) or a decrease (a.o. Finland, France and Germany) (Karim et al., 2008).

Jemal et al. (2008) estimated that 47,500 people were diagnosed with head and neck cancer in the United States, representing approximately 3% of new cancer diagnoses, and an estimated 11,260 people died from this disease, with squamous cell carcinomas in the majority of these cases.

Shiboski et al. (2005) showed, with an analysis of the National Cancer Institute’s Surveillance, Epidemiology and End Results (SEER) data from 1973-2001, an annual increase in the incidence of oral tongue, palatine tonsil, and base-of-tongue cancers, by 2.1%, 3.9%, and 1.7%, respectively, in 20- to 44-year-old white patients, while the incidence of HNSCC at other sites declined.

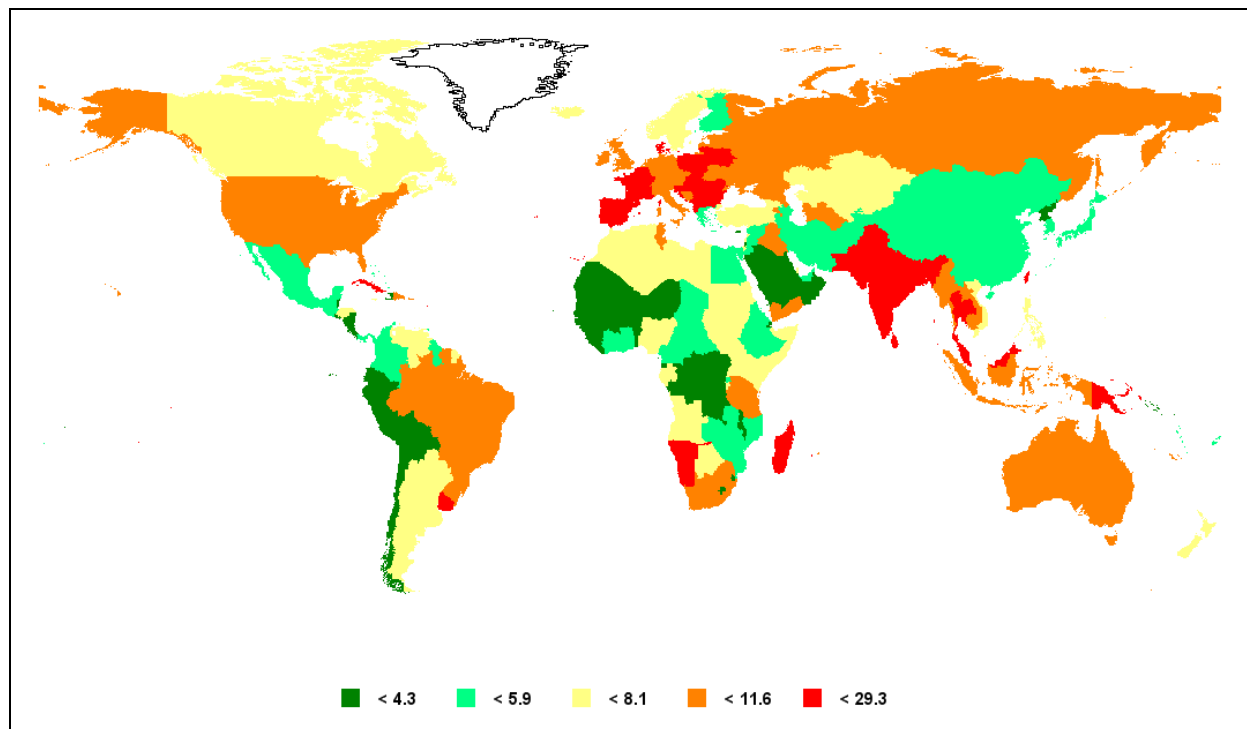


Fig. 1. Global incidence of head and neck tumors (oral cavity and lip, larynx, nasopharynx and other pharynx). Estimated age-standardized incidence rate per 100,000, both sexes, all ages (Ferlay et al., 2010). GLOBOCAN (IARC).

3. Head and neck cancer and HPV

Since the first description of a potential link between HPV infection and head and neck cancer (Syrjänen, 1984), several studies have strongly supported an etiologic role for HPV in cancers arising from specific mucosal sites within the head and neck (D'Souza et al., 2007; Gillison et al., 2000; Herrero et al., 2003). Thus, the detection of HPV genomic deoxyribonucleic acid (DNA) has been found in approximately 25.9% of 5,046 HNSCC cancer specimens from 60 studies using sensitive polymerase chain reaction-based methods (Kreimer et al., 2005).

Head and neck squamous cell carcinoma (HNSCC) typically affects male smokers older than 55 years. Recently, an increase in the incidence of HNSCC in young adults has been recognized, many of them nonsmokers and females. Functional inactivation of p16 is known to be a common event in HNSCC, mainly by either deletion or epigenetic changes. A previous study by this group has shown that p16 deletions in HNSCC are significantly associated with age. The primary objective of this study was to evaluate additional molecular alterations of p16 in HNSCC, specifically in relation to age, site, and human papillomavirus (HPV) status. Patients ranging in age from 22 to 76 years with HNSCC were prospectively identified ($n = 24$). Methylation-specific polymerase chain reaction and immunohistochemistry were used to evaluate p16 gene inactivation and p16 protein expression, respectively. HPV 16 status was determined for each case. Overall, p16 inactivation was a frequent event detected in 46% of cases. Methylation of p16 was more often detected in females than males ($P = .05$). All cases showing p16 methylation were from the anterior tongue, and 75% of them were young patients. The results indicate that p16

methylation is a more common event in those younger than 40 years in contrast to p16 deletions, which are more common in those older than 40 years. Consequently, it appears that specific modes of inactivation of p16 in HNSCC are related to specific patient risk profiles. Interestingly, HPV 16 messenger RNA was detected exclusively in HNSCC from the base of tongue lesions and was only found in males. This differs from the patient profile of HNSCC in the young, which affects the anterior tongue and commonly females, thus, making it highly unlikely that this virus is a primary causative agent of HNSCC in these young adults (O'Regan et al., 2008).

Despite successful efforts to control tobacco and alcohol consumption in the western world, several developed countries report rising oropharyngeal squamous cell carcinoma (OPSCC) incidence figures, specifically in young individuals. Similar to anogenital cancers, a significant proportion of OPSCC (up to 60%) is caused by sexually acquired HPV infection and the rise in OPSCC has been attributed to changing sexual behaviours in the Western World. Accordingly, patients with HPV-positive OPSCC report divergent sexual histories and absence of classical risk factors as tobacco and alcohol exposure compared to patients with HPV-negative OPSCC. The profile of HPV-positive OPSCC differs from HPV-negative OPSCC in several other significant aspects, including a unique molecular biologic tumor characteristics and improved clinical behaviour. Thus, a further increase in HPV-positive OPSCC will impact significantly upon clinical management of OPSCC, unless it is halted by adequate preventive measures aimed at reduction of HPV-associated disease. HPV vaccination has been recently offered to young females in an attempt to reduce HPV-induced cervical cancer and may ultimately result in a decline of OPSCC incidence as well. Until then, close collaboration between otolaryngologists/head and neck surgeons and anogenital/genitourinary specialists is warranted to optimize clinical management of HPV-induced malignancy and improve detection of second primary tumor development (Monsj et al., 2010).

In addition, some researches revealed differences between positive and negative tumors for human papillomavirus being the HPV-positive HNSCC patients approximately 5 years younger than HPV-negative HNSCC patients with equal distribution between the sexes (Haraf et al., 1996; Cruz et al., 1996; Sisk et al., 2002; Strome et al., 2002). For a better understanding, although the epidemiology of HPV in head and neck cancer is the aim in this chapter, a brief explanation on the risk factors in HPV infection is necessary before beginning this approach.

3.1 Risk factors

Over the last two decades, biological agents have been implicated in the etiology of this tumor. Among these agents, human papillomavirus (HPV) is particularly important (Badaracco et al., 2000; Cortezzi et al., 2004; Lo Muzio et al., 2004; Smith et al., 2004; Ibieta et al., 2005). HPV is a DNA virus which encodes two oncoproteins that play an important role in carcinogenesis, i.e., E6 which binds, sequesters and degrades p53, and E7 which binds and degrades pRb; thus facilitating the development of tumors (Badaracco et al., 2000; Cortezzi et al., 2004; Lo Muzio et al., 2004; Remmerbach et al., 2004). Although the relationship between this virus and malignant uterine cervix tumors has been well established in the literature, with more than 90% of these tumors being positive for the virus, the same does not apply to oral carcinogenesis (Miller et al., 2001; Sugiyama et al., 2003). The HPV detection rates at this

anatomical site is very variable, probably due to differences in sample size, in the population studied and in the sensitivity of the techniques used.

The presence of HPV in oral cancers suggests that HPV may play a similar role in transforming the oral epithelia. Persistent infection with high-risk types of HPV plays a critical role in the pathogenesis of cervical cancer, as well as OSCC. HPVs are 8-kb circular DNA viruses that specifically target the basal cells of the epithelial mucosa. The HPV family is comprised of more than 100 genotypes, classified in accordance with the type of epithelial cells infected and the ability to effect cellular transformation. The ability of HPV to transform epithelial cells is divided into high-risk and low-risk types. Low-risk types are associated with benign lesions such as warts, while infections with high-risk types progress to malignant lesions. The HPV genome is comprised of several early (E1 to E7) and late (L1 and L2) genes, as well as a non-coding region, all of which play roles in viral replication, transcription, and carcinogenesis (Ragin et al., 2007).

The primary risk factors for the majority of head and neck cancer worldwide are tobacco and alcohol consumption (Hennessey et al., 2009). In spite of these traditional risk factors, the HPV-positive HNSCC, in particular high-risk HPV type 16, appears more frequently than HPV-negative HNSCC in non-smokers and non-drinkers (Gillison et al., 2000; Hafkamp et al., 2003; Ritchie et al., 2003; Haraf et al., 1996). In case-control researches, the association between tobacco or alcohol use and the development of HPV-positive HNSCC was not found (D'Souza et al., 2007; Gillison et al., 2008). Furthermore, human papillomaviruses have recognized influence in the development of HNSCC in such sites as oropharynx, being considered as an independent risk factor (Schwartz et al., 1998; Gillison et al., 2000; Mork et al., 2001; Wiest et al., 2002; Herrero et al., 2003; Hobbs et al., 2006; Ernster et al., 2007; Andrews et al., 2008). Nevertheless, there is controversy in the literature as to the combination of HPV infection with tobacco and/or alcohol increasing the risk of cancer. Schwartz et al. (1998) and Smith et al. (2004) showed an additive effect between oral HPV infection, tobacco or alcohol use, and oral cancer, but more researches are necessary to evaluate possible interactions among these exposures (Vidal & Gillison, 2008).

The two most prevalent HPV types in oral carcinomas are HPV 16 and 18, far exceeding the detection rate of all the other types (Snijders et al., 1996, 1997; Badaracco et al., 2000; Syrjänen and Syrjänen, 2000; Miller and Johnstone, 2001; Ringströmet al., 2002). Interestingly, the low-risk HPV types 6 and 11 can also be identified in some oral carcinomas, similar to laryngeal carcinomas (Yamaguchi et al., 1991; Fife et al., 1996; Chang et al., 2002). A study by Sisk et al. (2000) showed that the incidence of HPV in younger patients is not significantly different from older patients, suggesting a similar role for HPV in all age groups.

Sexual contact has been associated to cervical cancer through high-risk mucosotropic HPVs (IACR, 1995), but the means by which HPV is transmitted to the upper airways are still unclear (Mannarini et al., 2009). Studies showed a rare oral HPV infection in newborn babies of infected mothers (Watts et al. 1998) and children prior to sexual activity (Koch et al., 1997) being the infections rate increased from the first sexual intercourse (Kellokoski et al., 1992).

Sexual behavior has an association with HPV-positive cancer in head and neck cancer, as observed by D'Souza et al. (2007) in a case-control study of 100 individuals with oropharyngeal cancer and 200 control persons, which found that the development of oropharyngeal cancer is linked with a high lifetime number of vaginal sex partners (≥ 26) and with a high lifetime number of oral sex partners (≥ 6). Gillison et al. (2008) found with a case-control study of 240 individuals with oropharyngeal cancer that the risk of developing an HPV-16-positive HNSCC increased with increasing numbers of oral sex partners. In addition, oral-anal contacts are very strongly associated with the risk of HPV-positive tumor (Rosenquist et al., 2005; Rajkumar et al., 2003).

In a research, Rintala et al. (2006) observed the natural history of oral and genital HPV infection. The results showed that oral sex had no association to oral HPV infection; however, a persistent oral HPV infection of the spouse increased the risk of persistent oral HPV infection 10-fold in the other spouse.

Although the relation of *cannabis sativa* with HPV infections of head and neck sites is unclear (Mannarini et al., 2009), such behavior has been proposed as a reason for increasing numbers of young patients with head and neck cancer (Báez, 2008). Gillison et al. (2008) observed a strong association between *cannabis sativa* use and HPV-16 - positive HNSCC, with a relation of increasing intensity and duration of use.

Among the risk factors for HPV infection in head and neck tumors, there is the immunosuppression, as observed in human immunodeficiency virus (HIV)-positive cases (Adamopoulou et al., 2008). The genetic susceptibility is also an important risk factor to increase the risk of HPV infection, as noted in Fanconi anemia (Park et al., 2010).

3.2 Epidemiology of head and neck cancer with HPV involvement

3.2.1 Premalignant lesions

According to Axell et al. (1996), premalignant lesions, or pre-cancer lesions, of the oral mucosa are epithelial changes more likely to undergo malignant transformation than normal tissue at other mucosal sites. There are two types of clinical premalignant lesions: white lesions (leukoplakia) and reddish lesions (erythroplakia) (Axell et al., 1996). These two terms are purely clinical, and have no association with the underlying histopathology (Syrjänen, 2005).

3.2.1.1 Erythroplakia

Erythroplakia lesions are defined as a bright red patches that cannot be diagnosed as any other lesions (Axell et al., 1996). There are few researches about erythroplakia lesions involving human papillomavirus in head and neck. Nielsen et al. (1996), in a case-control study with 49 patients with oral premalignant lesions, observed 10 cases of oral erythroplakia (1 man and 9 women). The presence of HPV was examined immunohistochemically, through DNA-DNA *in situ* hybridization and through PCR. The investigations revealed that HPV was found in 50.0% of the erythroplakias and 33.3% of erythroleucoplakias. The authors concluded that HPV may be an etiologic co-factor, because 100% of patients who developed oral cancer within 4–12 years were all positive for HPV, with one being HPV-16-positive. This sample had few cases and a critical analysis of these

results is necessary. Further confirmatory data are needed before any conclusions can be drawn on the possible causal role of HPV in this disease (Syrjänen, 2005).

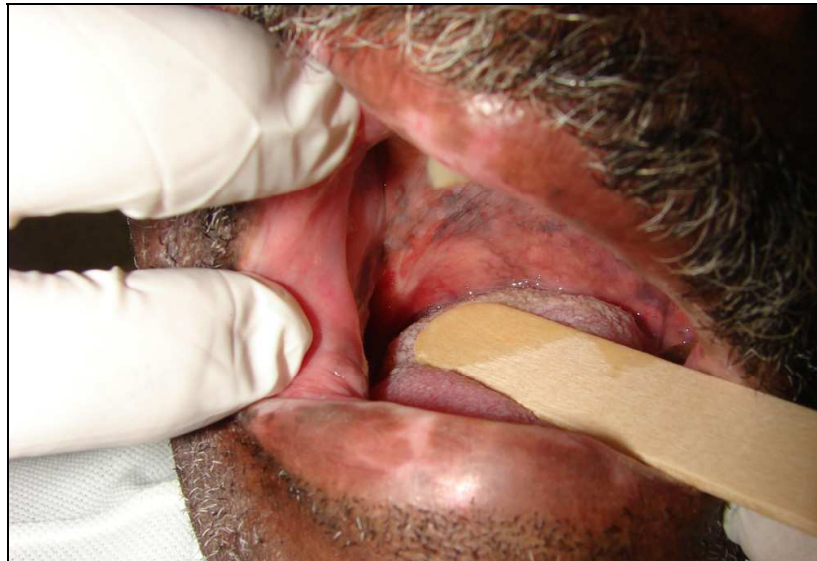

Fig. 2. Erythroplakia in soft palate

3.2.1.2 Leukoplakia

Oral leukoplakia is considered as a premalignant lesion for the development of oral squamous cell carcinoma (OSCC) and several risk factors have been reported to contribute to this step-wise carcinogenesis, including human papillomavirus (HPV) (Yang et al., 2009).

Syrjänen (2005) observed in the literature 964 leukoplakia biopsies, of which 31.1% contained HPV DNA. The HPV types 6/11 were the most prevalent (55.8%), followed by HPV types 16/18 evidenced in 28.2% of the cases (Miller & Johnstone, 2001).

However, Yang et al. (2009) analyzed, using PCR in paraffin sections, 167 patients with oral leukoplakia, including 12 who had malignant transformation from the pre-existing oral leukoplakia. The HPV prevalence in patients with oral leukoplakia was approximately 22.8%, and the most prevalent viral strain was HPV-18 (78.9%). This research also suggested that HPV in oral leukoplakia is not a prognostic indicator of malignant transformation.

Ostwald et al. (2003) examined 72 oral leukoplakia for the presence of HPV 6/11, 16 and 18 DNA through PCR/Southern blot hybridization. The HPV DNA was found in 16/72 (22.2%) leukoplakias, and HPV 16 and 18 DNA were present in 12/72 (16.7%) leukoplakias, being 11.1% the detection rate of HPV 6/11.

In a case-control study, the HPV presence was found in 62.5% of the verrucous leukoplakias, 45.5% of the homogeneous leukoplakias and in 12.5% of the nodular leukoplakias (Nielsen et al., 1996).

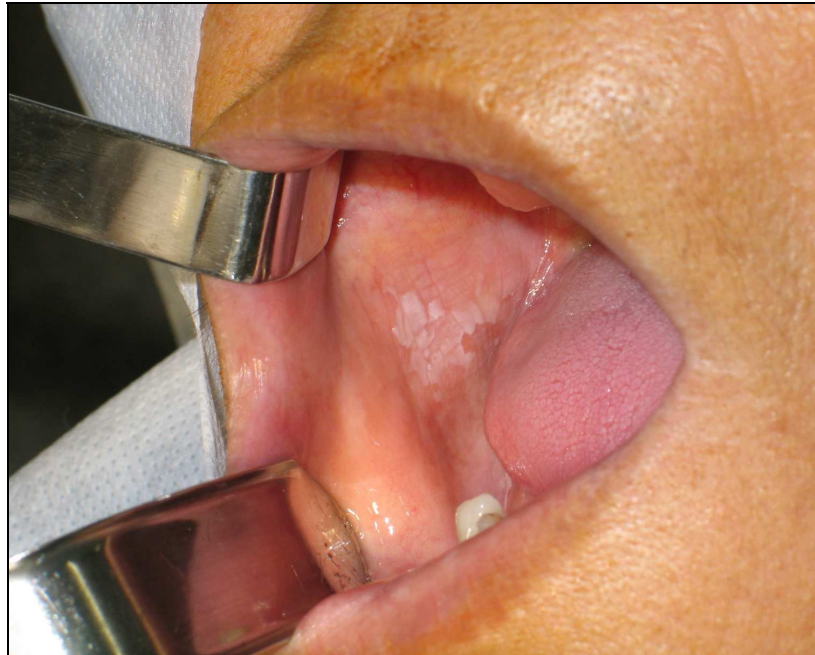

Fig. 3. Leukoplakia in buccal.

3.2.2 Oral cavity and lips

Clinical presentation of oral cancer is highly variable. On clinical examination, oral SCC lesions may be preceded by mucosal alterations with histologically detectable dysplastic changes. However, a malignancy involving a complex genetic process may also occur directly “de novo” without any pre-existing clinically detectable mucosal changes. All head and neck carcinomas tend to be diagnosed late because there is no pain until the late stages. Thus, the overall survival is only 40–50% (Johnson et al., 1991; Berrino et al., 1999; Franceschi et al., 2000).

Studies that support a causal relationship between HPV and OSCC include: a consistent detection of HPV DNA in tumor specimens (Hansson et al., 2005); E6/E7 viral oncogene expression in oral lesions (Braakhuis et al., 2004); the requirement of oral carcinoma cell lines to express E6/E7, to maintain a malignant phenotype; and epidemiological data highlighting HPV infection as a risk factor for the development of OSCC (Ragin et al., 2007). At least three proteins (E5, E6, E7) coded by the high-risk HPVs, which are expressed throughout the viral life cycle, are considered oncogenic, due to their transforming and growth-stimulating properties. These proteins have the ability to deregulate tumor suppressor function by binding to and abrogating the functions of p21 (Tsai & Chen., 2003), p53 (Camus, 2007), and pRb (Huh et al., 2007) proteins, resulting in defects in apoptosis, DNA repair, cell cycle control, and eventually leading to cellular immortalization.

Oliveira et al. (2009) showed that the presence of HPV DNA by PCR was detected in only 29.5% of OSCC cases, 80.8% of which were identified for HPV 18. Although this investigation have detected only 29.5% of HR-HPV DNA in OSCC, it is possible that this virus contribute to the development of some case of this tumor. Furthermore, it seems that the immunohistochemical expression of p53 and bcl-2 and the presence of HPV DNA are independent events in OSCC.

Cancers involving the oral cavity account for 2–3% of all malignancies and the tongue is the subsite with the highest incidence of cancer in the oral cavity (Silverman Jr, 2001). The tongue may be the first site of exposure to viral microorganisms in the aerodigestive tract and oral tongue cancer could be susceptible to HPV exposure, directly or indirectly. The prevalence of HPV in oral tongue cancer is extremely diverse, ranging from 0% to 100% in the literature, and the prevalence of HPV in HNSCC is not uncommon (Bouda et al., 2000, Gillison et al., 2001, Matzow, 1998, Ringström, 2002). The markedly different reports of prevalence of HPV in oral tongue cancer may be due to: mixed samples with the oropharynx; methodological differences for detecting HPV, including less accurate methods; various tumour stages and racial and geographical differences between the studies.

In a study made in the Republic of Korea for Lee et al. (2010), HPV prevalence in early oral tongue cancer was 36% (13/36). In the HPV-positive tumours, 11 cases (84.8%) were infected with HPV-16 and the others were infected with non-16 highrisk type and low-risk type HPV each and multiple infections were not found in these cases.

Sugiyama et al. (2007) examined 66 oral squamous cell carcinomas (OSCCs) for human papillomavirus-16 (HPV-16) infection to evaluate its prognostic significance. Cox regression analysis of 5-year survival demonstrated that patients without nodal metastasis or with intratumoural HPV-16 showed better prognoses compared with each counterpart. In Kaplan-Meier survival analysis, nodal status but not HPV-16 status was statistically significant. The 5-year survival rate of HPV-16 positive patients without nodal metastasis (94%) was extremely high, compared with that of HPV-16 negative patients with nodal metastasis (25%). These results suggest that HPV-16 status as well as nodal status may provide prognostic significance in patients with OSCC.

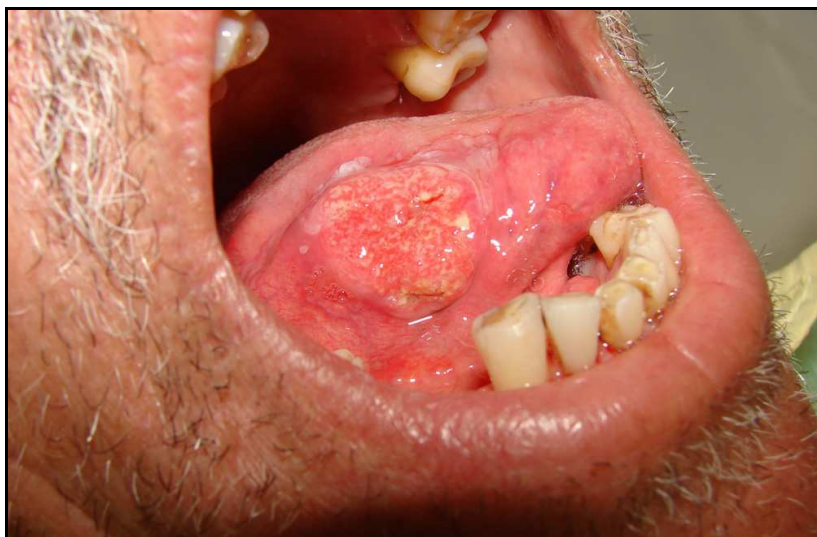

Fig. 4. Oral cancer in tongue.

3.2.3 Pharynx

3.2.3.1 Oropharynx

The oropharynx is the predominant site where HPV-induced squamous cell carcinomas develop (Braakhuis et al., 2009). This region of interest for HPV infection comprises

predominantly the vallecula, walls of the oropharynx, and in particular the tonsils (Kreimer et al., 2005).

In some countries, such as the United States and the Netherlands, the incidence of oropharyngeal cancer is increasing (Braakhuis et al., 2009; Ernster et al., 2007), and it represents an emerging public health problem (St Guily et al., 2011). One potential way to explain this increase would be to demonstrate an increasing prevalence of oncogenic HPV in palatine or lingual tonsil tissue over time (Ernster et al., 2009).

Studies found a strong association between oropharynx cancers and HPV infection, with detection rates of 50% or more (Hammarstead et al., 2006; Klusmann et al., 2001; Venuti et al., 2004; Paz et al., 1997). The biological explanation for why the prevalence of HPV is higher in tumors from the oropharynx compared with other sites in the head and neck remains unclear (Kreimer et al., 2005). However, it is possibly explained because of “specific virus-tissue interactions” (Kreimer et al., 2005) that allow a facilitated viral access to basal mucosal cells in the tonsillar crypts and an apparent predilection for this anatomic site for transformation by HPVs, analogous to the cervical transformation zone (Vidal & Gillison, 2008).

In a systematic review of HNSCC biopsies that employed PCR-based methods to detect and genotype HPV, Kreimer et al. (2005) observed a HPV prevalence significantly higher in oropharyngeal squamous cell carcinomas (35.6% of 969) than in oral squamous cell carcinomas (23.5% of 2,642) or laryngeal squamous cell carcinomas (24.0% of 1,435). Furthermore, the human papillomavirus type 16 was found in a larger majority of HPV-positive oropharyngeal squamous cell carcinomas (86.7%). However, the HPV18 infection was rare in HPV-positive oropharyngeal SCCs (2.8%) compared with other head and neck sites. Aside from HPV16 and HPV18, other oncogenic HPVs were rarely detected in oropharynx. This research also found geographic differences in HPV-positivity of oropharyngeal carcinomas possibly linked to differences in HPV exposure or variation in host susceptibility factors among countries.

From a literature review worldwide, Syrjänen (2004) identified 422 tonsillar SCCs and 51% of these tumors contained HPV DNA. The HPV 16 was the most frequent type, identified in 84% of the 216 HPV DNA-positive tumors, but also the low-risk HPV types 6/11 DNA have been detected in 3% of the HPV-positive carcinomas, and the following HPV types have been detected in occasional tonsillar carcinomas: HPV 5, 12, 31, 35, and 59.

In a research developed in France, the overall HPV prevalence was 57% in tonsil cancers, and was significantly higher in female than in male cases (28/35 versus 78/150 in tonsil cases). Among HPV positive samples, HPV 16 was found in 89% of tonsil cases, and all other HPV types had prevalence below 5% (St Guily et al., 2011).

In Norway, a study with 137 patients about the prevalence of HPV with tonsillar carcinomas observed HPV infection in 52% of the tumors being the HPV-16 the most frequent subtype (87%). Furthermore, the study showed that the survival of the HPV-positive group was significantly better in males (Hannisdal et al., 2010).

In Stockholm, 98 pretreatment biopsies of tonsillar squamous cell carcinoma were analyzed. The HPV DNA was present in 83 cases (85%) of the tonsillar SCC biopsies and 77 of these were HPV-16 positive. HPV-16 E6 and E7 RNA were found in 98% of 52 HPV-16 positive cases analyzed. In addition, the incidence rate of HPV-positive tumors almost doubled each decade between 1970 and 2007, in parallel with a decline of HPV-negative tumors. The

study suggested that the incidence of HPV-positive cancers is still increasing in Stockholm, and also an epidemic of a virus-induced carcinoma, with soon practically all tonsillar SCC being HPV positive, as in cervical cancer (Nasman et al., 2009).

A study developed in the United States in the state of Colorado through PCR observed an increase of oropharyngeal cancer in males from 2.54 per 100,000 to 3.47 or 36.6%. Of the 72 cases, 50 (69%) were positive for HPV subtype 16. The ratio of HPV-positive to HPV-negative cases prior to 1995 was 0.72 (8:11), but it was 3.81 (42:11) afterwards. The survival was positively affected by HPV status, being 83% in the HPV-positive patients and 15% in the HPV-negative group (Ernster et al., 2007).

A research in Puerto Rico evaluated through PCR 118 head and neck squamous cell carcinoma, and 16 cases were found in the oropharynx. Furthermore, in 52 patients, HPV16 was detected, being 19% or 10 cases in oropharynx that had a slightly higher incidence of HPV16 DNA (Báez et al., 2004).

In Australia, a study involving 86 tonsil cancers analyzed the HPV status through PCR and immunohistochemistry. The HPV status could be established in 67 of the tumors, and 31 (46%) of these were HPV-positive, predominantly (28/31) for HPV16 (Li et al., 2003).

Overall, the percentage of HPV-positive oropharyngeal carcinomas varies among different reports, which is not only explained by the varying inclusion of tumors from different anatomic sublocations among studies (van Monsjou et al., 2010). Therefore, further standardized seroepidemiologic studies are important to answer some questions.

3.2.3.2 Nasopharynx

Nasopharyngeal carcinoma (NPC) is a tumor that arises in the epithelium surface of the posterior nasopharynx and shows a peculiar geographic and ethnic distribution (Parkin et al., 1997). Despite the strong association with Epstein-Barr virus (EBV), the human papillomavirus (HPV) has also been linked as a cofactor for the development of nasopharyngeal carcinoma (Punwaney et al., 1999).

Although NPC is rare in most populations, it is a leading form of cancer in a few well-defined populations, including natives of southern China, Southeast Asia, the Arctic, and the Middle East/North Africa. Thus, the distinctive racial/ethnic and geographic distribution of NPC worldwide suggests that both environmental factors and genetic traits contribute to its development (Chang & Adami, 2006).

In North Africa, 70 Moroccan patients with NPC were screened for EBV and HPV. The EBV was detected in all NPC tumors, whereas HPV DNA was revealed in 34% of cases (24/70). Molecular analysis showed that 20.8% (5/24) were infected with HPV31, and the remaining were infected with other oncogenic types (i.e., HPV59, 16, 18, 33, 35 and 45). The mean age of HPV-positive patients was 37.3, whereas the mean age of HPV-negative cases was 43.0 years old. Nonetheless, the statistical analysis showed that there's no association between sex or age and HPV infection. The study revealed that EBV is commonly associated with NPC in Moroccan patients and that NPC tumors from Moroccan patients harbor high-risk HPV genotypes (Laantri et al., 2011).

In Iran, a retrospective study analyzed the prevalence of EBV and HPV infection subtypes 6/11 and 16/18 in 20 patients with NPC. Thus, 16 cases were classified as undifferentiated carcinoma (WHO type III) and 4 as non-keratinizing SCC (WHO type II). About the HPV

infection, two of 20 NPC (10%) contained HPV 6/11 sequences and two of 20 NPC (10%) contained HPV 16/18 sequences, and combined EBV and HPV infection was detected in 3 of the 20 (15%) patients (Mirzamani et al., 2006).

A research involving North Americans with NPC showed that five (5.6%) of 89 cases had nasopharyngeal carcinoma, all with non-keratinizing histology. Of the 5 patients with NPC, 4 (80%) were HPV-positive for subtypes 16 (1 patient), 18 (2 patients), and 59 (1 patient). All 4 cases were white North Americans with age ranging between 58-76 years old. Therefore, it suggests that HPV may be the etiologic factor in some EBV-negative, nonkeratinizing NPCs among whites (Maxwell et al., 2010).

An investigation developed by Punwaney et al. (1999) with 30 patients (6 Caucasian Americans, 1 Chinese American, 14 and 9 patients from Korea and China, respectively) found in 7 (23%) HPV sequences. The human papillomavirus appears to be uncommonly (17%) associated with NPC in patients from the Far East and was detected more often (50%) in NPC from American Caucasian patients. There appears to be a broad profile in the relationship between HPV, EBV, and NPC histologic subtype. However, strong conclusions are not possible because of a low number of American Caucasian cases studied.

In Hong Kong Chinese people, 16 of nasopharyngeal were examined for the presence of HPV 16 and 18 using PCR on paraffin-wax-embedded biopsy specimens. However, no DNA of either human papillomavirus subtype was detected. The number of cases in this series was small, and further studies are warranted using fresh biopsy material and including other viral subtypes (Dickens et al., 1992).

Singhi et al. (2011) analyzed 45 carcinomas of the nasopharynx through immunohistochemistry and *in situ* hybridization for EBV and HPV. In this series, only 4 cases (9%) were HPV-positive being all these specimens EBV-negative. The HPV was more likely to be detected in carcinomas from white patients than non-white patients (16% vs 0%), and in 3 HPV-positive patients, there was the finding of an extension into the oropharynx.

Further studies are still required to associate the coexistence of EBV and HPV in the development of nasopharyngeal carcinomas (Mirzamani et al., 2006; Tyan et al., 1993). Moreover, epidemiology studies would also be of interest to determine whether the incidence of HPV-positive NPC is increasing in concert with the increased frequency of HPV-positive oropharyngeal cancers (Maxwell et al., 2010).

3.2.3.3 Larynx and hypopharynx

The larynx is among the most significant anatomic sites in terms of HPV involvement, exceeded in clinical importance perhaps only by the genital tract and skin infections (Syrjänen, 2005). However, the HPV role in anatomic sites in the upper aerodigestive tract such as the larynx is less clear (Herrero, 2003), and data on HPV involvement in preneoplastic and neoplastic lesions of the larynx and other locations are limited and conflicting (Gorgoulis et al., 1999).

The hypopharynx comprises the postcricoid region, hypopharyngeal region of the aryepiglottic fold, and posterior wall of the hypopharynx (Kreimer et al., 2005). Unfortunately, there are few researches involving only hypopharynx in association with HPV presence in the literature. In this chapter, the hypopharynx and larynx were combined because of few reports observed in hypopharynx with HPV involvement and for the reason that some manuscripts aggregated these anatomical sites. Therefore, this group of diseases

was called “larynx cancers” or laryngeal squamous cell carcinomas (SCCs) in accordance to Kreimer et al. (2005).

3.2.3.4 Larynx cancers

Most malignancies in the larynx are squamous cell carcinomas (>90%). Similar to oral and pharyngeal cancers, multiple case series have reported prevalences of HPV DNA in laryngeal cancer (Herrero, 2003). Although the association and clinical significance of human papillomavirus (HPV) infections with a subset of head and neck cancers, particularly for oropharyngeal carcinoma, has recently been well documented, the involvement of HPV in laryngeal cancer has been inadequately evaluated (Torrente et al., 2011).

In a systematic review worldwide comprising 1,435 cases (1,222 of larynx and 213 of hypopharynx cancers), the overall HPV prevalence was of 24% in laryngeal SCCs. The HPV was detected in 21.3%, 13.8%, and 38.2% of SCCs of the larynx from Europe, North America, and Asia, respectively. In addition, the HPV16 was the most common type detected in samples accounted for 69.2% of all HPV-positive laryngeal SCCs, followed by HPV18 detected in 3.9% of cases (Kreimer et al., 2005).

A study of Syrjänen & Syrjänen (2000) involving 1,252 cases had a detection rate of 25% for HPV DNA in 313 samples. Furthermore, the HPV 16 was the single most common HPV type detected in these lesions, with other high-risk types being occasionally reported.

In the United States, 21 hypopharynx cases and 86 larynx cases were evaluated through PCR, Southern blot hybridization and *in situ* hybridization. Thus, the HPV positivity was identified in 10% of hypopharynx samples and 19% of larynx samples (Gillison et al., 2000).

In Poland, the HPV 16 DNA presence was analyzed using PCR technique in 72 samples of laryngeal carcinoma. The human papillomavirus was detected in 26 (36.1%) of the 72 patients. However, there was no statistically significant correlation HPV positivity and clinical-pathological features of the group analyzed (Morshed et al., 2005).

In France, the human papillomavirus was detected in 5% in larynx squamous cell carcinoma, and no patient analyzed had p53 gene mutations in cancer cells (Fouret et al., 1997).

In Belgium, the laryngeal squamous cell carcinomas were evaluated for the presence of HPV DNA through E6/E7 type-specific PCR, and 75% of patients (44 out of 59) presented high-risk HPV types with a high prevalence of HPV-16 (Duray et al., 2011).

In the Puerto Rican population, of 118 head and neck squamous cell carcinoma evaluated through PCR, the larynx was the most common site affected (52 out of 118). Separately, the HPV 16 detected in larynx was 85.7% and 55.6% in hypopharynx. When aggregated, the hypopharynx and larynx showed 56% (29 cases) of all HPV16 DNA detected in the study (Báez et al., 2004).

In Northeast China, 102 patients with laryngeal squamous cell carcinomas were examined for HPV DNA. The HPV DNA was found in 60 cases (58.8%), being the HPV-16, -18, -6, -11, and -33 DNA detected in 30 cases, 22 cases, 25 cases, 2 cases and 1 case, respectively. Moreover, co-infection either with HPV-6 and -16 or with HPV-6 and -18 was detected in 20 cases (33.3% of HPV DNA-positive cases) (Ma et al., 1998).

A retrospective study examining early larynx malignancies from 38 patients detected a rate of 16% in HPV DNA, and the HPV types 16, 26, 31, 39, and 52 were identified. Although the

HPV-26 is related to uterine cervical cancer, the research found the first evidence of this subtype in a laryngeal carcinoma (Baumann et al., 2009).

Although several researches support the HPV presence in hypopharynx/larynx cancer with prevalences ranging of 13.8% to 38.2% (Kreimer et al., 2005), Ribeiro et al. (2011) observed in 78 fresh tissue biopsies a low prevalence of 3.8% in cases from Central Europe and Latin America. These wide variations in HPV prevalence which are reported may depend on the HPV diagnostic methodologies, especially in earlier studies (St Guily et al., 2010). Researches for the development of accurate, specific, and confirmatory methods for the detections of HPV in laryngeal squamous cell carcinoma are necessary, being standardized seroepidemiologic studies important to answer some questions.

Table 2. summarizes some researches of head and neck lesions with HPV involvement.

	AUTHORS (YEAR)	GEOGRAPHIC LOCATION	METHOD*	HPV TYPE**	POSITIVE/ CASES	%
ORAL CAVITY AND LIP	Kreimer et al. (2005)	Australia, Canada, China, Cuba, Finland, France, Germany, India, Ireland, Italy, Japan, Korea, Netherlands, Norway, Poland, Spain, Slovenia, Sudan, Sweden, Switzerland, Taiwan, United Kingdom, United States, Venezuela	PCR-based HPV testing methods	HPV-16	423/ 2,642	16%
	Oliveira et al. (2009)	Brazil	PCR	HPV-18	21/88	23,9%
	Lee et al. (2010)	Republic of Korea	HPV genotyping chip and RT-PCR	HPV-16	11/36	30,6%
OROPHARYNX	Kreimer et al. (2005)	Australia, Canada, Cuba, Finland, France, Germany, India, Ireland, Italy, Japan, Netherlands, Norway, Poland, Spain, Slovenia, Sudan, Sweden, Switzerland, United States	PCR-based HPV testing methods	HPV-16	299/969	30,9%
	St Guily et al. (2011)	France	INNO-LiPA HPV Genotypingextra test	HPV-16	94/185	50,8%
	Nasman et al. (2009)	Stockholm	PCR	HPV-16	77/98	78,6%
	Ernster et al. (2007)	United States	PCR	HPV-16	50/72	69,4%
	Li et al. (2003)	Australia	PCR and IHC	HPV-16	28/67	41,8%

	AUTHORS (YEAR)	GEOGRAPHIC LOCATION	METHOD*	HPV TYPE**	POSITIVE/ CASES	%
	Báez et al. (2004)	Puerto Rico	PCR	HPV-16	10/16	62,5%
NASOPHARYNX	Laantri et al. (2011)	Morocco	PCR	HPV-31	5/70	7,1%
	Mirzamani et al. (2006)	Iran	ISH	HPV-6/11; HPV-16/18	2/20; 2/20	10%; 10%
	Dickens et al. (1992)	Hong Kong	PCR	none	0/16	0%
LARYNX AND HYPOPHARYNX	Kreimer et al. (2005)	Canada, Cuba, Denmark, Finland, France, Germany, Greece, India, Italy, Japan, Netherlands, Norway, Spain, Slovenia, Sweden, Switzerland, United Kingdom, United States	PCR-based HPV testing methods	HPV-16	238/1,435	16,6%
	Morshed et al. (2005)	Poland	PCR	HPV-16	26/72	36.1%
	Ma et al. (1998)	Northeast China	PCR, SB, and IHC	HPV-16	30/102	29,4%
ERYTHROPLAKIA	D'Costa et al. (1998), Giovannelli et al. (2002), Syrjänen & Syrjänen (2000)	India, Italy, ???	PCR, ???	HPV-16	9/32	28,1%
LEUKOPLAKIA	Ostwald et al. (2003)	Germany	PCR, SB	HPV-16/18	12/72	16.7%

*Abbreviations: PCR = Polymerase chain reaction, RT-PCR = Real Time PCR, IHC = Immunohistochemistry, SB = Southern Blotting, ISH = *In situ* hybridization.

**Most common HPV types found in studies.

Table 2. Prevalence of HPV in lesions of the head and neck.

4. Conclusion

The present review showed heterogeneous prevalence between different anatomical sites in HNSCC with HPV involvement around the world. These results must be interpreted with caution because most researches conducted for data on HPV and HNSCC have been, with rare exception, small (<100 cases). The methods employed for case identification have often been unclear, and it is difficult to differentiate studies that enrolled consecutive patients from studies that used alternative inclusion criteria. Moreover, poor quality of some biopsy specimens may also have affected the prevalence estimates with some false-negative findings (Kreimer et al., 2005).

Further standardized seroepidemiologic studies are important to answer some questions, among them the impact of HPV vaccination on HNSCC. Thus, epidemiology studies are interesting to determine whether the incidence of HPV-positive is increasing, mainly in sites frequently affected such as oropharynx, in particular the tonsils.

In conclusion, with a clear understanding of the prevalence of oncogenic HPV in specific populations, an estimate of the progression rate from HPV infection to HPV-positive carcinoma may be derived. This effort could help guide screening and prevention strategies in the future (Ernster et al., 2009), such as the development of screening programs, new therapeutic approaches and specific methods of prevention, especially in high incidence areas (Laantri et al., 2011).

5. Acknowledgements

The authors are grateful to Mr. Abílio Borghi for the critical reading of the chapter.

6. References

- Adamopoulou M, Vairaktaris E, Panis V, Nkenke E, Neukam FW & Yapijakis C (2008). HPV detection rate in saliva may depend on the immune system efficiency. *In Vivo*, Vol. 22, pp. 599-602
- Andrews E, Seaman WT & Webster-Cyriaque J (2009). Oropharyngeal carcinoma in non-smokers and non-drinkers: a role for HPV. *Oral Oncol*, Vol. 45, pp. 486-491
- Badaracco G, Venuti A, Bartolazzi A, Morillo R, Marzetti F, Marcante ML. (2000), Overexpression of p53 and bcl-2 proteins and the presence of HPV infection are independent events in head and neck cancer. *J Oral Pathol Med*. Vol. 29, pp. 173-179
- Báez A, Almodovar JL, Cantor A, Celestin F, Cruz-Cruz L, Fonseca S et al (2004). High frequency of HPV16-associated head and neck squamous cell carcinoma in the Puerto Rican population. *Head Neck*, Vol. 26, pp. 778-784
- Báez A (2008). Genetic and environmental factors in head and neck cancer genesis. *J Environ Sci Health C Environ Carcinog Ecotoxicol Rev*, Vol. 26, pp. 174-200
- Baumann JL, Cohen S, Evjen AN, Law JH, Vadivelu S, Attia A et al (2009). Human papillomavirus in early laryngeal carcinoma. *Laryngoscope*, Vol. 119, pp. 1531-1537
- Berrino F, Capocaccia R, Esteve J, et al., Survival of cancer patients in Europe: the EURO CARE-2 study. IARC Scientific Publication No. 151. Lyon, France; 1999

- Bosch FX, Manos MM, Munoz N, Sherman M, Jansen AM, Peto J, et al (1995). Prevalence of human papillomavirus in cervical cancer: a worldwide perspective. International biological study on cervical cancer (IBSCC) Study Group. *J Natl Cancer Inst*, Vol. 87, pp. 796–802
- Bouda M, Gorgoulis VG, Kastrinakis NG, Giannoudis A, Tsoli E, Danassi-Afentaki D, et al. (2000) “High risk” HPV types are frequently detected in potentially malignant and malignant oral lesion, but not in normal oral mucosa. *ModPathol*. Vol. 13, pp.644–653
- Braakhuis BJ, Snijders PJ, Keune WJ. (2004). Genetic patterns in head and neck cancers that contain or lack transcriptionally active human papillomavirus. *J Natl Cancer Inst* . Vol. 96, pp. 998–1006
- Braakhuis BJ, Visser O & Leemans CR (2009). Oral and oropharyngeal cancer in The Netherlands between 1989 and 2006: Increasing incidence, but not in young adults. *Oral Oncol*, Vol. 45, pp. e85-89
- Camus S, Menendez S, Cheok CF, Stevenson LF (2007). Ubiquitin-independent degradation of p53 mediated by high-risk human papillomavirus protein E6. *Oncogene*. Vol. 26, pp. 4059–470
- Chang ET & Adami HO (2006). The enigmatic epidemiology of nasopharyngeal carcinoma. *Cancer Epidemiol Biomarkers Prev*, Vol. 15, pp. 1765-1777
- Chung CH & Gillison ML (2009). Human papillomavirus in head and neck cancer: its role in pathogenesis and clinical implications. *Clin Cancer Res. [Review]*, Vol. 15, No. 22, pp. 6758-62
- Cortezzi SS, Provazzi PJ, Sobrinho JS, Mann-Prado JC, Reis PMP, Freitas SEN, et al. (2004), Analysis of human papillomavirus prevalence and TP53 polymorphism in head and neck squamous cell carcinomas. *Cancer Genet Cytogenet*. Vol.150, pp:44–49
- Cruz IB, Snijders PJ, Steenbergen RD, Meijer CJ, Snow GB, Walboomers JM, et al (1996). Age-dependence of human papillomavirus DNA presence in oral squamous cell carcinomas. *Eur J Cancer B Oral Oncol*, Vol. 32, No. 1, pp. 55–62
- D'Costa J, Saranath D, Dedhia P, Sanghvi V, Mehta AR (1998). Detection of HPV-16 genome in human oral cancers and potentially malignant lesions from India. *Oral Onco*, Vol. 34, pp. 413-420
- D'Souza G, Kreimer AR, Viscidi R, et al (2007). Case-control study of human papillomavirus and oropharyngeal cancer. *N Engl J Med*, Vol. 356 , pp. 1944–56
- Dickens P, Srivastava G & Liu YT (1992). Human papillomavirus 16/18 and nasopharyngeal carcinoma. *J Clin Pathol*, Vol. 45, pp. 81-82
- Duray A, Descamps G, Arafa M, Decaestecker C, Remmelink M, Sirtaine N et al (2011). High incidence of high-risk HPV in benign and malignant lesions of the larynx. *Int J Oncol*, Vol. 39, pp. 51-59
- Ernster JA, Sciutto CG, O'Brien MM, Finch JL, Robinson LJ, Willson T, et al. (2007). Rising incidence of oropharyngeal cancer and the role of oncogenic human papilloma virus. *Laryngoscope*, Vol. 117, pp. 2115-2128
- Ernster JA, Sciutto CG, O'Brien MM, Robinson LJ & Willson T (2009). Prevalence of oncogenic human papillomavirus 16 and 18 in the palatine tonsils of the general adult population. *Arch Otolaryngol Head Neck Surg*, Vol. 135, pp. 554-557

- Ferlay J, Shin HR, Bray F, Forman D, Mathers C & Parkin DM. (2010). Cancer Incidence and Mortality Worldwide: IARC CancerBase No. 10 [Internet], In: *GLOBOCAN 2008 v1.2*, 16/07/2011, Available from: < <http://globocan.iarc.fr> >
- Fouret P, Monceaux G, Temam S, Lacourreye L & St Guily JL (1997). Human papillomavirus in head and neck squamous cell carcinomas in nonsmokers. *Arch Otolaryngol Head Neck Surg*, Vol. 123, pp. 513-516
- Franceschi S, Bidoli E, Herrero R. (2000). Comparison of cancers of the oral cavity and pharynx worldwide: etiological clues. *Oral Oncol*. Vol. 36, pp.106-15
- Franceschi S, Munoz N, Bosch XF, Snijders PJ & Walboomers JM (1996). Human papillomavirus and cancers of the upper aerodigestive tract: a review of epidemiological and experimental evidence. *Cancer Epidemiol Biomarkers Prev*, Vol. 5, pp. 567 – 75
- Frisch M, Fenger C, van den Brule AJC, Sørensen P, Meijer CJLM, Walboomers JMM, et al (1999). Variants of squamous cell carcinoma of the anal canal and perianal skin and their relation to human papillomaviruses. *Cancer Res*, Vol. 59, pp. 753-7
- Frisch M, Goodman MT. (2000). Human papillomavirus-associated carcinomas in Hawaii and the mainland. *Cancer*. Vol. 88, pp. 1464-1469
- Gillison ML, D'Souza G, Westra W, Sugar E, Xiao W, Begum S et al (2008). Distinct risk factor profiles for human papillomavirus type 16-positive and human papillomavirus type 16-negative head and neck cancers. *J Natl Cancer Inst*, Vol. 100, pp. 407-420
- Gillison ML, Koch WM, Capone RB, Spafford M, Westra WH, Wu L et al (2000). Evidence for a causal association between human papillomavirus and a subset of head and neck cancers. *J Natl Cancer Inst*, Vol. 92, pp. 709-720
- Gillison ML, Shah KV (2001). Human papillomavirus-associated head and neck squamous cell carcinoma: mounting evidence for an etiologic role for human papillomavirus in a subset of head and neck cancers. *Curr Opin Oncol*. Vol. 13, pp.183-188
- Giovannelli L, Campisi G, Lama A, Giambalvo O, Osborn J, Margiotta V, et al. (2002), Human papillomavirus DNA in oral mucosal lesions. *J Infect Dis*. Vol. 185, pp. 833-836
- Gorgoulis VG, Zacharatos P, Kotsinas A, Kyroudi A, Rassidakis AN, Ikononopoulos JA et al (1999). Human papilloma virus (HPV) is possibly involved in laryngeal but not in lung carcinogenesis. *Hum Pathol*, Vol. 30, pp. 274-283
- Hafkamp HC, Speel EJ, Haesevoets A, Bot FJ, Dinjens WN, Ramaekers FC, et al (2003). A subset of head and neck squamous cell carcinomas exhibits integration of HPV 16/18 DNA and overexpression of p16INK4A and p53 in the absence of mutations in p53 exons 5-8. *Int J Cancer*, Vol. 107, No. 3, pp. 394-400
- Hammarstedt L, Lindquist D, Dahlstrand H, Romanitan M, Dahlgren LO, Joneberg J et al (2006). Human papillomavirus as a risk factor for the increase in incidence of tonsillar cancer. *Int J Cancer*, Vol. 119, pp. 2620-2623
- Hannisdal K, Schjolberg A, De Angelis PM, Boysen M & Clausen OP (2010). Human papillomavirus (HPV)-positive tonsillar carcinomas are frequent and have a favourable prognosis in males in Norway. *Acta Otolaryngol*, Vol. 130, pp. 293-299

- Hansson BG, Rosenquist K, Antonsson A, Wennerberg J. (2005). Strong association between infection with human papillomavirus and oral and oropharyngeal squamous cell carcinoma: a population-based case-control study in southern Sweden. *Acta Otolaryngol.* Vol. 25, pp. 1337-1344
- Haraf DJ, Nodzenski E, Brachman D, Mick R, Montag A, Graves D, et al (1996). Human papilloma virus and p53 in head and neck cancer: clinical correlates and survival. *Clin Cancer Res*, Vol. 2, No. 4, pp. 755-62
- Hennessey PT, Westra WH & Califano JA (2009). Human papillomavirus and head and neck squamous cell carcinoma: recent evidence and clinical implications. *J Dent Res. [Research Support, N.I.H., Extramural Review]*, Vol. 88, No. 4, pp. 300-6
- Herrero R, Castellsague X, Pawlita M, Lissowska J, Kee F, Balaram P et al (2003). Human papillomavirus and oral cancer: the International Agency for Research on cancer multicenter study. *J Natl Cancer Inst*, Vol. 95, pp. 1772-83
- Herrero R (2003). Chapter 7: Human papillomavirus and cancer of the upper aerodigestive tract. *J Natl Cancer Inst Monogr*, pp. 47-51
- Hobbs CG, Sterne JA, Bailey M, Heyderman RS, Birchall MA & Thomas SJ (2006). Human papillomavirus and head and neck cancer: a systematic review and meta-analysis. *Clin Otolaryngol*, Vol. 31, pp. 259-266
- Huh K, Zhou X, Hayakawa H, Cho JY, Libermann TA. (2007). The Human Papillomavirus type 16 E7 oncoprotein associates with the cullin 2 ubiquitin ligase complex, which contributes to degradation of the retinoblastoma tumor suppressor. *J Virol*, Vol. 81, pp. 9737-47
- IARC Working Group on the Evaluation of Carcinogenic Risks to Humans (1995). Human papillomaviruses. *IARC Monogr Eval Carcinog Risks Hum*, Vol. 64, pp. 1-378
- Ibieta BR, Lizano M, Frias-Mendivil M, Barrera JL, Carrillo A, Ruiz-Godoy LM, et al. Human papilloma virus in oral squamous cell carcinoma in a Mexican population (2005). *Oral Surg Oral Med Oral Pathol Oral Radiol Endod.*, Vol.99, pp. 311-5
- Jemal A, Siegel R, Ward E, Murray T, Xu J & Thun MJ (2007). Cancer statistics. *CA Cancer J Clin*, Vol. 57, No. 1, pp. 43-66
- Jemal A, Siegel R, Ward E, Hao Y, Xu J, Murray T, et al. (2008). Cancer statistics, 2008. *CA Cancer J Clin*, Vol. 58, pp. 71-96
- Johnson NW, et al. (1991). Orofacial neoplasms: global epidemiology, risk factors and recommendations for research. *Int Dent J*. Vol. 41, pp. 365-375
- Karim-Kos HE, de Vries E, Soerjomataram I, Lemmens V, Siesling S & Coebergh JW (2008). Recent trends of cancer in Europe: a combined approach of incidence, survival and mortality for 17 cancer sites since the 1990s. *Eur J Cancer*, Vol. 44, No. 10, pp. 1345-89
- Kellokoski JK, Syrjänen SM, Chang F, Yliskoski M & Syrjänen KJ (1992). Southern blot hybridization and PCR detection of oral human papillomavirus (HPV) infections in women with genital HPV infections. *J Oral Pathol Med*, Vol. 21, pp. 459-64
- Kim SH, Koo BS, Kang S, Park K, Kim H, Lee KR, Lee MJ, Kim JM, Choi EC, Cho NH. (2007), HPV. Integration begins in the tonsillar crypt and leads to the alteration of p16, EGFR and c-myc during tumor formation. *Int J Cancer*. Vol. 120, pp. 1418-1425

- Klussmann JP, Weissenborn SJ, Wieland U, Dries V, Kolligs J, Jungehuelsing M et al (2001). Prevalence, distribution, and viral load of human papillomavirus 16 DNA in tonsillar carcinomas. *Cancer*, Vol. 92, pp. 2875-2884
- Koch A, Hansen SV, Nielsen NM, Palefsky J & Melbye M (1997). HPV detection in children prior to sexual debut. *Int J Cancer*, Vol. 73, pp. 621-4
- Kreimer AR, Clifford GM, Boyle P, et al (2005). Human papillomavirus types in head and neck squamous cell carcinomas worldwide: a systematic review. *Cancer Epidemiol Biomarkers Prev*, Vol. 14, pp. 467-75
- Laantri N, Attaleb M, Kandil M, Naji F, Mouttaki T, Dardari R et al (2011). Human papillomavirus detection in moroccan patients with nasopharyngeal carcinoma. *Infect Agent Cancer*, Vol. 6, pp. 3
- Lassen P (2010). The role of Human papillomavirus in head and neck cancer and the impact on radiotherapy outcome. *Radiother Oncol. [Research Support, Non-U.S. Gov't Review]*, Vol. 95, No. 3, pp. 371-80
- Lee S Y, Cho N H, Choi E C, Baek S J, Kim W S, Shin D. H. et al. (2010). Relevance of human papilloma virus (HPV) infection to carcinogenesis of oral tongue cancer. *Int. J. Oral Maxillofac. Surg.*, Vol. 39, pp. 678-683
- Li W, Thompson CH, O'Brien CJ, McNeil EB, Scolyer RA, Cossart YE et al (2003). Human papillomavirus positivity predicts favourable outcome for squamous carcinoma of the tonsil. *Int J Cancer*, Vol. 106, pp. 553-558
- Lo Muzio L, Campisi G, Giovannelli L, Ammatuna P, Greco I, Staibano S, et al. HPV DNA and surviving expression in epithelial oral carcinogenesis: a relationship? (2004), *Oral Oncol*; Vol. 40, pp. 736-741
- Ma XL, Ueno K, Pan ZM, Hi SZ, Ohyama M & Eizuru Y (1998). Human papillomavirus DNA sequences and p53 over-expression in laryngeal squamous cell carcinomas in Northeast China. *J Med Virol*, Vol. 54, pp. 186-191
- Mannarini L, Kratochvil V, Calabrese L, Gomes Silva L, Morbini P, Betka J, et al (2009). Human Papilloma Virus (HPV) in head and neck region: review of literature. *Acta Otorhinolaryngol Ital. [Review]*, Vol. 29, No. 3, pp. 119-26
- Matzow T, Boysen M, Kalantari M, Johansson B, Hagmar B. (1998). Low detection rate of HPV in oral and laryngeal carcinomas. *Acta Oncol*. Vol. 37, pp. 73-76
- Maxwell JH, Kumar B, Feng FY, McHugh JB, Cordell KG, Eisbruch A et al (2010). HPV-positive/p16-positive/EBV-negative nasopharyngeal carcinoma in white North Americans. *Head Neck*, Vol. 32, pp. 562-567
- McKing RG, Baric RS, Olhsan AF. (1998). Human papillomavirus and head and neck cancer: epidemiology and molecular biology. *Head Neck*. Vol. 20, pp. 250-265
- Melbye M, Frisch M (1998). The role of human papillomaviruses in anogenital cancers. *Semin Cancer Biol*, Vol. 8, pp. 307-313
- Mellin H, Friesland S, Lewensohn R, Dalianis T & Munck-Wikland E (2000). Human papillomavirus (HPV) DNA in tonsillar cancer: clinical correlates, risk of relapse, and survival. *Int J Cancer*, Vol. 89, No. 3, pp. 300-4
- Miller CS & Johnstone BM. (2001). Human papillomavirus as a risk factor for oral squamous cell carcinoma: a meta-analysis, 1982-1997. *Oral Surg Oral Med Oral Pathol Oral Radiol Endod*. Vol. 91, pp.622-635


- Mirzamani N, Salehian P, Farhadi M & Tehran EA (2006). Detection of EBV and HPV in nasopharyngeal carcinoma by in situ hybridization. *Exp Mol Pathol*, Vol. 81, pp. 231-234
- Mork J, Lie AK, Glatte E, Clark S, Hallmans G, Jellum E, et al. (2001). Human papillomavirus infection as a risk factor for squamous-cell carcinoma of the head and neck. *N Engl J Med*, Vol. 344, pp. 1125-1131
- Morshed K, Polz-Dacewicz M, Rajtar B, Szymanski M, Ziaja-Soltys M & Golabek W (2005). [The prevalence of E6/E7 HPV type 16 in laryngeal cancer and in normal mucosa]. *Pol Merkur Lekarski*, Vol. 19, pp. 291-293
- Nasman A, Attner P, Hammarstedt L, Du J, Eriksson M, Giraud G et al. (2009). Incidence of human papillomavirus (HPV) positive tonsillar carcinoma in Stockholm, Sweden: an epidemic of viral-induced carcinoma? *Int J Cancer*, Vol. 125, pp. 362-366
- Nielsen H, Norrild B, Vedtofte P, Praetorius F, Reibel J & Holmstrup P (1996). Human papillomavirus in oral premalignant lesions. *Eur J Cancer B Oral Oncol. [Research Support, Non-U.S. Gov't]*, Vol. 32B, No. 4, pp. 264-70
- Oliveira MC, Soares RC, Pinto LP, Souza LB, Medeiros SRB & Costa ALL (2009). High-risk human papillomavirus (HPV) is not associated with p53 and bcl-2 expression in oral squamous cell carcinomas. *Auris Nasus Larynx*, Vol. 36, pp. 450-456
- O'Regan E M, Toner M E, Finn S P, Fan C Y, Ring M, Hagmar B. et al. (2008). p16INK4A genetic and epigenetic profiles differ in relation to age and site in head and neck squamous cell carcinomas. *Human Pathology* Vol., 39, pp.452-458
- Ostwald C, Rutsatz K, Schweder J, Schmidt W, Gundlach K & Barten M (2003). Human papillomavirus 6/11, 16 and 18 in oral carcinomas and benign oral lesions. *Med Microbiol Immunol*, Vol. 192, pp. 145-148
- Pan HY, Zhang ZY, Zhou XJ, Li J. (2006). The establishment of a carcinogenesis model of oral squamous cell carcinoma in vitro. *Zhonghua Kou Qiang Yi Xue Za Zhi*. Vol. 41, pp.: 20-24
- Park JW, Pitot HC, Strati K, Spardy N, Duensing S, Grompe M, et al. (2010). Deficiencies in the Fanconi anemia DNA damage response pathway increase sensitivity to HPV-associated head and neck cancer. *Cancer Res. [Research Support, N.I.H., Extramural]*, Vol. 70, No. 23, pp. 9959-68
- Parkin DM, Whelan SL, Ferlay J, Raymond L & Young J. (1997). In: *Scientific publications Cancer incidence in five continents*, IARC, Lyon
- Parkin DM, Bray F, Ferlay J & Pisani P (2005). Global cancer statistics, 2002. *CA Cancer J Clin*, Vol. 55, No. 2, pp. 74-108
- Paz IB, Cook N, Odom-Maryon T, Xie Y & Wilczynski SP (1997). Human papillomavirus (HPV) in head and neck cancer. An association of HPV 16 with squamous cell carcinoma of Waldeyer's tonsillar ring. *Cancer*, Vol. 79, pp. 595-604
- Punwaney R, Brandwein MS, Zhang DY, Urken ML, Cheng R, Park CS et al. (1999). Human papillomavirus may be common within nasopharyngeal carcinoma of Caucasian Americans: investigation of Epstein-Barr virus and human papillomavirus in eastern and western nasopharyngeal carcinoma using ligation-dependent polymerase chain reaction. *Head Neck*, Vol. 21, pp. 21-29

- Ragin CCR, Modugno F, Gollin SM. (2007). The epidemiology and risk factors of head and neck cancer: a focus on human papillomavirus. *J Dent Res*. Vol. 86, pp. 104-14
- Rajkumar T, Sridhar H, Balaram P, Vaccarella S, Gajalakshmi V, Nandakumar A et al. (2003). Oral cancer in Southern India: the influence of body size, diet, infections and sexual practices. *Eur J Cancer Prev*, Vol. 12, pp. 135-143
- Remmerbach TW, Brinckmann UG, Hemprich A, Chekol M, Ku'hndel K, Liebert UG. (2004). PCR detection of human papillomavirus of the mucosa: comparison between MY09/11 and GP5+/GP6+ primer sets, *J Clin Virol* . Vol. 30, pp. 302-308
- Ribeiro KB, Levi JE, Pawlita M, Koifman S, Matos E, Eluf-Neto J et al. (2011). Low human papillomavirus prevalence in head and neck cancer: results from two large case-control studies in high-incidence regions. *Int J Epidemiol*, Vol. 40, pp. 489-502
- Ringström E, Peters E, Hasegawa M, Posner M, Liu M, Kelsey KT. (2002). Human papillomavirus type 16 and squamous cell carcinoma of the head and neck. *Clin Cancer Res*. Vol. 8, pp.3187-3192
- Rintala M., Grénmana S., Puranen M., Syrjänen S. (2006). Natural history of oral papillomavirus infections in spouses: A prospective Finnish HPV Family Study. *Journal of Clinical Virology*, Vol. 35, pp. 89-94
- Ritchie JM, Smith EM, Summersgill KF, Hoffman HT, Wang D, Klussmann JP, et al. (2003). Human papillomavirus infection as a prognostic factor in carcinomas of the oral cavity and oropharynx. *Int J Cancer*, Vol. 104, No. 3, pp. 336-44
- Rosenquist K, Wennerberg J & Schildt EB (2005). Oral status, oral infections and some lifestyle factors as risk factors for oral and oropharyngeal squamous cell carcinoma. A populationbased case-control study in southern Sweden. *Acta Otolaryngol*, Vol. 125, pp. 1327-36
- Schwartz SM, Daling JR, Doody DR, Wipf GC, Carter JJ, Madeleine MM, et al. (1998). Oral cancer risk in relation to sexual history and evidence of human papillomavirus infection. *J Natl Cancer Inst*, Vol. 90, pp. 1626-1636
- Shiboski CH, Schmidt BL, Jordan RC (2005). Tongue and tonsil carcinoma: increasing trends in the U.S. population ages 20-44 years. *Cancer*, Vol. 103, pp. 1843-1849
- Silverman Jr S. (2001). Demographics and occurrence of oral and pharyngeal cancers. The outcomes, the trends, the challenge. *J Am Dent Assoc*. Vol. 132(Suppl.):7S
- Singhi AD, Califano J & Westra WH (2011). High-risk human papillomavirus in nasopharyngeal carcinoma. *Head Neck*
- Sisk EA, Soltys SG, Zhu S, Fisher SG, Carey TE & Bradford CR (2002). Human papillomavirus and p53 mutational status as prognostic factors in head and neck carcinoma. *Head Neck*, Vol. 24, No. 9, pp. 841-9
- Smith EM, Ritchie JM, Summersgill KF, Hoffman HT, Wang DH, Haugen TH, et al. (2004). Human papillomavirus in oral exfoliated cells and risk of head and neck cancer. *J Natl Cancer Ins*. Vol. 96, pp. 449-55
- Smith EM, Ritchie JM, Summersgill KF, Klussmann JP, Lee JH, Wang D et al. (2004). Age, sexual behavior and human papillomavirus infection in oral cavity and oropharyngeal cancers. *Int J Cancer*, Vol. 108, pp. 766-772

- Snijders PJ, Scholes AG, Hart CA, et al. (1996). Prevalence of mucosotropic human papillomaviruses in squamous-cell carcinoma of the head and neck. *Int J Cancer*, Vol. 66, pp. 464-469
- Snijders PJ, Steenbergen RD, Meijer CJ, Walboomers JM. (1997). Role of human papillomaviruses in cancer of the respiratory and upper digestive tract. *Clin Dermatol.*, Vol. 15, pp. 415-425
- Strome SE, Savva A, Brissett AE, Gostout BS, Lewis J, Clayton AC, et al. (2002). Squamous cell carcinoma of the tonsils: a molecular analysis of HPV associations. *Clin Cancer Res*, Vol. 8, No. 4, pp. 1093-100
- Sugiyama M, Bhawal U K, Kawamura M, Ishioka Y, Shigeishi H, Higashikawa K. et al. (2007). Human papillomavirus-16 in oral squamous cell carcinoma: Clinical correlates and 5-year survival British Journal of Oral and Maxillofacial Surgery, Vol. 45, pp. 116-122
- Sugiyama M, Bhawal UK, Dohmen T, Ono S, Miyauchi M, Ishikawa T. (2003). Detection of human papillomavirus-16 and HPV-18 DNA in normal, dysplastic, and malignant oral epithelium. *Oral Surg Oral Med Oral Pathol Oral Radiol Endod.* Vol. 95, pp. 594-600
- Syrjänen K, Syrjänen S, Lamberg M, Pyrhonen S & Nuutinen J (1983). Morphological and immunohistochemical evidence suggesting human papillomavirus (HPV) involvement in oral squamous cell carcinogenesis. *Int J Oral Surg*, Vol. 12, pp. 418-424
- Syrjänen K & Syrjänen S. (2000). Papillomavirus infections in human disease, pp. 1-615, Wiley, New York
- Syrjänen S (2004). HPV infections and tonsillar carcinoma. *J Clin Pathol*, Vol. 57, pp. 449-455
- Syrjänen S (2005). Human papillomavirus (HPV) in head and neck cancer. *J Clin Virol.* [Review], Vol. 32, No. , pp. S59-66
- St Guily JL, Clavel C, Okais C, Pretet JL, Beby-Defaux A, Agius G et al. (2011). Human papillomavirus genotype distribution in tonsil cancers. *Head Neck Oncol*, Vol. 3, pp. 6
- St Guily JL, Borget I, Vainchtock A, Remy V & Takizawa C (2010). Head and neck cancers in France: an analysis of the hospital medical information system (PMSI) database. *Head Neck Oncol*, Vol. 2, pp. 22
- Tang X, Jia L, Ouyang J, Takagi M. (2003). Comparative study of HPV prevalence in Japanese and north-east Chinese oral carcinoma. *J Oral Pathol Med.* Vol. 2, pp. 393-398
- Torrente MC, Rodrigo JP, Haigentz M, Jr., Dikkers FG, Rinaldo A, Takes RP et al. (2011). Human papillomavirus infections in laryngeal cancer. *Head Neck*, Vol. 33, pp. 581-586
- Tsai TC, Chen SL (2003). The biochemical and biological functions of human papillomavirus type 16 E5 protein. *Arch Virol.* Vol. 148, pp.1445-153
- Tyan YS, Liu ST, Ong WR, Chen ML, Shu CH & Chang YS (1993). Detection of Epstein-Barr virus and human papillomavirus in head and neck tumors. *J Clin Microbiol*, Vol. 31, pp. 53-56

- van Monsjou HS, Balm AJ, van den Brekel MM & Wreesmann VB (2010). Oropharyngeal squamous cell carcinoma: a unique disease on the rise? *Oral Oncol*, Vol. 46, pp. 780-785
- Venuti A, Badaracco G, Rizzo C, Mafera B, Rahimi S & Vigili M (2004). Presence of HPV in head and neck tumours: high prevalence in tonsillar localization. *J Exp Clin Cancer Res*, Vol. 23, pp. 561-566
- Vidal L & Gillison ML (2008). Human papillomavirus in HNSCC: recognition of a distinct disease type. *Hematol Oncol Clin North Am. [Review]*, Vol. 22, No. 6, pp. 1125-42
- Watts DH, Koutsky LA, Holmes KK, Goldman D, Kuypers J, Kiviat NB et al. (1998). Low risk of perinatal transmission of human papillomavirus: results from a prospective cohort study. *Am J Obstet Gynecol*, Vol. 178, pp. 365-73
- Wiest T, Schwarz E, Enders C, Flechtenmacher C, Bosch FX (2002). Involvement of intact HPV16 E6/E7 gene expression in head and neck cancers with unaltered p53 status and perturbed pRb cell cycle control. *Oncogene*, Vol. 21, pp.1510-1517
- Yang SW, Lee YS, Chen TA, Wu CJ & Tsai CN (2009). Human papillomavirus in oral leukoplakia is no prognostic indicator of malignant transformation. *Cancer Epidemiol*, Vol. 33, pp. 118-122

IntechOpen



Human Papillomavirus and Related Diseases - From Bench to Bedside - A Clinical Perspective

Edited by Dr. Davy Vanden Broeck

ISBN 978-953-307-860-1

Hard cover, 348 pages

Publisher InTech

Published online 20, January, 2012

Published in print edition January, 2012

Cervical cancer is the second most prevalent cancer among women worldwide, and infection with Human Papilloma Virus (HPV) has been identified as the causal agent for this condition. The natural history of cervical cancer is characterized by slow disease progression, rendering the condition, in essence, preventable and even treatable when diagnosed in early stages. Pap smear and the recently introduced prophylactic vaccines are the most prominent prevention options, but despite the availability of these primary and secondary screening tools, the global burden of disease is unfortunately still very high. This book will focus on the clinical aspects of HPV and related disease, highlighting the latest developments in this field.

How to reference

In order to correctly reference this scholarly work, feel free to copy and paste the following:

Márcio Campos Oliveira, Maria da Conceição Andrade and Fabrício dos Santos Menezes (2012). Epidemiology of HPV in Head and Neck Cancer, Human Papillomavirus and Related Diseases - From Bench to Bedside - A Clinical Perspective, Dr. Davy Vanden Broeck (Ed.), ISBN: 978-953-307-860-1, InTech, Available from: <http://www.intechopen.com/books/human-papillomavirus-and-related-diseases-from-bench-to-bedside-a-clinical-perspective/epidemiology-of-hpv-in-head-and-neck-cancer>

INTech
open science | open minds

InTech Europe

University Campus STeP Ri
Slavka Krautzeka 83/A
51000 Rijeka, Croatia
Phone: +385 (51) 770 447
Fax: +385 (51) 686 166
www.intechopen.com

InTech China

Unit 405, Office Block, Hotel Equatorial Shanghai
No.65, Yan An Road (West), Shanghai, 200040, China
中国上海市延安西路65号上海国际贵都大饭店办公楼405单元
Phone: +86-21-62489820
Fax: +86-21-62489821

© 2012 The Author(s). Licensee IntechOpen. This is an open access article distributed under the terms of the [Creative Commons Attribution 3.0 License](https://creativecommons.org/licenses/by/3.0/), which permits unrestricted use, distribution, and reproduction in any medium, provided the original work is properly cited.

IntechOpen

IntechOpen