

We are IntechOpen, the world's leading publisher of Open Access books Built by scientists, for scientists

6,900

Open access books available

186,000

International authors and editors

200M

Downloads

Our authors are among the

154

Countries delivered to

TOP 1%

most cited scientists

12.2%

Contributors from top 500 universities



WEB OF SCIENCE™

Selection of our books indexed in the Book Citation Index
in Web of Science™ Core Collection (BKCI)

Interested in publishing with us?
Contact book.department@intechopen.com

Numbers displayed above are based on latest data collected.
For more information visit www.intechopen.com



Diaschisis, Degeneration, and Adaptive Plasticity After Focal Ischemic Stroke

Bernice Sist, Sam Joshva Baskar Jesudasan and Ian R. Winship
*Centre for Neuroscience and Department of Psychiatry, University of Alberta,
 Canada*

1. Introduction

Focal stroke refers to sudden brain dysfunction due to an interruption of blood supply to a particular region of the brain. An ischemic stroke (~80% of focal strokes) occurs due to a blockage of a blood vessel, typically by a blood clot, whereas a haemorrhagic stroke results from rupture of a cerebral blood vessel and the resulting accumulation of blood in the brain parenchyma. Symptoms of stroke will vary depending on the size and location of the tissue damaged by the reduced blood flow (the infarct), but common symptoms include sudden weakness of the limbs or face, trouble speaking or understanding speech, impaired vision, headache and dizziness. According to the World Health Organization (WHO), more than 15 million people suffer a stroke each year, of which five million people will die. Stroke is a leading cause of chronic adult disability worldwide, and the majority of those who survive their stroke (more than five million people per year) are left with permanent sensorimotor disabilities, which may include loss of strength, sensation, coordination or balance (with the nature and severity of disability depending on the location and size of the lesion).

Despite the significant societal and personal cost of stroke, treatment options remain limited. Currently, only recombinant tissue-type plasminogen activator (rtPA), a serine proteinase, has proved effective in treating ischemic stroke in clinical trials (NINDS, 1995). Thrombolysis after rtPA administration occurs as a result of plasminogen being converted to plasmin by rtPA. The plasmin then participates in the degradation of fibrin to restore blood flow to territories downstream of the occlusion. Unfortunately, few patients are treated with rtPA, in part due to its short therapeutic window of 4.5 hours (relative to delays in symptom recognition, transport, and triaging) after ischemic onset (Lansberg et al., 2009; Kaur et al., 2004; Clark et al., 1999; Del Zoppo et al., 2009). Moreover, rtPA is ineffective for many patients treated within its therapeutic window, particularly with respect to middle cerebral artery occlusion (MCAo), the most common cause of focal ischemic stroke (Kaur et al., 2004; Seitz et al., 2011). Given the limited treatment options for stroke, an improved understanding of its pathophysiology and the brain's endogenous mechanisms for neuroprotection, brain repair and neuroanatomical rewiring is important to developing new strategies and improving stroke care.

While death and disability due to stroke can be predicted based on the size and location of the infarct, damage due to stroke extends beyond the ischemic territories. Moreover, while treatment options remain limited, partial recovery after stroke occurs due to adaptive changes (plasticity) in brain structure and function that allow uninjured brain regions to

adopt the function of neural tissue destroyed by ischemia (Winship and Murphy, 2009; C.E. Brown and Murphy, 2008). While pathological and adaptive changes that occur in peri-infarct cortex have been well characterized, less research has examined adaptive and maladaptive changes distal to the infarct. In this chapter, we will review the pathophysiology that leads to expansion of the infarct into surrounding peri-infarct tissue, diaschisis and degeneration in distal but anatomically connected regions, and the adaptive changes that occur distal to the infarct after focal stroke.

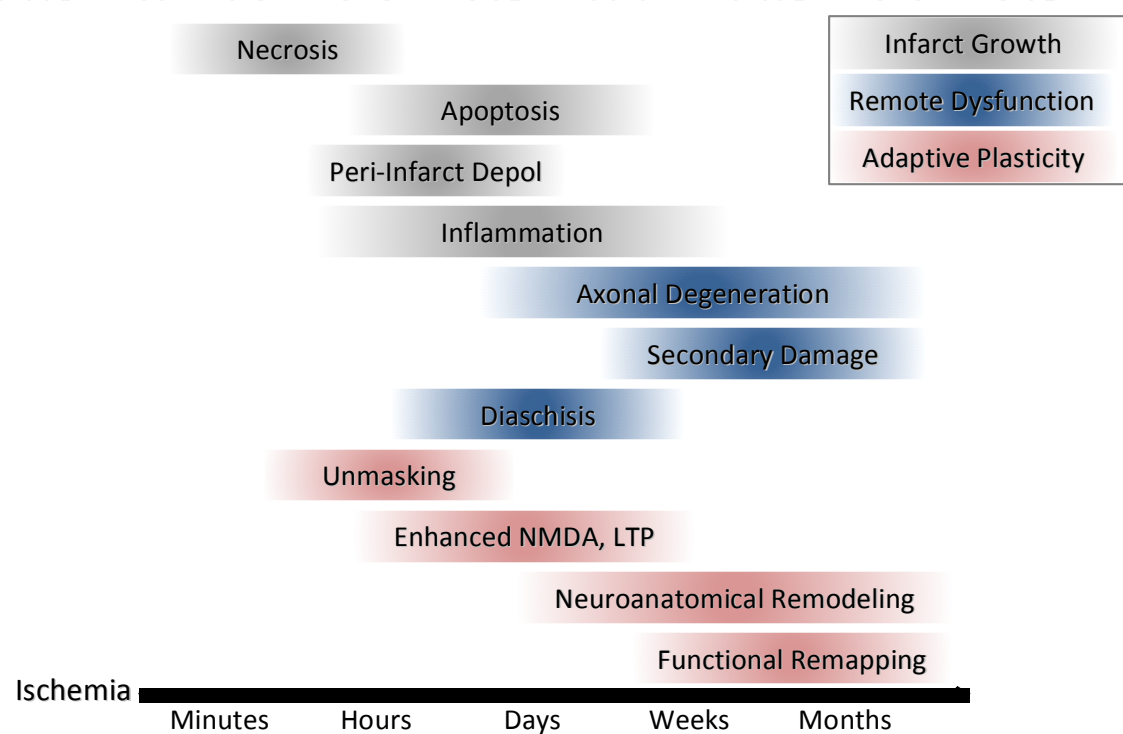


Fig. 1. Timeline of stroke-induced degeneration, dysfunction and adaptive plasticity. During ischemia, several processes lead to development of an infarct core and expansion of this core into penumbral tissue (grey bars). Metabolic failure in the core of the ischemic territory leads to rapid and irreversible cell death (necrosis), while inflammation and peri-infarct depolarizations can induce delayed cell death (through apoptosis) in cells in the penumbra over the following days and weeks. Focal stroke can also induce degeneration and dysfunction in regions far from the infarct (blue bars). Brain dysfunction distal to the stroke (diaschisis) can appear soon after ischemia and persist for weeks, and includes changes in blood flow, metabolism, and altered inhibitory neurotransmission remote from the infarct. Similarly, remote to the site of injury, axons from neurons in the infarct core degenerate, inducing inflammation that can trigger secondary damage and atrophy in structures with neuroanatomical links to the infarct. Finally, adaptive plasticity induced by the stroke can occur immediately following ischemia and persist for months (red bars). Functional unmasking of existing connections can lead to rapid redistribution of some function lost to the infarct, and changes in glutamatergic transmission and long-term potentiation have been reported in peri-infarct cortex and beyond in the first week after stroke. Neuroanatomical rewiring to compensate for lost connections starts days after ischemia and persists for months, allowing functional representations lost to stroke to remap to new locations in the weeks and months after this initial insult.

2. Mechanisms of cell death and infarct growth after ischemic stroke

At the centre of the stroke, the “ischemic core”, brain damage is fast and irreversible as reduced blood flow leads to the activation of proteolytic enzymes, degradation of the cytoskeleton, cytotoxic swelling, and peroxidation of membrane lipids (Witte et al., 2000).

As blood flow within the core drops below 20% of normal flow rates, metabolic failure leads to anoxic depolarization and activation of the “ischemic cascade” that triggers neuronal death beginning within minutes of ischemic onset (Dirnagl et al., 1999; Hossmann, 1994; Witte et al., 2000). Reduced blood flow decreases delivery of oxygen and glucose to the brain, which leads to reduced production of adenosine triphosphate (ATP) and failure of energy dependent membrane receptors, ion channels and ionic pumps. These failures lead to collapse of transmembrane potential as ions such as sodium (Na^+), potassium (K^+) and calcium (Ca^{2+}) flow freely down their concentration gradients, leading to anoxic depolarization and the release of additional excitatory neurotransmitters (primarily glutamate). The resulting excitotoxicity is potentiated by the disruption of energy dependent glutamate reuptake from the synaptic cleft, and the ensuing activation of the glutamatergic N-methyl-D-amino (NMDA) receptor and the alpha-amino-3-hydroxy-5-methyl-4-isoxazole-propionic acid (AMPA) receptor lead to further depolarization and excitotoxicity. Water begins to enter the cells in response to change in ion concentrations, producing cytotoxic oedema, a pathophysiological marker of ischemia.

Intracellular increases in Ca^{2+} concentration are particularly important regulators of cell death in the ischemic core due to the role Ca^{2+} plays as a second messenger. Ca^{2+} increases activate multiple signalling pathways that contribute to cell death, including enhancing the production of nitric oxide (NO). NO is an intracellular messenger important for the normal physiology of an organism, with a well-characterized role in regulating circulation (Huang, 1994; Dirnagl et al., 1999). NO production is regulated by nitric oxide synthase (NOS), a Ca^{2+} dependent enzyme. Following ischemia, increased activation of NOS can lead to neurotoxic levels of NO (A.T. Brown et al., 1995; Dirnagl et al., 1999; Danton and Dietrich, 2003). During initial stages of ischemia, NO produced by endothelial NOS triggers arterial dilation near the region of occlusion, thereby increasing blood flow and increases the chance of survival of the penumbra. However, NO can react with a superoxide anion to form the highly reactive species peroxynitrite, which can react with and damage virtually any cellular component (Mergenthaler et al., 2004). Increases in NO can initiate cell death by inducing lipid oxidation chain reactions, which disrupt the lipid membranes of the mitochondria (Burwell and Brookes, 2008), or by causing energy failures by acting as an electron acceptor and thereby disrupting cellular respiration in the mitochondria (Bolaños et al., 1997; Brookes et al., 1999; Burwell and Brookes, 2008; Dirnagl et al., 1999). Moreover, these reactive species lead to peroxidation of the plasma, nuclear, and mitochondrial membranes, inducing DNA damage and cell lysis. Beyond their direct effects on cell death, increased levels of reactive oxygen and nitrogen species also induce release of pro-inflammatory factors from immune cells, leading to inflammation and expansion of the stroke core (discussed further in Section 2.2) (Lai and Todd, 2006; Jin et al., 2010; Vila et al., 2000, 2003).

Surrounding the stroke core is a band of tissue referred to as the penumbra, in which blood flow is partially preserved due to redundant collateral circulation. While this tissue is somewhat ischemic, neurons here can be saved from death by reperfusion or neuroprotective treatments soon after ischemic onset. The brain maintains independent thresholds for functional integrity and structural integrity, thereby keeping a gradient of cell

viability after ischemic insults. The threshold for functional integrity and that of structural integrity are governed by two key factors: the residual flow rate of blood and duration of reduced flow (Heiss and Graf, 1994). Since the threshold for functional integrity is higher than that for structural integrity, the neurons in the penumbra are electrically silent but still able to maintain ion homeostasis and structural integrity (Astrup et al., 1981; Ferrer and Planas, 2003; Heiss and Graf, 1994; Symon, 1975; Hossmann, 1994). However, viability in the penumbra is variable and time dependent, and a number of processes lead to cell death and expansion of the infarct core into the penumbra. Three of these factors, peri-infarct depolarizations, inflammation, and apoptosis, are discussed below.

2.1 Peri-infarct depolarizations

Excitotoxicity and anoxic depolarizations caused by ischemia increase extracellular glutamate and potassium levels in the stroke core, which may then diffuse into penumbral regions and trigger depolarization of the resident neurons and glia (Mergenthaler et al., 2004). A propagating wave of depolarization moving away from the core is initiated and places additional stress on the metabolically compromised cells in the penumbra. These depolarizations can occur several times per hour during acute stroke (Busch et al., 1996; Wolf et al., 1997). Since there are fluctuations in blood flow which compromise oxygen and glucose supply, depolarizations within the peri-infarct cortex contribute to energy failure and cell death, leading to the growth of the infarct core over time (Back et al., 1996). Recent data from animal models suggests that ischemic depolarizations are accompanied by intracellular Ca^{2+} accumulation and a loss of synaptic integrity (Murphy et al., 2008). Murphy et al. (2008) demonstrated that ischemic depolarizations and increases in intracellular calcium were glutamate receptor independent and suggested that these depolarizations were the major ionic event associated with the degeneration of synaptic structure early after ischemic onset. Notably, persistent depolarizations resembling anoxic depolarization and transient depolarizations resembling recurrent peri-infarct depolarizations emerge not only in cortex, but also occur in striatal gray matter, suggesting that infarct expansion due to peri-infarct depolarization extends beyond the cortex (Umegaki et al., 2005).

2.2 Inflammation and infarct growth

Inflammation is a non-specific physiological response to infection or injury. The central nervous system is often labeled as "immune privileged" due to the presence of a blood brain barrier that separates it from the periphery and prevents entry of most infectious materials into the brain. However, inflammation after brain injury is characterized by the infiltration and proliferation of immune cells in an attempt to eliminate cellular debris and pathogens, and the secretion of chemokines and pro- and/or anti-inflammatory cytokines. After stroke, the inflammatory response contributes to cell death and infarct growth for days after ischemic onset (Dirnagl et al., 1999). Leukocytes, monocytes, neurons, and glial cells (microglia and astrocytes) all participate in the inflammatory response to stroke. During ischemia, leukocytes aggregate and adhere to the vascular endothelium, in part due to increased release of chemokines such as monocyte chemo attractant protein 1 (MCP1) and adhesion molecules such as selectins in ischemic territories (Danton and Dietrich, 2003; Mergenthaler et al., 2004). Following ischemia, endothelial cells increase their expression of selectin, which promotes cellular interactions with leukocytes and aggregates of leukocytes that accumulate platelets and fibrin and thereby occlude vessels, reduce perfusion and contribute to the expansion of the infarct (Ritter, 2000; Danton and Dietrich, 2003).

Glial cells are major contributors to post-stroke inflammation. As the resident immune cells of the brain, microglia serve to monitor the brain microenvironment for injury or infection. After stroke, microglia become activated and migrate to the stroke penumbra. Therein, they assume an activated morphology and participate (along with leukocytes, neurons, and astrocytes) in modulating inflammation through the secretion of pro- and anti-inflammatory cytokines.

Cytokines are small glycoproteins and able to trigger multiple signaling pathways relevant to cell death. Cytokines are important mediators of apoptosis (programmed cell death) during stroke. In the hours following stroke, microglia transform from surveying the microenvironment in a ramified “resting state” into an amoeboid phagocytotic state, scavenging for debris and secreting cytotoxic and pro-inflammatory factors such as interleukin-1 (IL-1), interleukin-6 (IL-6) and tumor necrosis factor alpha (TNF- α) (Danton and Dietrich, 2003; J.J. Legos et al., 2000; E. Tarkowski et al., 1999). Within the first 24 hours after stroke, amoeboid microglia and macrophages expressing high levels of interleukin-1 beta (IL-1 β) accumulate at the border of the infarct area (Clausen et al., 2008; Mabuchi et al., 2000). The interleukin-1 family of cytokines has multiple members that mediate degeneration following ischemic stroke. Evidence for the importance of interleukin-1 alpha (IL-1 α) and IL-1 β has been confirmed by studies that demonstrate that deleting both cytokines can reduce infarct volume (Boutin et al., 2001). IL-1 α is an important modulator of cerebrovascular inflammation and induces activation of endothelial cells and expression of adhesion molecules, allowing leukocytes and neutrophils to enter the central nervous system and increase secretion of pro-inflammatory cytokines and production of reactive oxygen species (Jin et al., 2010; Thornton et al., 2010). TNF- α released by immune cells binds to the TNF type 1 receptor, inducing the recruitment of adaptor proteins that influence multiple distinct signaling pathways. These adaptor proteins can enhance inflammation or lead to apoptosis by increasing the adhesion of leukocytes and elevating release of IL-1, NO, or other inflammatory mediators (Hallenbeck, 2002; Lykke et al., 2009). Conversely, the same signaling pathways can lead to the transduction of a cell survival signal, perhaps in response to activation at different receptor subtypes (Hallenbeck, 2002; Lykke et al., 2009). Similarly, activated immune cells also secrete anti-inflammatory cytokines (TNF- β 1, IL-10) under some conditions, reinforcing the complexity of the inflammatory response as it relates to cell death (Mergenthaler et al., 2004).

2.3 Apoptosis

Following cerebral ischemia, both necrotic and apoptotic cell death contribute to ultimate lesion volume. Necrosis is a passive process confined to the ischemic core where cell death is fast and characterized by the loss of membrane integrity, abnormal morphology of organelles and cellular swelling (Bredesen, 2000; Ferrer and Planas, 2003). Programmed cell death, or apoptosis, is an energy dependent process that occurs in cells distributed throughout the penumbra that involves translation of proteins to facilitate an “orderly” cell death process. Apoptosis is the systematic degradation of a cell in response to injury and is characterized by the condensation of chromatin, nuclear fragmentation, preserved membrane integrity and blebbing of the plasma membrane (apoptotic bodies) (Bredesen, 2000).

Apoptosis can be triggered through an intrinsic pathway or an extrinsic pathway. The intrinsic apoptotic signaling pathway is due to the disruption of mitochondrial transmembrane potential and integrity, which can be induced through multiple pro-apoptotic pathways (Ferri and Kroemer, 2001). The mitochondria produce reactive oxygen

species after injury or excessive Ca^{2+} influx, such as might occur due to excitotoxicity or persistent NMDA receptor activation (Zipfel et al., 2000), causing disruption to the membrane permeability (Burwell and Brookes, 2008; Lewen et al., 2000; Zipfel et al., 2000). Changes in mitochondrial membrane permeability increase the release of pro-apoptotic factors including cytochrome c (Bredesen, 2000; Ferri and Kroemer, 2001; Garrido et al., 2006; Saelens et al., 2004; Vaux, 2011). The release of cytochrome c disrupts metabolism and energy production within the mitochondria, further exacerbating free radical production and release of cytochrome c (Burwell and Brookes, 2008; Lewen et al., 2000). High levels of oxidative stress will push cells towards necrosis while moderate levels will trigger apoptosis (Lewen et al., 2000). The release of cytochrome c into the cytosol also stimulates the assembly of apoptosomes, protein complexes that serve to activate cysteine-dependent aspartic acid proteases (caspases) (Ferri and Kroemer, 2001).

Caspases are the major regulators of apoptosis and have been categorized based on their function (Alnemri et al., 1996; Graham and Chen, 2001). Initiator caspases (caspase-2, -8, -9, -10) cleave the inactive pro-forms of effector caspases (caspase-3, -6, -7), allowing them to trigger apoptosis by cleaving multiple protein substrates and degrade DNA by activating nucleases (Fujimura et al., 1998; Enari et al., 1998; Lewen et al., 2000; Mergenthaler et al., 2004). Caspases 1, 3, 8, and 9 are involved in inducing apoptosis during stroke, with caspase-1 involved in the early activation of cytokine release and caspase-3 central to the apoptotic signaling cascade (Mergenthaler et al., 2004; Ferrer and Planas, 2003). Blockage of caspase-3 function is associated with robust neuroprotection in animal models of stroke (Hara et al., 1997; Le et al., 2002).

The extrinsic apoptotic pathway also acts through the activation of caspases. The TNF class of cytokines are the major mediators of the extrinsic apoptotic pathway. Binding at the TNF receptors leads to caspase activation via the TNF receptor-associated death domain (TRADD) and the Fas-associated death domain protein (FADD) (Bredesen, 2000; Ferrer and Planas, 2003). Accordingly, elevated TNF- α signaling increases caspase-3 mediated neuronal apoptosis and infarct volume after ischemic stroke (Emsley and Tyrell, 2002; Pettigrew et al., 2008). Conversely, blockade of TNF- α via TNF-binding proteins has been demonstrated to be neuroprotective during cerebral ischemia (Nawashiro et al., 1997).

3. Diaschisis and degeneration distal to the infarct

While the size and location of the stroke core and the expansion of the infarct accounts for much of the death and disability due to stroke, focal ischemia induces widespread changes in the brain, even in non-ischemic territories. In this section, we will examine dysfunction and degeneration induced by focal stroke in regions that are anatomically connected but distal to the infarct.

3.1 Diaschisis after stroke

Diaschisis is defined as brain dysfunction in a region of the brain distal to a site of injury that is anatomical connected to the damaged area. While functional deafferentiation is thought to be the primary mechanism of diaschisis (Finger et al., 2004), it is influenced by a number of factors. In stroke, brain swelling and spreading depression as well as neuroanatomical disconnection contribute to diaschisis that can manifest as altered neuronal excitability or neurotransmitter receptor expression, hypometabolism, and/or hypoperfusion in areas not directly damaged by ischemia.

Both cytotoxic and vasogenic oedema are induced by stroke, and persistent water accumulation occurs in the brain over the days following ischemia in animal models and human stroke patients (Witte et al., 2000). Oedema remote to the infarct can occur and may result from the migration of extravasated fluid and protein (Izumi et al., 2002). In the case of large strokes such as MCAo, acute brain swelling can directly compress the contralesional hemisphere and remote ipsilesional regions (O'Brien et al., 1974; Izumi et al., 2002). The effects of widespread brain swelling are multifold, inducing secondary damage directly through physical compression and inducing secondary hypoperfusion and ischemia due to compression of low resistance vasculature (Witte et al., 2000).

Reductions in cerebral blood flow on the side of the brain opposite of an ischemic insult have been reported in stroke patients since the 1960s (Kempinsky et al., 1961; Hoedt-Rasmussen and Skinhoj, 1964). Local measurement of cerebral blood flow confirmed this reduction in perfusion in sites remote from the infarct, including the contralesional hemisphere, and demonstrated a progressive decline in blood flow in both hemispheres during the first week after infarction in most stroke patients (Slater et al., 1977). Based on this progressive decline, Slater et al. (1977) suggested that diaschisis in the contralesional hemisphere involved a process more complex than simple destruction of axonal afferents, and proposed that a combination of decreased neuronal stimulation, loss of cerebral autoregulation, release of vasoactive compounds, and oedema, as well as other factors, led to the widespread and long-lasting changes in cerebral blood flow. Transhemispheric reductions in cerebral oxygen metabolism and cerebral blood flow have been confirmed using positron emission tomography (PET) and shown to correlate with the patients' level of consciousness (Lenzi et al., 1982). Moreover, approximately 50% of patients exhibit "mirror diaschisis" during the first two weeks after stroke, as indicated by a decrease in oxygen metabolism and blood flow in the contralateral brain regions homotypical to the infarct (Lenzi et al., 1982). In addition to regional changes in blood flow, animal models have suggested that vasoreactivity (measured in response to hypercapnia) is impaired even in non-infarcted, non-penumbra brain regions (Dettmers et al., 1993).

Not surprisingly, in light of the changes in cerebral blood flow discussed above, widespread hypometabolism has been reported in human patients and animal models after focal stroke. In patients measured acutely and three weeks after MCAo, oxygen consumption measured by PET decreased throughout the ipsilesional hemisphere (including the thalamus and remote, non-ischemic tissue) between imaging sessions (Iglesias et al., 2000). Similarly, using small cortical strokes in rats, Carmichael et al. (2004) demonstrated impaired glucose metabolism (a direct reflection of neuronal activity) one day after stroke throughout ipsilesional cortex, striatum, and thalamus that was not associated with reductions in blood flow. The affected cortex was approximated 13X larger than the infarct and incorporated functionally related areas in the sensorimotor cortex. By eight days post-stroke, hypometabolism in the thalamus and striatum had resolved, but persisted in this ipsilesional cortex.

In addition to diffuse changes in the cerebral cortices, region specific diaschisis has been identified in the ipsilesional thalamus and contralateral cerebellum after stroke (Iglesias et al., 2000; De Reuck et al., 1995; Nagasawa et al., 1994; Baron et al., 1981). Decreased blood flow and metabolism in the contralateral cerebellum (typically called crossed cerebellar diaschisis, CCD) has been reported via a number of modalities (computed tomography (CT) and single photon emission CT, PET, and magnetic resonance imaging) after cerebral hemispheric infarction. CCD occurs within 6 hours of ischemic onset (Kamouchi et al., 2004)

and persists into the chronic phase of stroke recovery. In the acute phase (approximately 16 hours after onset) of stroke, CCD is not correlated with clinical outcome (Takasawa et al., 2002). However, CCD in the subacute period (approximately 10 days after stroke) is significantly correlated with performance on the Scandinavian Stroke Scale and Barthel Index (Takasawa et al., 2002). CCD varies according to the size and location of the cerebral infarction. Infarcts incorporating temporal association cortex and pyramidal tract of the corona radiata were correlated with CCD in the medial zone of the cerebellum, whereas lesions of the primary and supplementary motor cortex, premotor cortex, primary somatosensory cortex, and posterior limb of the internal capsule were associated with CCD in the intermediate cerebellum (Z. Liu et al., 2007). Finally, infarcts occupying the primary motor cortex, supplementary motor cortex, premotor cortex and genu of the internal capsule were associated with CCD in the lateral cerebellum (Z. Liu et al., 2007). Notably, CCD in the lateral and intermediate were found to be better predictors of clinical outcome.

As discussed in Section 2.1, peri-infarct depolarizations place tremendous metabolic stress on neurons in the penumbra and contribute to delayed cell death and infarct expansion. However, it is important to note that, at least in animal models, these depolarizations travel into healthy brain tissue throughout the ipsilesional hemisphere as waves of spreading depression (SD). SD moves through cortex at ~2-5 mm/minute and is characterized by local suppression of electrical activity and a large direct current (DC) shift associated with the redistribution of ions between the intracellular and extracellular space (Chuquet et al, 2007; Somjen, 2001). Even in non-ischemic regions, these waves induce significant metabolic stress, with an initial increase in brain metabolism followed by profound hypometabolism and transient changes in the expression of a number of neurotrophic and inflammatory cytokines and molecular signalling cascades (Witte et al., 2007). In vivo calcium imaging has demonstrated the SD is associated with calcium waves propagating through both neurons and astrocytes, and that these waves elicit vasoconstriction sufficient to stop capillary blood flow in affected cortex (Chuquet et al., 2007). Chuquet et al. (2007) suggest that SD propagation is driven by neuronal signals, while astrocyte waves are responsible for hemodynamic failure after SD.

In addition to changes in metabolism and blood flow, diaschisis is also reflected by direct changes in neuronal activity in regions of the brain remote to the ischemic infarct. While task-evoked blood oxygen level dependent (BOLD) signals (an indirect measure of neuronal activation) detected during functional magnetic resonance imaging (fMRI) are normal in areas of diaschisis (Fair et al., 2009), synaptic signalling and sensory-evoked activity may be impaired. For example, in patients with stroke affecting the striate cortex, visual activation (evidenced by fMRI BOLD signals) was reduced or absent in extrastriate cortex in the first 10 days after stroke (Brodtmann et al., 2007). Visually evoked activation was restored in these regions six months after infarction.

Numerous reports have identified significant changes in neuronal excitability throughout the brain after stroke. Mechanisms responsible for changes in electrical properties within the peri-infarct cortex have included fluctuations in cerebral blood flow (Dietrich et al., 2010) and disrupted balance of excitatory and inhibitory membrane receptors (Jolkkonen et al., 2003; Qü et al., 1998; Que et al., 1999; Schiene et al., 1996; Clarkson et al., 2010). Focal stroke produces a long-lasting impairment in gamma-aminobutyric acid (GABA) transmission in peri-infarct and contralesional cortex (Buchkremer-Ratzmann et al., 1996; Domann et al., 1993; Schiene et al., 1996; Wang, 2003). A massive upregulation of GABA_A receptor mRNA has been reported throughout the ipsilesional hemisphere in rats (Neumann-Haefelin et al., 1999) after targeted

cortical stroke. Translation of the GABA_A receptor is impaired, however, such that GABA_A receptor protein and binding are reduced and GABAergic inhibition (measured by paired pulse inhibition) is impaired in both cerebral hemispheres (Neumann-Haefelin et al., 1999; Buchkremer-Ratzmann et al., 1996, 1998; Buchkremer-Ratzmann and Witte, 1997a,b). This GABA_A dysfunction would lead to cortical hyperexcitability, an assertion supported by in vivo recordings that identified increased spontaneous activity in neurons near the infarct (Schiene et al., 1996). Notably, long-lasting disinhibition of both the ipsi- and contralesional hemispheres has been reported in human stroke patients (Butefisch et al., 2003; Manganotti et al., 2008). This hyperexcitability may explain epileptic-like electrical activity often observed after ischemic stroke (Back et al., 1996). However, alterations in GABAergic inhibition appear to be more complex than a simple loss of GABA activity. Cortical GABAergic signalling contains both synaptic and extrasynaptic components, and these components are responsible for phasic and tonic inhibition, respectively (Clarkson et al., 2010). Reduced paired pulse inhibition would reflect a change in phasic inhibition, while more recent studies suggest that GABA_A-mediated tonic (extrasynaptic) inhibition may be potentiated for at least two weeks after stroke, likely due to impaired function of GABA transporters (GAT-3/GAT-4) (Clarkson et al., 2010). Moreover, selectively blocking tonic inhibition produces an early and sustained restoration of sensorimotor function, suggesting that counteracting heightened tonic inhibition after stroke may promote recovery in stroke patients (Clarkson et al., 2010).

3.2 Degeneration of areas distal to infarct

Regions that participate in post-stroke plasticity (to be discussed further in Section 4) typically share an anatomical connection with the brain region damaged by stroke. In a similar manner, focal damage in one area of the brain can lead to dysfunction and degeneration in neuroanatomically related brain areas.

Diffusion tensor imaging (DTI) (Basser et al., 1994) and tractography (Jones et al., 1999; Mori et al., 1999) are powerful new tools for evaluating white matter structure in human stroke patients in vivo. Changes in fractional anisotropy (FA), a DTI-derived measure of white matter microstructure (Beaulieu, 2002) can be used to map Wallerian and retrograde degeneration (Pierpaoli et al., 2001; Werring et al., 2000) or measure potentially beneficial changes in white matter structure (Crofts et al., 2011). DTI is a type of magnetic resonance imaging developed in the 1980s and involves the measurement of water diffusion rate and directionality, combined together to give what is called a tensor (Le Bihan et al., 2001). Tractography or fibre tracking is achieved by combining tensors mathematically. Since water preferentially diffuses along the orientation of white matter tracts, tractography can be used to assess the integrity of major white matter tracts such as the CST. DTI may be useful for predicting motor impairments early after an ischemic event, since changes in water diffusion are observable early after ischemic onset (Moseley, 1990; Le Bihan et al., 2001).

A recent study using DTI and computational network analysis revealed widespread changes in “communicability” based on white matter degeneration in stroke patients (Crofts et al., 2011). Communicability represents a measure of the integrity of both direct and indirect white matter connections between regions. Not surprisingly, reduced communicability was found in the ipsilesional hemisphere. However, communicability was also reduced in homotypical locations in the contralesional hemisphere, a finding that Croft et al. (2011) interpreted as evidence of secondary degeneration of white matter pathways in remote regions with direct or indirect connections with the infarcted territory. Notably, the authors also identified regions with increased communicability indicative of adaptive plasticity.

Thalamic atrophy has also been reported in the months following infarct in human stroke patients (Tamura et al., 1991). The thalamus is a main relay station for sensory afferents from multiple sensory modalities ascending to the cortex. Within the ventral nuclear group of the thalamus are the ventroposteromedial nucleus, a primary relay station for facial somatosensation, as well as the ventroposterolateral nucleus, the relay station somatosensation of the limbs and the body (Platz, 1994 and Steriade, 1988; Binkofski et al., 1996). After stroke, the ipsilesional thalamus exhibits hypometabolism and atrophy, likely due to a loss of cortical afferents and efferents (Binkofski et al., 2004; Fujie et al., 1990; Tamura et al., 1991). Dependent upon lesion size and location, one or both nuclei may contain neurons with shrunken cytoplasm and abnormal nuclei as well as elevated infiltration of microglia (Dihne et al., 2002; Iizuka et al., 1990). Although the majority of excitatory and inhibitory receptors lost originate from the ischemic core, a small but significant number of receptors are also lost in the retrogradely affected thalamic nuclei (Qü et al., 1998). Receptor densities are not affected in the contralateral thalamic nuclei (Qü et al., 1998). Thalamic degeneration after stroke appears to be progressive. Two weeks after MCAo in rats, ipsilesional thalamic volume is 87% of the contralateral thalamus, and falls to 77% at one month, 54% at three and six months (Fujie et al., 1990). This progressive atrophy likely results from degeneration of corticothalamic and thalamocortical pathways linking the thalamus to the infarcted cortex (Fujie et al., 1990; Iizuka et al., 1990; Tamura et al., 1991; Qü et al., 1998). Interestingly, vascular remodelling and neurogenesis in thalamic nuclei is enhanced in response to the secondary thalamic damage due to a cortical infarct (Ling et al., 2009).

3.3 Degeneration in the spinal cord

Following spinal cord injury, the inflammatory response leads to cell death and scar formation and damage of previously healthy tissue by cytotoxic inflammatory by-products (Hagg and Oudega, 2006; Weishaupt et al., 2010). As such, spinal cord injury is followed by degeneration of axons below the site of injury that are disconnected from their cell bodies. This is termed Wallerian degeneration (WD) as first described in 1850 by Waller. WD exhibits the following stereotypical course: (i) degeneration of axonal structures in the days following injury, (ii) infiltration of macrophages and degradation of myelin and (iii) gradual fibrosis and atrophy of fibre tracts. WD can affect many tracts including the corticothalamic tract, thalamocortical tract, descending corticospinal tract (CST) and ascending sensory fibre tracts, depending on the location of the injury. As described above, changes in white matter connectivity suggestive of WD have been reported in the contralesional cortex after stroke (Crofts et al., 2011).

The pathological time course of WD, including the degeneration of the axons and the degeneration of myelin in regions such as the CST, can be analyzed based on distinct DTI image characteristics acquired at different time points during stroke recovery (DeVetten et al., 2010; X. Liu et al., 2011; Yu et al., 2009). However, the heterogeneity of the stroke population has made clear inferences on the role of CST degeneration in sensorimotor disability difficult to make. The use of DTI in the first 3 days after stroke may not be useful for prognosis as WD in the spinal cord may not be detectable. However, DTI at 30 days post-stroke appear useful in defining prognosis and response to rehabilitation (Binkofski et al., 1996; Puig et al., 2010). Dynamic changes in WD can first be detected in the CST using DTI in the first two weeks following stroke and begin to stabilize by 3 months after injury (DeVetten et al., 2010; Puig et al., 2010; Yu et al., 2009). DTI studies suggest that sparing and integrity of the ipsilesional and contralesional CST can aid in prognosis for motor recovery

after stroke (Binkofski et al., 1996; DeVetten et al., 2010; Lindenberg et al., 2009, 2011; (Xiang) Liu et al., 2010; Madhavan et al., 2011; Puig et al., 2010; Schaechter et al., 2006; Thomalla et al., 2004; Yu et al., 2009). While patients that did not recover well from stroke had reduced FA in both corticospinal tracts relative to healthy controls, patients that exhibited good functional recovery had elevated FA in these same tracts (Schaechter et al., 2006).

Histological assessment in animal models has confirmed that focal stroke damaging the sensorimotor cortex induces secondary degeneration of the descending CST (Weishaupt et al., 2010). Damage to motor neurons in the forelimb motor cortex induces degeneration of their descending axons and activation of immune cells near their terminals in the cervical spinal cord. In the weeks following cortical injury, secondary damage extends past the cervical cord and progressive and delayed degeneration of descending CST fibres is observed in the thoracic spinal cord. An increased population of microglia was also observed in the cervical spinal cord within one week of infarction, and Weishaupt et al. (2010) suggest that this initial infiltration of microglia and concomitant release of pro-inflammatory and cytotoxic proteins is the likely mechanism of secondary damage to CST fibres terminating below the cervical cord.

4. Reactive plasticity after stroke

4.1 Plasticity in peri-infarct cortex

Stroke-induced impairments in motor, sensory and cognitive function improve over time, likely due to adaptive rewiring (plasticity) of damaged neural circuitry. Post-stroke plasticity includes physiological and anatomical changes that facilitate remapping of lost function onto surviving brain tissue through the expression of growth-promoting genes in peri-infarct cortex (Carmichael et al., 2005). These altered patterns of gene expression induce long-lasting increases in neuronal excitability (Centonze et al., 2007; Mittmann et al., 1998; Buchkremer-Ratzmann et al., 1996; Domann et al., 1993; Schiene et al., 1996; Butefisch et al., 2003; Manganotti et al., 2008; Hagemann et al., 1998). In addition to altered GABAergic transmission (discussed in Section 3.1), studies using animal models of focal stroke have demonstrated that NMDA receptor-mediated and non-NMDA receptor-mediated glutamate transmission are potentiated for four weeks after MCAo (Centonze et al., 2007; Mittmann et al., 1998). Long-term potentiation is also facilitated in peri-lesional cortex for seven days after focal cortical stroke (Hagemann et al., 1998), providing a favorable environment for functional rewiring of lost synaptic connections.

Moreover, stroke induces considerable neuronanatomical remodeling with elevated axonal sprouting, dendritic remodeling, and synaptogenesis persisting for weeks after stroke (Brown et al., 2007; Brown et al., 2009; Carmichael et al., 2001; Carmichael and Chesselet, 2002; Li et al., 1998; Stroemer et al., 1995). Changes in gene expression patterns of growth promoting and inhibiting factors occur early after ischemic onset and persist for months after injury, facilitating axonal growth and rewiring of injured tissue (Carmichael et al., 2005; Zhang et al., 2000). Growth-associated protein-43 (GAP-43) is an essential component of the growth cones of extending axons that is up regulated during development and after neuronal injury. mRNA expression for GAP-43 shows a two-fold increase as early as 3 days after stroke and remains up-regulated 28 days after injury (Carmichael et al., 2005). During long-term (months) recovery, a progression from axonal sprouting to synaptogenesis is suggested by increased synaptophysin (a presynaptic component of mature synapses) levels and a return to baseline GAP-43 levels (Stroemer et al., 1995; Carmichael, 2003). The expression of growth inhibiting

genes such as ephrin-A5 and brevican also fluctuate during recovery. For example, brevican mRNA increases slowly over time before peaking 28 days after stroke (Carmichael et al., 2005). It is therefore the balance of the expression profiles of growth promoting and growth inhibiting genes that govern adaptive plasticity after ischemic insult.

Adaptive plasticity includes significant neuroanatomical remodelling of the peri-infarct cortex. Neuroanatomical tract tracing has shown that this axonal sprouting leads to rewiring of local and distal intracortical projections (Brown et al., 2009; Carmichael et al., 2001; Dancause et al., 2005) with enhanced interhemispheric connectivity that correlates with improved sensorimotor function (van der Zijden et al., 2007; van der Zijden et al., 2008). Anatomical remodeling is also apparent in the dendritic trees of peri-infarct neurons. As the locus for the majority of excitatory synapses in the brain, dendritic spines provide the anatomical framework for excitatory neurotransmission. These spines show significant alterations to their structural morphology during the acute and chronic phases of stroke, including reversible dendritic blebbing, changes in spine length, dendritic spine retraction, and enhanced spine turnover in response to injury (Brown et al., 2007, 2008; Li and Murphy, 2008; Risher et al., 2010; Zhang et al., 2005, 2007). Dendritic spines are dynamic yet resilient during acute stroke. In cases where reperfusion of the ischemic area occurs within 60 minutes, dendritic blebbing and retraction cease and neuroanatomical structure is restored (Li and Murphy, 2008). Additionally, spines are highly dynamic during long-term stroke recovery. It has been suggested that dynamic changes in spine morphology are important during learning and adaptive plasticity (Majewska et al., 2006). Repeated imaging studies show an initial loss of dendritic spines in the hours after stroke followed by increased spine turnover (formation and elimination) during the weeks that follow (Brown et al., 2008). Because the degree of tissue reperfusion in the peri-infarct cortex varies with distance from the infarct core, greater perfusion rates further from the core are associated with greater spine densities after long-term recovery (Mostany et al., 2010). While dendritic arbors themselves are stable over several weeks in non-stroke animals, dendritic arbor remodeling, including both dendritic tip growth and retraction, is up-regulated within the first two weeks after stroke (Brown et al., 2010). However, this phenomenon appears restricted to the peri-infarct cortex, as dendrites farther from the stroke do not appear to exhibit large-scale structural plasticity (Mostany and Portera-Cailliau, 2011).

These physiological and anatomical changes facilitate functional reorganization of the cortex after stroke (Winship and Murphy, 2009). Reorganization of the motor cortex following focal stroke has been investigated in animal models and human patients using motor-mapping techniques. (Castro-Alamancos and Borrel, 1995; Friel et al., 2000; Frost et al., 2003; Remple et al., 2001; Kleim et al., 2003; Gharbawie et al., 2005; Nudo and Milliken, 1996; Traversa et al., 1997; Cicinelli et al., 1997) These studies show that ablation of the remapped cortex reinstates behavioural impairments (Castro-Alamancos and Borrel, 1995) and physical therapy induces an increase in motor map size that correlates with significant functional improvement (Liepert et al., 1998; Liepert et al., 2000).

Functional imaging has been used to demonstrate that patients with stroke-induced sensorimotor impairments show a reorganization of cortical activity evoked by stimulation of the stroke-affected limbs after stroke (Calautti and Baron, 2003; Carey et al., 2006; Chollet et al., 1991; Cramer et al., 1997; Cramer and Chopp, 2000; Herholz and Heiss, 2000; Jaillard et al., 2005; Nelles et al., 1999a; Nelles et al., 1999b; Seitz et al., 1998; Ward et al., 2003b; Ward et al., 2003ab; Ward et al., 2006; Weiller et al., 1993). Strikingly, increased activity in novel ipsilesional sensorimotor areas has been correlated with improved recovery in human

stroke patients (Fridman et al., 2004; Johansen-Berg et al., 2002b; Johansen-Berg et al., 2002a; Schaechter et al., 2006). A number of studies in animal models have used *in vivo* imaging to map regional reorganization of functional representations after stroke (van der Zijden et al., 2008; Dijkhuizen et al., 2001; Dijkhuizen et al., 2003; Weber et al., 2008). Winship and Murphy (2008) showed that small strokes damaging the forelimb somatosensory cortex resulted in posteromedial remapping of the forelimb representation. Moreover, the authors showed that adaptive re-mapping is initiated at the cellular level by surviving neurons adopting new roles in addition to their usual function. Later in recovery, these “multitasking” neurons become more selective to a particular stimulus, which may reflect a transitory phase in the progression from involvement in one sensorimotor function to a new function that replaces processing lost to stroke (Winship and Murphy, 2009). Increases in the receptive field size of peri-infarct neurons in the somatosensory cortex have also been reported using sensory-evoked electrophysiology (Jenkins & Merzenich, 1987; Reinecke et al., 2003) after focal lesions. Regional remapping has also been confirmed with voltage sensitive dye imaging (Brown et al., 2009). Eight weeks after targeted forelimb stroke, forelimb-evoked depolarizations reemerged in surviving portions of forelimb cortex and spread horizontally into neighboring peri-infarct motor and hindlimb areas. Notably, forelimb-evoked depolarization persisted 300-400% longer than controls, and was not limited to the remapped peri-infarct zone as similar changes were observed in the posteromedial retrosplenial cortex located millimeters from the stroke. More recent studies using voltage sensitive dyes suggests that forelimb-specific somatosensory cortex activity can be partially redistributed within one hour of ischemic damage, likely through unmasking of surviving ancillary pathways (Murphy et al., 2008; Sigler et al., 2009).

4.2 Contralesional cortical plasticity

While increased activity in novel ipsilesional sensorimotor areas has been correlated with improved recovery in human stroke patients, (Fridman et al., 2004; Johansen-Berg et al., 2002b; Johansen-Berg et al., 2002a; Schaechter et al., 2006) elevated contralesional activity has generally been associated with extensive infarcts and, as such, poor recovery (Calautti and Baron, 2003; Schaechter, 2004). Recruitment of the contralesional motor cortex in patients with extensive injury has been confirmed using transcranial magnetic stimulation and functional magnetic resonance imaging (Bestmann et al., 2010), suggesting that remote regions of the brain can participate in recovery from stroke under these conditions. Positron emission tomography (PET) scans have been used to demonstrate bilateral activation during movement (Bestmann et al., 2010; Cao et al., 1998; Chollet et al., 1991). Clinical observations also show that patients who have a second stroke in the contralesional hemisphere will have greater sensorimotor deficits and lose functional recovery of previously impaired abilities (Ago, 2003, Fisher, 1992 and Song, 2005 as cited by Riecker et al., 2010).

In some respects, clinical studies are in agreement with studies in animal models that have used a variety of imaging and electrophysiological assays and found altered patterns of somatosensory activation in both ipsilesional and contralesional cortex during recovery from stroke (Brown et al., 2009; Dijkhuizen et al., 2001; Dijkhuizen et al., 2003; Weber et al., 2008; Winship and Murphy, 2008; Wei et al., 2001; Abo et al., 2001). However, contralesional activation is not always observed (Weber et al., 2008) and, as in human stroke patients, good recovery from stroke-induced sensorimotor impairment is associated with the emergence or restoration of peri-lesional activity (Dijkhuizen et al., 2001; Dijkhuizen et al., 2003; Weber et al., 2008).

Functional recruitment of the contralesional cortex has been suggested by changes neuronal excitability, electrical activity, receptor densities, and dendritic structure in the days and weeks following ischemic insult in animal models. Biernaskie and Corbett (2001) showed that an enriched environment paired with a task-specific physical rehabilitation could elicit plasticity in dendritic arbors in the contralesional motor cortex that correlates with improved functional recovery on a skilled reaching task. Increases in NMDA receptor density in the homotypical motor cortex contralateral to a focal ischemic insult have been reported as early as two days after stroke and may persist for at least 24 days (Adkins et al., 2004; Hsu and Jones, 2006; Luhmann et al., 1995). Takatsuru and colleagues (2009) have recently identified adaptive changes in the structure and function of the homotypical contralateral cortex after focal stroke in sensorimotor cortex. Their data demonstrated that stimulus-evoked neuronal activity in the contralesional hemisphere was transiently potentiated two days after focal stroke. At four weeks post-stroke, behavioural recovery was complete and novel patterns of circuit activity were found in the intact contralateral hemisphere. Takatsuru et al. (2009) found anatomical correlates of this contralesional functional remapping using *in vivo* two-photon microscopy that identified a selective increase in the turnover rate of mushroom-type dendritic spines one week after stroke. Recently, Mohanjeran et al. (2011) investigated the effect of targeted strokes on contralateral sensory-evoked activity during the first two hours after occlusion using voltage-sensitive dye imaging. Blockade of a single surface arteriole in the mouse forelimb somatosensory cortex reduced the sensory-evoked response to contralateral forelimb stimulation. However, in the contralesional hemisphere, significantly enhanced sensory responses were evoked by stimulation of either forelimb within 30-50 min of stroke onset. Notably, acallosal mice showed similar rapid interhemispheric redistribution of sensory processing after stroke, and pharmacological thalamic inactivation before stroke prevented the contralateral changes in sensory-evoked activity. Combined, these data suggest that existing subcortical connections and not transcallosal projections mediate rapid redistribution of sensory-evoked activity.

4.3 Spinal plasticity after cortical injury

Previous sections have established that neuroanatomically connected regions distal to the infarct exhibit both degenerative and adaptive changes during recovery. As the host for the afferent somatosensory fibres and the efferent CST that control voluntary movement and somatosensation, plasticity in the spinal cord is ideally situated to play a role in functional recovery after stroke. The spontaneous regenerative capacity of the CST in the adult system after spinal cord injury was previously thought to be negligible. However, in recent years research has shown that even in the absence of intervention, the CST is able to spontaneously regenerate after partial lesion (Lundell et al., 2011). After an incomplete spinal cord injury, spared fibres are able to sprout and circumvent the injury site (Rosenzweig et al., 2010; Steward et al., 2008).

Recently, several studies have investigated axonal sprouting in the spinal cord induced by stroke in the brain, and its relation to stroke treatment or spontaneous recovery. Neuroanatomical tracers have been used to demonstrate that CST axons that originate in the uninjured hemisphere exhibit increased midline crossing and innervation of spinal grey matter that has been denervated by stroke (LaPash Daniels et al., 2009; Liu et al., 2009). Liu et al. (2009) used transynaptic retrograde tracers injected into the forepaw to show that spontaneous behavioural recovery after focal stroke was associated with an increase in retrogradely labelled axons in the stroke-affected cervical spinal cord one month after

stroke. Notably, transynaptic retrograde labelling of neuronal somata in the ischemic hemisphere was significantly reduced 11 days after MCAo, but a significant increase in retrograde labelling (relative to 11 days post) in both the injured and uninjured hemisphere was found one month after stroke. Similarly, plasticity-enhancing treatments that improve functional recovery often increases the number of CST fibres originating in the uninjured sensorimotor cortex that cross the midline and innervate the stroke-affected side of the cervical spinal cord. For example, treatment of focal stroke with bone marrow stromal cells (Z. Liu et al., 2007, 2008, 2011), anti-Nogo antibody infusion (Weissner et al., 2003; Tsai et al., 2007), and inosine (Zai et al., 2011) are all associated with improved functional recovery and increased innervation of the stroke-affected spinal cord by the unaffected CST originating contralateral to the stroke. While the role of axonal sprouting from the ipsilesional cortex is less defined, enhanced axonal sprouting in corticorubral and corticobulbar tracts originating in both the contralesional and ipsilesional cortex has been reported at the level of the brainstem after MCAo in mice (Reitmeir et al., 2011).

5. Summary

Permanent disabilities after ischemic stroke are dependent on the size and location of the infarct, and the pathophysiology through which the ischemic core expands into the vulnerable penumbral tissue has been well characterized. In the peri-infarct cortex, the relative contributions of excitotoxicity, peri-infarct depolarizations, inflammation and apoptosis are well characterized as they relate to infarct growth during ischemia (Dirnagl et al., 1999; Witte et al., 2000). However, degeneration and dysfunction is not confined to the infarct core and the surrounding peri-infarct cortex. Areas that are remote but neuroanatomically linked to the infarct, including the contralateral cortex, thalamus, and spinal cord exhibit altered neuronal excitability, blood flow, and metabolism after stroke. Moreover, degeneration of afferent or efferent connections with the infarcted territory can lead to atrophy and secondary damage in distal structures. Similarly, while the functional reorganization of peri-infarct cortex is well correlated with behavioural recovery, these distal but anatomically related regions also exhibit physiological and anatomical plasticity that may contribute to the resolution of stroke-induced impairments. An understanding of the adaptive plasticity and stroke-induced dysfunction in these remote areas may be important in developing and evaluating delayed strategies for neuroprotection and rehabilitation after stroke.

6. References

- Abo M., Chen Z., Lai L.J., Reese T., Bjelke B. (2001) Functional recovery after brain lesion--contralateral neuromodulation: An fMRI study. *Neuroreport*, Vol. 12, pp: (1543-1547).
- Adkins, D. L., Voorhies, A. C., & Jones, T. A. (2004). Behavioral and neuroplastic effects of focal endothelin-1 induced sensorimotor cortex lesions. *Neuroscience*, Vol. 128, No. 3, pp. (473-486).
- Alnemri, E. S., Livingston, D. J., Nicholson, D. W., Salvesen, G., Thornberry, N. A., Wong, W. W., et al. (1996). Human ICE/CED-3 protease nomenclature. *Cell*, Vol. 82, No. 2, pp. (171).
- Astrup, J., Siesjo, B.K., Symon, L. (1981) Threshold in cerebral ischemia- the ischemic penumbra. *Stroke*, Vol. 12, pp. (723-725).

- Back, T., Ginsberg, M. D., Dietrich, W D, & Watson, B. D. (1996). Induction of spreading depression in the ischemic hemisphere following experimental middle cerebral artery occlusion: effect on infarct morphology *Journal of cerebral blood flow and metabolism : official journal of the International Society of Cerebral Blood Flow and Metabolism*, Vol.16, No. 2, pp: (202-213).
- Baron, J. C., Boussier, M. G., Comar, D., & Castaigne, P. (1981). "Crossed cerebellar diaschisis" in human supratentorial brain infarction. *Transactions of the American Neurological Association*, Vol.105, pp. (459-461).
- Beaulieu, C. (2002). The basis of anisotropic water diffusion in the nervous system - a technical review. *NMR in Biomedicine*, Vol. 15, No. 7-8, pp. (435-455).
- Bestmann, S., Swayne, O., Blankenburg, F., Ruff, C. C., Teo, J., Weiskopf, N., et al. (2010). The role of contralesional dorsal premotor cortex after stroke as studied with concurrent TMS-fMRI. *The Journal of Neuroscience : The Official Journal of the Society for Neuroscience*, Vol. 30, No. 36, pp. (11926-11937).
- Biernaskie, J., & Corbett, D. (2001). Enriched Rehabilitative Training Promotes Improved Forelimb Motor Function and Enhanced Dendritic Growth after Focal Ischemic Injury, 1-9.
- Binkofski, F., Seitz, R. J., Arnold, S., Classen, J., Benecke, R., & Freund, H. J. (1996). Thalamic metabolism and corticospinal tract integrity determine motor recovery in stroke. *Annals of neurology*, Vol. 39, No. 4, pp. (460-470).
- Bolaños, J. P., Almeida, A., Stewart, V., Peuchen, S., Land, J. M., Clark, J. B., & Heales, S. J. (1997). Nitric oxide-mediated mitochondrial damage in the brain: mechanisms and implications for neurodegenerative diseases. *Journal of Neurochemistry*, Vol. 68, No. 6, pp. (2227-2240).
- Boutin, H., LeFeuvre, R. A., Horai, R., Asano, M., Iwakura, Y., & Rothwell, N. J. (2001). Role of IL-1alpha and IL-1beta in ischemic brain damage. *Journal of Neuroscience*, Vol. 21, No.15, pp. (5528-5534).
- Bredesen, D. E. (2000). Apoptosis: Overview and signal transduction pathways. *Journal of Neurotrauma*, Vol. 17, No. 10, pp. (801-810).
- Brodthmann, A., Puce, A., Darby, D., & Donnan, G. (2007). fMRI demonstrates diaschisis in the extrastriate visual cortex. *Stroke; a Journal of Cerebral Circulation*, Vol. 38, No. 8, pp. (2360-2363).
- Brookes, P. S., Bolaños, J. P., & Heales, S. J. (1999). The assumption that nitric oxide inhibits mitochondrial ATP synthesis is correct. *FEBS letters*, Vol. 446, No. 2-3, pp. (261-263).
- Brown C.E. & Murphy T.H. (2008a) Livin' on the edge: Imaging dendritic spine turnover in the peri-infarct zone during ischemic stroke and recovery. *Neuroscientist*, Vol. 14, pp. (139-146).
- Brown, C. E., Aminoltejari, K., Erb, H., Winship, I. R., & Murphy, T H. (2009a). In Vivo Voltage-Sensitive Dye Imaging in Adult Mice Reveals That Somatosensory Maps Lost to Stroke Are Replaced over Weeks by New Structural and Functional Circuits with Prolonged Modes of Activation within Both the Peri-Infarct Zone and Distant Sites. *Journal of Neuroscience*, Vol. 29, No. 6, pp. (1719-1734).
- Brown, C. E., Boyd, Jamie D, & Murphy, Timothy H. (2009b). Longitudinal in vivo imaging reveals balanced and branch-specific remodeling of mature cortical pyramidal dendritic arbors after stroke. *Journal of Cerebral Blood Flow & Metabolism*, Vol. 30, No. 4, pp. (783-791).

- Brown, C. E., Li, P., Boyd, J. D., Delaney, K. R., & Murphy, T. H. (2007). Extensive Turnover of Dendritic Spines and Vascular Remodeling in Cortical Tissues Recovering from Stroke. *Journal of Neuroscience*, Vol. 27, No. 15, pp. (4101–4109).
- Brown, C. E., Wong, C., & Murphy, T. H. (2008b). Rapid Morphologic Plasticity of Peri-Infarct Dendritic Spines After Focal Ischemic Stroke. *Stroke*, Vol. 39, No. 4, pp. (1286–1291).
- Brown, G. C., Bolaños, J. P., Heales, S. J., & Clark, J. B. (1995). Nitric oxide produced by activated astrocytes rapidly and reversibly inhibits cellular respiration. *Neuroscience Letters*, Vol. 193, No. 3, pp. (201–204).
- Buchkremer-Ratzmann, I., August, M., Hagemann, G., & Witte, O. W. (1996). Electrophysiological transcortical diaschisis after cortical photothrombosis in rat brain. *Stroke; a Journal of Cerebral Circulation*, Vol. 27, No. 6, pp. (1105–9).
- Buchkremer-Ratzmann, I., & Witte, O. W. (1997). Extended brain disinhibition following small photothrombotic lesions in rat frontal cortex. *Neuroreport*, Vol. 8, No. 2, pp. (519–522).
- Burwell, L. S., & Brookes, Paul S. (2008). Mitochondria as a target for the cardioprotective effects of nitric oxide in ischemia-reperfusion injury. *Antioxidants & redox signaling*, Vol. 10, No. 3, pp. (579–599).
- Busch, A. E., Quester, S., Ulzheimer, J. C., Waldegger, S., Gorboulev, V., Arndt, P., et al. (1996). Electrogenic properties and substrate specificity of the polyspecific rat cation transporter rOCT1. *The Journal of Biological Chemistry*, Vol. 271, No. 51, pp. (32599–32604).
- Butefisch, C. M., Netz, J., Wessling, M., Seitz, R. J., & Homberg, V. (2003). Remote changes in cortical excitability after stroke. *Brain : A Journal of Neurology*, Vol. 126, No. 2, pp. (470–481).
- Calautti, C., Jones, P. S., Naccarato, M., Sharma, N., Day, D. J., Bullmore, E. T., Warburton, E. A., et al. (2010). The relationship between motor deficit and primary motor cortex hemispheric activation balance after stroke: longitudinal fMRI study. *Journal of Neurology, Neurosurgery & Psychiatry*, Vol. 81, No. 7, pp. (788–792).
- Cao, Y., George, K. P., Ewing, J. R., Vikingstad, E. M., & Johnson, A. F. (1998). Neuroimaging of language and aphasia after stroke. *Journal of Stroke and Cerebrovascular Diseases : The Official Journal of National Stroke Association*, Vol. 7, No. 4, pp. (230–233).
- Carmichael S.T. & Chesselet M.F. (2002) Synchronous neuronal activity is a signal for axonal sprouting after cortical lesions in the adult. *Journal of Neuroscience*, Vol 22, pp. (6062–6070).
- Carmichael S.T., Wei L., Rovainen C.M., Woolsey T.A. (2001) New patterns of intracortical projections after focal cortical stroke. *Neurobiology of Disease*, Vol. 8, pp. (910–922).
- Carmichael, S.T. (2003) Plasticity of cortical projections after stroke. *Neuroscientist*, Vol 9, pp. (64–75).
- Carmichael, S. T., Tatsukawa, K., Katsman, D., Tsuyuguchi, N., & Kornblum, H. I. (2004). Evolution of diaschisis in a focal stroke model. *Stroke; a Journal of Cerebral Circulation*, Vol. 35, No. 3, pp. (758–763).
- Carmichael, S., Archibeque, I., Luke, L., Nolan, T., Momiy, J., & Li, S. (2005). Growth-associated gene expression after stroke: evidence for a growth-promoting region in peri-infarct cortex. *Experimental Neurology*, Vol. 193, No. 2, pp. (291–311).
- Carey J.R., Greer K.R., Grunewald T.K., Steele J.L., Wiemiller J.W., Bhatt E., Nagpal A., Lungu O., Auerbach E.J. (2006) Primary motor area activation during precision-

- demanding versus simple finger movement. *Neurorehabilitation and Neural Repair*, Vol. 20, pp. (361-370).
- Castro-Alamancos M.A., Borrel J. (1995) Functional recovery of forelimb response capacity after forelimb primary motor cortex damage in the rat is due to the reorganization of adjacent areas of cortex. *Neuroscience*, Vol.68, pp. (793-805).
- Centonze D., Rossi S., Tortiglione A., Picconi B., Prosperetti C., De Chiara V., Bernardi G., Calabresi P. (2007) Synaptic plasticity during recovery from permanent occlusion of the middle cerebral artery. *Neurobiology of Disease*, Vol. 27, pp. (44-53).
- Chollet F., DiPiero V., Wise R.J., Brooks D.J., Dolan R.J., Frackowiak R.S. (1991) The functional anatomy of motor recovery after stroke in humans: A study with positron emission tomography. *Annals of Neurology*, Vol. 29, pp. (63-71).
- Chuquet, J., Hollender, L., & Nimchinsky, E. A. (2007). High-resolution in vivo imaging of the neurovascular unit during spreading depression. *The Journal of Neuroscience : The Official Journal of the Society for Neuroscience*, Vol. 27, No. 15, pp. (4036-4044).
- Cicinelli P., Traversa R., Rossini P.M. (1997) Post-stroke reorganization of brain motor output to the hand: A 2-4 month follow-up with focal magnetic transcranial stimulation. *Electroencephalography and Clinical Neurophysiology*, Vol. 105, pp. (438-450).
- Clark, W. M., Wissman, S., Albers, G. W., Jhamandas, J. H., Madden, K. P., & Hamilton, S. (1999). Recombinant tissue-type plasminogen activator (Alteplase) for ischemic stroke 3 to 5 hours after symptom onset. The ATLANTIS Study: a randomized controlled trial. Alteplase Thrombolysis for Acute Noninterventional Therapy in Ischemic Stroke. *JAMA : the journal of the American Medical Association*, Vol. 282, No. 21, pp. (2019-2026).
- Clarkson, A. N., Huang, B. S., Macisaac, S. E., Mody, I., & Carmichael, S. T. (2010). Reducing excessive GABA-mediated tonic inhibition promotes functional recovery after stroke. *Nature*, Vol. 468, No. 7321, pp. (305-309).
- Clausen, B. H., Lambertsen, K. L., Babcock, A. A., Holm, T. H., Dagnaes-Hansen, F., & Finsen, B. (2008). Interleukin-1beta and tumor necrosis factor-alpha are expressed by different subsets of microglia and macrophages after ischemic stroke in mice. *Journal of neuroinflammation*, Vol. 5, pp. 46.
- Cramer, S. C. (2008). Repairing the human brain after stroke: I. mechanisms of spontaneous recovery. *Annals of Neurology*, Vol. 63, No. 3, pp. (272-287).
- Cramer S.C. & Chopp M. (2000) Recovery recapitulates ontogeny. *Trends in Neuroscience*, Vol. 23, pp. (265-271).
- Cramer S.C., Nelles G., Benson R.R., Kaplan J.D., Parker R.A., Kwong K.K., Kennedy D.N., Finklestein S.P., Rosen B.R. (1997) A functional MRI study of subjects recovered from hemiparetic stroke. *Stroke*, Vol. 28, pp. (2518-2527).
- Crofts, J. J., Higham, D. J., Bosnell, R., Jbabdi, S., Matthews, P. M., Behrens, T. E., et al. (2011). Network analysis detects changes in the contralesional hemisphere following stroke. *NeuroImage*, Vol. 54, No. 1, pp. (161-169).
- Dancause N., Barbay S., Frost S.B., Plautz E.J., Chen D., Zoubina E.V., Stowe A.M., Nudo R.J. (2005) Extensive cortical rewiring after brain injury. *Journal of Neuroscience*, Vol. 25, pp. (10167-10179).
- Danton, G.H. & Dietrich, W.D. (2003). Inflammatory mechanisms after ischemia and stroke. *Journal of Neuropathology and Experimental Neurology*, Vol. 62, No. 2, pp. 127-136.
- Del Zoppo, G. J., Saver, J. L., Jauch, E. C., Adams, H. P., Jr, & American Heart Association Stroke Council. (2009). Expansion of the time window for treatment of acute ischemic stroke with intravenous tissue plasminogen activator: A science advisory

- from the american heart Association/ American stroke association. *Stroke; a Journal of Cerebral Circulation*, Vol. 40, No. 8, pp. (2945-2948).
- De Reuck, J., Decoo, D., Lemahieu, I., Strijckmans, K., Goethals, P., & Van Maele, G. (1995). Ipsilateral thalamic diaschisis after middle cerebral artery infarction. *Journal of the Neurological Sciences*, Vol. 134, No. 1-2, pp. (130-135).
- DeVetten, G., Coutts, S. B., Hill, M. D., Goyal, M., Eesa, M., O'Brien, B., Demchuk, A. M., et al. (2010). Acute Corticospinal Tract Wallerian Degeneration Is Associated With Stroke Outcome. *Stroke*, Vol. 41, No. 4, pp. (751-756).
- Dettmers, C., Young, A., Rommel, T., Hartmann, A., Weingart, O., & Baron, J. C. (1993). CO₂ reactivity in the ischaemic core, penumbra, and normal tissue 6 hours after acute MCA-occlusion in primates. *Acta Neurochirurgica*, Vol. 125, No. 1-4, pp. (150-155).
- Dietrich, W., Dalton, Feng, Z.-C., Leistra, H., Watson, B. D., & Rosenthal, M. (2010). Photothrombotic infarction triggers multiple episodes of cortical spreading depression in distant brain regions. *Journal of Cerebral Blood Flow and Metabolism*, Vol. 14, pp. (20-28).
- Dihne, M., Grommes, C., Lutzenburg, M., Witte, O. W., & Block, F. (2002). Different Mechanisms of Secondary Neuronal Damage in Thalamic Nuclei After Focal Cerebral Ischemia in Rats. *Stroke*, Vol. 33, No. 12, pp. (3006-3011).
- Dijkhuizen R.M., Singhal A.B., Mandeville J.B., Wu O., Halpern E.F., Finklestein S.P., Rosen B.R., Lo E.H. (2003) Correlation between brain reorganization, ischemic damage, and neurologic status after transient focal cerebral ischemia in rats: A functional magnetic resonance imaging study. *Journal of Neuroscience*, Vol. 23, pp. (510-517).
- Dijkhuizen R.M., Ren J., Mandeville J.B., Wu O., Ozdag F.M., Moskowitz M.A., Rosen B.R., Finklestein S.P. (2001) Functional magnetic resonance imaging of reorganization in rat brain after stroke. *Proceedings of the National Academy of Sciences of the United States of America*, Vol. 98, pp. (12766-12771).
- Dirnagl, U., & Iadecola, C., Moskowitz M.A. (1999). Pathobiology of ischaemic stroke: an integrated view. *Trends in neurosciences*.
- Domann, R., Hagemann, G., Kraemer, M., Freund, H. J., & Witte, O. W. (1993). Electrophysiological changes in the surrounding brain tissue of photochemically induced cortical infarcts in the rat. *Neuroscience Letters*, Vol. 155, No. 1, pp. (69-72).
- Emsley, H. C., & Tyrrell, P. J. (2002). Inflammation and infection in clinical stroke. *Journal of Cerebral Blood Flow and Metabolism : Official Journal of the International Society of Cerebral Blood Flow and Metabolism*, Vol. 22, No. 12, pp. (1399-1419).
- Fair, D. A., Snyder, A. Z., Connor, L. T., Nardos, B., & Corbetta, M. (2009). Task-evoked BOLD responses are normal in areas of diaschisis after stroke. *Neurorehabilitation and Neural Repair*, Vol. 23, No. 1, pp. (52-57).
- Ferrer I., Planas A.M. (2003) Signaling of cell death and cell survival following focal cerebral ischemia: Life and death struggle in the penumbra. *Journal of Neuropathology and Experimental Neurology*, Vol. 62, pp. (329-339).
- Ferri, K. F., & Kroemer, G. (2001). Organelle-specific initiation of cell death pathways. *Nature Cell Biology*, Vol. 3, No. 11, pp. (E255-63).
- Finger, S., Koehler, P. J., & Jagella, C. (2004). The monakow concept of diaschisis: Origins and perspectives. *Archives of Neurology*, Vol. 61, No. 2, pp. (283-288).
- Fridman E.A., Hanakawa T., Chung M., Hummel F., Leiguarda R.C., Cohen L.G. (2004) Reorganization of the human ipsilesional premotor cortex after stroke. *Brain*, Vol. 127, pp. (747-758).

- Friel K.M., Heddings A.A., Nudo R.J. (2000) Effects of postlesion experience on behavioral recovery and neurophysiologic reorganization after cortical injury in primates. *Neurorehabilitation and Neural Repair*, Vol. 14, pp. (187-198).
- Frost S.B., Barbay S., Friel K.M., Plautz E.J., Nudo R.J. (2003) Reorganization of remote cortical regions after ischemic brain injury: A potential substrate for stroke recovery. *Journal of Neurophysiology*, Vol. 89, pp. (3205-3214).
- Fujie, W., Kirino, T., Tomukai, N., Iwasawa, T., & Tamura, A. (1990). Progressive shrinkage of the thalamus following middle cerebral artery occlusion in rats. *Stroke; a Journal of Cerebral Circulation*, Vol. 21, No. 10, pp. (1485-1488).
- Fujimura, M., Morita-Fujimura, Y., Murakami, K., Kawase, M., & Chan, P. H. (1998). Cytosolic redistribution of cytochrome c after transient focal cerebral ischemia in rats. *Journal of Cerebral Blood Flow and Metabolism : Official Journal of the International Society of Cerebral Blood Flow and Metabolism*, Vol. 18, No. 11, pp. (1239-1247).
- Fukui, K., Iguchi, I., Kito, A., Watanabe, Y., & Sugita, K. (1994). Extent of pontine pyramidal tract Wallerian degeneration and outcome after supratentorial hemorrhagic stroke. *Stroke*, Vol. 25, No. 6, pp. (1207-1210).
- Garrido, C., Galluzzi, L., Brunet, M., Puig, P. E., Didelot, C., & Kroemer, G. (2006). Mechanisms of cytochrome c release from mitochondria. *Cell Death and Differentiation*, Vol. 13, No. 9, pp. (1423-1433).
- Graham, S. H., & Chen, J. (2001). Programmed cell death in cerebral ischemia. *Journal of Cerebral Blood Flow and Metabolism : Official Journal of the International Society of Cerebral Blood Flow and Metabolism*, Vol. 21, No. 2, pp. (99-109).
- Gharbawie O.A., Gonzalez C.L., Williams P.T., Kleim J.A., Whishaw I.Q. (2005) Middle cerebral artery (MCA) stroke produces dysfunction in adjacent motor cortex as detected by intracortical microstimulation in rats. *Neuroscience*, Vol. 130, pp. (601-610).
- Hagemann G., Redecker C., Neumann-Haefelin T., Freund H.J., Witte O.W. (1998) Increased long-term potentiation in the surround of experimentally induced focal cortical infarction. *Annals of Neurology*, Vol. 44, pp. (255-258).
- Hallenbeck, J. M. (2002). The many faces of tumor necrosis factor in stroke. *Nature Medicine*, Vol. 8, No. 12, pp. (1363-1368).
- Hara H., Friedlander R.M., Gagliardini V., Ayata C., Fink K., Huang Z., Shimizu-Sasamata M., Yuan J., Moskowitz M.A. (1997) Inhibition of interleukin 1beta converting enzyme family proteases reduces ischemic and excitotoxic neuronal damage. *Proceedings of the National Academy of Sciences of the United States of America*, Vol. 94, pp. (2007-2012).
- Heiss, W. D., & Graf, R. (1994). The ischemic penumbra. *Current Opinion in Neurology*, Vol. 7, No. 1, pp. (11-19).
- Herholz K. & Heiss W.D. (2000) Functional imaging correlates of recovery after stroke in humans. *Journal of Cerebral Blood Flow and Metabolism*, Vol. 20, pp. (1619-1631).
- Hirata, K., Kuge, Y., Yokota, C., Harada, A., Kokame, K., Inoue, H., Kawashima, H., et al. (2011). Gene and protein analysis of brain derived neurotrophic factor expression in relation to neurological recovery induced by an enriched environment in a rat stroke model. *Neuroscience Letters*, Vol. 495, No. 3, pp. (210-215).
- Hoedt-Rasmussen, K. & Skinhoj, E. (1964). Transneuronal depression of the cerebral hemispheric metabolism in man. *Acta Neurologica Scandinavica*, Vol. 40, pp. (41-46).
- Hossmann, K. A. (1994). Viability thresholds and the penumbra of focal ischemia. *Annals of Neurology*, Vol. 36, No. 4, pp. (557-565).

- Hsu, J. E., & Jones, T. A. (2006). Contralesional neural plasticity and functional changes in the less-affected forelimb after large and small cortical infarcts in rats. *Experimental Neurology*, Vol. 201, No. 2, pp. (479-494).
- Iglesias, S., Marchal, G., Viader, F., & Baron, J. C. (2000). Delayed intrahemispheric remote hypometabolism. correlations with early recovery after stroke. *Cerebrovascular Diseases*, Vol. 10, No. 5, pp. (391-402).
- Iizuka, H., Sakatani, K., & Young, W. (2005). Neural damage in the rat thalamus after cortical infarcts. *Stroke*, pp. (1-6).
- Izumi, Y., Haida, M., Hata, T., Isozumi, K., Kurita, D., & Shinohara, Y. (2002). Distribution of brain oedema in the contralateral hemisphere after cerebral infarction: Repeated MRI measurement in the rat. *Journal of Clinical Neuroscience : Official Journal of the Neurosurgical Society of Australasia*, Vol. 9, No. 3, pp. (289-293).
- Jaillard A., Martin C.D., Garambois K., Lebas J.F., Hommel M. (2005) Vicarious function within the human primary motor cortex? A longitudinal fMRI stroke study. *Brain*, Vol. 128, pp. (1122-1138).
- Jenkins, W. M., & Merzenich, M. M. (1987). Reorganization of neocortical representations after brain injury: A neurophysiological model of the bases of recovery from stroke. *Progress in Brain Research*, Vol. 71, pp. (249-266).
- Jin, R., Yang, G., & Li, G. (2010). Inflammatory mechanisms in ischemic stroke: role of inflammatory cells. *Journal of Leukocyte Biology*, Vol. 87, No. 5, pp. (779-789).
- Johansen-Berg H., Dawes H., Guy C., Smith S.M., Wade D.T., Matthews P.M. (2002a) Correlation between motor improvements and altered fMRI activity after rehabilitative therapy. *Brain*, Vol. 125, pp. (2731-2742).
- Johansen-Berg H., Rushworth M.F., Bogdanovic M.D., Kischka U., Wimalaratna S., Matthews P.M. (2002b) The role of ipsilateral premotor cortex in hand movement after stroke. *Proceedings of the National Academy of Sciences of the United States of America*, Vol. 99, pp. (14518-14523).
- Jolkkonen, J., Gallagher, N. P., Zilles, Karl, & Sivenius, J. (2003). Behavioral deficits and recovery following transient focal cerebral ischemia in rats: glutamatergic and GABAergic receptor densities. *Behavioural brain research*, Vol. 138, No. 2, pp. (187-200).
- Jones, D. K., Simmons, A., Williams, S. C., & Horsfield, M. A. (1999). Non-invasive assessment of axonal fiber connectivity in the human brain via diffusion tensor MRI. *Magnetic Resonance in Medicine : Official Journal of the Society of Magnetic Resonance in Medicine / Society of Magnetic Resonance in Medicine*, Vol. 42, No. 1, pp. (37-41).
- Jones, T. A., Allred, R. P., Adkins, D. L., Hsu, J. E., O'Bryant, A., & Maldonado, M. A. (2009). Remodeling the brain with behavioral experience after stroke. *Stroke; a Journal of Cerebral Circulation*, Vol. 40, No. 3.
- Kamouchi, M., Fujishima, M., Saku, Y., Ibayashi, S., & Iida, M. (2004). Crossed cerebellar hypoperfusion in hyperacute ischemic stroke. *Journal of the Neurological Sciences*, Vol. 225, No. 1-2, pp. (65-69).
- Kaur J., Zhao Z., Klein G.M., Lo E.H., Buchan A.M. (2004) The neurotoxicity of tissue plasminogen activator? *Journal of Cerebral Blood Flow and Metabolism*, Vol. 24, pp. (945-963).
- Kempinsky, W.H., Boniface W.R., Keating, J.B., & Morgan, P.P. (1961). Serial hemodynamic study of cerebral infarction in man. *Circulation Research*, Vol. 9, pp. (1051-1058).
- Kleim J.A., Bruneau R., VandenBerg P., MacDonald E., Mulrooney R., Pocock D. (2003) Motor cortex stimulation enhances motor recovery and reduces peri-infarct dysfunction following ischemic insult. *Neurological Research*, Vol. 25, pp. (789-793).

- Lai, A. Y., & Todd, K. G. (2006). Microglia in cerebral ischemia: molecular actions and interactions. *Canadian journal of physiology and pharmacology*, Vol. 84, No. 1, pp. (49-59).
- Lansberg M.G., Bluhmki E., Thijs V.N. (2009) Efficacy and safety of tissue plasminogen activator 3 to 4.5 hours after acute ischemic stroke: A metaanalysis. *Stroke*, Vol. 40, pp. (2438-2441).
- LaPash Daniels, C. M., Ayers, K. L., Finley, A. M., Culver, J. P., & Goldberg, M. P. (2009). Axon sprouting in adult mouse spinal cord after motor cortex stroke. *Neuroscience Letters*, Vol. 450, No. 2, pp. (191-195).
- Le D.A., Wu Y., Huang Z., Matsushita K., Plesnila N., Augustinack J.C., Hyman B.T., Yuan J., Kuida K., Flavell R.A., Moskowitz M.A. (2002) Caspase activation and neuroprotection in caspase-3- deficient mice after in vivo cerebral ischemia and in vitro oxygen glucose deprivation. *Proceedings of the National Academy of Sciences of the United States of America*, Vol. 99, pp. (15188-15193).
- Le Bihan, D., Mangin, J. F., Poupon, C., Clark, C. A., Pappata, S., Molko, N., et al. (2001). Diffusion tensor imaging: Concepts and applications. *Journal of Magnetic Resonance Imaging : JMRI*, Vol. 13, No. 4, pp. (534-546).
- Legos, J. J., Whitmore, R. G., Erhardt, J. A., Parsons, A. A., Tuma, R. F., & Barone, F. C. (2000). Quantitative changes in interleukin proteins following focal stroke in the rat. *Neuroscience Letters*, Vol. 282, No. 3, pp. (189-192).
- Lenzi, G. L., Frackowiak, R. S., & Jones, T. (1982). Cerebral oxygen metabolism and blood flow in human cerebral ischemic infarction. *Journal of Cerebral Blood Flow and Metabolism : Official Journal of the International Society of Cerebral Blood Flow and Metabolism*, Vol. 2, No. 3, pp. (321-335).
- Lewén, A., Matz, P., & Chan, P H. (2000). Free radical pathways in CNS injury. *Journal of neurotrauma*, Vol. 17, No. 10, pp. (871-890).
- Li Y., Jiang N., Powers C., Chopp M. (1998) Neuronal damage and plasticity identified by microtubule-associated protein 2, growth-associated protein 43, and cyclin D1 immunoreactivity after focal cerebral ischemia in rats. *Stroke*, Vol. 29, pp. (1972-80).
- Li, P. and Murphy, T.H. (2008). Two-photon imaging during prolonged middle cerebral artery occlusion in mice reveals recovery of dendritic structure after reperfusion. *Journal of Neuroscience*, Vol. 28, No. 46, pp. (11970-11979).
- Liepert J., Bauder H., Wolfgang H.R., Miltner W.H., Taub E., Weiller C. (2000) Treatment-induced cortical reorganization after stroke in humans. *Stroke*, Vol. 31, pp. (1210-1216).
- Liepert J., Miltner W.H., Bauder H., Sommer M., Dettmers C., Taub E., Weiller C. (1998) Motor cortex plasticity during constraint-induced movement therapy in stroke patients. *Neuroscience Letters*, Vol. 250, pp. (5-8).
- Lindberg, P. G., Bensmail, D., Bussel, B., Maier, M. A., & Feydy, A. (2010). Wallerian Degeneration in Lateral Cervical Spinal Cord Detected with Diffusion Tensor Imaging in Four Chronic Stroke Patients. *Journal of Neuroimaging*, Vol. 21, No. 1, pp. (44-48).
- Lindenberg, R., Zhu, L. L., Rüber, T., & Schlaug, G. (2011). Predicting functional motor potential in chronic stroke patients using diffusion tensor imaging. *Human brain mapping*.
- Ling, L., Zeng, J., Pei, Z., Cheung, R. T., Hou, Q., Xing, S., & Zhang, S. (2009). Neurogenesis and angiogenesis within the ipsilateral thalamus with secondary damage after focal cortical infarction in hypertensive rats, Vol. 29, No. 9, pp. (1538-1546).
- Liu, K., Lu, Y., Lee, J. K., Samara, R., Willenberg, R., Sears-Kraxberger, I., Tedeschi, A., et al. (2010). PTEN deletion enhances the regenerative ability of adult corticospinal neurons. *Nature Neuroscience*, Vol. 13, No. 9, pp. (1075-1081).

- Liu, X., Tian, W., Qiu, X., Li, J., Thomson, S., Li, L., & Wang, H. Z. (2011). Correlation Analysis of Quantitative Diffusion Parameters in Ipsilateral Cerebral Peduncle during Wallerian Degeneration with Motor Function Outcome after Cerebral Ischemic Stroke. *Journal of Neuroimaging*,
- Liu, Y., Liu, X.-J., & Dandan, S. (2009a). Ion transporters and ischemic mitochondrial dysfunction. *Cell Adhesion & Migration*, Vol. 3, No. 1, pp. (94-98).
- Liu, Z., Li, Y., Qu, R., Shen, L., Gao, Q., Zhang, X., Lu, M., et al. (2007). Axonal sprouting into the denervated spinal cord and synaptic and postsynaptic protein expression in the spinal cord after transplantation of bone marrow stromal cell in stroke rats. *Brain Research*, Vol. 1149, pp. (172-180).
- Liu, Z., Li, Y., Zhang, R. L., Cui, Y., & Chopp, M. (2011). Bone Marrow Stromal Cells Promote Skilled Motor Recovery and Enhance Contralateral Axonal Connections After Ischemic Stroke in Adult Mice. *Stroke*, Vol. 42, No. 3, pp. (740-744).
- Liu, Z., Li, Y., Zhang, X., Savant-Bhonsale, S., & Chopp, Michael. (2008). Contralateral axonal remodeling of the corticospinal system in adult rats after stroke and bone marrow stromal cell treatment. *Stroke*, Vol. 39, No. 9, pp. (2571-2577).
- Liu, Z., Zhang, R. L., Li, Y., Cui, Y., & Chopp, M. (2009). Remodeling of the Corticospinal Innervation and Spontaneous Behavioral Recovery After Ischemic Stroke in Adult Mice. *Stroke*, Vol. 40, No. 7, pp. (2546-2551).
- Liu, X., Tian, W., Li, L., Kolar, B., Qiu, X., Chen, F., & Dogra, V. S. (2011). Hyperintensity on diffusion weighted image along ipsilateral cortical spinal tract after cerebral ischemic stroke: A diffusion tensor analysis. *European Journal of Radiology*,
- Liu, Y., Karonen, J. O., Nuutinen, J., Vanninen, E., Kuikka, J. T., & Vanninen, R. L. (2007). Crossed cerebellar diaschisis in acute ischemic stroke: A study with serial SPECT and MRI. *Journal of Cerebral Blood Flow and Metabolism : Official Journal of the International Society of Cerebral Blood Flow and Metabolism*, Vol. 27, No. 10, pp. (1724-1732).
- Luhmann, H. J., Mudrick-Donnon, L. A., Mittmann, T., & Heinemann, U. (1995). Ischaemia-induced long-term hyperexcitability in rat neocortex. *The European Journal of Neuroscience*, Vol. 7, No. 2, pp. (180-191).
- Lundell, H., Christensen, M. S., Barthélemy, D., Willerslev-Olsen, M., Biering-Sørensen, F., & Nielsen, J. B. (2011). Cerebral activation is correlated to regional atrophy of the spinal cord and functional motor disability in spinal cord injured individuals. *NeuroImage*, Vol. 54, No. 2, pp. (1254-1261).
- Mabuchi, T., Kitagawa, K., Ohtsuki, T., Kuwabara, K., Yagita, Y., Yanagihara, T., Hori, M., et al. (2000). Contribution of microglia/macrophages to expansion of infarction and response of oligodendrocytes after focal cerebral ischemia in rats. *Stroke*, Vol. 31, No. 7, pp. (1735-1743).
- Madhavan, S., Krishnan, C., Jayaraman, A., Rymer, W. Z., & Stinear, J. W. (2011). Corticospinal tract integrity correlates with knee extensor weakness in chronic stroke survivors. *Clinical neurophysiology*, pp. (1-7).
- Majewska, A. K. (2006). Remodeling of Synaptic Structure in Sensory Cortical Areas In Vivo. *Journal of Neuroscience*, Vol. 26, No. 11, pp. (3021-3029).
- Manganotti, P., Acler, M., Zanette, G. P., Smania, N., & Fiaschi, A. (2008). Motor cortical disinhibition during early and late recovery after stroke. *Neurorehabilitation and Neural Repair*, Vol. 22, No. 4, pp. (396-403).
- Mergenthaler P., Dirnagl U., Meisel A. (2004) Pathophysiology of stroke: Lessons from animal models. *Metabolic Brain Disease*, Vol. 19, pp. (151-167).


- Minnerup, J., Kim, J. B., Schmidt, A., Diederich, K., Bauer, H., Schilling, M., Strecker, J. K., et al. (2011). Effects of Neural Progenitor Cells on Sensorimotor Recovery and Endogenous Repair Mechanisms After Photothrombotic Stroke. *Stroke*, Vol. 42, No. 6, pp. (1757–1763).
- Mittmann T., Qu M., Zilles K., Luhmann H.J. (1998) Long-term cellular dysfunction after focal cerebral ischemia: In vitro analyses. *Neuroscience*, Vol. 85, pp. (15-27).
- Mohajerani, M. H., Aminoltejari, K., & Murphy, T. H. (2011). Targeted mini-strokes produce changes in interhemispheric sensory signal processing that are indicative of disinhibition within minutes. *Proceedings of the National Academy of Sciences of the United States of America*, Vol. 108, No. 22, pp. (E183-91).
- Mori, S., Crain, B. J., Chacko, V. P., & van Zijl, P. C. (1999). Three-dimensional tracking of axonal projections in the brain by magnetic resonance imaging. *Annals of Neurology*, Vol. 45, No. 2, pp. (265-269).
- Mostany, R., Chowdhury, T. G., Johnston, D. G., Portonovo, S. A., Carmichael, S. T., & Portera-Cailliau, C. (2010). Local Hemodynamics Dictate Long-Term Dendritic Plasticity in Peri-Infarct Cortex. *Journal of Neuroscience*, Vol. 30, No. 42, pp. (14116–14126).
- Mostany, R., & Portera-Cailliau, C. (2011). Absence of Large-Scale Dendritic Plasticity of Layer 5 Pyramidal Neurons in Peri-Infarct Cortex. *Journal of Neuroscience*, Vol. 31, No. 5, pp. (1734–1738).
- Murphy, Timothy H, & Corbett, D. (2009). Plasticity during stroke recovery: from synapse to behaviour. *Nature Reviews Neuroscience*, Vol. 10, No. 12, pp. (861–872).
- Murphy, T. H., Li, P., Betts, K., & Liu, R. (2008). Two-photon imaging of stroke onset in vivo reveals that NMDA-receptor independent ischemic depolarization is the major cause of rapid reversible damage to dendrites and spines. *Journal of Neuroscience*, Vol. 28, No. 7, pp. (1756–1772).
- Nagasawa, H., Kogure, K., Fujiwara, T., Itoh, M., & Ido, T. (1994). Metabolic disturbances in exo-focal brain areas after cortical stroke studied by positron emission tomography. *Journal of the Neurological Sciences*, Vol. 123, No. 1-2, pp. (147-153).
- Nawashiro H., Martin D., Hallenbeck J.M. (1997) Neuroprotective effects of TNF binding protein in focal cerebral ischemia. *Brain Research*, Vol. 778, pp. (265-271).
- Nelles G., Spiekermann G., Jueptner M., Leonhardt G., Muller S., Gerhard H., Diener H.C. (1999a) Evolution of functional reorganization in hemiplegic stroke: A serial positron emission tomographic activation study. *Annals of Neurology*, Vol. 46, pp. (901-909).
- Nelles G., Spiekermann G., Jueptner M., Leonhardt G., Muller S., Gerhard H., Diener H.C. (1999b) Reorganization of sensory and motor systems in hemiplegic stroke patients. A positron emission tomography study. *Stroke*, Vol. 30, pp. (1510-1516).
- Neumann-Haefelin, T., Hagemann, G., & Witte, O. W. (1995). Cellular correlates of neuronal hyperexcitability in the vicinity of photochemically induced cortical infarcts in rats in vitro. *Neuroscience Letters*, Vol. 193, No. 2, pp. (101-104).
- Neumann-Haefelin, T., Bosse, F., Redecker, C., Muller, H. W., & Witte, O. W. (1999). Upregulation of GABAA-receptor alpha1- and alpha2-subunit mRNAs following ischemic cortical lesions in rats. *Brain Research*, Vol. 816, No. 1, pp. (234-237).
- Niizuma, K., Endo, H., & Chan, Pak H. (2009). Oxidative stress and mitochondrial dysfunction as determinants of ischemic neuronal death and survival. *Journal of Neurochemistry*, Vol. 109, pp. (133–138).
- NINDS Tissue plasminogen activator for acute ischemic stroke. the national institute of neurological disorders and stroke rt-PA stroke study group. (1995) *New England Journal of Medicine*, Vol. 333, pp. (1581-1587).

- Nudo R.J. & Milliken G.W. (1996) Reorganization of movement representations in primary motor cortex following focal ischemic infarcts in adult squirrel monkeys. *Journal of Neurophysiology*, Vol. 75, pp. (2144-2149).
- O'Brien, M. D., Waltz, A. G., & Jordan, M. M. (1974). Ischemic cerebral edema. distribution of water in brains of cats after occlusion of the middle cerebral artery. *Archives of Neurology*, Vol. 30, No. 6, pp. (456-460).
- Pettigrew, L. C., Kindy, M. S., Scheff, S., Springer, J. E., Kryscio, R. J., Li, Y., et al. (2008). Focal cerebral ischemia in the TNFalpha-transgenic rat. *Journal of Neuroinflammation*, Vol. 5, pp. (47).
- Pierpaoli, C., Barnett, A., Pajevic, S., Chen, R., Penix, L. R., Virta, A., et al. (2001). Water diffusion changes in wallerian degeneration and their dependence on white matter architecture. *NeuroImage*, Vol. 13, No. 6, pp. (1174-1185).
- Platz, T., Denzler, P., Kaden, B., & Mauritz, K. H. (1994). Motor learning after recovery from hemiparesis. *Neuropsychologia*, Vol. 32, No. 10, pp. (1209-1223).
- Puig, J., Pedraza, S., Blasco, G., Daunis-I-Estadella, J., Prats, A., Prados, F., Boada, I., et al. (2010). Wallerian degeneration in the corticospinal tract evaluated by diffusion tensor imaging correlates with motor deficit 30 days after middle cerebral artery ischemic stroke. *AJNR. American journal of neuroradiology*, Vol. 31, No. 7, pp. (1324-1330).
- Que, M., Schiene, K., Witte, O. W., & Zilles, K. (1999). Widespread up-regulation of N-methyl-D-aspartate receptors after focal photothrombotic lesion in rat brain. *Neuroscience Letters*, Vol. 273, No. 2, pp. (77-80).
- Qü, M., Mittmann, T., Luhmann, H. J., Schleicher, A., & Zilles, K. (1998). Long-term changes of ionotropic glutamate and GABA receptors after unilateral permanent focal cerebral ischemia in the mouse brain. *Neuroscience*, Vol.85, No. 1, pp. (29-43).
- Reinecke, S., Dinse, H. R., Reinke, H., & Witte, O. W. (2003). Induction of bilateral plasticity in sensory cortical maps by small unilateral cortical infarcts in rats. *The European Journal of Neuroscience*, Vol. 17, No. 3, pp. (623-627).
- Reitmeir, R., Kilic, E., Kilic, U., Bacigaluppi, M., ElAli, A., Salani, G., Pluchino, S., et al. (2011). Post-acute delivery of erythropoietin induces stroke recovery by promoting perilesional tissue remodelling and contralesional pyramidal tract plasticity. *Brain : a journal of neurology*, Vol.134, No. 1, pp. (84-99).
- Remple M.S., Bruneau R.M., VandenBerg P.M., Goertzen C., Kleim J.A. (2001) Sensitivity of cortical movement representations to motor experience: Evidence that skill learning but not strength training induces cortical reorganization. *Behavioral Brain Research*, Vol. 123, pp. (133-141).
- Riecker, A., Gröschel, K., Ackermann, H., Schnaudigel, S., Kassubek, J., & Kastrup, A. (2010). The role of the unaffected hemisphere in motor recovery after stroke. *Human brain mapping*, Vol. 31, No. 7, pp. (1017-1029).
- Ritter, L. S., Orozco, J. A., Coull, B. M., McDonagh, P. F., & Rosenblum, W. I. (2000). Leukocyte accumulation and hemodynamic changes in the cerebral microcirculation during early reperfusion after stroke. *Stroke; a Journal of Cerebral Circulation*, Vol. 31, No. 5, pp. (1153-1161).
- Rosenzweig, E. S., Courtine, G., Jindrich, D. L., Brock, J. H., Ferguson, A. R., Strand, S. C., Nout, Y. S., et al. (2010). Extensive spontaneous plasticity of corticospinal projections after primate spinal cord injury. *Nature Neuroscience*, Vol. 13, No. 12, pp. (1505-1510).
- Schaechter J.D. (2004) Motor rehabilitation and brain plasticity after hemiparetic stroke. *Progress in Neurobiology*, Vol. 73, pp. (61-72).

- Schaechter J.D., Moore C.I., Connell B.D., Rosen B.R., Dijkhuizen R.M. (2006) Structural and functional plasticity in the somatosensory cortex of chronic stroke patients. *Brain*, Vol. 129, pp. (2722-2733).
- Schiene, K., Bruehl, C., Zilles, K., Qü, M., Hagemann, G., Kraemer, M., & Witte, O. W. (1996). Neuronal hyperexcitability and reduction of GABAA-receptor expression in the surround of cerebral photothrombosis. *Journal of cerebral blood flow and metabolism : official journal of the International Society of Cerebral Blood Flow and Metabolism*, Vol. 16, No. 5, pp. (906-914).
- Seitz R.J., Hoflich P., Binkofski F., Tellmann L., Herzog H., Freund H.J. (1998) Role of the premotor cortex in recovery from middle cerebral artery infarction. *Archives of Neurology*, Vol. 55, pp. (1081-1088).
- Sigler, A., Mohajerani, M. H., & Murphy, T. H. (2009). Imaging rapid redistribution of sensory-evoked depolarization through existing cortical pathways after targeted stroke in mice. *Proceedings of the National Academy of Sciences of the United States of America*, Vol. 106, No. 28, pp. (11759-11764).
- Slater, R., Reivich, M., Goldberg, H., Banka, R., & Greenberg, J. (1977). Diaschisis with cerebral infarction. *Stroke; a Journal of Cerebral Circulation*, Vol. 8, No. 6, pp. (684-690).
- Somjen, G. G. (2001). Mechanisms of spreading depression and hypoxic spreading depression-like depolarization. *Physiological Reviews*, Vol. 81, No. 3, pp. (1065-1096).
- Steriade, M., & Llinas, R. R. (1988). The functional states of the thalamus and the associated neuronal interplay. *Physiological Reviews*, Vol. 68, No. 3, pp. (649-742).
- Steward, O., Zheng, B., Tessier-Lavigne, M., Hofstadter, M., Sharp, K., & Yee, K. M. (2008). Regenerative Growth of Corticospinal Tract Axons via the Ventral Column after Spinal Cord Injury in Mice. *Journal of Neuroscience*, Vol. 28, No. 27, pp. (6836-6847).
- Stroemer, R. P., Kent, T. A., & Hulsebosch, C. E. (1995). Neocortical neural sprouting, synaptogenesis, and behavioral recovery after neocortical infarction in rats. *Stroke*, Vol. 26, No. 11, pp. (2135-2144).
- Takasawa, M., Watanabe, M., Yamamoto, S., Hoshi, T., Sasaki, T., Hashikawa, K., . . . Kinoshita, N. (2002). Prognostic value of subacute crossed cerebellar diaschisis: Single-photon emission CT study in patients with middle cerebral artery territory infarct. *AJNR. American Journal of Neuroradiology*, Vol. 23, No. 2, pp. (189-193).
- Takatsuru, Y., Fukumoto, D., Yoshitomo, M., Nemoto, T., Tsukada, H., & Nabekura, J. (2009). Neuronal Circuit Remodeling in the Contralateral Cortical Hemisphere during Functional Recovery from Cerebral Infarction. *Journal of Neuroscience*, Vol. 29, No. 32, pp. (10081-10086).
- Tamura, A., Tahira, Y., Nagashima, H., Kirino, T., Gotoh, O., Hojo, S., & Sano, K. (1991). Thalamic atrophy following cerebral infarction in the territory of the middle cerebral artery. *Stroke*, Vol. 22, No. 5, pp. (615-618).
- Thomalla, G., Glauche, V., Koch, M., Beaulieu, C., Weiller, C., & Rother, J. (2004). Diffusion tensor imaging detects early Wallerian degeneration of the pyramidal tract after ischemic stroke. *NeuroImage*, Vol. 22, No. 4, pp. (1767-1774).
- Thornton, P., McColl, B. W., Greenhalgh, A., Denes, A., Allan, S. M., & Rothwell, N. J. (2010). Platelet interleukin-1alpha drives cerebrovascular inflammation. *Blood*, Vol. 115, No. 17, pp. (3632-3639).
- Traversa R., Cicinelli P., Bassi A., Rossini P.M., Bernardi G. (1997) Mapping of motor cortical reorganization after stroke. A brain stimulation study with focal magnetic pulses. *Stroke*, Vol. 28, pp. (110-117).

- Tsai, S. Y., Markus, T. M., Andrews, E. M., Cheatwood, J. L., Emerick, A. J., Mir, A. K., et al. (2007). Intrathecal treatment with anti-nogo-A antibody improves functional recovery in adult rats after stroke. *Experimental Brain Research. Experimentelle Hirnforschung. Experimentation Cerebrale*, Vol. 182, No. 2, pp. (261-266).
- Umegaki, M. (2005). Peri-Infarct Depolarizations Reveal Penumbra-Like Conditions in Striatum. *Journal of Neuroscience*, Vol. 25, No. 6, pp. (1387-1394).
- van der Zijden J.P., van der Toorn A., van der Marel K., Dijkhuizen R.M. (2008) Longitudinal in vivo MRI of alterations in perilesional tissue after transient ischemic stroke in rats. *Experimental Neurology*, Vol. 212, pp. (207-212).
- van der Zijden J.P., Wu O., van der Toorn A., Roeling T.P., Bleys R.L., Dijkhuizen R.M. (2007) Changes in neuronal connectivity after stroke in rats as studied by serial manganese-enhanced MRI. *Neuroimage*, Vol. 34, pp. (1650-1657).
- Vila, Nicolás, Castillo, J., Dávalos, A., Esteve, A., Planas, A. M., & Chamorro, A. (2003). Levels of anti-inflammatory cytokines and neurological worsening in acute ischemic stroke. *Stroke*, Vol. 34, No. 3, pp. (671-675).
- Vila, N, Castillo, J., Dávalos, A., & Chamorro, A. (2000). Proinflammatory cytokines and early neurological worsening in ischemic stroke. *Stroke*, Vol. 31, No. 10, pp. (2325-2329).
- Wang, T., Wang, J., Yin, C., Liu, R., Zhang, J. H., & Qin, X. (2010). Down-regulation of Nogo receptor promotes functional recovery by enhancing axonal connectivity after experimental stroke in rats. *Brain Research*, Vo. 1360, pp. (147-158).
- Ward N.S., Brown M.M., Thompson A.J., Frackowiak R.S. (2006) Longitudinal changes in cerebral response to proprioceptive input in individual patients after stroke: An fMRI study. *Neurorehabilitation and Neural Repair*, Vol. 20, pp. (398-405).
- Ward, N. S., Brown, M. M., Thompson, A. J., & Frackowiak, R. S. (2003). Neural correlates of outcome after stroke: A cross-sectional fMRI study. *Brain : A Journal of Neurology*, Vol. 126, No. 6, pp. (1430-1448).
- Weber R., Ramos-Cabrer P., Justicia C., Wiedermann D., Strecker C., Sprenger C., Hoehn M. (2008) Early prediction of functional recovery after experimental stroke: Functional magnetic resonance imaging, electrophysiology, and behavioral testing in rats. *Journal of Neuroscience*, Vol. 28, pp. (1022-1029).
- Wei L., Erinjeri J.P., Rovainen C.M., Woolsey T.A. (2001) Collateral growth and angiogenesis around cortical stroke. *Stroke*, Vol. 32, pp. (2179-2184).
- Weiller C., Ramsay S.C., Wise R.J., Friston K.J., Frackowiak R.S. (1993) Individual patterns of functional reorganization in the human cerebral cortex after capsular infarction. *Annals of Neurology*, Vol. 33, pp. (181-189).
- Weishaupt, N., Silasi, G., Colbourne, F., Fouad, K. (2010). Secondary damage in the spinal cord after motor cortex injury in rats. *Journal of Neurotrauma*, Vol. 27, pp. (1387-1397).
- Werring, D. J., Toosy, A. T., Clark, C. A., Parker, G. J., Barker, G. J., Miller, D. H., et al. (2000). Diffusion tensor imaging can detect and quantify corticospinal tract degeneration after stroke. *Journal of Neurology, Neurosurgery, and Psychiatry*, Vol. 69, No. 2, pp. (269-272).
- Wiessner, C., Bareyre, F. M., Allegrini, P. R., Mir, A. K., Frentzel, S., Zurini, M., et al. (2003). Anti-nogo-A antibody infusion 24 hours after experimental stroke improved behavioral outcome and corticospinal plasticity in normotensive and spontaneously hypertensive rats. *Journal of Cerebral Blood Flow and Metabolism : Official Journal of the International Society of Cerebral Blood Flow and Metabolism*, Vol. 23, No. 2, pp. (154-165).

- Winship, I. R., & Murphy, T. H. (2009). Remapping the Somatosensory Cortex after Stroke: Insight from Imaging the Synapse to Network. *The Neuroscientist*, Vol. 15, No. 5, pp. (507-524).
- Winship I.R. & Murphy T.H. (2008) In vivo calcium imaging reveals functional rewiring of single somatosensory neurons after stroke. *Journal of Neuroscience*, Vol. 28, pp. (6592-6606).
- Witte, O. W., Bidmon, H. J., Schiene, K., Redecker, C., & Hagemann, G. (2000). Functional differentiation of multiple perilesional zones after focal cerebral ischemia. *Journal of Cerebral Blood Flow and Metabolism : Official Journal of the International Society of Cerebral Blood Flow and Metabolism*, Vol. 20, No. 8, pp. (1149-1165).
- Wolf, T., Lindauer, U., Reuter, U., Back, T., Villringer, A., Einhaupl, K., et al. (1997). Noninvasive near infrared spectroscopy monitoring of regional cerebral blood oxygenation changes during peri-infarct depolarizations in focal cerebral ischemia in the rat. *Journal of Cerebral Blood Flow and Metabolism : Official Journal of the International Society of Cerebral Blood Flow and Metabolism*, Vol. 17, No. 9, pp. (950-954).
- Yu, C., Zhu, C., Zhang, Y., Chen, H., Qin, W., Wang, M., & Li, K. (2009). A longitudinal diffusion tensor imaging study on Wallerian degeneration of corticospinal tract after motor pathway stroke. *NeuroImage*, Vol. 47, No. 2, pp. (451-458). ISSN: 1053-8119
- Zai, L., Ferrari, C., Dice, C., Subbaiah, S., Havton, L. A., Coppola, G., et al. (2011). Inosine augments the effects of a nogo receptor blocker and of environmental enrichment to restore skilled forelimb use after stroke. *The Journal of Neuroscience : The Official Journal of the Society for Neuroscience*, Vol. 31, No. 16, pp. (5977-5988).
- Zhang, S., & Murphy, Timothy H. (2007). Imaging the impact of cortical microcirculation on synaptic structure and sensory-evoked hemodynamic responses in vivo. *PLoS biology*, Vol. 5, No. 5, pp. (e119).
- Zhang, Y., Xiong, Y., Mahmood, A., Meng, Y., Liu, Z., Qu, C., & Chopp, M. (2010). Sprouting of corticospinal tract axons from the contralateral hemisphere into the denervated side of the spinal cord is associated with functional recovery in adult rat after traumatic brain injury and erythropoietin treatment. *Brain Research*, Vol. 1353, pp. (249-257).
- Zipfel, G. J., Babcock, D. J., Lee, J. M., & Choi, D. W. (2000). Neuronal apoptosis after CNS injury: The roles of glutamate and calcium. *Journal of Neurotrauma*, Vol. 17, No. 10, pp. (857-869).



Acute Ischemic Stroke

Edited by Prof. Julio Cesar Garcia Rodriguez

ISBN 978-953-307-983-7

Hard cover, 236 pages

Publisher InTech

Published online 18, January, 2012

Published in print edition January, 2012

Despite significant technological advances in recent years, their impact on our overall health and social, well-being is not always clear to see. Perhaps, one of the best examples of this can be highlighted by the fact that mortality rates as a result of cerebrovascular diseases have hardly changed, if at all. This places cerebrovascular diseases as one of the most prominent causes of both disability and death. In Cuba, for instance, a total of 22,000 cases of cerebrovascular diseases are reported each year in a country where life expectancy should increase to 80 years in the near future. In such a situation, to have a book that includes in a clear and summarized way, a group of topics directly related to the preclinical investigations advances and the therapeutic procedures for the cerebrovascular disease in its acute phase constitutes a useful tool for the wide range of the contributors to this affection's problems solution. In this group is included students, professors, researchers, and health policy makers whose work represents one of the greatest social and human impact challenges of the XXI century basic and clinical neurosciences.

How to reference

In order to correctly reference this scholarly work, feel free to copy and paste the following:

Bernice Sist, Sam Joshva Baskar Jesudasan and Ian R. Winship (2012). Diaschisis, Degeneration, and Adaptive Plasticity After Focal Ischemic Stroke, *Acute Ischemic Stroke*, Prof. Julio Cesar Garcia Rodriguez (Ed.), ISBN: 978-953-307-983-7, InTech, Available from: <http://www.intechopen.com/books/acute-ischemic-stroke/diaschisis-degeneration-and-adaptive-plasticity-after-focal-ischemic-stroke>

INTech
open science | open minds

InTech Europe

University Campus STeP Ri
Slavka Krautzeka 83/A
51000 Rijeka, Croatia
Phone: +385 (51) 770 447
Fax: +385 (51) 686 166
www.intechopen.com

InTech China

Unit 405, Office Block, Hotel Equatorial Shanghai
No.65, Yan An Road (West), Shanghai, 200040, China
中国上海市延安西路65号上海国际贵都大饭店办公楼405单元
Phone: +86-21-62489820
Fax: +86-21-62489821

© 2012 The Author(s). Licensee IntechOpen. This is an open access article distributed under the terms of the [Creative Commons Attribution 3.0 License](https://creativecommons.org/licenses/by/3.0/), which permits unrestricted use, distribution, and reproduction in any medium, provided the original work is properly cited.

IntechOpen

IntechOpen