

# We are IntechOpen, the world's leading publisher of Open Access books Built by scientists, for scientists

6,900

Open access books available

186,000

International authors and editors

200M

Downloads

Our authors are among the

154

Countries delivered to

TOP 1%

most cited scientists

12.2%

Contributors from top 500 universities



WEB OF SCIENCE™

Selection of our books indexed in the Book Citation Index  
in Web of Science™ Core Collection (BKCI)

Interested in publishing with us?  
Contact [book.department@intechopen.com](mailto:book.department@intechopen.com)

Numbers displayed above are based on latest data collected.  
For more information visit [www.intechopen.com](http://www.intechopen.com)



# Acute Pancreatitis During Pregnancy

Tea Štimac and Davor Štimac<sup>1</sup>  
*Department of Gynecology & Obstetrics*

<sup>1</sup>*Division of Gastroenterology, Department of Internal Medicine  
 University Hospital Rijeka  
 Croatia*

## 1. Introduction

Acute pancreatitis is rare and serious complication during pregnancy, estimated to occur in 1/1000 to 1/12000 pregnancies (Ramin et al., 1995). Discrepancy in incidence is because of the rarity of disease and because studies span different decades and countries. Acute pancreatitis appears to be more prevalent with advanced gestational stage, occurring more commonly in the second and the third trimester (Hernandez et al., 2007; Ramin et al., 2001). Ramin and al. noted that 19% of acute pancreatitis occurs in the first, 26% in the second, 53% in the third and 2% in the postpartum period, while others reported most of cases, 56%, in the second trimester (Hernandez et al., 2007; Ramin et al., 1995).

The most frequent etiology of acute pancreatitis in pregnancy is biliary caused by gallstones or sludge (Wang et al., 2009). Other causes are hyperlipidemia and alcohol abuse. Rarely it could be, also, caused by hyperparathyroidism, connective tissue diseases, abdominal surgery, infections (viral, bacterial or parasitic), blunt abdominal injuries or could be iatrogenic caused by medications (diuretics, antibiotics, antihypertensive drugs) (Wang et al., 2009; Ramin et al., 1995).

In pregnancy gallstones and sludge induce most of the cases of acute pancreatitis, they cause duct obstruction with pancreatic hyperstimulation that increases pancreatic duct pressure, trypsin reflux and activation of trypsin in the pancreatic acinar cells. This leads to enzyme activation within pancreas and causes autodigestion of the gland, followed by local inflammation. Pregnancy does not primarily predispose the pregnant woman to pancreatitis, but it does increase the risk of cholelithiasis and biliary sludge formation (Ramin et al., 1995). Theoretical reasons for the association of pregnancy and biliary tract diseases include increased bile acid pool size, decreased enterohepatic circulation, decreased percentage of chenodeoxycholic acid, and increased percentage of cholic acid and cholesterol secretion and bile stasis (Scott, 1992). Moreover, the steroid hormones of pregnancy decrease gallbladder motility (Ramin et al., 1995). Progesterone is a smooth muscle cell inhibitor that provokes gallbladder volume increase and slows emptying (Ramin et al., 1995). Estrogens increase cholesterol secretion and minimally alter gallbladder function (Ramin et al., 1995). Also in the third trimester when the acute pancreatitis is most frequent, the uterus is enlarged and intrabdominal pressure on the biliary ducts is increased (Berk et al., 1971).

## 2. Clinical features

Acute pancreatitis presents essentially in the same way during pregnancy as in the non-pregnant state. However, it is difficult to diagnose acute pancreatitis by history and physical examination because of similarity to many acute abdominal illnesses.

### 2.1 Symptomatology

Acute pancreatitis in pregnancy is mainly related to gallbladder disorders and correlates with cholelithiasis and biliary sludge (muddy sediment, precursor to gallstone formation) as the most likely predisposing causes (Ramin et al., 1995). The symptoms of gallbladder disease can be present or can precede the clinical presentation of acute pancreatitis. The symptoms include abdominal pain (colicky or stabbing) which may radiate to the right flank, scapula and shoulder. Onset of pain is rapid, with maximal intensity in 10 to 20 minutes. Pain is steady and moderate to severe. Band-like radiation of the pain to the back occurs in half of patients. Other symptoms of gallbladder disease include anorexia, nausea, vomiting, dyspepsia, low-grade fever, tachycardia and fatty food intolerance (Ramin et al., 1995).

### 2.2 Physical examination

Physical findings vary with the severity of illness, in moderate to severe pancreatitis the patient appears acutely ill and is found lying in the “fetal position” with flexed knees, hips and trunk. Abdominal tenderness is often found; in diffuse peritonitis muscle rigidity can be present. Bowel sounds, secondary to paralytic ileus, are usually hypoactive or absent. In severe pancreatitis the general physical examination may reveal abnormal vital signs if there are third-space fluid losses and systemic toxicity. Due to hypovolemia tachycardia up to 150/min and low blood pressure could be found. Also, because of severe retroperitoneal inflammatory process temperature may increase. Dyspnea, tachypnea and shallow respirations resulting with hypoxemia may be present. Altered maternal acid-base status can adversely affect fetal acid-base status. Acute fetal hypoxia activates some compensatory mechanisms for redistribution of blood that enable fetus to achieve a constancy of oxygen consumption in the fetal cerebral circulation and in fetal myocardium. Redistribution of blood to vital organs enable fetus to survive for moderately long period of limited oxygen supply, but during more severe or sustained hypoxemia, these responses were no longer maintained and decompensation with fetal tissue damage and even fetal death may occur (Crisan et al., 2009; Date et al., 2008).

Some physical findings point to a specific cause of acute pancreatitis: jaundice in biliary origin, spider angiomas in alcoholic or xanthomas and lipemia retinalis in hyperlipidemic pancreatitis.

## 3. Diagnosis

Acute pancreatitis in pregnancy is diagnosed by symptoms already described, by laboratory investigations and imaging methods.

### 3.1 Laboratory diagnosis

Laboratory investigations are the same as in non-pregnant and relies on at least a three-fold elevation of serum amylase and lipase levels in the blood. The total serum amylase level rises within 6 to 12 hours of onset of the disease, usually remain elevated for three to five

days. However, there are several conditions (i.e. pathologic processes in salivary glands, fallopian tubes, bowel obstruction, cholecystitis, hepatic trauma, perforative duodenal ulcer, hyperamylasemia on familial basis...) that may result in elevation of serum amylase. Serum lipase is elevated on the first day of illness and remains elevated longer than the serum amylase. Specificity of serum lipase is greater than amylase, lipase level is normal in salivary gland disorder, tumors, gynecologic conditions and familial macroamylasemia. Calculation of an amylase to creatinine clearance ratio may be helpful in pregnancy, ratio greater than 5% suggests acute pancreatitis (Augustin&Majerovic, 2007).

### 3.2 Imaging methods

Imaging in pregnancy remains a controversial issue with concern of the effect of radiation on the developing fetus. Abdominal ultrasound (US) is the ideal imaging technique for detection of dilated pancreatic ducts and pseudocysts and focal accumulations larger than 2 to 3 cm. US has no radiation risk to the fetus, but is limited by operator skill, patient obesity and bowel dilatation. Computed tomography (CT) should be avoided, especially during the first trimester, because of radiation exposure to the fetus, but has to be performed when benefits outweigh the risk. When a common bile duct stone is suspected, endoscopic ultrasound (EUS) has a high positive predictive value nearing 100%, even for small stones  $\leq 2$ mm or sludge (Pitchumoni & Yegneswaran, 2009). EUS is considered to be the best imaging study to evaluate common bile duct, but requires expensive equipment, intravenous sedation and technical expertise. It is superior to magnetic resonance cholangiopancreatography (MRCP), an imaging method providing multi - planar large field of view images of the biliary-pancreatic ductal system. There are some concerns about the safety of MRCP in the first trimester of pregnancy because radiofrequency pulses result in energy deposition and could potentially result in tissue heating (Leyendecker et al., 2004). MR procedures are indicated in pregnancy if other non-ionizing forms of diagnostic imaging studies are inadequate, or if the examination provides information that would otherwise require exposure to ionizing radiation. Endoscopic retrograde cholangiopancreatography (ERCP) as a diagnostic tool lost its value because of the risk of radiation and the availability of safer procedures (i.e. EUS or MRCP). ERCP should be used only as a therapeutic option in selected cases with confirmed bile duct stones. In cases of severe acute biliary pancreatitis (SABP) with or without cholangitis, early ERCP, preferably within 24 hours, is recommended (Banks&Freeman, 2006). Decompression of the common bile duct and removal of gallstones with subsequent papillotomy could prevent complications and reduce mortality in SABP. Before proceeding to therapeutic ERCP, a less-invasive diagnostic method such as MRCP or EUS should be performed. In pregnancy it is necessary to minimize radiation exposure during ERCP, the procedure should be carried out only by a very experienced endoscopic and radiologic team and the fetus should be shielded all the time (Chong & Jalihal, 2010; O'Mahony, 2007). With the advent of ERCP and MRCP, the need for IOC (intraoperative cholangiogram) is minimal, although there have been no reports investigating the safety of IOC during pregnancy (Date et al., 2008). Laparoscopic US scan appears to be alternative to retained common bile duct stones (Date et al., 2008).

## 4. Treatment

### 4.1 Conventional treatment measures

The initial management of acute pancreatitis during pregnancy is similar to management in non-pregnant patients. Treatment consists of fluid restoration, oxygen, analgetics,

antiemetics and monitoring of vital signs. Important additional measures during pregnancy include fetal monitoring, attention to the choice of medications and positioning of the mother to avoid inferior vena cava constriction.

Mild pancreatitis treated conservatively usually resolves within 7 days. Ten percent of patients have severe course, and they are best managed in an intensive care unit. The third space fluid sequestration is the most serious hemodynamic disorder leading to hypovolemia and organ hypoperfusion resulting in multiple organ failure. In volume-depleted patients the essential treatment modality is initial infusion of 500 to 1000 mL of fluid per hour (Gardner et al., 2008). Monitoring of hydration, cardiovascular, renal and respiratory functions is important for early detection of volume overload and electrolyte disturbances (Forsmark & Baillie, 2007).

Many pharmacological agents (somatostatin, octreotide, n-acetyl-cystein, gabexate mesylate, lexipafant and probiotics) have been investigated in acute pancreatitis, but because most of them have failed to show a positive effect they should be avoided in pregnancy.

Cessation of oral feeding has been thought to suppress the exocrine function of pancreas, and to prevent further pancreatic autodigestion. Bowel rest is associated with increased infectious complications, and total parenteral nutrition (TPN) and enteral nutrition (EN) have an important role in the management of acute pancreatitis. Keeping the patients "*nil by mouth*" with the use of TPN has been for years a traditional treatment of acute pancreatitis, but carries a significant risk of infections and metabolic distress. EN is physiological, helps the gut flora maintain the gut mucosal immunity, reduced translocation of bacteria, while simultaneously avoiding all the risks of TPN.

Mild cases of acute pancreatitis do not need nutritional support, as the clinical course is usually uncomplicated and a low-fat diet can be started within 3 to 5 days.

Treatment of severe necrotising pancreatitis should include enteral feeding by nasojejunal tube and if needed, should be supplemented by parenteral nutrition (Meier et al., 2006).

Prophylactic use of antibiotics is very controversial and the choice of antibiotic in pregnancy is difficult. There are concerns with regarding to the antibiotic being transplacentally transferred to the fetus with a risk of teratogenicity. Antibiotics have no role in the treatment of mild acute pancreatitis. The use of prophylactic antibiotics in severe acute pancreatitis remains controversial. The available evidence demonstrates that antibiotic prophylaxis might have a protective effect against non-pancreatic infections, but failed to show a benefit on reduction of mortality, infected necrosis and need for surgical intervention (Bai Y et al., 2010; Jafri, 2009). Due to the lack of evidence on beneficial effect of antibiotics, an even more conservative approach is recommended in pregnancy.

#### 4.2 Surgical treatment

Surgical treatment of pancreatitis has two aspects, which include operative intervention for the disease itself and surgical management of associated biliary tract disease once acute inflammation subsides (Ramin et al., 1995).

Since, first study published in 1963 (Greene et al., 1963), the dilemma, whether or not to treat pregnant patients with gall-stones conservatively, still exists. Risk of conservative treatment include risk to the fetus due to recurrent episodes, complications of gallstones, risk of malnutrition caused by lack of oral intake. Conversely, surgical treatment carries risk to the fetus from surgery and anaesthesia and risk specific to laparoscopic surgery. Laparoscopic cholecystectomy (once considered contraindicated during pregnancy) (Gadacz & Talamini,



1991), is today, probably, the best treatment for the patients failed to respond to conservative management or because of recurrent episodes (Cosenza et al., 1999; SAGES Guidelines, 2011). Benefits of laparoscopy during pregnancy appear similar to those non-pregnant patients including less postoperative pain, less postoperative ileus, significantly reduced hospitalization, decreased narcotic use and quick return to a regular diet and faster recovery. Other advantages of laparoscopy include less manipulation of the uterus and detection of other pathology that may be present and because of early mobility reduced risk of postoperative deep vein thrombosis (Date et al., 2008). Cholecystectomy is considered safe at all stages of pregnancy, and may be performed in any trimester of pregnancy without any increased risk to the mother or fetus (Cosenza et al., 1999; SAGES Guidelines, 2011). Historical recommendations to delay surgery until the second trimester or gestational age limit of 26 to 28 weeks of pregnancy have been refuted. Laparoscopy in pregnancy was connected with the fear of damage to the gravid uterus upon Veress or trocar insertion, technical difficulty in performing the surgery with the presence of an enlarged, gravid uterus and the concern of fetal acidemia due to decreased uterine blood flow because of increased intraabdominal pressure from insufflation and possible fetal carbon dioxide absorption (Wang et al., 2009). Also, maternal venous return secondary to increased intraperitoneal pressure from CO<sub>2</sub> insufflation could be present. The use of a uterine manipulator is contraindicated in pregnancy. At the beginning of 2011, The Society of American Gastrointestinal and Endoscopic Surgeons (SAGES) updated its guidelines for laparoscopy during pregnancy (SAGES Guidelines, 2011). Recent reports suggest that the risk of fetal wasting and teratogenicity from gastrointestinal operation during pregnancy is minimal (Barone et al., 1999). However, some precautions should be followed: the use of an open technique for the insertion of the umbilical port, avoiding high intraperitoneal pressures, using of left lateral position to minimize aortocaval compression, avoiding rapid changes in the position of the patient and using electrocautery cautiously and away from uterus (Date et al., 2008).

Early cholecystectomy should be performed in patients with mild acute biliary pancreatitis while patients with SABP should undergo this procedure within 4 and 6 weeks, respectively, after hospital discharge (Forsmark & Baillie, 2007).

While sterile necrosis is treated conservatively, infected necrosis requires the use of antibiotics and surgical necrosectomy. Patients with infected necrosis should be treated surgically within 3 to 4 weeks after the onset of symptoms. Minimal invasive surgical techniques are new in the management of acute pancreatitis with only a few relatively small series reported to date (Van Santvoort et al., 2007).

A diagnostic and therapeutic algorithm for acute pancreatitis in pregnancy is proposed in Diagramm 1 (Stimac & Stimac, *in press*)

## 5. Outcome

Prognosis for women with mild disease who respond to conservative management is excellent for mother and fetus. However, for more severe form of disease, mother mortality and fetal morbidity and mortality rates increase. In 1973 Wilkinson reviewed 98 cases of acute pancreatitis during pregnancy, 30 patients died (Wilkinson, 1973). Also, fetal death was noted in 60% of cases. Recently, the percentage of fatal outcomes of acute pancreatitis has been less than 5% (Talukdar & Vege, 2009) and is similar in pregnancy (Hernandez et al., 2007). In the past decades high perinatal mortality rate, up to 50% (Wilkinson, 1973)

secondary to acute pancreatitis resulted from neonatal deaths after preterm delivery, but improvements in neonatal intensive and supportive care play important role in premature babies' survival. The mechanisms of demise include, also, placental abruption and profound metabolic disturbance, including acidosis. This highlights the importance of regular fetal monitoring and consideration of delivery if the maternal disease is deteriorating.

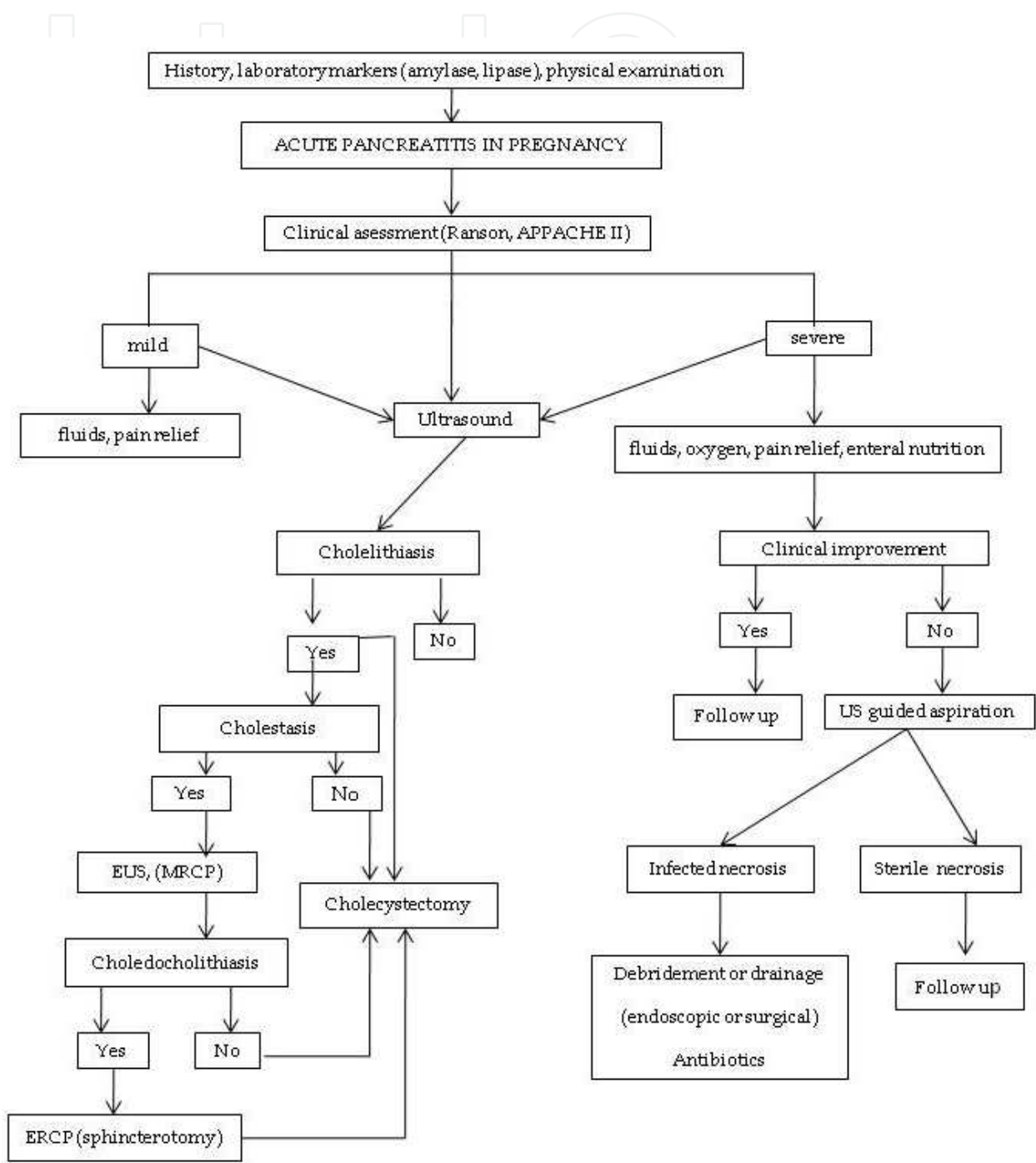


Diagramm 1. Diagnostic and therapeutic alghorithm - acute pancreatitis in pregnancy

## 6. Conclusions

Acute pancreatitis is a rare entity in pregnancy, mainly caused by gallbladder disorders, in which symptoms of cholelithiasis and biliary sludge in many cases precede the symptoms and clinical picture of acute pancreatitis. Diagnosis is based on clinical presentation, laboratory investigations and imaging methods performed with precaution because of potential radiation risk to the fetus.

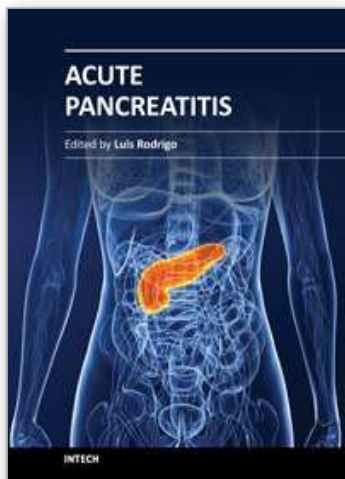
General management of mild AP in pregnancy is conservative and supportive, while severe AP deserves hospitalisation in intensive care unit and endoscopic or surgical interventions. The most common in pregnancy - biliary pancreatitis, can be resolved with urgent ERCP sphincterotomy and laparoscopic cholecystectomy preferably in second trimester, when technical conditions are optimal and risk for fetus and pregnant woman minimized. Although treatment of acute pancreatitis during pregnancy is similar to general approach in acute pancreatitis patients, a multidisciplinary team consisting of gastroenterologist, gastrointestinal surgeon, radiologist and obstetrician should be included in the treatment and follow up of these patients.

## 7. References

- Augustin, G. & Majerovic, M. (2007). Non-obstetrical acute abdomen during pregnancy. *Eur J Obstet Gynecol Reprod Biol* Vol.131, No.1, (Mar 2007), pp. 4-12
- Bai, Y.; Gao, J.; Zou, DW. & Li, ZS. (2010). Antibiotics prophylaxis in acute necrotizing pancreatitis: an update. *Am J Gastroenterol* Vol. 103, No. 1, (Mar 2010), pp. 705-7
- Banks, PA. & Freeman ML. (2006). Practice guidelines in acute pancreatitis. *Am J Gastroenterol* Vol. 101, No. 10, (Oct 2006), pp. 2379-400
- Barone, JE.; Bears, S.; Chen, S.; Tsai, J. & Russell, JC. (1999). Outcome study of cholecystectomy during pregnancy. *Am J Surg* Vol. 177, No. 3 (Mar 1999), pp. 232-6
- Berk, JE.; Smith, BH. & Krawi, MM (1971). Pregnancy pancreatitis. *Am J Gastroenterol* Vol. 56, No. 2 (Sep 1971), pp.216-26
- Chong, VH. & Jalihal, A. (2010). Endoscopic management of biliary disorders during pregnancy. *Hepatobiliary Pancreat Dis Int* Vol. 9, No. 2 (Apr 2010), pp. 180-5
- Cosenza, CA.; Saffari, B.; Jabbour, N.; Stain, SC.; Garry, D.; Parekh, D. & Selby, RR. (1999). Surgical management of biliary gallstone disease during pregnancy. *Am J Surg* Vol. 178, No. 6 (Dec 1999), pp. 545-8
- Crisan, LS.; Steidl, ET. & Rivera-Alsina, ME. (2008). Acute hyperlipidemic pancreatitis in pregnancy. *Am J Obstet Gynecol* Vol. 198, No. 5 (May 2008), pp.e57-9
- Date, RS.; Kaushal, M. & Ramesh, A.(2008). A review of the management of gallstone disease and its complications in pregnancy. *Am J Surg* 2008; Vol. 196, No. 4 (Oct 2008), pp. 599-608
- Forsmark, CE. & Baillie, J. (2007). AGA Institute technical review on acute pancreatitis. *Gastroenterology* Vol. 132, No. 5 (May 2007), pp. 2022-44
- Gadacz, TR. & Talamini, MA. (1991). Traditional versus laparoscopic cholecystectomy. *Am J Surg* Vol. 161, No. 3 (Mar 1991), pp. 336-8
- Gardner, TB., Vege, SS., Pearson, RK. & Chari, ST. (2008). Fluid resuscitation in acute pancreatitis. *Clin Gastroel Hepatol* Vol. 6, No. 10 (Oct 2008), pp. 1070-6
- Guidelines for diagnosis, treatment, and use of laparoscopy for surgical problems during pregnancy: this statement was reviewed and approved by the Board of Governors



- of the Society of American Gastrointestinal and Endoscopic Surgeons (SAGES). (2008). *Surg Endosc* Vol. 22, No. 4 (Apr 2008), pp. 849-61
- Hernandez, A., Petrov, MS., Brooks, DC., Banks, PA., Ashley, SW. & Tavakkolizadeh, A. (2007). Acute pancreatitis in pregnancy: a 10-year single center experience. *J Gastrointest Surg* Vol. 11, No. 12 (Dec 2007), pp.1623-7
- Jafri, NS., Mahid SS, Idstein SR., Hornung, CA. & Galandiuk S. (2009). Antibiotic prophylaxis is not protective in severe acute pancreatitis: a systematic review and meta-analysis. *Am J Surg* Vol. 197, No. 6 (Jun 2009), pp. 806-13
- Leyendecker, JR., Gorengaut, V. & Brown, JJ. (2004). MR imaging of maternal diseases of the abdomen and pelvis during pregnancy and the immediate postpartum period. *Radiographics* Vol. 24, No. 5 (Sep-Oct 2004), pp. 1301-16
- Meier, R., Ockenga, J., Pertkiewicz, M., Pap, A., Milinic, N. & Macfie, J. (2006). ESPEN guidelines on enteral nutrition: pancreas. *Clin Nutr* Vol. 25, No. 2 (Apr 2006), pp. 275-84
- O'Mahony, S. (2007). Endoscopy in pregnancy. *Best Pract Res Clin Gastroenterol* Vol. 21, No. 5 (May 2007), pp. 893-9
- Pitchumoni, CS. & Yegneswaran, B. (2009). Acute pancreatitis in pregnancy. *World J Gastroenterol* Vol. 15, No. 45 (Dec 2009), pp. 5641-6
- Ramin, KD., Ramin, SM., Richey, SD. & Cunningham, FG. (1995). Acute pancreatitis in pregnancy. *Am J Obstet Gynecol* Vol. 173, No. 1 (Jul 1995), pp. 187-91
- Ramin, KD. & Ramsey, PS. (2001). Disease of the gallbladder and pancreas in pregnancy. *Obstet Gynecol Clin North Am* Vol. 28, No. 3 (Sep 2001), pp. 571-80
- Stimac D. & Stimac T (in press). Acute pancreatitis in pregnancy. *EJGH* (in press)
- Talukdar, R. & Vege, SS. (2009). Recent developments in acute pancreatitis. *Clin Gastroenterol Hepatol* Vol. 7, No. 11 Suppl. (Nov 2009), S3-S9
- Van Santvoort, HC., Besselink, MG., Horvath, KD., Sinanan, MN., Bollen, TL., Van Ramshorst, B. & Gooszen, HG. (2007). Videoscopic assisted retroperitoneal debridement in infected necrotizing pancreatitis. *HPB* Vol. 9, No. 2 (Feb 2007), pp. 156-9
- Wang, GJ., Gao, CF., Wei, D., Wang, C. & Ding, SQ. (2009). Acute pancreatitis: Etiology and common pathogenesis. *World J Gastroenterol* Vol. 15, No. 12 (Mar 2009), pp. 1427-30
- Wilkinson, EJ. (1973). Acute pancreatitis in pregnancy: a review of 98 cases and a report of 8 new cases. *Obstet Gynecol Surv* Vol. 28, No. 5 (May 1973), pp. 281-303



## **Acute Pancreatitis**

Edited by Prof. Luis Rodrigo

ISBN 978-953-307-984-4

Hard cover, 300 pages

**Publisher** InTech

**Published online** 18, January, 2012

**Published in print edition** January, 2012

Acute Pancreatitis (AP) in approximately 80% of cases, occurs as a secondary complication related to gallstone disease and alcohol misuse. However there are several other different causes that produce it such as metabolism, genetics, autoimmunity, post-ERCP, and trauma for example... This disease is commonly associated with the sudden onset of upper abdominal pain that is usually severe enough to warrant the patient seeking urgent medical attention. Overall, 10-25% of AP episodes are classified as severe. This leads to an associated mortality rate of 7-30% that has not changed in recent years. Treatment is conservative and generally performed by experienced teams often in ICUs. Although most cases of acute pancreatitis are uncomplicated and resolve spontaneously, the presence of complications has a significant prognostic importance. Necrosis, hemorrhage, and infection convey up to 25%, 50%, and 80% mortality, respectively. Other complications such as pseudocyst formation, pseudo-aneurysm formation, or venous thrombosis, increase morbidity and mortality to a lesser degree. The presence of pancreatic infection must be avoided.

### **How to reference**

In order to correctly reference this scholarly work, feel free to copy and paste the following:

Tea Štimac and Davor Štimac (2012). Acute Pancreatitis During Pregnancy, Acute Pancreatitis, Prof. Luis Rodrigo (Ed.), ISBN: 978-953-307-984-4, InTech, Available from: <http://www.intechopen.com/books/acute-pancreatitis/acute-pancreatitis-during-pregnancy>

**INTECH**  
open science | open minds

### **InTech Europe**

University Campus STeP Ri  
Slavka Krautzeka 83/A  
51000 Rijeka, Croatia  
Phone: +385 (51) 770 447  
Fax: +385 (51) 686 166  
[www.intechopen.com](http://www.intechopen.com)

### **InTech China**

Unit 405, Office Block, Hotel Equatorial Shanghai  
No.65, Yan An Road (West), Shanghai, 200040, China  
中国上海市延安西路65号上海国际贵都大饭店办公楼405单元  
Phone: +86-21-62489820  
Fax: +86-21-62489821

© 2012 The Author(s). Licensee IntechOpen. This is an open access article distributed under the terms of the [Creative Commons Attribution 3.0 License](https://creativecommons.org/licenses/by/3.0/), which permits unrestricted use, distribution, and reproduction in any medium, provided the original work is properly cited.

IntechOpen

IntechOpen