

# We are IntechOpen, the world's leading publisher of Open Access books Built by scientists, for scientists

6,900

Open access books available

185,000

International authors and editors

200M

Downloads

Our authors are among the

154

Countries delivered to

TOP 1%

most cited scientists

12.2%

Contributors from top 500 universities



WEB OF SCIENCE™

Selection of our books indexed in the Book Citation Index  
in Web of Science™ Core Collection (BKCI)

Interested in publishing with us?  
Contact [book.department@intechopen.com](mailto:book.department@intechopen.com)

Numbers displayed above are based on latest data collected.  
For more information visit [www.intechopen.com](http://www.intechopen.com)



# Diagnosis and Treatment of a Rare Complication After Penetrating Keratoplasty: Retained Descemet's Membrane

Roberto Ceccuzzi, Gabriella Ricciardelli, Annita Fiorentino,  
Meri Tasellari, Giovanni Furiosi and Paolo Emilio Bianchi  
*University of Pavia, Ophthalmic Department Foundation IRCCS San Matteo Pavia  
Italy*

## 1. Introduction

Retention of the host's Descemet's membrane is a complication which can occur during the course of a penetrating keratoplasty and which eventually leads to loss of graft clarity by clouding or by coming into contact with the graft endothelium. The retained Descemet's membrane can compromise endothelial tissue by contact injury or by limiting diffusion of aqueous humour nutrients.

In our study we discuss the pathogenesis, diagnosis and treatment of this complication. In addition we report some our cases treated with three different approaches.

## 2. Corneal transplant techniques

Corneal grafting techniques date back to the latter part of the 19<sup>th</sup> century and the earlier part of the 20<sup>th</sup> century as exemplified by pioneer ophthalmologists such as Reisinger, von Hippel and Elsching.

Penetrating Keratoplasty refers to the full thickness replacement of a diseased cornea with a healthy donor tissue. This technique may be used or to provide tectonic support in case of corneal thinning and perforation, either in case of keratoconus, bullous keratopathy, corneal dystrophies and degeneration, trauma or any other causes of corneal decompensation. Because of the "open sky" exposure of the intraocular contents during this kind of surgery, IOP control is an important step to avoid the risk of intraoperative expulsive choroidal haemorrhage. Using a calliper the horizontal and vertical diameters of the recipient's cornea are measured and the size of the graft is determined base on pathology and clinical judgement. Traditionally is used a size disparity in which the donor tissue is 0.25 mm larger than that of the recipient. The centre of the recipient cornea is marked so as the periphery with a radial keratotomy marker stained with ink. Then, while preparing the donor tissue punching the corneal button, the recipient cornea is cut by a trephine and the trephination is stopped as soon as aqueous egress shows the anterior chamber has been entered. Suction is released and the viscoelastic is then injected; the recipient button is excised using forceps and corneal scissors. Then the donor button is placed over the recipient bed and sutured in

place with four cardinal sutures whose depth is typically 90% of the corneal thickness. After placement of the 12 o'clock suture, particular attention is paid to the 6 o'clock suture because these two sutures follow a vertical line and bisect the entire donor button such as the two at 3 and 9 o'clock. The rest of the sutures could be a combination of interrupted and running sutures.

But since the advent of penetrating keratoplasty surgeons have recognized the undesirable postoperative consequences of full-thickness corneal surgery such as high astigmatism, unpredictable refractive outcomes and prolonged visual rehabilitation. That's why ophthalmologists have conceptualized more selective transplanting techniques such as deep stromal and endothelial keratoplasty.

Lamellar keratoplasty involves placing a partial thickness donor corneal graft within a recipient corneal bed prepared by lamellar dissection of abnormal corneal tissue. It could be considered an alternative surgical option to penetrating keratoplasty in many specific cases such as all the ectatic corneal disorders that don't affect the endothelial cell layer. Lamellar keratoplasty offers several advantages over traditional PKP by avoiding complications associated with the "open sky" surgery and decreasing allograft rejection. The goal of this kind of surgery is a sufficient restoration of optical clarity of the central cornea; achievement of this objective is dependent upon a clean and complete posterior lamellar dissection of the host's corneal stroma from Descemet's membrane. An inadequate dissection could result in stromal and interface opacification and irregular astigmatism.

Descemet's stripping automatic endothelial keratoplasty (DSAEK) has become the preferred method of corneal transplantation for endothelial disease with improved safety, reduced astigmatism, and faster visual recovery. It is often performed with topical anaesthesia and monitored intravenous sedation. With the patient in a supine position, the horizontal corneal diameter of the recipient eye is measured with callipers to guide the selection of an appropriate donor tissue diameter. A 5 mm temporal clear corneal or sclera tunnel incision is made in the recipient eye. If the recipient epithelium is hazy or scarred it can be removed and this usually improves the view into the eye. Multiple ink points around the entire diameter of recipient cornea are used to lightly mark the surface of the recipient cornea to delineate the area for Descemet's membrane removal. The recipient endothelium, in fact, should only be stripped from the area that will be covered by the donor tissue because any stripped area not covered with donor tissue will become oedematous. To prevent this occurrence some surgeons score an area somewhat smaller than the planned donor diameter. Trypan blue could also be introduced in the anterior chamber to improve membrane visualization during the stripping. Descemet's membrane is then scored in a circular pattern along the perimeter of the area to be removed with a modified hook. During the scoring and stripping steps the anterior chamber can remain formed by continuous infusion of balanced salt solution or air (we prefer to avoid the use of viscoelastic because, if it will not be completely removed before inserting the donor button, it will impair donor adherence).

After the donor tissue is inserted the anterior chamber is inflated by injecting air or balanced salt solution which allows the posterior portion of the donor tissue to unfold. The anterior chamber is then completely filled with air to firmly press the donor tissue up against the recipient cornea.

### 3. Retention of Descemet's membrane

Retention of the host's Descemet's membrane is a complication which can occur during the course of a penetrating keratoplasty (but also DALK and DSAEK present retention of Descemet's complications) and which eventually leads to loss of graft clarity by clouding or by coming into contact with the graft endothelium. Penetrating keratoplasty is a common technique with good prognosis value and has been the first choice for corneal endothelial decompensation even if in the last years for this kind of diseases DSAEK is preferred in order to its minimal sequelae. DSAEK requires much less manipulation of the recipient cornea and anterior chamber, compared with the earlier PK and DALK procedure and this help to minimize intraoperative and postoperative complications. Moreover DSAEK technique does not induce significative alterations of corneal topography so that it could be considered an essentially refractive neutral transplant procedure.

Postoperative complications of penetrating keratoplasty include high or irregular astigmatism, prolonged wound healing, late wound dehiscence with trauma, suture-related infections, vascularisation, and graft rejection. The most postoperative complication with DSAEK, instead, is that sometimes the donor tissue detaches in the early postoperative period (from 1 day to 1 week after surgery) so that additional air must to be injected to again firmly press the donor tissue against the recipient cornea.

In addition, retention of the host's Descemet's membrane can be seen as a rare complication of these surgical techniques. The retained Descemet's membrane can compromise endothelial tissue by contact injury or by limiting diffusion of aqueous humour nutrients.

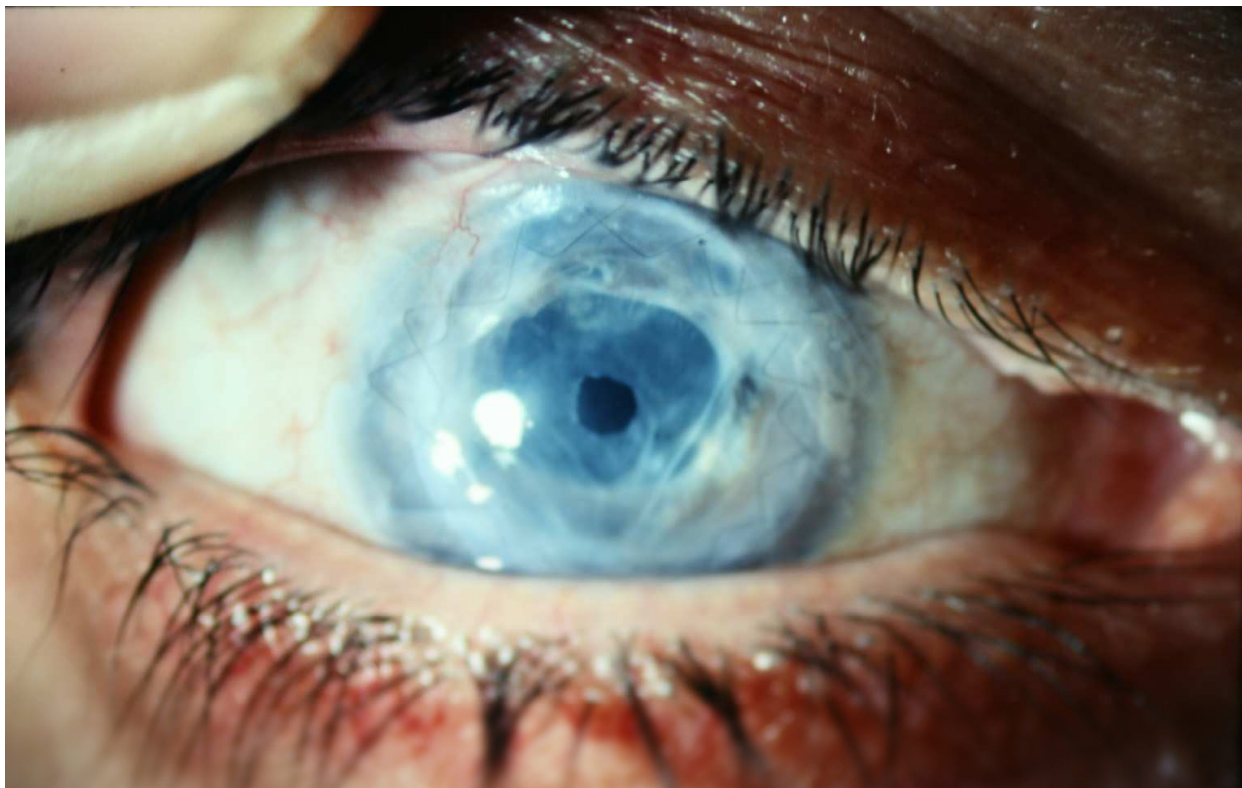

Fig. 1.a Retained Descemet's membrane after PK treated with YAG laser

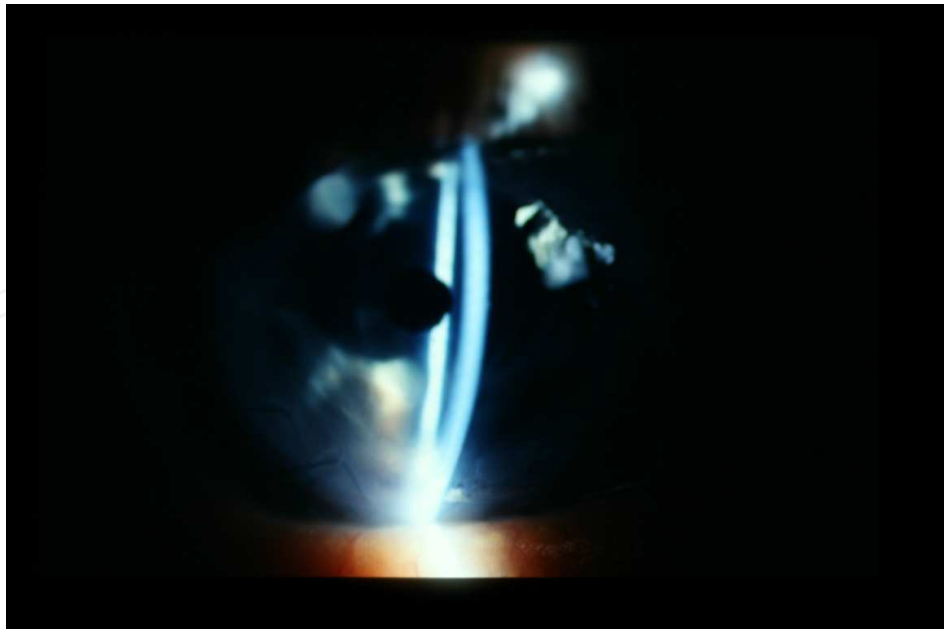

Fig. 1.b Retained Descemet's membrane after PK treated with YAG laser

This complication consists in the incomplete removal of the host cornea: after partial trephination we make an opening into the anterior chamber and introduce curved corneal scissors. Especially in an oedematous cornea it could occur that the lower blade is placed anterior to Descemet's membrane so that, when the button is lifted from the eye, a portion of Descemet's membrane leaves behind.

The result is a wavy, diaphanous membrane that creates a supernumerary anterior chamber behind the graft on the first postoperative control by slit lamp examination.

The following case histories from the Department of Ophthalmology of San Matteo General Hospital of Pavia, may help to illustrate the course and prognosis of this mishap.

## 4. Cases report

### 4.1 Case 1

A 62 year old white woman underwent penetrating keratoplasty in her right eye on April 23, 2002. Because of the appearance of deep new vessels, especially in nasal and upper corneal sectors, she underwent a retransplantation on February 26, 2003.

On the first post-operative control, slit lamp biomicroscopy revealed a retained Descemet's membrane and a supernumerary anterior chamber. The graft was clear with a best corrected visual acuity of 1/10 with +2 D sphere.

The patient opted for Laser treatment (March 2003) to improve visual function so that it was created a central circular opening in the retrograft membrane at optical zone level just one month after PK.

The laser was setted to 0.9 mJ with posterior focus shift and increased up to 1.7 mJ when a central tear appeared in the membrane; subsequently enlarged focusing the beam near to the first tear to create a central circular 2.5 mm opening.

There were no complication resulting from the Yag Laser treatment and the donor cornea remained thin and clear with a visual acuity two years after PK improved to 6/10 with +2 D sphere.



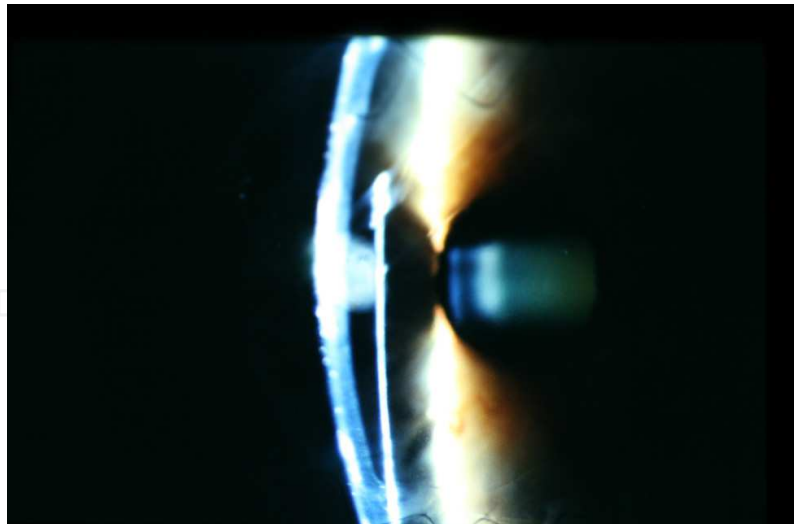


Fig. 2. Partial double anterior chamber in retained Descemet's membrane

#### 4.2 Case 2

A 54 year old white woman was referred to our department on December 2002. The patient was diagnosed as having glaucoma in 1990 and since then on she was treated with Timololo. In 1998 a cataract extraction was performed in patient's right eye and on December 03, 2002 she underwent a penetrating keratoplasty in RE for endothelial decompensation. After surgery the patient reported excellent visual function lasting for some time but on July 2003 she had experienced decreased visual acuity and marked diffuse corneal oedema, later on which it was performed a retransplantation.

On the first post-operative control the slit lamp biomicroscopy revealed a Descemet's retention with a supernumerary anterior chamber so that the patient underwent descemetorhexis to leave the pupillary field one month later. Nine months after the treatment the patient had a best-corrected visual acuity of 5/10 and the graft was clear. Unfortunately the patient did not complete the follow-up in our department.

#### 4.3 Case 3

An 81 year old man with a history of cataract extraction in both eyes, glaucoma and penetrating keratoplasty in right eye in 2000, was referred to the Department of Ophthalmology of San Matteo General Hospital with ocular pain and marked reduction of visual acuity. In spite of risks connected with his glaucomatous history, the patient opted for new surgical treatment and on October 2003 he underwent a new penetrating keratoplasty.

On the first post-operative control was referred Descemet's retention from removed graft. On September 2004 the graft appeared oedematous and with a lot of new vessels all around the limbus. Because of this on November 23, 2004 was performed a new penetrating keratoplasty in right eye. On the last control (September 2010) the patient's visual acuity in his right eye was limited to hand motions.

### 5. Discussion

These cases document the occurrence of a retained Descemet's membrane following penetrating keratoplasty especially in case of severe oedema and thickening of the recipient cornea, which facilitates the separation of Descemet's membrane and, in turn, incomplete

trephination when the recipient cornea is cut. Alternatively, it can be caused by improper instillation of a viscoelastic agent, which can dissect an artificial corneal plane and contribute to inadvertent retention of posterior corneal lamellae.

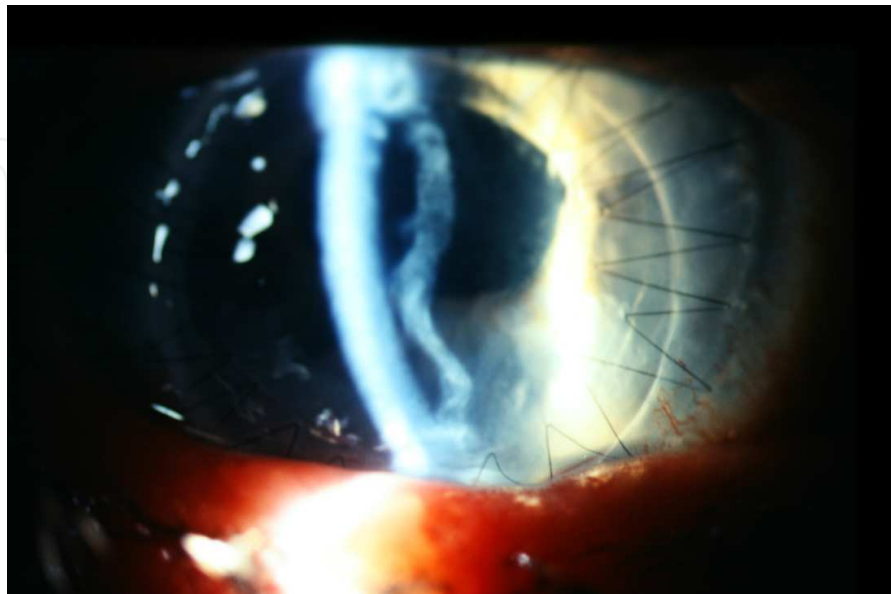


Fig. 3. Double anterior chamber in retained Descemet's membrane

The principal mechanisms which lead to Descemet's membrane's retention are:

- inadvertent and incomplete trephination of oedematous corneas as in congenital hereditary endothelial dystrophy or bullous keratopathy that forces the surgeon to complete the cut with forceps acting on different levels;
- longstanding stromal oedema which cause loosening of the attachment of the DM, thereby predisposing to its separation from the overlying stroma
- marked hypotonia of ocular globe with decrease of backpressure during the cut
- scar's marked fibrosis in case of retransplantation
- stromal recipient imbibitions (not by chance in some techniques of DALK surgery the imbibitions is deliberately requested to make easier the identification of Descemet's membrane). It's important to underline that in case of corneal imbibitions Descemet's membrane becomes thickened due to endothelial decompensation and this fact leads to a further resistance to trephination.

The retained DM may be associated with progressive opacification of the graft that has been postulated to occur due to presence of a sliver of residual stroma with keratocytes from which the fibroblastic activity occurs. The differential time taken for the opacification of the retained DM is due to the thickness of the residual stroma retained along with the DM in these cases.

The best way to avoid this complication is to inspect the wound site carefully with the operating microscope at high magnification and pick up the iris with a fine-tipped forceps to detect a detached Descemet's membrane, especially in oedematous corneal host tissue.

Also, it is important to note that loss of aqueous humour during trephination indicates Descemet's membrane is perforated in 1 or more places, even if this doesn't strictly mean that Descemet's membrane has been completely cut.

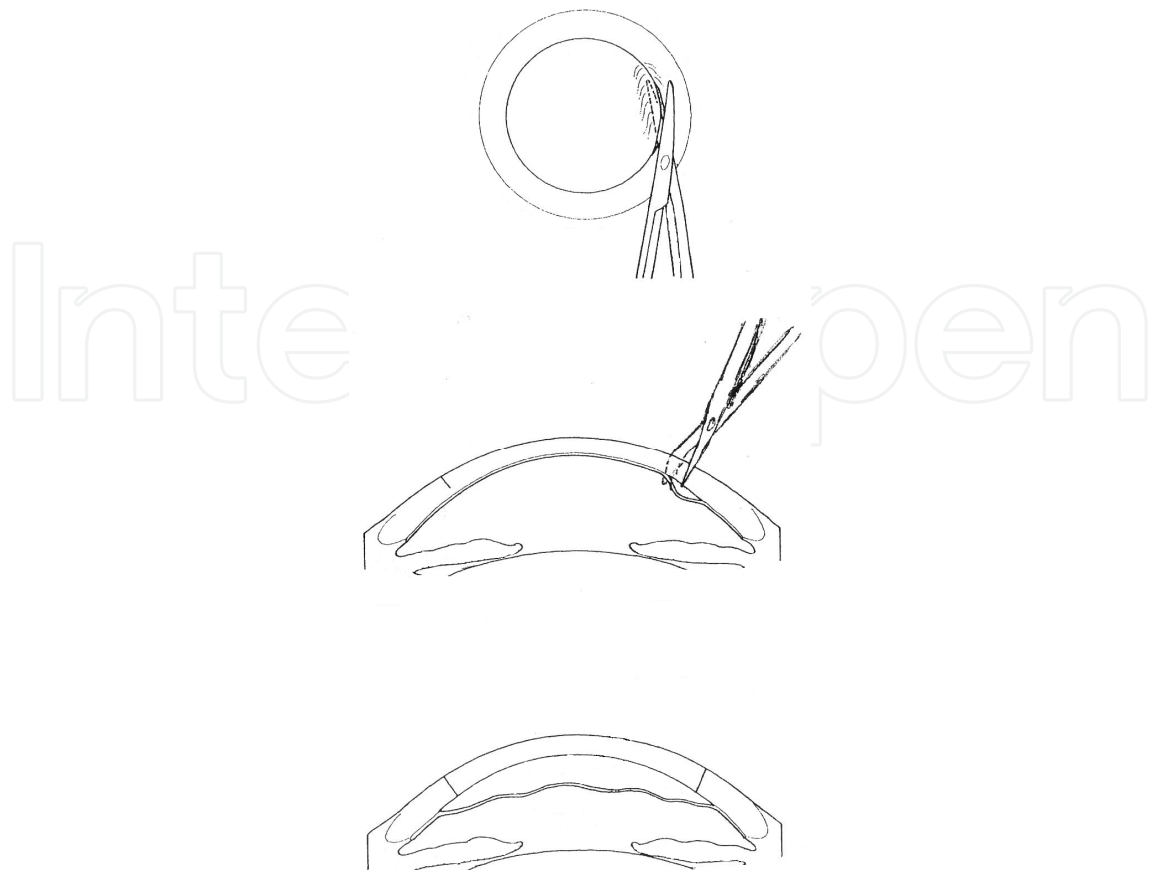


Fig. 4. Scissors incomplete insertion results in retained Descemet's membrane

A possible solution to this problem is the use of dye, such as trypan blue or indocyanine green, to highlight the Descemet's membrane. The use of indocyanine green staining of the Descemet's membrane to make DLEK surgery easier has previously been described. Although it bears further study to determine its value, the use of dye after Descemet's stripping in DSEK may improve visualization of this transparent membrane and alleviate the inadvertent retention of the delaminated fetal Descemet's membrane on the recipient bed.

About DALK surgery it's possible to have retained Descemet's in management of a complication such as macroperforation and subsequently surgical switch to PKP in critical condition: shallow anterior chamber, poor surgical field vision for stromal air or fluid imbibition, dishomogeneous thickness due to the pathology (often keratoconus).

Even during DSAEK Descemet's retention could be a complication which affects the outcome of corneal surgery. Crucial is in this case the presence of folded peripheral spurs that prevent the attachment of donor button being responsible of graft failure. In this case AS-OCT is a useful instrument for the early recognition of retained Descemet's membrane. Retained Descemet's membrane after keratoplasty can be difficult to diagnose in the early postoperative course and AS-OCT may be a useful adjunctive diagnostic tool to aid in the recognition and management of such a complication, especially for patients with either corneal opacity or oedema or after corneal surgeries.

To determine whether the entire desired surgical area of the Descemet's membrane has been removed in DSEK surgery, practitioners routinely examine the stripped Descemet's membrane during surgery with placement of the tissue onto the anterior corneal surface.

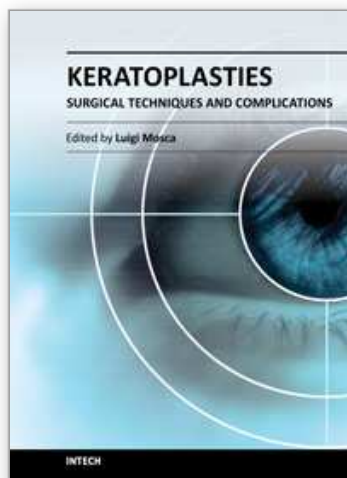


Doing so allows the surgeon to visually inspect the tissue for missing fragments, which could be removed from the anterior chamber. Despite this precaution, it would be difficult, if not impossible, for the surgeon to discern whether a small lamellar remnant was retained on the recipient's posterior cornea.

Retention of the host's Descemet's membrane is a complication which can occur during the course of a penetrating keratoplasty and which eventually leads to loss of graft clarity by clouding or by coming into contact with the graft endothelium. The retained Descemet's membrane can compromise endothelial tissue by contact injury or by limiting diffusion of aqueous humour nutrients. That's why the use of YAG laser could allow not only the optic zone relief but also the diffusion of aqueous humour nutrients, avoiding complications related to retransplantation. Moreover this "non open sky" technique grants us smaller risk of postoperative complications but avoids only a little central hole which results inadequate in case of big descemetical residue. We have also to notice that Yag laser could induce a further Descemet's - endothelial failure thanks to its thermic effect.

## 6. References

- Archila E.A., Ramirez Cabrera M.F. Alviar A.M., Double Descemet's Membrane in Penetrating Keratoplasty *J Refract and Corneal Surg.* 9 65-66, 1993
- Banik R, Novick LH, Smith RE, & Chuck RS. Retrocorneal Membrane With Descemet's Detachment *Cornea* 20(7): 763-764, 2001
- Bui K.M., Tu E.Y. A Rigid Band of Retained Descemet's Membrane as a Mechanical Cause of Graft Non-attachment in Repeat DSAEK. ARVO 2011 Abstract - May 1-5 2011
- Chen YP, Lai PCC, Chen PYF, Lin KK, & Hsiao CH. Retained Descemet's membrane after penetrating keratoplasty *J Cataract Refract Surg* 2003; 29:1842-1844
- Cohen AV, Goins KM, Sutphin JE, Wandling GR, & Wagoner MD. Penetrating keratoplasty versus deep anterior lamellar keratoplasty for the treatment of keratoconus. *Int Ophthalmol* (2010) 30:675-681
- Ichihashi Y., Nejima R., Matsumoto Y., Kawakita T., Miyata K., Tsubota K., Shimmura S. Results of Non-Descemet's Stripping And Automated Endothelial Keratoplasty (nDSAEK) ARVO 2011 Abstract - May 1-5 2011
- Ide T., Yoo S.H., Kymionis G.D., Shah P. A., & O'Brien T. P.. Double Descemet's Membranes After Penetrating Keratoplasty With Anterior Segment Optical Coherence Tomography *Ophthalmic surgery laser and imaging* 2008; 39, 05: 422-425
- Mittal V, Mittal R, & Sangwan VS. Successful Descemet's stripping endothelial keratoplasty in congenital hereditary endothelial dystrophy *Cornea* 2011 Mar;30(3):354-356
- Mondloch M. C., Giegengack M., Terry M. A. & Wilson D. J. Histologic Evidence of Retained Fetal Layer of the Descemet's Membrane After Presumed Total Removal for Endothelial Keratoplasty A Possible Cause for Graft Failure *Cornea* 2007; 26, 10: 1263-1266
- Romaniv N., Price M.O., Price F. W., & Nick Mamalis. Donor Descemet's Membrane Detachment After Endothelial Keratoplasty *Cornea* 2006; 25, 8: 943-947
- Sbarbaro JA, Eagle RC, Thumma P, & Raber IM. Histopathology of Posterior Lamellar Endothelial Keratoplasty Graft Failure *Cornea* 2008;27:900-904



## **Keratoplasties - Surgical techniques and complications**

Edited by Dr. Luigi Mosca

ISBN 978-953-307-809-0

Hard cover, 134 pages

**Publisher** InTech

**Published online** 18, January, 2012

**Published in print edition** January, 2012

In this book, the authors illustrate different therapeutic and surgical approaches to treating various corneal pathologies. This edition in electronic format allows universal access to everybody regardless of the time of day or setting, portability, and speed of information access. Such features show more feasibility for all readers and reduce the time necessary for research. This book will be a good tool for students as well as specialists working in the field of corneal transplantation, to improve their knowledge of treatment of corneal disease.

### **How to reference**

In order to correctly reference this scholarly work, feel free to copy and paste the following:

Roberto Ceccuzzi, Gabriella Ricciardelli, Annita Fiorentino, Meri Tasellari, Giovanni Furioli and Paolo Emilio Bianchi (2012). Diagnosis and Treatment of a Rare Complication After Penetrating Keratoplasty: Retained Descemet's Membrane, *Keratoplasties - Surgical techniques and complications*, Dr. Luigi Mosca (Ed.), ISBN: 978-953-307-809-0, InTech, Available from: <http://www.intechopen.com/books/keratoplasties-surgical-techniques-and-complications/diagnosis-and-treatment-of-a-rare-complication-after-penetrating-keratoplasty-retained-descemet-s-me>

**INTECH**  
open science | open minds

### **InTech Europe**

University Campus STeP Ri  
Slavka Krautzeka 83/A  
51000 Rijeka, Croatia  
Phone: +385 (51) 770 447  
Fax: +385 (51) 686 166  
[www.intechopen.com](http://www.intechopen.com)

### **InTech China**

Unit 405, Office Block, Hotel Equatorial Shanghai  
No.65, Yan An Road (West), Shanghai, 200040, China  
中国上海市延安西路65号上海国际贵都大饭店办公楼405单元  
Phone: +86-21-62489820  
Fax: +86-21-62489821

© 2012 The Author(s). Licensee IntechOpen. This is an open access article distributed under the terms of the [Creative Commons Attribution 3.0 License](https://creativecommons.org/licenses/by/3.0/), which permits unrestricted use, distribution, and reproduction in any medium, provided the original work is properly cited.

IntechOpen

IntechOpen