

We are IntechOpen, the world's leading publisher of Open Access books Built by scientists, for scientists

6,900

Open access books available

185,000

International authors and editors

200M

Downloads

Our authors are among the

154

Countries delivered to

TOP 1%

most cited scientists

12.2%

Contributors from top 500 universities



WEB OF SCIENCE™

Selection of our books indexed in the Book Citation Index
in Web of Science™ Core Collection (BKCI)

Interested in publishing with us?
Contact book.department@intechopen.com

Numbers displayed above are based on latest data collected.
For more information visit www.intechopen.com



Femtosecond Laser Assisted Lamellar Keratoplasties

Luigi Mosca, Laura Guccione, Luca Mosca,
Romina Fasciani and Emilio Balestrazzi

*Catholic University of "Sacro Cuore" – "A. Gemelli" Polyclinic, Rome,
Italy*

1. Introduction

The concept of lamellar keratoplasty (LK) is that of targeted lamellar replacement of corneal tissue while retaining normal cornea. It involves replacing anterior stroma at different deepness with an anterior lamellar keratoplasty (ALK). Despite the significant advantages of LK surgery, penetrating keratoplasty (PK) remains the most common procedure, largely because lamellar surgery is more technically demanding and time consuming ¹. Moreover, interface irregularity arising from manual lamellar dissection often results in suboptimal visual outcomes ². Long-term graft survival rates and endothelial cell counts after PK continue to drop for many years after surgery, clearly showing the disadvantage of unnecessary replacement of a healthy endothelium in anterior-stromal disorders ³. For these reasons, PK is now being replaced by various types of lamellar techniques that aim to replace damaged tissue only, while maintaining healthy tissue intact.

Recent improvements of surgical techniques and advances in instrumentation, such as microkeratome-assisted LK (ALTK) ⁴, and excimer laser assisted LK (ELLK), ^{5,6} have contributed to improve visual quality in corneal lamellar surgery, promoting a paradigm shift in the surgical treatment of anterior corneal disease.

The new femtosecond laser technology has been introduced for ophthalmic surgery in the last years with the aim to resolve the microkeratomes related problems in LASIK surgery ⁷. This new technology has been shown to be the "top" to perform LASIK flaps, creating flaps of precise and homogeneous thickness, reducing the flap related problems (free cap, button hole, flap irregularity) and leaving more stroma for the excimer ablation allowing to correct higher refractive defects (especially with the ultrathin flaps of 90 microns).

Moreover, the femtolaser technology, allowing to perform precise corneal cuts with a planned and customized shape, offers clear advantages also applied in anterior lamellar keratoplasty (ALK) surgery⁸⁻¹⁰.

Penetrating Keratoplasty (PK) is still the most common and effective technique for corneal transplantation, but is an "open sky" surgical technique and could be complicated by choroidal effusion or haemorrhage, spontaneous lens expression and vitreous loss ¹. Moreover, this technique is characterized by an everlasting endothelial cell loss, leading to corneal decompensation necessitating a re-PK to restore a clear graft. To avoid these risks, more conservative surgical techniques have been proposed for the treatment of anterior corneal pathologies with healthy endothelium, enclosed in the great chapter of the lamellar keratoplasty (LK) ^{2,3}. So that, during the last 10 years, to increase the results of traditional

manual ALK, the use of high technologic tools such as microkeratomes or excimer lasers with customized ablation patterns has been proposed, with uncertain outcomes ⁴⁻⁶.

With the aim to realize a more safe, repeatable and effective LK technique, suitable to every surgical skills, in 2005 we started to use the femtosecond laser technology (IntraLase, AMO, USA) (Figure 1,2) in several cases of anterior corneal pathologies (Femtolasers-assisted Anterior Lamellar Keratoplasty - Femto-ALK -. Early data published on *Cornea* in 2008) ⁹. With the diffusion of the new manual techniques of DALK, especially the “Big Bubble” one¹¹⁻¹⁵, allowing the better visual results ever reached by a ALK, the Femto-ALK technique resulted quite inadequate. For these reasons, we developed a more effective femtolasers-assisted lamellar technique: the Femtolasers-assisted Deep Anterior Lamellar Keratoplasty (Femto-DALK). Below the description of our Femtolasers-assisted LK techniques and the results reached after more than two years of follow-up with these two techniques.

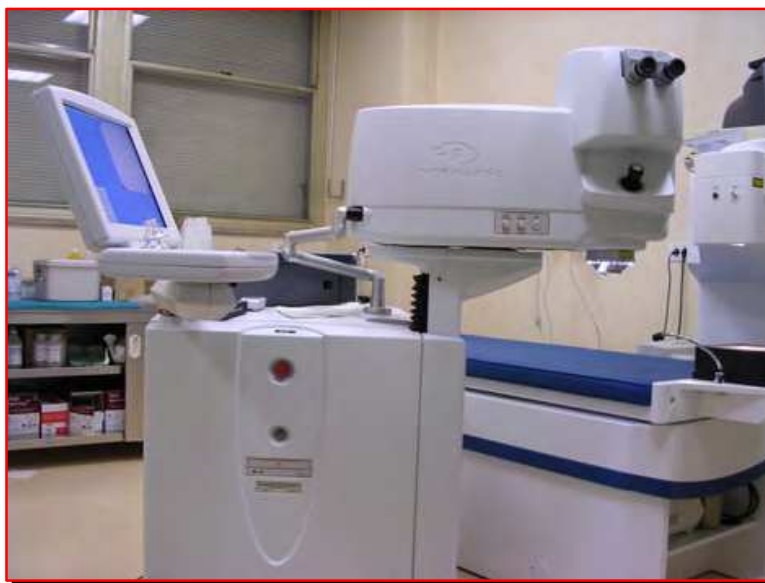

Fig. 1. The femtosecond laser (IntraLase, AMO, USA) settled near the excimer laser (Technolas 217C, Bausch & Lomb, USA) in the Laser Room of the Ophthalmic Department of Catholic University of “Sacro Cuore” of Rome, Italy.

2. Anterior Lamellar Keratoplasty (ALK)

In 2008 we published our first data on femtolasers-assisted ALK after one year of follow-up ⁹. The technique of femtolasers-assisted ALK reaches modest results, with slight patient's dissatisfaction in the first months after surgery, even if after complete suture removal the visual acuity resulted drastically growing up (Figure 3). Nevertheless, these initial results were not validated by a longer follow-up. Below, we present the clinical results more than three years postoperatively.

2.1 Clinical experience with Femto-ALK

The experience performing Anterior Lamellar Keratoplasty (ALK) for different corneal pathologies starts in May 2005, first with a 15 kHz (10 cases) and then with a 60kHz (11 cases) femtosecond laser (IntraLase, AMO, USA). From July 2005 to December 2007 has been performed 21 consecutive femtolasers-assisted ALK (Femto-ALK) procedures for different

corneal pathologies (5 post-traumatic corneal scar, 3 post-keratitis corneal leucoma, and 13 moderate keratoconus).

2.2 Femtosecond laser features

The femtosecond laser of the Ophthalmic Department of Catholic University of “Sacro Cuore” (Figure 1) features are as follows: spot size of $< 3\mu\text{m}$, repetition rate of 60 kHz (for the first 10 patients the repetition rate was 15kHz); laser pulse duration of 600-800 fs (± 50); maximum laser pulse peak power of 12 MW (± 2); central laser wavelength of 1053nm; maximum pulse energy of 7.3 mJ (± 0.7); maximum laser beam output of 110mW (± 11). The laser acts with four different ablation patterns (Raster, double raster, spiral and pocket) that can be mixed by the surgeon for the surgical target. The femtosecond laser pulses result in multiple corneal intrastromal gas bubbles (micro-cavitations), requiring only a manual light lamellar dissection using a blunted spatula, to create the intrastromal cut with a smooth surface.

2.3 Surgical procedure

The Femto-ALK surgical technique has been realized in two surgical steps:

The first step was performed in the laser room where a femtosecond laser cut was created on both donor and receiving cornea (Figure 2). In the second step, performed in the surgery room, the donor lamella was sutured into the receiving stromal bed with 16 radial 10/0 nylon stitches.

To realize the donor lamella, the cut was performed on an entire donor cornea, analyzed and delivered by an ocular tissue bank, positioned on an artificial anterior chamber (Moria, France). Mean lamellar diameter was $8.34\text{mm} \pm 0.28 \text{ SD}$ (range: 8.2 - 8.7mm), and mean lamellar thickness was $353.91\mu\text{m} \pm 38.82\text{SD}$ (range: 220 - 400 μm). The donor button has been planned thicker than the amount of receiving cornea removed, in way to restore a normal corneal thickness (at least 550 micron), and 0.2 mm larger, in way to avoid too much corneal compression with the sutures and to evade the risk of anterior chamber (AC) reduction after surgery.

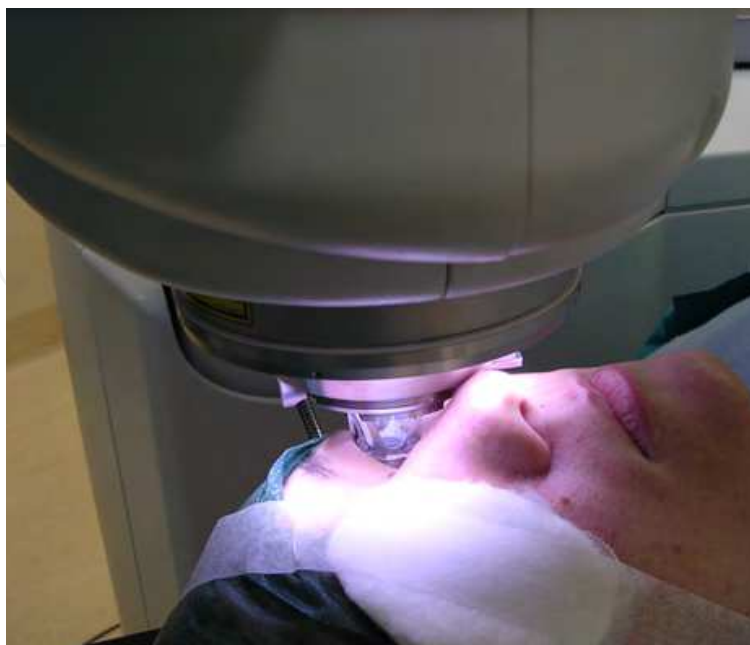

Fig. 2. Femtosecond laser cut on recipient bed after docking on the cornea of the patient.

Under topical anaesthesia (Ossibuprocaine 4% drops for 4 times), a disposable suction ring was positioned at the sclero-limbal margin to stabilize the eye. After the docking, the femtosecond laser cut (Figure 2) on receiving corneal stroma was performed to leave at least 200µm residual stromal bed (mean stromal cut deepness of 243.91µm ±51.59SD, with a mean diameter of 8.13mm ±0.37 SD, and mean residual stromal bed of 181.61µm ± 57.78SD). After stromal laser cut execution, the patient was carried in the surgery room where the corneal button was removed with a blunt spatula leaving the clear stromal residual bed. Then, the donor lamella was first secured in the recipient bed with four 10/0 nylon cardinal sutures at the 6, 12, 9 and 3 o'clock positions, and subsequently it was sutured with twelve more 10/0 nylon radial stitches. Intraoperatively, corneal astigmatism was evaluated with a corneal disposable keratometer, (Janach, Como, Italy) and suture adjustment, if required, was performed. At the end of surgery, a soft contact lens was placed on the eye surface to help restoring of corneal epithelium. Topical antibiotics (Nethylmicine), steroids (Desamethasone 0.18%) and artificial tear drops (Hyaluronate sodium 0.2%) were applied several times a day, and then tapered and titrated, basing on the corneal transparency and scarring of the surgical wound.

The surgical plannings have been realized in all cases basing on the accurate preoperative pachymetric values found with optical pachymetry (Confoscan 4, Nidek technologies, Tokyo, Japan; and Orbscan II, Bausch & Lomb, CA, USA).

In all the cases performed, the surgery restored a clear cornea from the first week after surgery with an interface hard to detect at the slit lamp examination.

The postoperative corneal thickness (mean corneal pachymetry: 542.48µm ± 33.20SD), curvature (mean K reading: 44.32D ± 13.50SD) and shape resulted nearer to physiologic values. Nevertheless, the results in visual acuity obtained with the Femto-ALK were not so brilliant as planned, especially in the keratoconic eyes, with a very slow recovery time. Three months after surgery, mean BSCVA was 0.30, increasing to 0.40 after complete suture removal six months later, and stabilizing 12 months postoperatively to 0.64 (the Figure 3 showed the BSCVA during follow-up).

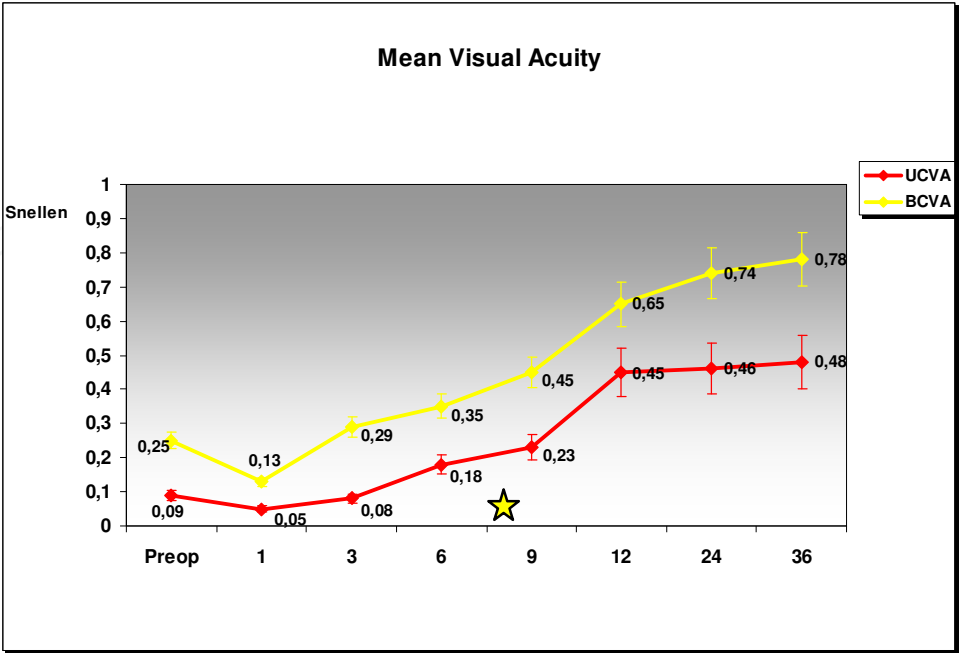


Fig. 3. Visual acuity results three years after Femto-ALK. The yellow star marks the mean removal suture period.

Analyzing all our cases with the confocal microscopy analysis (Confoscan4), we found that this unsatisfactory visual results were mostly related to the excessive thickness of residual stromal bed (150 microns or more), resulting in a irregular stromal interface (Fig. 4) with dark folds before suture removal (published on "Cornea 2008 Jul; 27(6): 668-72"); few months after suture removal, these findings disappeared gradually with a parallel increase of the BSCVA, setting to 0.64 Snellen at 12 months of follow-up. At two years of follow up the mean BSCVA resulted increased to $0.74 \pm 0.18SD$. After a three years of follow-up, these visual results resulted quite similar (mean UCVA of $0.48 \pm 0.13SD$ and mean BSCVA of $0.78 \pm 0.13SD$), confirming the stability of the outcomes during time and the validity of the Femto-ALK technique (Figure 3) and confirming that, comparing to penetrating keratoplasty (PK), lamellar keratoplasty need more time to stabilize the results.

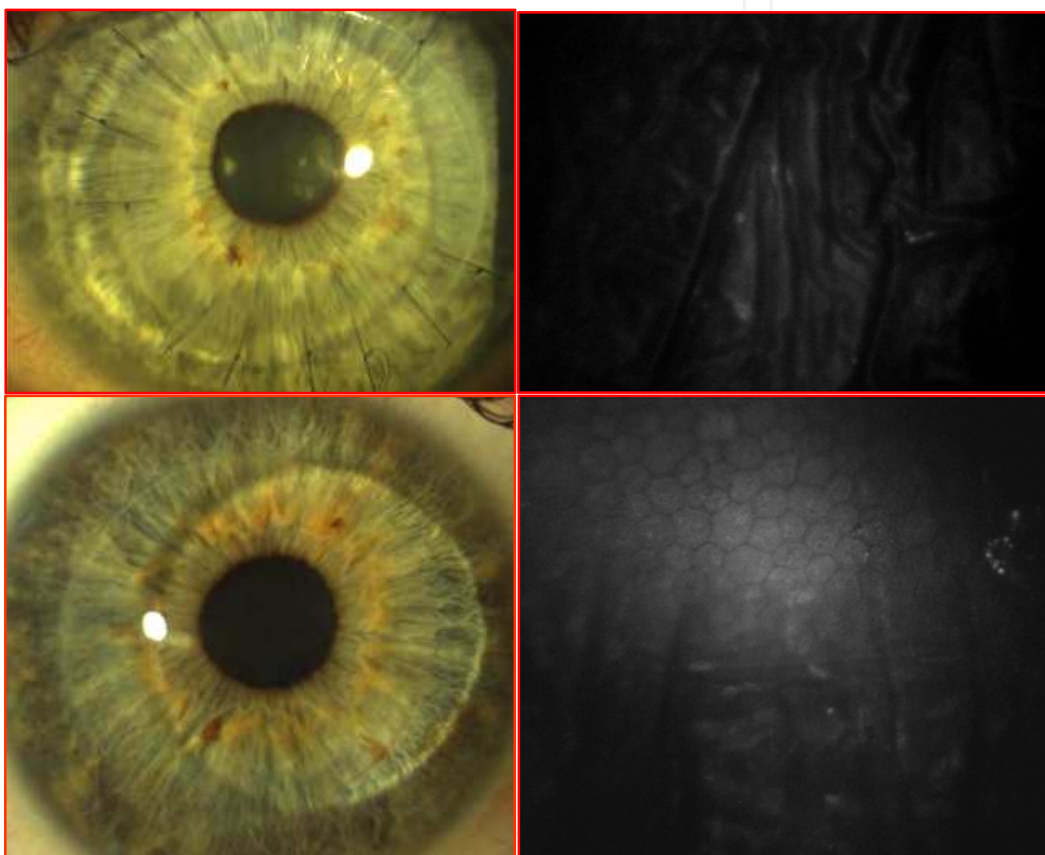


Fig. 4. Femto-ALK results: a. slit lamp examination 3 months after surgery shows a clear graft with sutures still on; b. Confoscan 4 confocal microscopy analysis at three months shows dark folds of the residual bed stroma related to the slow visual recovery; c. Six months postoperatively slit lamp shows a clear graft and confocal analysis (d) shows disappearance of the stromal folds and a healthy endothelium.

3. Deep Anterior Lamellar Keratoplasty (DALK)

After the quite unsatisfactory results obtained with the Femto-ALK technique, in keratoconic cases, We designed a new surgical technique trying to duplicate the superior results obtained with the descemetic and pre-descemetic DALK techniques: the femtolaser-assisted DALK. Deep Anterior Lamellar Keratoplasty (DALK) has the target of removing all the pathological stromal tissue, maintaining only the Descemet/endothelium layers in the recipient bed,

replacing it with a healthy stromal tissue, and restoring in that way a normal corneal thickness and shape ¹¹⁻¹³. However, there are some drawbacks to DALK, including the great difficulty of the manual intrastromal dissection and the fact that the procedure rarely achieves precision, resulting in low visual acuity and poor optical quality, especially if Descemet's membrane is not reached with the Big Bubble technique. There is also a high risk of micro- or macro-perforation ¹³⁻¹⁵, often requiring a conversion to Penetrating Keratoplasty. Many of these problems could be focused by the femtosecond laser assisted deep anterior lamellar keratoplasty (femto-DALK) procedure created to open this difficult surgery to every surgical skills.

In keratoconus patients, the goal is to utilise a surgical option that could be compared in results to manual descemetic DALK, preserving the health and integrity of the corneal endothelium layer.

3.1 Clinical experience with Femto-DALK

This technique was performed on 21 eyes of 21 patients, with advanced keratoconus with a mean corneal power of $53.2D \pm 6.08SD$ and a mean corneal topographic astigmatism of $4.3D \pm 2.82SD$. Mean UCVA was $0.1 \pm 0.05SD$, and mean BSCVA was $0.33 \pm 0.15SD$; mean SE was $-3.73 \pm 2.65SD$, and mean preoperative pachymetry was $361.19\mu m \pm 46.85SD$.

3.2 Surgical procedure

The new technique of DALK assisted by a femtosecond laser has been planned in two surgical phases.

During the first phase, performed in the laser room, a deep 8.2mm wide stromal cut on receiving bed is performed with a 60 kHz femtosecond laser (IntraLase, AMO, USA), leaving at least 100 μm of residual stromal bed, on the base of the pachymetric parameters of the patient (optical pachymetry evaluated by Orbscan II). Then, a +4 D spherical hyperopic PRK ablation with an optical zone of 6.5 mm (8.5 mm of maximum ablation diameter), to reduce the peripheral bed thickness in the way to reach a more uniform stromal bed thickness, followed by a 40-60 μm , 7.0mm wide, PTK ablation with fluid mask to reach as much as possible the Descemet's layer, is carried out with an excimer laser (Technolas 217C, B&L, USA) on the residual stromal bed (Fig. 5).

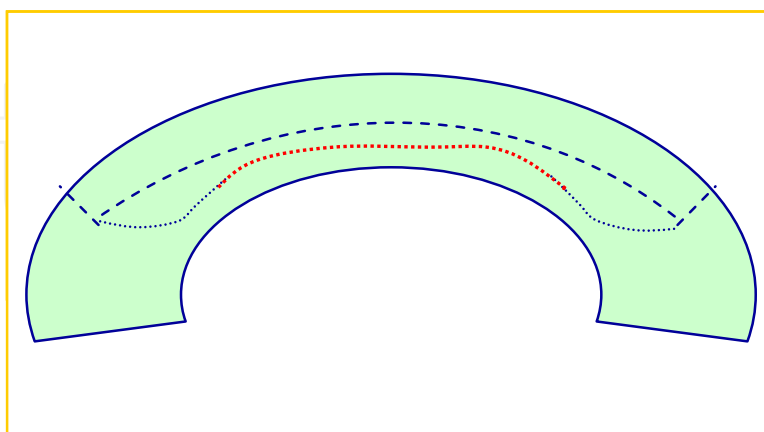


Fig. 5. First step of Femto-DALK technique: preparation of recipient bed in the laser room: ("----") Femtosecond laser cut as deep as possible, leaving at least 100microns of stromal residual bed; ("....") Excimer laser ablation +3/4 sph PRK to reduce peripheral bed thickness; ("....") Excimer laser 40-60 microns PTK to reach Descemet/epithelium layer as near as possible.

In the second surgical phase, performed in the operatory room, the donor button is cut from an entire cornea delivered by an Italian Corneal Bank with a corneal trephine (Hanna suction system, Moria, France) 0.25mm wider than the receiving bed (Fig. 6); then, after Descemet/endothelium layers manual stripping, the donor button is sutured on receiving stromal bed using 16 radial 10/0 nylon stitches.

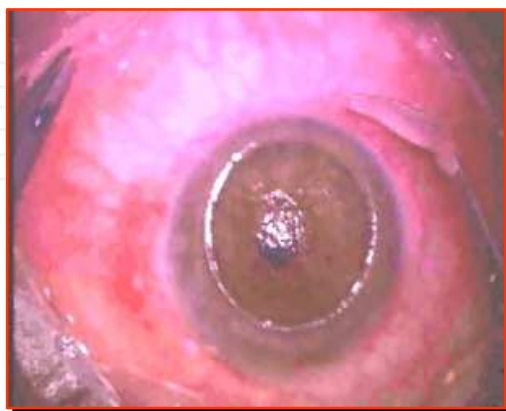


Fig. 6. Second step of Femto-DALK technique in operatory room: Suturing of the donor lamella after Descemet/endothelium layer manual stripping on recipient bed with 16 radial nylon stitches.

During the surgical procedure, two patients experienced a perforation performing the receiving bed cut with the femtolaser, that required a conversion to PK.

In another case, a microperforation occurred during the PTK ablation, that was managed with air injection in AC, and then the procedure was carried out without any further complication in operatory room.

One week after surgery a clear graft is shown in all cases, with an interface very hard to detect at slit lamp examination (Fig. 7). In all patients, one month after surgery the mean BSCVA was 0.40, three months later was 0.60, and at the one-year follow-up mark a clear graft and a regular astigmatism was reached (Figure 8), and BSCVA resulted 0.74. Two years after surgery, all patients experience stable results in both UCVA ($0.43 \pm 0.25SD$) and BSCVA ($0.84 \pm 0.13SD$), showing the validity of this femtolaser assisted DALK technique (Figure 9).

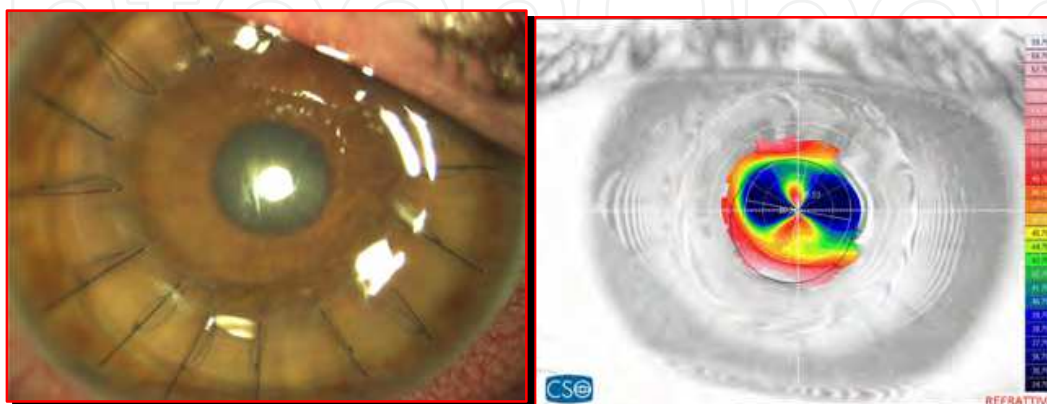


Fig. 7. Slit lamp examination (on left) at first week shows a clear graft with 16 radial nylon stitches; the topography analysis shows a regular “with the rule” astigmatism.

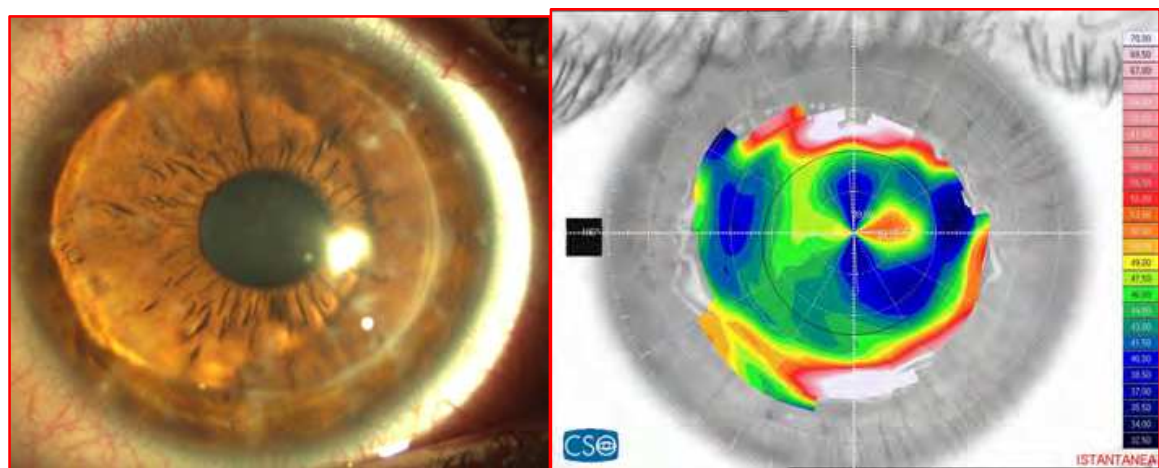
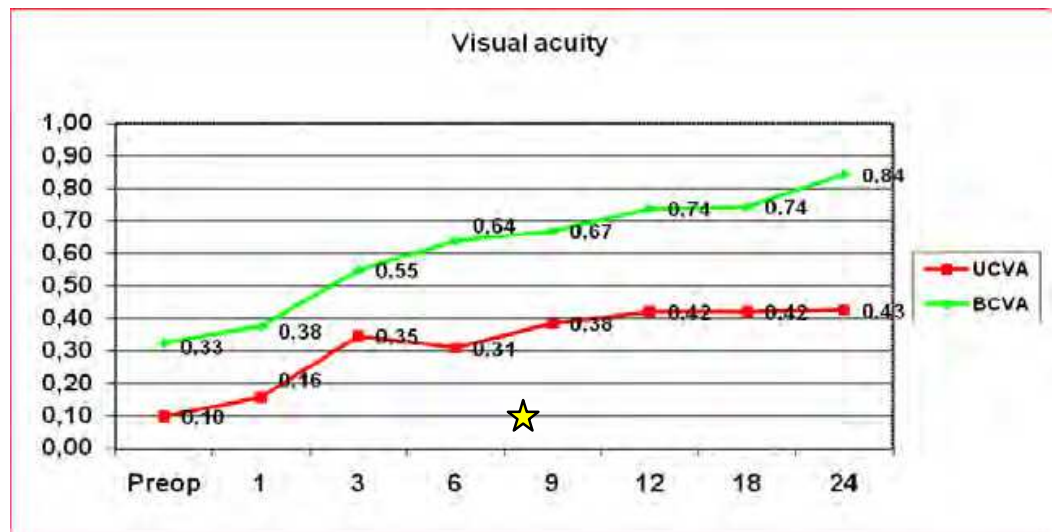


Fig. 8. Slit lamp examination (on the left) at 12 months shows a clear graft after all sutures removal. The topography analysis (on the right) shows a regular bow-tie “against the rule” astigmatism.



(the yellow star marks the mean suture removal period)

Fig. 9. Visual acuity results of Femto-DALK after 2 years (Mean follow-up : 32.94 months \pm 11,50SD)

Postoperative optical pachymetry evaluation with Optical Coherence Tomography (Visante, Carl Zeiss, Jena, Germany) and Confoscan4 showed a mean residual stromal bed thickness of $67.19\mu\text{m} \pm 13.19$ SD (range: 50 to 85 micron), three months after surgery (Fig.10). In three cases of our case series, a stromal rejection of the donor lamella occurred at 5, 16 and 18 months after surgery. The stromal reject was resolved in all cases only with topical steroid therapy (Fig. 11). Confocal microscopy analysis with Confoscan4 showed no recipient endothelium involvement, oedema of deep donor lamellar stroma, immunological infiltrates of the anterior stroma of donor lamella, and inflammatory infiltrates and oedema of epithelium of the graft (Fig. 12). The case observed 5 months after surgery developed four months later an herpetic keratitis of the donor lamella and was removed from the study after nine months of follow-up.

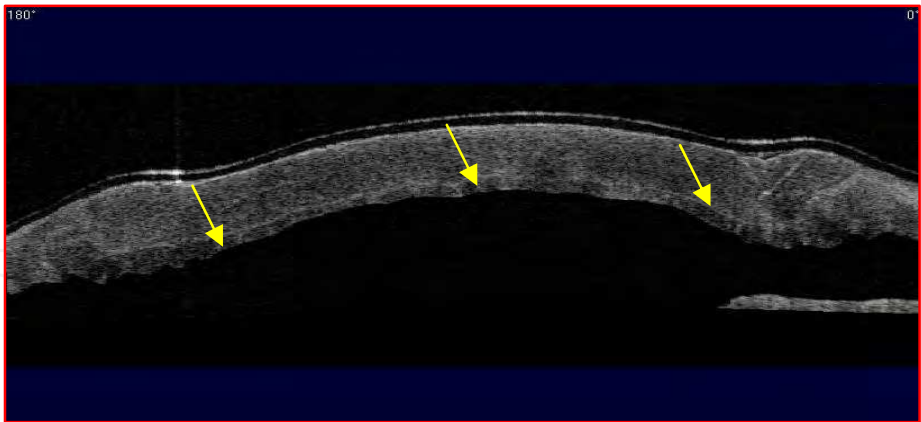

Fig. 10. Optical Coherence Tomography of a Femto-DALK shows a regular residual bed thickness 1 month after surgery (the yellow arrows mark the residual stromal bed).

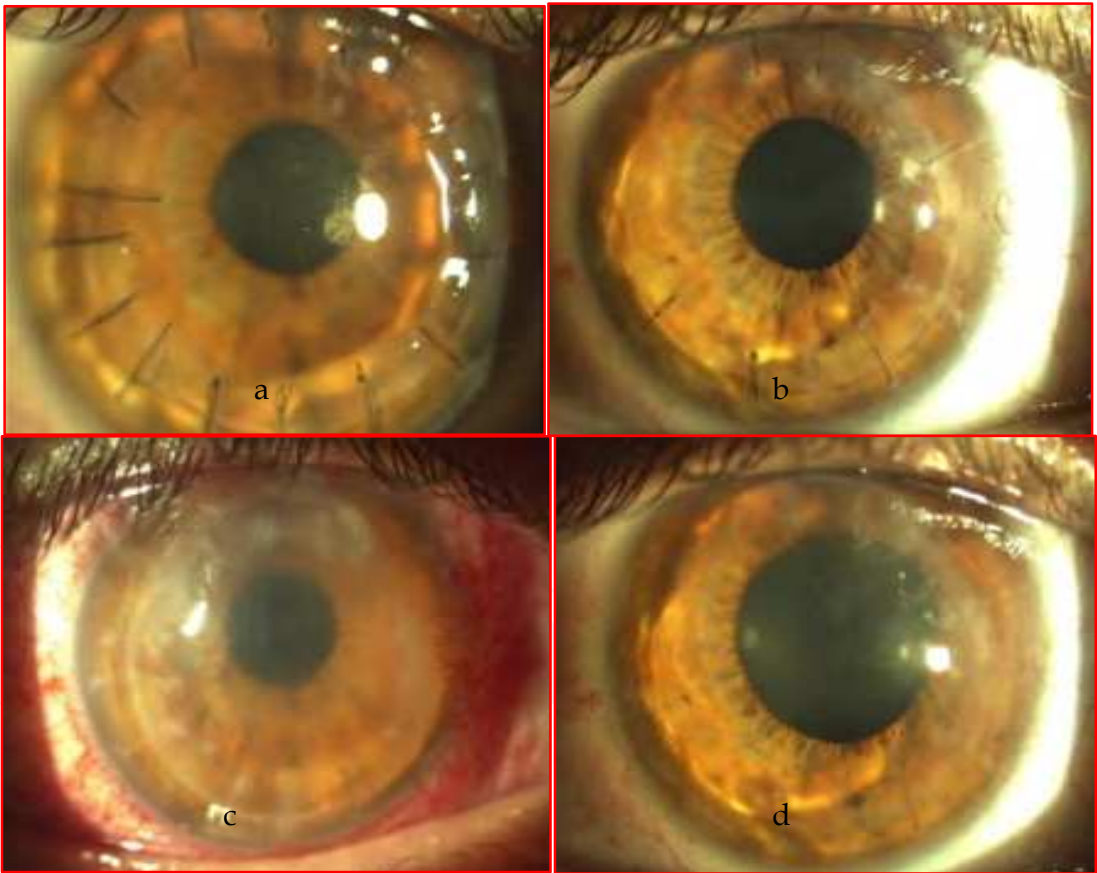


Fig. 11. Case of stromal reject 15 months after surgery: a. Clear graft two weeks after surgery; b. Clear graft before all suture removal nine months after surgery; c. Stromal rejection 15 months postoperatively with neovessels and massive stromal oedema; d. Complete resolution of the stromal rejection after two weeks of massive topical steroid therapy.

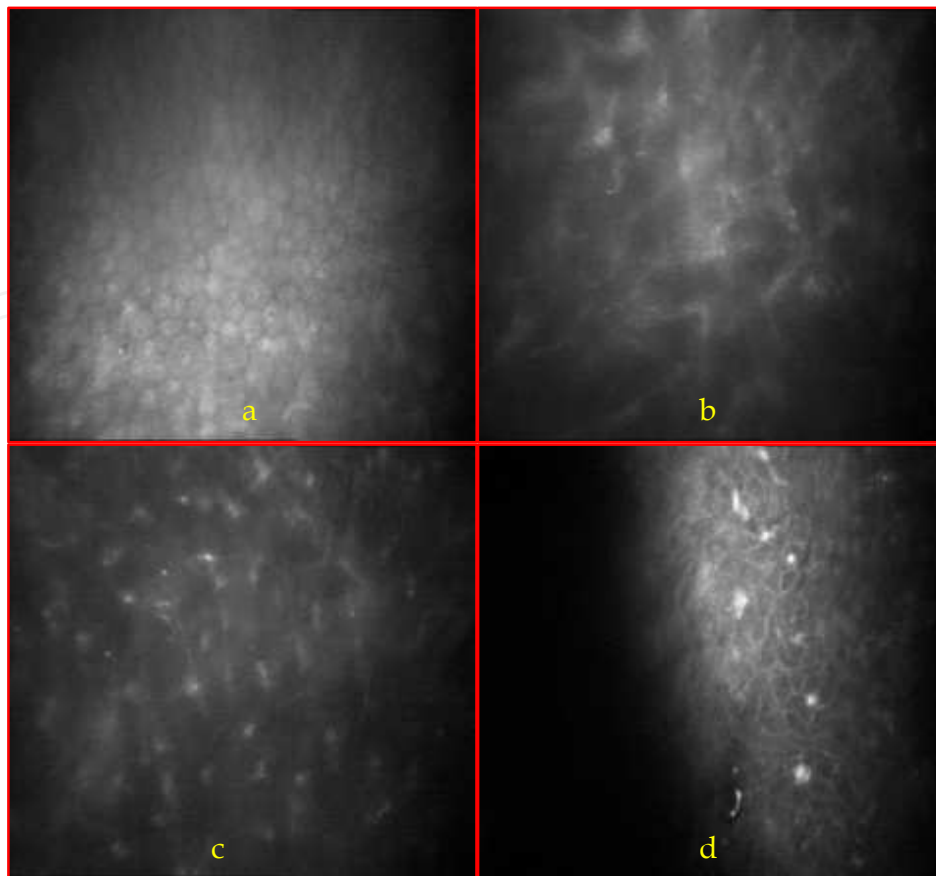


Fig. 12. Confoscan 4 confocal microscopy analysis of graft rejection of Femto-DALK: a. no recipient endothelium involvement, b. oedema of deep donor lamellar stroma; c. immunological infiltrates of the anterior stroma of donor lamella; d. inflammatory infiltrates and oedema of epithelium of the graft

4. Posterior Lamellar Keratoplasty Techniques (DSEK/DLEK)

4.1 Clinical experience with Femto-DSEK/DLEK

Another application of the femtosecond laser technology is the new frontier of lamellar surgery: the posterior lamellar keratoplasty (PLK).

The new technique of Descemet Stripping Endothelial Keratoplasty (DSEK)^{16, 17} assisted by a femtosecond laser has been planned to perform more regular and precise endothelial donor buttons.

We performed this femtosecond-assisted DSEK technique on 12 eyes of 12 patients using the original “taco” technique for endothelial lamella insertion.

4.2 Surgical procedure

The donor lamella is performed on an entire donor cornea delivered by an Italian Corneal Bank using an artificial anterior chamber (Moria, France) and the 60kHz femtosecond laser with a double raster pattern of 9mm diameter at 400 microns of depth. Then, the button is punched with a 8.50mm diameter corneal trephine and the two resulting lamellae are divided with forceps (Figure 13). The receiving bed is prepared in the usual way with endothelium/Descemet layer manual stripping. Then, the donor button is inserted in AC with the “taco” technique and settled in place with air injection.

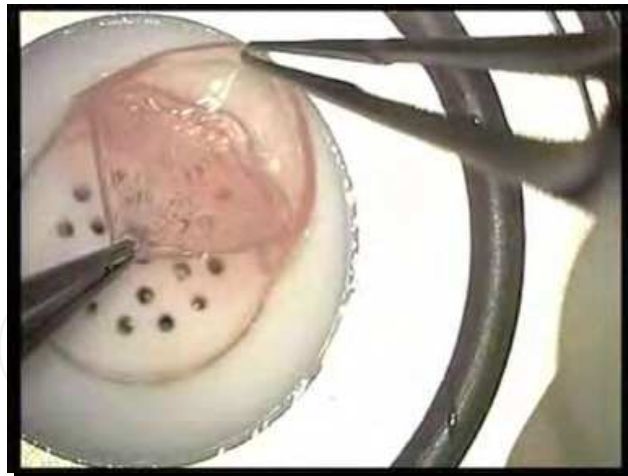


Fig. 13. Preparing the donor lamella: division the two lamellae with forceps after donor corneal punch.

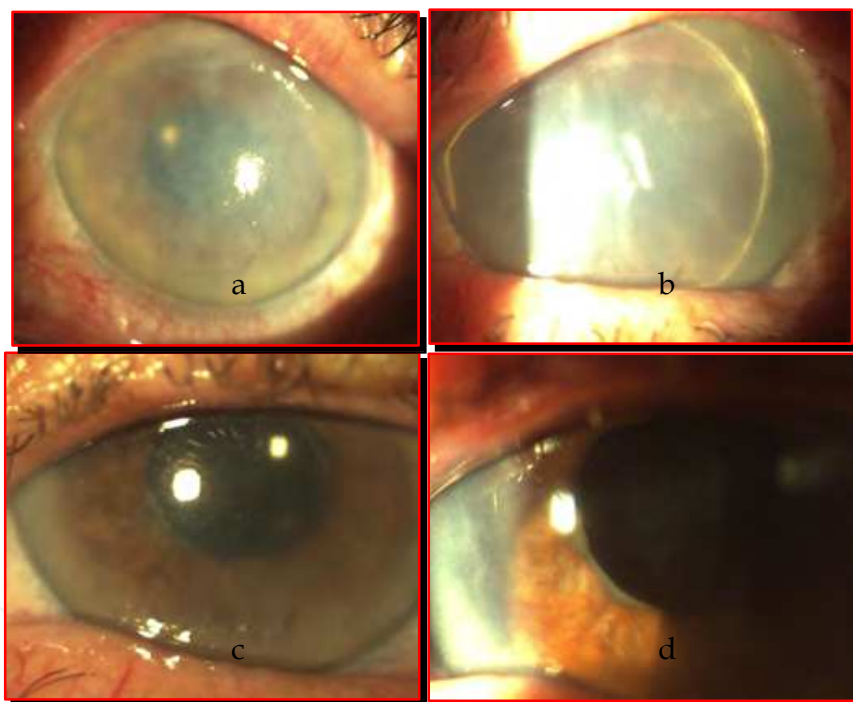


Fig. 14. Clinical case of Femto-DSEK (with “taco” technique): Preoperative slit lamp examination shows massive corneal oedema (a); One week postoperative shows corneal oedema, endothelial lamella centred with air in AC (b); one month postoperatively the corneal oedema is reduced (c) and three months postoperatively a clear graft is shown (d)

One day postoperatively, the donor lamella resulted in place in 9 cases (Figure 14). In three cases, the donor lamella resulted dislocated (Fig. 15), requiring a second air injection in AC to reposition it back.

One month after surgery the BSCVA resulted not so good (mean BSCVA 0.5 ± 0.15 SD) and increased slowly during the follow-up, resulting a little bit higher six months after surgery (0.58 ± 0.23 SD).

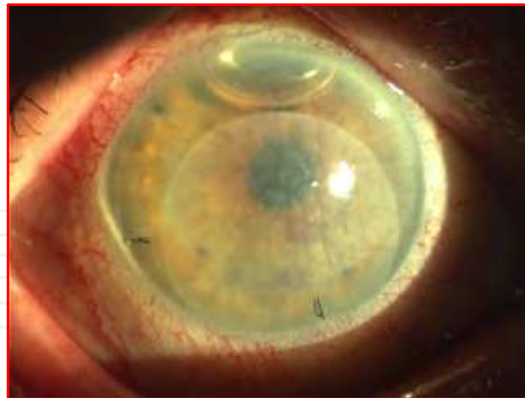


Fig. 15. Donor lamella dislocated downward three days after surgery.

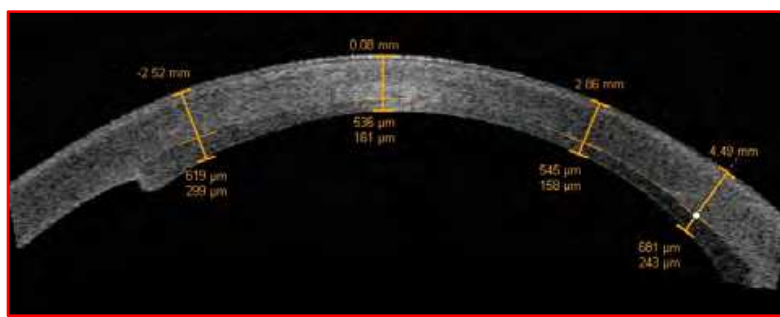

Fig. 16. Optical Coherence Tomography with Visante shows the endothelial lamellar thickness.

To assess the precision, safety and reproducibility of femtosecond laser cut we studied the donor lamellae with a Spectral Domain Optical Coherent Tomography analysis (Visante, Carl Zeiss Meditec, Jena, Germany). The planned donor lamellar thickness of $198\mu\text{m} \pm 25.45\text{SD}$ (range 190-210), resulted $177\mu\text{m} \pm 34.50\text{SD}$ (range 150-200) three months after surgery (Fig. 16). These results probably were related to the deswelling of the donor lamella during the follow-up.

Nevertheless, the greatest problem using the “taco” technique was the high surgical endothelial cell loss. In fact, with Confoscan 4 confocal microscopy analysis we found that endothelial cell loss was around 49% three months after surgery (preoperative mean ECD: 2389 ± 368 cell/mm² (range: 2150-2580; postoperative mean ECD: 1028 ± 582 cell/mm² (range 787-1550), with respect to the 22% of PK procedures. These higher rate resulted in a high graft failure percentage (around 55%).

For this reason, we began to utilize the “pull in technique” with the Busin folder. Utilizing this new device to insert the donor lamella, we performed the Femto-DSEK in 12 eyes of 10 patients with endothelial pathologies. With this technique, intraoperative endothelial cell loss resulted around 30%, with better postoperative results (Figure17). During the follow-up, two cases required endothelial lamella replacing and two cases required a penetrating keratoplasty after the DSEK failure for vision recovery.

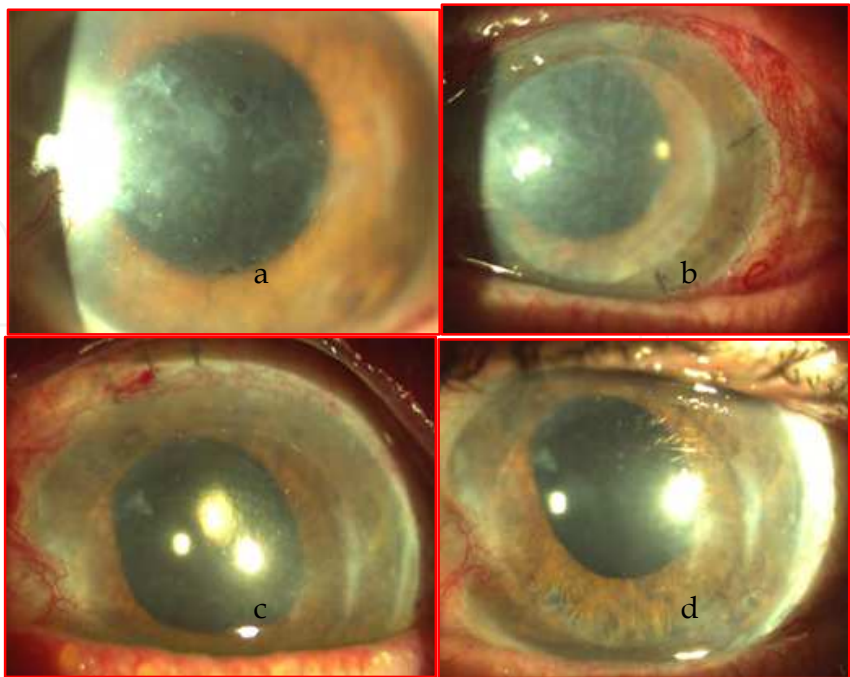


Fig. 17. Clinical case of Femto-DSEK (with Busin folder): Preoperative massive corneal oedema with bullous keratopathy (a); one week postoperatively the donor lamella is well adherent but corneal oedema is still present (b); One month postoperatively endothelial lamella is well centred and adherent with light corneal oedema (c); three months postoperatively there's a clear cornea and the BSCVA results 0.7 (d).

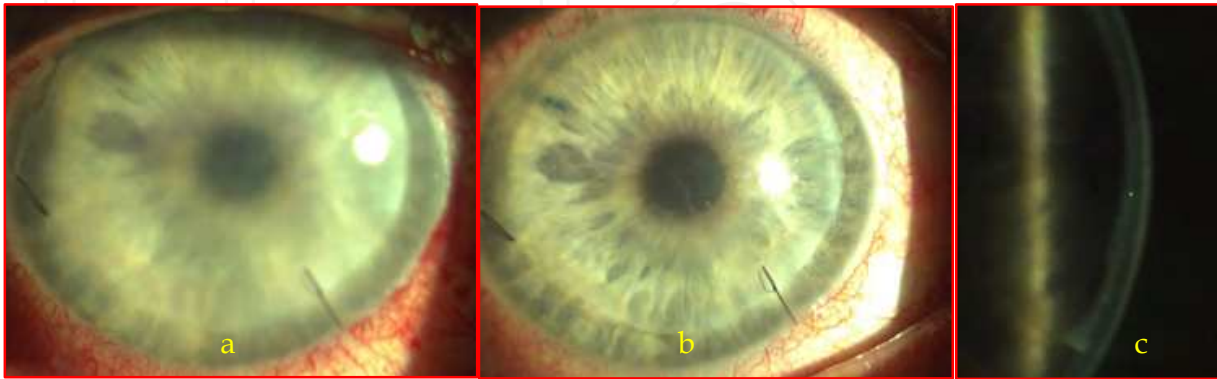


Fig. 18. Femto-DSEK: a. one week after surgery stromal oedema is still present; b. one month postoperatively a clear graft with little oedema well centred and strongly adherent to the internal surface but with the “step” between donor and recipient (c)




Fig. 19. Optical Coherent Tomography (on the left) of Femto-DLEK shows perfect “matching” of donor lamella like an “insert” into the recipient bed.

To avoid the problems of the endothelial lamellar dislocation (Figure 15) and the presence of the “step” between donor and recipient (Figure 18), we tried to perform a Femto-DLEK technique (basing on the Melles’ manual DLEK technique) using the femtosecond laser to perform the endothelial lamellar cut both in the donor cornea and the recipient one¹⁸. In this way we tried to realize a perfect “match” between donor and recipient cornea with the donor lamella “inserted” in the recipient bed (Figure. 19), but the stroma-stroma interface resulted in a hard scarring showing low visual results (0.3 or little more) with patient dissatisfaction that required a PK and we abandoned this technique.

5. Conclusions

Both the femtolaser assisted ALK and DALK techniques seem to be effective in restoring a clear and normal cornea with a good recovery one year after surgery with a mean BSCVA of 0.60 and 0.80, respectively. The Femto-DALK technique resulted more rapid in recovery time and more effective with results comparable to the manual descemetec DALK technique.

With the new femtosecond lasers machines developed by different manufacturers, femtolaser-assisted Anterior Lamellar Keratoplasties will be available to more surgeons.

The development of the femtosecond laser softwares and the possible association with scanning topography systems could help in performing customized treatment to the single cornea, improving the results reached with the empirical femtolaser-assisted ALK techniques.

Moreover, femtosecond laser allows to perform precise lamellar thickness graft for posterior lamellar keratoplasty. This application of the femtosecond laser showed good results especially associated with the Busin folder “pull-in” technique.

The femtosecond laser showed to be a dynamic surgical tool, enabling surgeons to perform safe and reproducible anterior and posterior lamellar keratoplasty procedures.

Nevertheless, we must be cautious in the application of this exciting technology, remembering that it is still “a work in progress” and the preliminary results need to be evaluated by longer follow-up.

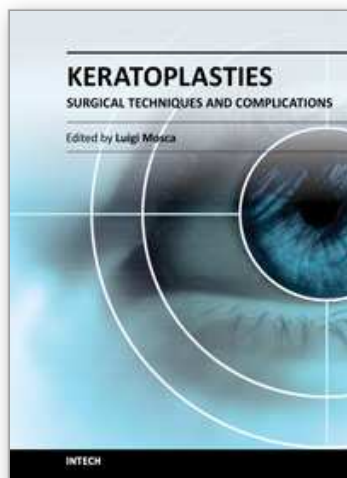
6. References

- [1] Laibson P R. Current concepts and techniques in corneal transplantation. *Curr Opin in Ophth* 2002; 13: 220-223.
- [2] Tan DT, Mehta JS. Future directions in lamellar corneal transplantation. *Cornea*. 2007 Oct; 26 (9 Suppl 1): S21-8.
- [3] Malbran E, Malbran E J, Malvran J. Lamellar keratoplasty in keratoconus. *Ophthalmology* 2001; 108 (6): 1010.
- [4] Busin M, Zambianchi L, Arffa RC. Microkeratome-assisted lamellar keratoplasty for the surgical treatment of keratoconus. *Ophthalmology*. 2005 Jun;112(6):987-97.
- [5] Buratto L, Belloni S, Valeri R. Excimer laser lamellar keratoplasty of augmented thickness for keratoconus. *J Refract Surg* 1998 Sep-Oct; 14 (5): 517-525.
- [6] Spadea L, Giammaria D, Fiasca A, Verrecchia V. Excimer laser-assisted lamellar keratoplasty for the surgical treatment of keratoconus. *J Cataract Refract Surg*. 2009 Jan;35(1):105-12
- [7] Ratkay-Traub I, Ferincz IE, Juhasz T, Kurtz RM, Krueger RR. First clinical results with the femtosecond neodymium-glass laser in refractive surgery. *J Refract Surg*. 2003 Mar-Apr;19(2):94-103.
- [8] Nurozler MO. Femtosecond laser holds promise for lamellar keratoplasty applications. *ESCRS Eurotimes*, vol 10, May 2005.
- [9] Mosca L, Fasciani R, Tamburelli C, Buzzonetti L, Guccione L, Mandarà E, Balestrazzi E. Femtosecond laser-assisted lamellar keratoplasty: early results. *Cornea*. 2008 Jul;27(6):668-72.
- [10] Ehrenhaus MP, Aliprandis E, Lazzaro DR. Sizing guidelines for performing lamellar keratoplasty with the Intralase femtosecond laser. *Invest Ophthalmol Vis Sci* 2006; 47: E-Abstract 3594.
- [11] Fontana L, Parente G, Tassinari G. Clinical outcomes after deep anterior lamellar keratoplasty using the big-bubble technique in patients with keratoconus. *Am J Ophthalmol*. 2007 Jan;143(1):117-124. Epub 2006 Oct 20.
- [12] Fournié P, Couillet J, Moalic S, Malecaze F, Chapotot E, Arné JL. Deep anterior lamellar keratoplasty in the surgical treatment of keratoconus. A 1-year follow-up. *J Fr Ophtalmol*. 2006 Jun;29(6):602-13.
- [13] Noble BA, Agrawal A, Collins C, Saldana M, Brogden PR, Zuberbuhler B. Deep Anterior Lamellar Keratoplasty (DALK): visual outcome and complications for a heterogeneous group of corneal pathologies. *Cornea*. 2007 Jan;26(1):59-64.
- [14] Shimmura S, Tsubota K. Deep anterior lamellar keratoplasty. *Curr Opin Ophthalmol*. 2006 Aug;17(4):349-55.
- [15] Balestrazzi E, Mosca L, Balestrazzi A. "Descemet's membrane dyeing technique" in *Atlas of Lamellar Keratoplasty*. Fabiano Ed, 2007.
- [16] Melles GRJ, Lander F, Dooren BTH. Preliminary clinical results of posterior lamellar keratoplasty through a sclerocorneal pocket incision. *Ophthalmology* 2000; 107: 1850-1857.
- [17] Terry MA, Ousley PJ, Will B. A practical femtosecond laser procedure for DLEK endothelial transplantation: cadaver eye histology and topography. *Cornea*. 2005 May;24(4): 453-9.

- [18] Mehta JS, Shilbayeh R, Por YM, Cajucom-Uy H, Beuerman RW, Tan DT. Femtosecond laser creation of donor ornea buttons for Descemet-stripping endothelial keratoplasty. J Cataract Refract Surg. 2008 Nov;34(11):1970-5

IntechOpen

IntechOpen



Keratoplasties - Surgical techniques and complications

Edited by Dr. Luigi Mosca

ISBN 978-953-307-809-0

Hard cover, 134 pages

Publisher InTech

Published online 18, January, 2012

Published in print edition January, 2012

In this book, the authors illustrate different therapeutic and surgical approaches to treating various corneal pathologies. This edition in electronic format allows universal access to everybody regardless of the time of day or setting, portability, and speed of information access. Such features show more feasibility for all readers and reduce the time necessary for research. This book will be a good tool for students as well as specialists working in the field of corneal transplantation, to improve their knowledge of treatment of corneal disease.

How to reference

In order to correctly reference this scholarly work, feel free to copy and paste the following:

Luigi Mosca, Laura Guccione, Luca Mosca, Romina Fasciani and Emilio Balestrazzi (2012). Femtosecond Laser Assisted Lamellar Keratoplasties, *Keratoplasties - Surgical techniques and complications*, Dr. Luigi Mosca (Ed.), ISBN: 978-953-307-809-0, InTech, Available from:
<http://www.intechopen.com/books/keratoplasties-surgical-techniques-and-complications/femtosecond-laser-assisted-lamellar-keratoplasties>

INTECH
open science | open minds

InTech Europe

University Campus STeP Ri
Slavka Krautzeka 83/A
51000 Rijeka, Croatia
Phone: +385 (51) 770 447
Fax: +385 (51) 686 166
www.intechopen.com

InTech China

Unit 405, Office Block, Hotel Equatorial Shanghai
No.65, Yan An Road (West), Shanghai, 200040, China
中国上海市延安西路65号上海国际贵都大饭店办公楼405单元
Phone: +86-21-62489820
Fax: +86-21-62489821

© 2012 The Author(s). Licensee IntechOpen. This is an open access article distributed under the terms of the [Creative Commons Attribution 3.0 License](https://creativecommons.org/licenses/by/3.0/), which permits unrestricted use, distribution, and reproduction in any medium, provided the original work is properly cited.

IntechOpen

IntechOpen