

We are IntechOpen, the world's leading publisher of Open Access books Built by scientists, for scientists

6,900

Open access books available

186,000

International authors and editors

200M

Downloads

Our authors are among the

154

Countries delivered to

TOP 1%

most cited scientists

12.2%

Contributors from top 500 universities



WEB OF SCIENCE™

Selection of our books indexed in the Book Citation Index
in Web of Science™ Core Collection (BKCI)

Interested in publishing with us?
Contact book.department@intechopen.com

Numbers displayed above are based on latest data collected.
For more information visit www.intechopen.com



Manual Deep Anterior Lamellar Keratoplasty

Farid Daneshgar
Kermanshah University of Medical Sciences
Iran

1. Introduction

Keratoplasty is considered the most successful organ transplantation procedure in the world. Reisinger was the first to use the term keratoplasty (Reisinger, 1824), when he suggested using an animal's eye to provide donor corneal tissue for corneal transplantation in a human. In 1906, the first successful penetrating keratoplasty was performed by Edward Konrad Zirm on a patient suffering from bilateral alkali burns (Zirm, 1906). Ramon Castroviejo created some fine instruments that were named after him and was the first to perform successful penetrating keratoplasty using fine sutures (Castroviejo, 1932). His square-shaped grafts survived for many years and provided good vision for his patients.

In 1886, Von Hippel performed lamellar corneal transplantation (Von Hippel, 1888). The concept of deep lamellar corneal dissection and leaving the Descemet membrane (DM) intact was first proposed by Von Walther and was described further by Muhlbauer (Muhlbauer, 1824). A full-thickness donor corneal tissue without any dissection through the corneal stromal tissue was proposed for lamellar keratoplasty in 1959 (Hallermann, 1963). Hallermann proposed both full-thickness donor graft with the endothelium (FTDGE) and full-thickness donor graft without the endothelium (FTDG) over a deeply dissected corneal stromal recipient's bed for lamellar keratoplasty. Morrison and Swan provided histopathologic evidence that FTDG is associated with less inflammation and scarring than FTDGE (Morrison & Swan, 1982).

Today, removing the corneal stromal tissues down to the DM or the pre-Descemet membrane level and using a FTDG is the standard of care for patients requiring deep anterior lamellar keratoplasty (DALK) surgery. Many techniques have been developed for performing DALK surgery. Before reviewing some surgical techniques for the procedure, I will discuss some factors that influence the visual outcomes.

2. Major factors influencing the visual outcome after DALK surgery

2.1 Clear donor tissue

The purpose of lamellar corneal transplantation is to substitute the diseased parts of the cornea by a clear donor tissue.

2.2 Clear remaining corneal tissue in recipient

A corneal surgeon must be vigilant to remove every opacified or scar tissue from the stromal bed. Involvement of the DM and adjacent tissues with scarring could be considered a contraindication for DALK surgery.

2.3 Deep plane of recipient's corneal stromal dissection

Lamellar corneal grafts are classified according to the depth of dissection through the recipient's corneal stromal tissues.

2.3.1 Superficial anterior lamellar keratoplasty (SALK)

The dissection plane is up to 160 μm or about 30% of corneal thickness from the surface.

2.3.2 Mid-anterior lamellar keratoplasty (MALK)

The dissection plane is from 160 to 400 μm or about 30% to 70% of corneal thickness from the surface.

2.3.3 Deep anterior lamellar keratoplasty (DALK)

The dissection plane is 400 μm from the surface to the DM. However, from the terminology viewpoint, the term maximum-depth anterior lamellar keratoplasty (MD-ALK) is used when the bare DM is exposed in the recipient's cornea and the term total anterior lamellar keratoplasty (TALK) is used when the bare DM is exposed in the recipient's entire corneal bed and no remaining corneal stromal tissue is present within the trephination wound area. Generally, the wound repair process is accompanied by more scar formation and opacification in the superficial corneal stromal layers compared to the deep corneal stromal layers. So the deeper the dissection plane in the recipient's corneal stromal tissues, the lower is the risk of irregularities and scarring in the interface.

2.4 Smooth posterior surface of donor tissue

The smoothest posterior surface of the donor tissue is provided when no dissection cuts through the stromal tissues, FTDG is used, and the DM and endothelial cells are wiped out gently.

2.5 Smooth anterior surface of recipient's tissue

The smoothest surface of recipient's bed is provided when the bare DM is exposed in the recipient's cornea.

2.6 Clear interface

The interface between donor and recipient tissues should be washed thoroughly to eliminate the risk of any retained material in the interface, such as viscoelastic material or filaments especially over the optical zone of the cornea.

2.7 Uniform thickness of donor tissue throughout the graft area

Because the normal corneal thickness gradually increases from the central area toward the peripheral area, great care must be taken to avoid any decentration of the donor tissue when it is cut by a corneal punch. Decentered punching of the donor cornea will result in a donor button that has different thicknesses around the edge of its circumference.

2.8 Uniform thickness of recipient's tissue throughout the graft area

Many corneal surgeons focus their attention on removing the corneal stromal tissues over the central area to expose the bare DM. They may pay little attention to removing adequate stromal tissues near the trephination wound to make a uniform thickness recipient bed for

transplantation. It should be emphasized that removing adequate stromal tissues near the trephination wound is as important, if not more important, than doing so in the central cornea. If the task is not performed, the Bowman-to-Bowman opposition of the donor and recipient will occur by excessive force over the sutures and unpredictable visual results will occur when sutures are removed or when sutures lose their tensile strength. The ideal situation is provided by the TALK procedure in which the DM is exposed in the entire trephination wound area. In TALK cases, early removal of corneal sutures can be accompanied with good visual results.

2.9 Minimal irregularities of the anterior surface of the donor tissue over the optical zone

Given a donor cornea devoid of any preexisting pathology, the corneal sutures will be the major source of irregularities of the anterior corneal surface. In fact, the irregularities originate from the suture sites and radiate over the corneal surface vanishing toward the central area. So the further the distance between a given point over the corneal surface and a suture site, the less the amount of irregularity at the specific point.

If we liken the irregularities that originate from the sutures to the cold winds and the optical zone to a freezing man, it could be said that cold wind of irregularities blow from the suture sites toward the optical zone so the best way to protect the freezing man in the optical zone from the cold wind of irregularities will be to put it at the center of the circle (Figure 1)

Hence, selection of the pupil center as the center of the trephination wound protects the optical zone from adverse effects of the sutures all around the wound.



Fig. 1. Visual axis can be kept away from the sutures at the center of the circle just as the Freezing man keep himself away from the cold winds.

3. Indications for optical DALK surgery

DALK is indicated for conditions associated with opacification of the corneal stromal tissues over the central area of the cornea while the DM and endothelium are normal and not involved. The opacification may be due to trauma, infections, iatrogenic causes, chemical insults, dystrophies, or degenerations.

DALK is also used for ectatic corneal disorders with normal DM and endothelium, such as keratoconus, keratoglobus, pellucid marginal degeneration, or ectasia occurring after LASIK surgery.

4. Surgical techniques

The superiorities of DALK over penetrating keratoplasty cannot be overemphasized. However, for obtaining best results, a corneal surgeon must be familiar with different surgical maneuvers used for performing DALK. In this overview of some techniques for performing DALK, some surgical “pearls” will enrich our repertoire of skills.

4.1 Using air to perform DALK

In 1984, Arenas introduced the concept of injecting air into the corneal stroma for performing DALK and the technique was named air-deep lamellar keratoplasty (AD-LKP) (Arenas, 1985). He injected air into superficial corneal stromal tissues at the peripheral cornea. Then a partial-thickness trephination cut of about 400 μm was performed in the resultant emphysematous, white corneal tissue. The superficial corneal layers were removed using sharp blades and deep stromal layers were removed using blunt spatulas until reaching the pre-Descemet level. The movement of the spatulas was centripetally starting at the wound margins and ending at the center or thinnest part of the cornea. He described the pre-Descemet layer as a black and shiny surface devoid of air. The DM was not exposed by this technique; however, after long-term follow-up, the visual results were better than those for penetrating keratoplasty.

4.2 Using shearing and traction force instead of cutting to perform DALK

Malbran introduced the peeling-off technique (Malbran, 1966). His concept of a peeling rather than a cutting action for removing the recipient's corneal stromal tissues provided a smoother surface that served as the bed for transplantation. In this technique, the stromal tissues are pooled in a direction that is perpendicular to the corneal surface and a semi-sharp instrument leads the direction of shearing of tissue through the corneal stromal layers. He also modified his technique by combining it with intrastromal air injection. The intrastromal air facilitates tissue removal and also provides some assistance for differentiating the pre-Descemet layer from more superficial stromal layers. He used the pre-Descemet layer as the bed for the FTDG while he did the DALK procedure. He performed large-diameter grafts (9-10 mm) and reported that the astigmatism was usually regular from the first postoperative day. It seems that large-diameter grafts provide enough distance between suture sites and the visual axis to protect it from cold winds of irregularity (Factor 9 above). In my experience, regular astigmatism on the first postoperative day can be obtained with an 8-mm wound area if the center of the trephination wound has been set over the pupil center.

4.3 Using fluid to perform DALK

Sugita and Kondo introduced the technique of hydrodelamination (Sugita & Kondo, 1997). They injected a balanced salt solution (BSS) into the stromal bed after a lamellar dissection of the cornea. The injection made the stromal collagen fibers swell. A spatula was introduced into the hydrated area and the stroma was dissected by moving the spatula in a fanlike motion. They called this maneuver “spatula delamination.” The overlying dissected tissues were removed and the maneuver was repeated until the bare DM was reached in the central cornea. This technique has the advantage of discriminating between normal and pathologic cornea because the pathologic cornea (usually scar) does not swell as well as the normal cornea when being hydrated. This allows the surgeon to determine the depth of the pathology in the corneal stroma.

4.4 Using air and fluid to perform DALK

Anwar and Teichmann combined the use of air and fluid for planned near-Descemet membrane dissection for performing DALK (Anwar & Teichmann, 2002). They recommended that this technique be used in patients in whom exposing the DM carries a high risk of DM perforation. Such conditions include deep corneal scars involving the DM, patients with keratoconus who have experienced hydrops, those with known DM fragility such as macular dystrophy, and inexperienced corneal surgeons performing occasional lamellar grafts. They created some swelling in the stromal bed after a lamellar dissection by hydrating the stromal collagen fibers. They injected air into the swollen area and removed the resultant emphysematous tissues using Anwar’s keratoplasty spatula and repeated the maneuver until they reached the pre-Descemet layer. They described the layer as a semitransparent tissue with the pupil and iris pattern visible through the layer. They concluded that the risk of DM rupture is lower with this technique compared to injecting air alone because the hydrated tissues are thickened and introducing the needle and spatula into the thickened tissue carries a lower risk of violating the DM.

4.5 Using viscoelastic material for performing DALK

Manche and colleagues used viscoelastic material for separating the DM from the overlying stromal tissues (Manche et al., 1999). They used forceful injection of the viscoelastic material into a pocket incision to make a cleavage plane between the DM and posterior stroma. The pocket was made by a Paufigue knife and was parallel to the stromal collagen fibers. Melles and coworkers described the “air-to-endothelium” light reflex as a guide for approaching the DM–stroma interface (Melles et al., 1999). They described a “dark band” between the blade tip and a specular light reflex as the non-incised stromal tissue before reaching the DM–stroma interface. By advancing the blade tip through the dark band the custom-made blade reached the DM–stroma interface and they redirected the blade parallel to the interface to separate the overlying tissues. In 2002, Melles and colleagues introduced the visco-dissection DALK (Melles et al., 2002). They injected viscoelastic material directly over the DM using the air-to-endothelium light reflex as a guide for precise location of the injection for making a DM detachment over an area that was going to be cut by a vacuum trephine. In fact, a TALK procedure has been performed by removing the overlying tissues and using the FTDG.

4.6 Using dye for performing DALK

Balestrazzi and colleagues used a 0.02% solution of trypan blue for staining the stromal collagen fibers (Balestrazzi et al., 2002). This facilitated the discrimination of the stromal

fibers from underlying DM. John used indocyanine green and forced hydrodissection for performing TALK (John, 2004). This technique benefits from both hydrating the collagen fibers to create stromal swelling for introducing spatulas into the stromal tissues safely and using dye for discriminating the stromal fibers from the underlying DM.

4.7 Using air for DM detachment in performing DALK

Anwar and Teichmann introduced the big-bubble technique for performing DALK (Anwar & Teichmann, 2002). The technique is a fast method for separating the DM from corneal stroma. The air is injected in the deep layers of the corneal stromal tissues after a partial-thickness trephination cut of about 60% to 80% of the corneal thickness. In most cases a big bubble is formed at the DM–stroma interface and a circular white outline demarcates the borders of the air bubble. The overlying corneal tissues are removed to expose the DM and provide the recipient bed for performing MD-ALK. This technique is used by many corneal surgeons throughout the world for performing DALK.

Large-bubble modified technique for performing DALK was introduced in 2010 (Behrooz & Daneshgar, 2010). The rationale of this technique was to create an air bubble at the DM–stroma interface that was larger than the trephination wound so that total removal of the corneal stromal tissues could be accomplished with scissors to perform the TALK procedure. The “expanding-bubble modification of the big-bubble technique” (Daneshgar & Fallahtafi, 2011) is the method that I believe is useful for providing full exposure of the DM and performing TALK. The procedure is performed as follows:

A partial-thickness trephination to a depth of about 60% to 80% of the corneal thickness is performed as described in the big-bubble technique (Anwar & Teichmann, 2002). The center of the pupil is determined as the center of trephination using an 8- to 8.25- calibrated trephine (Katena Products, Denville, NJ) for an average cornea (Figures 2 and 3).

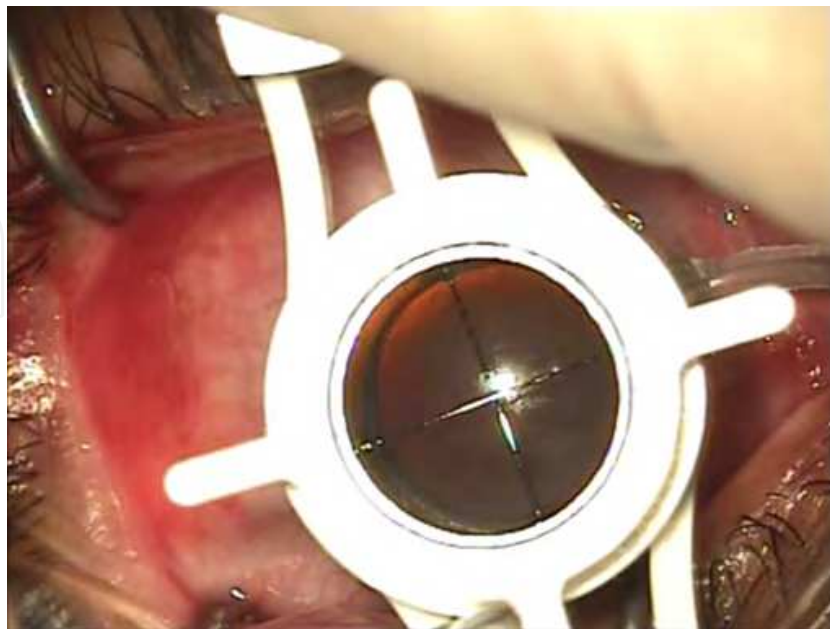


Fig. 2. Center of the pupil is considered as the center for trephination cut. Note that the pupil is dilated due to the injection of retrobulbar anesthetic solution.

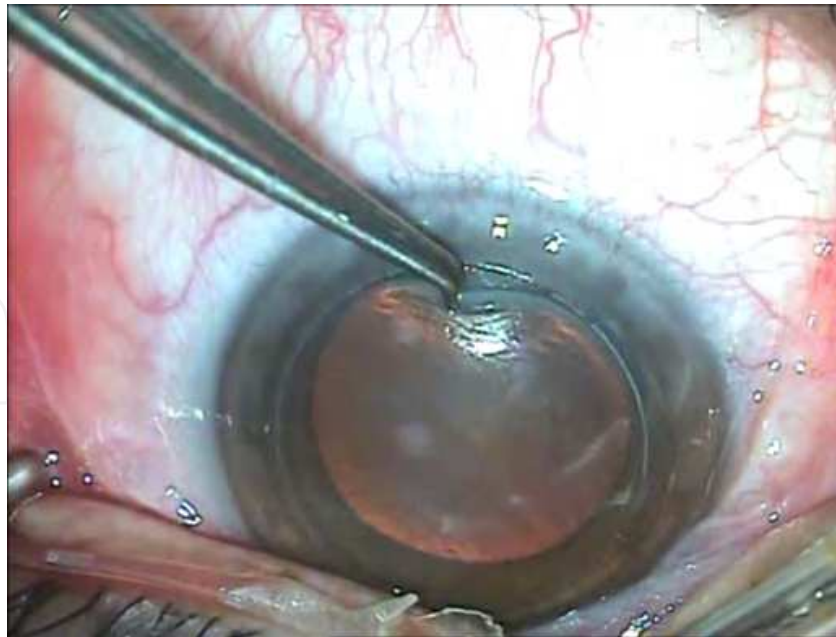


Fig. 3. Depth of the trephination wound is checked using a fine toothed forceps.

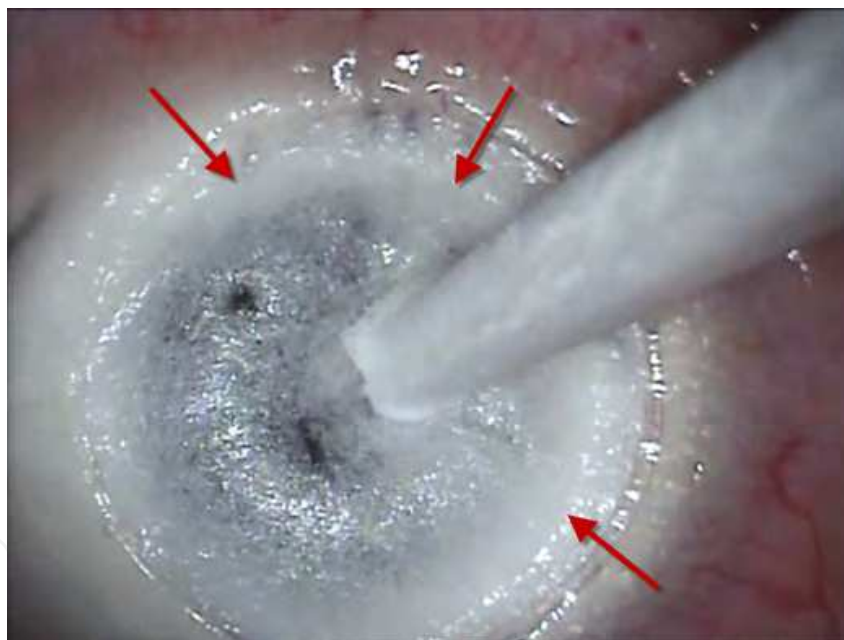

Fig. 4. Sunny side up sign, red arrows point at a circular furrow encircling the air bubble at the DM_ stroma interface.

A 27-gauge needle attached to an air-filled syringe is inserted bevel down into the deep stroma in the paracentral cornea as in the big-bubble technique. After air is injected, a paracentesis wound is performed using a stab knife (Eagle Laboratories, Rancho Cucamonga, CA) in a semivertical direction to drain aqueous fluid. A crescent blade (Eagle Laboratories) is used to excise emphysematous stromal tissues as in lamellar keratectomy. The paracentesis wound is widened to 3 mm with the stab knife and the posterior lip of the wound is depressed to drain some aqueous fluid to make the anterior chamber obviously hypotensive. A dry Weck-Cel® sponge is used to depress the cornea. When a big bubble

forms, the outline of the bubble is obviously seen as a circular furrow around a dome-shaped elevation in the center, similar to the yolk of a sunny-side up egg (Figure 4).

This sunny-side up sign is useful for determining the presence and extent of the air bubble. The diameter of the bubble can easily be measured using calipers. In most instances the diameter of the bubble is about 6 to 7 mm and the border of the air bubble coincides with the trephination wound inferiorly and lies within about 2 mm inside the trephination wound superiorly (Figure 4). It may also be smaller in size, usually when repeated attempts at air injection have been needed (Figure 5),

It may form eccentrically as the bubble border extends beyond the trephination wound over a specific area and lies within the trephination wound in some other area (Figure 6).

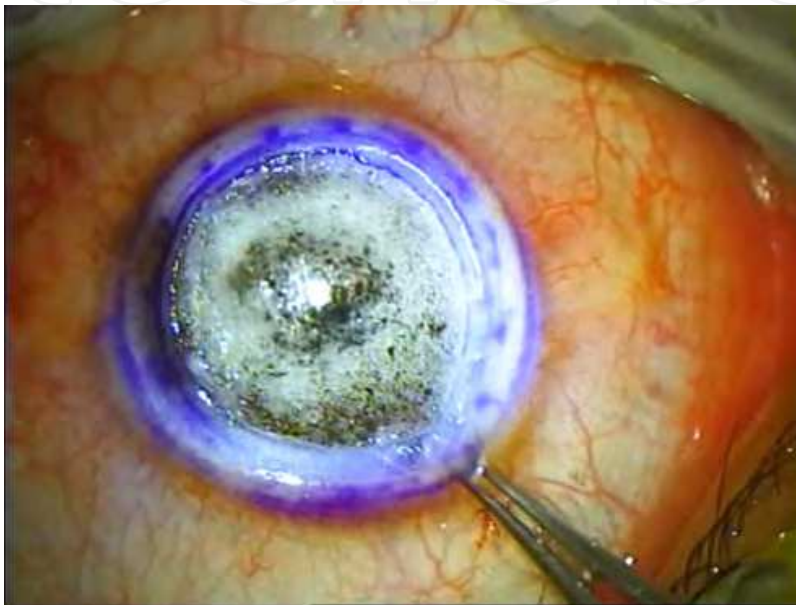


Fig. 5. Sunny side up sign with a small egg yoke.

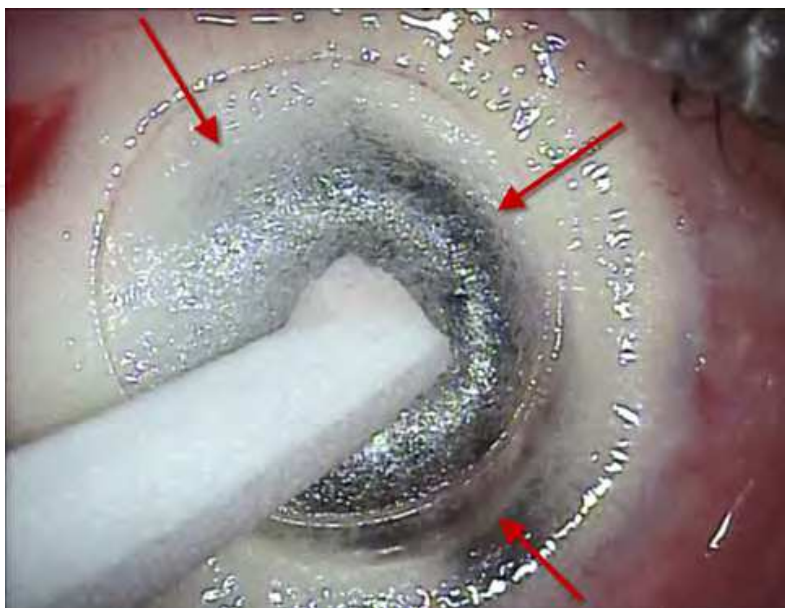


Fig. 6. Eccentric big-bubble. The air bubble extends beyond the trephination wound inferiorly. Red Arrows point at the boundaries of the big-bubble.

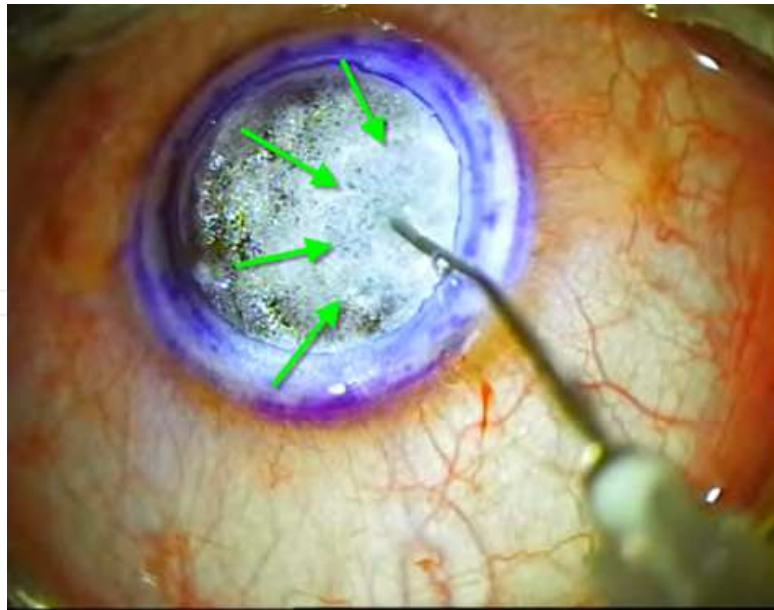


Fig. 7. Green arrows point at the hydrated area in the corneal stromal bed.

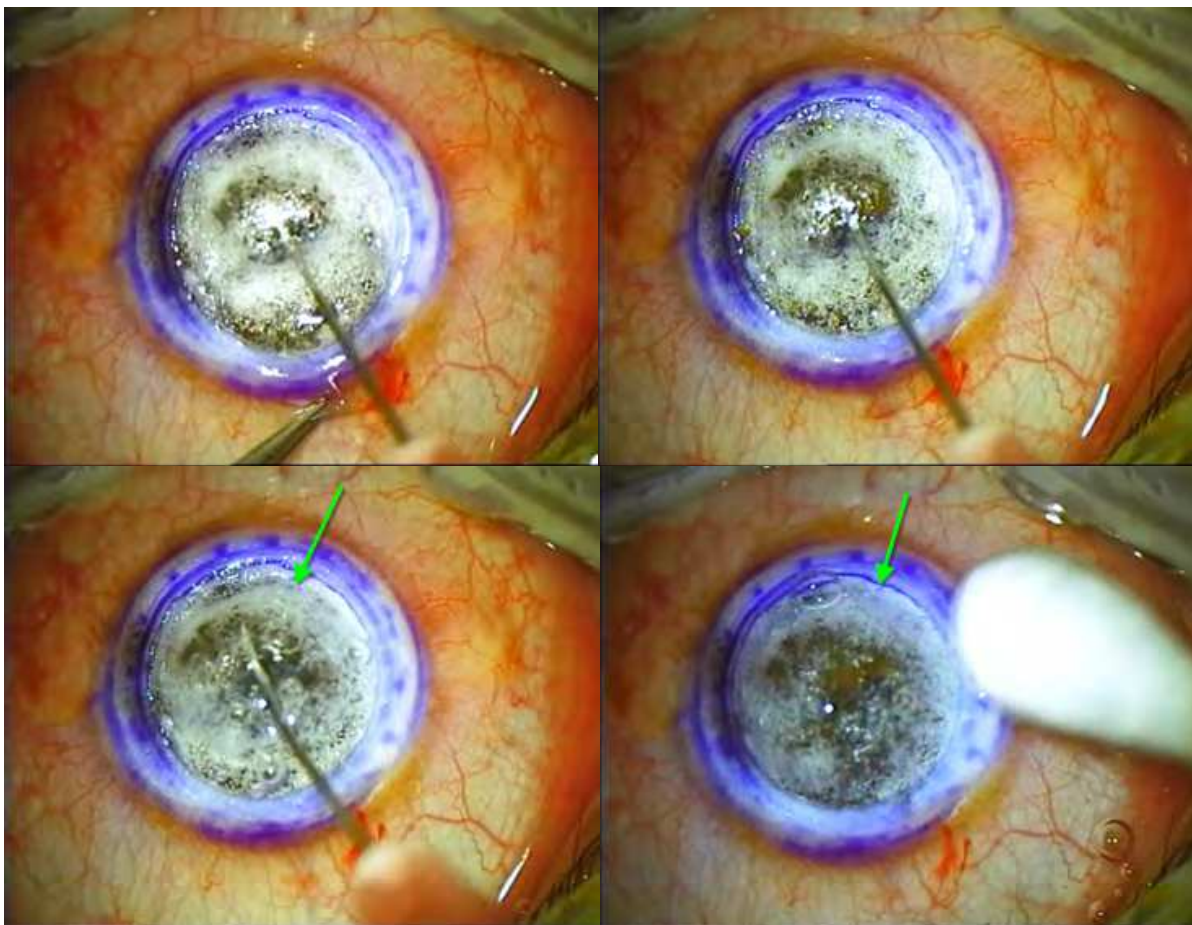


Fig. 8. The bubble is expanded by injecting viscoelastic material into the bubble cavity. Viscoelastic injection is discontinued and the needle is withdrawn when the demarcating furrow reaches the trephination wound circumference.

When no big bubble is formed, the procedure is continued by hydrating a localized area in the stroma with BSS. There is no need for introducing a needle into the corneal stromal tissues for hydrating the collagen fibers; instead we can use a blunt-tipped cannula attached to a syringe filled with BSS to hydrate the stromal tissues by putting the blunt tip in close contact with the stromal tissues in a perpendicular direction and injecting fluid while depressing the tissues by the tip of the cannula (Figure 7). Air injection is repeated in the hydrated area using the same 27-gauge needle and an air-filled syringe. After the sunny-side up sign is seen, the 27-gauge needle used for air injection is attached to a syringe containing viscoelastic material (Coatel™; Bausch & Lomb, Madison, NJ). Viscoelastic material is injected while the needle is inserted into the bubble cavity in the horizontal direction with a rapid movement.

The injection of the viscoelastic material into the bubble cavity is continued slowly as the “egg yolk” is expanded slowly (Figures 8-9).

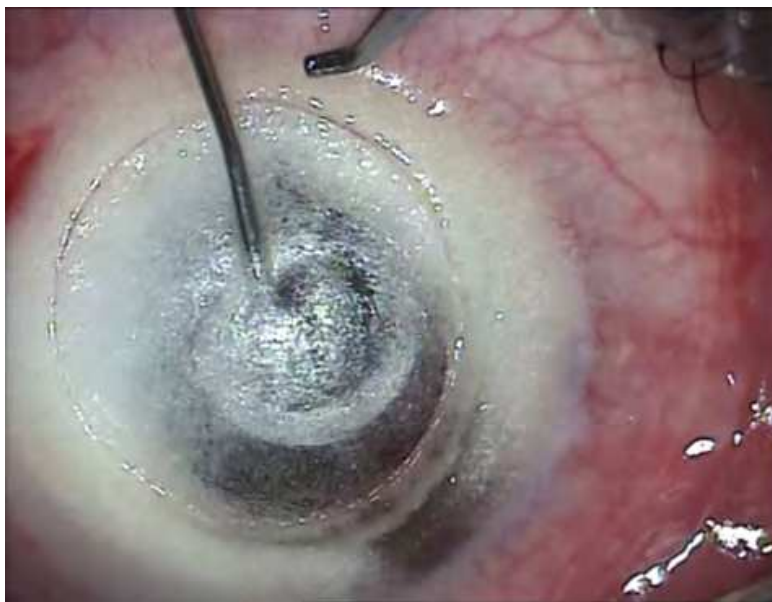

Fig. 9. Viscoelastic material is injected into the bubble cavity.

Care must be taken not to depress the cornea while injecting the viscoelastic material or to overexpand the bubble beyond the trephination wound because these actions may rupture the DM. Just as the demarcation furrow reaches the trephination wound margins, the injection of viscoelastic material is stopped and the needle is withdrawn. The stab knife is used to incise the roof of the bubble (Figure 10).

The stromal tissues at the anterior wall of the bubble are excised using curved blunt-tipped corneal scissors (18010; Moria, Antony, France) around the trephination wound circumference (Figure 11).

The DM is exposed to the full extent (Figure 12).

The donor tissue is prepared by disinserting the DM and endothelium from peripheral insertion using a dry Weck-Cel® sponge and wiping it off from the posterior surface of the corneal stroma. A vital dye can be used to stain the endothelium and DM for discriminating the layer from stromal tissues and easy removal of the layer, but I usually put the donor tissue over the back surface of a steel container. The shining reflex of the steel surface facilitates the visualization of the delicate DM (Figure 13).

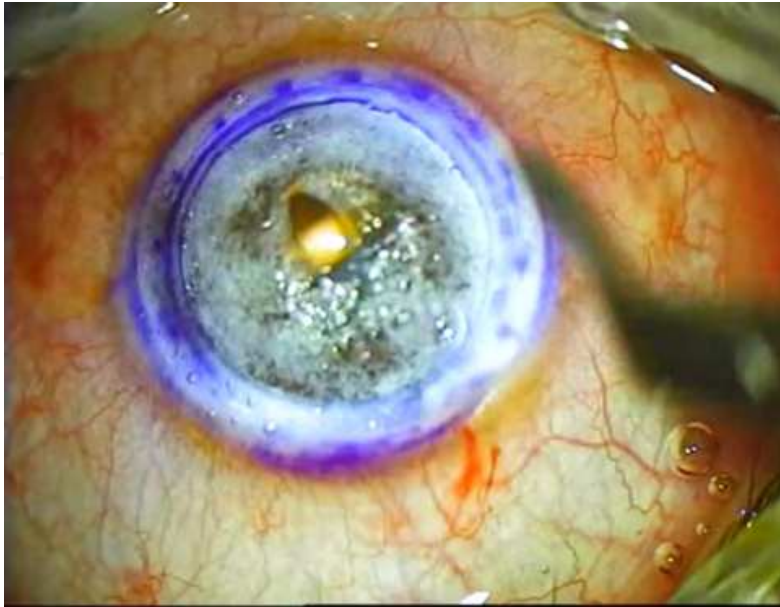


Fig. 10. Anterior wall of the bubble is incised using a stab knife.

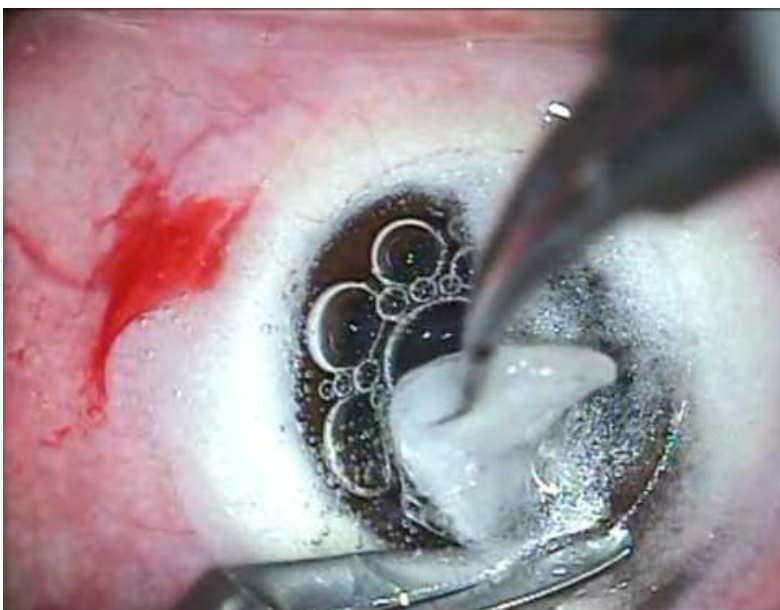

Fig. 11. Anterior wall of the bubble is excised using blunt tip curved scissors along the trephination wound circumference leaving no corneal stromal tissues within the trephination wound area.

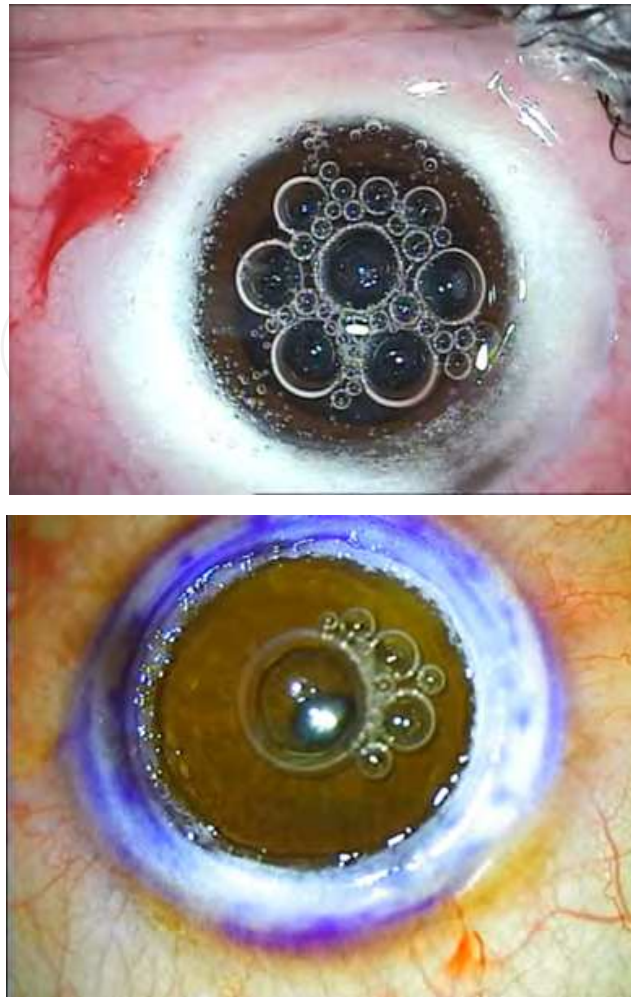


Fig. 12. Descemet mambrane is exposed troughout the entire trephination wound area.

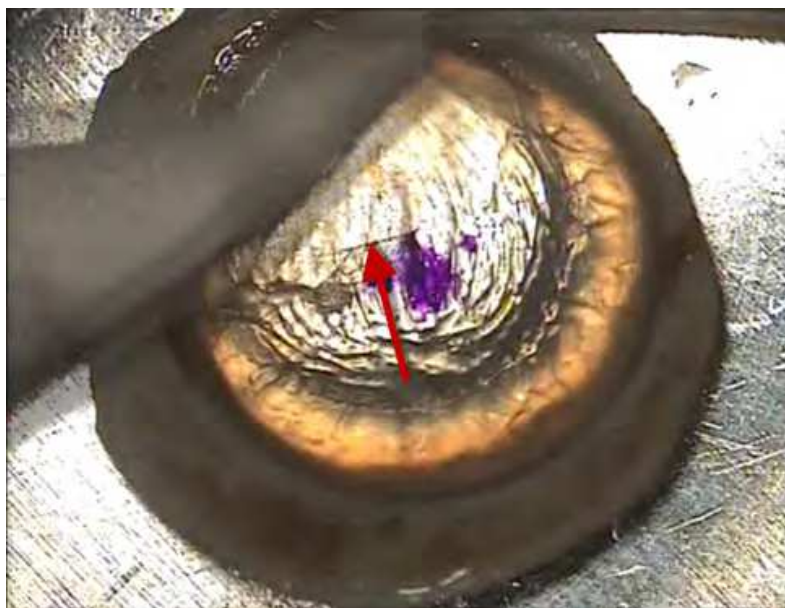


Fig. 13. Dry Weck-Cel sponge is used for disinserting DM from the peripheral insertions and wipping it off from posterior surface of the donor cornea.

After this stage no manipulation of the recipient's bed is allowed because no endothelium is present in the donor tissue for converting to penetrating keratoplasty if required. I always remove any residual episcleral and scleral tissues except a small rim around the limbus because those excessive tissues may cause decentered punching of the donor tissue if the punch is not equipped with a suction system (Figure 14).

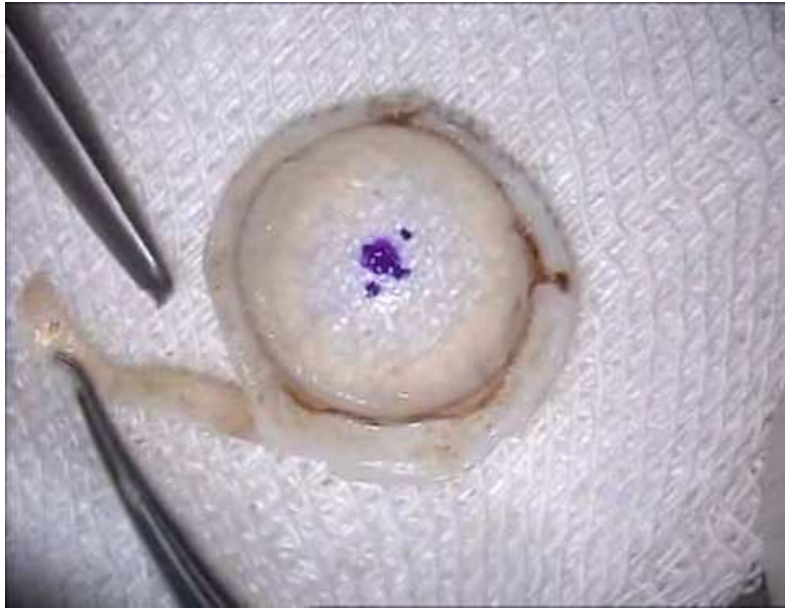

Fig. 14. Excessive scleral tissues are excised.

Conversely, care must be taken not to violate the limbus. Cutting the limbal tissues by scissors will result in an ellipsoid rather than round donor button. Loose corneal epithelium may result in donor tissue slippage and decentered punching if the donor tissue is not fresh.

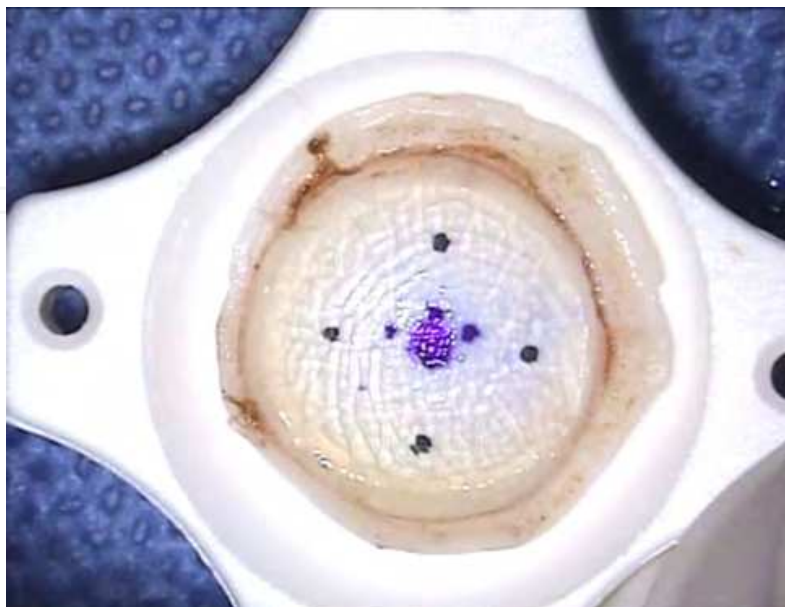


Fig. 15. Geometrical center of the donor cornea is considered as the center for cutting the donor tissue using a corneal punch.

Hence, if the corneal epithelium is loose and edematous it must be wiped away using an applicator. The precise geometric center of the donor cornea is determined and marked. The donor cornea devoid of endothelium is put in a corneal punch (Katena Products) using the mark for centration (Figure 15) and is cut to the desired size.

I routinely put some viscoelastic material over the punch blade before cutting, which is useful in creating a more even and smoother edge of the cut donor button. Conversely, the edge of the donor button might become “s” shaped especially if the punch blade is not sharp enough (Figure 16).

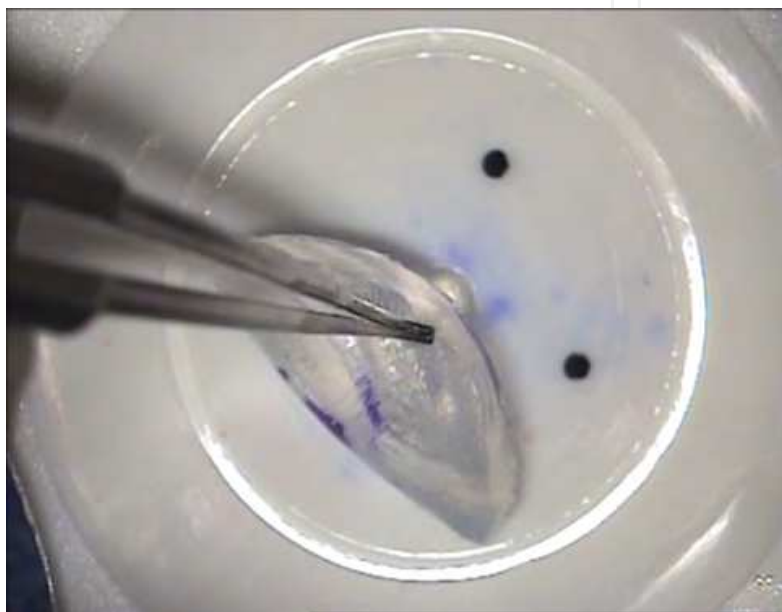

Fig. 16. A coin shape donor button with vertical edges is achieved.

Ultimately, the donor button is secured in the recipient site with sutures (10-0 nylon). The exposed surface of the DM is irrigated with free-flowing BSS for removing the viscoelastic material completely after placing the first corneal suture (Figure 17). I prefer to perform mixed continuous and separate sutures (Figures 18-20). In the TALK procedure the depth of the sutures traveling through the corneal tissues is identical at both sides of the graft interface and is approximately 80% to 90% of the corneal thickness at both donor and host tissue sides. If no big bubble is formed after several attempts at air injection, a deep lamellar dissection is performed with a crescent knife to the pre-Descemet level. The tiny air bubbles can be recognized at the DM–stroma interface under high microscopic magnification. The viscoelastic material is injected after inserting the tip of a 30-gauge needle attached to the viscoelastic syringe into a tiny bubble and the bubble will begin to expand. If the overlying collagen fibers are not removed sufficiently, the bubble will expand into the anterior chamber and the surgeon must drain the aqueous fluid from the anterior chamber to provide space for the bubble to expand. If the overlying collagen fibers are minimal, the bubble will expand over the DM toward the outer space and the procedure will continue as described above.

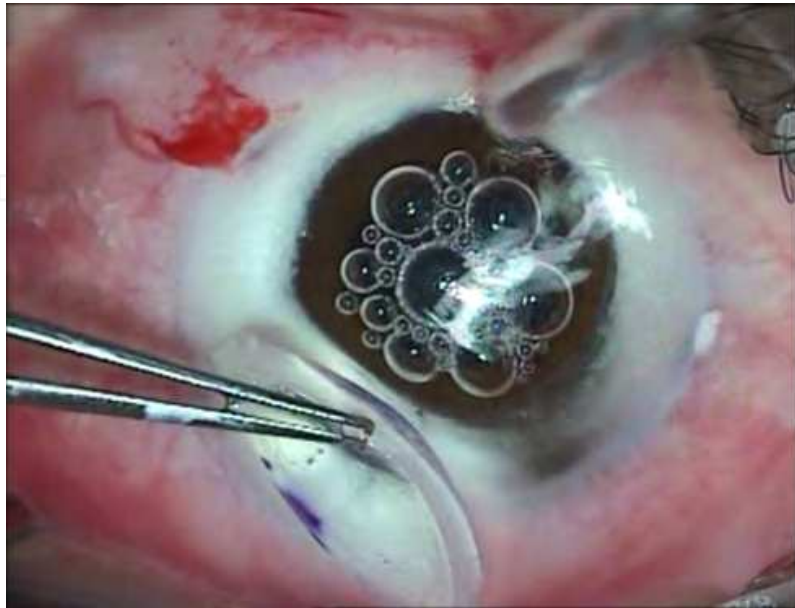


Fig. 17. The exposed surface of the DM is irrigated with free-flowing solution.

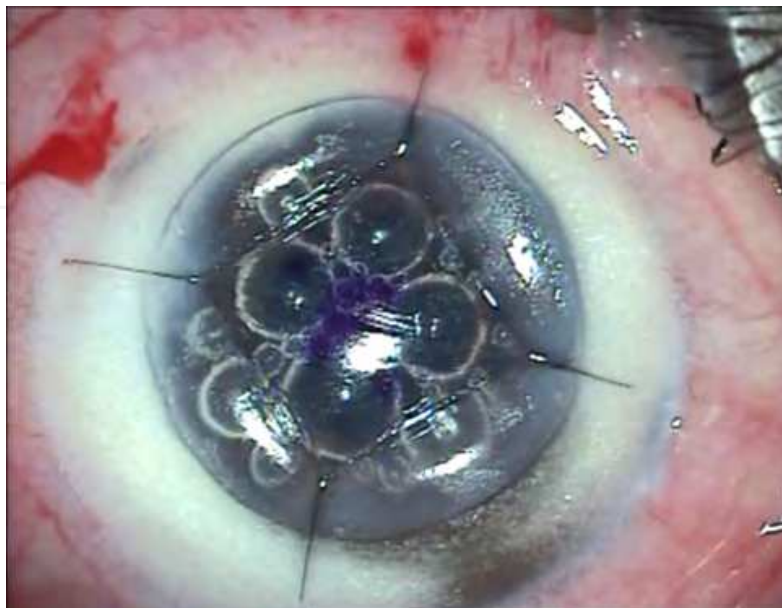


Fig. 18. Cardinal sutures are placed

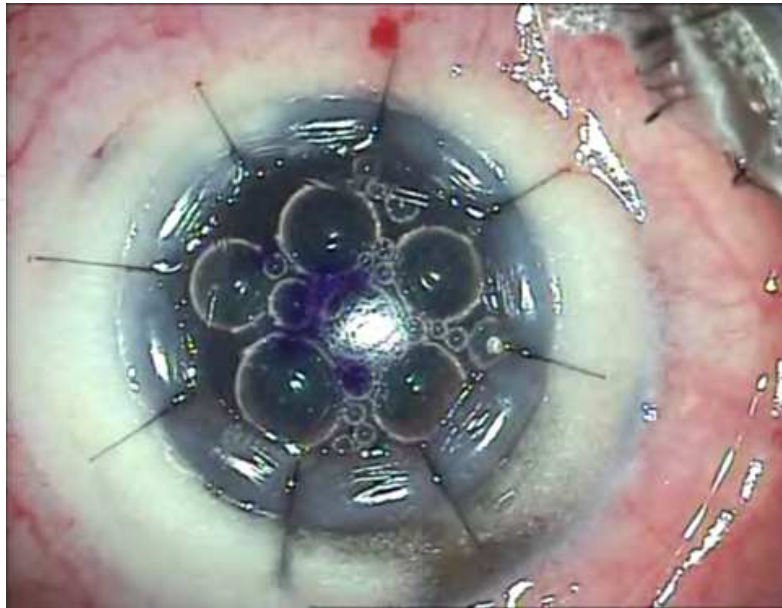


Fig. 19. Eight separate radial sutures are tied and Burried in the donor button.

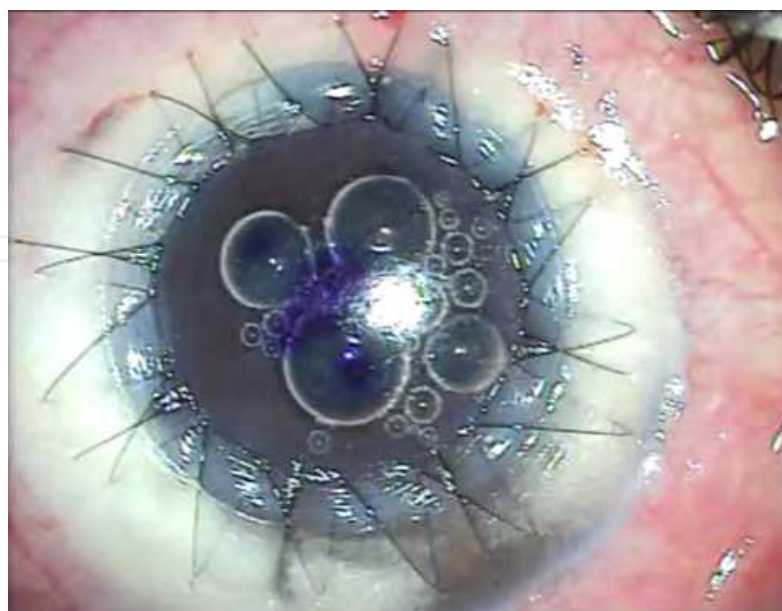


Fig. 20. Suturing the donor button in the recipient bed is completed using combined Interrupted and continuous sutures.

5. Follow-up schedule

The eye is examined on the first postoperative day and after a week. In these visits special attention is focused on the corneal epithelium. Usually a bandage soft lens and nonpreserved lubricant drops are used to improve reepithelialization of the cornea. Topical steroids and antibiotics are started on the first postoperative day. Topical antibiotics are discontinued after the epithelium heals completely. Topical steroids are tapered off over a 4-month period. The patient visits at monthly intervals for 4 months. During this period, every loose suture must be removed and replaced by a new suture. Adjustment of the tension of the continuous sutures can be performed during this period. After the fourth month the patient is examined every 2 months. At the 6-month postoperative visit and beyond the corneal sutures are selectively removed to improve visual function. I routinely remove sutures with the guide of retinoscopy alone and rarely a topographic corneal image is needed to determine the suture that requires removal. I remove the continuous suture if the spherical equivalent is over +3 and remove radial sutures along the steepest corneal meridian (the most “with movement” of the light reflex intercept while performing retinoscopy).

6. Complications

6.1 Perforation of the DM

Perforation of the DM can occur during trephination. In this instance the wound must be sutured and the operation is better postponed to a time after the wound has healed for planned pre-Descemet level DALK.

Perforation can also occur after penetration by the tip of the needle for air injection, in which case air immediately enters the anterior chamber. No attempt to expose the bare DM should be made. However, a pre-Descemet DALK could be performed in these cases.

When the large-bubble or expanding-bubble technique is used, perforation of the DM may occur after the DM–stroma interface is overfilled. A horizontal radial tear appears at the center of the DM along the 3-to-9 o'clock meridian. It is wise to convert these surgeries to penetrating keratoplasty because trying to oppose the DM to the posterior surface of the donor cornea using gas tamponade is difficult. Even if this procedure is successfully performed, it is associated with opacification and scar formation over an elliptical area (fish-mouth shape) in the posterior corneal surface that is devoid of DM. The opacification has adverse visual effects because it is centrally located.

Perforation of the DM can occur during lamellar dissection and tissue removal. In these cases a pre-Descemet DALK can be performed. The perforation site must be left until the end of tissue removal and a small amount of stromal tissue must be left over the perforation site to seal the perforation.

If an instrument touches the bare DM, perforation is possible. In most of these cases the procedure can be continued by thoroughly washing any retained viscoelastic material, suturing the donor tissue in place, and using air for intracameral injection to seal the perforation. Because the dome-shaped contour of the cornea is reduced, especially with tight sutures, the air bubble in the anterior chamber will apply noticeable pressure over the pupil to induce papillary block. Performing a peripheral iridotomy via a paracentesis is necessary and infusion of a hyperosmotic solution such as 20% mannitol is necessary to induce vitreous shrinkage if not contraindicated according to the patient's general status.

A small peripheral iridotomy will not guarantee that the patient will not experience a relative papillary block if the air bubble is so large or if expanding gas such as SF₆ or C₃F₈ is used.

6.2 Double anterior chamber

Double anterior chamber occurs when a perforation is present in the recipient's bed. If the amount of fluid in the interface is minimal, the condition can be managed by observation alone. If not, the intracameral injection of air or gas (SF₆ or C₃F₈) and the drainage of the interface fluid can manage the condition. Great care must be taken to not inject air over the DM in the interface. Every effort must be made to prevent papillary block.

6.3 Foreign particles within the interface

Foreign particles in the interface can be left in place without any attempt to remove them if there has been no associated inflammation and edema and they have been out of the optical zone of the cornea (Figure 21).

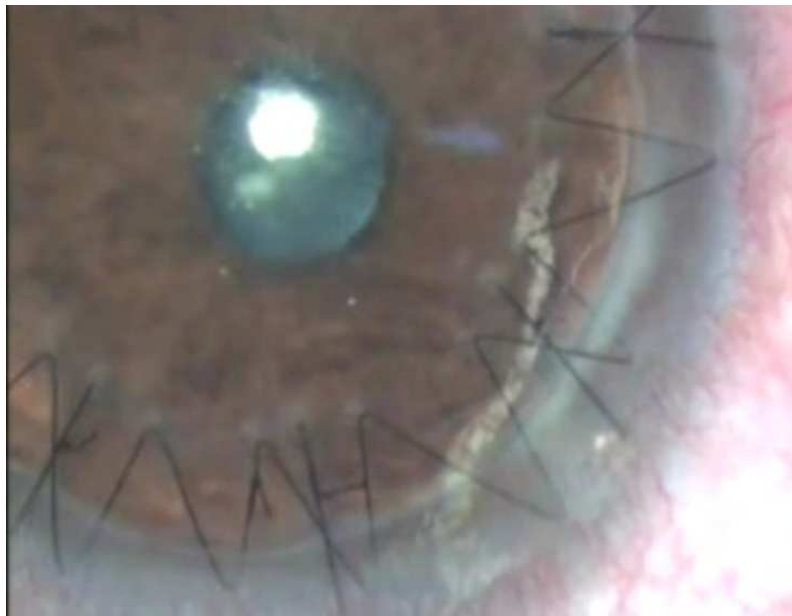

Fig. 21. One piece of sponge entrapped in the donor_ host interface.

Small filaments in the interface do not affect the visual acuity even if they are located within the optical zone.

6.4 Hemorrhage in the interface

A noticeable amount of bleeding in the interface due to preexisting corneal vascularization should be managed by washing and cleaning the interface because residual blood in the interface may result in interface opacity.

6.5 Hyphema

Because the paracentesis is made in a semivertical direction to not violate the DM, introducing an instrument into the anterior chamber can cause injury to the iris tissue and hyphema (Figure 22).

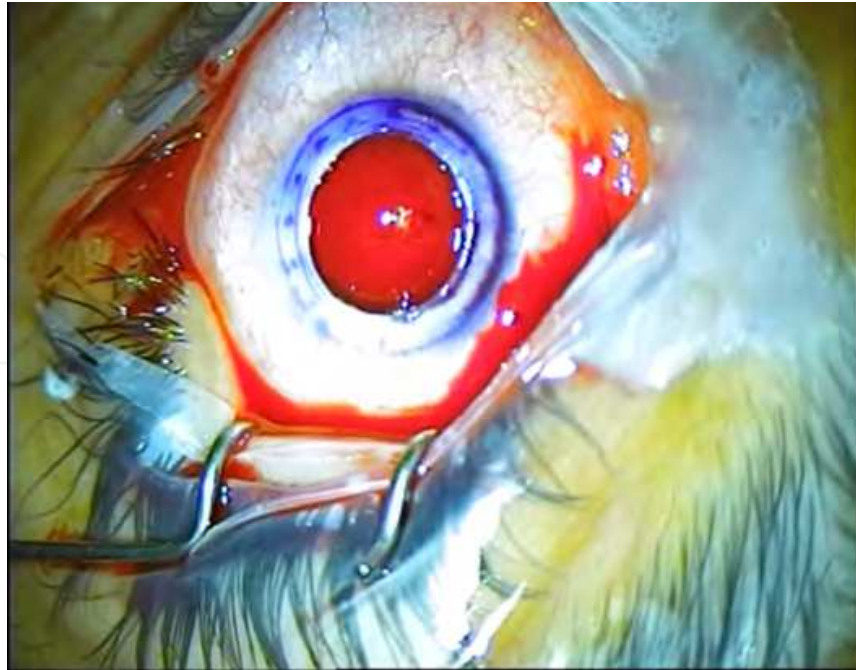


Fig. 22. Introducing surgical devices into the anterior chamber may be accompanied with hyphema.

Management includes gentle washing of the anterior chamber for floating red blood cells after cardinal sutures are placed using a blunt-tipped cannula and irrigating the BSS through the paracentesis wound and depressing the posterior lip of the wound to drain the blood. Introducing any instrument into the anterior chamber may violate the peripheral DM and turn the condition into a major complication.

6.6 Corneal intrastromal cyst

This rare condition results from proliferation of the epithelial cells in the interface. Management includes removing donor tissue, scrapping and irrigating the recipient's bed, and performing a new graft.

6.7 Infectious keratitis

Peripheral wound infection is accompanied by edema, infiltration, loosening of sutures, and occasionally melting of the cornea. The loose sutures must be removed and placed in culture media along with suitable specimens for recognition of the etiologic organism. The treatment is similar to that for an infectious corneal ulcer. Fungal elements may cause deep ulcers without surface involvement. However, involvement of the donor–recipient interface with an infectious process requires donor tissue removal, vigorous treatment of the recipient's bed, and a new graft (Thomas & Purnell, 1965).

6.8 Allograft stromal and epithelial rejection

Stromal allograft rejection may occur after successful DALK surgeries and can be accompanied by segmental corneal edema and thickening and corneal stromal vascularization (Figure 23).

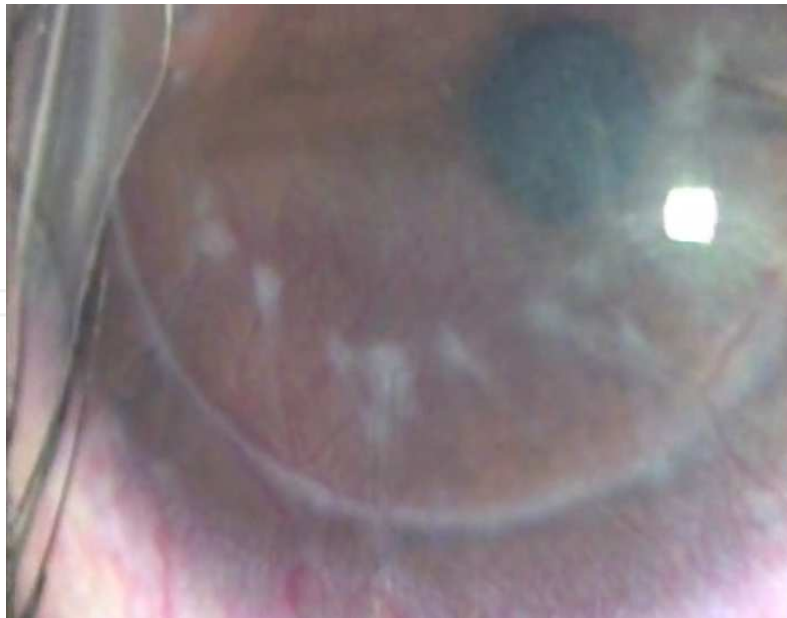

Fig. 23. Allograft corneal stromal rejection associated with vascularization and segmental corneal edema.

Epithelial allograft rejection is clinically less problematic than other types of allograft rejections. However, management includes aggressive steroid therapy to control and reverse the process. Segmental thickening of the cornea may take a long time to resolve after quiescence of the rejection process. Rarely, graft failure that requires regrafting occurs.

6.9 Persistent epithelial defect

Great attention should be focused on the tear condition, ocular surface, and lids before a patient is scheduled for corneal transplantation. Optimization of the ocular surface by lid care, lid surgery, and fornix reconstruction before attempting a corneal graft prevents delayed epithelial healing in special cases. However, management of persistent epithelial defects includes frequent nonpreserved lubricants, reduction or cessation of application of any preserved eye drop, and bandage soft contact lens. Care must be taken to recognize herpetic corneal ulceration and to treat it appropriately. In special resistant cases tarsorrhaphy and punctal occlusion of inferior or both puncta works well. Application of the autologous serum augments the epithelialization of the cornea. Rare unresponsive cases may lead to stromal opacification or vascularization and require regrafting.

7. Conclusion

DALK has several advantages over penetrating keratoplasty for patients with functional endothelium and a normal DM. However, many challenges tend to deter corneal surgeons from performing the procedure routinely as indicated. The advent of surgical techniques introduced by experts in corneal surgery in recent years have led to increases in DALK surgery in corneal surgical centers throughout the world. These techniques have reduced complications and the time and complexity of the procedures and increased their safety, repeatability, and efficiency. Reviewing the surgical techniques will increase our expertise in corneal surgery if we take every specific surgical “pearl” from the techniques described by

experts. The expanding-bubble modification of the big-bubble technique is the one I consider most useful for routinely performing DALK surgery. I hope it will assist corneal surgeons in providing better visual results for their patients.

8. Acknowledgment

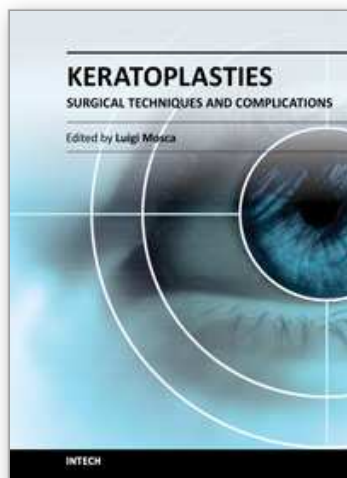
I appreciate and thank Arash Daneshgar for his technical support.

9. References

- Anwar, M., & Teichmann, K.D. (2002). Deep lamellar keratoplasty. Surgical techniques for anterior lamellar keratoplasty with and without barring of Descemet's membrane. *Cornea*, 21, 374-380.
- Anwar, M., & Teichmann, K.D. (2002). Big-bubble technique to bare Descemet's membrane in anterior lamellar keratoplasty. *J Cataract Refract Surg*, 28, 398-403.
- Arenas, A.E. (1984/1985). Deep lamellar keratoplasty dissection of host tissue with intrastromal air injection. *Cornea*, 3, 21-28.
- Balestrazzi, E., Balestrazzi, A.N., Mosca, L., & Balestrazzi, A. (2002). Deep lamellar keratoplasty with trypan blue intrastromal staining. *J Cataract Refractive Surg*, 28, 929-931.
- Behrooz, M.J., & Daneshgar, F. (2010) "Large-bubble" modification of the "big-bubble" technique for performing maximum depth anterior lamellar keratoplasty. *Cornea*, 29, 820-824.
- Castroviejo, R. (1932). Keratoplasty. A historical and an experimental study, including a new method. Part 1. *Am J Ophthalmol*, 15, 825-838.
- Daneshgar, F., & Fallahtafi, M.R. (2011). Expanding-bubble modification of the big-bubble technique for performing maximum depth anterior lamellar keratoplasty. *Eye*, 25(6), 803-8.
- Hallermann, W. (1963). On the technic of lamellar keratoplasty. *Klin Monatsbl Augenheilkd*, 142, 243-250.
- John, T. (2004). Use of indocyanine green (ICG) and forced hydrodissection in total anterior lamellar keratoplasty (TALK). Presented at the 22nd Congress of the ESCRS, Paris, France, September 18-22, 2004.
- John, T. (2006). Indocyanine green and forced hydrodissection in total anterior lamellar keratoplasty, In: *Surgical Techniques in Anterior and Posterior Lamellar Corneal Surgery*, John T., (pp. 150-164), Jaypee Brothers Medical Publishers, 81-8061-605-3, New Dehli.
- Malbran, E. (1966). Lamellar keratoplasty in keratoconus. *Int Ophthalmol Clin*, 6, 99-109.
- Manche, E.E., Holland, G.N., & Maloney, R.K. (1999). Deep lamellar keratoplasty using viscoelastic dissection. *Arch Ophthalmol*, 117, 1561-1565.
- Melles, G.R., Lander, F., Rietveld, F.J., Remeijer, L., Beekhuis, W.H., & Binder, P.S. (1999). A new surgical technique for deep stromal, anterior lamellar keratoplasty. *Br J Ophthalmol*, 83, 327-333.
- Melles, G.R.J., Remeijer, L., Geerards, A.J.M., & Beekhuis, W.H. (2000). A quick surgical technique for deep, anterior lamellar keratoplasty using visco-dissection. *Cornea*, 19, 427-432.

- Morrison, J.C., & Swan, K.C. (1982). Full-thickness lamellar keratoplasty. A histopathologic study in human eyes. *Ophthalmology*, 89, 715-719.
- Muhlbauer, F.X. (1842). Transplantation der cornea (Gekronte preisschrift, jas. Lindauer, Munich 1840). In: Schmidt CC, ed. Jahrbucher der in- und auslandischen gesammten medicin. Leipzig: Otto Weigand, 1842.
- Reisinger, F. (1824). Die Keratoplastik Ein Versuch Zur Eiweiterung der Angenheilkunst. *Bayerische Annalen*, 1, 207-215.
- Sugita, J., & Kondo, J. (1997). Deep lamellar keratoplasty with complete removal of pathological stroma for vision improvement. *Br J Ophthalmol*, 81, 184-188.
- Thomas, C.L., & Purnell, E.W. (1965). Prevention and management of early and late complications of keratoplasty (penetrating and lamellar) an analysis of 120 consecutive cases. *Am J Ophthalmol*, 60, 385-405.
- Von Hippel, A. (1888), *Albrecht V Graefes Arch Ophthalmol* 34, 108.
- Zirm, E. (1906). Eine erfolgreiche totale keratoplastic. *Albrecht V. Graefes Arch Ophthalmol*, 64, 580.

IntechOpen



Keratoplasties - Surgical techniques and complications

Edited by Dr. Luigi Mosca

ISBN 978-953-307-809-0

Hard cover, 134 pages

Publisher InTech

Published online 18, January, 2012

Published in print edition January, 2012

In this book, the authors illustrate different therapeutic and surgical approaches to treating various corneal pathologies. This edition in electronic format allows universal access to everybody regardless of the time of day or setting, portability, and speed of information access. Such features show more feasibility for all readers and reduce the time necessary for research. This book will be a good tool for students as well as specialists working in the field of corneal transplantation, to improve their knowledge of treatment of corneal disease.

How to reference

In order to correctly reference this scholarly work, feel free to copy and paste the following:

Farid Daneshgar (2012). Manual Deep Anterior Lamellar Keratoplasty, Keratoplasties - Surgical techniques and complications, Dr. Luigi Mosca (Ed.), ISBN: 978-953-307-809-0, InTech, Available from:
<http://www.intechopen.com/books/keratoplasties-surgical-techniques-and-complications/manual-deep-anterior-lamellar-keratoplasty>

INTECH
open science | open minds

InTech Europe

University Campus STeP Ri
Slavka Krautzeka 83/A
51000 Rijeka, Croatia
Phone: +385 (51) 770 447
Fax: +385 (51) 686 166
www.intechopen.com

InTech China

Unit 405, Office Block, Hotel Equatorial Shanghai
No.65, Yan An Road (West), Shanghai, 200040, China
中国上海市延安西路65号上海国际贵都大饭店办公楼405单元
Phone: +86-21-62489820
Fax: +86-21-62489821

© 2012 The Author(s). Licensee IntechOpen. This is an open access article distributed under the terms of the [Creative Commons Attribution 3.0 License](https://creativecommons.org/licenses/by/3.0/), which permits unrestricted use, distribution, and reproduction in any medium, provided the original work is properly cited.

IntechOpen

IntechOpen