

We are IntechOpen, the world's leading publisher of Open Access books Built by scientists, for scientists

6,900

Open access books available

186,000

International authors and editors

200M

Downloads

Our authors are among the

154

Countries delivered to

TOP 1%

most cited scientists

12.2%

Contributors from top 500 universities



WEB OF SCIENCE™

Selection of our books indexed in the Book Citation Index
in Web of Science™ Core Collection (BKCI)

Interested in publishing with us?
Contact book.department@intechopen.com

Numbers displayed above are based on latest data collected.
For more information visit www.intechopen.com



Laparoscopic Appendicectomy

IntechOpen

Maheswaran Pitchaimuthu
*SpR in General/HPB Surgery,
 Department of Surgery, Queens Medical Centre,
 Nottingham University Hospitals NHS Trust, Nottingham,
 UK*

1. Introduction

Appendicitis is the most common surgical emergency, with the greatest incidence in the 2nd decade of life. It is 40% more common in males than females [1]. The clinical presentation, investigations and management options are discussed elsewhere in this text book. The laparoscopic or keyhole approach has become widespread where facilities are available. Kurt Semm from Switzerland performed the first laparoscopic appendicectomy in 1980 [2]. However, it was not widely practiced until the success of elective laparoscopic cholecystectomy was well established. Improvements in instruments, video equipment and training have made this a routine approach for the emergency appendicectomy.

2. Advantages

There are benefits for laparoscopy when the diagnosis of appendicitis is in doubt especially in young women when other diagnoses are relatively common. There is evidence for reduced wound infection rates, less postoperative pain and earlier return to normal activities. It may also reduce postoperative adhesion formation and it provides better cosmesis.

3. Patient selection

Most patients with suspected appendicitis can undergo a laparoscopic appendicectomy. It is particularly also useful in obese patients in whom it avoids a large wound. However, laparoscopic appendicectomy is generally avoided in patients with major cardio-respiratory problems. In patients who have had previous lower abdominal surgery, it may be difficult to visualize the appendix due to adhesions. Some consider that laparoscopic appendicectomy is contraindicated in patients who are septic and have generalized peritonitis, where laparotomy may be preferable. In advanced pregnancy laparoscopic appendicectomy may be difficult due to the gravid uterus which interferes with adequate visualization and instrumentation [3]

4. Preoperative assessment and preparation

The preoperative assessment and preparation for laparoscopic appendicectomy is similar to any surgical procedure. Patients are assessed for fitness for general anesthesia and coagulation

is corrected if necessary prior to surgery. When obtaining consent, it is important to explain the procedure to the patient, especially the possibility of open conversion. Patients should also be informed about potential complications including bleeding, wound infection, intra abdominal collections, appendicular stump leak and faecal fistula.

All patients should be kept fasting at least 6 hrs prior to the procedure and should be given intravenous fluids to avoid dehydration. Antibiotics should be given preoperatively especially in those who show signs of sepsis (spiking temperature, high white cell count and CRP).

5. Procedure

5.1 Position

After general anesthesia with muscle relaxation, the patient is placed in the supine position with the left arm by the side. This is very important to allow sufficient space for the surgeon and the assistant who stand on the left side of the patient. The position of the surgeon and the assistant differs depending upon the port sites. Some surgeons prefer the lithotomy position, especially in women to allow access to the perineum, so that a cervical manipulator can be used to get a better visualization of the pelvic organs [4]. The monitor is on the right side of the patient. The bladder is catheterized to get a better view of the pelvis and to avoid bladder injury during suprapubic port insertion. The catheter can be removed at the end of the procedure.

5.2 Recommended Instruments

1. 5 -12mm trocar (camera port)
2. Two 5mm trocars or one 5mm and one 10mm trocar with reducer
3. Two atraumatic bowel grasping forceps
4. One dissecting curved forceps
5. One curved scissors
6. One hook
7. Bipolar / Monopolar diathermy
8. Endoloop x 3 (Ethicon Endoloop® Ligature PDS II/Vicryl Suture)
9. Clip applicator with clips if necessary
10. Vascular and intestine stapler if necessary
11. Retrieval bag if necessary
12. Drain if necessary

5.3 Ports

Usually 3 ports are required to perform a laparoscopic appendicectomy. The first trocar is introduced through an infra or supra umbilical incision by using either a Veress needle or through an open technique. Once the umbilical port is inserted a pneumoperitoneum is created and the intraperitoneal pressure is set at 12 mmHg with a maximum of 14mmHg being accepted in adults. In children the maximum pressure is lower at around 8 -10 mmHg [5]. A 0 or 30 degree telescope is inserted and other ports are inserted under vision. If there is fogging of the telescope lens an anti fogging solution is used. The other two port positions are placed depending upon surgeon's preference. The author's standard practice is to have a left iliac fossa and a supra pubic working port [Fig. 1], where the assistant stands on the surgeon's right.

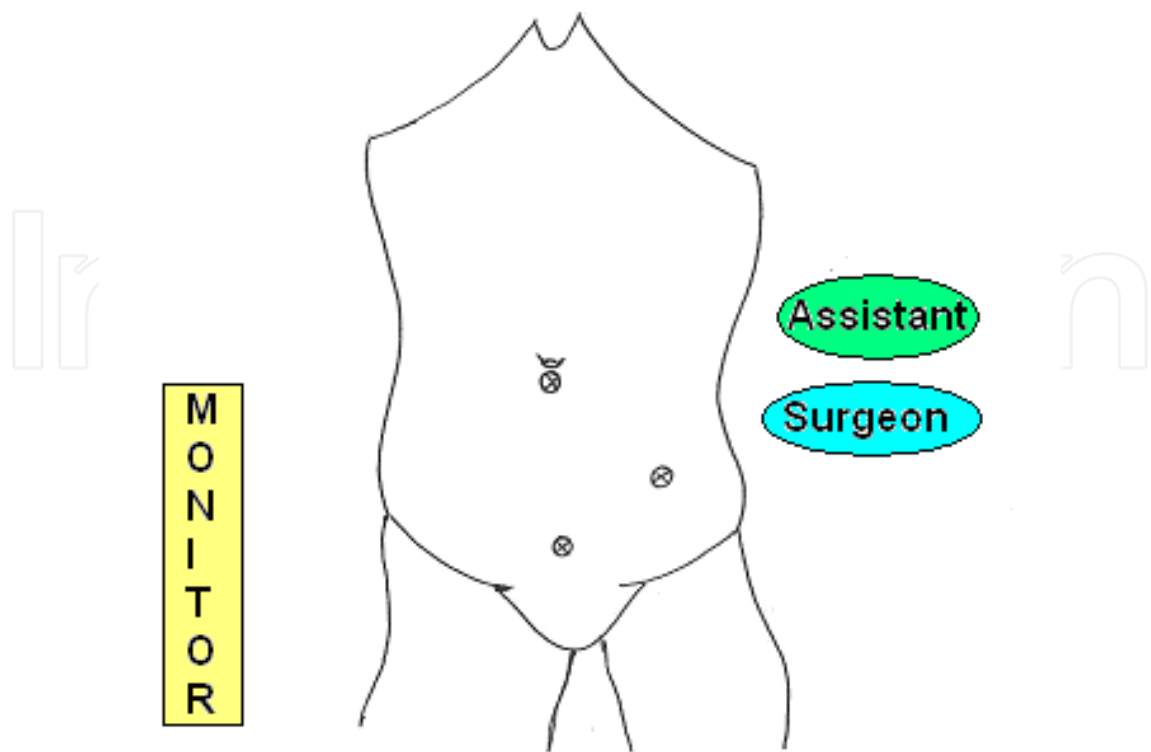


Fig. 1. Port positions for laparoscopic appendicectomy
Other port positions include,

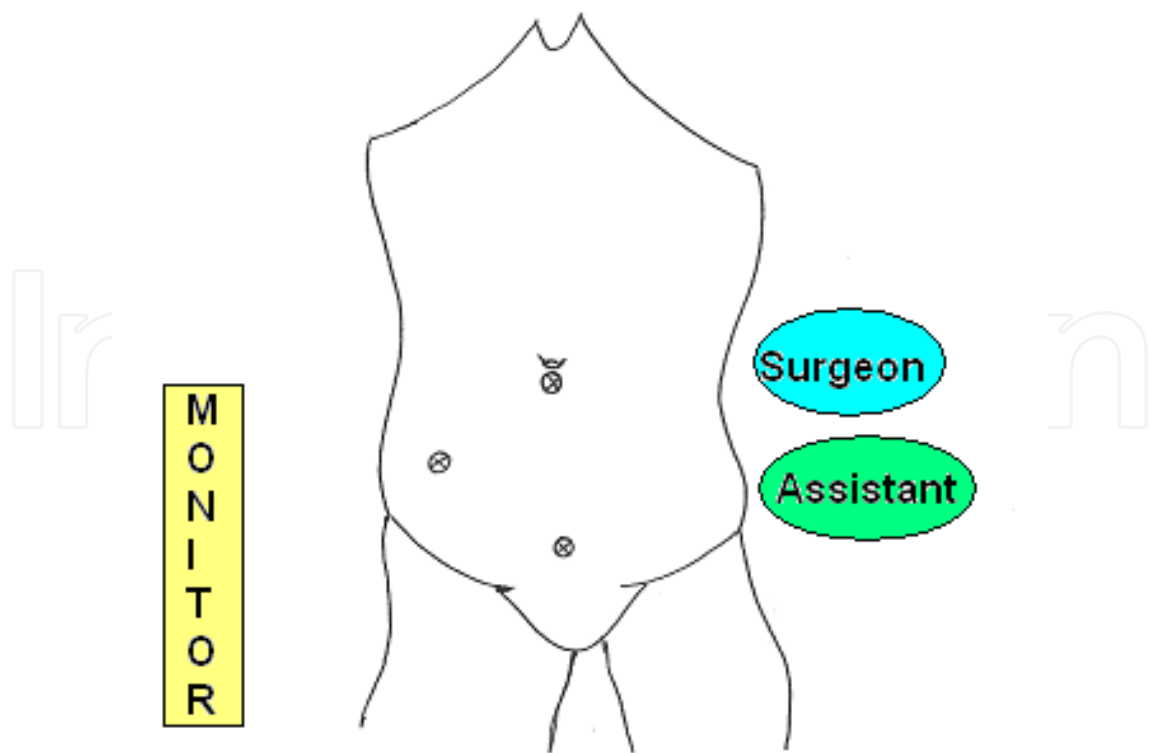


Fig. 2. a) Umbilical, suprapubic and right iliac (assistant on surgeon's left)

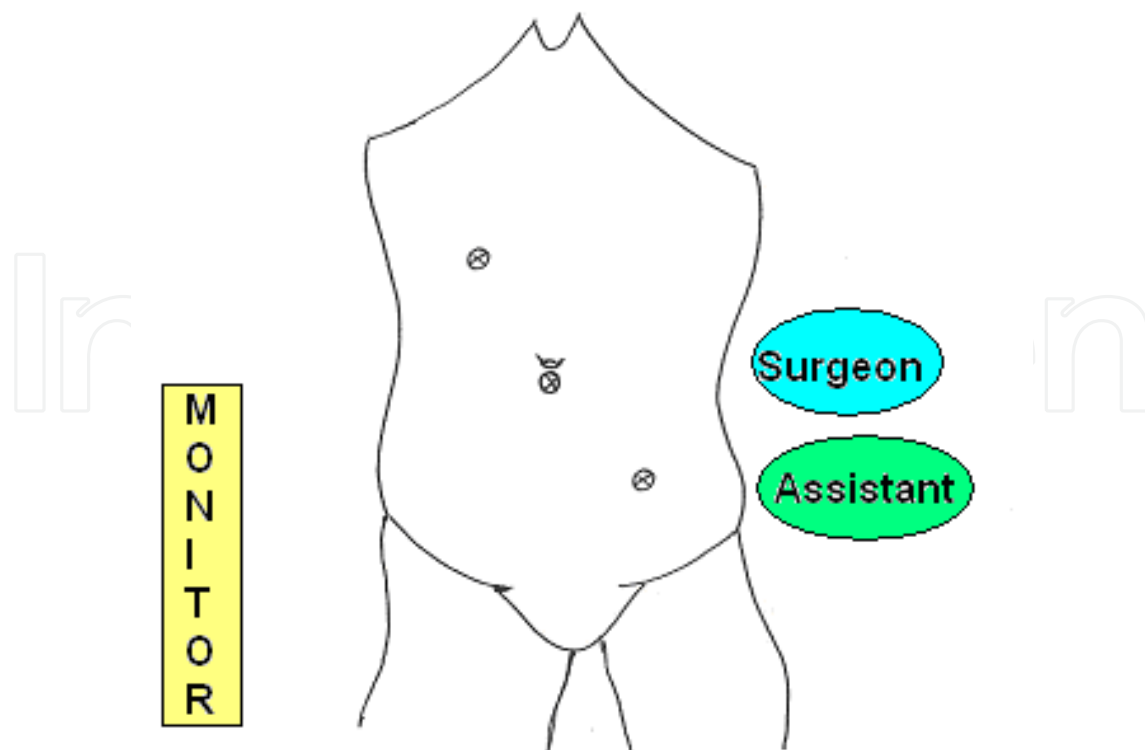


Fig. 2. b) Umbilical, left iliac and right hypochondrium (assistant on surgeon's left)

5.4 Diagnostic laparoscopy

Once the telescope is inserted, a general laparoscopy of the entire abdomen is performed to rule out any other intra abdominal pathology and to assess the degree of peritonitis from the spread of purulent peritoneal fluid. Then the patient is placed in the trendelenburg position to visualize the pelvic organs, especially in women to rule out gynecological pathology. Then the patient is tilted with the right side up to get a view of the caecum and appendix. If the appendix is inflamed the appendicectomy is performed as detailed below.

5.5 Management of the macroscopically normal appendix

If the appendix is macroscopically normal [Fig. 3], then a careful search should be made for other pathology such as caecal diverticulitis, terminal ileitis, terminal ileal Crohn's disease, Meckel's diverticulitis. In females, pelvic inflammatory disease, salpingitis, ovarian cyst rupture or torsion, tubo ovarian abscess, and endometriosis should be looked for. If any of the above pathology is encountered, then the operation should be modified according to the unexpected findings.

If every thing is normal, the author's preference is to take the normal appendix out. The reasons as follows a) 75% of patients get improvement in their pain symptoms [6] b) There may be a pathological inflammation, even if the appendix is grossly normal [7] c) adequate inspection of the appendix needs mobilization, which may cause trauma to the appendix and mesoappendix, where it is not advisable to leave the appendix d) In one study patients who only had diagnostic laparoscopy without removal of appendix, presented later with recurrent abdominal pain [8] e) Performing laparoscopic appendicectomy for a normal appendix is simple and quick [9] f) to avoid future appendicitis.

Some surgeons prefer to leave the normal appendix to avoid the complications related to the procedure.

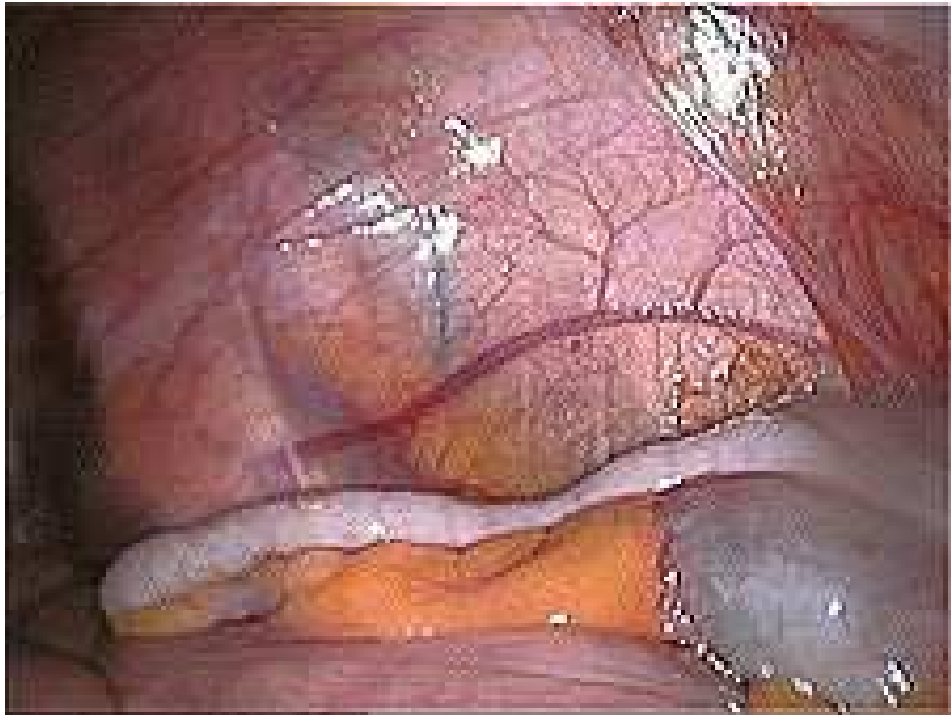


Fig. 3. Normal looking appendix on laparoscopy

5.6 Dissection of the appendix

Once the diagnosis of appendicitis is confirmed [Fig. 4], the tip of the appendix is grasped with atraumatic bowel grasping forceps inserted through the lower port and the appendix is lifted towards the anterior abdominal wall with the surgeon's left hand. Then a curved dissecting forceps is inserted through the upper port to start the dissection. If the tip is not visualized due to omental adhesions, which is usually the case, the adhesions are gently teased away from the appendix. Then a relatively healthy, non necrotic part of the appendix is grasped with left hand and the dissection continues towards the base.

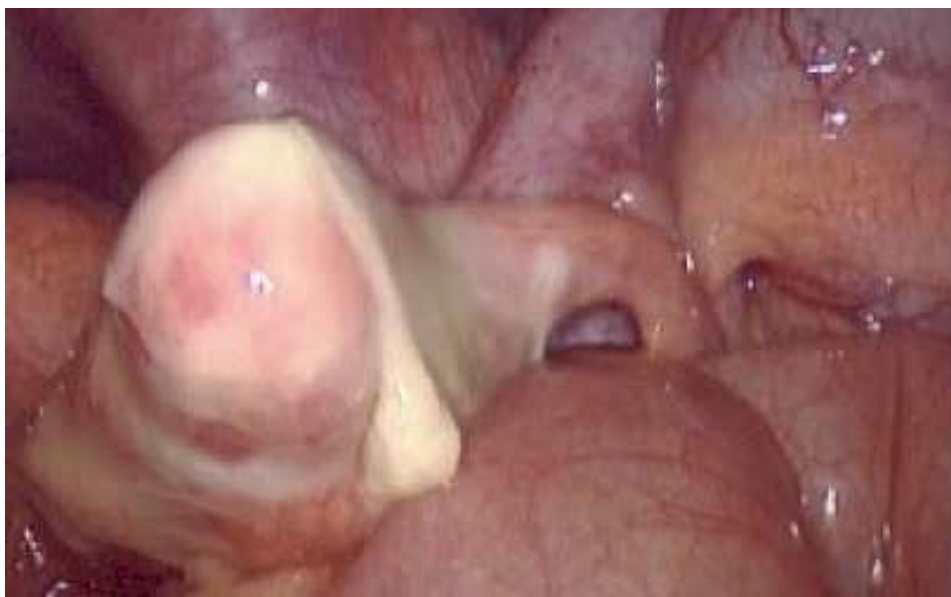

Fig. 4. Inflamed appendix on laparoscopy

If the tip is not visualized due to an unusual position [Fig. 5], then the base should be identified, which is usually 2cm lateral and inferior to ileo-caecal junction. If the base is correctly identified then there are 2 options. 1) grasp the base and dissect towards the tip without dividing it. 2) Divide the base between two ligations (intra or extra corporeal sutures), within 5mm of the attachment to the caecum and then continue the dissection of the appendix and the mesoappendix towards the tip.

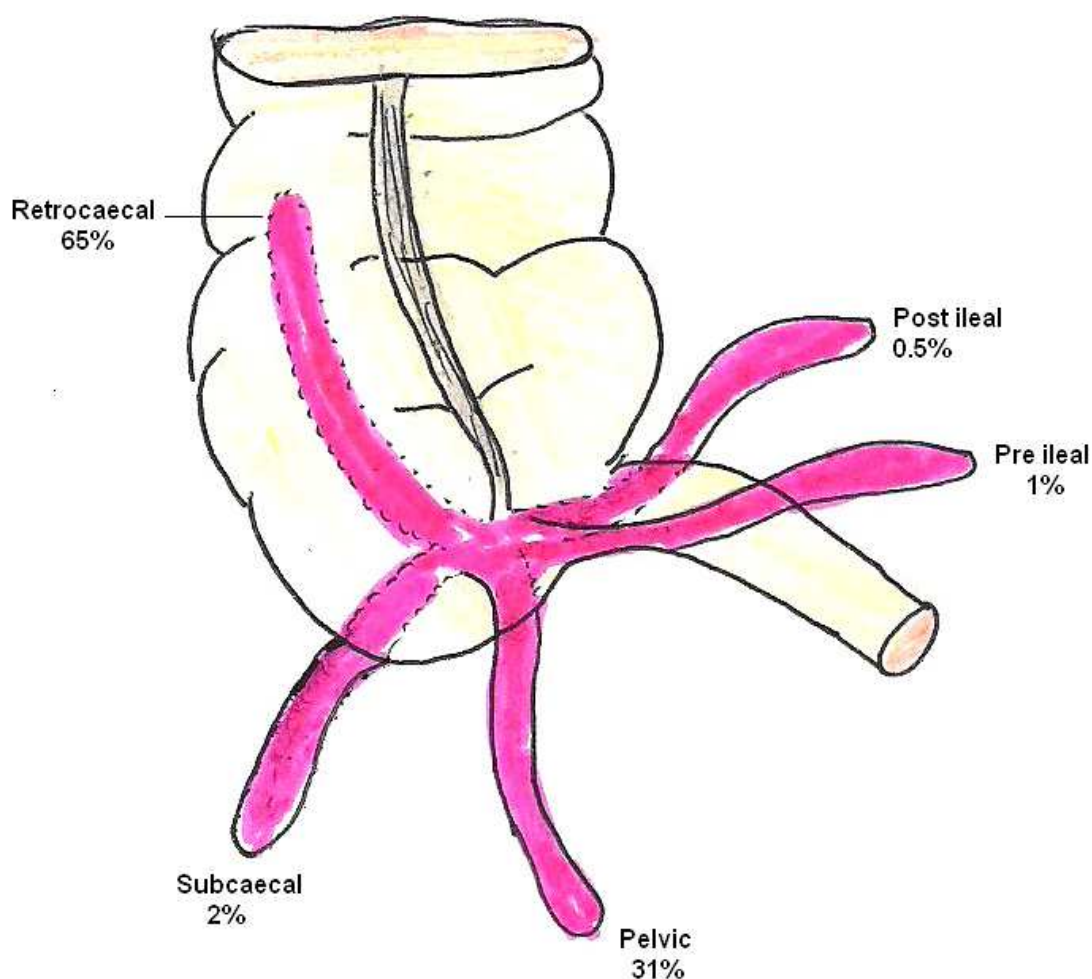


Fig. 5. Different positions of the appendix

If there is an appendicular mass or abscess, gentle dissection should be carried out to visualize the anatomical structures appropriately and there should be a low threshold to convert to an open procedure as prolong dissection carries the risk of causing more damage.

5.7 Division of the mesoappendix and appendix

The options to divide the mesoappendix and appendix are as follows:

- Diathermy dissection of the mesoappendix and ligation of the appendix
- Ligation of both appendix and mesoappendix
- Clip application for the appendicular artery and ligation of the appendix
- Stapled division of both structures

5.7.1 Diathermy dissection of the meso appendix and ligation of the appendix

Bipolar diathermy is safely used to divide the meso appendix, as it has minimal lateral spread of energy, thus avoid tissue damage. Monopolar diathermy can also be safely used with short burst of energy rather than using it for prolonged periods. The dissection is started at the middle part of free edge of meso appendix and directed towards the appendix. Once dissection is close to the appendix the dissection is carried towards the base. The reason for starting in the middle part of meso appendix is, in case the appendicular artery is injured, it can be easily grasped and dealt with. Diathermy causes thrombosis of the appendicular artery and coagulates the surrounding tissue. Once the meso appendix is completely divided then the appendix base is ligated [Fig. 6]. Some surgeons prefer to free the meso appendix from the appendix from the tip to the base using diathermy, where the meso appendix is left intact. The appendix base is ligated twice with an endoloop (Ethicon Endoloop® Ligature PDS II/Vicryl Suture) at the base and a third loop is placed about 1cm from the previous one. The appendix is divided at least 5mm from the ligation at the base side.

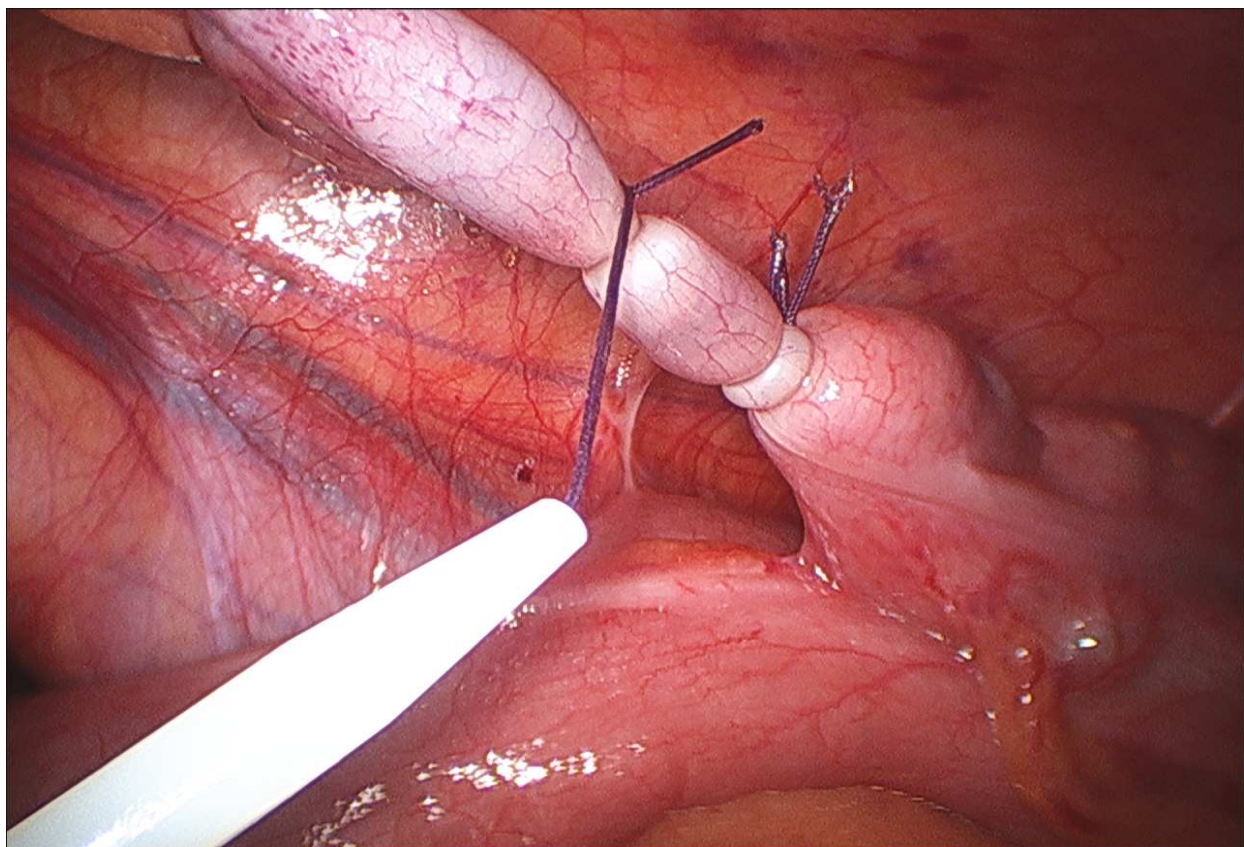


Fig. 6. Ligation of base of the appendix using an endoloop

5.7.2 Ligation of both appendix and meso appendix

Both the appendix and meso appendix can be safely ligated with either intra corporeal or extra corporeal knots. For this a window is created [Fig. 7] in the meso appendix near the base of the appendix using curved dissecting forceps. Then the suture material (2-0 Vicryl or PDS) is passed through the window and the meso appendix and appendix are ligated twice

and divided between the ligatures. The other option is to ligate the mesoappendix as described and ligate the base of the appendix using endoloop

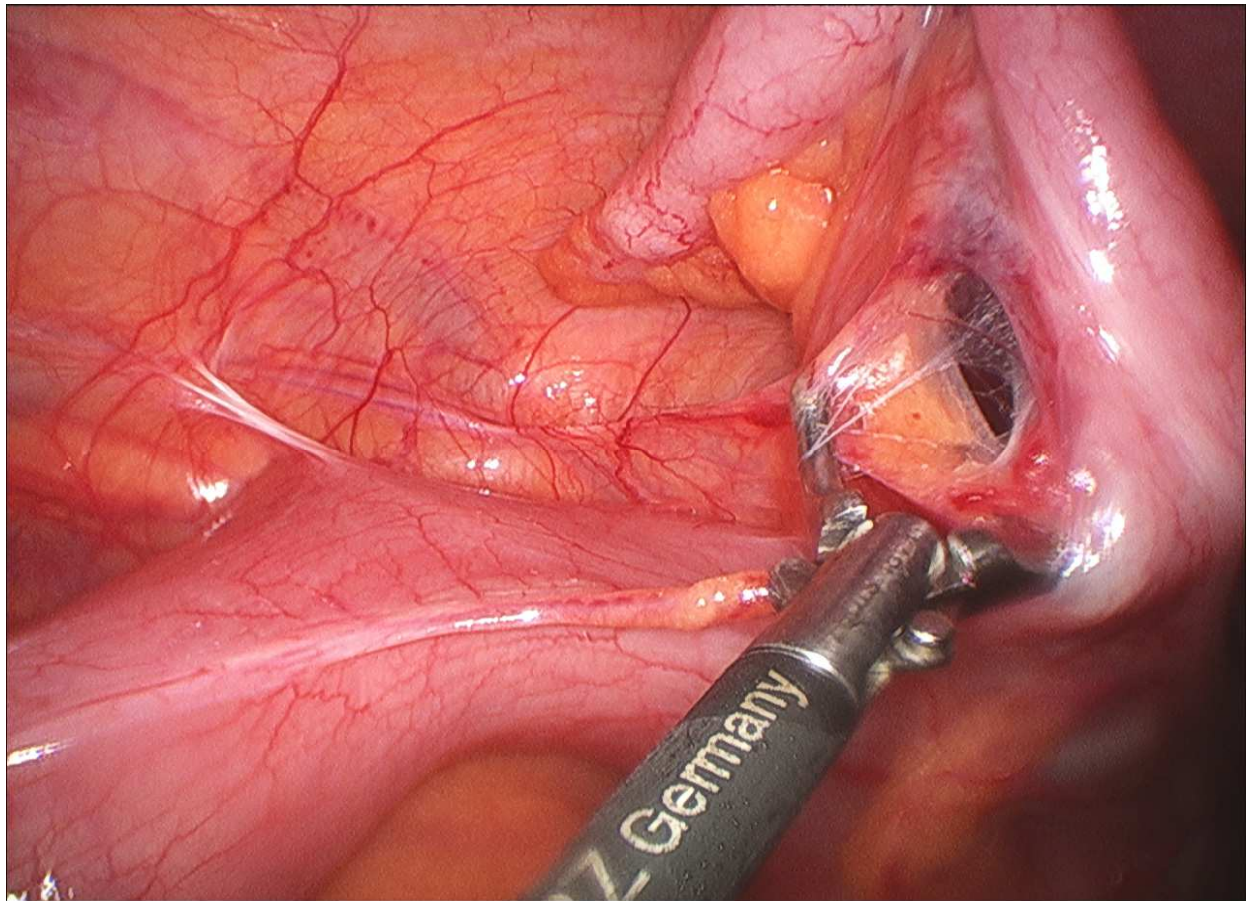


Fig. 7. Creation of window in the mesoappendix near the base

5.7.3 Clip application for appendicular artery and ligation of the appendix

This is possible where the meso appendix is not grossly inflamed and friable. The fat over the meso appendix is gently dissected and the appendicular artery is identified. Then 3 clips are applied to the artery [Fig. 8] (2 towards the base and 1 proximal to these) and the artery is divided between the clips. Then the base of the appendix is ligated as mentioned above.

5.7.4 Stapler division of appendix and meso appendix

The principal advantage of using a stapler device is the ability to divide the appendiceal mesentery and appendix in a single maneuver [Fig. 9], even in the presence of severe inflammation and thickening of meso appendix. The main disadvantage of the stapler includes the cost and the requirement for a larger trocar size. In general a minimally inflamed or an uninflamed appendix only needs ligation with an endoloop, but a stapler can greatly facilitate the surgery in the presence of severe inflammation with a thickened mesoappendix and appendix base. It is also useful, where the base of the appendix is necrotic. In these cases the stapler is applied at the healthy caecal wall.

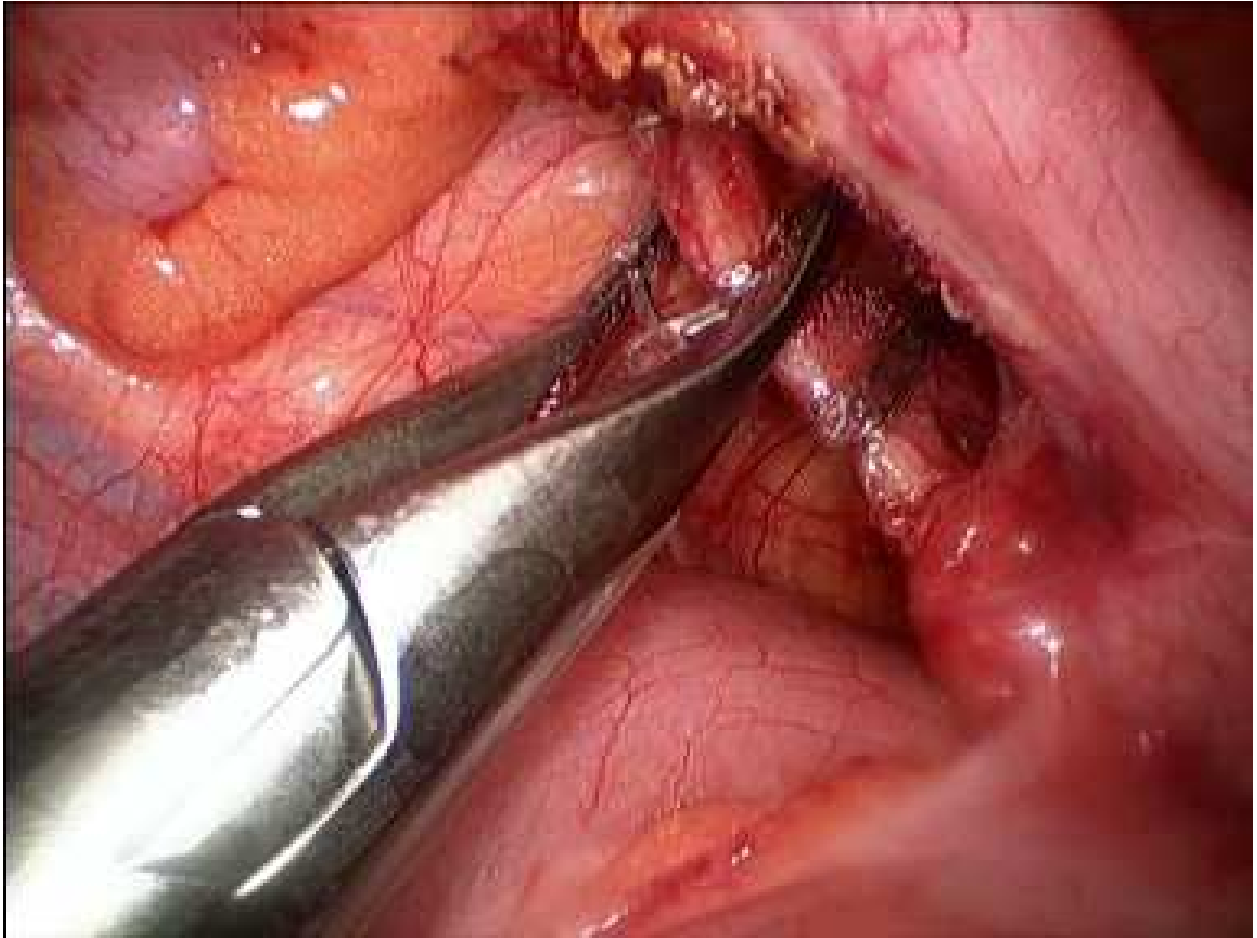


Fig. 8. Application of clip to the appendicular artery

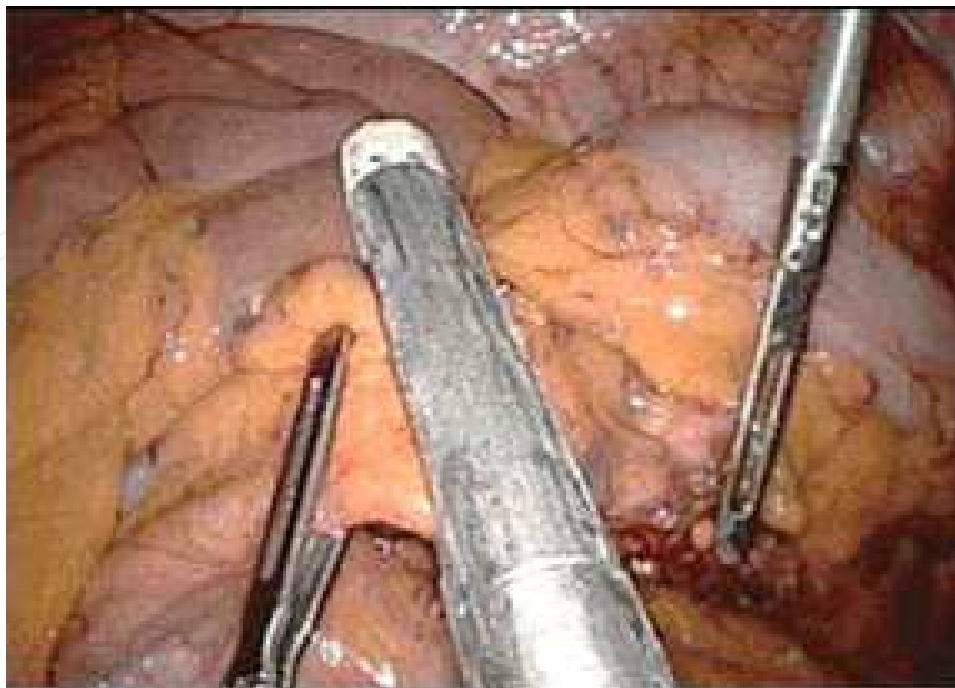


Fig. 9. Stapler division of appendix and mesoappendix

To use the stapler the surgeon will need to use a 5mm telescope, so that the stapler device can be introduced through the larger umbilical port or one of the 5mm existing working ports should be converted to a larger 12mm port. When using a single stapler to divide both appendix and meso appendix, careful inspection of the meso appendix is performed to check hemostasis. The other option is to use a vascular stapler for the meso appendix and an intestinal stapler for the base of the appendix. For this a window is created in the mesoappendix adjacent to the appendicular base and both structures are divided separately using the stapler devices. When the stapling device is used, care should be taken not to include the terminal ileum, right ureter or gonadal vessel in the jaws of the stapling device. Very rarely a harmonic scalpel (Ethicon Endo-Surgery inc.,) or the Ligasure (Ligasure TM, Covidien plc, USA) are used to divide the meso appendix.

5.8 Removal of the appendix

Once the appendix and meso appendix are divided the appendix specimen should be removed. If the appendix is thin and normal or minimally inflamed then it is removed through the umbilical port by feeding the appendix to the umbilical port when the camera is in situ. Then the whole umbilical port is removed along with the specimen.

If the appendix is thick and highly inflamed then either a 5mm telescope is used in the lateral port or one of the 5mm ports is converted to a 10mm port to remove the appendix under vision. If the meso appendix is thick and the appendix is friable, gangrenous and filled with pus, then an endobag (Endobag® retrieval bags, Tyco Healthcare USA) [Fig. 10] or BERT (Synergy Health (UK) Limited) bag is used to remove the appendix to avoid rupture of the specimen in the peritoneal cavity. A BERT bag can be inserted (attached with Vicryl suture with long ends left outside) and removed along with the specimen through the umbilical port if a 5mm telescope is not available and to avoid conversion of a 5mm to 10mm port.

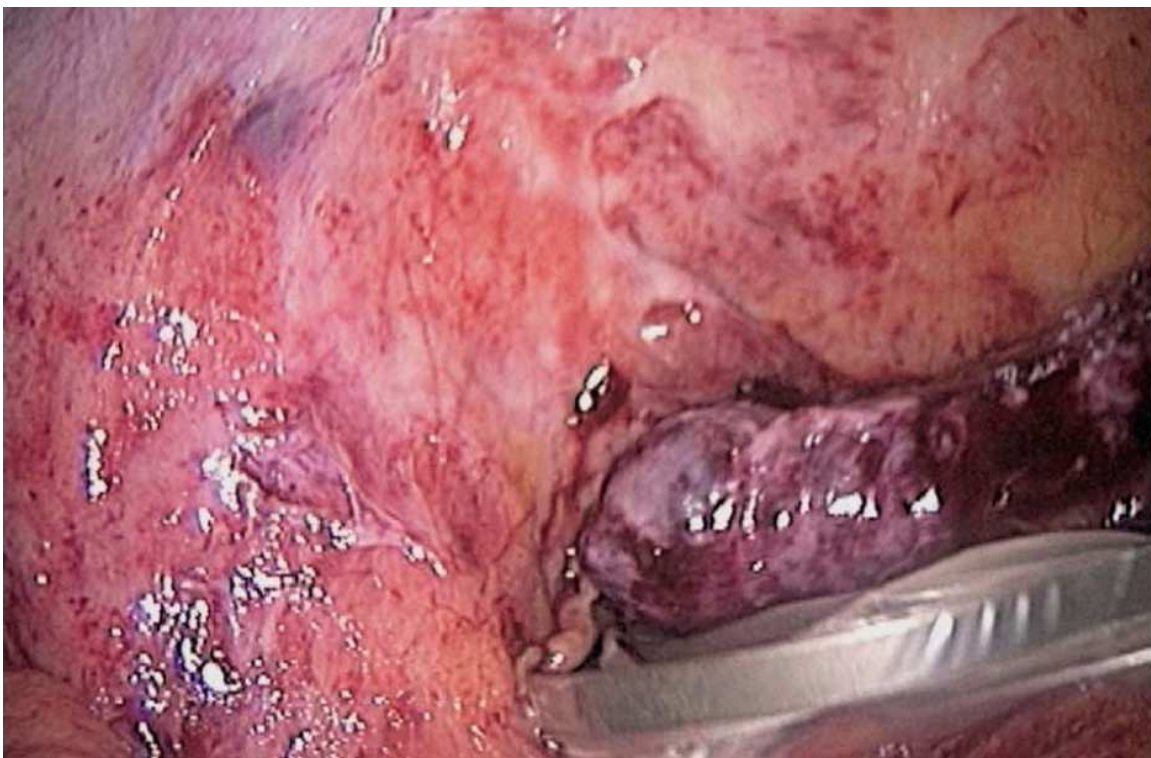

Fig. 10. Removal of appendix using endobag

Care should be taken to avoid the contact between the specimen and the anterior abdominal wall to prevent wound infection. Once the specimen is retrieved the port is reinserted and the pneumoperitoneum is created for a final check.

5.9 Wash and close

Careful inspection should be performed to check for hemostasis and any residual contamination. If there is gross contamination then a local wash should be performed with normal saline. If there is extensive contamination of the peritoneal cavity then all quadrants of the abdomen should be irrigated with copious amount of normal saline until the returned fluid is clear. Once this has been done the patient is placed in the head up position and the fluid gravitating to the pelvis is sucked out. Some surgeons place a drain if there has been gross contamination with perforation of the appendix, though there is no evidence for the benefit of drains.

Ports should be withdrawn under vision; especially the lateral port to make sure that there is no injury to the inferior epigastric artery. The umbilical port is closed with 2-0 vicryl / PDS and the skin is closed with either subcuticular suture or skin glue.

5.10 Postoperative management

Oral fluids and diet can be started when the patient tolerates them. Adequate analgesia with initial parenteral then oral analgesics and thrombo prophylaxis are prescribed. Antibiotics are continued for a few days if there is gross contamination, perforation or gangrenous appendicitis. The drain can be removed, if placed, when the out put is minimal and clear. With early mobilization patients are usually discharged before the 2nd post operative day.

6. Difficult dissection

6.1 Retrocaecal appendix

The retrocaecal appendix comprises about 65% of the normal appendix positions. Performing an appendicectomy for retrocaecal appendicitis may be challenging. In this situation, the caecum and the ascending colon are mobilized, similar to the dissection for a right hemicolectomy. By this maneuver the appendix can be visualized, which then should be gently dissected off from the caecum. Care should be taken to avoid injury to the adjacent retroperitoneal structures i.e right ureter or gonadal vessels. Once the entire appendix is mobilized then the appendicectomy is completed as above. If the surgeon is not experienced in mobilization of the colon or the dissection is found to be difficult, then there should be no hesitation to convert to an open procedure.

6.2 Subhepatic appendix

Sometimes the appendix tip may be in the subhepatic space. If the appendix is mildly inflamed, it may be easy to mobilize it. But in case of gross inflammation, the appendix may be completely stuck in the paracolic position. In these cases it is ideal to find the base by identifying the ileo caecal junction. Then the base can be divided between ligatures and proceed with dissection of the appendix and meso appendix towards the tip. It is also acceptable to proceed without dividing the base. When the dissection reaches the tip, care should be taken to avoid injury to the gall bladder or liver.

6.3 Gangrenous base

Some times the inflammation extends up to the base and the base is found to be necrotic. All precautions should be taken to avoid accidental avulsion of the appendix. The appendix should be removed along with a healthy cap of caecum, by using endo staplers as mentioned earlier. If the stapler is not available then the appendix is removed and intracorporeal suturing with the healthy caecal wall should be applied. If that is not possible then the procedure should be converted to an open operation.

6.4 Appendicular mass

An appendicular mass is formed by adhesions between the appendix, small bowel, caecum and the omentum. In this situation all the adhesions are gently teased away to find the appendix. If it is difficult then the procedure is converted. In elderly patients caecal malignancy should be considered when dealing with a mass in the right iliac fossa.

6.5 Perforated appendix

While most patients are found to have a perforated appendix only after laparoscopic or open exploration, some have preoperative evidence with generalized peritonitis, SIRS or radiological findings [10]. When there is obvious evidence of appendicular perforation, some surgeons prefer to proceed directly to an open procedure, as there is some evidence of an increased risk of a pelvic abscess following a laparoscopic approach [11]. Further, in contrast to patients with simple appendicitis, the recovery period is similar with the open or the laparoscopic method in patients with perforation and generalized peritonitis, because the recovery depends on resolution of the intra abdominal pathology rather than the abdominal incision [12]. However, when perforated appendix is identified unexpectedly during a laparoscopic approach, it is acceptable to proceed with appendectomy laparoscopically, if it is safe and feasible.

7. Special situations (children, pregnancy, previous surgeries)

7.1 Children

Laparoscopic appendectomy is considered to be safe in children, provided the operator has ample experience in performing the procedure. The procedure is similar to that of adults. But the instruments required for paediatric patients differ according to their age. Usually 3mm – 5mm scopes are used. The size of the additional trocars varies between 3 – 5mm. Even though there is little published data regarding safe intra abdominal pressures lower pressures are used and are age related [5]. The result of one of the meta analyses suggests that laparoscopic appendectomy in children reduces the complications in comparison with the open procedure [13]

7.2 Pregnancy

Appendectomy is the most common non obstetric operation performed during pregnancy [14, 15] with a reported incidence of 0.05% - 0.1% [16]. Twenty-five per cent of all pregnant women who have acute appendicitis will progress to perforation [17]. A 66% perforation incidence has been reported where surgery is delayed by more than 24 hours compared with 0% incidence when surgical management is initiated prior to 24 hours after presentation [18]

Laparoscopic appendicectomy has potential advantages with a small incision, less postoperative pain and early return to normal activity [19 - 23]

Laparoscopy can result in less manipulation of the uterus while obtaining optimum exposure of the surgical field and can reduce delays in diagnosis and treatment. Laparoscopy also affords an easier visualization and treatment of the ectopically located appendix and helps in detecting other unexpected sources of pain [23, 24]

A recent review of laparoscopic appendicectomy in pregnancy reported a significantly higher fetal loss rate compared with open appendicectomy and has raised some concerns [25]. Fetal loss is due to spontaneous abortion in the first trimester and premature labour in 3rd trimester [26]. The areas of concern were the effect of the pneumoperitoneum and increased intra abdominal pressure on uterine blood flow, fetal distress due to maternal hypotension, fetal respiratory acidosis and trocar injury to the pregnant uterus [27].

Laparoscopic appendicectomy can be performed safely with the following measures. It is vital to get involvement of the obstetricians during the peri operative period. Place the patient slightly left lateral to avoid compression of the IVC by the uterus. Anti embolic devices should be used to prevent venous thrombosis. End tidal CO₂ should be monitored continuously. Recent evidence suggests that it is essential to have uterine and fetal monitoring before and after operation, as continuous monitoring may be difficult. The open technique (Hassan method) should be used for induction of the pneumoperitoneum, especially after the 1st trimester, to avoid a Veress needle injury to the uterus [28]. Other port positions depend upon the position of the appendix. Intra abdominal pressure should be maintained between 10 -12mmHg. Operative time should be reduced as low as possible, ideally less than 60 minutes. Prophylactic tocolytic agents are not used routinely unless there are uterine contractions and a risk of premature birth [20, 29, 30]

7.3 Previous abdominal surgery

Previous lower abdominal surgery was a relative contraindication for laparoscopic appendicectomy. However, various techniques have been used to perform appendicectomy laparoscopically. Using Optiview (Ethicon Endo-Surgery, Cincinnati, OH) or Visiport (Autosuture, USA) helps to place the camera port and the secondary ports under vision. If the adhesions are found to be flimsy they can be released with blunt and sharp dissection. If the appendix is visualized, then the procedure can be done as described earlier. But if the adhesions are found to be dense and the appendix is not visualized, then it is safer to convert the procedure to an open technique.

8. Complications

8.1 Bleeding

Aggressive or careless dissection of the mesoappendix can cause significant bleeding. If the appendix is highly inflamed and forms an early mass then dissection of the omentum, small bowel and caecum can also cause bleeding. Early control of the meso appendix and gentle dissection prevent this complication. Once bleeding is noted, it is controlled with an adequate view, gentle suction and simple pressure. Additional trocar may be necessary to solve this issue. Once the bleeding vessel is identified it is better to control it with a clip or endoloop, than continuous diathermy, which may potentially cause lateral damage.

Bleeding and haematoma can also arise from the port site, due to accidental injury to an anterior abdominal wall muscle/vessel, especially the inferior epigastric artery. This can be avoided by placing the incision away from the vascular structures by creating transillumination of the abdominal wall with the telescope. If there is a significant bleeding, it should be controlled with a suture at the port site.

8.2 Wound infection

One of the principal advantages of laparoscopy is the reduced rate of wound complications [31]. But still patients can get infections at the port sites. This may be due to delivery of the highly inflamed, gangrenous or perforated appendix through the port. This can be avoided by using a retrieval bag. If the patient develops a wound infection, it should be dealt with similar to any surgery.

8.3 Intra abdominal collection/ abscess

This is related to the degree of contamination caused by the inflamed appendix. This may also be due to the pneumoperitoneum, increased operative time and a prolonged dependant position [32]. A Cochrane review of 34 trials in 2003 showed an increased rate of intra abdominal abscess (pooled odds ratio 2.77, 95% CI 1.61 – 4.77) [33]. But later on it was proved that the pooled data was highly influenced by one large study and more perforated and gangrenous appendix were included in the laparoscopic group [11].

Patients who develop intra abdominal collections show signs of sepsis, including fever, abdominal pain and rising inflammatory markers. A CT scan is the investigation of choice to identify intra abdominal collections. Patients are treated with antibiotics and percutaneous radiological drainage if possible. If these measures fail then they should be dealt with surgically with either a re-look laparoscopy with liberal wash or a formal laparotomy.

8.4 Leakage of appendicial pus and faecoliths

Leakage of pus happens when the appendix is distended with pus and about to perforate. This can be prevented by gentle dissection and by using a retrieval bag for specimen removal. If there is accidental perforation of the appendix and leakage of pus or a faecolith, thorough irrigation should be performed and any visible faecolith should be removed immediately to prevent intra abdominal abscess formation.

8.5 Appendix stump leak

Leakage from the appendix stump occurs when an endoloop is applied to the gangrenous base. As there is no viable tissue the loop can cut through and cause leakage of caecal contents. This can be prevented by dividing the appendix with a healthy cuff of caecum by using a stapler device.

9. Open conversion

Open conversion should not be considered as a failure of laparoscopic appendicectomy. The common reasons for open conversion include, unable to find the appendix or mobilize the appendix, appendicular mass which is difficult to dissect, necrotic or perforated appendix, suspicion of a caecal malignancy where a right hemicolectomy is needed. The choice of incision depends on surgeon's preference and the findings on laparoscopy

10. Comparison with the open procedure

There is no evidence in the published literature that laparoscopic appendicectomy is less safe than open appendicectomy [34]. Whether the laparoscopic appendicectomy is better than open procedure depends on the outcomes measured, such as resource utilization, diagnostic accuracy, duration of surgery and stay, postoperative recovery and complications. Many randomized trials compared one or more of the above outcome measures. A Cochrane review in 2003 showed no difference in overall healthcare resource consumption between these groups [33].

A Cochrane review in 2011 found a significant difference favouring laparoscopy in diagnostic accuracy (7 RCTs, 561 participants; OR 4.1, 95% CI 2.50 – 6.71). Although the operative time is significantly less in the open appendicectomy group (by 14.55 mins, 95% CI 3.62 – 25.48, 5 RCTs, 355 participants), there was no difference in the overall length of hospital stay (6 RCTs, 455 participants; WMD -0.07, 95%CI -0.63 – 0.49).

The rate of removal of normal appendix was reduced with the laparoscopic approach compared to open appendicectomy (7 RCTs, OR 0.13, 95% CI 0.07 – 0.24). Laparoscopic appendicectomy was superior in regards to measures of postoperative recovery, such as pain reduction on a 10cm visual analogue scale (by 0.8cm, 95% CI 1.3 – 0.3), wound infection (pooled odds ratio 0.47, 95% CI 0.36 – 0.62) and reduced time to return to normal activity (by 5.09 days, 95% CI 5.56 – 4.61) [35]. Overall it appears that laparoscopic appendicectomy has obvious benefits in view of diagnostic accuracy and post operative outcome, with no overall increase in health care cost.



Fig. 11. SILS ports and 5mm 30 degree scope

11. SILS appendicectomy

SILS (Single Incision Laparoscopic Surgery) appendicectomy involves appendicectomy through a single incision through the umbilicus. Esposito C reported single trocar appendicectomy in 1998 [36], where the appendix was tied off laparoscopically and the appendicectomy was performed extracorporeally. Now the complete procedure is performed with a single umbilical incision with multiple ports [Fig. 11]. It improves the cosmetic outcome and minimizes the pain as it is not penetrating the muscle. It also avoids injury to the inferior epigastric vessels [37]. However, it needs great technical ability.

12. Conclusion


Laparoscopic appendicectomy is well tolerated by patients with reduced postoperative wound complications, improved cosmetic appearance and earlier return to normal activity. It is a preferred method in obese patients and young women, especially when the diagnosis is uncertain.

13. References

- [1] Addiss DG et al. (1990). The epidemiology of appendicitis and appendectomy in the United States. *Am J Epidemiol* 132:910-25
- [2] Semm K. (1983). Endoscopic appendicectomy. *Endoscopy* 15:59-64
- [3] Barnes SL et al. (2004). Laparoscopic appendectomy after 30 weeks pregnancy: report of two cases and description of technique. *Am Surg.* 70:733–736.
- [4] Keith N, Apeltgren. (2006). Laparoscopic Appendicectomy.. *The SAGES manual. Fundamentals of Laparoscopy, Thoracoscopy and GI Endoscopy.* Carol E.H. Scott-Conner :350 -56. Springer, ISBN : 13: 978-0387-23267-6, USA
- [5] Jean-Louis Dulucq. (2003). *Tips and Techniques in laparoscopic surgery.* 103 -118. Springer, ISBN 3-540-20902-6, Berlin Heidelberg New York
- [6] Roumen R. M. et al. (2008). Randomized clinical trial evaluating elective laparoscopic appendicectomy for chronic right lower-quadrant pain. *Br J Surg*; 95: 169-174
- [7] Grunewald B, Keating J. (1993). Should the 'normal' appendix be removed at operation for appendicitis? *J R Coll Surg Edin*; 38:158 – 60.
- [8] Van den Broek WT et al. (2001). A normal appendix found during laparoscopic appendectomy should not be removed. *Br J Surg*; 88:251-4.
- [9] Greason KL, Rappold JF, Liberman MA. (1998). Incidental laparoscopic appendicectomy for acute right lower quadrant abdominal pain. Its time has come. *Surg Endosc*; 12:223 -25.
- [10] Horrow MM, White DS, Horrow JC. (2003) Differentiation of perforated from nonperforated appendicitis on CT. *Radiology*; 227:45-51.
- [11] Pedersen AG, Petersen OB, Wara P, et al. (2001) Randomised controlled trial of laparoscopic versus open appendicectomy. *Br J Surg*; 88:200 – 5.
- [12] Piskun G, Kozik D, Rajpal S, Shaftan G, Fogler R (2001). Comparison of laparoscopic, open and converted appendectomy for perforated appendicitis. *Surg Endosc*; 15:660-2.
- [13] Omer Aziz, Thanos Athanasiou et al. (2006) Laparoscopic Versus Open Appendicectomy in Children – A meta analysis. *Ann Surg* ; 243: 17-27

- [14] Kammerer WS. Nonobstetric surgery during pregnancy. (1979) *Med Clin North Am.*; 63:1157-1164
- [15] Kort B, Katz VL, Watson WJ. (1993). The effect of nonobstetric operation during pregnancy. *Surg Gynecol Obstet.*; 177:371-376.
- [16] Curet MJ. Special problems in laparoscopic surgery. (2000) Previous abdominal surgery, obesity and pregnancy. *Surg Clin North Am.* ;80:1093-1110.
- [17] Cappell MS, Friedel D. Abdominal pain during pregnancy. (2003) *Gastroenterol Clin North Am.*; 32:1-58.
- [18] Tamir IL, Bongard FS, Klein SR (1990). Acute appendicitis in the pregnant patient. *Am J Surg.*; 160:571-575.
- [19] Affleck DG, Handrahan DL, Egger MJ, Price PR (1999). The laparoscopic management of appendicitis and cholelithiasis during pregnancy. *Am J Surg.*; 178:523-529.
- [20] Moreno-Sanz C et al. (2007) Laparoscopic appendectomy during pregnancy: between personal experiences and scientific evidence. *J Am Coll Surg.*; 205(1):37-42.
- [21] Rollins MD, Chan KJ, Price RR. (2004) Laparoscopy for appendicitis and cholelithiasis during pregnancy: a new standard of care. *Surg Endosc.*; 18:237-241.
- [22] Halkic N et al. (2006) Laparoscopic management of appendicitis and symptomatic cholelithiasis during pregnancy. *Langenbecks Arch Surg.*; 391:467-471.
- [23] Lyass S et al. (2001) Is laparoscopic appendicectomy safe in pregnant women? *Surg Endosc.*; 15:377-379.
- [24] de Perrot MD et al. (2000) Laparoscopic appendicectomy during pregnancy. *Surg Laparosc Endosc Percutan Tech.*; 10(6):368-371.
- [25] McGory ML et al. (2007) Negative appendectomy in pregnant women is associated with a substantial risk of fetal loss. *J Am Coll Surg.*; 205:534-540.
- [26] Al-Fozan H, Tulandi T. (2001). Safety and risks of laparoscopy in pregnancy. *Curr Opin Obstet Gynecol* ; 14:375-9
- [27] Amos JD, Schorr SJ, Norman PF, et al. (1996) Laparoscopic surgery during pregnancy. *Am J Surg*; 171:435 - 7.
- [28] Friedman JD, Ramsey PS, Ramin KD, Berry C. (2003). Pneumoamnion and pregnancy loss after second-trimester laparoscopic surgery. *Obstet Gynecol* ; 99:512-3
- [29] Walsh CA, Tang T, Walsh SR. (2008). Laparoscopic versus open appendectomy in pregnancy: a systematic review. *Int J Surg.* 6:339-344 Epub 2008 Feb1.
- [30] Jackson H, Granger S, Price R, et al. (2008). Diagnosis and laparoscopic treatment of surgical diseases during pregnancy: an evidence based review. *Surg Endosc.*; 22:1917-1927.
- [31] Holzman MD et al. (1997). Laparoscopic ventral and incisional hernioplasty. *Surg Endosc*; 11:32-5.
- [32] Balague Ponz C, Trias M. (2001). Laparoscopic surgery and surgical infection. *J Chemother* ;13 Spec No 1:17-22
- [33] Sauerland S, Lefering R, Neugebauer EAM (2003). Laparoscopic versus open surgery for suspected appendicitis (Cochrane Review) In: *The Cochrane Library*, Issue 1. Oxford: update Software, 2003.
- [34] Edmund AM Neugebaue et al. (2006). *EAES guidelines for Endoscopic Surgery*. ISBN-10 3-540-32783-5, Springer Berlin Heidelberg New York

- [35] Gaitan HG, Reveiz L, Farquhar C (2011). Laparoscopy for the management of acute lower abdominal pain in women of childbearing age (Cochrane review). *The Cochrane Library*, Issue 1.
- [36] Esposito C. One trocar appendicectomy in pediatric surgery (1998). *Surg Endosc.*; 12:177-78
- [37] Maria DF et al. (2011) Single incision transumbilical laparoscopic appendicectomy: initial experience. *CIR ESP.*; 89(1):37-41



Appendicitis - A Collection of Essays from Around the World

Edited by Dr. Anthony Lander

ISBN 978-953-307-814-4

Hard cover, 226 pages

Publisher InTech

Published online 11, January, 2012

Published in print edition January, 2012

This book is a collection of essays and papers from around the world, written by surgeons who look after patients of all ages with abdominal pain, many of whom have appendicitis. All general surgeons maintain a fascination with this important condition because it is so common and yet so easy to miss. All surgeons have a view on the literature and any gathering of surgeons embraces a spectrum of opinion on management options. Many aspects of the disease and its presentation and management remain controversial. This book does not answer those controversies, but should prove food for thought. The reflections of these surgeons are presented in many cases with novel data. The chapters encourage us to consider new epidemiological views and explore clinical scoring systems and the literature on imaging. Appendicitis is discussed in patients of all ages and in all manner of presentations.

How to reference

In order to correctly reference this scholarly work, feel free to copy and paste the following:

Maheswaran Pitchaimuthu (2012). Laparoscopic Appendicectomy, *Appendicitis - A Collection of Essays from Around the World*, Dr. Anthony Lander (Ed.), ISBN: 978-953-307-814-4, InTech, Available from: <http://www.intechopen.com/books/appendicitis-a-collection-of-essays-from-around-the-world/laparoscopic-appendicectomy>

INTECH
open science | open minds

InTech Europe

University Campus STeP Ri
Slavka Krautzeka 83/A
51000 Rijeka, Croatia
Phone: +385 (51) 770 447
Fax: +385 (51) 686 166
www.intechopen.com

InTech China

Unit 405, Office Block, Hotel Equatorial Shanghai
No.65, Yan An Road (West), Shanghai, 200040, China
中国上海市延安西路65号上海国际贵都大饭店办公楼405单元
Phone: +86-21-62489820
Fax: +86-21-62489821

© 2012 The Author(s). Licensee IntechOpen. This is an open access article distributed under the terms of the [Creative Commons Attribution 3.0 License](https://creativecommons.org/licenses/by/3.0/), which permits unrestricted use, distribution, and reproduction in any medium, provided the original work is properly cited.

IntechOpen

IntechOpen