

# We are IntechOpen, the world's leading publisher of Open Access books Built by scientists, for scientists

6,900

Open access books available

185,000

International authors and editors

200M

Downloads

Our authors are among the

154

Countries delivered to

TOP 1%

most cited scientists

12.2%

Contributors from top 500 universities



WEB OF SCIENCE™

Selection of our books indexed in the Book Citation Index  
in Web of Science™ Core Collection (BKCI)

Interested in publishing with us?  
Contact [book.department@intechopen.com](mailto:book.department@intechopen.com)

Numbers displayed above are based on latest data collected.  
For more information visit [www.intechopen.com](http://www.intechopen.com)



## Current Evidence and Recommendations for Laparoscopic Appendectomy

Hung-Sheng Wu<sup>1,3,4,5,6</sup>, James Wall<sup>2</sup>,  
Hung-Wen Lai<sup>1</sup> and Jacques Marescaux<sup>2</sup>

<sup>1</sup>Asia Institute Tele-Surgery

<sup>2</sup>European Institute Tele-Surgery

<sup>3</sup>Show-Chwan Memorial Hospital, Chang-Hua

<sup>4</sup>Chang-Bin Show Chwan Memorial Hospital, Chang-Hua

<sup>5</sup>Tri-service General Hospital, Taipei

<sup>6</sup>National Defense Medical Center, Taipei  
R.O.C.

### 1. Introduction

Acute appendicitis is the most common etiology of the acute abdomen, generally requiring urgent surgical intervention. The lifetime incidence of acute appendicitis is approximate 7%. In 1886, Fitz described the natural course of appendicitis. He began advocating early appendectomy to prevent perforation with subsequent complications of sepsis, shock and potential mortality. In 1894 McBurney introduced the right lower quadrant incision to approach the appendix. The open appendectomy (OA) through a McBurney incision came into favour more than a century ago. It is a simple, safe, quick, and effective operation that can be performed by a general surgeon with the basic surgical instruments.

### 2. Laparoscopic appendectomy

During the past two decades, general surgery has seen a major shift from open to minimally invasive surgery. This has been driven by the development of laparoscopic technology that enables surgeons to perform increasingly complex tasks through small incisions. Laparoscopic appendectomy (LA) was one of the first reported laparoscopic cases in general surgery by de Kok in 1977<sup>1</sup>. Despite an early start, it did not enjoy the same popularity as other general surgery procedures such as laparoscopic cholecystectomy.

There are over 2000 articles on LA and over 60 randomized clinical trials comparing OA to LA. In the 2004 Cochrane review of OA versus LA several key differences were noted<sup>2</sup>. Wound infections were less likely after LA than after OA; however the incidence of intraabdominal abscesses was higher after LA. The duration of surgery was on average 10 minutes longer for laparoscopic procedures. Pain on day 1 after surgery was modestly reduced after LA on a 100 point visual analog scale and hospital stay was shortened by 1.1 days after LA. Return to normal activity, work, and sport occurred earlier after laparoscopic procedures than after open procedures. While the operation costs of laparoscopic procedures were significantly higher,

the costs outside hospital were reduced. The conclusion of the review was that young female, obese, and employed patients seem to benefit from the laparoscopic procedure more than other groups. The European Association of Endoscopic Surgeons (EAES) has recently released guidelines on appendectomy that clearly favor the laparoscopic approach<sup>3</sup>. The justification includes the benefits of decreased wound infection and faster return to activity. EAES additionally highlights that the highest level of evidence for benefit of LA over OA is in women of childbearing age and obese patients.

We performed a retrospective analysis of 1366 patients with acute appendicitis at Changhua and Chang-Bing Show-Chwan Memorial Hospitals from January 1, 2004 to December 31, 2009<sup>4</sup>. Compared with OA, LA was associated with a lower complication rate (9.5% versus 5.8%;  $P=0.013$ ), a lower wound infection rate (8.6% versus 4.2%;  $P=0.001$ ), and a shorter hospital stay ( $4.60\pm3.64$  versus  $4.06\pm1.84$  days;  $P=0.001$ ), but a higher mean cost ( $32,670\pm28,568$  versus  $37,567\pm12,064$  New Taiwan dollars). In the subgroup analysis, the patients with complicated appendicitis, female patients, and pediatric and elderly patients benefited from a reduced hospital stay.

A global trend toward an increased use of laparoscopic appendectomy has been observed. Hove et al. reported an increase in the United States from 19.1% in 1997 to 37.9% in 2003 based on the Nationwide Inpatient Sample<sup>5</sup>. Sporn et al. reported a further increase to 58% in 2005 based in the same sampling technique<sup>6</sup>. In our institution the rate has increased rapidly, from 8.1% in 2004 to 90.3% in 2009<sup>4</sup>. The reasons for such a rapid increase are not entirely clear in light of the modest benefits of LA over OA at significantly increased cost. The increased adoption of LA is undoubtedly multifactorial and includes motivations of the surgeon, patient and medical device industry that go beyond the measurable outcome benefits. From the surgeons' perspective, laparoscopy offers greater flexibility for both diagnosis and intervention in the event of finding unexpected pathology when operating on suspected appendicitis. In addition, the current generation of surgeons is significantly more familiar and comfortable with laparoscopy. Satisfaction with improved cosmetic results and a perception of decreased surgical trauma is driving patient demand for less invasive surgical approaches. Finally, the medical device industry profits from the increased use of laparoscopic technologies and has gone to great lengths to promote minimally invasive approaches.

Findings	Statistical Significance
Lower wound infection rate for LA	0.43 odds ratio (0.34 - 0.54 95% CI)
Higher intra-abdominal abscess rate	2.48 odds ratio (1.45 - 4.21 95% CI)
12 minute longer operating time for LA	12 min (7-16 95% CI)
Decreased post-operative pain after LA on a 100 point visual analog scale	2.48 odds ratio (1.45 - 4.21 95% CI)
Decreased hospital stay by 1.1 day after LA	1.1 day (0.6 - 1.5 95%CI)
Reduced risk of negative appendectomy with diagnostic laparoscopy in women of child bearing age	0.20 odds ratio (0.11 - 0.34)
Reduced risk of negative appendectomy with diagnostic laparoscopy in the general adult population	0.37 odd ratio (0.13 - 1.01)

Table 1. Summary of findings from the 2004 Cochrane review of LA vs OA.

### 3. Minimally invasive training

Appropriate laparoscopic training is important in assuring good surgical outcomes. Iatrogenic bowel perforations and vascular injuries from both trocar placement and out of field instruments have been reported in LA<sup>7,8</sup>. These injuries should be avoidable with appropriate training and experience. With the growing popularity of minimally invasive surgery, there is an increasing need to training surgeons to become proficient in minimally invasive techniques. In Asia, the Asia Institute Tele-Surgery (AITS) laparoscopic training center has played a major role in increasing surgeons' preference for laparoscopic appendectomy.

### 4. Complex appendicitis

Complex appendicitis includes the presence of an intraabdominal abscess or a phlegmon. The risk of surgical complications is increased in these situations. Conservative treatment with antibiotics followed by interval appendectomy has been proposed since the 1920s in patients who do not have generalized peritonitis<sup>9</sup>. This approach has been reported to carry significantly fewer complications, wound infections, abdominal/pelvic abscesses, ileus/bowel obstructions, and reoperations while not increasing hospitalization or length of antibiotic use<sup>10</sup>. Interval appendectomy after successful conservative treatment of an appendiceal mass remains controversial. The rate of recurrent appendicitis in patients has been reported as high as 10-20% and interval appendectomy was generally recommended in all but the highest risk patients<sup>11</sup>. More recent studies show that the failure rate of conservative treatment ranges from 5-15% and those patients will require surgical intervention within the first few months<sup>12</sup>. However, recurrent appendicitis beyond one year of successful conservative management is low at 2% and interval appendectomy in those patients may not be justified<sup>13</sup>. We believe there is still a role for interval appendectomy with benefits for a substantial group of patients, but it is not routinely necessary. If it is to be performed a laparoscopic approach is appropriate.

### 5. Technique for laparoscopic appendectomy

#### 5.1 Patient positioning and room setup

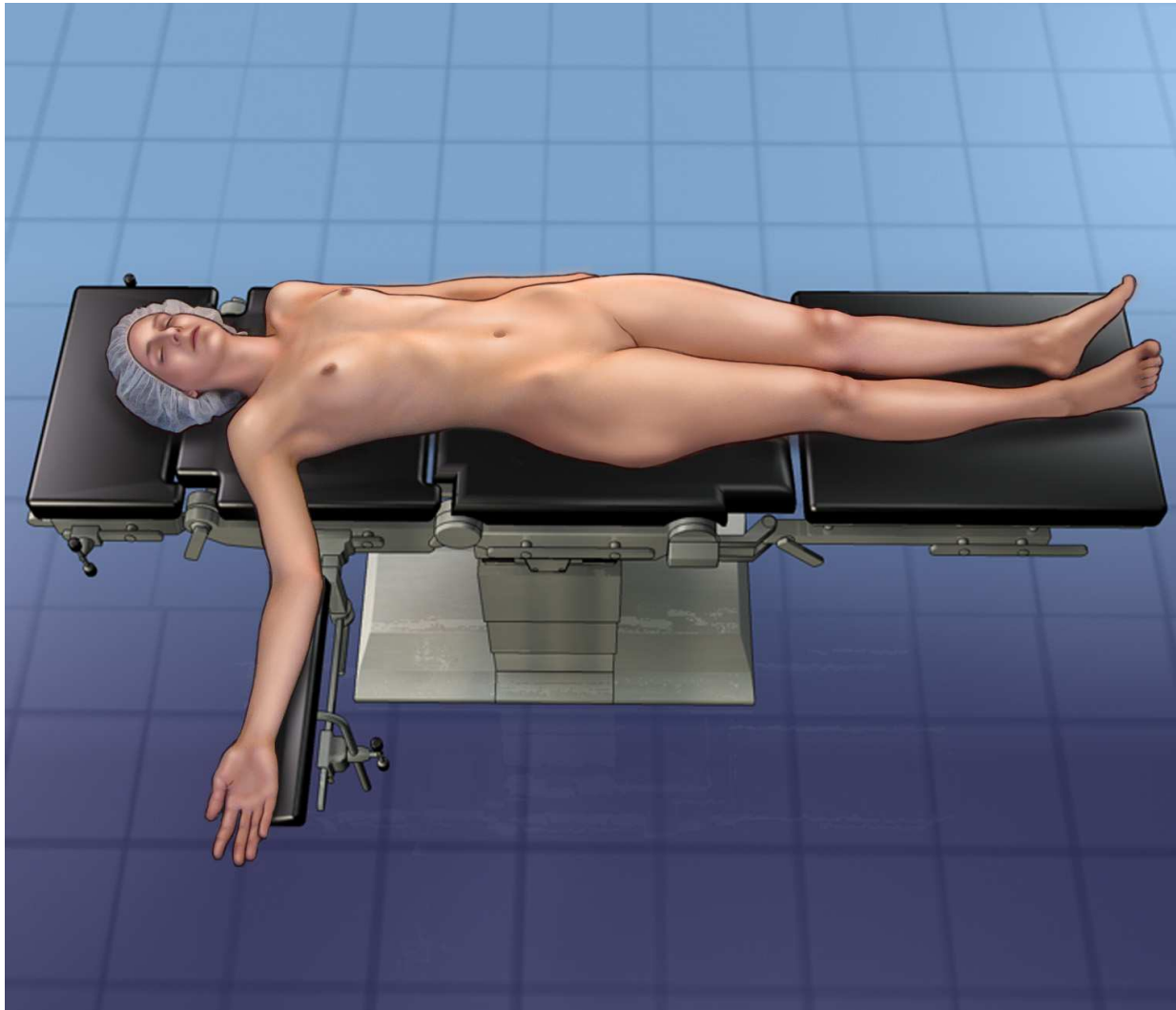
The patient is positioned as for an open appendectomy in the supine position with the legs together, right arm angled on a board, and left arm tucked alongside the body (Image 1). This position allows the surgeon and their assistant to work on the left side of the patient. A single monitor is placed over the right side of the patient. In order to facilitate maximal exposure of the appendix after trocar placement, the operating table is placed in a Trendelenburg position and tilted to the left.

#### 5.2 Instrumentation

We use the following instrumentation at our institution for standard laparoscopic appendectomy:

1. 0° laparoscope
2. Fine dissection scissors
3. Peanut swab
4. Fenestrated grasping forceps
5. Bipolar cauterizing grasper

6. Clip applicator
7. Electrocautery hook
8. Suction-irrigation device
9. 2 endoloops
10. Extraction bag.



COPYRIGHT WebSurg – IRCAD – All rights reserved

Image 1. Patient positioning for laparoscopic appendectomy. The left arm is tucked by the side and the right arm is angled on a board.

### 5.3 Trocar placement

Three trocars placed in triangular formation are generally needed: one optical trocar and two operating trocars. The optical trocar is generally a 10/11mm trocar placed in the peri-umbilical position. Smaller 3-5mm optics can be used, particularly in children. Two operating trocars are placed ideally at a minimum of 8 to 10cm from one another. One operating trocar (5 or 10/11mm) is placed in the midline suprapubic position and another operating trocar (5 or 10/11mm) is placed in left iliac fossa position (Image 2). Some authors place the second operating trocar in the right iliac fossa, however we find that this places a



working instrument too close to the field of interest. Another notable variation is placement of the two working ports adjacent to one another in the suprapubic position. This reduces the benefits of the triangulation of the working instruments described above, but leaves scars generally hidden below the waistline. Another option is to use two 5mm operating ports placed similarly. As with any laparoscopic case, as difficulty arise with retraction and visualization, additional ports can be added.

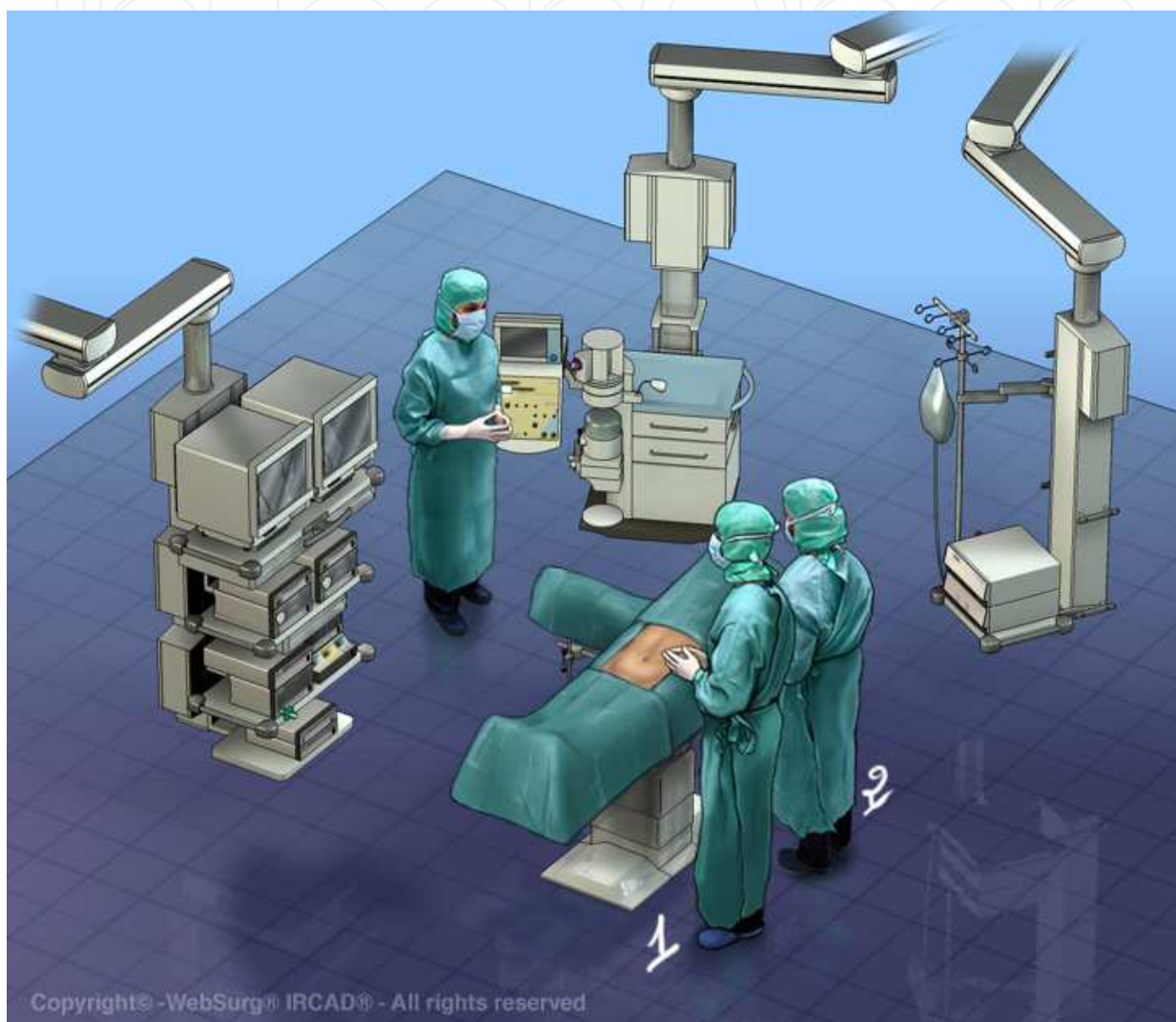


Image 2. Operating room setup for laparoscopic appendectomy. The surgeon and assistant are positioned on the left side of the patient with a monitor on the right side of the patient.

#### 5.4 Dissection

The procedure begins with an exploration to confirm the diagnosis of acute appendicitis. Laparoscopy is clearly superior to the surgeons' finger through a McBurney's point incision in the diagnosis of alternative abdominal pathologies.

If acute appendicitis is confirmed, any adhesions between the appendix and the peritoneal wall are divided to expose the appendix from its tip to its base. The appendix is

frequently located laterally or posterior to the cecum. Next the mesoappendix is controlled using either bipolar forceps or a harmonic scalpel for coagulation of the appendiceal artery. Finally the ligation of the appendix and control of the appendiceal stump are performed. Double ligation of the base of the appendix is performed with a Surgitie™ Loop (Covidien) or an ENDOLOOP® Ligature (Ethicon) and the appendix is amputated with scissors. The appendix can be extracted through a port site directly or placed into a specimen bag to prevent contamination. The specimen is extracted through the largest port site, which is typically the 10/11mm periumbilical trocar. Alternative approaches include the use of an Endo GIA™ Universal Stapler (Covidien) to divide both the mesoappendix and the appendix. In the case of necrosis of the base of the appendix, a stapler can be used to resect a small wedge of the cecum while taking great care not to create a stenosis.

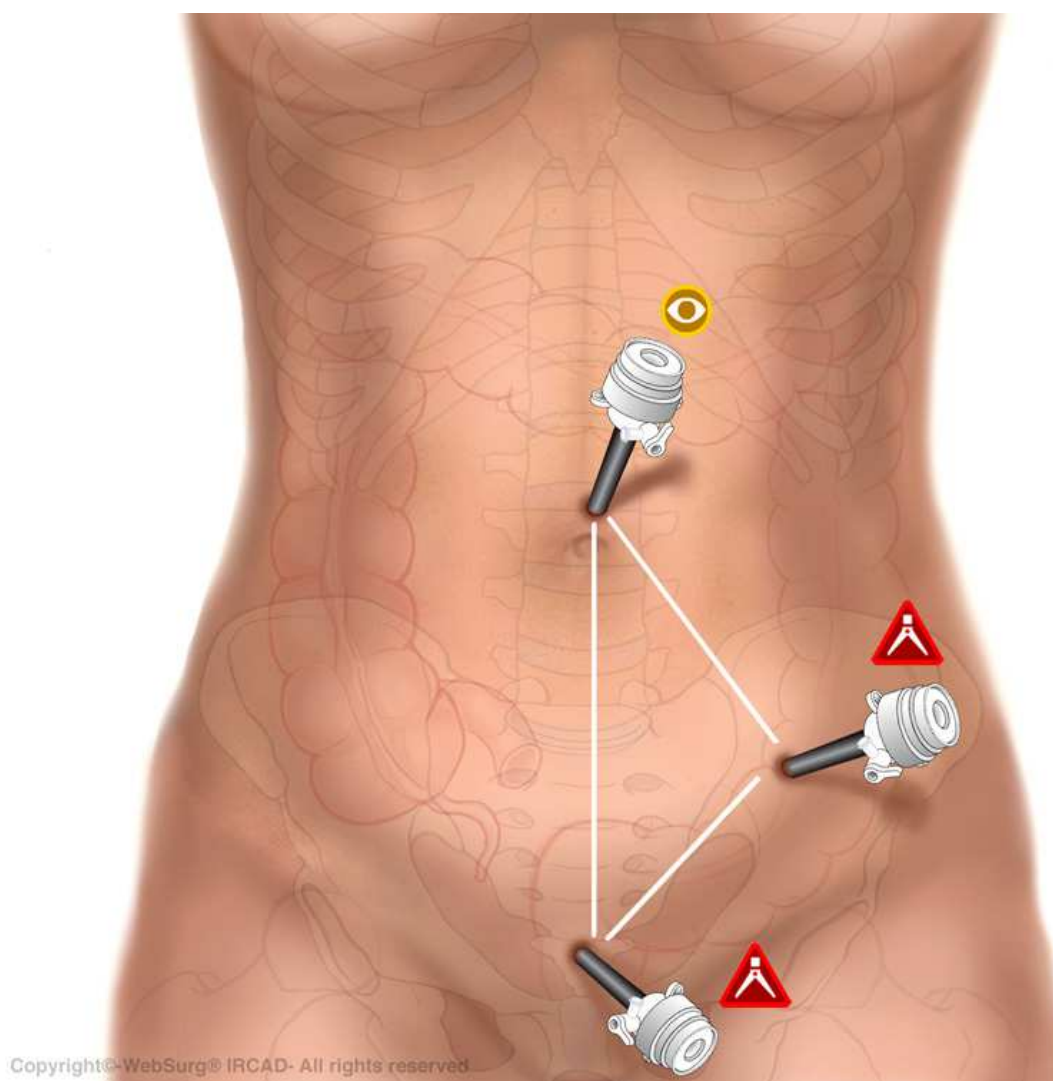
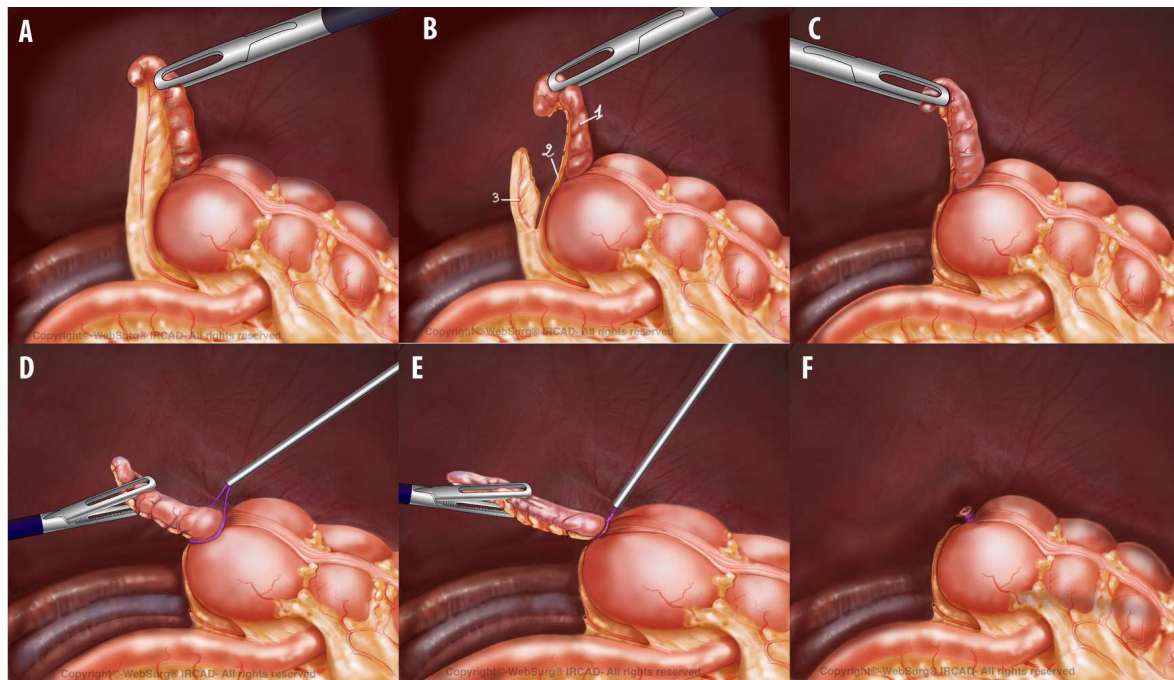


Image 3. Preferred trocar placement for laparoscopic appendectomy. An optical trocar in the umbilicus and working trocars in the suprapubic and left lower quadrant.



COPYRIGHT WebSurg – IRCAD – All rights reserved

Image 4. Basic technique of laparoscopic appendectomy. (A) exposure of the appendix and meso appendix (B) division of the mesoappendix and appendicular artery (C) isolation of the appendiceal base (D) placement of endoloop at the base of the appendix (E) ligation of the base of the appendix (F) completed appendectomy.

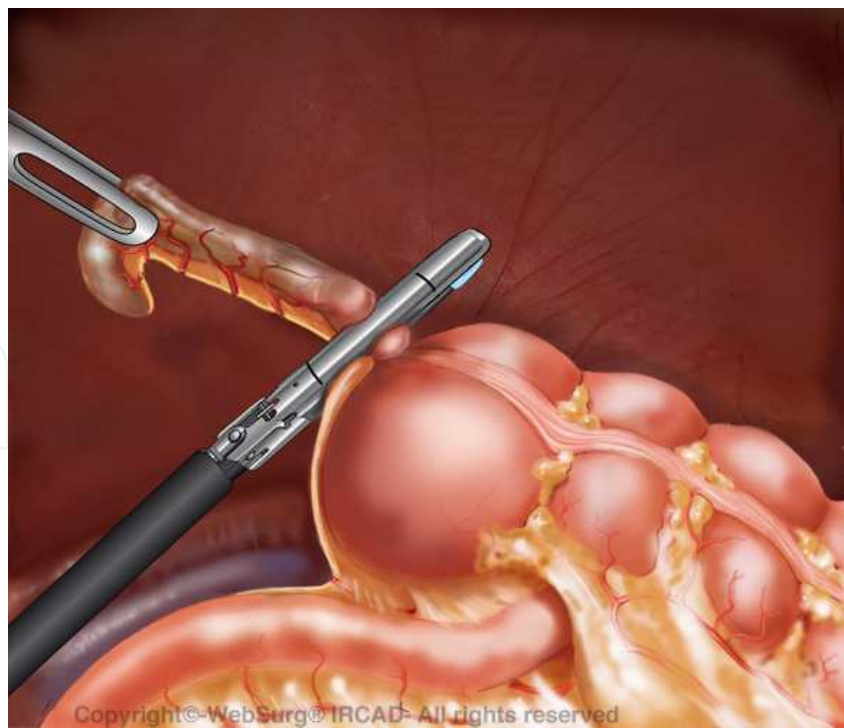

Image 5. Alternative approach to division of the appendix using an EndoGIA stapler. This approach is useful for a necrotic appendiceal base that may require a small wedge resection of the cecum taking care not to create a stenosis.



## 6. Emerging technologies

### 6.1 Single Incision Laparoscopic Surgery (SILS)

Minimally invasive surgery has seen the emergence of two new techniques that attempt to further minimize surgical trauma for the benefit of the patient. Single Incision Laparoscopic Surgery (SILS) attempts to limit abdominal wall trauma by performing procedures through a single incision that can accommodate multiple working instruments. SILS procedures are technically demanding due to multiple factors including 1) internal and external conflicts between operating instruments and the optical system, 2) lack of triangulation for working instruments, 3) in-line view, and 4) limited ability to retract and expose. Early reports used more endoscopic techniques<sup>14</sup>, but a recent emergence of single port operating systems have begun to address the challenges of SILS with such innovations as angulated instruments. Appendectomy may be ideally suited for SILS as the procedure rarely requires significant retraction, the dissection is not complex and the operative field is limited to the right lower quadrant. Initial reports have shown the feasibility of SILS<sup>15,16</sup>, and trials are ongoing to compare the benefits with traditional LA. While awaiting the results of definitive trials, SILS appears to be a reasonable approach in highly skilled hands.

### 6.2 Natural Orifice Transluminal Endoscopic Surgery (NOTES)

Natural Orifice Transluminal Endoscopic Surgery goes a step beyond SILS in minimizing abdominal wall trauma by avoiding any abdominal incisions. The concept of NOTES is to introduce a flexible operative platform through natural orifices including the mouth, vagina or anus. A vicerotomy is made in the wall of the stomach, vagina, or rectum respectively to gain access into the peritoneal cavity. The procedure is then performed and any specimen extracted through the natural orifice, leaving behind no abdominal scar. Both transvaginal and transgastric NOTES appendectomy have been performed in humans<sup>17,18</sup>, but major concerns exist around the need to create a vicerotomy in an otherwise healthy organ and then securely close the defect. NOTES appendectomy can currently only be considered appropriate for experienced surgeon in the setting of approved clinical trials.

## 7. Conclusion

The management of appendicitis is at the core of general surgery practice. The development of minimally invasive surgery has offered the surgeon a wider range of options in the treatment of this age-old disease. Laparoscopy is a robust and safe platform that allows the surgeon more flexibility in exploring the abdomen than the traditional McBurney's incision. Overall benefits of LA are modest but measurable and multiple factors have combined to significantly increase the choice of LA over OA in recent years. Appropriate training is necessary for all new technologies and techniques in the OR. Emerging technologies are on the horizon that may further minimize surgical trauma for the benefit of patients.

## 8. References


- [1] de Kok HJ. A new technique for resecting the non-inflamed not-adhesive appendix through a mini-laparotomy with the aid of the laparoscope. *Arch Chir Neerl.* 1977;29(3):195-198.

- [2] Sauerland S, Lefering R, Neugebauer EA. Laparoscopic versus open surgery for suspected appendicitis. *Cochrane Database Syst Rev*. 2004(4):CD001546.
- [3] Vettoretto N, Gobbi S, Corradi A, et al. Consensus conference on laparoscopic appendectomy: development of guidelines. *Colorectal Dis*. Jul 2011;13(7):748-754.
- [4] Wu HS, Lai HW, Kuo SJ, et al. Competitive edge of laparoscopic appendectomy versus open appendectomy: a subgroup comparison analysis. *J Laparoendosc Adv Surg Tech A*. Apr 2011;21(3):197-202.
- [5] Van Hove C, Hardiman K, Diggs B, Deveney C, Sheppard B. Demographic and socioeconomic trends in the use of laparoscopic appendectomy from 1997 to 2003. *Am J Surg*. May 2008;195(5):580-583; discussion 583-584.
- [6] Sporn E, Petroski GF, Mancini GJ, Astudillo JA, Miedema BW, Thaler K. Laparoscopic appendectomy--is it worth the cost? Trend analysis in the US from 2000 to 2005. *J Am Coll Surg*. Feb 2009;208(2):179-185 e172.
- [7] Long KH, Bannon MP, Zietlow SP, et al. A prospective randomized comparison of laparoscopic appendectomy with open appendectomy: Clinical and economic analyses. *Surgery*. Apr 2001;129(4):390-400.
- [8] Guloglu R, Dilege S, Aksoy M, et al. Major retroperitoneal vascular injuries during laparoscopic cholecystectomy and appendectomy. *J Laparoendosc Adv Surg Tech A*. Apr 2004;14(2):73-76.
- [9] Soresi AL. Technic of Appendectomy: Description of a Rational, Safe and Easy Technic of the Operation for Acute and Interval Appendicitis. *Ann Surg*. Mar 1920;71(3):315-346.
- [10] Simillis C, Symeonides P, Shorthouse AJ, Tekkis PP. A meta-analysis comparing conservative treatment versus acute appendectomy for complicated appendicitis (abscess or phlegmon). *Surgery*. Jun 2010;147(6):818-829.
- [11] Bradley EL, 3rd, Isaacs J. Appendiceal abscess revisited. *Arch Surg*. Feb 1978;113(2):130-132.
- [12] Willemsen PJ, Hoorntje LE, Eddes EH, Ploeg RJ. The need for interval appendectomy after resolution of an appendiceal mass questioned. *Dig Surg*. 2002;19(3):216-220; discussion 221.
- [13] Tekin A, Kurtoglu HC, Can I, Oztan S. Routine interval appendectomy is unnecessary after conservative treatment of appendiceal mass. *Colorectal Dis*. Jun 2008;10(5):465-468.
- [14] Inoue H, Takeshita K, Endo M. Single-port laparoscopy assisted appendectomy under local pneumoperitoneum condition. *Surg Endosc*. Jun 1994;8(6):714-716.
- [15] Lee J, Baek J, Kim W. Laparoscopic transumbilical single-port appendectomy: initial experience and comparison with three-port appendectomy. *Surg Laparosc Endosc Percutan Tech*. Apr 2010;20(2):100-103.
- [16] Chow A, Purkayastha S, Paraskeva P. Appendicectomy and cholecystectomy using single-incision laparoscopic surgery (SILS): the first UK experience. *Surg Innov*. Sep 2009;16(3):211-217.
- [17] Park PO, Bergstrom M. Transgastric peritoneoscopy and appendectomy: thoughts on our first experience in humans. *Endoscopy*. Jan 2010;42(1):81-84.

- [18] Palanivelu C, Rajan PS, Rangarajan M, Parthasarathi R, Senthilnathan P, Prasad M. Transvaginal endoscopic appendectomy in humans: a unique approach to NOTES--world's first report. *Surg Endosc.* May 2008;22(5):1343-1347.

IntechOpen

IntechOpen



## **Appendicitis - A Collection of Essays from Around the World**

Edited by Dr. Anthony Lander

ISBN 978-953-307-814-4

Hard cover, 226 pages

**Publisher** InTech

**Published online** 11, January, 2012

**Published in print edition** January, 2012

This book is a collection of essays and papers from around the world, written by surgeons who look after patients of all ages with abdominal pain, many of whom have appendicitis. All general surgeons maintain a fascination with this important condition because it is so common and yet so easy to miss. All surgeons have a view on the literature and any gathering of surgeons embraces a spectrum of opinion on management options. Many aspects of the disease and its presentation and management remain controversial. This book does not answer those controversies, but should prove food for thought. The reflections of these surgeons are presented in many cases with novel data. The chapters encourage us to consider new epidemiological views and explore clinical scoring systems and the literature on imaging. Appendicitis is discussed in patients of all ages and in all manner of presentations.

### **How to reference**

In order to correctly reference this scholarly work, feel free to copy and paste the following:

Hurng-Sheng Wu, James Wall, Hung-Wen Lai and Jacques Marescaux (2012). Current Evidence and Recommendations for Laparoscopic Appendectomy, *Appendicitis - A Collection of Essays from Around the World*, Dr. Anthony Lander (Ed.), ISBN: 978-953-307-814-4, InTech, Available from: <http://www.intechopen.com/books/appendicitis-a-collection-of-essays-from-around-the-world/current-evidence-and-recommendations-for-laparoscopic-appendectomy>

**INTECH**  
open science | open minds

### **InTech Europe**

University Campus STeP Ri  
Slavka Krautzeka 83/A  
51000 Rijeka, Croatia  
Phone: +385 (51) 770 447  
Fax: +385 (51) 686 166  
[www.intechopen.com](http://www.intechopen.com)

### **InTech China**

Unit 405, Office Block, Hotel Equatorial Shanghai  
No.65, Yan An Road (West), Shanghai, 200040, China  
中国上海市延安西路65号上海国际贵都大饭店办公楼405单元  
Phone: +86-21-62489820  
Fax: +86-21-62489821



© 2012 The Author(s). Licensee IntechOpen. This is an open access article distributed under the terms of the [Creative Commons Attribution 3.0 License](https://creativecommons.org/licenses/by/3.0/), which permits unrestricted use, distribution, and reproduction in any medium, provided the original work is properly cited.

IntechOpen

IntechOpen