

# We are IntechOpen, the world's leading publisher of Open Access books Built by scientists, for scientists

6,900

Open access books available

186,000

International authors and editors

200M

Downloads

Our authors are among the

154

Countries delivered to

TOP 1%

most cited scientists

12.2%

Contributors from top 500 universities



WEB OF SCIENCE™

Selection of our books indexed in the Book Citation Index  
in Web of Science™ Core Collection (BKCI)

Interested in publishing with us?  
Contact [book.department@intechopen.com](mailto:book.department@intechopen.com)

Numbers displayed above are based on latest data collected.  
For more information visit [www.intechopen.com](http://www.intechopen.com)



# Diagnostic Challenges in Acute Appendicitis

Sanjay Harrison<sup>1</sup> and Harrison Benziger<sup>2</sup>

<sup>1</sup>Sunderland Royal Hospital

<sup>2</sup>Queen Elizabeth the Queen Mother Hospital  
United Kingdom

## 1. Introduction

Acute appendicitis is one of the commonest surgical problems (Humes et al, 2007) and though less common at the extremes of age, it can present classically or in an atypical manner in the very young and the elderly. Making a diagnosis of appendicitis is not always easy and it has led to the development of clinical scoring systems and a wider use of imaging techniques.

A raised white cell count and C-reactive protein level reflect inflammation and raise the probability that a patient with right iliac fossa pain has appendicitis. These markers have been joined by serum levels of novel markers such as interleukin-6 and procalcitonin (Erkasap, 2000; Paajanen, 2002). Importantly, it should be realised that no test has a 100% sensitivity or specificity.

The diagnosis of acute appendicitis can be missed leading to morbidity and mortality especially at the extremes of age sometimes with medico-legal consequences. It is estimated that a missed or delayed diagnosis of acute appendicitis is among the top five most frequent malpractice claims made against emergency department clinicians (Chung, 2000). This highlights the need for improving our ability to diagnose this condition.

Missed or delayed diagnoses sometimes follow classical presentations and reveal an education gap in training. Missed or delayed diagnoses following atypical presentations are well documented (Alloo, 2004; Paulson, 2003; Rusnak, 1994). All clinicians involved in the initial assessment of patients with abdominal pain need a good understanding of the pathophysiology of appendicitis, appropriate investigations and imaging.

## 2. Methods

A Pubmed and Medline search of papers utilising the keywords appendicitis, atypical appendicitis, appendicitis in pregnancy, appendicitis in the elderly, pathophysiology appendicitis, scoring systems appendicitis, imaging appendicitis, ultrasound appendicitis, computerised tomography appendicitis, causes of appendicitis were used for this review. The bibliographies of relevant articles were also searched.

## 3. The classical presentation

The typical history usually attributed to an underlying inflamed appendix is a central abdominal pain which gets progressively worse and localises to the right iliac fossa. This

is usually associated with anorexia, nausea, vomiting and a low grade pyrexia. The initial central abdominal pain is described as dull and becomes sharp once localised to the right iliac fossa where it is exacerbated by movement, coughing or sneezing. There may be a history of one or two episodes of loose stools. The vomiting occurs once the abdominal pain has been noticed. Vomiting preceding the pain should raise suspicion of the symptoms being due to gastroenteritis. The frequencies with which these occur is illustrated in table 1.

On physical examination, the patient may appear slightly dehydrated and in pain. A low grade pyrexia with an accompanying tachycardia might be noted. Tenderness is elicited on palpation of the right lower abdomen. Signs of localised peritonism include guarding and rebound tenderness. Other signs that have been described are a characteristic oral fetor and facial expression (Terry, 1983). Occasionally, there might be an increased urinary frequency and urinalysis may demonstrate the presence of white blood cells in the urine (Puskar, 1995).

The signs and symptoms of the classical presentation of acute appendicitis are understood in terms of the underlying pathophysiology. The initial triggering factor is often the obstruction of the appendiceal lumen by a faecolith. This results in the accumulation of appendiceal secretions. Continued distension of the lumen stimulates the nerve endings of visceral afferent pain fibres which accounts for the initial central pain. As the distension progresses, the pressure within the appendix exceeds the venous pressure but not the arterial pressure. This results in a continued inflow of blood to the appendix but a very limited or no outflow. This leads to engorgement and vascular congestion and distension of this magnitude triggers a reflex nausea and vomiting. This distension exacerbates the diffuse visceral abdominal pain. Bacterial overgrowth occurs and an inflammatory reaction is triggered which spreads across the mucosa of the appendix through to the serosa and the overlying peritoneum. This is perceived by the patient as the initial central abdominal pain migrating to the right lower abdomen.

The clinical presentation can vary with the position of the appendix (Ahmed, 2007). An inflamed appendix lying in the pelvis can sometimes irritate the rectum causing loose stools. If the inflamed appendix comes in contact with the right ureter or bladder, it causes a localised inflammatory response which can result in a urinalysis positive for white cells and sometimes blood (Puskar, 1995). Irritation of the bladder by the inflamed appendix can result in an increased urinary frequency. Classically, the point of maximal tenderness is described as being at McBurney’s point but this is very variable (Karim, 1990).

Sign or Symptom	Frequency (%)
Abdominal pain	99 – 100
Right lower quadrant pain/tenderness	96
Anorexia	24 – 99
Nausea	62 – 90
Low grade pyrexia	67 – 69
Vomiting	32 – 75
Migration of pain to right iliac fossa	50
Rebound tenderness	26
Right lower quadrant guarding	21

Table 1. The frequencies with which the ‘classical signs’ present in acute appendicitis (Old et al, 2005)

#### 4. Anatomical variations of the vermiform appendix

Clinicians involved in the assessment of patients suspected of having acute appendicitis should be familiar with the variations that can occur in the anatomy of the appendix. The variable position of the appendix is attributed to developmental processes (Schumpelick, 2000; Devlin, 1971). The structure that develops into the caecum and appendix is called the caecal diverticulum or the 'bud of the caecum'. This structure lies in the distal segment of the umbilical loop. The appendix appears as a distinct structure and becomes visible only in the eighth week of gestation. The embryonic gut undergoes rotations that bring the duodenal curve to its classic "C" shape and a rotation that brings the early caecum to the right. The caecum descends into the right iliac fossa as described below.

As a result of these morphological movements, the caecal diverticulum comes to occupy a region in the right half of the abdominal cavity. This is in close apposition to the liver. The liver in the developing fetus takes up a large proportion of the abdominal cavity. During subsequent development, the liver migrates cranially and separates from the caecum and appendix. The intervening bowel elongates to form the ascending colon. The appendix along with the caecum is pushed downwards and occupies the right lower quadrant. At this stage, the position of the appendix is determined by chance (Kozar, 1999). During the post partum period, the caecum grows in the lateral direction which results in the vermiform appendix being displaced medially. This movement of the appendix in the medial direction and its acquisition of a position that borders the caecum is believed to play a major role in placing the appendix in a retrocolic position, especially in later life (Herrinton, 1991).

Results of studies in humans looking at the relative frequencies with which the appendix occupies various anatomical positions demonstrate considerable variability (Nayak, 2010). Given the complexity of the underlying embryological processes this finding should not be surprising. In a post mortem study of ten thousand cases, Wakeley (1933) found the retrocaecal position to be the most common. Given our current understanding of the embryological processes this is to be expected. However, several other studies indicate that there might be other factors involved and that the final position of the appendix is not the result of purely embryological development as suggested by Wakeley.

Most authors follow the variations described by Sir Frederick Treaves but alternative descriptions have been suggested (Sahana's Human Anatomy, 1994). In his paper, Treaves considers the caecum to be analogous to the dial of a clock and the appendix as the hour arm. Therefore, the positions of the appendix are described as in Figure 1.

- 11 O'clock position or para colic or para caecal. The appendix is directed upwards and lies to the right side of the caecum in close apposition. In this position, the appendix can even lie in front of the right kidney. In this position, a long appendix can irritate the ureter resulting in leucocytes detected on urinalysis or may even mimic the presentation of pyelonephritis (Jones, 1988).
- 12 O'clock position or retro caecal. The appendix lies behind the caecum or the ascending colon and may be intraperitoneal or lie behind the peritoneum.
- 2 O'clock position or splenic. The appendix lies directed towards the spleen or towards the left upper quadrant and may lie in front of the terminal ileum (pre-ileal) or behind the terminal ileum (post-ileal).
- 3 O'clock position or promonteric. The appendix is directed transversely in a medial direction towards the sacral promontory.

- 4 O'clock position or pelvic. The appendix hangs just at the brim of the pelvis and projects into the pelvic cavity. This position is of clinical importance as the tip of the appendix lies on the psoas muscle. Irritation of the psoas muscle by an inflamed appendix on flexion of the hip is the basis of the 'psoas test' (Sharma, 2005, Smith, 1965).
- 6 O'clock or midinguinal. The appendix passes inferiorly towards the midpoint of the inguinal ligament. This is also referred to as the sub-caecal position. In this position, the appendix lies in the iliac fossa, separated from the iliacus muscle only by the intervening peritoneum. This is of clinical importance as an inflamed appendix in this position can irritate the iliacus muscle which would be indicated by worsening pain when the right hip is flexed (Smith, 1965).

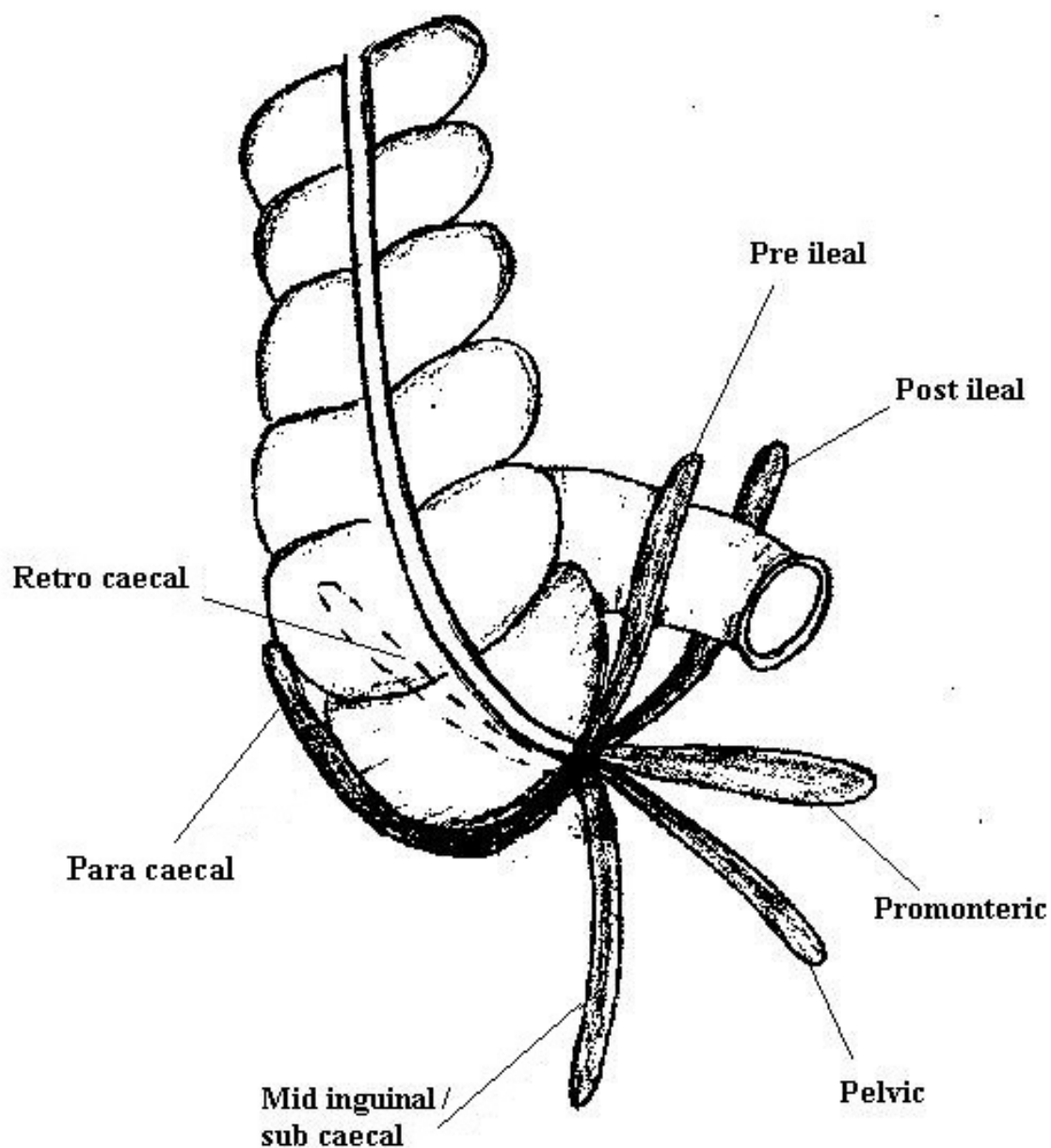


Fig. 1. A diagrammatic representation of the different positions of the appendix as described by Treaves

Based on his analysis of ten thousand cases, Wakeley (1933) also noted the presence of ectopic appendices. These are rare and accounted for only five cases out of the ten thousand. Of these five, two were found to be pre-hepatic in position. Another two were noted to be with the caecum in the umbilical region just below the stomach and transverse colon. The remaining one was in the left side of the abdomen and was the result of a complete transposition of the abdominal viscera.

The results from various studies summarising their results on the different positions of the vermiform appendix are given in table 2.

In addition to the considerable variability of the eventual position of the appendix, various authors have also noted that there is a corresponding heterogeneity in the length of the appendix as well (Alzaraa, 2009). In a classic study by Collins (1932) of 4680 specimens, the length was found to vary from 0.3 cm to 24.5 cm with around 61% of the specimens having a length between 6 cm and 9 cm. The length of the appendix is just as important as its position in influencing the clinical presentation of acute appendicitis. This is because, a long appendix in the paracolic position can abut the right kidney and sometimes even the duodenum giving the clinical impression of cholecystitis or a pathology related to the duodenum (Hsu, 2011). Likewise, an inflamed pelvic appendix which extends deep enough into the pelvis can irritate the rectum causing the loose stool which is sometimes observed in acute appendicitis (Codon & Telford, 1991). These kind of symptoms that appear to localise in areas far removed from the ‘traditional’ or ‘classical’ position of the appendix can mislead the clinician who is not aware of the anatomical variations.

Authors	Year	Country	Number	Retro caecal	Pelvic	Para caecal	Pre ileal	Post ileal
Liertz	1909	Germany	2092	35.0	42.1	9.0	13.9	
Smith	1911	USA	882	24.2	19.4	2.9	50.9	
Ajmani & Ajmani	1983	India	100	58.0	23.0	7.0	2.0	10.0
Ojeifo	1989	Nigeria	548	44.5	25.0	8.7	1.8	1.6
Wakeley	1933	UK	10,000	65.3	31.0	12.3	1.4	
Peterson	1934	Finland	373	31.0	42.2	0.0	26.8	
Shah & Shah	1945	India	405	61.2	3.7	5.4	26.9	
Waas	1960	South Africa	103	26.7	58.0	5.0	28.0	
Solanke	1970	Nigeria	203	38.4	31.2	11.2	29.2	
Bakheit & Warille	1996	Sudan	60	58.3	21.7	11.7	11.7	
Delic	2002	Croatia	50	52.0	32.0	8.0	10.0	

Table 2. The above table shows the relative frequencies (%) of the different positions of the appendix (see Old et al, 2005)

The results of various studies that have reported on the length of the vermiform appendix are summarised below (table 3). Although most anatomical studies of the appendix were done several decades ago, their results are still relevant today as it is the knowledge gained from such studies that guides our diagnostic reasoning to a very large extent.

Author	Shortest	Longest	Average
Monks & Blake	1.0	24.0	7.9
Deaver	1.0	23.0	8.9
Lewis	2.0	20.0	8.3
Robinson	1.8	23.0	9.2
Royster	2.5	29.4	7.5
Hafferl	2.5	20.0	9.0
Solanke	4.0	20.0	9.6

Table 3. Lengths of the appendix (in cm) (Thyagaraj, 2005)

5. The pathophysiological mechanisms of acute appendicitis

It is widely believed that acute appendicitis is the result of an obstruction of the appendiceal lumen, usually by a faecolith (Larner, 1988) but some have found a faecolith only in a minority of cases of acute appendicitis (Chang, 1981). Furthermore, faecoliths need not always cause appendicitis since they have been demonstrated to be present in the appendix in the absence of any inflammation (Fraser, 2004). Obstruction can also be the result of lymphoid hyperplasia (Humes, 2007; Walker, 1990), or rarely caecal tumours can obstruct the lumen (Sieren, 2010). A number of authors find little convincing evidence that appendiceal obstruction is the principle cause of acute appendicitis (Carr, 2000; Andreou, 1990). In a small series by Horton (1997) the lumen was empty in 25% of 44 cases and faecoliths were only found in 9% and in the rest, only purulent material or soft faeces were found within the lumen of the appendix. Other important possible factors include: the role of infection, hygiene, genetics and diet.

Interestingly Chang found lymphoid hyperplasia to be more common in non inflamed appendices and he estimated it to occur in only 6% of cases of acute appendicitis (Chang, 1981). Experimental work by Arnbjornsson and Bengmark (1983, 1984) provided evidence for an etiology other than just luminal obstruction. In their study, the pressure within the lumen of the appendix was measured with a U-tube manometer. Their results showed that there was no increase in intraluminal pressure in 19 out of the 21 cases of phlegmonous appendicitis. The other two cases of phlegmonous appendicitis along with all six cases of gangrenous appendicitis however, had intraluminal pressures of over 20 cm saline. No increase in intraluminal pressure was noted in the normal appendices. The results of this study are not consistent with luminal obstruction as a major cause of acute appendicitis. The finding of increased intraluminal pressure in the gangrenous appendices suggests that increases in pressures within the appendiceal lumen might be a late change and could result from an inflammatory process.

There has been much speculation about the cause of the early mucosal ulceration seen in acute appendicitis. A study by Sisson et al (1971) demonstrated that mucosal ulceration happens before any distension of the appendix. Moreover, it has been observed in several studies that cases of acute appendicitis tend to cluster in manner that is suggestive of a transmissible infective agent (Anderson, 1995). Such investigations led to the idea of the mucosal ulceration being the result of a viral infection which is then followed by a secondary bacterial infection which aides the perpetuation of the inflammatory response. Various infectious agents have been implicated in the etiology of acute appendicitis (Lamps, 2010). This theory would to a certain degree explain the seasonal variations of the incidence of acute appendicitis reported by some (Sulu, 2010). Periods of high incidence might be

because certain associated gut infections are more common during these periods. While there is substantial evidence demonstrating the role played by different infectious agents in the pathogenesis of acute appendicitis, the effects of season, altitude and temperature are yet to be conclusively established.

Closely connected with the role of a possible infectious etiology of acute appendicitis is the 'hygiene hypothesis' which also proposes that enteric infections during childhood and early adulthood trigger acute appendicitis (Raynor, 2010). The appeal of this hypothesis is that it provides an explanation for certain epidemiological characteristics of appendicitis. The epidemiology of acute appendicitis shows a rising incidence accompanies increasing industrialisation (Barker et al, 1988). This is believed to be because as increasing industrialisation and improved socio-economic conditions arise there is a concomitant improvement in hygiene. This in turn leads to a reduced immunity in adult life as infections rates during childhood decrease. This decreased resistance predisposes to appendicitis. The theory remains controversial (Coggon et al, 1991).

The observation that the incidence of acute appendicitis is a lot less common in developing countries compared to the Western world led to the suggestion that diet may play an important role in the etiology (Burkitt 1971). The initial suggestion was that a diet relatively low in fibre and high in unrefined food predisposed to the development of acute appendicitis (Larner, 1988). This was inferred primarily from the observation that there was a decrease in the incidence of acute appendicitis during the second world war when there was an increase in the use of high fibre and unrefined food (Burkitt, 1971). There has however, been evidence to suggest the contrary as the decrease in incidence of acute appendicitis in the United States and Western Europe in the last few decades has not been associated with any significant alteration in diet (Larner, 1988). Moreover, studies in South Africa demonstrate a lower incidence of acute appendicitis among the urban black population despite their diet being relatively low in fibre (Walker & Segal, 1995). High fibre diets decrease the stool transit times and also have the effect of reducing faecal viscosity. This impairs the formation of faecoliths and could therefore provide a theoretical basis for the association with appendicitis (Burkitt et al, 1972). Epidemiological studies have suggested a protective role for green vegetables and tomatoes which might be partly due to alterations in the gut flora (Barker et al, 1986). It is possible that diet works in conjunction with other predisposing factors and exerts a modulatory role.

Vascular compromise is a factor that might play a role in triggering acute appendicitis. Histological examinations of certain appendicectomy specimens have noted an association between an obstructed blood supply and morphological changes resembling that of ischaemic colitis (Carr, 2000). The role of vascular compromise in the pathogenesis of acute appendicitis is also illustrated by the fact that appendicitis appears to progress more rapidly to perforation in patients with sickle cell anaemia (Al Salem et al 1998). It has been suggested that this is due to the ischaemia that results when the blood vessels get blocked by the sickled red blood cells. Abdominal trauma has also been seen to result in acute appendicitis (Toumi et al, 2010). This is believed to be mediated by processes that result in the obstruction of the appendiceal lumen. However, it must also be noted that bruising, edema and rupture of the mesoappendix are very often seen with these cases and can occur without any luminal obstruction. The result would be compromise to the vascular supply of the appendix which would then promote bacterial invasion of the appendiceal wall and subsequent inflammation.

Some authors have suggested a genetic component in the pathogenesis of acute appendicitis (Azodi et al, 2009). It has been suggested that certain individuals could be more susceptible to developing appendicitis. Some studies demonstrate differences in the incidence of acute appendicitis between different races and also on the observation of a familial tendency (Hiraiwa et al, 1995). Some studies report that for individuals with a close family member who has had appendicitis, their likelihood of developing the condition is higher than average (Ergul, 2007). While it is possible that genetic factors play a role in determining an individual's response to inflammation and other pathogenic factors such as bacteria, it is very difficult to isolate the effects of genetics from that of the environment.

Rare causes of obstruction include foreign bodies with the following reported: nails, pins, screws, shot gun pellets, condoms and teeth (Klinger et al, 1997). Barium has been implicated in appendicitis following its use for investigation for other bowel pathology (Fang et al, 2009). 'Barium appendicitis' is more common in children as they tend to retain the barium for longer periods than adults.

## 6. The role of imaging

Studies have demonstrated that history and examination alone has an accuracy for diagnosis of between 78 to 92 percent in males and between 58 to 85 percent in females (Birnbbaum & Wilson, 2000). Imaging has improved diagnostic accuracy to over 95% (Old, 2005). Imaging should be interpreted in conjunction with the history, clinical examination and blood test results.

### 6.1 Plain radiography

The use of plain radiography is generally not indicated when appendicitis is suspected unless there is clinical evidence to suspect a co-existing pathology such as an obstruction or perforation. Plain radiography is not cost effective and can be misleading (Rao et al, 1999). An incidental finding of faecal loading in the right hemicolon might mistakenly be labelled as the cause of the right iliac fossa pain. Faecoliths are visible on plain radiography in less than 5% of cases of appendicitis (Rao et al, 1999). Therefore, the routine use of abdominal films is not indicated as part of the initial assessment.

### 6.2 Ultrasonography (USS)

Diagnostic accuracy with ultrasonography in identifying an inflamed appendix varies between 71% and 97% (Rao et al, 1998a, Wilson et al, 2001). This large variation is due in part to the operator dependency of this imaging modality. While the biggest advantage of ultrasonography is the absence of any ionising radiation, its use is limited by the requirement for well trained staff out of normal working hours. Importantly, ultrasound can identify other causes of right iliac fossa pain such as ovarian cysts, ectopic pregnancies and tubo-ovarian abscesses. USS is also ideal for assessment during pregnancy.

The features suggesting a diagnosis of acute appendicitis on ultrasonography are well established and when observed, are very reliable (Puylaert, 1986). One highly suggestive feature is the presence of a distended appendix with an outer diameter of 6 mm or greater when viewed in the cross sectional plane (Kessler et al, 2004). Other features include evidence of inflammatory changes in the vicinity of the appendix especially in the surrounding fat. Ultrasonography can also be used to identify a perforated appendicitis with evidence of a loculated fluid collection around the caecum, prominent pericaecal fat or

the presence of an abscess. Loss of the submucosal layer in a circumferential manner apparent on ultrasonography has also been associated with a perforated appendicitis. The presence of a phlegmon is identified as an ill defined structure very closely apposed to the appendiceal wall (Rumack et al, 1998).

The pressure exerted by the transducer can cause discomfort for the patient (Wise et al, 2001). Visualisation of the appendix can be limited by a variety of factors which include a co-existent ileus or in the obese (Fefferman et al, 2001). Bowel gas in the overlying dilated small bowel loops can cast an ultrasonographic shadow which can obscure the appendix. Also, if the appendix occupies a retrocaecal position, it can be difficult to identify. Inflammatory bowel disease, caecal diverticulitis, pelvic inflammatory disease and endometriosis can not only mimic the clinical presentation of acute appendicitis but also its ultrasonographical findings.

### 6.3 Computed Tomography (CT)

CT has an accuracy between 93% and 98% (Rao et al, 1998b) which is superior to that of ultrasonography in cases of suspected acute appendicitis (Terasawa et al, 2004). There has been a shift towards the use of CT in clinical practice with ultrasonography usually being reserved for cases where exposure to ionising radiation is contra indicated. The success of CT is due largely to its ability to visualise the appendix (Friedland & Siegel, 1997). An inflamed appendix usually appears to be larger than 6 mm in diameter and there will also tend to be evidence of inflammatory changes in the surrounding tissues (Choi et al, 2003; Haaga et al, 2003). These changes include the presence of a phlegmon, inflammatory fat stranding, free fluid, abscess formation and in the case of a perforated appendicitis even the presence of small amounts of free air (Haaga et al, 2003). CT also has the advantage of being able to detect other pathologies, for instance, luminal obstruction leading to acute appendicitis due to a caecal malignancy should be identifiable on computed tomography. Also, any associated adenopathy or metastasis could be detected as well. Figure 2 is a computed tomography scan that demonstrates acute appendicitis.

The main disadvantage of CT is that it involves ionising radiation and its use in children has to be weighed against the potential risks. Cost is also an issue however, at present the cost of a CT scan is less than the costs associated with performing a negative laparotomy or diagnostic laparoscopy. Another disadvantage of using computed tomography scans is the need for administering a contrast agent to which there may be a reaction. The administration of rectal contrast is also associated with patient discomfort. The presence of intra abdominal fat can be used as a contrast agent and therefore even very subtle inflammatory changes can be detected.. One factor that might lead to a diagnosis of acute appendicitis being missed on a CT scan is the lack of intra abdominal fat. This is usually encountered in children and very slim patients (Levine et al, 2005). In such cases an ultrasonography scan would seem to be more beneficial.

### 6.4 Magnetic Resonance Imaging (MRI)

There are no large studies conclusively demonstrating a superiority for MRI over other imaging modalities (Rothrock & Pagane, 2000). A recent study by Pedrosa et al (2009) studied 148 pregnant patients with suspected acute appendicitis. Their results showed that the use of magnetic resonance imaging did lower the incidence of negative laparotomies and perforation rates and thereby suggested a potential benefit. MRI however, is time consuming and its cost effectiveness is yet to be evaluated.

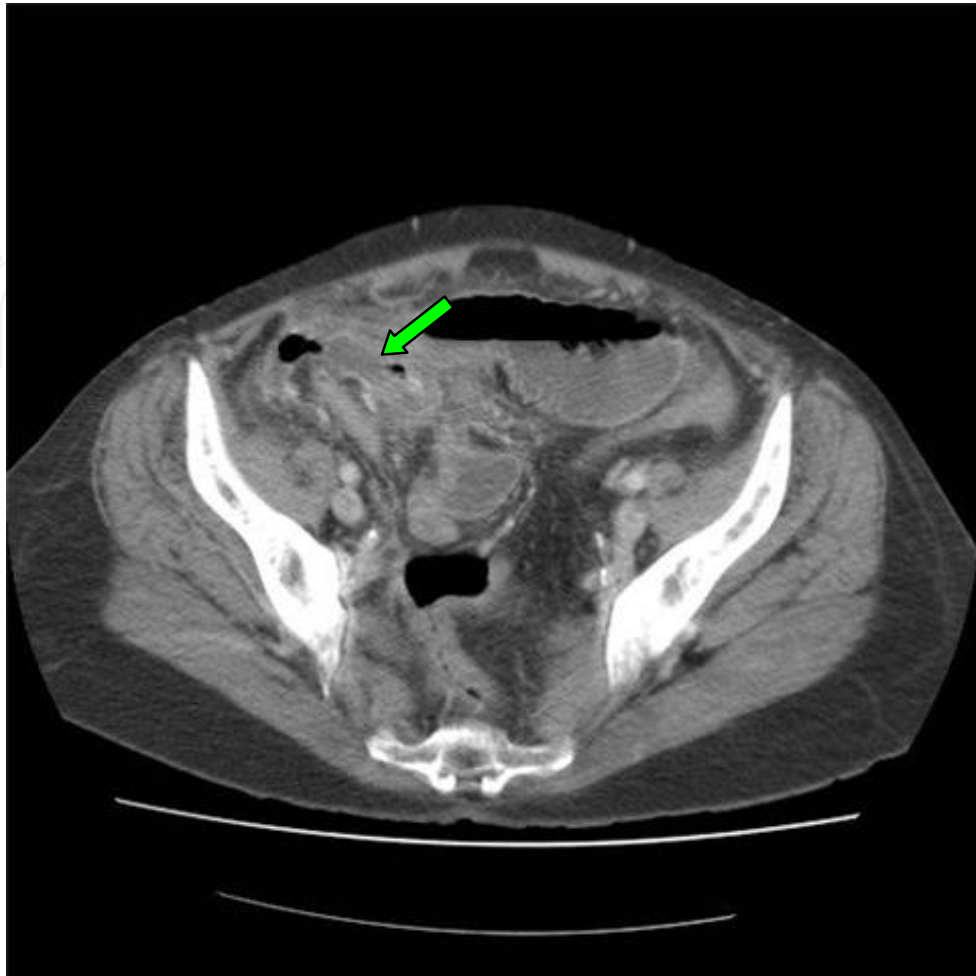


Fig. 2. A computed tomography scan of a patient with acute appendicitis. The arrow illustrates the position of the appendix.

## 7. The role of blood tests

Numerous studies have looked at the role of blood tests such as the serum levels of certain inflammatory markers like the white cell count and the C-reactive protein level (Andersson, 2004). From a pathophysiological point of view one would expect the serum levels of these inflammatory markers to rise in a patient with acute appendicitis. This indeed is the case in the majority of cases and has been confirmed in various studies (Sack et al, 2006; Beltran et al, 2007). A study by Dueholm et al (1989) which looked at patients between the ages of 15 and 45 reported that the patients with acute appendicitis had higher white cell counts than those who did not have appendicitis. It must be noted that taken on their own, the elevated values of these inflammatory markers have a poor predictive value for acute appendicitis (Beltran, 2007). There are also contradictory reports on the value of the white cell count as a marker of severity of the disease (Sasso et al, 1970; Vermeulen et al, 1995)). The value of these inflammatory markers is appreciated only when they are interpreted together and not in isolation. Studies have demonstrated that elevated levels of the white cell count and the C-reactive protein together improve the predictive value (Andersson, 2004; Peitola et al, 1986).

The converse however which is if the patient does not have elevated serum levels of the relevant inflammatory markers then they are unlikely to have acute appendicitis needs to be interpreted with caution. While there are studies that suggest the absence of raised inflammatory markers indicates a low likelihood of acute appendicitis (Sengupta, 2009), one must be wary when encountering a patient with a suggestive history but normal blood tests. There are reports in the literature suggesting that 21% to 65% of patients with acute appendicitis have a normal white cell count (Merlin et al, 2010).

Similar results have been demonstrated for the serum levels of the C-reactive protein (Old, 2011). Studies indicate that it is a poor predictor of acute appendicitis when looked at in isolation but in conjunction with the white cell count it increases the likelihood ratio considerably (Visser & Lennarz, 2010). Other studies have also indicated that normal levels of the white cell count, C-reactive protein and the neutrophil count have a high negative predictive value (Dueholm et al, 1989). One reason for the varying results between studies could be the heterogeneity of the sample population. Factors known to influence the levels of these inflammatory markers include the patient's age and the duration of symptoms (Paajanen et al, 1997). The temporal relation that the serum levels of the inflammatory markers bear with the onset of symptoms is that the white cell count appears to rise early on in acute appendicitis with the C-reactive protein levels following later on. Persistently rising or high C-reactive levels could indicate the possibility of an appendiceal perforation (Chung et al, 1996, Sanjuan et al, 1999). This temporal relation does not seem to be so clear cut in children and therefore making a diagnosis in children poses additional problems (Kharbanda et al, 2011).

As always, it should be emphasised that blood tests alone cannot be used to diagnose acute appendicitis and therefore what should be employed is a holistic approach which takes into account the patients history and also the results of any other investigations.

## 8. Appendicitis scoring systems

The need to collate information obtained from the patients history, clinical examination and investigation results, which should then be interpreted as a coherent whole when assessing a patient with suspected appendicitis, has been recognised by many investigators (Zimmermann, 2008). Attempts to simplify the process and quantify the likelihood of a positive diagnosis for acute appendicitis led to the development of various scoring systems. All these systems allocate particular numerical values to a feature. These are then added to give a final number which should give the clinician an idea of the likelihood of the patient having acute appendicitis. The most commonly used in clinical practice is the Alvarado score or the MANTRELS (Migratory pain, Anorexia, Nausea/vomiting, Tenderness in right iliac fossa, Rebound tenderness, Elevated temperature, Leucocytosis shift to the left) score (Alvarado, 1986). The scoring system is illustrated in table 4. Currently there are many variants of the Alvarado score, specifically modified to address certain groups of patients like children (Macklin et al, 1997). It must be noted that none of these modified scoring systems have demonstrated an increased accuracy in diagnosing acute appendicitis.

A multicentre prospective study conducted by Ohmann et al (1995) looked at 1254 patients with acute abdominal pain and assessed various appendicitis scoring systems such as the Alvarado score, the Lindberg score, the Fenyo score and the Christian score against certain pre-set criteria. The pre-set standardised criteria included a negative laparotomy rate of 15% or less, a potential perforation rate of 35% or less, an initial missed perforation rate of 15% or

less and a missed appendicitis rate of 5% or less. The results of this study indicated that there were marked differences between the different scoring systems and that none of them satisfied the standardised criteria. However, when the published data was evaluated, many of the scoring systems demonstrated better agreement with the standardised criteria. The authors conclude that the original published data is ‘optimistically biased’ and that further large scale studies are required to validate these scoring systems.

Symptoms	Score
Migratory right iliac fossa pain	1
Nausea/vomiting	1
Anorexia	1
Signs	
Tenderness in right iliac fossa	2
Rebound tenderness in right iliac fossa	1
Pyrexia	1
Blood Test Results	
Elevated white cell count	2
Shift to the left of neutrophils	1
TOTAL	10

Table 4. The Alvarado score (Alvarado, 1986; Malik et al, 2000)

A more recent study by Horzic et al (2005) looked at the value of appendicitis scoring systems in diagnosing acute appendicitis in women. This study involved 126 female patients admitted with abdominal pain and looked at the Alvarado score, the Ohmann score and the Eskelinen score. This study too gave variable results in terms of accuracy but did report that the scoring systems, when used in conjunction with each other can be used to determine whether the patient would require surgery immediately or if observation would suffice initially. This potentially has the advantage of avoiding delays in operation and further investigations. It must be noted that the relatively small number of patients in this study does mean that further studies are required before such a strategy is adopted in clinical practice.

While clinical scoring systems appear to be useful adjuncts in diagnosing acute appendicitis, one should always bear in mind the variable diagnostic accuracy for each scoring system and therefore the limitations associated with them. As with all investigations, the different scoring systems should only play an ancillary role in the diagnosis. Clinical decisions should not be made solely on the basis of the value obtained on the application of a single scoring system.

9. Appendicitis at the extremes of age

While a diagnosis of acute appendicitis is considered rare in the elderly population, it is still common enough to be included in the differential diagnosis in an elderly patient presenting with an acute abdomen. It is estimated that 7% of elderly patients with acute abdominal pain have acute appendicitis (Doria et al 2006; Vissers & Lennarz, 2010). The diagnosis of acute appendicitis in the elderly population is particularly difficult as the clinical picture is often complicated by comorbidities. These include conditions which can mask or suppress

the normal inflammatory reaction, such as diabetes or immunosuppression (Binderow & Shaked, 1991; Tsai et al, 2008). In such cases, the symptoms tend to be rather non specific. The damped inflammatory reaction demonstrated by certain elderly patients often complicates the clinical picture as palpation of the abdomen may not elicit marked tenderness or signs of peritonism.

The physical examination can be complicated, and for the unwary clinician even misleading at times, by the fact that many elderly patients have a weak abdominal musculature. This would mean that the expected signs of rigidity and guarding in a patient with peritonitis may not be present. It should also be noted that the rates of perforation are much higher in the elderly population and so many of the patients can also present with diffuse abdominal tenderness and peritonism (Korner et al, 1997; Hiu et al, 2002). The differential diagnosis for elderly patients presenting with abdominal pain is much broader and therefore when such a patient presents, especially with a non specific history, a computed tomography scan is the imaging modality of choice (Paranjape et al, 2007). In such circumstances, the presence of any other pathology can be assessed with a computed tomography scan and the appropriate management can be planned accordingly. Also, the benefits of the scan outweigh the risks associated with exposure to ionising radiation.

Appendicitis in the very young child can pose considerable challenges. The signs and symptoms of acute appendicitis are age dependent (Blab et al, 2004). From the age of around six and over the signs and symptoms are more reliable and tend to conform to the classical presentation. In younger children, nausea and vomiting seem to be constant features. Rothrock et al (1991) report that vomiting tends to precede the abdominal pain, and very often it is the vomiting that is noticed first by parents before a history of abdominal pain. In the 2 to 5 age group, the pain tends to be more localised which is in contrast to the children of ages 2 and younger where the abdominal pain tends to be more diffuse. Localised tenderness has been reported to be present in less than 50% in this age group (Barker & Davey, 1988; Horwitz et al, 1997). Patients in this age group or even younger tend to also exhibit lethargy, abdominal distension, diarrhoea and fever. Acute appendicitis has a higher rate of perforation with subsequent diffuse peritonism in the very young patient. This is partly due to the fact that in such young patients, the omentum has not reached sufficient maturity and therefore is unable to wall off any leakage that occurs during a perforation. This leads to the enteric contents being spread throughout the abdominal cavity. Other misleading signs in the very young patient include irritability and pain or stiffness in the right hip (Daehlin, 1982; Rothrock & Pagane, 2000).

Misdiagnosing acute appendicitis in young children can result in considerable morbidity and has been the subject of numerous medicolegal investigations. An understanding of the variations that occur in the very young should alert the astute clinician to the possibility of an underlying acute appendicitis when encountering a child with non specific symptoms.

## 10. Acute appendicitis in pregnancy

The pathophysiology and presentation of acute appendicitis in the pregnant patient can be very similar to that of the non pregnant patient (Mourad et al, 2000). The appendix can be displaced upwards as the uterus enlarges and therefore it may give rise to pain and tenderness in unexpected positions. There are however, studies that report the location of pain in pregnant patients with acute appendicitis to be predominantly in the right iliac fossa

(Hodjati et al, 2003; Oto et al 2006). White cell counts can be misleading as they are raised as a consequence of the pregnancy. A delay in the diagnosis of acute appendicitis can put the fetus at risk and a ruptured appendicitis is associated with a fetal loss rate of between 20% and 25% (Kilpatrick et al, 2007). It is therefore essential to confirm the diagnosis by ultrasonography. This avoids ionising radiation but can be difficult due to the displaced anatomy. Not visualising the appendix does not rule appendicitis out and therefore the diagnosis would still be in question. In such cases the use of computed tomography would need to be considered with due consideration given to the associated risks and benefits. Magnetic resonance imaging is another possibility however, large scale studies demonstrating its accuracy in pregnant patients are lacking and therefore no definitive conclusion can be made regarding its usefulness (Blumenfeld et al, 2011).

## 11. Atypical presentations of acute appendicitis

The literature detail numerous atypical presentations. Akbulut et al (2010) report a case of a 21 year old lady with congenital situs inversus presenting with acute appendicitis. She had a one day history of mid epigastric pain which migrated to the left iliac fossa. Her white cell count was normal on admission although clinical examination revealed tenderness and guarding in the left iliac fossa. The diagnosis was confirmed on ultrasonography and she subsequently underwent an open appendicectomy. What is notable about this case is that the patient's history was 'classical' apart from the migration of the pain to the left iliac fossa. Given her situs inversus, the reason for her left sided migratory pain is obvious. It is worthy of note that her chest radiograph demonstrated dextrocardia and a right sided gastric bubble. In patients presenting with such histories, dextrocardia can be deduced either from plain radiographs or from the clinical examination of the cardio-respiratory system. One should bear in mind that as the vermiform appendix can end up in the left side of the abdomen as a result of midgut malrotation, dextrocardia may not always be present.

Chae et al (2007) report a case of a 49 year old lady who underwent a colonoscopy as part of a bowel screening programme. The colonoscopy was uneventful and all caecal landmarks were identified. The lady was well post procedure and discharged home the same day. She developed progressively worsening right sided abdominal pain and was seen in the outpatient department four days later. Her blood tests were within normal limits but physical examination revealed tenderness in her right iliac fossa. Appendicitis was confirmed on ultrasonography and the patient subsequently underwent an appendicectomy and was discharged 3 days later. The potential mechanisms suggested for this rare complication of colonoscopy are increased intra-luminal pressure due to gas insufflation and possible displacement of faecoliths into the appendiceal lumen. The authors also suggest that ulceration of the appendiceal mucosa by the colonoscope was a possibility.

Another unusual presentation of acute appendicitis is as a small bowel obstruction with raised inflammatory markers. Harrison et al (2009) describe two elderly patients presenting with small bowel obstruction diagnosed on computed tomography scans to be due to an acute appendicitis (Figure 3). Often the inflammatory process that accompanies acute appendicitis can result in small bowel obstruction. A similar case has been reported by Assenza et al (2005) who suggested that adherence of the inflamed tip of the appendix to the posterior peritoneum across the terminal ileum resulted in bowel compression.

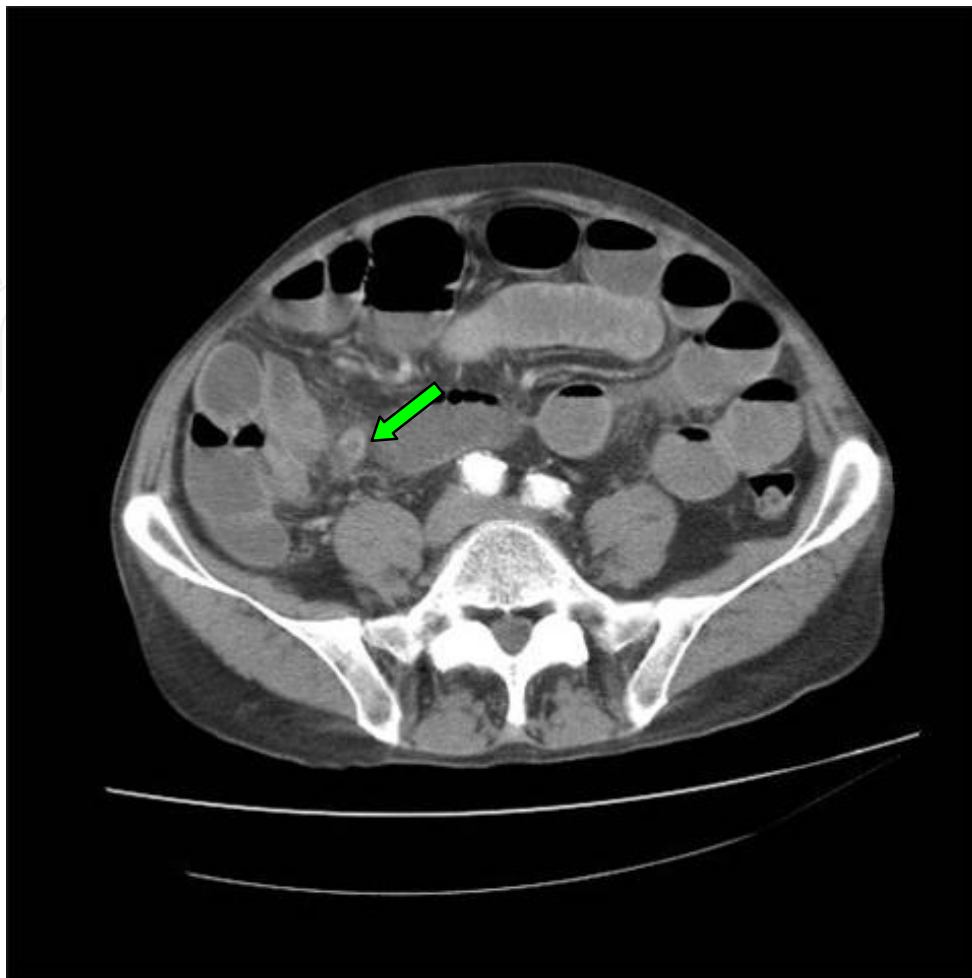


Fig. 3. A computed tomographic image illustrating an inflamed appendix (arrow) with a co-existent small bowel obstruction. (Harrison et al, 2009)

D'Ambrosio et al (2006) report a case of a 71 year old lady who presented with an inflamed tender lump on her right proximal thigh which had been progressively increasing in size over the preceding two weeks. On examination she was noted to have a tender erythematous and indurated mass near her inguinal region and laboratory investigations demonstrated a marked leucocytosis. Subsequent computed tomography demonstrated the inferior portion of the caecum to be thickened and in contact with an inflammatory mass which was contained in a femoral hernia. The patient underwent a laparotomy and right hemicolectomy. The appendix was found to be perforated and abscess formation was also noted and drained at surgery. While inflamed appendices within a hernia is rare, it should be noted that the perforation of the appendix into a limited space prevents the spillage of enteric contents into the abdominal cavity. In this case the perforated appendix was contained within the femoral hernia and so rather than developing diffuse peritonitis, the patient developed superficial signs of erythema, tenderness and induration.

## 12. Conclusion

Diagnosing appendicitis can pose considerable challenges even to the experienced clinician. A delayed or missed diagnosis can have complications which can result in morbidity and

medicolegal claims. To minimise the risks of missing the diagnosis, it is important for clinicians involved in the initial assessment of patients to have a good understanding of factors that can influence the clinical presentation. The clinician should be aware of atypical presentations especially at extremes of age and in pregnancy. No single test nor a combination of tests can distinguish all cases of acute appendicitis from other conditions. An awareness of the limitations of imaging, blood tests and scoring systems is essential. A thorough history and repeated clinical examinations if necessary in conjunction with the results of the appropriate investigations are essential to diagnose acute appendicitis. Sometimes, in equivocal cases, a period of clinical observation is necessary. Despite the advances made in diagnostic modalities, patience may prove to be the most valuable. Often, time and expert clinical review are key to successfully diagnosing acute appendicitis.

### 13. Acknowledgements

The authors would like to thank Mrs Sindhu Harrison for her help with the artwork for this article.

### 14. References

- Ahmed I, Asgeirsson KS, Beckingham IJ et al (2007). The position of the vermiform appendix at laparoscopy. *Surgical and Radiological Anatomy*, 29(2):165-8.
- Akbulut S, Ulku A, Senol A et al (2010). Left-sided appendicitis: review of 95 published cases and a case report. *World Journal of Gastroenterology*, 16(44):5598-602
- Al-Salem AH, Qureshi ZS, Qaisarudin S et al (1998). Is acute appendicitis different in patients with sickle cell disease? *Pediatric Surgery International*, 13(4):265-7
- Alloo J, Gerstle T, Shilyansky J et al (2004). Appendicitis in children less than 3 years of age: a 28 year review. *Paediatric Surgery International*, 19:777-779
- Alvarado A (1986). A practical score for the early diagnosis of acute appendicitis. *Annals of Emergency Medicine*, 15:557-564
- Alzaraa A, Chaudhry S (2009). An unusually long appendix in a child: a case report. *Cases Journal*, 11;2:7398.
- Andersson R, Hugander A, Thulin A et al (1995). Clusters of acute appendicitis. Further evidence of an infectious aetiology. *International Journal of Epidemiology*, 24:829-833
- Andersson RE (2004). Meta-analysis of the clinical and laboratory diagnosis of appendicitis. *British Journal of Surgery*, 91(1):28-37
- Andreou P, Blain S, du Boulay EH (1990). A histopathological study of the appendix at autopsy and after surgical resection. *Histopathology*, 17:427-431
- Arnbjornsson E, Bengmark S (1983). Obstruction of the appendix lumen in relation to pathogenesis of acute appendicitis. *Acta Chirurgica Scandinavica*, 149:789-791
- Arnbjornsson E, Bengmark S (1984). Role of obstruction in the pathogenesis of acute appendicitis. *American Journal of Surgery*, 147:390-392
- Assenza M, Ricci G, Bartolucci P (2005). Mechanical small bowel obstruction due to an inflamed appendix wrapping around the last loop of ileum. *Giornale di Chirurgia*, 26(6-7):261-6.
- Azodi SO, Sandberg AA, Larsson H (2009). Genetic and environmental influences on the risk of acute appendicitis in twins. *British Journal of Surgery*, 96(11):1336-40

- Barker AP, Davey RB (1988). Appendicitis in the first three years of life. *Australian and New Zealand Journal of Surgery*, 58:491-494
- Barker JP, Morris J, Nelson M (1986). Vegetable consumption and acute appendicitis in 59 areas in England and Wales. *British Medical Journal*, 292:927-930
- Beltrán MA, Almonacid J, Vicencio A et al (2007). Predictive value of white blood cell count and C-reactive protein in children with appendicitis. *Journal of Paediatric Surgery*, 42(7):1208-1214
- Binderow SR, Shaked AA (1991). Acute appendicitis in patients with AIDS/HIV infection. *American Journal of Surgery*, 162(1):9-12.
- Birnbaum BA, Wilson SR (2000). Appendicitis at the Millennium. *Radiology*, 215:337-48
- Blab E, Kohlhuber U, Tillawi S et al (2004). Advancements in the diagnosis of acute appendicitis in children and adolescents. *European Journal of Paediatric Surgery*, 14:404-409
- Blumenfeld YJ, Wong AE, Jafari A et al (2011). MR imaging in cases of antenatal suspected appendicitis--a meta-analysis. *Journal of Maternal, Fetal and Neonatal Medicine*, 24(3):485-8.
- Burkitt DP (1971). The etiology of appendicitis. *British Journal of Surgery*, 58:695-699
- Burkitt DP, Walker RP, Painter NS (1972). Effect of dietary fibre on stools and transit times, and its role in the causation of disease. *Lancet*, 2:1408-1412
- Carr NJ (2000). The pathology of acute appendicitis. *Annals of Diagnostic Pathology*, 4(1):46-58
- Chae HS, Jeon SY, Nam WS (2007). Acute appendicitis caused by colonoscopy. *Korean Journal of Internal Medicine*, 22(4):308-11
- Chang AR (1981). An analysis of the pathology of 3003 appendices. *Australian and New Zealand Journal of Surgery*, 51:169-178
- Choi D, Park H, Lee YR et al (2003). The most useful findings for diagnosing acute appendicitis on contrast enhanced helical CT. *Acta Radiologica*, 44:574-82
- Chung CH, Ng CP, Lai KK (2000). Delays by patients, emergency physicians and surgeons in the management of acute appendicitis: retrospective study. *Hong Kong Medical Journal*, 6:254-259
- Chung JL, Kong MS, Lin SL et al (1996). Diagnostic value of C-reactive protein in children with perforated appendicitis. *European Journal of Paediatrics*, 155:529-531
- Codon RE, Telford GL (1991). Appendicitis; In: Townsend CM (eds). *Sabiston Text book of Surgery: The biological basis of modern surgical practice*. 14<sup>th</sup> ed, Philadelphia, Pa:WB Saunders and Co; pp 884-898
- Coggon D, Barker JP, Cruddas et al (1991). Housing and appendicitis in Anglesey. *Journal of Epidemiology and Community Health*, 45:244-246
- Collins DC (1932). The Length and Position of the Vermiform Appendix: A Study of 4,680 Specimens. *Annals of Surgery*, 96(6):1044-8
- Daehlin L (1982). Acute appendicitis during the first three years of life. *Acta Chirurgica Scandinavica*, 148:291-294
- D'Ambrosio N, Katz D, Hines J (2006). Perforated appendix within a femoral hernia. *AJR American Journal of Roentgenology*, 186(3):906-7
- Devlin B (1971). Midgut malrotation causing intestinal obstruction. *Annals of the Royal College of Surgeons of England*, 48:227-237

- Doria AS, Moineddin R, Kellenberger CJ et al (2006). US or CT for diagnosis of appendicitis in children and adults? A meta analysis. *Radiology*, 241:83-94
- Dueholm S, Bagi P, Bud M (1989). Laboratory aid in the diagnosis of acute appendicitis. A blinded, prospective trial concerning diagnostic value of leukocyte count, neutrophil differential count, and C-reactive protein. *Diseases of the Colon and Rectum*, 32(10):855-9.
- Ergul E (2007). Heredity and familial tendency of acute appendicitis. *Scandinavian Journal of Surgery*, 96(4):290-2
- Erkasap S, Ates E, Ustuner Z et al (2000). Diagnostic value of interleukin-6 and C-reactive protein in acute appendicitis. *Swiss Surgery*.6(4):169-72
- Fang YJ, Wang HP, Ho CM et al (2009). Barium appendicitis. *Surgery*, 146(5):957-8
- Fefferman NR, Roche KJ, Pinkney LP et al (2001). Suspected appendicitis in children: focussed CT technique for evaluation. *Radiology*, 220:691-5
- Fraser N, Gannon C, Stringer MD (2004). Appendicular colic and the non-inflamed appendix: fact or fiction? *European Journal of Paediatric Surgery*, 14(1):21-4.
- Friedland JA, Siegel MJ (1997). CT appearance of acute appendicitis in childhood. *AJR American Journal of Roentgenology*, 168:439-442
- Haaga JR, Lanzieri CF, Gilkeson RC et al (2003). CT and MR imaging of the whole body. 4<sup>th</sup> edition, St Louis: Mosby: 2061
- Harrison S, Mahawar K, Brown D et al (2009). Acute appendicitis presenting as small bowel obstruction: two case reports. *Cases Journal*, Nov 28;2:9106.
- Herrinton JL (1991). The vermiform appendix: its surgical history. *Contemporary Surgery*, 39:36-44
- Hiraiwa H, Umemoto M, Take H (1995). Prevalence of appendectomy in Japanese families. *Acta Paediatrica Japan*, 37:691-693
- Hiu TT, Major KM, Avital I et al (2002). Outcome of elderly patients with appendicitis. *Archives of Surgery*, 135:479-88
- Hodjati H, Kazerooni T (2003). Location of the appendix in the gravid patient: a re-evaluation of the established concept. *International Journal of Gynaecology and Obstetrics*, 81(3):245-7
- Horton WL (1977). Pathogenesis of acute appendicitis. *British Medical Journal*, 2:1672-1673
- Horwitz JR, Gursoy M, Jaksic et al (1997). Importance of diarrhoea as a presenting symptom of appendicitis in very young children. *American Journal of Surgery*, 173:80-82
- Horzić M, Salamon A, Kopljarić M et al (2005). Analysis of scores in diagnosis of acute appendicitis in women. *Collegium Anthropologicum*, 29(1):133-8
- Hsu KF, Yu JC, Chan DC et al (2011). Atypical acute appendicitis and its complications: a rare location of the appendix in the periduodenum. *Acta Gastroenterologica Belgica*, 74(1):105
- Humes D, Speake WJ, Simpson J (2007). Appendicitis. *Clinical Evidence*, Jul 1;2007. pii: 0408
- Jones WG, Barie PS (1988). Urological manifestations of acute appendicitis. *Journal of Urology*, 139(6):1325-1328
- Karim OM, Boothroyd AE, Wyllie JH (1990). McBurney's point--fact or fiction? *Annals of the Royal College of Surgeons of England*, 72(5):304-8.

- Kessler N, Cyteval C, Gallix B et al (2004). Appendicitis: evaluation of sensitivity, specificity and predictive values of US, Doppler US and laboratory findings. *Radiology*, 230:472-8
- Kharbanda AB, Cosme Y, Liu K et al (2011). Discriminative accuracy of novel and traditional biomarkers in children with suspected appendicitis adjusted for duration of abdominal pain. *Academic Emergency Medicine*, 18(6):567-74.
- Kilpatrick CC, Monga M (2007). Approach to the acute abdomen in pregnancy. *Obstetric and Gynaecology Clinics of North America*, 34:389-402
- Klinger PJ, Smith SL, Abdenstein BJ et al (1997). Management of ingested foreign bodies within the appendix: a case report with review of the literature. *American Journal of Gastroenterology*, 92:2295-2298
- Körner H, Söndena K, Söreide JA et al (1997). Incidence of Acute Nonperforated and Perforated Appendicitis: Age-specific and Sex-specific Analysis. *World Journal of Surgery*, 21(3):313-317
- Kozar RA, Roslyn JL (1999). The appendix. In: Principles of Surgery. 7<sup>th</sup> International edition, Seymour I Schwartz, (ed); McGraw-Hill Health Profession Division, pp 1383-94
- Lamps LW (2010). Infectious causes of appendicitis. *Infectious Disease Clinics of North America*, 24(4):995-1018
- Larner AJ (1988). The etiology of appendicitis. *British Journal of Hospital Medicine*, 39:540-542
- Levine CD, Aizenstein O, Lehavi O et al (2005). Why we miss the diagnosis of appendicitis on abdominal CT: evaluation of imaging features of appendicitis incorrectly diagnosed on CT. *AJR American Journal of Roentgenology*, 184:855-859
- Macklin CP, Radcliffe GS, Merei JM et al (1997). A prospective evaluation of the modified Alvarado score for acute appendicitis in children. *Annals of the Royal College of Surgeons of England*, 79(3):203-5
- Malik KA, Khan A, Waheed I (2000). Evaluation of the Alvarado score in diagnosis of acute appendicitis. *Journal of the College of Physicians Surgeons Pakistan*, 10:392-4
- Merlin MA, Shah CN, Shiroff AM (2010). Evidence based appendicitis: The initial work up. *Postgraduate Medicine*, 122(3):189-195
- Mourad J, Elliol JP, Erikson L et al (2000). Appendicitis in pregnancy: new information that contradicts long held clinical beliefs. *American Journal of Obstetrics and Gynaecology*, 182(5):1027-0
- Nayak BS (2010). Why the tip of vermiform appendix has variable position? *Medical Hypotheses*, 75(6):682-683
- Ohmann C, Yang Q, Franke C (1995). Diagnostic scores for acute appendicitis. Abdominal Pain Study Group. *European Journal of Surgery*, 161(4):273-81
- Old J, Dusing RW, Yap W (2005). Imaging for suspected appendicitis. *American family Physician*, 71(1):71-78
- Old O (2011). C-Reactive protein estimation does not improve accuracy in the diagnosis of acute appendicitis in pediatric patients. *International Journal of Surgery*, 9(5):440
- Oto A, Srinivasan PN, Erns RD et al (2006). Revisiting MRI for appendix location during pregnancy. *AJR American Journal of Roentgenology*, 186(3):883-7

- Paajanen H, Mansikka A, Laato M et al (1997). Are serum inflammatory markers age dependent in acute appendicitis? *Journal of the American College of Surgeons*, 184:303-308
- Paajanen H, Mansikka A, Laato M et al (2002). Novel serum inflammatory markers in acute appendicitis. *Scandinavian Journal of Clinical Laboratory Investigation*, 62(8):579-84
- Paranjape C, Dalia S, Pan J, Horattas M (2007). Appendicitis in the elderly: a change in the laparoscopic era. *Surgical Endoscopy*, 21(5):777-81
- Paulson EK, Kalady MF, Pappas TN (2003). Clinical Practice. Suspected appendicitis. *New England Journal of Medicine*, 348:236-242
- Pedrosa I, Lafornera M, Pandharipande PV et al (2009). Pregnant patients suspected of having acute appendicitis: effect of MR imaging on negative laparotomy rate and appendiceal perforation rate. *Radiology*, 250(3):749-57.
- Peitola H, Ahlqvist J, Rapola J et al (1986). C reactive protein compared with white blood cell count and erythrocyte sedimentation rate in the diagnosis of acute appendicitis in children. *Acta Chirurgica Scandinavica*, 152:55-58
- Puskar D, Bedalov G, Fridrih S et al (1995). Urinalysis, ultrasound analysis, and renal dynamic scintigraphy in acute appendicitis. *Journal of Urology*, 45(1):108-112
- Puylaert JB (1986). Acute appendicitis: US evaluation using graded compression. *Radiology*, 158:355-60
- Rao PM, Boland GW (1998a). Imaging of acute right lower abdominal quadrant pain. *Clinical Radiology*, 53:639-49
- Rao PM, Rhea JT, Novelline RA et al (1998b). Effect of computed tomography of the appendix on treatment of patients and use of hospital resources. *New England Journal of Medicine*, 338:141-6
- Rao PM, Rhea JT, Rao JA et al (1999). Plain abdominal radiography in clinically suspected appendicitis: diagnostic yield, resource use and comparison with CT. *American Journal of Emergency Medicine*, 17:325-328
- Raynor MR, Cliff AD, Ord JK (2010). Common acute childhood infections and appendicitis: a historical study of statistical association in 27 English public boarding schools, 1930-1934. *Epidemiology and Infection*, 138(8):1155-65
- Rothrock SG, Skeoch G, Rush JJ et al (1991). Clinical features of misdiagnosed appendicitis in children. *Annals of Emergency Medicine*, 20:45-50
- Rumack CM, Wilson SR, Charboneau JW et al (1998). Diagnostic ultrasound. 2<sup>nd</sup> ed. St Louis: Mosby, 1998:303-6
- Rusnak RA, Borer JM, Fastow JS et al (1994). Misdiagnosis of acute appendicitis: common features discovered in cases after litigation. *American Journal of Emergency Medicine*, 12:397-402
- Sack U, Biereder B, Elouahidi T et al (2006). Diagnostic value of blood inflammatory markers for detection of acute appendicitis in children. *BMC Surgery*, 28:6:15
- Sahana's Human Anatomy, Descriptive and Applied (1994). Vol II, Ankur ed, Ankur Publications (AP), pp 362-367
- Sanjuán JC, Martín-Parra JI, Seco I et al (1999). C-reactive protein and leukocyte count in the diagnosis of acute appendicitis in children. *Diseases of the Colon and Rectum*, 42(10):1325-1329


- Sasso RD, Hanna EA, Moore DL (1970). Leucocyte and neutrophilic counts in acute appendicitis. *American Journal of Surgery*, 120(5):563-566
- Schumpelick V, Dreuw B, Ophoff K et al (2000). Appendix and caecum. Embryology, anatomy and surgical applications. *Surgical Clinics of North America*, 80:295-318
- Sengupta A, Bax G, Paterson-Brown S (2009). White cell count and C-reactive protein measurement in patients with possible appendicitis. *Annals of the Royal College of Surgeons of England*, 91(2):113-5
- Sharma SB, Gupta V, Sharma SC (2005). Acute appendicitis presenting as thigh abscess in a child: a case report..
- Sieren LM, Collins JN, Weireter LJ (2010). The incidence of benign and malignant neoplasia presenting as acute appendicitis, *The American Surgeon*, 76(8):808-11
- Simpson J, Scholefield JH (2002). Acute appendicitis. *Clinical Evidence*, 20(7):153-157
- Sisson RG, Ahlvin RC, Harlow MC (1971). Superficial mucosal ulceration and the pathogenesis of acute appendicitis. *American Journal of Surgery*, 122:378-380
- Smith PH (1965). The diagnosis of acute appendicitis. *Post Graduate Medical Journal*, 41:2-5
- Sulu B, Gunerhan Y, Palanci Y et al (2010). Epidemiological and demographic features of appendicitis and influences of several environmental factors. *Turkish Journal of Trauma & Emergency Surgery*, 16(1):38-42
- Terasawa T, Blackmore CC, Bent S et al (2004). Systematic review: computed tomography and ultrasonography to detect acute appendicitis in adults and adolescents. *Annals of Internal Medicine*, 141(7):537-46
- Terry TR, Cook AJ, Talbot A et al (1983). Facial expression in acute appendicitis. *Annals of the Royal College of Surgeons of England*, 65(1):65
- Thyagaraj J (2005). Study of the anatomical position of the appendix in normal population and inflamed cases. Accessed June 18<sup>th</sup>, 2011. Available from : <http://119.82.96.198:8080/jspui/bitstream/123456789/1037/1/CDMGENS00045.pdf>
- Toumi Z, Chan A, Hadfield MB et al (2010). Systematic review of blunt abdominal trauma as a cause of acute appendicitis. *Annals of the Royal College of Surgeons of England*, 92(6):477-482
- Tsai SH, Hsu CW, Chen SC (2008). Complicated acute appendicitis in diabetic patients. *American Journal of Surgery*, 196(1):34-9
- Vermeulen B, Morabia A, Under PF (1995). Influence of white cell count on surgical decision making in patients with abdominal pain in the right lower quadrant. *European Journal of Surgery*, 161(7):483-486
- Vissers RJ, Lennarz WB (2010). Pitfalls in appendicitis. *Emergency Medicine Clinics of North America*, 28:103-118
- Wakeley C (1933). The Position of the Vermiform Appendix as Ascertained by an Analysis of 10,000 Cases. *Journal of Anatomy*, 67(2):277-283
- Walker AR, Segal I (1995). Appendicitis: an African perspective. *Journal of the Royal Society of Medicine*, 88:616-619
- Walker RP, Segal I (1990). What causes appendicitis? *Journal of Clinical Gastroenterology*, 12:127-129
- Wilson EB, Cole JC, Nipper ML et al (2001). Computed tomography and ultrasonography in the diagnosis of appendicitis: when are they indicated? *Archives of Surgery*, 136:670-5

Wise SW, Labuski MR, Kasales CJ et al (2001). Comparative assessment of CT and sonographic techniques for appendiceal imaging. *AJR American Journal of Roentgenology*, 176:933-41

Zimmermann PG (2008). Is it appendicitis? *American Journal of Nursing*, 108(9):27-31

IntechOpen

IntechOpen



## **Appendicitis - A Collection of Essays from Around the World**

Edited by Dr. Anthony Lander

ISBN 978-953-307-814-4

Hard cover, 226 pages

**Publisher** InTech

**Published online** 11, January, 2012

**Published in print edition** January, 2012

This book is a collection of essays and papers from around the world, written by surgeons who look after patients of all ages with abdominal pain, many of whom have appendicitis. All general surgeons maintain a fascination with this important condition because it is so common and yet so easy to miss. All surgeons have a view on the literature and any gathering of surgeons embraces a spectrum of opinion on management options. Many aspects of the disease and its presentation and management remain controversial. This book does not answer those controversies, but should prove food for thought. The reflections of these surgeons are presented in many cases with novel data. The chapters encourage us to consider new epidemiological views and explore clinical scoring systems and the literature on imaging. Appendicitis is discussed in patients of all ages and in all manner of presentations.

### **How to reference**

In order to correctly reference this scholarly work, feel free to copy and paste the following:

Sanjay Harrison and Harrison Benziger (2012). Diagnostic Challenges in Acute Appendicitis, *Appendicitis - A Collection of Essays from Around the World*, Dr. Anthony Lander (Ed.), ISBN: 978-953-307-814-4, InTech, Available from: <http://www.intechopen.com/books/appendicitis-a-collection-of-essays-from-around-the-world/diagnostic-challenges-in-acute-appendicitis>

**INTech**  
open science | open minds

### **InTech Europe**

University Campus STeP Ri  
Slavka Krautzeka 83/A  
51000 Rijeka, Croatia  
Phone: +385 (51) 770 447  
Fax: +385 (51) 686 166  
[www.intechopen.com](http://www.intechopen.com)

### **InTech China**

Unit 405, Office Block, Hotel Equatorial Shanghai  
No.65, Yan An Road (West), Shanghai, 200040, China  
中国上海市延安西路65号上海国际贵都大饭店办公楼405单元  
Phone: +86-21-62489820  
Fax: +86-21-62489821

© 2012 The Author(s). Licensee IntechOpen. This is an open access article distributed under the terms of the [Creative Commons Attribution 3.0 License](https://creativecommons.org/licenses/by/3.0/), which permits unrestricted use, distribution, and reproduction in any medium, provided the original work is properly cited.

IntechOpen

IntechOpen