

We are IntechOpen, the world's leading publisher of Open Access books Built by scientists, for scientists

6,900

Open access books available

186,000

International authors and editors

200M

Downloads

Our authors are among the

154

Countries delivered to

TOP 1%

most cited scientists

12.2%

Contributors from top 500 universities



WEB OF SCIENCE™

Selection of our books indexed in the Book Citation Index
in Web of Science™ Core Collection (BKCI)

Interested in publishing with us?
Contact book.department@intechopen.com

Numbers displayed above are based on latest data collected.
For more information visit www.intechopen.com



Application of CT Scanning in the Studies of Minimal Invasive Thoracoscopic Surgery of Adolescent Idiopathic Scoliosis

Yong Qiu

*Spine Surgery, The Affiliated Drum Tower Hospital of Nanjing University Medical School
China*

1. Introduction

Adolescent idiopathic scoliosis (AIS) is a structural, lateral, rotated curvature of the spine that arises in otherwise healthy children at or around puberty, for which no cause has been established. (Lowe TG, *et al.* 2000, Weinstein SL, *et al.* 2008, Wang WJ, *et al.* 2011) The diagnosis is one of clinical and radiographic exclusion, and is made only when other causes of scoliosis, such as vertebral malformation, neuromuscular disorder, syndromic disorders, connective tissue disorders and genetic syndromes, have been ruled out. Spinal deformity is usually noted by a school screening examination, a pediatrician, or a family member observant to the changes seen in the trunk including: unlevel shoulders, waistline asymmetry, and thoracic or lumbar prominences. The diagnosis is confirmed on long-cassettal coronal and lateral radiograph of the spine, with a Cobb measurement greater than or equal to 10°. In addition, the radiographs should exclude congenital anomalies of the spine and atypical curve patterns, such as left thoracic curves that may be associated with syringomyelia. With this definition, epidemiological studies estimate the prevalence of 1-3% in the at-risk population (children aged 10-16 years). In these patients, the most common type of AIS is main right thoracic curve (RT).

The size of the curve tends to increase over the entire lifetime, but the fastest progression happened during pubertal growth. Female showed a significant higher tendency of progression than male AIS patients, with the ratio of 9:1 or 10:1 with curves greater than 40°, at which a surgical intervention would be recommended with the aim of arresting progression, achieving maximum permanent correction of the deformity in three dimensions, improving appearance by balancing the trunk, and keeping short-term and long-term complications to a minimum. Both posterior and anterior instrumentation methods have been used successfully in surgical treatment of AIS. The AIS patients with a primary thoracic curve have the highest prevalence of progression. When the curve pattern is such that only thoracic instrumentation is required, the choice between anterior and posterior surgical approach exists. Segmental posterior spinal instrumentation and fusion has been accepted as the gold standard method in treating RT-AIS, for the consistent correction rate in short and long term, and low incidence of complication. (Weinstein SL, *et al.* 2008) In contrast, anterior scoliosis surgery was introduced with the ability to create thoracic kyphosis and better correct vertebral rotation and torsion, and with the fusion of

fewer motion segments when compared to posterior approach. The procedure, however, traditionally has required a thoracotomy, which has approach-related morbidity, such as significantly reduced pulmonary function with slow recovery after operation, large skin scar with massive wound injury which results in the postoperative pain.

Two decades ago, a video-assisted thoracoscopic surgery (VATS) was developed for intervention of spinal deformation, firstly for anterior release of severe and rigid RT-AIS, and then successfully used for instrumentation and correction of well-chosen patients with RT-AIS. This approach obviates many of the disadvantages of the traditional open anterior thoracic approach. The morbidity associated with a thoracotomy is limited because of the requirement of minimal skin and chest wall dissection by this method, hence the approach showed less detrimental to pulmonary function and more favorable in terms of postoperative pain and appearance.

The fundamental aims of AIS instrumentation and fusion are safe and efficient curve correction and solid fusion to maintain the long term correction. In anterior spinal instrumentation, ideal discectomy with auto bone graft is important for bony fusion. In addition, bi-cortical vertebral screw projecting one or two threads outside the vertebra was recommended to reinforce pull out strength (Lowe T, *et al.* 2002, Huang TJ, *et al.* 2003). However, it was in concern that during the procedure of discectomy, instrumentations may penetrate into spinal canal and lead to spinal cord injury. In addition, the bi-cortical inserted screws could result in vascular injury or neurological complications. Furthermore, comparing with the control subjects, the thoracic aorta in patients with RT-AIS was found to shift more posteriorly and closely to the vertebra because of the vertebral rotation and morphological anomaly at the vertical plane.(Sevastik B, *et al.* 1996, Sucato DJ and Duchene C 2003a, Maruyama T, *et al.* 2004) When correcting RT-AIS with VATS, it's challenge for surgeons to work with this minimal invasive approach by long-arm instruments based on two-dimensional vision on fluoroscopy, instead of managing under direct view through free hand. (Sucato DJ, *et al.* 2004, Grewal H, *et al.* 2005, Lonner BS, *et al.* 2005, Newton PO, *et al.* 2005a) For these reasons, the placement of the screws in these patients thoracoscopically was subject to the complication of aorta injury and the penetration of the spinal canal.(Dunn HK 1986, Ohnishi T, *et al.* 2001, Parent S, *et al.* 2002, Bullmann V, *et al.* 2005, Kuklo TR, *et al.* 2005, Huitema GC, *et al.* 2006) Hence a well knowledge on the anatomic relationship between the para spinal tissues and the thoracic vertebral bodies, and the dynamic changes of the relationship during operation is critical for accurate screw insertion and the other procedures so that a satisfied instrumentation and fusion could be achieved in patients with RT-AIS.

With these objectives, a series computed tomography (CT) based studies were carried out in our centre. Firstly, with the concern of aortic and neurological complications caused by screw insertion, morphometric comparison of the spatial relationship between thoracic aorta and thoracic vertebrae in patients with RT-AIS and that in control subjects were carried out to find the safe entry point, trajectory, and length of screw for Chinese AIS as well as provide the anatomic reference data for correct screw placement under thoracoscopy. Secondly, during curve correction, thoracic pleura would be dissected for discectomy and anterior release of thoracic spine, and sometimes thoracic aorta would be released as well. Some surgeons close the pleura to minimize the drainage, while others would not with the aim to save operation time. Whether the anatomic relationship between thoracic aorta and vertebrae would be changed during surgical procedures is also critical for screw insertion. Hence the dynamic changes of this relationship during operation were investigated. With the knowledge, VAST

and VAST associated mini-open thoracotomy approaches were used in correcting RT-AIS, then the accuracy of instrumentation was investigated on CT scan images.

2. Methods and results

2.1 Anatomical relationship between the aorta and thoracic vertebral bodies in RT-AIS

2.1.1 Methods

2.1.1.1 Subjects

Thirty cases of RT-AIS including 8 males and 22 females, with an average age of 15.7 years (range 13–20 years) were recruited. Posteroanterior and lateral radiographs and pan spinal cord MRI were performed to ensure that the scoliosis was idiopathic. Patients with proven or suspected congenital, muscular or neurological scoliosis were excluded.

Sixty-four patients without any spinal deformity who had axial thoracic CT because of non-vertebral pathology were chosen as the control group. Patients with any congenital malformation or other diseases which may affect the normal anatomy of thoracic vertebrae and aorta were excluded. There were 28 males and 36 females with an average age of 13.3 years (range 15–20 years) in the control group. The patients in both groups were from mainland China.

2.1.1.2 CT scans and analysis

Spiral scans were obtained on a 16-multidetector-spiral CT (MDCT) scanner (LightSpeed, GE Healthcare) with the following parameters: 320 mAs, 120 kVp, 10 mm slice thickness. Images showing bilateral rib heads and costovertebral joints were selected for measurement. The transverse CT images from T4 to T12 in both groups were measured with conimeter, vernier caliper and compasses with respect to the following parameters (figure 1): (1) the angle for safety screw placement (β): angle formed by the line that passed the anterior edge of the bilateral rib heads (Line RR) and the line from the anterior edge of the right rib head to the posterior wall of the aorta, (2) the angle of the aorta relative to the vertebral body (α): angle composed by Line RR and another line from the anterior midpoint of the spinal canal to the center of the aorta, (3) the vertical distance from the line RR to the anterior wall of the spinal canal (RV), (4) the distance from the anterior edge of the left rib head to the posterior wall of the aorta (a), (5) the vertebral body transverse diameter (c), (6) vertebral rotation (γ) i.e. RAsag angle. (Krismer M, *et al.* 1992)

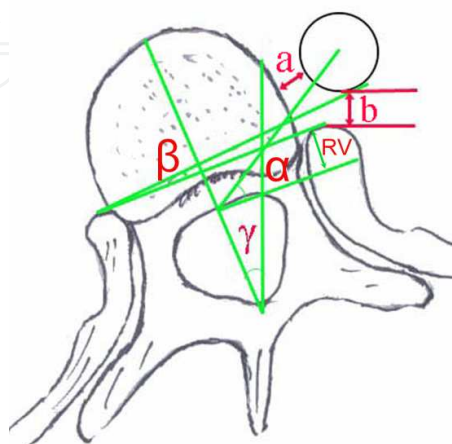


Fig. 1. Illustration of parameters measured on the CT images.

2.1.1.3 Statistical analysis

Statistical analysis was performed with the use of SPSS software (version 11.5, America). Mean values \pm standard deviations were calculated for all variables at each level. Comparisons were made between the two groups with the use of the student t test. Significance was defined as a $p < 0.05$.

2.1.2 Results

No significant differences were found between the two groups with respect to age or gender distribution. In the scoliosis group, Cobb angles ranged from 40° to 70° with an average of 54°. No anomaly of thoracic vertebrae and aorta were found except scoliosis, and the most common apical vertebra was eighth thoracic vertebra. A total of 403 vertebrae in the control group and 266 vertebrae in the scoliosis group were measured. The measurement results in the control group and the scoliosis group were summarized in Table 1. The β angle, α angle and a value had a tendency to decrease and then increased from T4 to T12, and values were generally lower in the scoliosis group than that in the control group. The β angle from T7 to T10, α angle from T5 to T10 and a values at T9, T10 were significantly lower in the scoliosis group. The RV value decreased steadily from the cephalic to the caudal aspect of the spine in both groups and became negative at T11 and T12 in the scoliosis group, while the values were significantly lower in the scoliosis group from T4 to T11. The c value of both groups increased gradually from T4 to T12, however, no significant difference was found at any segment level other than T7. The γ angle in the scoliosis group also had a tendency to increase and then decrease from T4 to T12, while the value was larger at the periapical levels. At the periapical levels, there were significant negative corrections between the vertebral rotation and the α angle($R = -0.765$, $p < 0.05$).

Level	n	$\beta(^{\circ})$	$\alpha(^{\circ})$	RV (mm)	a (mm)	c (mm)
T4	44	27.5 \pm 8.9	60.8 \pm 8.2	6.4 \pm 2.6	17.8 \pm 5.8	26.2 \pm 2.4
T5	44	13.4 \pm 9.3	47.0 \pm 9.5	5.9 \pm 2.4	8.1 \pm 5.5	27.1 \pm 2.0
T6	45	9.2 \pm 7.9	43.0 \pm 9.3	5.1 \pm 1.9	5.5 \pm 4.9	28.0 \pm 2.1
T7	44	11.5 \pm 8.7	45.2 \pm 10.6	4.7 \pm 2.2	7.3 \pm 5.2	29.2 \pm 2.3
T8	46	18.4 \pm 9.2	50.3 \pm 10.2	3.6 \pm 2.4	11.5 \pm 5.7	30.1 \pm 2.4
T9	48	21.8 \pm 9.7	54.8 \pm 12.6	3.4 \pm 2.3	14.0 \pm 6.3	31.5 \pm 2.7
T10	49	26.9 \pm 8.6	59.2 \pm 15.8	3.3 \pm 2.4	18.0 \pm 6.0	33.1 \pm 2.9
T11	42	31.7 \pm 7.3	67.0 \pm 9.4	2.3 \pm 2.1	21.6 \pm 6.3	35.2 \pm 2.1
T12	39	35.9 \pm 6.1	70.8 \pm 7.6	0.2 \pm 2.5	26.4 \pm 5.2	37.9 \pm 2.2

Table 1. Quantitative measurements of relationship between aorta and vertebrae in control

2.2 Dynamic changes of the relationship between thoracic aorta and vertebrae in RT-AIS underwent thoracic associated mini-open thoracotomy Instrumentation with pleura closure

2.2.1 Methods

2.2.1.1 Surgical technique

Fourteen patients treated with mini-incision thoracoscopic anterior fusion with CDH-TSRH instrument (Medtronic Sofamor Danek, Memphis, TN) were recruited. The operation was done under general anaesthesia with routine endotracheal intubation. The patient was

Level	n	$\beta(^{\circ})$	$\alpha(^{\circ})$	RV (mm)	a (mm)	c (mm)	$\gamma(^{\circ})$
T4	30	29.1±13.0	61.1±19.1	3.7±2.0*	17.3±7.6	26.2±2.2	-13.0±6.0
T5	30	10.1±11.3	38.5±17.7*	2.4±2.2*	6.8±6.8	27.6±2.8	-10.3±7.9
T6	30	5.8±9.7	32.6±14.7*	1.8±1.9*	4.0±6.2	28.9±3.8	-3.3±8.9
T7	30	5.2±7.8*	26.9±12.2*	1.4±1.7*	4.8±5.9	30.4±4.2*	7.1±7.3
T8	30	10.5±8.9*	31.5±13.5*	1.2±1.4*	8.5±8.1	30.9±3.2	13.4±5.3
T9	30	12.7±9.1*	37.6±12.3*	0.6±2.4*	8.4±5.5*	32.1±3.6	13.4±6.8
T10	30	17.8±11.5*	43.6±15.2*	0.5±3.0*	13.0±7.5*	33.1±3.1	11.6±9.0
T11	29	26.6±11.5	68.5±55.2	-1.4±1.9*	20.5±7.7	34.8±3.7	4.2±11.6
T12	27	35.4±12.1	69.0±18.7	-1.6±3.3	26.7±7.9	37.1±4.0	-2.8±15.3

*: the difference was significant when comparing with the control group ($p<0.01$).

Table 2. Quantitative measurements of relationship between aorta and vertebrae in RT-AIS

placed in lateral decubitus position with the convexity up. The superior and the inferior vertebrae in the fusion segments as well as their skin projections were determined with the help of a C arm X-Ray. A 10 cm incision was done parallel to the sixth or seventh rib ending 2–4 cm anterior to the anterior axillary line and 2–3 cm posterior to the posterior axillary line. The thoracotomy was made by removing 10–12 cm of rib.

Elevate the parietal pleura along the thoracic spine with Adsons and open it with Metzenbaum scissors. Extend the opening of the parietal pleura in a cephalad and caudad direction till upper and lower instrumented level. Bluntly dissect the cut edges of the parietal pleura off the spine with a sponge. Elevate it on the discs and lift it off the vessels on the vertebral body. Dissection started over the discs was less likely to cause bleeding. Segmental vessels were clamped and ligated. After division of the segmental vessels, bluntly expose the out surface of the spine. Periosteal elevator was used to expose the entire disc and vertebral column. On the convex side of the curve, the parietal pleura were elevated from vertebral body laterally till right rib head. On the concave side of the curve, the swabs were inserted under the parietal pleura to bluntly push the aorta away from vertebrae and the parietal pleura were peel off the vertebral bodies to the opposite side.

Disectomy at periapical vertebral were done through the incision. Then CDH vertebral screws (6.5 mm in diameter and 3.0–3.5 mm in length) were inserted into the four apical vertebrae, with the similar techniques as conventional anterior open surgery. Two portals with 2.0 cm diameter were made on the middle axillary line at the interval of two intercostals spaces above and below the incision, respectively. These two portals were used as working portals for thoracoscopic procedures. Under direct and thoracoscopic observation, two more intervertebral discs above and below the apical area was removed. Through the portals, CDH or TSRH screws (6.5 mm in diameter and 2.5–3.0 mm in length) were placed into the target vertebrae. At the cephalad thoracic spine (T4–T6), the ventral excursion angle was 15°, the entry-point of the screw should be close to the rib head. For apical vertebrae (T7–T9), the ventral excursion angle should be 10°. At the caudal thoracic spine (T10–T12), the ventral excursion angle was 15°, the entry-point should shift 5 mm ventrally. Morserized autogenous ribs grafts were packed into intervertebral discs for fusion and followed by the placement of the previously bent rod into the CDH or TSRH screws. Without derotation manoeuvre, only compression was applied on adjacent screws from the apex to the upper and lower end vertebrae. The correction of the deformity was

checked under C arm X-ray and finished by wrench out self-breaking nuts. The parietal pleura covering the vertebrae were thoroughly sutured, haemostasis was confirmed and a chest tube was placed through the inferior portal.

All patients were operated on by the same team of surgeons (Y.Q and B.W). Somatosensory evoked potential (SEP) was used for intra-operative neurological monitoring. The pre- and post-operative thoracic coronal curves, kyphosis between T5 and T12 and apical vertebral translation (AVT) were measured on standard standing posterior-anterior and lateral X-ray using the Cobb method.

2.2.1.2 CT scan and analysis

All recruited subjects underwent spiral CT of the spine before and one week after operation. Axial images from T5 to T12 were obtained with the subjects in supine position. The CT examinations were performed by a spiral CT scanner (LightSpeed GE Healthcare) with the following parameters: 320mAs, 120kVp, and 5mm thicknesses, with 5mm gap between slices. Pre- and post-operative CT images with most similar morphology of vertebrae and bilateral rib heads were selected for analysis. A number of parameters were measured using PacsClient software (PACS) on workstation, which included (1) Angle α , the angle subtended by the line joining left and right rib heads and the line from anterior midpoint of vertebral canal to midpoint of the aorta showing the relative position of aorta to the vertebrae, (2) Vertebral rotation angle γ , similar to the Rasag angle, (Krismer M, *et al.* 1992) (3) Distance a, defined as the distance from posterior wall of the aorta to anterior edge of the left rib head, and (4) Distance b defined as the distance from aorta to the closest point of the cortex of the vertebral body (figure 1). The screw position was analyzed on CT images based on the following criteria. The vertebral screw had a bi-cortical penetration which did not encroach on the spinal canal and had at least 1mm distance from aorta. This was defined as satisfactory screw position. (Sucato DJ, *et al.* 2004, Bullmann V, *et al.* 2005, Kuklo TR, *et al.* 2005) All the measurements were taken by an independent observer.

2.2.1.3 Statistical analysis

The data was statistically evaluated using SPSS software for Windows (10.0, Chicago). Related two sample test (Wilcoxon signed ranks test) was used to determine the difference between vertebral levels pre- and post-operation and also differences between the two groups. The Pearson correlation analysis was used to evaluate the relationship between the aorta shifting and curve correction. Significance was defined as a $p < 0.05$.

2.2.2 Results

The average age was 14.3 ± 1.7 (12~18) years. The Cobb angle, the curve pattern, thoracic kyphosis and flexibility of main thoracic curve were listed in Table 3. All patients were treated with selective spinal instrumentation (Lenke LG, *et al.* 2001) with an average fusion level of 8.2 ± 0.4 (8~9). The average immediate postoperative MT curve magnitude was 9.6° , showing an average curve correction rate of 78.6%. The thoracic kyphosis was restored. Significant improvement of the apical vertebral translation was achieved (Table 3). No intra-operative SEP monitoring abnormality was found and no neurologic deficits were occurred after operation. All patients were followed up for a minimum of one year. No obvious complications were found during the operation and follow up.

	Pre-OP	Post-OP
N (F)		14 (13)
Riser sign		3.4 (2~4)
Main thoracic curve		
Cobb angle (°)	44.9±5.8 (40~55)	9.6±3.6 (4~15)
Flexibility (%)	59.6±13.2 (40.5-69.4)	78.6±7.2 (69~90)
Kyphosis Cobb angle (T5-T12) (°)	12.6±9.5(-4~22)	19.3±11.3 (2~40)*
Apical vertebral translation (mm)	3.50±1.14 (0.70~5.10)	0.53±0.55 (0~1.68)**
Lenke classification	-	N
	1A	3
	1B	1
	1C	1

Significant difference was found when compared with pre-operation: *: $p<0.05$; **: $p<0.01$
Significantly higher curve correction rate was achieved in group A: ††: $p<0.01$

Table 3. The pre-operative and post-operative information of patients

2.2.2.1 The changes in the relative anatomical position of the thoracic aorta with the vertebral body postoperatively

In total, 111 thoracic vertebrae were instrumented and measured. The results were summarized in Table 4. By curve correction, the angle α increased at T6-T12 with maximum found at T8 and T9 measuring 11.7°. The increments were 44.8%. The distance between the left rib head and the thoracic aorta also increased from T6 to T10 with the most significant increase at T9 (31.3%, $p<0.05$). These increments showed that the aorta had shifted anteriorly relative to the vertebrae after curve correction (figure 2). Significant derotation was also found in the periapical vertebrae. Further analysis revealed that the increase of angle α and distance were significantly correlated with the decrease of angle γ ($p<0.01$). The most significant aortic shifting was found at the periapical vertebral levels. The increase of angle α and distance were negatively correlated with the decrease of AVT ($p<0.05$). The distance b decreased post-operatively with the maximum decrease at T9 (27.0%, $p<0.05$), which meant aorta moved closely to the vertebral body following curve correction. The decrease also correlated significantly with the increase of thoracic kyphosis ($p<0.05$).

	$\alpha(^{\circ})$		$\gamma(^{\circ})$		a(mm)		b(mm)	
	Preop	Postop	Preop	Postop	Preop	Postop	Preop	Postop
T5	40.8±22.3	38.9±11.5	1.1±14.0	-1.6±4.1	7.6±8.4	7. 4±5.1	3.1±1.5	2.9±2.3
T6	31.0±25.7	34.4±14.0	4.2±10.0	1.1±4.3	5.1±8.2	6.6±6.4	3.5±2.8	2.7±1.0
T7	28.4±21.8	32.5±14.7	8.1±10.5	4.5±5.4	5.4±8.2	6.0±6.3	3.6±2.7	2.8±1.5
T8	26.1±22.5	37.8±14.9**	12.2±7.8	4.7±5.2**	6.4±8.1	9.2±7.4	3.8±3.1	3.3±1.1
T9	32.7±23.4	42.3±16.0*	12.1±9.7	6.0±5.9**	9.6±8.1	12.6±6.6*	3.7±2.4	2.7±1.7*
T10	44.4±22.4	48.5±13.9	10.9±13.5	7.0±7.1	14.7±8.1	15.7±7.6	3.2±1.3	2.9±1.5
T11	53.8±24.9	56.5±13.8	8.3±18.3	4.0±8.9	19.5±7.4	18.5±9.1	2.5±1.4	2.0±1.1
T12	65.8±23.2	67.8±15.2	4.2±20.3	1.4±9.7	26.6±7.0	25.2±8.3	2.0±1.4	1.3±1.2

Significant difference was found compared with the pre-operation: * $p<0.05$, ** $p<0.01$
Related two sample test: Wilcoxon Signed Ranks Test

Table 4. The average measurements of CT scans

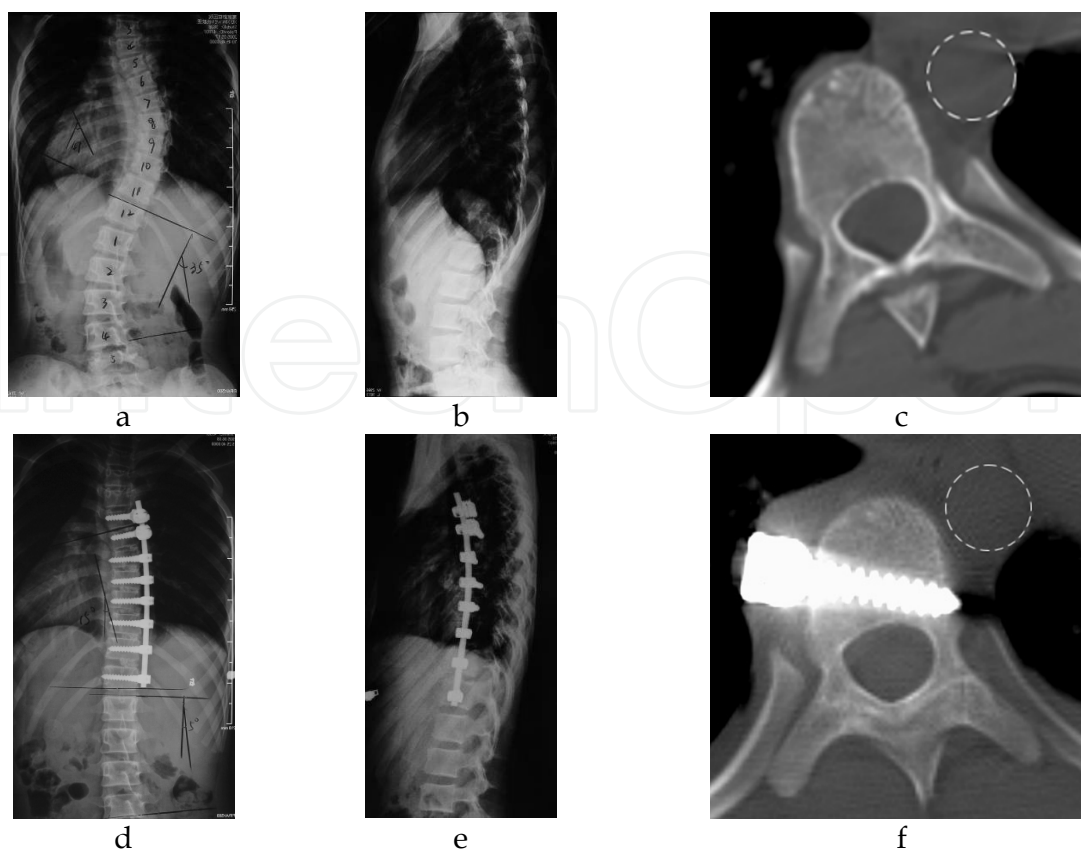


Fig. 2. A 12-year-old girl with AIS Lenke Type 1BN was operated by mini-incision thoracotomic anterior approach. a & d: Pre and Post-operative anteroposterior X-ray; b & e: Pre and Post-operative lateral X-ray ; c & f: CT images of T8, the aorta shift antero-medially after curve correction compared with the preoperative CT images

2.3 Migration of thoracic aorta after the anterior correction of RT-AIS without parietal pleura closure

2.3.1 Methods

2.3.1.1 Subjects

Thirty one patients with the diagnosis of RT-AIS who underwent anterior instrumentation in our institute were recruited. Of which fifteen cases (10 females and 5 males) met the following criteria were recruited into this prospective study. The inclusion criteria were: (1) the Cobb angle less than 60° , (2) apex between T8~T9, (3) the thoracic kyphosis less than 40° , (4) pre-operative and one week post-operative spiral CT scanning available for the same patient. The exclusion criteria were: (1) CT scanning did not clearly show the aorta and bilateral pedicles in interest levels, (2) previous spinal surgery, (3) previous intra-thoracic surgery, (4) pleural adhesions found during surgery, (5) thoracolumbar junctional kyphosis. The average age was 15.9 ± 3.6 years (range, 12~20 years). The average Cobb angle was $45.8^\circ \pm 6.3^\circ$ (range, $40^\circ \sim 60^\circ$) and thoracic kyphosis from T5 to T12 was $13.7^\circ \pm 12.4^\circ$ (range - $2^\circ \sim 25^\circ$). The apex vertebra ranged from T8 to T9 and the AVT was 3.62 ± 1.84 cm (0.81 cm ~5.22 cm). The curve type was classified as Lenke type 1A in eight cases, type 1B in three cases and type 1C in four cases²¹ (Table 5). The pre- and post-operative thoracic coronal curves, kyphosis between T5 and T12 and AVT were measured on standard standing whole

spine X-ray films. The study was approved by a university based Institutional Research Ethics Committee.

	Pre-OP	Post-OP
N (F)	15 (10)	
Riser sign	(3.8)2~5	
Main thoracic curve		
Cobb angle (°)	45.8±6.3 (40~60)	10.9±5.7 (6~18)
Flexibility (%)	64.5±10.4(45.0-70.3)	75.0±8.4 (70~85)
Kyphosis Cobb angle (T5-T12) (°)	13.7±12.4 (-2-25)	22.4±10.8 (10~40)
Apical vertebral translation (mm)	3.62±1.84 (0.81-5.22)	0.78±0.65 (0~1.75)
Lenke classification	-	N
1A	4	4
1B	2	1
1C		4

Table 5. The pre- and post- operative general information of patients

2.3.1.2 Surgical techniques

The anterior mini-open instrumentation was performed by the same team of surgeons (Y.Q and B.W) at a single institution. The surgical procedures were same as the one described previously. The only difference was that the dissected parietal pleura was not sutured and kept free from any tension on it after correction.

2.3.1.3 CT scans and analysis

Same as the methods described in previous part, CT scans were carried pre-operation and oen week post-operation. Then the relative position of the aorta to the vertebral body was evaluated on CT images as in the previous study.

2.3.1.4 Statistical analysis

All data were expressed as mean ± standard deviation (SD). SPSS/PC 13.0 (SPSS Inc., Chicago, USA) was used on all statistical computation. Comparisons between the pre- and post-operative parameters were analyzed by related two sample test (Wilcoxon signed ranks test). The Pearson correlation analysis was used to evaluate the relationship between the aorta shifting and curve correction. A value of *p*<0.05 was considered statistically significant.

2.3.2 Results

2.3.2.1 Clinical and radiographic data

The thoracic curve was instrumented from upper to lower end vertebrae which were T5~T12 in 11 cases, T5~T11 in 2 cases and T6~T12 in 2 cases. The post-op Cobb angle of the thoracic curve on average was 10.9°±5.7° (range, 6°-18°) with 75% curve correction. AVT was corrected to 0.78 cm±0.65 cm (range, 0 cm - 1.75 cm). Normal kyphosis was restored in all patients (Table 5). The total thoracic drainage ranged from 260ml to 600ml (average 450ml). The chest tube was removed once the drainage was less than 50 ml per 24 hr and the mean duration of chest tube stay was 3.1 days (ranged 2 to 4 days). There was no intra-operative fracture of vertebrae body and aortic injury. No complication of pneumonia,

effusive pleuritis, pulmonary atelectasis, pneumothorax or respiratory tract obstruction was observed. All patients were followed up for a minimum of one year (ranged 12~38 months). There was no neurological or vascular complication, nor instrumentation failure.

2.3.2.2 CT-based analysis

In CT measurement, the average preoperative angle α decreased from 39.8° at T5 to 28.9° at T8, then gradually increased to 68.3° at T12. After surgery, the angle α became smaller at all levels with an average value of 34.7°, 18.8° and 63.2° at T5, T8 and T12, respectively. The distance a decreased from 7.0 mm at T5 to 8.1 mm at T8 then increased to 28.1 mm at T12 before surgery. After operation, the distance a was smaller at all levels with an average of 5.8 mm, 3.7 mm and 24.3 mm at T5, T8 and T12, respectively. The pre-operative distance b increased from 3.2 mm at T5 to 4.3 mm at T7 then decreased to 1.9 mm at T12. The distance b increased in all levels after surgery with an average of 3.9 mm at T5, 8.0 mm at T8 and 2.3 mm at T12, respectively. All the post-operative parameters were significantly different from the pre-operative ones ($p<0.05$) except in T5, T11 and T12 (Table 6). The post-operative decrease of angle α and the distance a indicated that the aorta migrates posteriorly after surgery, while the increase of distance b indicated the lateral migration of the aorta relative to the vertebrae (figure 3).

level	Angle α (°)		Distance a (mm)		Distance b (mm)	
	Pre-op	Post-op	Pre-op	Post-op	Pre-op	Post-op
T5	39.8±9.8	34.7±13.0	7.0±6.1	5.8±4.4	3.2±0.9	3.9±3.3
T6	36.0±13.0	28.0±9.6	6.3±4.9	3.5±3.1*	3.5±2.9	5.7±3.9*
T7	35.5±15.0	23.2±10.2*	5.6±4.8	2.3±2.2*	4.3±2.8	7.9±2.7*
T8	28.9±12.7	18.8±10.3*	8.1±5.5	3.7±3.1*	4.1±3.3	8.0±2.0*
T9	35.3±13.2	26.2±10.4*	12.6±6.3	5.0±3.2*	2.2±1.8	6.9±2.4*
T10	53.1±10.4	38.5±11.2*	16.8±5.7	10.5±4.1*	1.7±1.2	4.1±1.5*
T11	58.1±18.3	53.6±13.7	20.9±5.4	18.1±5.6	2.0±1.5	2.3±1.1
T12	68.3±17.5	63.2±14.6	28.1±7.9	24.3±6.9	1.9±1.6	2.3±0.7

Significant difference was found compared with the pre-operation: * $p<0.05$. Related two sample test: Wilcoxon Signed Ranks Test.

Table 6. Average Measurement results of CT scans in patients (Average ± SD, n=15)

Further analysis revealed that the most significant aortic shifting was found at the periapical vertebral levels with the maximum decrease of angle α at T8 (34.9%) and increase of distance b at T9 (213.6%). The changes of angle α , the distance a and distance b didn't correlate with coronal curve correction, the decrease of AVT and the increase of thoracic kyphosis.

2.4 Accuracy of thoracic vertebral screw in rt-ais inserted through thoracoscopic and mini-open thoracotomy approaches

2.4.1 Methods

2.4.1.1 Subjects

Patients with right thoracic AIS treated with thoracoscopic or mini-open anterior instrumentation from June 2002 to December 2005 in one center were reviewed retrospectively. Those with post-operative CT scanning on instrumented vertebrae were

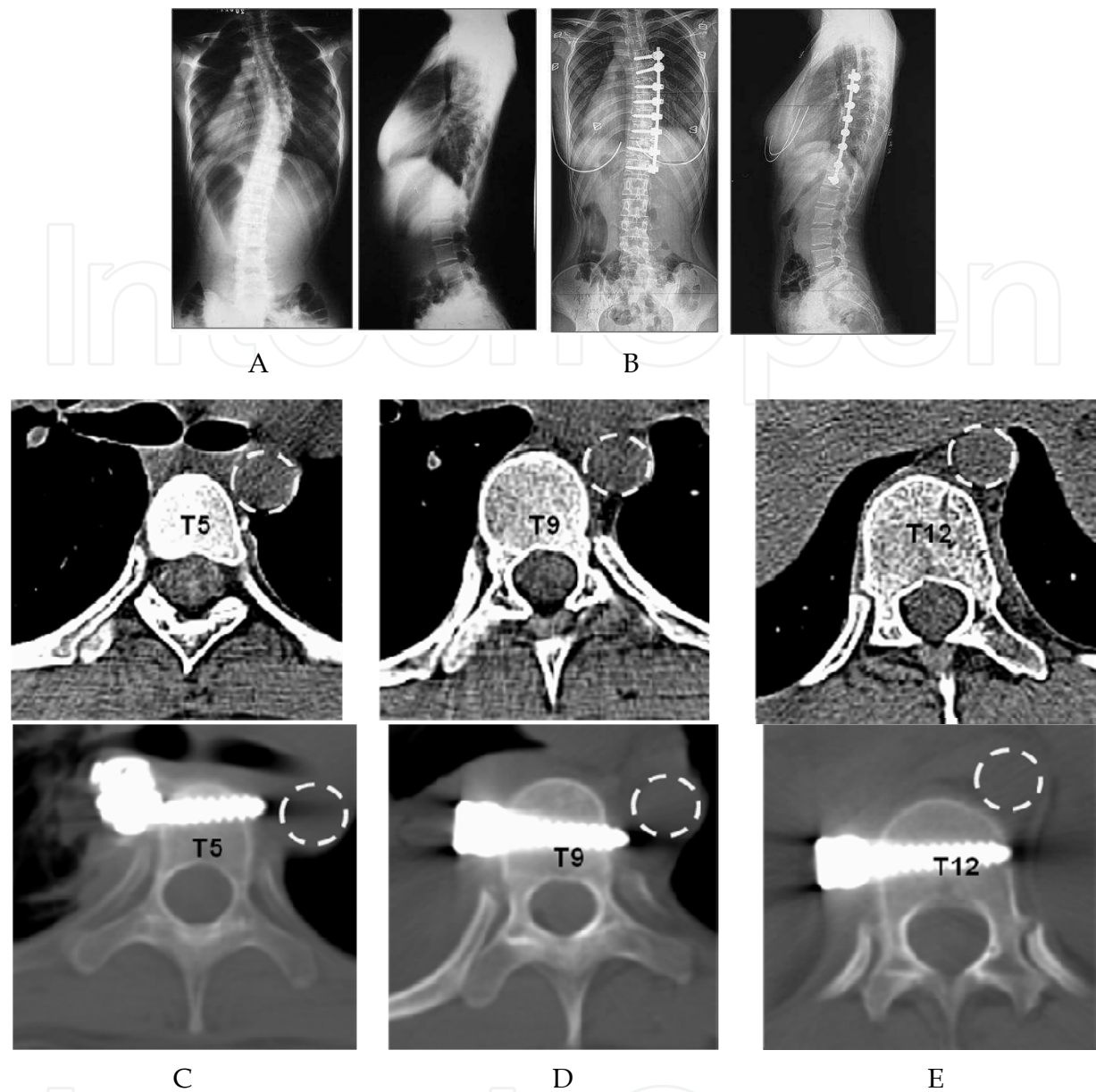


Fig. 3. A 17-year-old girl with IS Lenke Type 1A- was operated by mini-open thoracotomic anterior approach. A: Pre-op anteroposterior and lateral X-ray, Cobb angle 40°; B: Post-operative anteroposterior and lateral X-ray show the Cobb angle corrected to 10°; pre and post-op CT images of T5 (C), T9 (D), T12 (E), the aorta shift posterolaterally after curve correction.

recruited into the study. To lessen the learning curve effect of thoracoscopic technique on screw positioning,(Lonner BS, *et al.* 2005, Newton PO, *et al.* 2005a) the first 20 patients were excluded from the study. To allow better comparison, the first 27 patients treated with mini-open thoracotomy within the same period were also excluded. In this series, a total of ten girls treated with thoracoscopic instrumentation and twenty-one patients (19 female and 2 male) with instrumentation through mini-open thoracotomy were recruited as Group A and Group B respectively. The general clinical information of these patients was listed in Table 7. The curve types were classified according to the Lenke classification.(Lenke LG, *et al.* 2001)

In Group A, two patients were classified as 1A-, three as 1B-, the remaining five were classified as 1AN, 1BN, 1B+, 1CN, 2AN, respectively. In Group B, there were five patients with Lenke type 1A-, six as 1AN, three as 1B-, three as 1BN, two as 1C- and two as 1CN. Eight patients in Group A were treated with *Eclipse* instrumentation (Medtronic Sofamor Danek, US) and the latter two with *Frontier* instrumentation (Johnson & Johnson, US). All patients in Group B were corrected with CDH-TSRH instrumentation (Medtronic Sofamor Danek, US). The instrumentation and fusion techniques were described in previous studies.

	Thoracoscopy (Group A, n=10)	Mini-open thoracotomy (Group B, n=21)
Age (yr)	14.4 (11.5-16.3)	14.4 (11.8-17.2)
Riser grade	2.5 (0-4)	3.5 (2-5)
Pre-operation		
Thoracic curve (°)	52.9 (45-70)	45.4 (40-55)
Flexibility (%)	50.8 (37-73)	57.2 (28.9-87.5)
lumbar curve (°)	30.1 (15-37)	26.5 (16-41)
Post-operation		
Fusion level	7.3 (6-8)	8.1 (8-9)
Thoracic curve (°)	14.3 (5-24)	10.0 (4.3-15.0)
Correction rate (%)	73.6 (66.0-100)	77.9 (66.7-89.2)

Table 7. The pre- and post-operative general clinical information of patients in both groups

2.4.1.2 Surgical techniques

In patients treated with mini-open thoracotomy approach, the sixth or seventh rib was removed through a 10-12cm incision parallel to the rib with its center in the median axillary line. Screws for the four vertebrae at the apical region could be inserted through the incision similar to the conventional anterior thoracotomy approach. The vertebral levels were confirmed by lateral fluoroscopy. For girls with AIS, 30mm-length screws were used for T7, T8 and T9 and 35mm-length screws for T10 vertebrae. The screws were inserted into the vertebral bodies 5mm anterior to the right rib head with a 10° ventral excursion. Two portals with 2.0cm diameter were made on the median axillary line with an interval of two ribs above and below the incision respectively. Screws with 25mm length were selected for proximal vertebrae (often T5, T6). The screws were inserted through the upper portal with the help of thoracoscopic equipments under direct visualization through the thoracotomic incision. The entry points were close to the right rib heads while the ventral excursion angle is no more than 5°. Screws for distal vertebrae (often T11, T12) were inserted with similar technique. 35mm-length screws were used for these lower vertebrae. The entry-point should move 10mm anteriorly away from the rib head with the ventral excursion angle around 15-20°. (Qiu Y, *et al.* 2007) In boys with AIS, the screw length was determined according to preoperative CT scans. The bio-cortical purchase of screw was confirmed by palpating the contralateral tips. Furthermore, the proper screw placement was confirmed by anteroposterior and lateral fluoroscopy.

In patients treated with thoracoscopic approach, surgery was performed under single-lung ventilation. As proposed by Newton *et al.* (Newton PO, *et al.* 2000) and Mehlman *et*

al., (Mehlman CT, *et al.* 1997) the first portal (2cm in diameter) was established in the anterior axillary line at the sixth or seventh intercostal space. After confirming deflation of the lung, three additional portals were placed gradually in the median axillary line under thoracoscopic visualization. The first screw was inserted into the apical vertebra using thoracoscopic instruments under fluoroscopic image guidance with guide wire. The position was confirmed with anteroposterior and lateral fluoroscopic images. The other screws were inserted with similar procedures through the four portals and the entry points and trend of screws were same as Group B. Anteroposterior fluoroscopic image was taken on every screw to confirm proper screw placement.

2.4.1.3 CT scan and analysis

Axial spiral images of the instrumented vertebrae were obtained by a 16-multidetector-spiral CT scanner (LightSpeed, GE Healthcare) two weeks after operation with the following specifications: 320mAs, 120kVp, 5mm thickness, with 5mm gap between slices. CT images were then reconstructed at 1.25mm intervals. The images showing bilateral rib heads and screw were selected for analysis with Dicom Pacs Client on workstation. Several parameters were measured as described by other studies: (Sucato DJ, *et al.* 2004, Bullmann V, *et al.* 2005, Vaccaro AR, *et al.* 2005) (1) Distance a: the distance from the anterior edge of the right rib head to the central line of screw, (2) Distance b: the minimum distance of the screw to the anterior cortex of the spinal canal, (3) Distance c: the minimum distance of the screw to the aorta, (4) Length d: the length of screw tips to the contralateral vertebral cortex, (5) Distance e: distance from the aorta to the closest point of vertebral body cortex, (6) Angle α : the angle subtended by the line joining the left and right rib heads and the line parallel to the axis of screw (figure 1). According to previous studies, (Sucato DJ, *et al.* 2004, Bullmann V, *et al.* 2005, Kuklo TR, *et al.* 2005) the closest distance from the screw tip to aorta was measured and the screws were categorized into three different grades (DAC grades, figure 4): D, the screw was distant from the aorta ($>1\text{mm}$); A, the screw was adjacent to the aorta ($\leq 1\text{mm}$); C, the screw was found to be against the aorta and creating contour deformity. The bicortical purchase of screws was also evaluated. Finally, the screw distant from the aorta and the spinal canal with bicortical purchase was defined to be in a good position and the rate of good position was analyzed.

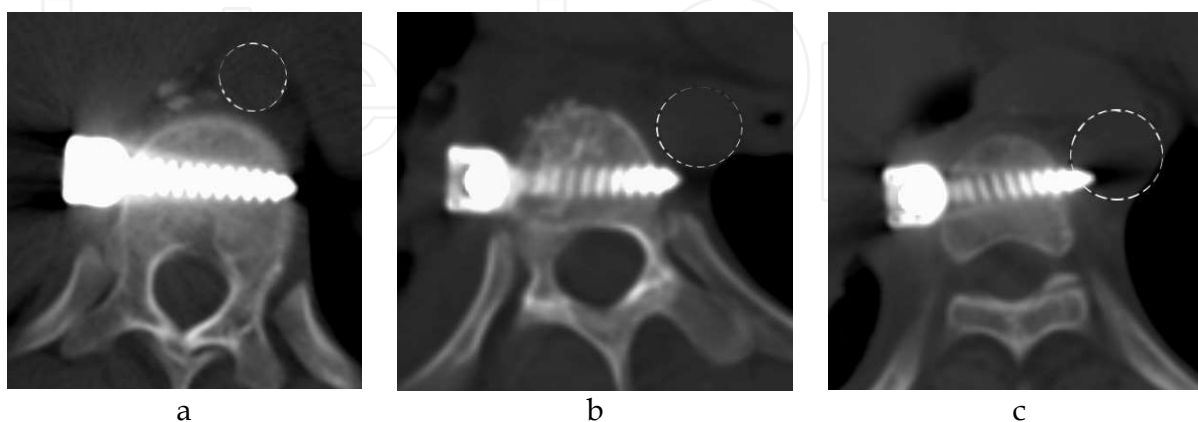


Fig. 4. Relationships between screw tip and aorta. a: the distance between screw tip and the aorta is more than 1mm; b: the screw tip is adjacent to the aorta with the distance no more than 1mm; c: the screw tip shows contour deformity to the aorta.

2.4.1.3 Statistical analysis

The data was analyzed by SPSS software for Windows (10.0, Chicago, IL). Parameters measured at all thoracic instrumented vertebrae in two groups were compared by independent samples t test. The Chi-square test was carried out regarding the DAC grades, bicortical purchase and the good position rate from the thoracic corresponding vertebrae of the two groups. When the cell was less than 5 in number, Fisher exact test was used. Correlation analysis was used to test the relationship between screw insertion accuracy and the Cobb angle of main thoracic curve. The difference was statistically significant when $p < 0.05$.

2.4.2 Results

2.4.2.1 Clinical and radiographic data

In Group A, six patients were instrumented from T5 to T12; the other four patients were instrumented from T5 to T10, T6 to T11, T6 to T12 and T7 to T12, respectively. In Group B, instrumented levels were from T5 to T12 in twelve patients, from T5 to L1 in three patients and from T6 to L1 in six patients. The mean operative time averaged 330 ± 65 min for Group A and 240 ± 57 min for Group B. The difference was statically significant using Student's t test. The saved operative time in Group B was mainly attributing to the faster screw insertion. The main thoracic curve correction rates were 73.6% in Group A and 77.9% in Group B (Table 7). No neurovascular complications were found during the operation and at the last follow-up. Rod breakage was found in one case at two years after operation with Eclipse instrumentation; a 26% loss of curve correction was noted. However, no symptoms were found in this patient. Neither screw loosening nor rod migration was noted. No reversion procedure was needed. There was no implant-related complication in other patients immediately after operation or during follow-up.

2.4.2.2 CT analysis

Seventy-three thoracic vertebral screws were inserted in Group A while 162 in Group B. The distance a, b, c, d, e and angle α showed no significant difference between the two groups at corresponding vertebral levels. However, length d in Group A was smaller than Group B with significant difference at T7 and T8 ($p < 0.05$) (Table 8).

Regarding the location of screws in relation to the aorta, 89.0% of screws in Group A and 80.2% in Group B were at grade D. In Group B, the length d in grade D screws was much less than that in grade A&C screws ($p < 0.05$). Significant negative correlation was found between the main thoracic Cobb angle and the percentage of Grade D screws ($t = -0.794$, $p < 0.01$). The bicortical purchase rate was 89.0% and 87.0% in Group A and B respectively. The good position rate was 74.0% and 66.7% in Group A and B respectively. Two screws in Group B penetrated into the spinal canal, the distance c was -0.51mm and -2.06mm respectively. When comparing the DAC grade, bicortical purchase rate and good position rate, no significant difference was found in screws for all corresponding thoracic vertebrae between the two groups (Table 9).

3. Discussion

3.1 Anatomical relationship between the aorta and thoracic vertebral bodies in RT-AIS

At present, the correction of scoliosis under thoracoscopy has been performed on some thoracic AIS patients, especially those with the Cobb angle less than 70° or relatively flexible

	Group	n	a(mm)	b(mm)	c(mm)	d(mm)	e(mm)	α(°)
T5	A	7	8.9±2.0	7.7±3.4	-11.3±3.7	1.9±2.1	5.8±1.9	1.3±5.3
	B	15	5.9±3.4	5.2±3.3	-6.3±8.2	1.8±2.9	3.0±3.4	6.2±7.5
T6	A	9	9.5±2.8	7.8±3.6	-9.0±6.3	2.0±1.8	5.5±1.7	-2.6±9.3
	B	21	6.9±2.8*	4.3±2.2*	-3.8±7.2	1.0±1.4	3.0±1.1*	-1.6±9.5
T7	A	10	11.4±2.4	7.2±3.6	-6.9±8.7	2.1±2.0	4.2±1.8	-4.4±6.5
	B	21	11.4±3.2	5.9±2.9	-2.7±7.1	4.3±2.3*	3.0±1.3	-8.7±6.9
T8	A	10	11.3±3.3	5.5±4.3	-2.6±8.8	1.4±2.0	4.2±1.5	-5.9±11.3
	B	21	12.2±2.7	5.9±2.5	1.2±7.0	3.7±2.8*	2.9±1.3*	-11.6±7.2
T9	A	10	10.9±2.9	5.3±4.4	0.4±8.0	1.2±1.6	3.1±1.2	-4.4±6.6
	B	21	12.6±2.6	6.0±2.7	3.7±7.6	2.8±3.1	2.4±1.1	-8.9±6.2
T10	A	10	10.0±3.1	6.5±2.9	2.7±6.8	1.2±1.4	2.7±1.1	-1.0±6.2
	B	21	12.4±2.4*	5.9±2.7	6.4±5.3	1.7±1.7	2.4±1.0	-7.8±6.6*
T11	A	9	11.2±3.5	7.6±3.6	4.8±6.8	2.2±1.5	2.3±1.1	3.4±4.2
	B	21	13.7±2.2*	6.7±2.6	7.8±4.5	2.1±2.5	1.8±1.2	-5.2±6.7*
T12	A	8	11.4±3.6	9.6±3.0	6.4±5.3	1.8±1.7	2.9±1.0	10.1±7.5
	B	21	14.4±3.4	8.1±2.6	7.4±4.2	3.4±2.8	1.8±1.3*	1.4±7.6*

Data in each group is normally distributed. The difference was significant when compared with corresponding results in Group A (**p*<0.05, **<0.01).

Table 8. Results of the parameters measured with CT images between patients operated by thoracoscopic and mini-open thoracotomy approaches.

Group	Area	DAC grade				Bicortical purchase		Good position rate (%)	
		D	A	C	%	n	%	n	%
A	Proximal (T5-T7)	22	2	1	84.6	22	84.6	17	65.4
	Periapical (T8-T9)	18	2	0	90	18	90	15	75
	Distal (T10-T12)	25	2	0	92.6	25	92.6	22	81.5
	Total	65	7	1	89	65	89	54	74
B	Proximal (T5-T7)	40	11	6	70.2	50	87.7	32	56.1
	Periapical (T8-T9)	30	2	10	71.4	36	85.7	25	59.5
	Distal (T10-T12)	60	2	1	95.2	55	87.3	51	81
	Total	130	15	17	80.2	141	87	108	66.7

There was no difference at corresponding area with respect to the DAC grade, bicortical purchase and good position rate.

Table 9. Analysis of accuracy of Screw insertion in patients operated by thoracoscopic and mini-open thoracotomy approaches

curve.(Picetti GD, 3rd, *et al.* 2002) The thoracoscopic technique features minimal injury, fewer complications, faster recovery, reduced pain, fewer respiratory compromises and cosmetically a less prominent surgical scar when compared with the traditional anterior

thoracotomic approach.(Picetti G, 3rd, *et al.* 1998, Arlet V 2000, Newton PO, *et al.* 2000, Niemeyer T, *et al.* 2000, Husted DS, *et al.* 2003, Newton PO, *et al.* 2005b) With the increasing popularity of this technique, there has also been an increasing concern over the proximity of the descending aorta to the tips of screws and the possibility of vessel wall erosion over time.(Baker JK, *et al.* 1993, Maruyama T, *et al.* 2004, Sucato DJ, *et al.* 2004, Huitema GC, *et al.* 2006, Zhang H and Sucato DJ 2006) Due to the rotation and distortion of vertebra, the deflected aorta and the deformed morphology of the spinal canal in patients with scoliosis,(Sevastik B, *et al.* 1996, Sucato DJ, *et al.* 2003a, Maruyama T, *et al.* 2004) the insertion of vertebral screws during scoliosis correction may place the patient at risk for aorta injury and violation of the spinal canal. Although no thoracic aorta complication caused by the placement of vertebral screw through thoracoscopic technique in AIS patients has been reported, some aortic complications such as screw penetration,(Matsuzaki H, *et al.* 1993) aortic laceration,(Woolsey RM 1986) false aneurysm of the thoracic aorta(Ahat E, *et al.* 1996, Choi JB, *et al.* 2001) have been found in anterior spinal instrumentation for other diseases.

Proper placement of the screws during anterior corrective surgery of scoliosis showed great importance and challenge to spine surgeons. Picetti *et al.* (Picetti GD, 3rd, *et al.* 2002) suggested usage of capitulum costae and vertebra segment vessel as the position landmark of screw placement. Ebara *et al.* (Ebara S, *et al.* 2000) recommended a new thoracoscopic instrument to measure the transverse diameter of vertebra after removing the intervertebral discs. Despite these studies, there was little information documenting the relationship of the aorta to the thoracic scoliotic spine and little anatomic data based on the pathological morphology of scoliosis. Through analyzing the CT images of the apical vertebra T8 or T9, Sevastik *et al.*(Sevastik B, *et al.* 1996) found that the mean lateral translation distance from the aorta to the mid axis of the vertebral body in the scoliosis group increased, while the vertical distance from the aorta to the mid axis of the vertebral body reduced compared with the adult control group. Liljenqvist *et al.* (Liljenqvist UR, *et al.* 2002) got the same result by measuring the distance from the aorta to the vertebra, without comparing with the normal spine. By analyzing the magnetic resonance images from the fourth thoracic vertebra to the third lumbar vertebra, Sucato *et al.* (Sucato DJ, *et al.* 2003a) found that the aorta was located more laterally and posteriorly relative to the vertebral body in patients with right thoracic idiopathic scoliosis compared with that in patients without scoliosis.

In the present study, the vertebrae from T4 to T12 in patients with scoliosis and age-matched controls were analyzed. A total of 401 vertebrae in the control group and 266 vertebrae in the scoliosis group were measured in the present study, and the parameters of β angle, b value and RV value were taken to ensure the safety of the placement of the screws. The β angle and a value could reflect the safe margin of screw insertion, and the RV value could predict the possibility of spinal cord injury during placement of the screw, then the α angle along with γ angle would show the extent of aortic displacement. The c value provided a reference index in screw length selection.

The displacement of the aorta in patients with scoliosis was expressed as the aorta-vertebral angle or α angle in the present study. Both Sucato *et al.* (Sucato DJ, *et al.* 2003a) and Sevastik *et al.* (Sevastik B, *et al.* 1996) found that the aorta was positioned more posteriorly in patients with AIS than in patients with a normal spine. The present study showed that α angle was smaller in the scoliosis group than that in the age matched control group at every vertebra, and the differences were significant from T5 to T10 ($p < 0.01$) particularly close to the apex of the curve (T7 to T9), with an angle of 45.2° and 26.9° , respectively, at the seventh thoracic vertebrae in control and scoliosis group; 50.3° and

31.5°, respectively, at the eighth thoracic vertebrae; and 54.8° and 37.6°, respectively, at the ninth thoracic vertebrae. As the rotational deformity increased in the scoliosis group, the α angle relative to the vertebral body decreased, and this negative correlation was significant in the periapical levels. The vertebral rotation was significant in the apex and the γ angle was 13.4°, which was similar with the report of Sucato *et al.* (Sucato DJ, *et al.* 2003a) But at proximal and distal thoracic levels, the vertebrae rotated to the convex side and γ angle turned out to be negative.

The safe margin for screw insertion was affected by the displacement of the aorta. The aorta arch was located more anterior to the vertebra at T4 level (β angle was 29.1°, b was 17.3 mm), which indicated that the screw placement in T4 was safe and unlikely to injure the aorta unless the insertion angle exceeded 29°. From T5 to T12, compared with that in the control group, β angle and a values in scoliosis group were relatively lower, the difference in β angle at T7–T10 levels and a value at T9, T10 levels are significant (Figure 2). It showed that the aorta was positioned more posteriorly to vertebrae and a safe margin for screw insertion decreased especially at the apex of the curve (T7–T10), where the vertebra rotation angle (c) was increased. Sucato *et al.* (Sucato DJ, *et al.* 2004) analyzed the accuracy of the vertebral screw placed following thoracoscopic anterior instrumentation. Fifteen (14.2%) of 106 screw tips were adjacent to the aorta, and there were 13 (12.3%) screws that were thought to create a contour deformity of the aorta. During Maruyama's (Maruyama T, *et al.* 2004) study, the aorta was found to be located posteriorly between T6 and T9 in patients with AIS, at these levels the aorta was found to be crossed by a line that passed the anterior edge of the bilateral rib heads in 33 of 40 vertebrae, so giving up the bicortical screw position at these levels were suggested. In the present study, the a value was minimum (4–8 mm) and from T5 to T9 in the scoliosis group the aorta was very close to the lateral wall of the vertebra. According to β angle, the safe ventral excursion angle couldn't exceed 5° at T6 and T7, 10° at T5 and T8 and 12° at T9, respectively. To get the bicortical fixation without violating the aorta, the screw could run nearly parallel to the posterior wall of the vertebral body directed to the rib head of the opposite side. In addition, the safe ventral excursion angle couldn't exceed 17° at T10 and 20° at T4, T11 and T12 while bicortical fixation was also recommended.

In the study of Sucato *et al.*, (Sucato DJ, *et al.* 2004) four screws at proximal and distal thoracic levels (T5, T6, and two at T12) were found to be violating the posterior cortex of the vertebral body. Zhang and Sucato (Zhang H, *et al.* 2006) have studied the position of the rib head with respect to the spinal canal and vertebral body in both normal patients and those with right thoracic AIS using MRI. They have found that the percent of the vertebra obscured by the rib head significantly decreased from T4 to T12 in both groups and no significant difference was found at the same thoracic levels between the two groups. They concluded that when placing anterior thoracic screws at the caudal thoracic spine (T10–T12), staying anterior to the rib head was important to avoid penetration into the spinal canal. In the present study, the vertical distance from Line RR to the anterior wall of the spinal canal (a) decreased steadily from T4 to T12 in both groups, while it turned out to be negative from T10 to T12 with the minimum negative value, -6 mm in the scoliosis group. The RV value was significantly lower in the scoliosis group at all segment levels but T12, which was opposite to Zhang *et al.* (Zhang H, *et al.* 2006) In the scoliosis group, the RV value was 0.5 ± 3.0 mm at the tenth thoracic vertebrae, -1.4 ± 1.9 mm at the 11th thoracic vertebrae and -1.6 ± 3.3 mm at the 12th thoracic vertebrae. Because the RV value (the vertical distance from the line RR to the anterior wall of the spinal canal) decreased steadily from the cephalic to the caudal levels of the spine in both groups and

became negative at T11 and T12 in the scoliosis group, the risk of screw violating into spinal canal would increase when the screw entry-point was still close to the rib head. Considering the screw was usually 6.5 or 5.5 mm in diameter, we recommend 3–5 mm ventral shift to the rib head at T10–T12 and be parallel to the rib head at T4–T9.

The screw length, which could be estimated by measuring the transverse diameter of vertebra on the CT scanning, was generally longer than that of the reported results. (Liljenqvist UR, *et al.* 2002) The c value at the fourth to the 12th thoracic reported the vertebral deformation of scoliosis, but in the present study the transverse diameter of the vertebral body showed no significant difference at any of the segment levels except for T7 between the two groups. It posed problems with present instrumentation systems that the incremental changes in screw length was 5 mm. Large increments would increase the risk of vascular injuries to the thoracic vertebrae. According to the present results, we suggested that the optimal screw length be 25 mm from T4 to T6 and 30 mm from T7 to T9, 35 mm from T10 to T12.

3.2 Dynamic changes of the relationship between thoracic aorta and vertebrae

3.2.1 Pleura closure

The anatomic relationship between thoracic aorta and vertebrae studied on the preoperative CT scans was static. During operation, the surgical procedures would release the paraspinal tissues which may result in a dynamic change of the relationship and affect the safety of screw insertion. Two studies on aorta shifting following curve correction of thoracic AIS have been reported. By studying the pre- and post-operative CT images, Kuklo *et al.* (Kuklo TR, *et al.* 2005) found the descending aorta moved antero-medially with curve correction. However, because the main emphasis in this study was given to the accuracy of screw placement, the position of the aorta relative to vertebral body was only recorded using a semi-quantitative clock method, and no further analyses were done on the shifting of thoracic aorta postoperatively. Recently, in a prospective study taken by Bullmann *et al.*, (Bullmann V, *et al.* 2006) the position of aorta in 25 consecutive patients with right thoracic AIS treated with anterior spinal fusion were studied. Base on the preoperative MRI and postoperative axial CT scans, the author concluded that the aorta had migrated from postero-lateral to a more antero-medial position after curve correction. This migration is maximal at the apex vertebra. The patients were scanned in supine position during MRI which differs from the lateral position in CT scanning thus making it difficult to calculate the real changes in aortic position postoperatively.

In the present prospective study, the changes of angle α , distance a and b in anterior instrumentation supported the fact that the aorta shifted antero-medially following curve correction. Same as Bullman, most significant shifting were found in periapical vertebrae. In group B, however, no shifting of aorta was found though the curve was equally well corrected as group A. To minimize the variation between pre- and post-operative images, same scanning technique and patients' position were used. Never the less, the metallic artifacts in some post-operative images would make the margin vertebrae and aorta hard to distinguish. In that case the margin of vertebrae and aorta would be determined by exploring on serial CT images. Another weak point in this study is all the images were parallel to transverse plane. The tilt of vertebrae might be changed by curve correction so it's ideal do measurement on the pre- and post-operative images made exactly through the same plane of each vertebrae. However, it's unavailable for the CT machine used. The images with similar morphology of vertebrae and aorta were selected for measurement to minimize the variation.

Several procedures in anterior spinal instrumentation might be responsible for the antero-medial aorta shifting. Opening and dissecting of the parietal pleura followed by cutting of the right segmental vessels along the periapical vertebrae could mobilize the aorta. Then following disectomy, the partially spontaneous vertebral derotation could contribute in part to the anterior shifting of aorta with increased angle α and distance a . By curve correction after instrumentation, much more aorta shifting would be gain. Moreover, the giving up pleura closure following with curve correction were also thought to help in allowing the aorta to transpose anteriorly by Crawford. (Crawford AH 2004) As the pleura were sutured in all patients in the present study, we would test the hypothesis in further study. In group B, no shifting of aorta was found, which can probably be explained by the absence of soft tissue release and vertebral derotation, and thoracic kyphosis. One of the concerns on the ligation and dissection of the segmental vessels and aorta shifting is the risk of spinal cord ischemia. (Orchowski J, *et al.* 2005) However, these have not been thought as the potential risk factor of neurological deficits of surgical correction for scoliosis in several previous studies. (MacEwen GD, *et al.* 1975, Orchardski J, *et al.* 2005, Coe JD, *et al.* 2006, Qiu Y, *et al.* 2008b) Our previous study (Wu L, *et al.* 2006) has showed that the occlusion of the segmental vessels could cause a temporary change of SEP monitoring but will return to its normal baseline within 17minutes and no neurologic complication was found in all patients. In the present study no abnormality was found by intro-operation SEP monitoring and no neurologic deficit was occurred in all patients after operation.

Since part of vertebral derotation was achieved before screw placement, the maximum ventral excursion angle for screw insertion could be increased slightly. After curve correction, with more anterior shifting of aorta the risk of aorta locating in the axis of screw would be diminished. However, as the distance between aorta and vertebral body was decreased, the bi-cortical inserted screws have higher risk of aorta encroaching if it's located on the screw axis. A feasible way to improve the critical situation is to use screws with shorter increment. Results from previous and present studies have shown that the risk of aorta encroaching by vertebral screws were relatively higher in patients instrumented by screws with 5mm increment (Sucato DJ, *et al.* 2003a, Kuklo TR, *et al.* 2005) when compared with those treated by screws with 2.5mm increment. (Bullmann V, *et al.* 2005) One of the reasons is the increment of vertebral width in thoracic vertebrae was 1.2mm per level. (Sucato DJ, *et al.* 2003a) Moreover, screws with blunt tips would also help to diminish the risk of aorta penetrating.

3.2.2 Pleura in non-closure

It was speculated that leaving the parietal pleura in no closure would allow more freedom for the aorta transposition which would reduce the risk of aortic injuries from screw tips impingement. (Crawford AH 2004) This hypothesis was supported partially by the results of the present study, for it was shown that the aorta located more laterally from the vertebral body after operation. By quantitative analysis of the pre- and post-operative CT scans of the thoracic spine these patients without closure of the pleura, it was found that angle α and the distance between the aorta and rib head decreased while the distance between aorta and vertebrae increased in post-operative CT images, indicating the aorta migrated posterolaterally during and after operation. The increased distance between the aorta and vertebral body lead to an increased safe margin for the bi-cortical penetrated screw tips which would lessen the risk of the late complication of aorta impingement. The posterior migration of the aorta observed in the current study would lead to a smaller safe space of screw tip

accommodation between aorta and rib heads (especially in T7 and T8 with angle α less than 25°). The risk of the aorta touching the trajectory of the vertebral screw increased with the decrease of angle α . However, the potential risk maybe diminished by the lateral migration of aorta with the distance b increased to 5.7mm, 7.9mm and 8.0mm in T6, T7 and T8 respectively. Migration of the thoracic aorta in patients with main right thoracic IS treated with posterior spinal instrumentation or anterior spinal instrumentation with pleura closure has been reported previously. (Bullmann V, *et al.* 2006, Wang W, *et al.* 2008) In patients treated with posterior spinal instrumentation only, no change was found on the relative position of the aorta to the vertebrae. However, these studies showed that patients who were treated with anterior curve correction with pleural closure the thoracic aorta migrated antero-medially, (Bullmann V, *et al.* 2006, Wang W, *et al.* 2008) which was attributed to releasing the aorta through pleural dissection and derotation of the curve. By comparing with the study from Wang *et al.*, (Wang W, *et al.* 2008) the clinical data and surgical outcomes were quite similar in terms of pre-op coronal and sagittal Cobb angle, curve flexibility, curve correction rate, pre-op and post-op AVT translation (Table 8 and 9). In the present study, by leaving the parietal pleura in non-closure, the post-operative CT imaging showed that the aorta was in a more postero-lateral position than its pre-operative location. Considering other factors which may be related to the aorta transposition are similar between Wang's and the current study, the contradiction on the direction of aortic migration strongly indicated the effect of pleural closure in affecting the post-operative position of the thoracic aorta. Two factors may contribute to the postero-lateral migration of the aorta in this study. Firstly, the wide range of dissection and stripping of the pleura. The parietal pleura was longitudinally incised from T5 to T12, and was peeled away from the vertebral body. On the convex side, the parietal pleura were elevated from the vertebrae and retracted to the right rib head. On the concave side, the parietal pleura were peeled off from the vertebral body to the contralateral side and swabs were inserted under the parietal pleura to bluntly push away the aorta from the vertebrae. Secondly, the segmental vessels were ligated and cut during surgery which may release the tension on the parietal pleural from restoring to its original position. More importantly, the divided vessels would be pushed laterally apart with their associated parietal pleura to visualize the vertebral body, which may additionally cause the aorta to migrate to a more postero-lateral position. In addition, it has been reported that the aorta would migrate to a more postero-lateral location when the patient is in a supine position and more antero-medial in a prone position. (Sucato DJ and Elerson E 2003b) In the present study, both pre- and post-operative CT scans of all subjects were carried out in a supine position.

One of the concerns of leaving the pleura in a non-closed state is the thoracic drainage. (Newton PO, *et al.* 2000, Sucato DJ, *et al.* 2003a) Increased thoracic drainage was also found in the present study. In previous study, the chest tube drainage in scoliotic patients after anterior instrumentation were 210 ± 90 ml (with parietal pleural closure) and 500 ± 160 ml (without parietal pleural closure), respectively. (Qiu Y, *et al.* 2008a) In the present study, the average thoracic drainage observed in the current study was 450 ml and the duration for chest tube drainage was averaged 3.1 days. But besides the relative increased volume and duration of chest tube drainage, no other related complication occurred in this series. So it is worthwhile to leave the parietal pleural unclosed after anterior corrective surgery in particular patients with relative smaller safe margin for vertebra screw insertion.

The problem of the metallic artifacts can't be denied in current study which would make the margin of vertebrae and aorta hard to distinguish in some post-operative images. In that case the borderline of vertebrae and aorta would be determined by exploring on upper and lower serial CT images.

In order to prevent the potential vascular injury without loss the accuracy of screw insertion, sacrificing bi-cortical penetration or optimal alignment of screws (Maruyama T, *et al.* 2004) and not closing the parietal pleura (Crawford AH 2004) were recommended options. In the case of the aorta being closely adhered to the vertebral body (distance b less than 2 mm) or the aorta closer to the pathway of vertebral screws (angle α less than 45°) on pre-operative CT scanning, the result of the present study suggested to keep the pleura open so as to increase the safe distance between the aorta and vertebrae, which will lessen the risk of screw tip impingement on the aorta. In patients whose aorta are away from the trajectory of vertebral screws (angle α larger than 45°), the pleural closure should be attempted. For patients receiving anterior release surgery, a postero-lateral positioned aorta with the parietal pleura open could decrease the risk of pedicle screw impingement on the aorta during pedicle screw insertion on the concave side of the thoracic curve.

3.3 Accuracy of vertebral screw

In anterior spinal instrumentation through thoracoscopic approach, one of the main concerns is the potential risk of damage to the spinal cord and aorta caused by the vertebral screws. The rotation of vertebrae makes the determination of the direction of screws difficult. In addition, the thoracic aorta was found to displace more laterally and posteriorly in relation to the vertebral body in patients with main thoracic AIS. (Sevastik B, *et al.* 1996, Sucato DJ, *et al.* 2003a, Maruyama T, *et al.* 2004, Qiu Y, *et al.* 2007) Thoracoscopic instrumentation is also technically demanding and requiring a longer duration of surgery with a sharp learning curve. (Grewal H, *et al.* 2005, Lonner BS, *et al.* 2005, Newton PO, *et al.* 2005a) Majority of the reports have found that the curve correction by thoracoscopic anterior instrumentation was as effective as the conventional thoracotomy approach. (Mehlman CT, *et al.* 1997, Picetti G, 3rd, *et al.* 1998, Faro FD, *et al.* 2005, Grewal H, *et al.* 2005) However, whether the vertebral screws inserted through thoracoscopic approach carries the same accuracy rate as the thoracotomy approach has not been properly studied. In the present study, the CT images of vertebral screws inserted through thoracoscopic and mini-open thoracotomy approach were compared. The relative position between the screw and the spinal canal, between the screw and the aorta and the bicortical purchase were quantitatively analyzed and compared.

Migration of vertebral screws into spinal canal has been reported. (Sucato DJ, *et al.* 2004, Huitema GC, *et al.* 2006, Qiu Y, *et al.* 2007) In a consecutive series of 17 patients with thoracolumbar idiopathic scoliosis treated with anterior spinal instrumentation, three vertebral screws were found penetrating into the spinal canal in two patients with three and 15 month postoperative leg pain respectively. (Huitema GC, *et al.* 2006) In patients with right thoracic AIS, the distance from the line joining the left and right rib heads to the anterior wall of the spinal canal was significantly lower from T4 to T11 compared with normal subjects. (Qiu Y, *et al.* 2007) Furthermore, in order to escape from the posteriorly located aorta, the ventral excursion of a screw might be limited or even become negative (dorsally excursion). In the study by Sucato *et al.*, (Sucato DJ, *et al.* 2004) the screw-to-spinal-canal distance averaged at 5.3mm from the coronal axis. Four of 106 screws were found to encroach into the canal by $<2\text{mm}$. In the present study, the minimum distance of the screw to the anterior cortex of the spine canal were 7.05mm and 6.02mm in average in Group A and B respectively, showing adequate safe zone between the screw and the spinal canal in both groups. No significant difference was found between the two groups. In Group B, the spinal canal cortex was found to be penetrated by two screws. One screw at T5 encroached

into the canal by 0.51mm, while the other one at T7 by 2.06mm. There was no neurologic complication observed in these two cases. This might be due to the minor encroachment of screws. It has been suggested that encroachment of less than 4mm into the canal by pedicle screws is probably safe.(Gertzbein SD and Robbins SE 1990, Sucato DJ, *et al.* 2004)

To achieve maximum pullout strength, the bicortical screw fixation with anterior spinal instrumentation was found mandatory in several biomechanical studies.(Lowe T, *et al.* 2002, Huang TJ, *et al.* 2003) In the present study, 89.0% and 87.0% of screws inserted through the thoracoscopic and mini-open thoracotomy approach showed bicortical purchase. The results were comparable with those of Bullmann *et al.*(Bullmann V, *et al.* 2005) in anterior dual rod instrumentation in which 88% of screws were found to have a bicortical purchase. The high rate of bicortical screw fixation might be partly attributed to the good preoperative anatomical assessment of the vertebral diameter.(Qiu Y, *et al.* 2007) In addition, the palpating of the tip of screw from the contralateral side of the vertebra enhanced the accuracy of placement in Group B, while the fluoroscopic guidance during screw insertion raised the rate in Group A. The bicortical screws, however, might result in critical proximity of the screw to the thoracic aorta. The life-threatening aortic complications caused by the penetrating of thoracic vertebral screw into the aorta can be found in the literature. Matsuzaki *et al.*(Matsuzaki H, *et al.* 1993) reported direct aortic screw penetration after anterior spinal fusion from T5 to T10 for thoracic myelopathy. Ohnishi *et al.*(Ohnishi T, *et al.* 2001) reported a case of delayed aortic rupture from pulsation of the aorta adjacent to the plate after anterior instrumentation and fusion from T10 to T12 for a T11 burst fracture via a left thoraco-abdominal approach. In thoracic AIS, Sucato *et al.*(Sucato DJ, *et al.* 2004) found that in 106 vertebral screws inserted thoracoscopically, 15 (14.2%) screws were adjacent to the aorta while 13 (12.3%) were thought to create a contour deformity. According to Kuklo's(Sucato DJ, *et al.* 2004) study the risk was significantly higher ($\chi^2=4.897$, $P=0.027$) when compared with the screws inserted through a thoracotomy approach. However, the differences in the experience and technique of different surgeons do not allow any reliable conclusion that the screws inserted by thoracoscopy has runs a higher risk of aortic impingement. The screws were all inserted by the same team of surgeons in the present study, which greatly diminished the variation of surgical techniques. The rate of screw causing contour deformity of the aorta was similar between the two groups. This demonstrated that thoracoscopic approach did not increase the risk of aorta impingement when compared with conventional mini-open thoracotomy approach. It has been a main concern that screws causing contour deformity of aorta could have high risk of aortic complication. From the literature, the actual outcomes has not been well documented. In the studies of Kuklo *et al.*(Kuklo TR, *et al.* 2005) and Sucato *et al.*,(Sucato DJ, *et al.* 2004) no aortic complication caused by these screws was found and the patients remain asymptomatic . In the present study the screws with grade C were followed up regularly and all patients remained asymptomatic. Similar to previous two studies,(Sucato DJ, *et al.* 2004, Kuklo TR, *et al.* 2005) aortography would be recommended for all suspected patients to confirm whether the screws have encroached into the aorta or leading to disruption of the aortic wall which may require removal or shortening. In future operation, measurement of the vertebral diameter on preoperative CT or magnetic resonance images could further help accurate screw length determination.

The impingement of the aorta by screw might be partially attributed to the large increments of screws. Previous studies have shown that the vertebral body width increased gradually from T4 to T12 with an average increment of 1.1mm or 1.2mm.(Sucato DJ, *et al.* 2003a, Bullmann V, *et al.* 2005) However, the screws used at our institution and by Sucato *et*

al.(Sucato DJ, *et al.* 2004) and Kuklo *et al.*(Kuklo TR, *et al.* 2005) have an increment interval of 5mm. The excessive contralateral penetration by screws would increase the risk of aorta impingement. This assumption was also supported by the study of Bullmann *et al.*(Bullmann V, *et al.* 2005) 226 screws with 2.5mm increment were inserted in standard anterior open dual-rod instrumentation in thoracic AIS while all of them were at least 1mm away from the aorta. In agreement with Sucato *et al.*, (Sucato DJ, *et al.* 2004) we also suggested that screws with smaller increment intervals should be used to get good bicortical screw purchase but at the same time without excessive contralateral penetration. Another reason for screw proximity to the aorta is the migration of the aorta with curve correction. The studies by Kuklo *et al.*(Kuklo TR, *et al.* 2005) and Bullmann *et al.*(Bullmann V, *et al.* 2006) have demonstrated that the posterolateral location of the aorta in thoracic AIS will shift anteromedially with anterior spinal instrumentation. The distance between the vertebrae and the aorta decreased significantly from 5.5mm to 3.7mm at the apical and periapical vertebrae. The curve severity was also found to attribute to the risk of aorta impingement by vertebral screws in the present study. The significant negative correlation between the Cobb angle of thoracic curve and the percentage of Grade D screws indicated that with the increasing of thoracic curve, the vertebral screws have a higher risk of being adjacent to or contouring a deformity of the aorta. This could be explained by the more severe vertebral tilt and rotation in larger curve and much more migration of the aorta after curve correction. According to previous studies, (Sucato DJ, *et al.* 2004, Bullmann V, *et al.* 2005, Kuklo TR, *et al.* 2005) the screws which were bicortically purchased but away from the aorta and the spinal canal were defined to be in a good position. In the present study, the rate of good position increased from proximal area to distal in both groups, which was thought to be attributed to the increment of vertebral morphology.(Kuklo TR, *et al.* 2005) When compared between the groups, the rate in Group A was higher than that in Group B. This was the same in all corresponding thoracic vertebrae, although the difference was not statistically significant. According to our experience, the higher rate of good position of screw insertion in Group A may be attributed to more frequent and careful fluoroscopic verification during surgery.

4. Conclusion

The advent of CT has revolutionized diagnostic radiology in the past decades. Through the series CT scanning-based studies on the patients with RT-AIS, a systematical understanding on the anatomic relationship between vertebral bodies and paraspinal tissues was achieved. According to our findings, to place the thoracoscopic vertebral screw safely, at the cephalad thoracic spine (T4-T6), the maximum ventral excursion angle should decrease gradually from 20° to 5°, the entry-point of the screw should be close to the rib head and the optimal screw length was 25 mm. At apical area (T7-T9), the maximum ventral excursion angle should increase gradually from 5° to 12°, and the optimal screw length was 30 mm. At the caudal thoracic spine (T10-T12), the maximum ventral excursion angle increased, the entry-point should shift 3~5 mm ventrally and the optimal screw length was 35 mm. In addition, dynamic changes of the anatomic relationship between thoracic aorta and vertebrae were identified in RT-AIS during anterior spinal instrumentation and fusion. When the pleura were sutured, significant antero-medial shifting of the thoracic aorta could be achieved. More space would be freed for screw excursion, but the aorta is closer to vertebral body with less safe area for contralateral screw penetration. In contrast, if the pleura were not sutured, the aorta would shift to a more postero-lateral position. In this case, the safe distance between the aorta and vertebrae increased, which will lessen the risk of screw tip impingement on the aorta.

With the knowledge, vertebral screws inserted through thoracoscopic approach could have comparable accuracy with mini-open thoracotomy approach in terms of relative position between the screws and the spinal canal, between the screws and the aorta, the bicortical screw purchase rate and rate of good position. Furthermore, the accuracy could be enhanced by using screws with smaller increments, being aware of the migration of the aorta with anterior spinal instrumentation and keeping the curve severity under consideration.


In addition, the variation of the vertebral rotation and morphology in different patients should also be taken into consideration. A preoperative measurement of CT scanning may be helpful in determining the precise screw selection. However, it should be kept in mind that the radiation exposure during CT scans might do harm to patients especially to children i.e. the radiation-induced carcinogenesis. (Brenner DJ and Hall EJ 2007) Hence the magnetic resonance imaging may serve as an optional media instead of the CT scans in future.

5. References

- [1] Ahat E, Tuzun H, Bozkurt AK, et al. False aneurysm of the descending aorta due to penetrating injury. *Injury* 1996;27:225-6.
- [2] Arlet V. Anterior thoracoscopic spine release in deformity surgery: a meta-analysis and review. *Eur Spine J* 2000;9 Suppl 1:S17-23.
- [3] Baker JK, Reardon PR, Reardon MJ, et al. Vascular injury in anterior lumbar surgery. *Spine (Phila Pa 1976)* 1993;18:2227-30.
- [4] Brenner DJ and Hall EJ. Computed tomography--an increasing source of radiation exposure. *N Engl J Med* 2007;357:2277-84.
- [5] Bullmann V, Fallenberg EM, Meier N, et al. The position of the aorta relative to the spine before and after anterior instrumentation in right thoracic scoliosis. *Spine (Phila Pa 1976)* 2006;31:1706-13.
- [6] Bullmann V, Fallenberg EM, Meier N, et al. Anterior dual rod instrumentation in idiopathic thoracic scoliosis: a computed tomography analysis of screw placement relative to the aorta and the spinal canal. *Spine (Phila Pa 1976)* 2005;30:2078-83.
- [7] Choi JB, Han JO and Jeong JW. False aneurysm of the thoracic aorta associated with an aorto-chest wall fistula after spinal instrumentation. *J Trauma* 2001;50:140-3.
- [8] Coe JD, Arlet V, Donaldson W, et al. Complications in spinal fusion for adolescent idiopathic scoliosis in the new millennium. A report of the Scoliosis Research Society Morbidity and Mortality Committee. *Spine (Phila Pa 1976)* 2006;31:345-9.
- [9] Crawford AH. Position of the aorta relative to the spine in idiopathic scoliosis. *J Bone Joint Surg Am* 2004;86-A:429; author reply -30.
- [10] Dunn HK. Anterior spine stabilization and decompression for thoracolumbar injuries. *Orthop Clin North Am* 1986;17:113-9.
- [11] Ebara S, Kamimura M, Itoh H, et al. A new system for the anterior restoration and fixation of thoracic spinal deformities using an endoscopic approach. *Spine (Phila Pa 1976)* 2000;25:876-83.
- [12] Faro FD, Farnsworth CL, Shapiro GS, et al. Thoracic vertebral screw impingement on the aorta in an in vivo bovine model. *Spine (Phila Pa 1976)* 2005;30:2406-13.
- [13] Gertzbein SD and Robbins SE. Accuracy of pedicular screw placement in vivo. *Spine (Phila Pa 1976)* 1990;15:11-4.
- [14] Grewal H, Betz RR, D'Andrea LP, et al. A prospective comparison of thoracoscopic vs open anterior instrumentation and spinal fusion for idiopathic thoracic scoliosis in children. *J Pediatr Surg* 2005;40:153-6; discussion 6-7.

- [15] Huang TJ, Hsu RW, Tai CL, et al. A biomechanical analysis of triangulation of anterior vertebral double-screw fixation. *Clin Biomech (Bristol, Avon)* 2003;18:S40-5.
- [16] Huitema GC, van Rhijn LW and van Ooij A. Screw position after double-rod anterior spinal fusion in idiopathic scoliosis: an evaluation using computerized tomography. *Spine (Phila Pa 1976)* 2006;31:1734-9.
- [17] Husted DS, Yue JJ, Fairchild TA, et al. An extrapedicular approach to the placement of screws in the thoracic spine: An anatomic and radiographic assessment. *Spine (Phila Pa 1976)* 2003;28:2324-30.
- [18] Krismer M, Bauer R and Sterzinger W. Scoliosis correction by Cotrel-Dubousset instrumentation. The effect of derotation and three dimensional correction. *Spine (Phila Pa 1976)* 1992;17:S263-9.
- [19] Kuklo TR, Lehman RA, Jr. and Lenke LG. Structures at risk following anterior instrumented spinal fusion for thoracic adolescent idiopathic scoliosis. *J Spinal Disord Tech* 2005;18 Suppl:S58-64.
- [20] Lenke LG, Betz RR, Harms J, et al. Adolescent idiopathic scoliosis: a new classification to determine extent of spinal arthrodesis. *J Bone Joint Surg Am* 2001;83-A:1169-81.
- [21] Liljenqvist UR, Allkemper T, Hackenberg L, et al. Analysis of vertebral morphology in idiopathic scoliosis with use of magnetic resonance imaging and multiplanar reconstruction. *J Bone Joint Surg Am* 2002;84-A:359-68.
- [22] Lonner BS, Scharf C, Antonacci D, et al. The learning curve associated with thoracoscopic spinal instrumentation. *Spine (Phila Pa 1976)* 2005;30:2835-40.
- [23] Lowe T, O'Brien M, Smith D, et al. Central and juxta-endplate vertebral body screw placement: a biomechanical analysis in a human cadaveric model. *Spine (Phila Pa 1976)* 2002;27:369-73.
- [24] Lowe TG, Edgar M, Margulies JY, et al. Etiology of idiopathic scoliosis: current trends in research. *J Bone Joint Surg Am* 2000;82-A:1157-68.
- [25] MacEwen GD, Bunnell WP and Sriram K. Acute neurological complications in the treatment of scoliosis. A report of the Scoliosis Research Society. *J Bone Joint Surg Am* 1975;57:404-8.
- [26] Maruyama T, Takeshita K, Nakamura K, et al. Spatial relations between the vertebral body and the thoracic aorta in adolescent idiopathic scoliosis. *Spine (Phila Pa 1976)* 2004;29:2067-9.
- [27] Matsuzaki H, Tokuhashi Y, Wakabayashi K, et al. Penetration of a screw into the thoracic aorta in anterior spinal instrumentation. A case report. *Spine (Phila Pa 1976)* 1993;18:2327-31.
- [28] Mehlman CT, Crawford AH and Wolf RK. Video-assisted thoracoscopic surgery (VATS). Endoscopic thoracoplasty technique. *Spine (Phila Pa 1976)* 1997;22:2178-82.
- [29] Newton PO, Parent S, Marks M, et al. Prospective evaluation of 50 consecutive scoliosis patients surgically treated with thoracoscopic anterior instrumentation. *Spine (Phila Pa 1976)* 2005a;30:S100-9.
- [30] Newton PO, Shea KG and Granlund KF. Defining the pediatric spinal thoracoscopy learning curve: sixty-five consecutive cases. *Spine (Phila Pa 1976)* 2000;25:1028-35.
- [31] Newton PO, White KK, Faro F, et al. The success of thoracoscopic anterior fusion in a consecutive series of 112 pediatric spinal deformity cases. *Spine (Phila Pa 1976)* 2005b;30:392-8.
- [32] Niemeyer T, Freeman BJ, Grevitt MP, et al. Anterior thoracoscopic surgery followed by posterior instrumentation and fusion in spinal deformity. *Eur Spine J* 2000;9:499-504.

- [33] Ohnishi T, Neo M, Matsushita M, et al. Delayed aortic rupture caused by an implanted anterior spinal device. Case report. *J Neurosurg* 2001;95:253-6.
- [34] Orchowski J, Bridwell KH and Lenke LG. Neurological deficit from a purely vascular etiology after unilateral vessel ligation during anterior thoracolumbar fusion of the spine. *Spine (Phila Pa 1976)* 2005;30:406-10.
- [35] Parent S, Labelle H, Skalli W, et al. Morphometric analysis of anatomic scoliotic specimens. *Spine (Phila Pa 1976)* 2002;27:2305-11.
- [36] Picetti G, 3rd, Blackman RG, O'Neal K, et al. Anterior endoscopic correction and fusion of scoliosis. *Orthopedics* 1998;21:1285-7.
- [37] Picetti GD, 3rd, Pang D and Bueff HU. Thoracoscopic techniques for the treatment of scoliosis: early results in procedure development. *Neurosurgery* 2002;51:978-84; discussion 84.
- [38] Qiu Y, He YX, Wang B, et al. The anatomical relationship between the aorta and the thoracic vertebral bodies and its importance in the placement of the screw in thoracoscopic correction of scoliosis. *Eur Spine J* 2007;16:1367-72.
- [39] Qiu Y, Wang B and Zhu F. Comparison of the curative effects of video assisted thoracoscopic anterior correction and small incision, thoracotomic anterior correction for idiopathic thoracic scoliosis. *Chin Med J (Engl)* 2008a;121:1369-73.
- [40] Qiu Y, Wang S, Wang B, et al. Incidence and risk factors of neurological deficits of surgical correction for scoliosis: analysis of 1373 cases at one Chinese institution. *Spine (Phila Pa 1976)* 2008b;33:519-26.
- [41] Sevastik B, Xiong B, Hedlund R, et al. The position of the aorta in relation to the vertebra in patients with idiopathic thoracic scoliosis. *Surg Radiol Anat* 1996;18:51-6.
- [42] Sucato DJ and Duchene C. The position of the aorta relative to the spine: a comparison of patients with and without idiopathic scoliosis. *J Bone Joint Surg Am* 2003a;85-A:1461-9.
- [43] Sucato DJ and Elerson E. A comparison between the prone and lateral position for performing a thoracoscopic anterior release and fusion for pediatric spinal deformity. *Spine (Phila Pa 1976)* 2003b;28:2176-80.
- [44] Sucato DJ, Kassab F and Dempsey M. Analysis of screw placement relative to the aorta and spinal canal following anterior instrumentation for thoracic idiopathic scoliosis. *Spine (Phila Pa 1976)* 2004;29:554-9; discussion 9.
- [45] Vaccaro AR, Yuan PS, Smith HE, et al. An evaluation of image-guided technologies in the placement of anterior thoracic vertebral body screws in spinal trauma: a cadaver study. *J Spinal Cord Med* 2005;28:308-13.
- [46] Wang W, Zhu Z, Zhu F, et al. The changes of relative position of the thoracic aorta after anterior or posterior instrumentation of type I Lenke curve in adolescent idiopathic thoracic scoliosis. *Eur Spine J* 2008;17:1019-26.
- [47] Wang WJ, Yeung HY, Chu WC, et al. Top theories for the etiopathogenesis of adolescent idiopathic scoliosis. *J Pediatr Orthop* 2011;31:S14-27.
- [48] Weinstein SL, Dolan LA, Cheng JC, et al. Adolescent idiopathic scoliosis. *Lancet* 2008;371:1527-37.
- [49] Woolsey RM. Aortic laceration after anterior spinal fusion. *Surg Neurol* 1986;25:267-8.
- [50] Wu L, Qiu Y, Ling W, et al. Change pattern of somatosensory-evoked potentials after occlusion of segmental vessels: possible indicator for spinal cord ischemia. *Eur Spine J* 2006;15:335-40.
- [51] Zhang H and Sucato DJ. Regional differences in anatomical landmarks for placing anterior instrumentation of the thoracic spine in both normal patients and patients with adolescent idiopathic scoliosis. *Spine (Phila Pa 1976)* 2006;31:183-9.



Computed Tomography - Clinical Applications

Edited by Dr. Luca Saba

ISBN 978-953-307-378-1

Hard cover, 342 pages

Publisher InTech

Published online 05, January, 2012

Published in print edition January, 2012

Computed Tomography (CT), and in particular multi-detector-row computed tomography (MDCT), is a powerful non-invasive imaging tool with a number of advantages over the others non-invasive imaging techniques. CT has evolved into an indispensable imaging method in clinical routine. It was the first method to non-invasively acquire images of the inside of the human body that were not biased by superimposition of distinct anatomical structures. The first generation of CT scanners developed in the 1970s and numerous innovations have improved the utility and application field of the CT, such as the introduction of helical systems that allowed the development of the "volumetric CT" concept. In this book we want to explore the applications of CT from medical imaging to other fields like physics, archeology and computer aided diagnosis. Recently interesting technical, anthropomorphic, forensic and archeological as well as paleontological applications of computed tomography have been developed. These applications further strengthen the method as a generic diagnostic tool for non-destructive material testing and three-dimensional visualization beyond its medical use.

How to reference

In order to correctly reference this scholarly work, feel free to copy and paste the following:

Yong Qiu (2012). Application of CT Scanning in the Studies of Minimal Invasive Thoracoscopic Surgery of Adolescent Idiopathic Scoliosis, *Computed Tomography - Clinical Applications*, Dr. Luca Saba (Ed.), ISBN: 978-953-307-378-1, InTech, Available from: <http://www.intechopen.com/books/computed-tomography-clinical-applications/application-of-ct-scanning-in-the-studies-of-minimal-invasive-thoracoscopic-surgery-of-adolescent-id>

INTeCH
open science | open minds

InTech Europe

University Campus STeP Ri
Slavka Krautzeka 83/A
51000 Rijeka, Croatia
Phone: +385 (51) 770 447
Fax: +385 (51) 686 166
www.intechopen.com

InTech China

Unit 405, Office Block, Hotel Equatorial Shanghai
No.65, Yan An Road (West), Shanghai, 200040, China
中国上海市延安西路65号上海国际贵都大饭店办公楼405单元
Phone: +86-21-62489820
Fax: +86-21-62489821

© 2012 The Author(s). Licensee IntechOpen. This is an open access article distributed under the terms of the [Creative Commons Attribution 3.0 License](https://creativecommons.org/licenses/by/3.0/), which permits unrestricted use, distribution, and reproduction in any medium, provided the original work is properly cited.

IntechOpen

IntechOpen