

We are IntechOpen, the world's leading publisher of Open Access books Built by scientists, for scientists

6,900

Open access books available

185,000

International authors and editors

200M

Downloads

Our authors are among the

154

Countries delivered to

TOP 1%

most cited scientists

12.2%

Contributors from top 500 universities



WEB OF SCIENCE™

Selection of our books indexed in the Book Citation Index
in Web of Science™ Core Collection (BKCI)

Interested in publishing with us?
Contact book.department@intechopen.com

Numbers displayed above are based on latest data collected.
For more information visit www.intechopen.com



Perforated Appendicitis

Ali Akbar Salari

*Shahid Sadoughi University of Medical Science, Yazd,
Iran*

1. Introduction

1.1 General consideration

All physicians should have a thorough knowledge of appendicitis. Although most patients with acute appendicitis can be easily diagnosed, there are many in whom the signs and symptoms are quite variable, and a firm clinical diagnosis may be difficult to establish. It is for this reason that the diagnosis is made rather liberally, with the full expectation that some patients will be operated on and found to have a normal appendix. It is preferable to maintain broad indications, as this tends to include the group of patients with indefinite signs and symptoms who actually have the disease but do not fulfill the classic criteria for the diagnosis. Following this course, patients who might proceed to perforation of the appendix, with a host of possible secondary complications, are spared that fate. Therefore, it is generally agreed that 10% to 15% of patients having a diagnosis of acute appendicitis by acceptable standards in most hospitals will actually be found at operation to have a normal appendix.

2. Anatomy

The vermiform appendix is located in the right lower quadrant, arises from the cecum, and is generally 6 to 10 cm in length. It has a separate mesoappendix with an appendicular artery and vein that are branches of the ileocolic vessels. The appendix is lined with colonic epithelium characterized by many lymph follicles numbering approximately 200, with the highest number occurring in the 10- to 20-year-old age group. After the age of 30, the number of lymph follicles is reduced to a trace, with total absence of lymphoid tissue occurring after the age of 60. The appendix may lie in a number of locations, essentially at any position on a clock wise rotation from the base of the cecum. It is important to emphasize that the *anatomic* position of the appendix determines the symptoms and the site of the muscular spasm and tenderness when the appendix becomes inflamed (Fig. 1)

2.1 Pathophysiology

It is widely accepted that the inciting event in most instances of appendicitis is obstruction of the appendiceal lumen. This may be due to lymphoid hyperplasia, inspissated stool (a fecalith), or some other foreign body. Given the correlation with the incidence of appendicitis by age and the size and distribution of the lymphoid tissue, it is likely that lymphoid obstruction or partial obstruction of the lumen is a common cause. Obstruction of

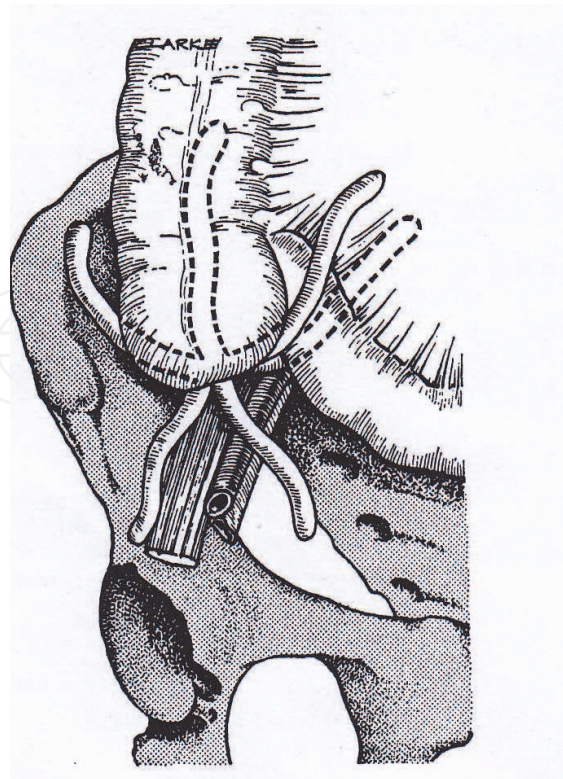


Fig. 1. The various possible positions of the appendix vermiformis

the lumen leads to bacterial overgrowth as well as continued mucous secretion. This causes distention of the lumen, and the intraluminal pressure increases. This may lead to lymphatic and then venous obstruction. With bacterial overgrowth and edema, an acute inflammatory response ensues. The appendix then becomes more edematous and ischemic. Necrosis of the appendiceal wall subsequently occurs along with translocation of bacteria through the ischemic wall. This is gangrenous appendicitis. Without intervention, the gangrenous appendix will perforate with spillage of the appendiceal contents into the peritoneal cavity. If this sequence of events occurs slowly, the appendix is contained by the inflammatory response and the omentum, leading to localized peritonitis and eventually an appendiceal abscess. If the body does not wall off the process, the patient may develop diffuse peritonitis.

2.2 Bacteriology

The flora in the noninflamed appendix is similar to the colon with a variety of facultative aerobic and anaerobic bacteria found; hence, the bacteria involved in appendicitis are the same as for other colonic disease. The incidence of obtaining positive cultures from the peritoneal cavity depends on the stage of appendicitis found. In patients with acute, nonperforated appendicitis, peritoneal fluid will culture bacteria in fewer than half of the patients. However, Peritoneal cultures will be positive in more than 85% of patients with gangrenous or perforated appendicitis. The number of bacterial species that can be cultured depends on how vigorously the investigators attempt to isolate them, with some investigators showing an average of more than nine different species. In 1938, Altemeier clearly demonstrated the polymicrobial nature of perforated appendicitis, and for practical purposes little has changed.

The usefulness of routine peritoneal cultures in patients with perforated appendicitis has been questioned. The flora are generally known, the results are not available for several days, and many times, no change in treatment plan is made despite culture results. It appears reasonable to avoid routine cultures and to obtain them only in patients with persisting infection or surgical site infection.

3. Clinical diagnosis

The diagnosis of acute appendicitis is made primarily on the basis of the history and the physical findings, with additional assistance from laboratory examinations. The *typical* history is one of onset of generalized abdominal pain followed by anorexia and nausea. The pain then becomes most prominent in the epigastrium and gradually moves toward the umbilicus, finally localizing in the right lower quadrant. Vomiting may occur during this time. Examination of the abdomen usually shows diminished bowel sounds, with direct tenderness and spasm in the right lower quadrant. As the process continues, the amount of spasm increases, with the appearance of rebound tenderness. The temperature is usually mildly elevated (approximately 38° C.) and usually rises to higher levels in the event of perforation. Direct tenderness is usually present in the right lower quadrant and may involve other parts of the abdomen, particularly if perforation has occurred. The appendix is usually situated at or around McBurney's point (a point one third of the way on a line drawn from the anterior superior spine to the umbilicus). However, it must be emphasized that the exact *anatomic location* of the appendix can be at any point on a 360-degree circle surrounding the base of the cecum, as shown in (Figure 1) This is the site where the pain and tenderness are usually maximal, and the exact site may vary from patient to patient.

Rovsing's sign, elicited when pressure applied in the left lower quadrant reflects pain to the right lower quadrant, is often present. The psoas sign may be positive and is elicited by extension of the right thigh with the patient lying on the left side. As the examiner extends the right thigh with stretching of the muscle, pain suggests the presence of an inflamed appendix overlying the psoas muscle. The obturator sign can be elicited with the patient in the supine position with passive rotation of the flexed right thigh. Pain with this maneuver indicates a positive sign. Rectal examination generally elicits tenderness at the site of the inflamed appendix in the right lower quadrant. If the appendix ruptures, abdominal pain becomes intense and more diffuse, the muscular spasm increases, and there is a simultaneous increase in the heart rate above 100, with a rise in temperature to 39° or 40° C. At this time, the patient appears toxic, and it becomes obvious that the clinical situation has deteriorated.

Olivier Monneuse and colleague, in France from 2002-2005 review of 326 patients, this study was designed to quantify the proportion of patients with a preoperative diagnosis of acute appendicitis that had isolated right lower quadrant pain without biological inflammatory sign's and then to determine which imaging examination led to the determination of the diagnosis.

The diagnosis acute appendicitis can not be excluded when an adult patient present with isolated rebound tenderness in the right lower quadrant even without fever and biological inflammatory signs.

Author's study of total 465 patients with abdominal pains referred to the two main hospitals Yazd Iran during 10 months 400 cases confirmed appendicitis 335 patients had anorexia.

Anorexia increases probability of appendicitis but its absences can not rule out diagnosis of acute appendicitis.

3.1 Imaging studies

Abdominal radiographs obtained in the evaluation of patients with acute abdominal pain typically include the flat and upright abdominal radiograph, as well as a chest radiograph. This sequence of studies may be useful in patients with atypical presenting symptoms and physical signs. However, plain abdominal radiographs should not be considered "routine" or "mandatory" components of the evaluation of patients with acute abdominal pain. Pneumoperitoneum on an upright abdominal radiograph suggests a diagnosis other than appendicitis. Rarely does a perforated appendix present with pneumoperitoneum (1 to 2%). Abdominal radiographs may demonstrate a fecalith, localized ileus, or loss of the peritoneal fat stripe. Gas in the appendix is not a sign specific for appendicitis and should not mandate laparotomy for appendicitis.

3.2 Computed Tomography

Recent improvements in CT technology have improved image resolution to the 0.5- to 1.0-cm range, thus improving the accuracy of CT scanning. Typically, CT has been reserved for patients with an equivocal history and physical and laboratory findings. CT is useful in patients with an observed inflammatory abdominal process, and the presentation is atypical for appendicitis. The accuracy of CT is greatest when a deliberate effort is made to visualize the appendix. Although some reports discount the use of intravenous contrast agent and only limited enteric contrast agent, the optimal technique requires complete small bowel opacification. The terminal ileum and cecum must be filled with contrast agent to improve the recognition of the normal or abnormal appendix and to avoid confusing unopacified ileal loops with the appendix. Unless contraindicated, intravenous contrast agent should be used as well. Specific, fine (5-mm) image intervals should be obtained in the region of the appendix.

In general, CT findings of appendicitis increase with the severity of the disease. The normal appendix appears as a thin tubular structure in the right lower quadrant that may or may not opacity with contrast. Appendicoliths appear as ring like homogeneous calcifications and are seen in approximately 25% of the population.

Classically, a CT diagnosis of acute appendicitis includes an abnormal appendix with periappendiceal inflammation. The appendix is considered abnormal when it is distended or thickened and greater than approximately 5 to 7 mm in size. The wall of the inflamed appendix is circumferentially thickened and may appear as a "halo" or "target." CT findings of periappendiceal inflammation suggest appendicitis; these include periappendiceal abscess, fluid collections, edema, and phlegmon. Periappendiceal inflammation or edema is visualized as clouding of the mesenteric fat ("dirty fat"), local fascial thickening, and ill-defined right lower quadrant soft tissue densities. Intravenous contrast agent-enhanced studies help to define the inflamed appendiceal and periappendiceal tissue. CT is especially useful in distinguishing those patients presenting late in their clinical course (48 to 72 hours) who may have developed a phlegmon or abscess, thus altering potential therapy.

The true sensitivity of CT in diagnosing acute appendicitis is unknown. Retrospective studies, studies of consecutive patients, and studies with debatable inclusion criteria have made the application of CT to individual patients with a truly equivocal presentation (those

who have undergone non diagnostic ultrasonography, evaluation by an experienced surgeon, and a brief period of repetitive examination) problematic. A reasonable estimate is that CT is 90% sensitive to the detection of intra-abdominal inflammation, with an 80 to 90% positive predictive value.

3.3 Barium enema

The barium enema has been used as a diagnostic adjunct in evaluating patients with equivocal clinical signs of appendicitis. This study was used primarily in the 1970s and early 1980s before the availability of CT and higher-quality ultrasonography. A positive study may show nonfilling of the appendix with indentation of the cecum, indicative of pericecal inflammation. A false-negative study (partial filling of appendix) can occur in up to 10% of patients. The equivocal study can occur in up to 40% of patients evaluated with this technique, due principally to partial filling of the appendix. Barium enema is no longer routinely used to evaluate patients with suspected acute appendicitis.

3.4 Ultrasound

Ultrasonography is often used as the initial diagnostic imaging study in the majority of patients in whom the clinical diagnosis of appendicitis is equivocal. Ultrasound is noninvasive and rapidly available and avoids radiation exposure. Most studies of graded compression ultrasound demonstrate a sensitivity of more than 85% and a specificity of more than 90%. However, the sonogram for appendicitis is a highly operator-dependent study. Sonographic criteria for the diagnosis of acute appendicitis are the demonstration of a noncompressible appendix of 7 mm or greater in anteroposterior diameter, the presence of an appendicolith, interruption of the continuity of the echogenic submucosa, and periappendiceal fluid or mass. A fecalith in combination with localized right lower quadrant pain is highly diagnostic of appendicitis. False-positive studies can be due to secondary inflammation of the appendix as a result of inflammatory bowel disease, salpingitis, or other causes. False-negative sonograms are usually due to nonvisualization of a retrocecal appendix and a gasfilled cecum, which prevents visualization of the appendix. In addition, perforation significantly decreases the diagnostic accuracy of graded compression of the appendix. Thus, the ultrasonographic diagnosis of perforated appendicitis depends on the secondary findings on periappendiceal fluid, mass, and loss of the integrity of the submucosa layer. Gaseous distention of the right lower quadrant bowel loops or prolonged symptoms suggesting perforation should make CT the preferred imaging study for improved accuracy and potential utility in planning intervention for appendiceal abscess or phlegmon.

In one study the role of diagnosis imaging in the management of patients with a suspicious of appendicitis is controversial. Early report of good result, with a low frequency of negative appendectomies based on ultrasound or CT Scan. Have been followed by other investigators with contradictory results. The encouraging results reported by toorenvliet et al from Leiden, the Netherlands, using routine ultrasonography and limited CT Scan, must therefore be put into perspective.

4. Laboratory finding

The clinical history and physical examination are most important in establishing a diagnosis of acute appendicitis, but laboratory findings may be helpful. The majority of patients with

acute appendicitis have an elevated leukocyte count of 10,000 to 20,000. For those in whom the level is normal, there is generally a shift to the left in the differential leukocyte count, indicating acute inflammation. However, it should be emphasized that a number of patients have a *normal* leukocyte count, especially the elderly. Urinary analysis may show a few red cells, indicating some inflammatory contact with the ureter or urinary bladder; a significant number of erythrocytes in the urine indicates a primary disorder of the urinary tract.

4.1 Perforated Appendicitis

The management of perforated or gangrenous appendicitis varies somewhat from that of acute nonperforated disease. In these patients, the appendix has already perforated, so the need for urgent intervention is less obvious. Patients with perforated appendicitis will often have a longer duration of symptoms, high fever, and a higher white blood count. Most of these patients are volume depleted and require several hours or more of fluid resuscitation before operative intervention. It is important to ensure that the patient has been adequately resuscitated before undertaking an operation. Patients with perforated disease have established peritonitis and should receive appropriate broad-spectrum intravenous antibiotic therapy, which should start as soon as the diagnosis is established." The duration of therapy is controversial. Some authors recommend an empiric time of treatment such as 7 or 10 days. Others suggest treatment until the patient is afebrile with a normal white blood cell count.

As with acute appendicitis, there are two possible approaches: an open laparotomy or laparoscopy. There is some controversy about the use of laparoscopy in patients with advanced disease because the incidence of postoperative intra-abdominal abscess formation in some series has been markedly higher with laparoscopy than with an open approach. Our approach to appendicitis is outlined.

Our study is on 500 patients refereed two main hospitals in Yazd Iran from 1998-1999 to appendectomy : 87% of the patients had acute appendicitis 9.5% perforated appendix (the report by Rao and his calleagues at the Massachusetts general hospital perforation rate of appendix was 14%) and 3.5% normal appendix : which early diagnosis reduced perforated appendicitis.

4.2 Appendicitis in patients with AIDS or HIV Infection

The incidence of acute appendicitis in HIV-infected patients is re-ported to be 0.5%. This is higher than the 0.1 to 0.2% incidence reported for the general population. The presentation of acute appendicitis in HIV-infected patients is similar to that of noninfecied patients. The majority of HIV-infected patients with appendicitis will have fever, periumbilical pain radiating to the right lower quadrant (91%), right lower quadrant tenderness (91%), and rebound tenderness (74%). HIV-infected patients will not manifest an absolute leukocytosis; however, if a baseline leukocyte count is available, nearly all HIV-infected patients with appendicitis will demonstrate a relative leukocytosis.

4.3 Late cases of appendicitis

In late cases of appendicitis that have led to a very diffuse or general peritonitis, or in those cases of a very fulminating type that are associated with a rapid form of spreading peritonitis, it is often impossible to make a certain diagnosis. Distinction has to be made from the following:

- Primary pneumococcal peritonitis
- Secondary general peritonitis due to other causes (rupture of gastric, duodenal, typhoid, stercoral, or carcinomatous ulcer or of a pyosalpinx)
- Thrombosis of mesenteric vessels
- Acute intestinal obstruction
- Acute pancreatitis
- Pylephlebitis
- In finding out the exact cause, the greatest importance attaches to the history.

5. Special features of acute appendicitis

Appendicitis in infants and young children is difficult to diagnose preoperatively, since these patients cannot provide a history. Therefore, it is unusual to make a firm diagnosis in a patient under the age of 1 year unless perforation has occurred.

Acute appendicitis during pregnancy also presents diagnostic problems, because during the third trimester, the uterus is rapidly enlarging and causes displacement of the cecum and appendix into the right upper abdomen. Thus, acute appendicitis in these patients causes symptoms and signs higher and more lateral during the third trimester.

In one study by Roland E. Anderson from Sweden, sonography more sensitive in first trimester of pregnancy (81.6%) in second trimester in 58.1% and third trimester 57.9%. But CT Scan in first trimester less than 2nd and 3rd trimester. So abdominal sonography essential diagnosis for lower quadrant pain in pregnant women in pregnancy. If sonography doesn't help, spiral CT Scan for treatment is useful.

5.1 Presentation with a mass or late complicated appendicitis

Two to five percent of patients with appendicitis present with a palpable right lower quadrant mass. This can represent either a discrete abscess or phlegmonous inflammation. (Fig.2) The management of these patients has been somewhat controversial on a number of issues. Historically, this has been fueled by equivocal imaging studies that could not reliably corroborate the physical findings and an inability to reliably drain an abscess percutaneously. There also has been a bias toward early removal of the perforated appendix/appendiceal abscess to "control intra-abdominal sepsis." The preferred approach to the management of the appendiceal mass is percutaneous drainage, which is performed under image guidance (ultrasound or CT) and intravenous antibiotics directed against aerobic gram-negative and anaerobic organisms. Numerous studies have documented the safety and efficacy of this approach. In late, complicated appendicitis, appendectomy can be a hazardous procedure. Surgery at this stage can serve to disseminate a localized inflammatory process; to injure surrounding inflamed or edematous bowel, resulting in fistulas; or to require more extensive procedures, such as cecectomy or right hemicolectomy. Authors studies Intrabdominal abscess formation after appendectomy may be intrapritoneal and extrapritoneal causes by primary and secondary infection. Abscess well be in different part of abdomen such as subdiaphragmatic, subhepatic, pelvis and midabdomen. Each one has special clinical signs and diagnosis and treatment.

Bradly and Isaacs in 1978 review of 2621 cases of acute appendicitis treated between 1962 and 1976 in Atlanta found that only 2% had an appendix abscess on admission, and has the average duration of symptom was 9 days.

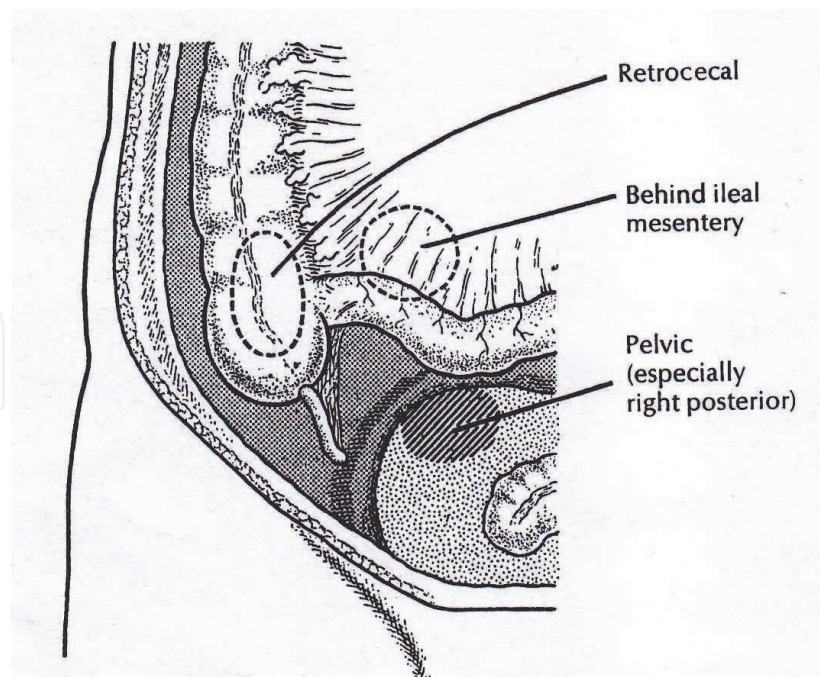


Fig. 2. Those sites where an abscess resulting from Appendicitis may sometimes be overlooked

5.2 Differential diagnosis

There are a number of acute abdominal disorders producing signs and symptoms similar to those of acute appendicitis. These include acute gastroenteritis, cholecystitis, pyelitis, salpingitis, tuboovarian abscess, and ruptured ovarian cyst. Although diarrhea may occur with acute appendicitis, it is much more common with gastroenteritis. In young children, intussusception enters the differential diagnosis. Other less common differential disorders include ureteral stones, cystitis, perforated peptic ulcer, ectopic pregnancy, acute regional enteritis (particularly the first attack), epididymitis, and testicular torsion. If a patient persists in having pain in the right lower quadrant that cannot be explained by some other definitive diagnosis, the patient should be considered to have acute appendicitis and should be operated on or at least carefully observed.

A report of 74 year old female had occasionally experienced right lower abdominal pain in the past. She underwent a barium enema, which revealed a wall irregularity around the appendix, but the appendix itself was not visualized. The patient was referred to hospital for possible appendiceal neoplasm. Colonoscopy revealed a tumor like protrusion with marked redness at the entrance to the appendix. Pathologic analysis of biopsy specimens revealed only inflammatory cells. Differential diagnosis appendiceal crohn's disease or appendiceal neoplasm was made and laparoscopic appendectomy was performed. Pathological results appendiceal crohn's disease was made.

6. Treatment

For the vast majority of patients with a diagnosis of acute appendicitis, the appropriate management is appendectomy. For patients with simple acute appendicitis, intravenous fluids should be initiated as well as an antibiotic agent effective against both aerobic and

anaerobic organisms. All patients are begun on antibiotics preoperatively and maintained post-operatively as needed. If the appendix is unruptured and not gangrenous, antibiotics can be discontinued after 24 hours. Although many agents are effective, cefoxitin is often the agent of choice on the basis of a multicenter randomized trial of 1735 patients. Half received 2 gm. of cefoxitin preoperatively. Three groups were evaluated: patients with a normal appendix, those with an acutely inflamed appendix, and those with a gangrenous appendix. The incidence of wound infection was significantly lower in all three groups. However, the formation of intra-abdominal abscess was not influenced by preoperative antibiotics. In a recent double-blind controlled study, prophylactic cefotetan was compared with prophylactic cefoxitin in the development of postoperative wound infections in patients with acute nonperforated appendicitis. The results showed that single-dose cefotetan and multiple-dose cefoxitin are equally effective. However, because of the greater convenience and decreased cost, single-dose cefotetan was considered the prophylaxis of choice in appendectomy for nonperforated appendicitis. Clindamycin with an aminoglycoside is indicated when *Bacteroides fragilis* is present; metronidazole can also be used for this organism.

6.1 Types of treatment

The treatment of appendicitis varies somewhat depending on the stage of the disease. In general, patients should receive fluid resuscitation before surgery, but this may require only 1 or 2 hours in patients with nonperforated disease.

6.2 Acute medical

Patients with acute, non perforated appendicitis should undergo urgent appendectomy. There have been very few studies examining the role of antibiotic therapy alone for appendicitis. Eriksson and Granstrom performed a randomized trial of antibiotic therapy versus surgery for patients with appendicitis. In a small number of patients, the initial success with medical therapy was 95%, but there was a recurrence rate of 35% with short follow-up. Antibiotics alone have been used in rare situations such as with sailors on long submarine tours. Due to the high recurrence rate, the current standard is operative treatment for acute appendicitis. There is a general consensus that prophylactic antibiotics should be administered before the start of the operation, but in acute disease, we use only a single dose. There are a wide number of agents that can be used as long as they provide activity against enteric anaerobics and gram-negative bacteria. We use a single dose of cefoxitin or cefotetan for prophylaxis.

In the past, the incidence of removing a normal appendix was acceptable if it was 20%. However, rates much lower than this have been quoted. An overall negative exploration rate of 20% should not be viewed as an appropriate standard with the availability of ultrasound- and CT-assisted diagnosis. The negative exploration rate in females is still slightly higher than that in males due to the confusion with diseases of the fallopian tubes and ovaries.

Authors study to compare risk of wound infection after appendectomy with and without irrigation after closure of fascia of external oblique muscle and before closure of skin. 200 patients were randomized in two groups: 99 in irrigation group and 101 in control group: irrigation group has significantly less wound infection after appendectomy.

Clinical trial patients with acute appendicitis are generally in the early stages of disease with inflaming and simple appendicitis. They are not suppurated, gangrene and perforated stages yet; therefore the use of antibiotic prophylaxis can be prevented to save the suffering

from antibiotic in a few days as well as the lowering the cost . In our study two groups of patients, one group given antibiotic prophylaxis before operation, other group not given antibiotic. There was a meaningful relation between the experimental group and the contrast one that the cause of reduction can not be related to antibiotic.

6.3 Antibiotic as definitive therapy

Traditional management of acute appendicitis has emphasized emergent surgical management. This approach has been based on the theory that, over time, simple appendicitis will progress to perforation, with resulting increases in morbidity and mortality. As a result, a relatively high negative appendectomy rate has been accepted to avoid the possibility of progression to perforation. Recent data suggest that acute appendicitis and acute appendicitis with perforation maybe separate disease entities with distinct pathophysiology. A time series analysis performed on a 25-year data set did not find a significant negative relationship between the rates of negative appendectomy and perforation. A study analyzing time to surgery and perforation demonstrated that risk of rupture is minimal within 36 ours of symptom onset. Beyond this point, there is about a 5% risk of rupture in each ensuing 12-hour period. However, in many patients the disease will have an indolent course. In one study 10 of the 18 patients who did not undergo operation for 6 days after their symptoms began did not experience rupture.

One study by Krisna K. Varadhan and Colleagues in Nottingham UK, Antibiotic treatment has been shown to be effective in treating selected patients with acute appendicitis, and three randomized controlled trials (RCTs) have compared the efficacy of antibiotic therapy alone with that of surgery for acute appendicitis. The purpose of this meta analysis of RCTs was to assess the outcome with these two therapeutic modalities. Of the 350 patients randomized to the antibiotic group, 238 (68%) were treated successfully with antibiotics alone and 38 (15%) were readmitted. The remaining 112 (32%) patients randomized to antibiotic therapy crossed over to surgery for a variety of reasons. At 1 year, 200 patients in the antibiotic group remained asymptomatic.

This meta-analysis suggest that although antibiotic may be used as primary treatment for selected patients with suspected uncomplicated at present. Selection bias and crossover to surgery in the RCTs suggest that appendectomy is still the gold standard therapy for acute appendicitis .

6.4 Surgical

There are two approaches to removal of the non perforated appendix: through an open incision, usually a transverse right lower quadrant skin incision (Davis-Rockey) or an oblique version (McArthur-McBurney) with separation of the muscles in the direction of their fibers, or a paramedian incision, but this is not routinely done. The incision is centered on the midclavicular line. Occasionally, where the diagnosis is uncertain, a periumbilical midline incision can be used. Once the peritoneum is entered, the appendix is delivered into the field. This can usually be accomplished with careful digital manipulation of the appendix and cecum. It is important to avoid too extensive of a blind dissection. In difficult cases, extending the incision 1 to 2 cm can greatly simplify the procedure. Once the appendix is delivered into the wound, the mesoappendix is sacrificed between clamps and ties. There are several ways to handle the actual removal of the appendix. Some surgeons simply suture ligate the base of the appendix and excise it. Others place a purse string or Z-

stitch in the cecum, excise the appendix, and invert the stump into the cecum. We have used both approaches. Once the appendix is removed, the cecum is returned to the abdomen, and the peritoneum is closed. The wound is closed primarily in most patients with non perforated appendicitis because the risk of infection is less than 5%.

Acute appendicitis is one of the commonest of surgical emergencies and appendectomy has become established as the gold standard of therapy. However as the diagnosis of appendicitis in most centers is mainly a clinical one, based on history and examinations diagnostic uncertainty in patients with suspected appendicitis may lead to delay in treatment or negative surgical exploration, adding to the morbidity associated with the condition.

6.5 Laparoscopy

Semm first reported successful laparoscopic appendectomy in, 1983, several years before the first laparoscopic cholecystectomy. However, the widespread use of the laparoscopic approach to appendectomy did not occur until after the success of laparoscopic cholecystectomy. This may be due to the fact that appendectomy, by virtue of its small incision, is already a form of minimal-access surgery.

Laparoscopic appendectomy is performed under general anesthesia. A nasogastric tube and a urinary catheter are placed prior to obtaining a pneumoperitoneum. Laparoscopic appendectomy usually requires the use of three ports. Four ports may occasionally be necessary to mobilize a retrocecal appendix. The surgeon usually stands to the patient's left. One assistant is required to operate the camera.(fig 3) One trocar is placed in the umbilicus

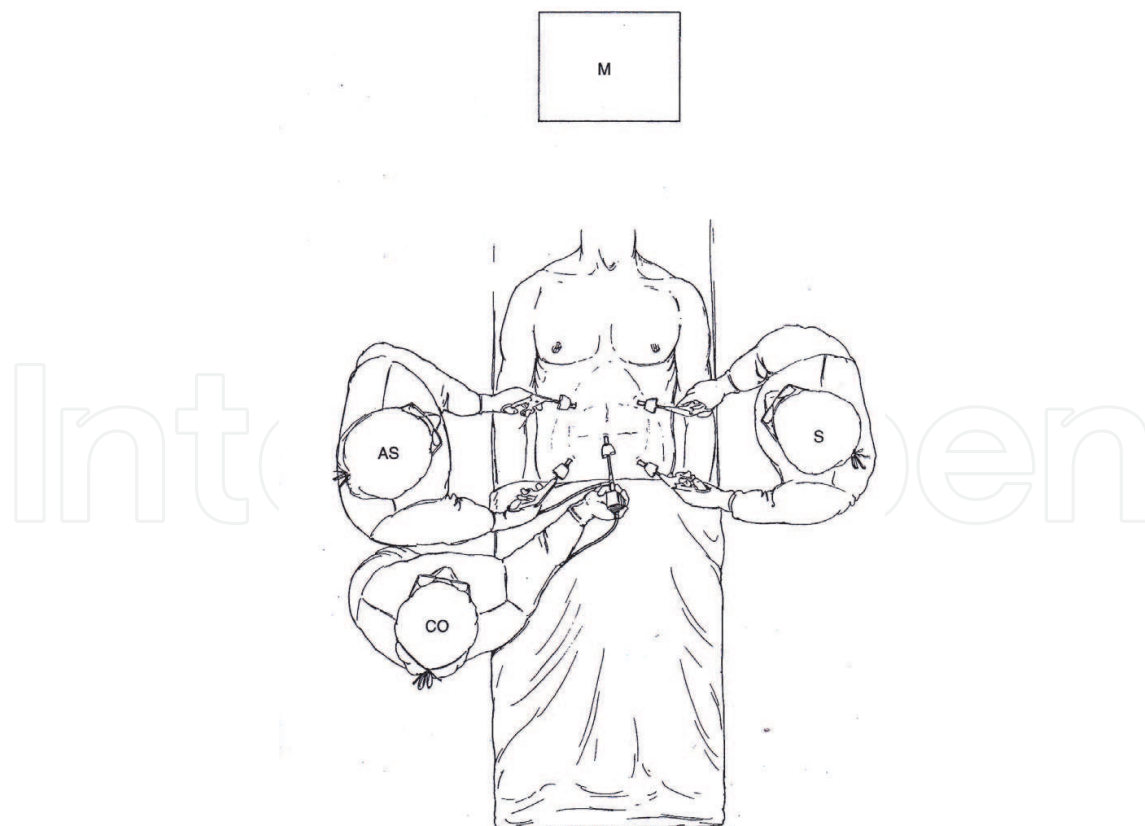


Fig. 3. Diagram of the operating room setup. CO, camera operator AS, assistant surgeon; M. monitor, S, surgeon. Monitor includes VDO, Video cassette recorder, and printer.

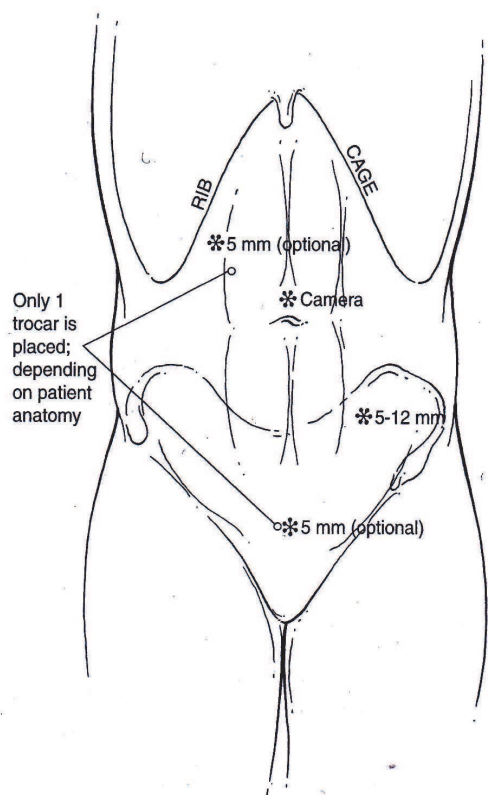


Fig. 4. Port site placement for laparoscopic appendectomy aright upper quadrant or suprapubic trocar is placed depending on patient anatomy

(10 mm), with a second trocar placed in the suprapubic position. Some surgeons will place this second port in the left lower quadrant. The suprapubic trocar is either 10 or 12 mm, depending on whether a linear stapler will be used. The placement of the third trocar (5 mm) is variable and is usually either in the left lower quadrant, epigastrium, or right upper quadrant. Placement is based on location of the appendix and surgeon preference. Initially, the abdomen is thoroughly explored to exclude other pathology. The appendix is identified by following the anterior taeniae to its base. Dissection at the base of the appendix enables the surgeon to create a window between the mesentery and base of the appendix (Fig. 4). The mesentery and base of the appendix are then secured and divided separately. When the mesoappendix is involved with the inflammatory process, it is often best to divide the appendix first with a linear stapler, and then to divide the mesoappendix immediately adjacent to the appendix with clips, electrocautery, Harmonic Scalpel, or staples. The base of the appendix is not inverted. The appendix is removed from the abdominal cavity through a trocar site or within a retrieval bag. The base of the appendix and the mesoappendix should be evaluated for hemostasis. The right lower quadrant should be irrigated. Trocars are removed under direct vision.

6.6 Natural Orifice Transluminal Endoscopic Surgery

Natural orifice transluminal endoscopic surgery (NOTES) is a new surgical procedure using flexible endoscopes in the abdominal cavity. In this procedure, access is gained by way of organs that are reached through a natural, already-existing external orifice. The hope for advantages associated with this method include the reduction of postoperative pain, shorter convalescence, avoidance of wound infection and abdominal-wall hernias, and the absence of scars. The first case of transvaginal removal of a normal appendix has recently been reported. Much work remains to determine if NOTES provides any additional advantages over the laparoscopic approach to appendectomy.

6.7 Outcomes

The mortality rate after appendectomy is less than 1% the morbidity of perforated appendicitis is higher than that of nonperforated cases and is related to increased rates of wound infection, intra-abdominal abscess formation, increased hospital stay, and delayed return to full activity.

Surgical site infections are the most common complications seen after appendectomy. About 5% of patients with uncomplicated appendicitis develop wound infections after open appendectomy. Laparoscopic appendectomy is associated with a lower incidence of wound infections; this difference is magnified among groups of patients with perforated appendicitis (14% versus 26%). Patients with a fever and leukocytosis and a normal appearing wound after appendectomy undergo CT or ultrasonography to exclude an intra abdominal abscess. Similarly, if pus emanates from a fascial opening during wound inspection, an imaging study is obtained to identify any undrained intra abdominal fluid collections. In this situation, we place a percutaneous drain into the collection to divert the infected material away from the fascia and facilitate wound healing. For pelvic abscesses that are located in proximity to the rectum or vagina, we prefer ultrasound-guided transrectal or transvaginal drainage, thereby avoiding the discomfort of a percutaneous perineal drain.

7. Tumors

Appendiceal malignancies are extremely rare. Primary appendiceal cancer is diagnosed in 0.9 to 1.4% of appendectomy specimens. These tumors are only rarely suspected preoperatively. Additionally, less than 50% of cases are diagnosed at operation. Most series report that carcinoid is the most common appendiceal malignancy, representing more than 50% of the primary lesions of the appendix. However, a recent review from The National Cancer Institute's Surveillance, Epidemiology, and End Results program found the age-adjusted incidence of appendiceal malignancies to be 0.12 cases per 1,000,000 people per year, and identified mucinous adenocarcinoma as the most frequent histologic diagnosis with 37% of total reported cases. Carcinoid was the second most frequent histologic diagnosis, comprising 33% of total cases.

7.1 Carcinoid

The finding of a firm, yellow, bulbar mass in the appendix should raise the suspicion of an appendiceal carcinoid. The appendix is the most common site of gastrointestinal carcinoid, followed by the small bowel and then rectum. Carcinoid syndrome is rarely associated with appendiceal carcinoid unless widespread metastases are present, which occur in 2.9% of cases. Symptoms attributable directly to the carcinoid are rare, although the tumor can occasionally obstruct the appendiceal lumen much like a fecalith and result in acute appendicitis.

The majority of carcinoids are located in the tip of the appendix. Malignant potential is related to size, with tumors less than 1 cm rarely resulting in extension outside of the appendix or adjacent to the mass. In one report, 78% of appendiceal carcinoids were less than 1 cm, 17% were 1 to 2 cm, and only 5% were greater than 2 cm.⁹⁴ Treatment rarely requires more than simple appendectomy. For tumors smaller than 1 cm with extension into the mesoappendix, and for all tumors larger than 1.5 cm, a right hemicolectomy should be performed.

One study by Claudio F Feo in Italy on 10 patients with primary of the appendix treated at University of Sassari Italy from 1998 to 2005. There were 5 women and 5 man with a meaning of 59.1 years. Laparatomy was performed in 4 cases : When as the other 6 cases underwent laparoscopic exploration: Three operations were completed laparoscopically and three were converted to laparatomy. Six tumors were malignant and the remaining were benign. Proportion of preoperative and late mortality were both 10%. Two of four patients with benign tumors died from causes unrelated to the appendical neoplasm. The 6 patients with malignant tumor and the other 2 with benign disease were alive and disease free after a mean follow up of 43 months despite of rarity of appendical primary tumor, surgeons should be aware of these neoplasm for making correct treatment decisions.

8. References

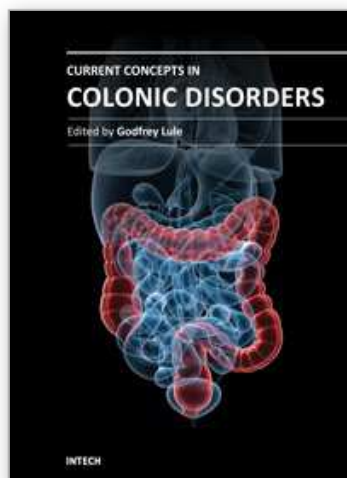
- [1] Beauchamp RD, Evers BM, Mattox KL, Sabiston Textbook of Surgery, 16th ed. Philadelphia, W.B.Saunders Company. 2001. P. 919.
- [2] Sabiston DC, Lysterly HK, Sabiston Textbook of Surgery, 15th ed. Philadelphia, W.B.Saunders Company. 1997. P. 964.

- [3] Brunicaardi FC, Anderson DK, Billiar TR, Dunn DL, Hunter JG, Pollock RE. Schwartz's Principles of Surgery. 8th ed , New York , McGraw Hill, 2010. P. 1080.
- [4] Salari AA. Intra abdominal abscess. NABZ. Iranian Journal. 1994; 3 : 34-38.
- [5] Salari AA. Peritonitis and Intraabdominal abscess. Yazd, Tebgostar, Shahid Sadoghi University of Medical sciences. Yazd, Iran. 2003. P. 93-110.
- [6] Sabiston DC, Lysterly HK, Sabiston Textbook of Surgery, 15th ed. Philadelphia, W.B.Saunders Company. 2001. P. 961-969.
- [7] Schwartz SI, Shires GT, Spencer FC. Principles of Surgery. 8th ed , New York , McGraw Hill, 1994. P.1304-1318.
- [8] Karl A. Zucker, MD., FACS Surgical Laparoscopy. Second edition, New York , London, Lippincott Williams Wilkins 2001. p. 231-232.
- [9] Ronald F. Anderson. Routine ultrasound and limited computed tomography for the diagnosis of acute appendicitis : A surgeon perspective. World Journal of Surgery. 2011; 35: 295-296.
- [10] Salari AA, MD. Sharifi MR , MD. Effects of Antibiotic prophylaxis and non prophylaxis in appendectomised patients without complications. Journal of Shahid Sadoughi University of Medical sciences Yazd Iran 1998; 6 : 42-47.
- [11] Butala P. Greenstein AJ, SUR MD, Mehta N, Sadot E, Divino CM. Special Management of acute right lower Quadrant pain in pregnancy : A prospective cohort study. Journal American college of Surgeons, 2010; 211 : 490-497.
- [12] Clausio F. FEO, Alberto Porcu, Antonio M. Scan U, Giorgio C, Ginesu, Alessandro Fancellu. Anlonell Loretto, Giuseppe Dettori. Primary Appendical Tumors : Report on 10 cases Int Surg 2009, 94 : 224-227.
- [13] Tamuro Hayama, Keiji Matsuda, Hajime Shibuay, Takuya Akahane, Atsushi Horiuchi, Ryu Shimada, Yoshiko Aoyagi, Keisuke Nakamura, Hideki Yamasa, Soichiro Ishihara, Keijiro Nozawa, Toshiaki Watanable. A case of appendiceal crohn's disease in children a laparoscopic appendectomy were performd. Int Surg 2010; 95 : 338 -342.
- [14] Krishna K. Varadhan. David J. Humes. Keith R. Neal. Dileep N. Lobo. Antibiotic therapy versus appendectomy for acute appendicitis : A Meta - analysis. Word J Surg 2010; 34: 199-209.
- [15] Salari AA., MD. Prevention of wound infection after appendectomy by irrigation of wound plus prophylactic antibiotic versus prophylactic antibiotic. Iranian Journal of Surgery. 2003. 11.53-57.
- [16] Salari AA, Zare M. Evaluation of perforated appendicitis in Yazd Iran (Shahid Sadoughi University of Medical Sciences and Health Services Yazd Iran. Word J Surg 2007; 31: 125.
- [17] Salari AA. Binesh F. Diagnosis value of anorexia in acute appendicitis. Pak J Med Sci 2007; 23: 68-70.
- [18] Silen W, Cop S. Early diagnosis of acute abdomen. 19th edition , New York , Oxford University Press. 1996 : 99-110.
- [19] Oliver Monneuse. S. Abdalla. Zf. Pilleul. V. Hervieu. L. Gruner. E. Tissot. X. Barth, Pain as the only consistent sign of acute appendicitis: Lack of inflammatory signs does not exclude the diagnosis. World J Surg 2010; 34: 210-215.

- [20] Seymour I.Schwartz, Harold Ellis. Maingut Abdominal Operation, 8th ed. USA. Prentice-Hall. 1985; 1274-1278.
- [21] Brunicardi FC, Anderson DK, Billiar TR, Dunn DL, Hunter JG, Pollock RE. Schwartz's Principles of Surgery. 8th ed , New York , McGraw Hill, 2005. P 1121-1134.

IntechOpen

IntechOpen



Current Concepts in Colonic Disorders

Edited by Dr. Godfrey Lule

ISBN 978-953-307-957-8

Hard cover, 276 pages

Publisher InTech

Published online 05, January, 2012

Published in print edition January, 2012

The 21st Century has seen a resurgence of research of the gastrointestinal tract, especially since it was established that it plays a central role as an immune system organ and consequentially has a huge impact on causation, impact and transmission of most human ailments. New diseases such as the Acquired Immunodeficiency Syndrome, hepatitis and tumours of the gastrointestinal tract have emerged and they are currently subjects of intensive research and topics of scientific papers published worldwide. Old diseases like diarrhea have become extremely complex to diagnose with new and old pathogens, drugs, tumours and malabsorptive disorders accounting for the confusion. This book has set out algorithms on how to approach such conditions in a systematic way both to reach a diagnosis and to make patient management cheaper and more efficient. "Current Concepts in Colonic Disorders" attempts to put all the new information into proper perspective with emphasis on aetiopathogenesis and providing rational approach to management of various old and new diseases. As the book editor, I have found this first edition extremely interesting and easy to understand. Comments on how to improve the content and manner of presentation for future editions are extremely welcome.

How to reference

In order to correctly reference this scholarly work, feel free to copy and paste the following:

Ali Akbar Salari (2012). Perforated Appendicitis, Current Concepts in Colonic Disorders, Dr. Godfrey Lule (Ed.), ISBN: 978-953-307-957-8, InTech, Available from: <http://www.intechopen.com/books/current-concepts-in-colonic-disorders/perforated-appendicitis>

INTECH
open science | open minds

InTech Europe

University Campus STeP Ri
Slavka Krautzeka 83/A
51000 Rijeka, Croatia
Phone: +385 (51) 770 447
Fax: +385 (51) 686 166
www.intechopen.com

InTech China

Unit 405, Office Block, Hotel Equatorial Shanghai
No.65, Yan An Road (West), Shanghai, 200040, China
中国上海市延安西路65号上海国际贵都大饭店办公楼405单元
Phone: +86-21-62489820
Fax: +86-21-62489821

© 2012 The Author(s). Licensee IntechOpen. This is an open access article distributed under the terms of the [Creative Commons Attribution 3.0 License](https://creativecommons.org/licenses/by/3.0/), which permits unrestricted use, distribution, and reproduction in any medium, provided the original work is properly cited.

IntechOpen

IntechOpen