

We are IntechOpen, the world's leading publisher of Open Access books Built by scientists, for scientists

6,900

Open access books available

185,000

International authors and editors

200M

Downloads

Our authors are among the

154

Countries delivered to

TOP 1%

most cited scientists

12.2%

Contributors from top 500 universities



WEB OF SCIENCE™

Selection of our books indexed in the Book Citation Index
in Web of Science™ Core Collection (BKCI)

Interested in publishing with us?
Contact book.department@intechopen.com

Numbers displayed above are based on latest data collected.
For more information visit www.intechopen.com



Aortic Valve Sparing Operations

Bradley G. Leshnower and Edward P. Chen
*Division of Cardiothoracic Surgery,
 Emory University School of Medicine
 USA*

1. Introduction

The treatment of aortic root and ascending aortic aneurysms often requires addressing concomitant aortic valve pathology. In the setting of aortic stenosis secondary to cusp degeneration, aortic valve replacement (AVR) is performed. However, when patients present with aortic insufficiency and normal cusp anatomy, a dilemma arises. Historically valve replacement has been performed; however, current options are all associated with their own specific issues. Implantation of a mechanical prosthesis commits the patient to lifelong anticoagulation and the concomitant risks of bleeding and thromboembolism. Use of a bioprosthetic valve eliminates the burden of anticoagulation, but these prostheses suffer from structural valve deterioration and commit the young patient to the potential need for a second or third operation. The optimal solution is to remove all diseased aorta while preserving and restoring the normal aortic cusps to their original geometry to allow for adequate coaptation and valve competency. The term “aortic valve-sparing operations” (AVS) was introduced by David in the 1990’s to describe procedures which preserved, rather than replaced the aortic valve cusps during the treatment of aneurysms of the aortic root or ascending aorta with associated aortic insufficiency (1). These are technically demanding procedures which require in-depth knowledge and comprehension of aortic root anatomy and physiology. In this chapter we will review the anatomy and physiology of the aortic root and discuss the various AVS operations which have been used in the treatment of aortic root and ascending aortic aneurysms.

2. Anatomy

The aortic root is a complex structure composed of several components including the aortic annulus, valve cusps, sinus of Valsalva segments, and the sinotubular junction. The aortic annulus is defined by the attachment or hinge point of the cusp and has been described as scalloped or coronet shaped. It is attached to ventricular myocardium in 45% of its circumference and fibrous structures in the remaining 55%. The annulus rises from the nadir of one cusp and peaks at the commissure, the highest point of the annulus and the junction between two adjacent cusps. The area below the commissures is referred to as the subcommissural triangle.

The shape of the aortic cusps is semilunar. The base (hinge point) of the cusp is 1.5 times longer than the length of the free margin (Figure 1). The cusps have three component parts: the hinge point, the body and the coapting surface (free margin). The hinge point has the ability to bend repeatedly without weakening or fracturing due to stress. The body of the cusp has a limited degree of distensibility due to a sliding movement of the different layers that compose the valve. The coapting surface has a specific length which is important in ensuring valve competence under different loading conditions (3). Histopathology studies have revealed that the thick collagenous bundles which comprise the cusps are oriented in an optimal way to transmit stress to the aortic wall (4). Normal aortic valves have three cusps with three corresponding sinus of Valsalva segments. Bicuspid aortic valve is a heritable condition which occurs in 1-2% of the population. These patients have two functional cusps and three sinus segments.

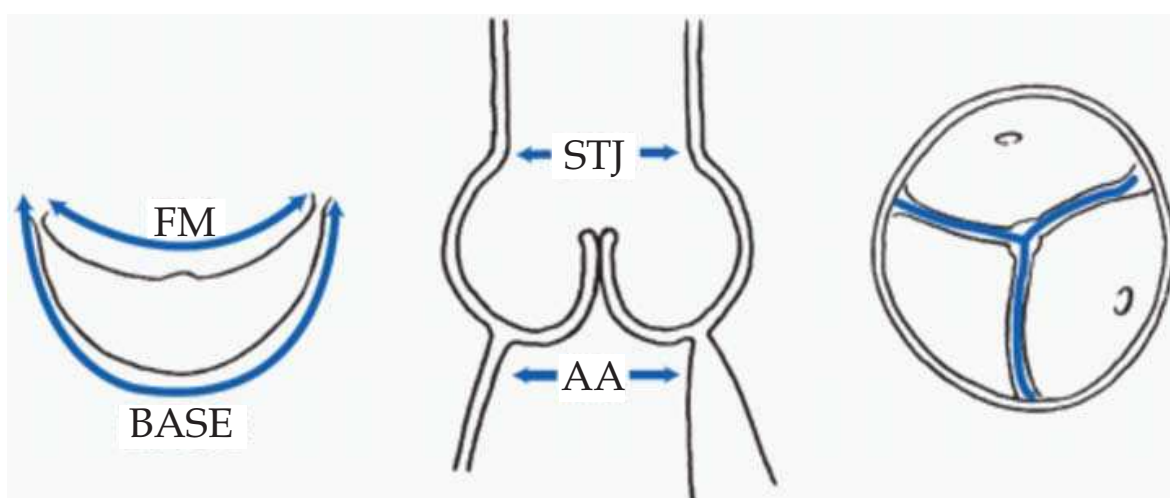


Fig. 1. Geometric relationships of various components of the aortic root. The base of the aortic cusp is 1.5 times longer than its free margin (FM). The diameter of the aortic annulus (AA) is 10 to 15% larger than the diameter of the sinotubular junction (STJ) in children and young adults, but it tends to become equal with aging. Three semilunar cusps seal the aortic orifice. The height of the cusps must be longer than the radius of the aortic annulus. From David TE. Aortic Valve Repair and Aortic Valve-Sparing Operations. In: Cohn LH, ed. *Cardiac Surgery in the Adult*. New York, NY: McGraw Hill:935-948, 2008

Beginning at the aortic annulus, the aorta bulges outward to form three sinuses of Valsalva segments which end at the sinotubular junction (STJ). The shape of the sinus segment is thought to be important in creating vortices which have an effect on both valve opening and closing as well as coronary blood flow (4). In vitro finite element analysis has proven that the shape of the sinus segments plays a vital role in limiting the stress and strain on the cusps (5). The important relationship between the shape of the sinus and its physiologic function has led to the development of prosthetic aortic root grafts with pre-made bulging sinus segments, in attempt to recreate normal aortic root geometry (6).

The sinotubular junction (STJ) is a ridge which lies above the aortic valve commissures and marks the transition from the aortic root to the ascending aorta. The circumference of the sinotubular junction is 15-20% smaller than the aortic annulus in young people, but normalizes to approximately a 1:1 relationship in older age (2). The close relationship of

the STJ and the aortic valve commissures is realized when aneurysmal dilation of the STJ moves the commissures apart and results in loss of leaflet coaptation and aortic insufficiency.

The aortic root is a dynamic structure that expands and contracts throughout the cardiac cycle in a manner which maximizes blood flow through the aortic valve and minimizes stress on the aortic valve cusps. The components of the aortic root complex have a specific geometric relationship with each other to produce optimal hemodynamics. Pathologic alterations in any of the four components can change their interactions and result in valvular dysfunction (4, 7).

3. Pathophysiology

AVS operations were designed for patients with aortic root or ascending aortic aneurysms and competent or regurgitant aortic valve function in the setting of normal cusps. Highly stenotic valves are rarely able to be preserved. The most common cause of aortic insufficiency in North America is annuloaortic ectasia. Young patients develop aortic root aneurysms beginning with dilatation of the sinus segments, followed by annular and STJ dilatation. Elderly patients can develop aortic insufficiency from ascending aortic aneurysms and subsequent dilatation of the STJ. In these patients, the aortic annulus and sinus segments are relatively normal. Marfan syndrome is the most common cause of aortic root aneurysms in young patients. Other connective tissue disorders such as ankylosing spondylitis, Ehlers-Danlos, osteogenesis imperfecta, rheumatoid arthritis, and lupus can cause aortic insufficiency. Aortic dissection is another common indication for an AVS operation. This dissection flap can extend into the aortic root and disconnect one of the aortic valve commissures from the aortic wall causing cusp prolapse and aortic insufficiency (2).

4. Indications

Indications for surgical intervention upon aortic root and ascending aneurysms include the presence of symptoms, aortic size, rapid growth, and the degree of aortic insufficiency. Most patients with aortic aneurysms are asymptomatic. Symptomatic patients complain of chest pain, which is considered a sign of rapid growth, dissection or impending rupture(8). The guidelines for the treatment of asymptomatic patients are drawn from natural history studies which correlated serial aortic measurements and aortic complications (rupture or dissection). It has been demonstrated that the ascending aortic grows at a rate of 1mm/year, and by the time the diameter of ascending aneurysms reaches 6cm, patients have been subjected to a lifetime 34% risk of rupture or dissection (9).

In the largest reported series from the Yale Aortic Institute comparing growth rates and complications, 50% of patients with ascending aortic aneurysms suffered aortic rupture or dissection at a median aortic diameter of 5.9 cm (10). Furthermore, there is a “hinge” point in the data which identifies a significant increase in the probability of rupture or dissection when an aneurysm reaches a size of 6.0cm. Therefore, elective repair of aortic root or ascending aneurysms in trileaflet valves is recommended at a diameter of $\geq 5.5\text{cm}$ or a growth rate of $\geq 0.5\text{cm/year}$ (8,10). Patients with genetic disorders such as bicuspid aortic valve, Marfan syndrome, Ehlers-Danlos, Turner syndrome, or a familial history of aneurysm

and dissection should undergo elective aortic replacement at a diameter of $<5\text{cm}$ depending upon the specific disease (8). These patients have a higher risk of rupture or dissection at smaller aortic diameters. It should be noted that the diameter for aortic intervention can be adjusted for body size based upon published nomograms correlating the aortic rupture/dissection risk to aortic diameter and body surface area (9).

In other situations, the primary indication for surgical intervention is aortic insufficiency and not aneurysmal disease. Current recommendations for aortic valve repair or replacement in the setting of chronic severe aortic insufficiency include: (1) symptoms of congestive heart failure, (2) left ventricular dysfunction with an ejection fraction $\leq 50\%$ at rest, (3) concomitant cardiac or aortic surgery, (4) LV end-diastolic dimension of $> 75\text{mm}$, (5) LV end-systolic dimension of $> 55\text{mm}$ and (6) declining exercise tolerance (11). When operating for a valvular indication or aortic dissection, concomitant aortic root or ascending replacement is recommended at aortic diameters $\geq 4.5\text{cm}$. In the setting of severe aortic insufficiency and aortic aneurysmal disease, aggressive operative intervention earlier rather than later may enable AVS operation to be performed. Long-standing, severe aortic insufficiency can damage the cusps, causing stress fenestrations or thickening of the free margin which may render the cusps unrepairable and mandate valve replacement.

In addition to the indications listed above, the surgeon must exhibit judgment in patients selected to receive a valve sparing operation. The patient's age and comorbid status must be taken into consideration. Given the excellent durability of bioprosthetic valves, patients with a life expectancy < 15 years should probably undergo aortic valve replacement. The aortic cusps must be carefully inspected both preoperatively on the transesophageal echocardiogram and at the time of surgery once the aorta is transected. Significant calcification of the annulus and cusps are generally considered prohibitive of an AVS operation. Severe free margin thickening has also been demonstrated to limit long term valve durability following AVS operations (7, 12). However stress fenestrations and free margin elongation are not contraindications to a valve sparing procedure, and valve repair techniques are often added to an AVS operation. Due to the extensive reconstruction involved in valve-sparing root replacement, myocardial protection is paramount, as the possibility of a second period of myocardial ischemia exists if the valve repair fails. All of these factors must be considered prior to proceeding with a valve-sparing procedure.

5. Ascending aortic replacement with remodeling of the sinotubular junction

Aortic insufficiency can occur in the setting of either isolated ascending aortic aneurysms or due to aortic root aneurysms. Isolated ascending aortic aneurysms cause aortic insufficiency due to dilation of the STJ which pulls the commissures apart and prevents valve coaptation during diastole (2). If the remainder of the aortic root components are normal, then a reduction of the STJ diameter will restore valve competence. Typically these patients are older and have a large ascending aortic aneurysm and aortic insufficiency. The preoperative echocardiogram will demonstrate loss of STJ definition, minimal dilation of the sinuses and central aortic insufficiency due to lack of cusp coaptation.

During the operation, the aorta is transected approximately 5mm distal to the STJ and the cusps are inspected. Often the cusps are small, there is minimal annular dilatation and the ridge of the STJ is unrecognizable. If the aortic insufficiency has been chronic, there may be

pathologic alterations in the cusps. The two most common alterations are elongation of the free margin or stress fenestrations near the commissures. Free margin elongation results in cusp prolapse, which can be corrected with a plication stitch in the center of cusp free margin at the nodule of Arantii. In the case of extensive stress fenestrations, the free margin is reinforced with a double layer 6-0 polytetrafluoroethylene suture. David and colleagues have shown that both of these adjunctive valve repair techniques are durable methods of achieving long-term valve competence with this operation. (1).

Restoring the normal diameter of the STJ is the key to achieving aortic valve competence in this procedure. There are two methods which are used to select the appropriate graft size which will define the neo-sinotubular junction. Once the aorta is transected, traction sutures are placed at the commissures and pulled up until the cusps achieve coaptation. The diameter of an imaginary circle which includes all three commissures is the ideal diameter of the neo-sinotubular junction (13). Next a transparent valve sizer (e.g. Medtronic Freestyle, Medtronic, Minneapolis, MN) is used to determine the annular diameter. The STJ and the annulus should be approximately the same diameter in order to recreate the normal aortic root geometry in this population. Furthermore, the location of the commissures should be marked on the graft and lined up accordingly during construction of the anastomosis in an effort to maintain normal root geometry (Figure 2). Once the graft has been sewn to the aorta, aortic valve competence can be tested by injecting cardioplegia into the graft under pressure. If the left ventricle remains decompressed and there is no distension, then the aortic valve is competent. (1).

David and colleagues reported their outcomes following ascending aortic replacement with reduction of the diameter of the sinotubular junction in 103 patients over a 15 year period. The mean age of these patients was 65 years and all patients had >3+ aortic insufficiency. 9% of patients had bicuspid aortic valves. The mean diameter of the neo-sinotubular junction following ascending replacement was 26mm, and leaflet repair was performed in 40 patients. There were two operative deaths, and 5 and 10 year survival was 80% and 54%. Freedom from moderate or severe aortic insufficiency at 5 and 10 years was 96% and 80%. Two patients in the entire series required reoperation for aortic valve replacement. One patient had severe aortic insufficiency and the other had infective endocarditis. The overall 10 year freedom from aortic valve replacement was 97% (1).

El-Khoury's group also reported their experience with remodeling the STJ for the treatment of supracoronary aortic aneurysms and associated aortic insufficiency. In a smaller series of 55 patients with a mean age of 65, these authors reported an overall survival of 94% and 75% at 5 and 7 years follow-up. 31% of patients had bicuspid aortic valves. Adjunctive cusp repair procedures were performed in 51% of patients and 69% of patients underwent subcommissural annuloplasty. Freedom from recurrent >2+ aortic insufficiency 87% at 5 years, and none of their patients required subsequent aortic valve replacement (14).

The outcomes from these two series provide data that a durable aortic valve sparing operation can be accomplished by remodeling the sinotubular junction with a supracoronary graft and simple leaflet repair techniques in both bicuspid and trileaflet valves. Patient selection and careful examination of the aortic valve cusps with preoperative echocardiography and intraoperative examination is the key to achieving short and long-term success. If the leaflets are severely damaged, the aortic valve should be replaced.

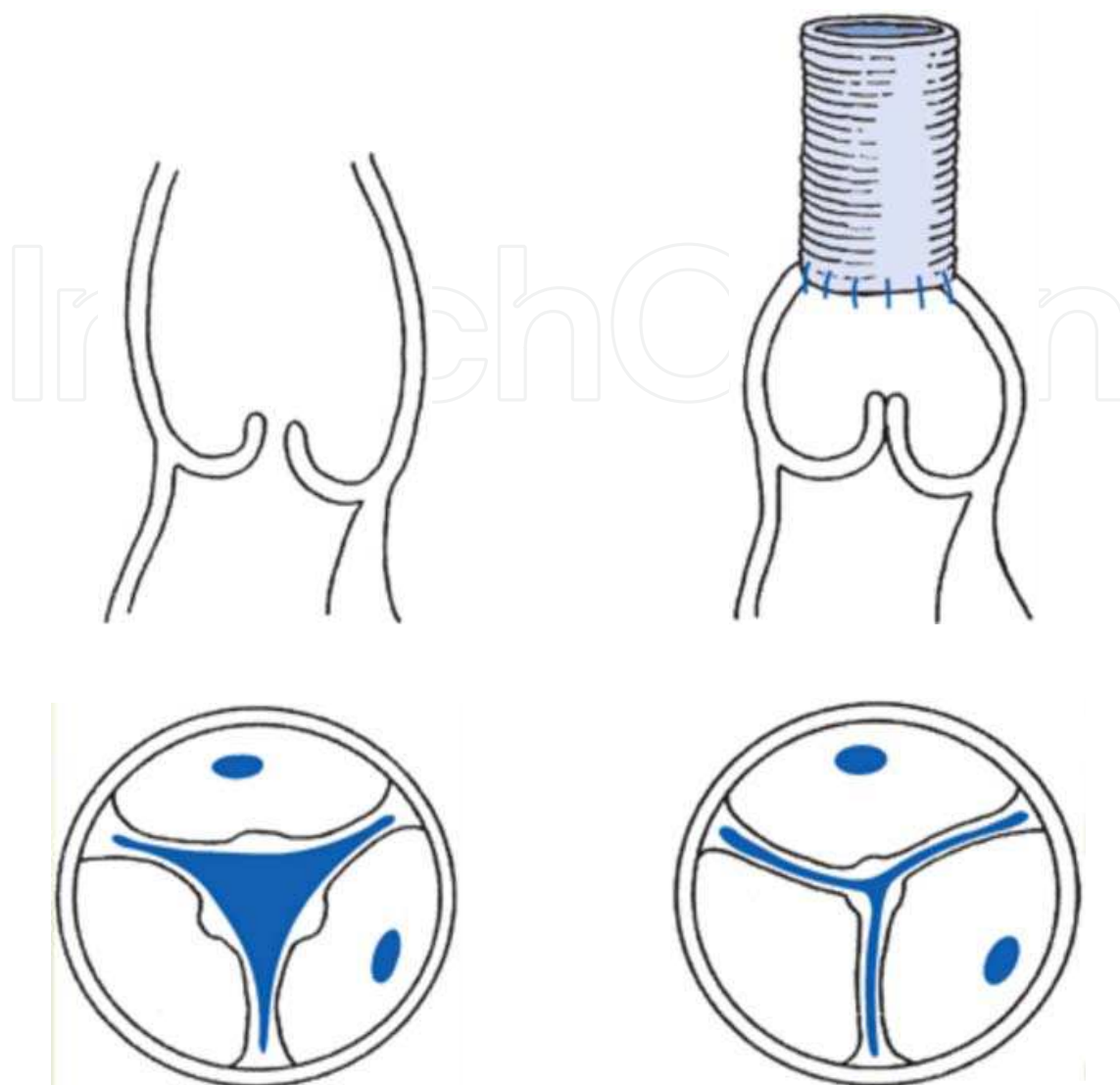


Fig. 2. Sinotubular Junction Remodeling. From David TE. Aortic Valve Repair and Aortic Valve-Sparing Operations. In: Cohn LH, ed. *Cardiac Surgery in the Adult*. New York, NY: McGraw Hill:935-948, 2008

6. Valve sparing aortic root replacement- remodeling technique

Yacoub developed the aortic root remodeling procedure to treat patients with aortic root aneurysms, aortic insufficiency and normal aortic valve cusps. In this population of patients, the pathology is confined to the aortic wall. He reported the first series of valve sparing root replacements for the treatment of 10 patients with aortic root aneurysms and aortic insufficiency in 1993 (15). In this series he described the technique of aortic root remodeling by replacing all diseased aortic root tissue with a tailored Dacron graft. One end of the graft was fashioned to produce three individual tongues which became the neo-aortic sinus segments of the remodeled root (Figure 3). The operative technique is described below.

After initiating cardiopulmonary bypass, the aorta is transected and a careful examination of the aortic valve cusps is performed. If abnormal cusps are discovered and found to be

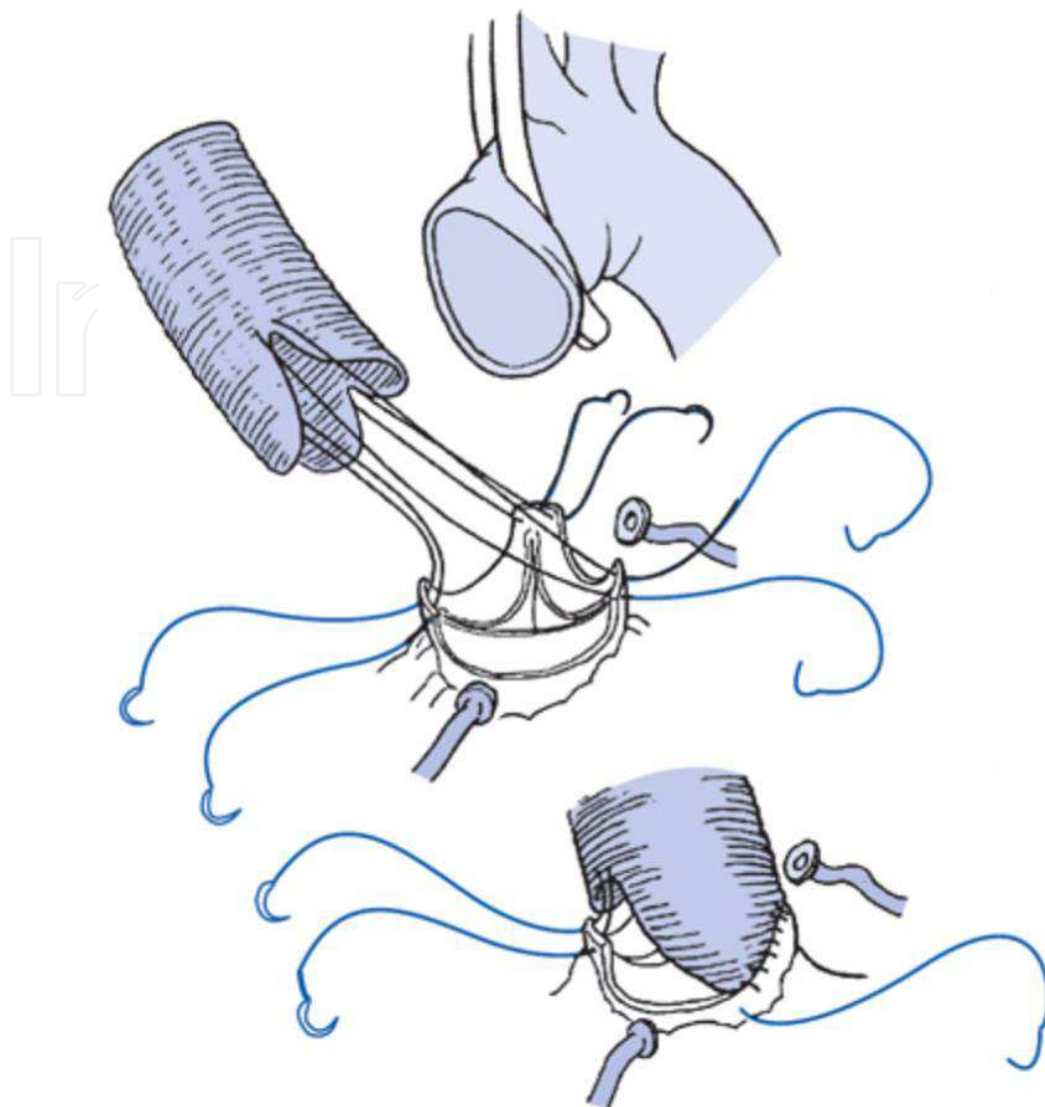


Fig. 3. Aortic Root Remodeling. From David TE. Aortic Valve Repair and Aortic Valve-Sparing Operations. In: Cohn LH, ed. *Cardiac Surgery in the Adult*. New York, NY: McGraw Hill:935-948, 2008

“unsalvageable” despite leaflet repair techniques, then the valve is excised and a conventional Bentall root replacement is performed (16). If the cusps are normal, then the aortic root is dissected out from the surrounding cardiac chambers all the way down to the aortic annulus. The abnormal aneurysmal sinus tissue is excised, leaving a 5mm remnant of aortic wall above the annulus. Traction sutures are placed at the top of each commissure. Additionally, the orifice and proximal portions of the left and right coronary arteries are dissected away from the surrounding structures leaving 5mm circumferentially of sinus tissue to form “coronary buttons”. Next, a Dacron graft is sized in a manner similar to the STJ remodeling procedure previously described. The traction sutures above each commissure are pulled up until the cusps achieve coaptation. The graft diameter is the diameter of an imaginary circle which includes all three commissures. A transparent valve sizer (e.g. Medtronic Freestyle) can be used to help determine the optimal graft diameter. The positions of the commissures are marked on the graft. The graft is then tailored with

three longitudinal cuts at the positions of the commissures with the ends rounded to create neo-aortic sinuses which are the width of the intercommissural distance. It is important to make the heights of the three neo-sinuses (two in the case of bicuspid valve) approximately the same size as the diameter of the graft to properly recreate normal aortic root geometry. Once the neo-sinus segments of the root graft are created, the commissural posts are sutured outside the graft above the neo-sinus (Figure 3). Then the remnant aortic wall tissue above the annulus is sutured to the graft with a running stitch. Once this is complete, holes are made inside the root graft with an ophthalmic cautery and the coronary buttons are reimplanted. At this point the leaflets are inspected again, and any leaflet repairs are performed at this time. The ideal level of coaptation is 5-6mm above the level of the nadir of the aortic annulus, and the optimal length of the coaptation zone is 4mm. Before proceeding with the remainder of the planned procedure, valve competency is re-tested by injecting cardioplegia into the graft under pressure. If the left ventricle remains decompressed and there is no distension, then the aortic valve is competent. (2, 17)

Yacoub reported the long term results of his remodeling procedure in 158 patients over an 18 year period. All patients had aortic root aneurysms, and 31% were performed in the setting of acute Type A aortic dissection. 43% of these patients had Marfan syndrome. 49% of patients had preoperative moderate aortic insufficiency and 18% had severe aortic insufficiency. The elective aneurysm group had a 1 and 10 year survival of 97% and 82%, while the acute dissection cohort had survival rates of 73% and 53%. Post-operative echocardiography revealed that 64% of patients had trivial or no aortic insufficiency, 33% had mild to moderate aortic insufficiency, and only 3% had severe aortic insufficiency. Freedom from reoperation was 99% and 89% at 1 and 10 years (18).

David modified Yacoub's remodeling technique for patients with annuloaortic ectasia or Marfan syndrome by adding an annuloplasty to the fibrous portion of the aortic annulus in an attempt to prevent future annular dilatation (19). This was accomplished by passing multiple horizontal sutures from inside to out on the fibrous aspect of the left ventricular outflow tract underneath the annulus. These sutures are then passed through a narrow strip of Dacron or Teflon felt and tied down to reduce the diameter of the aortic annulus (Figure 4). David recently reported his 12 year follow-up data from 61 patients who underwent his modified remodeling procedure. 42% of these patients had Marfan syndrome and 12% were performed in the setting of acute Type A dissection. 34% of patients had preoperative moderate aortic insufficiency, and 21% had severe aortic insufficiency. There was 1 operative death and survival rates were 97% and 83% at 1 and 12 years. At 12 years, freedom from moderate or severe aortic insufficiency was 83%, and freedom from reoperation upon the aortic valve was 90% (17). Other groups have also reported durable long-term valve function following root remodeling including patients with bicuspid valves (20, 21).

The root remodeling has been adopted by many surgeons and has produced excellent long term results with durable aortic valve function. However, due to its lack of an annuloplasty, many surgeons prefer the reimplantation technique, especially in patients with annular dilatation or connective tissue disorders.

7. Valve sparing aortic root replacement-reimplantation technique

In 1989, David performed the first valve sparing root replacement using the reimplantation technique. The patient was a young woman with Marfan syndrome and a 5.4cm aortic root

aneurysm who had elected to get an aortic valve homograft so that she could eventually have children. Instead, David reimplanted her native valve into a cylindrical Dacron tube graft (22). Since the original operation, this pioneering procedure has undergone several modifications and has been adopted by surgeons worldwide as their primary AVS operation. The technical aspects of the most recent iteration of the David V reimplantation procedure are described in the following paragraphs.

Once the decision is made to proceed with valve-sparing root replacement, the root is circumferentially dissected down to the nadir of the aortic annulus. All abnormal sinus tissue is excised, leaving a 5mm rim of aortic tissue above the annulus. Coronary buttons are also fashioned, and 4-0 pledgeted polypropylene sutures are placed from inside to out just above the top of each commissure.

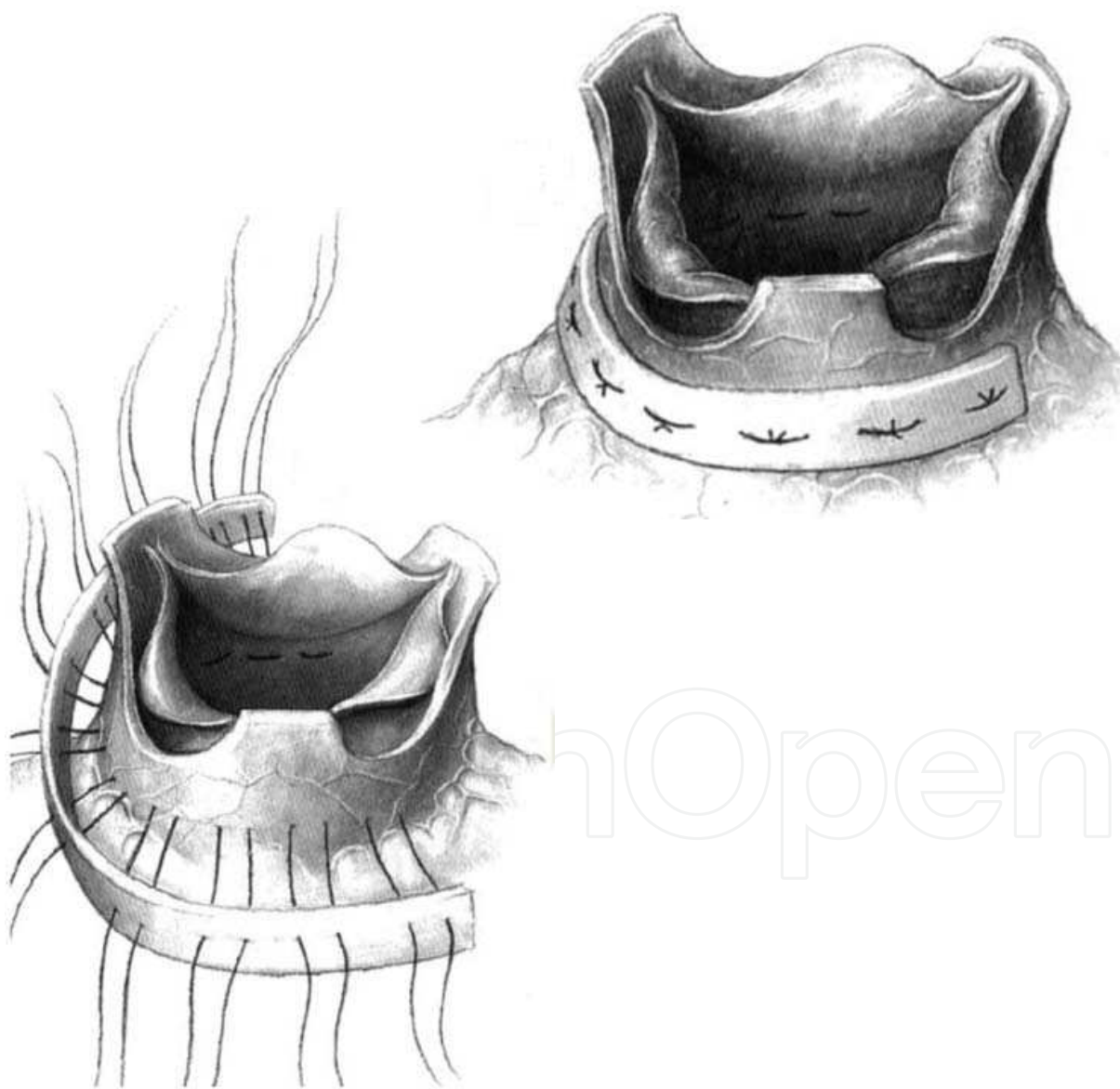


Fig. 4. Aortic Root Remodeling with Annuloplasty. From David TE. Remodeling of the Aortic Root and Preservation of the Native Aortic Valve. *Operative Techniques in Cardiac & Thoracic Surgery*. 1996; 1:44-56

In the reimplantation procedure, correct graft size selection is paramount to achieving a successful result. In the David V procedure, the diameter of the graft = $2(2/3 \text{ average cusp height}) + 8\text{mm}$. This is a slight modification of the original David-Feindel formula, as it enlarges the graft by 2mm to create neo-sinus segments (23,24). A ruler is used to measure the height of the cusp from the hinge point at the nadir of the annulus to the free margin edge at the nodule of Arantius. This formula is based upon the anatomic relationships of the normal human aortic root. Cusp height (as opposed to the annulus, STJ, or sinus) is used as the measured distance upon which graft size is based because it is the only relatively fixed measurement in the aortic root complex. In large series, most grafts range from 30-36mm in diameter (24).

Sizing the graft in this fashion allows for a graft larger than the ideal STJ and annulus, which can be plicated down at the top and bottom to create neo-sinus segments. A transparent valve sizer is used to measure the annulus. If annular dilatation is present, a valve sizer smaller than the annulus is selected and the graft sizer is placed through the bottom of the graft. A series of interrupted plicating stitches approximately 4mm above the end of the graft plicates the annular end of the graft down to the diameter of the valve sizer. The positions of the commissures are also marked on the graft, and a small triangle is cut out at the position of the left/right commissure.

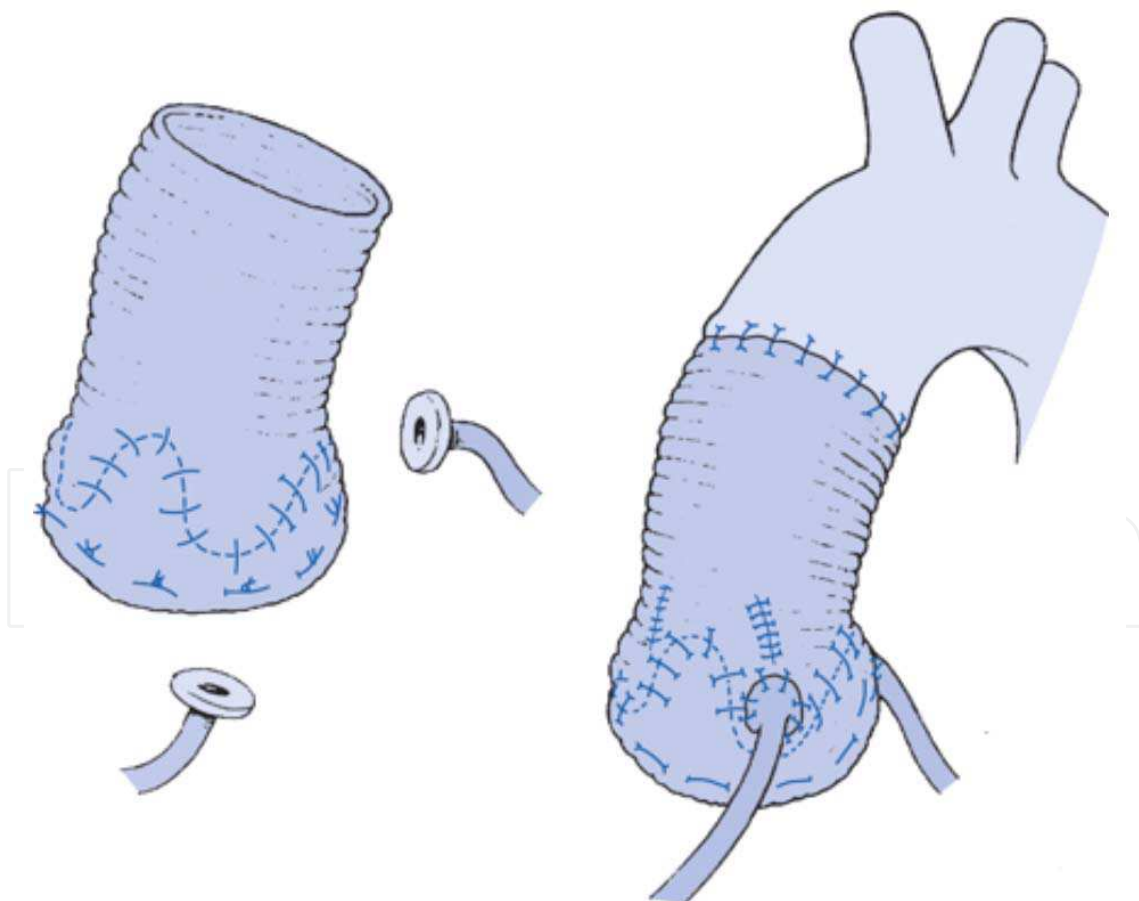


Fig. 5. David V Reimplantation Procedure. From David TE. Aortic Valve Repair and Aortic Valve-Sparing Operations. In: Cohn LH, ed. *Cardiac Surgery in the Adult*. New York, NY: McGraw Hill:935-948, 2008

Multiple (9-12) 2-0 or 3-0 horizontal pledgeted mattress stitches are placed circumferentially from inside to out of the left ventricular outflow tract at the level of 2mm below the nadir of the annulus in a horizontal plane. These stitches go through the fibrous portion of the outflow tract and the muscular interventricular septum and are passed through the tailored end of the Dacron graft. If the aortic annulus is not dilated, these sutures are spaced symmetrically. In the case of annular dilatation, the sutures which are placed in the area of the subcommissural triangles of the non-coronary cusp should be placed closer together, as this is where annular dilatation occurs. Next the commissural stitches are brought through the inside of the graft and the graft is seated around the outside of the annulus. The sutures are tied to secure the graft to the outside of the annulus, but not too tightly, which would pursestring the graft (2).

The graft is cut to about 5-7 cm in height and the commissural sutures are pulled up vertically and the cusps are assessed for the position of optimal coaptation. Once the ideal position of each commissure is recognized, the sutures on each commissure are passed through the root graft. This resuspends the valve inside the graft, and the cusps and commissures are inspected carefully for proper alignment and coaptation. Optimal position results in coaptation of all cusps at the same level approximately 5-6mm above the nadir of the annulus and a 4mm coaptation zone. The sutures of the commissures are tied outside the graft. Next, the annulus is secured to the graft by a 4-0 running polypropylene stitch by passing the needle from inside to out on the graft 1mm above the annulus and outside to in on the graft. Multiple sutures are used to secure the scalloped aortic annulus to the graft. Once this is complete, holes are made in the appropriate positions and the coronary artery buttons are reimplanted. Pleating stitches are again placed between each commissure to create bulges in the graft which form the neo-sinuses. Each 3mm of plication reduces the diameter of the neo-sinotubular junction by 1mm. Pressurized cardioplegia is injected into the graft to test for valve competence and hemostasis. Any necessary cusp repair procedures are performed at this time. When valve competence is satisfactory, the graft is sutured to the distal aorta.

In 2010, David reported his long-term results of 228 patients who underwent valve-sparing root replacement with the reimplantation technique. This series represented his entire experience with the reimplantation procedure including modifications of his own technique. 34% of patients had Marfan syndrome, 10% had bicuspid valves, and 8% of patients were operated on in the setting of acute Type A dissection. 24% of patients had moderate aortic insufficiency preoperatively, and 27% had severe aortic insufficiency. There were 4 operative deaths and survival at 1 and 12 years was 97% and 83%. 6 patients developed postoperative moderate aortic insufficiency and 2 patients developed severe aortic insufficiency. Freedom from moderate or severe aortic insufficiency at 4 and 12 years was 98% and 91 %. Two patients required reoperation on the aortic valve resulting in a freedom from reoperation at 4 and 12 years of 99% and 97% (17).

The importance and reproducibility of David's reimplantation technique is underscored by its adoption by surgeons worldwide who perform reimplantation procedures. In 2005 the Hannover group reported their 11 year experience with the reimplantation technique in 284 patients. 19% of patients had Marfan syndrome, 6% had bicuspid aortic valves and 19% of patients were operated on in the setting of acute Type A dissection. Elective operative mortality was 1.3%, and overall operative mortality was 3.1%. At 10 years follow-up, survival was 80%, and freedom from reoperation due to aortic valve dysfunction was 87%. In their analysis, the authors discovered that Marfan syndrome was an independent risk factor for requiring reoperation on the aortic valve (25).

The contribution of the shape of the sinus segments to minimizing stress and strain on the cusps and has led to the creation of the Valsalva graft, a graft with premade spherical sinus segments (6) (Vascutek, Renfrewshire, Scotland). In 2010, DePaulis reported a multi-center study from 8 Italian surgeons reporting the long-term results of performing the reimplantation technique with the Valsalva graft in 278 patients. 15% of patients had Marfan syndrome, 11% had bicuspid aortic valves, and 5% of patients underwent valve-sparing procedures in the setting of an acute Type A dissection. 49% of patients had preoperative moderate-severe aortic insufficiency. Operative mortality was 1.8%. At 10 year follow-up, survival was 95% and freedom from significant aortic insufficiency was 88%. 17 patients underwent subsequent AVR for a 10 year freedom from reoperation of on the aortic valve of 91%. The results of this multi-center study highlights the reproducibility of the David V procedure. Although many surgeons prefer to tailor their own graft, the use of a standardized, commercially available graft which has proven excellent long-term valve durability has both simplified and standardized the procedure (26).

8. Remodeling vs reimplantation

Valve-sparing root replacement has evolved from Yacoub's original remodeling procedure to the current David V reimplantation procedure. These two operations have sparked many debates over which is the optimal procedure to restore the natural anatomy and physiology of the aortic valve.

It has been argued that the remodeling procedure is superior to the reimplantation procedure in recreating native aortic root physiology because remodeling maintains the independent mobility of the individual sinus segments. Sinus segment mobility is crucial to facilitating changes in aortic root distensibility throughout the cardiac cycle. Root expansion and contraction throughout systole and diastole is thought to maximize blood flow through the valve apparatus while minimizing stress and strain on the leaflets. Based upon echocardiography data evaluating valve opening and closing characteristics, patients who received a remodeling procedure displayed more physiologic leaflet movements throughout the cardiac cycle compared to patients who underwent a reimplantation procedure inside a straight tube graft (27). Remodeling also preserves the dynamic properties of the annulus which becomes rigid when it is confined by a Dacron graft in the reimplantation technique.

The main arguments for the superiority of the reimplantation procedure is that the remodeling procedure fails to stabilize the annulus, which is important in preventing future annular dilatation, especially in patients with annuloaortic ectasia, Marfan syndrome or other connective tissue disorders. David provided data to support this theory by comparing the results of the remodeling and reimplantation procedures in his own personal series of valve-sparing root replacements in Marfan patients. Using echocardiographic measurements of the different components of the reconstructed aortic root, David showed that patients undergoing the remodeling procedure had progressive dilatation of the aortic annulus and neo-sinus segment over a 13 year period. The annular dilatation occurred even in patients who received an annuloplasty as an adjunctive part of their remodeling procedure. Annular and sinus dimensions were unchanged in patients who received a reimplantation procedure. This translated into more stability in aortic valve function in the reimplantation cohort with regards to progression of aortic insufficiency over time. David hypothesized

that the reason for the progression of dilatation in the remodeling cohort, even in the presence of an annuloplasty is that either the small amount of remnant connective tissue between the annuloplasty line and the remodeling suture line dilated, or the annuloplasty sutures cut through the abnormal fibrous tissue of the LVOT (28). David abandoned the use of the remodeling procedure in favor of reimplantation for patients with Marfan syndrome in 1998.

It has been recognized by multiple surgeons who perform both procedures that the remodeling procedure is a simpler, faster procedure as it requires one less suture line and requires less dissection and mobilization of the root (29, 30). The David V is a considerably more complex procedure, but it allows the surgeon the flexibility to adjust all of the components of the aortic root complex in order to achieve normal physiologic function. Despite its complexity, it has gained worldwide adoption and is the procedure of choice by the majority of surgeons who perform valve-sparing root replacements. Furthermore, many surgeons have published modifications of the David V technique with excellent results (31, 32, 33, 34).

Both the remodeling and the reimplantation procedures have demonstrated excellent long-term aortic valve durability. The two operations should be viewed as complementary rather than competing procedures. Most surgeons recommend that patients with annuloaortic ectasia, Marfan syndrome and other connective tissue disorders are best served by a reimplantation procedure. The remodeling procedure should be reserved for older patients with a normal aortic annulus (≤ 25 mm woman, ≤ 27 mm man) (17, 34)

9. Conclusions

The treatment of patients with aortic root and ascending aortic aneurysms has been evolving over the past three decades. The majority of patients are still currently receiving Bentall procedure with a mechanical or bioprosthetic valved conduit. However, the number of surgeons performing AVS operations is increasing, and the indications are expanding. More surgeons are beginning to perform these procedures on patients with bicuspid valves, severe aortic insufficiency, and in the setting of acute Type A dissection. Again, patient selection and cusp examination are paramount to achieving success, but the addition of cusp repair techniques to the AVS operation has enabled an increasing number of patients to retain their native valves. The long-term data has proven that these operations can be performed with low morbidity and mortality, and provide durable aortic valve function. When feasible, AVS operations are the optimal treatment for patients with aortic disease and normal leaflets, as they avoid the burden of lifelong anticoagulation and significantly reduce their risk of endocarditis or requiring a subsequent operation for structural valve deterioration.

10. References

- [1] David TE, Feindel CM, Armstrong S, Maganti M. Replacement of the ascending aorta with reduction of the diameter of the sinotubular junction to treat aortic insufficiency in patients with ascending aortic aneurysm. *J Thorac Cardiovasc Surg.* 2007;133:414-8.

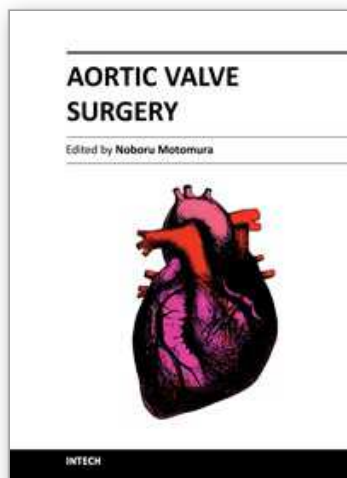
- [2] David TE. Aortic Valve Repair and Aortic Valve-Sparing Operations. In: Cohn LH, ed. *Cardiac Surgery in the Adult*. New York, NY: McGraw Hill:935-948, 2008.
- [3] Yacoub MH. Valve-Conserving Operation for Aortic Root Aneurysm or Dissection. *Operative Techniques in Cardiac & Thoracic Surgery* 1996;1:57-67.
- [4] Yacoub MH, Kilner PJ, Birks EJ, Misfeld M. The aortic outflow and Root: A Tale of Dynamism and Crosstalk. *Ann Thorac Surg.* 1999;68:S37-43.
- [5] Katayama S, Umetani N, Suquira S, Hisada T. The sinus of Valsalva relieves abnormal stress on aortic valve leaflets by facilitating smooth closure. *J Thorac Cardiovasc Surg.* 2008; 136(6):1528-35.
- [6] De Paulis R, De Matteis GM, Nardi P, Scaffa R, Colella DF, Chiarello L. A new aortic Dacron conduit for surgical treatment of aortic root pathology. *Ital Heart J.* 2000;1:457-63.
- [7] Gleason TG. Current Persepctive on Aortic Valve Repair and Valve-Sparing Aortic Root Replacement. *Semin Thorac Cardiovasc Surg.* 2006;18:154-164.
- [8] Hiratzka LF, Bakris GL, Beckman JA et al. 2010 ACCF / AHA / AATS / ACR / ASA / SCA / SCAI / SIR / STS / SVM Guidelines for the Diagnosis and Management of Patients with Thoracic Aortic Disease: A Report of the American College of Cardiology Foundation/American Heart Association Task Force on Practice Guidelines, American Association for Thoracic Surgery, Amercian College of Radiology, American Stroke Association, Society of Cardiovascular Anesthesiologists, Society for Cardiovascular Angiography and Interventions, Society of Interventional Radiology, Society of Thoracic Surgeons, and Society for Vascular Medicine. *Circulation* 2010;121:e266-e369.
- [9] Elefteriades JA. Indications for aortic replacement. *J Thorac and Cardiovasc Surg.* 2010;140(6):S5-S9.
- [10] Coady MA, Rizzo JA, Hammond GL et al. Surgical intervention criteria for thoracic aortic aneurysms: A study of growth rates and complications. *Ann Thorac Surg.* 67:1922-1926, 1999.
- [11] Bonow RO, Carabello BA, Chatterjee K, De Leon AC Jr. et al. 2008 Focused Update Incorporated Into the ACC/AHA 2006 Guidelines for the Management of Patients With Valvular Heart Disease. *J Am Coll Cardiol.* 2008;52:e1-142.
- [12] Casselman FP, Gillinov AM, Akhrass R, Kasirajan V et al. Intermediate-term durability of bicuspid aortic valve repair for prolapsing leaflet. *Eur J Cardiothorac Surg.* 1999; 15:302-308.
- [13] Morishita K, Abe T, Fukada J, Sato H, Shiiku C. A surgical method for selecting appropriate size of graft in aortic root remodeling. *Ann Thorac Surg.* 1998;65: 1795-6.
- [14] Boodhwani M, De Kerchove L, Glineur D, Rubay J et al. Aortic valve repair with ascending aortic aneurysms: associated lesions and adjunctive techniques. *Eur J Cardiothorac Surg.* 2011 Jan 12 epub.
- [15] Sarsam MA, Yacoub M. Remodeling of the aortic valve annulus. *J Thorac Cardiovasc Surg.* 1993;105:435-438.
- [16] Bentall H, De Bono A. A technique for complete replacement of the ascending aorta. *Thorax.* 1968; 23:338-339.
- [17] David TE, Maganti M, Armstrong S. Aortic root aneurysm: Principles of repair and long-term follow-up. *J Thorac Cardiovasc Surg.* 2010; 140:S14-19.

- [18] Yacoub MH, Gehle P, Chandrasekaran V, et al. Late results of a valve-preserving operation in patients with aneurysms of the ascending aorta and root. *J Thorac Cardiovasc Surg.* 1998; 115:1080-1090.
- [19] David TE. Remodeling of the Aortic Root and Preservation of the Native Aortic Valve. *Operative Techniques in Cardiac & Thoracic Surgery.* 1996; 1:44-56.
- [20] Aicher D, Langer F, Lausberg H, Bierbach B, Schafers HJ. Aortic root remodeling: ten-year experience with 274 patients. *J Thorac Cardiovasc Surg.* 2007;134(4):909-15.
- [21] Erasmi AW, Sievers HH, Bechtel JF, Hanke T et al. Remodeling or reimplantation for valve-sparing aortic root surgery? *Ann Thorac Surg.* 2007; 83(2):S752-76.
- [22] David TE. The aortic valve-sparing operation. *J Thorac Cardiovasc Surg.* 2011;141:613-5.
- [23] David TE, Feindel CM. An aortic valve-sparing operation for patients with aortic incompetence and aneurysm of the ascending aorta. *J Thorac Cardiovasc Surg.* 1992;103:617-22.
- [24] David TE. Sizing and tailoring the Dacron graft for reimplantation of the aortic valve. *J Thorac Cardiovasc Surg.* 2005;130:243-4.
- [25] Kallenbach K, Karck M, Pak D, Salcher R et al. Decade of Aortic Valve Sparing Reimplantation: Are We Pushing the Limits Too Far? *Circulation* 2005;112[S1]:I-253-259.
- [26] De Paulis R, Scaffa R, Nardella S, Maselli D et al. Use of the Valsalva graft and long-term follow-up. *J Thorac Cardiovasc Surg.* 2010;140:S23-7.
- [27] Leyh RG, Schmidtke C, Sievers HH, Yacoub MH. Opening and Closing Characteristics of the Aortic Valve After Different Types of Valve-Preserving Surgery. *Circulation* 1999;100:2153-2160.
- [28] De Oliveira NC, David TE, Ivanov J, Armstrong S et al. Results of surgery for aortic root aneurysm in patients with Marfan syndrome. *J Thorac Cardiovasc Surg.* 2003;125:789-96.
- [29] Miller DC. Valve-sparing aortic root replacement in patients with the Marfan syndrome. *J Thorac Cardiovasc Surg.* 2003;125:773-8.
- [30] David TE, Armstrong S, Maganti M, Colman J, Bradley TJ. Long-term results of aortic valve-sparing operations in patients with Marfan syndrome. *J Thorac Cardiovasc Surg.* 2009;138:859-64.
- [31] Gleason TG. New graft formulation and modification of the David reimplantation technique. *J Thorac Cardiovasc Surg.* 2005;130:601-3.
- [32] Patel ND, Williams JA, Barreiro CJ, Bethea BT, et al. Valve-Sparing Aortic Root Replacement: Early Experience with the De Paulis Valsalva Graft in 51 Patients. *Ann Thorac Surg.* 2006;82:548-53.
- [33] Kerendi F, Guyton RA, Vega JD, Kilgo PD, Chen EP. Early results of valve-sparing aortic root replacement in high-risk clinical scenarios. *Ann Thorac Surg.* 89(2):471-8.
- [34] Svensson LG, Cooper M, Batizy LH, Nowicki ER. Simplified david reimplantation with reduction of annular size and creation of artificial sinuses. *Ann Thorac Surg.* 2010;89(5):1443-7.
- [35] Hanke T, Charitos EI, Stierle U, Robinson D et al. Factors associated with the development of aortic valve regurgitation over time after two different techniques of valve-sparing aortic root surgery. *J Thorac Cardiovasc Surg.* 2009;137:314-9.

- [36] Cameron DE, Alejo DE, Patel ND, Nwakanma LU, et al. Aortic root replacement in 372 Marfan patients: evolution of operative repair over 30 years. *Ann Thorac Surg.* 2009;87(5):1344-9.

IntechOpen

IntechOpen



Aortic Valve Surgery

Edited by Prof. Noboru Motomura

ISBN 978-953-307-600-3

Hard cover, 246 pages

Publisher InTech

Published online 22, December, 2011

Published in print edition December, 2011

The aortic valve is located at the center of the heart. It is the core of cardiac anatomy and aortic valve surgery has led the field of cardiac surgery. This book describes all aspects of aortic valve surgery and it will help clarify daily questions regarding the clinical practice in aortic valve surgery, as well as induce inspiration and new insights into this field.

How to reference

In order to correctly reference this scholarly work, feel free to copy and paste the following:

Bradley G. Leshnower and Edward P. Chen (2011). Aortic Valve Sparing Operations, Aortic Valve Surgery, Prof. Noboru Motomura (Ed.), ISBN: 978-953-307-600-3, InTech, Available from:
<http://www.intechopen.com/books/aortic-valve-surgery/aortic-valve-sparing-operations>

INTeCH
open science | open minds

InTech Europe

University Campus STeP Ri
Slavka Krautzeka 83/A
51000 Rijeka, Croatia
Phone: +385 (51) 770 447
Fax: +385 (51) 686 166
www.intechopen.com

InTech China

Unit 405, Office Block, Hotel Equatorial Shanghai
No.65, Yan An Road (West), Shanghai, 200040, China
中国上海市延安西路65号上海国际贵都大饭店办公楼405单元
Phone: +86-21-62489820
Fax: +86-21-62489821

© 2011 The Author(s). Licensee IntechOpen. This is an open access article distributed under the terms of the [Creative Commons Attribution 3.0 License](https://creativecommons.org/licenses/by/3.0/), which permits unrestricted use, distribution, and reproduction in any medium, provided the original work is properly cited.

IntechOpen

IntechOpen