

# We are IntechOpen, the world's leading publisher of Open Access books Built by scientists, for scientists

6,900

Open access books available

186,000

International authors and editors

200M

Downloads

Our authors are among the

154

Countries delivered to

TOP 1%

most cited scientists

12.2%

Contributors from top 500 universities



WEB OF SCIENCE™

Selection of our books indexed in the Book Citation Index  
in Web of Science™ Core Collection (BKCI)

Interested in publishing with us?  
Contact [book.department@intechopen.com](mailto:book.department@intechopen.com)

Numbers displayed above are based on latest data collected.  
For more information visit [www.intechopen.com](http://www.intechopen.com)



# Valve-Sparing Aortic Root Replacement and Aortic Valve Repair

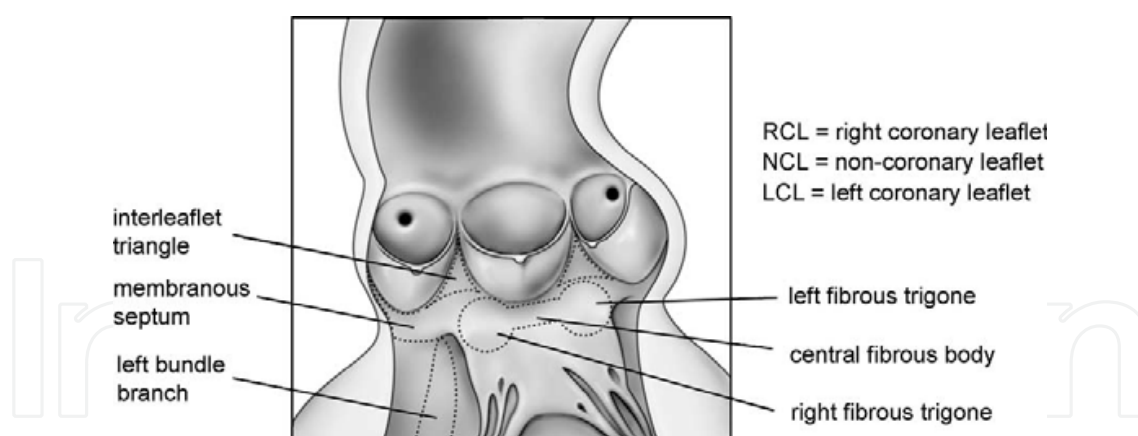
William Y. Shi, Michael O' Keefe and George Matalanis

*Department of Cardiac Surgery, Austin Hospital, University of Melbourne, Melbourne, Australia*

## 1. Introduction

The impetus behind preservation of the native aortic valve derives from the desire to avoid the inherent shortcomings of prosthetic valves. These include the requirement for long term anticoagulation in the case of mechanical valves, and tissue degeneration with the need for re-operations with bioprostheses. Aortic valve preservation in the setting of aortic root dilatation is technically challenging, however potentially rewarding if these benefits can be achieved. This enthusiasm for aortic valve preservation must of course be tempered by the potential risks of residual or recurrent significant aortic regurgitation and subsequent complex re-operations associated with repair failures.

Appreciation of the complex three-dimensional anatomy of the normal aortic root and how it changes in pathological states is essential to facilitate reconstruction.



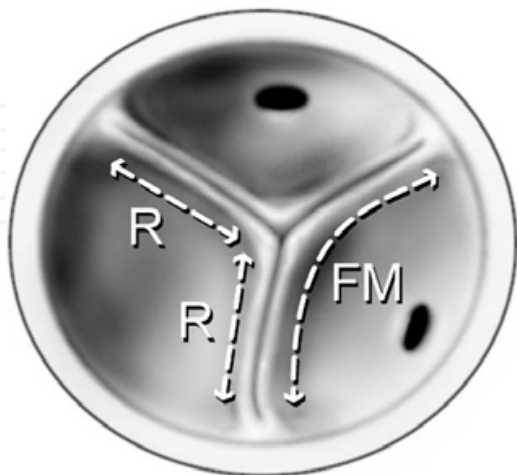*Reprinted from Heart, Lung and Circulation, 2004;13 Suppl 3, Matalanis G, Valve sparing aortic root repairs--an anatomical approach. S13-18., Copyright (2004), with permission from Elsevier*

Fig. 1. The aortic valves, leaflets and adjacent aortic root structures, which participate in normal aortic valve function

## 2. Aortic root anatomy

The aortic valve's function is dependant upon its leaflets, the sinotubular junction (STJ), aortic sinuses and annulus, which together constitute the aortic root. Important geometric relationships exist between several of the aortic root dimensions [1-3].

In clinical practice the aortic annulus is defined as the superior most aspect of the left ventricular outflow tract (LVOT) which connects the aortic cusps and sinuses to the left ventricle. The annulus’ perimeter consists of fibrous (55%) and muscular (45%) components. Of the two, the fibrous component is the one that tends to dilate first in aneurysmal disease.



Reprinted from Heart, Lung and Circulation, 2004;13 Suppl 3, Matalanis G, Valve sparing aortic root repairs--an anatomical approach. S13-18., Copyright (2004), with permission from Elsevier

Fig. 2. Dimensions of the aortic valve cusps, whereby R is the radius of the STJ and FM represents the length of the valve cusp free margin

For a trileaflet valve to be competent in the closed position, while not be stenotic in the open position, the length of the free margin (FM) must geometrically be equivalent to the diameter at the STJ (Fig. 2):

Valve in Closed position
<b>FM</b> $\approx 2 \times R$ (Radius of STJ)
<b>FM</b> $\approx D$ (Diameter of STJ) ..... ①
Valve in Open position
In order for the valve to hug the perimeter of the STJ in the open position, the circumference of the STJ (C) must be equivalent to the total length FM of the “n” leaflets combined:
<b>C</b> $\approx \mathbf{FM} \times n$ ; and thus
<b>FM</b> $\approx C/n$ ..... ②
Combining ① and ② we get:
<b>D</b> $\approx C/n$
From basic geometry we know that <b>C</b> = <b>D</b> $\times \pi$ , therefore:
<b>D</b> $\approx (D \times \pi) / n$
$\pi \approx n$
since $\pi \approx 3$
hence <b>n</b> $\approx 3$
ie. trileaflet design works best

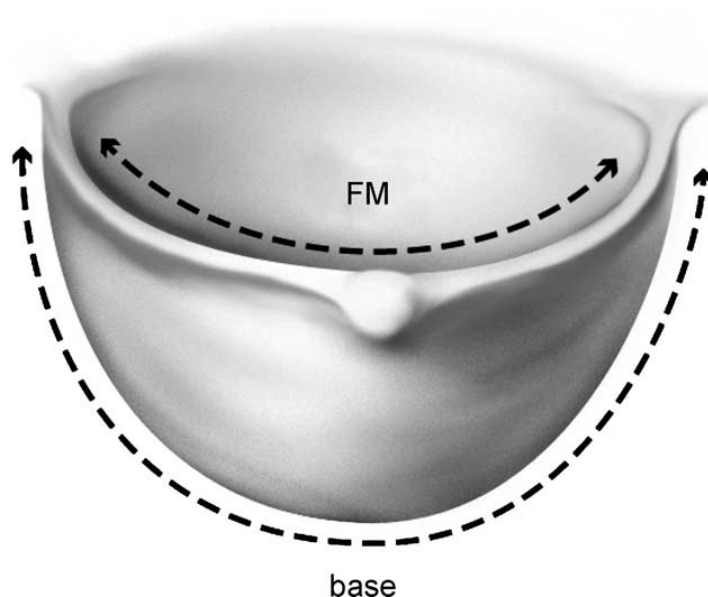
Table 1. Why a trileaflet valve is ideal geometric design

Therefore the ideal number of cusps whereby the valve will neither be incompetent nor stenotic is three (trileaflet). By similar arguments, we can understand how if a bileaflet valve is to open properly (i.e. not be stenotic) it will have redundant FM in the closed position, and thus prolapse and become incompetent. On the other hand, if the bileaflet valve is to close properly (i.e. with no prolapse), it will have a smaller diameter than the STJ in the open position and therefore be stenotic.

We can also derive the geometrically ideal FM length in relation to the length of the line of valve attachment.

The line of attachment of the leaflet is approximately a semicircle. Thus in the open position with the free margin of the leaflet hugging the line joining the 2 adjacent commissures, the FM approximates the diameter of the semicircle. Therefore,

$$\text{Base} \approx \pi/2 \times \text{FM} \approx 1.5 \times \text{FM}$$



*Reprinted from Heart, Lung and Circulation, 2004;13 Suppl 3, Matalanis G, Valve sparing aortic root repairs--an anatomical approach. S13-18., Copyright (2004), with permission from Elsevier*

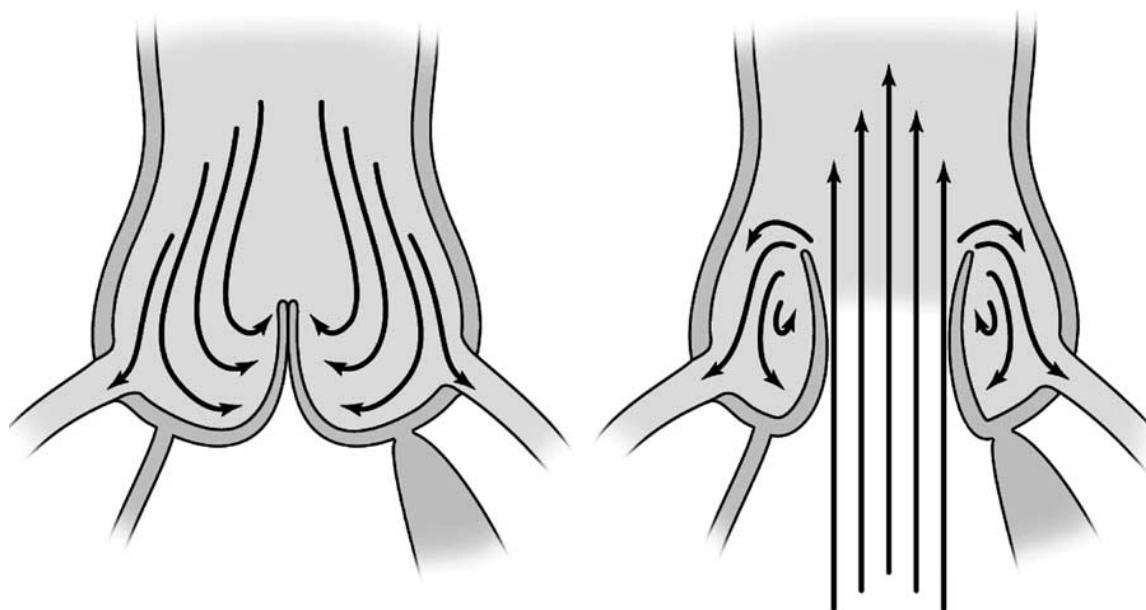
Fig. 3. The relationship between the base and free margin lengths –  $\text{base} \approx 1.5 \times \text{FM}$

There are three aortic sinuses corresponding to the respective leaflets. These sinuses play an important role in minimising leaflet stress and strain [4] by helping to evenly distribute the diastolic pressure load across the leaflets and the sinus wall through the formation of a relatively spherical shape together with the valve cusps.

A spherical surface is the shape that gives the minimal surface area for a given volume, thus minimising the stress forces on the leaflets in diastole.

In systole, the sinuses allow the development of eddy currents, which prevent contact between leaflet and aortic wall (Fig. 4). This may also keep the leaflets away from the coronary ostia, however this is not likely to be a major factor as the majority of coronary flow occurs during diastole. In late systole, these currents help the leaflets drift towards the centre, such that they are in contact immediately prior to the onset of diastole [5]. This results in closure prior to the reversal of pressure difference across the valve, thus abolishing early diastolic regurgitation.

It has been shown that increased stiffness of the aortic sinuses in advanced age and atherosclerosis contributes towards valve degeneration [6]. With reduced sinus compliance, leaflets may be more inclined to abruptly contact the aortic wall upon opening causing valve damage, while the delay in eddie current formation, with subsequent delay in valve closure may increase the regurgitant volume [3].



*Reprinted from Heart, Lung and Circulation, 2004;13 Suppl 3, Matalanis G, Valve sparing aortic root repairs--an anatomical approach. S13-18., Copyright (2004), with permission from Elsevier*

Fig. 4. The aortic sinuses form an integral part of the normal aortic valve function both in diastole and systole

### 3. Aortic root pathology

This chapter will focus primarily on aortic valve regurgitation, the most common cause of which is aortic root dilatation. Even in patients with an intact aortic root, dilatation of the ascending aorta may result in aortic regurgitation secondary to sinotubular junction dilatation. Age-related aortic dilatation is the most common cause of aortic dilatation. With age, degenerative changes in collagen and elastin leads to weakness and dilatation of the aortic wall. A genetic component also exists, whereby up to 15% of first-degree relatives to those with aortic aneurysms being affected.

Dilatation of the aorta is common in patients with Marfan's syndrome. Here, a defect in the glycoprotein fibrillin-1 results in cystic medial degeneration in the aortic wall, predisposing individuals to aortic dilatation. These patients are usually younger, and the aortic sinuses are the first to dilate, followed by the sinotubular junction and eventually the aortic annulus, result in leaflet prolapse and regurgitation. Loeys-Dietz syndrome is connective tissue disorder, it results from mutations in the genetic coding of transforming growth factor beta 1, which leads to aortic dilatation. Type IV Ehler Danlos syndrome is a deficiency in type III collagen, again increasing the risk of developing aneurysms of the aorta.

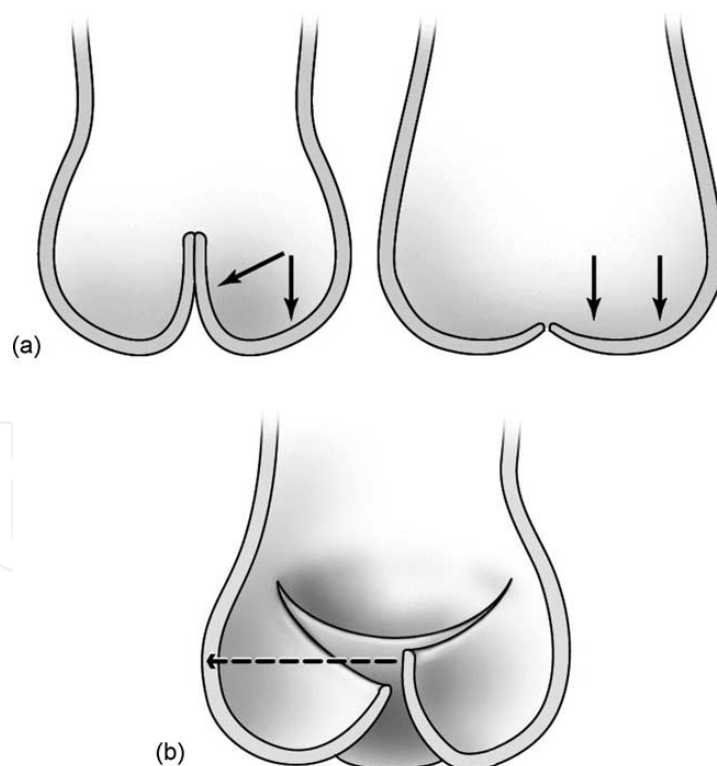
Additional causes for aortic aneurysms include arteritis (Giant Cell, Takayasu's, Kawasaki), infection (syphilitic, mycotic), systemic lupus erythematosus, ankylosing spondylitis and rarely due to granulomatous disease.

Nevertheless, in many patients, the aetiology of aortic aneurysms is multifactorial, with additional clinical characteristics such as age, hypertension and male gender among others serving as risk factors.

Acute or chronic type A dissections of the aorta is also a cause for valve regurgitation, resulting from commissural detachment due to the proximally propagating dissection. Patients with dissection may also have aortic regurgitation secondary to pre-existing aneurysmal disease.

As one of the most common congenital cardiac anomalies, bicuspid aortic valves (BAV) are found in between 1-2% of the population. BAVs may be anatomically or purely 'bicuspid' (Type 0), that is, consisting of two completely developed cusps, sinuses and commissures. However, most BAVs are functionally bicuspid (Type 1), in that three sinuses exist, with two cusps of different sizes whereby the larger cusp contains a median raphe, representing an obliterated or malformed commissure. This raphe extends from the mid-point of the cusp's free margin to the aortic annulus, inserting at a lower level than the other commissures.

Patients with BAV are at increased risk of developing aortopathy such as aortic dilatation and acute dissection. This may be due to a combination of 1) genetic predisposition, whereby the aortic tissue weakness and fragility responsible for dilatation is a manifestation of a development defect afflicting both the aortic valve and wall and 2) the haemodynamic abnormality caused by a bicuspid valve such as eccentric turbulence is responsible for aortic dilatation. Although there is widespread support for the genetic theory, some debate still exists as to which process exerts the most dominant effect [7].



*Reprinted from Heart, Lung and Circulation, 2004;13 Suppl 3, Matalanis G, Valve sparing aortic root repairs--an anatomical approach. S13-18., Copyright (2004), with permission from Elsevier*

Fig. 5. Leaflet prolapse (a) results in reduction of the area of coaptation between the leaflets and thus the security of the "seal" in diastole. Asymmetrical prolapse (b) will result in aortic regurgitation at a much earlier stage



3.1 Classification of aortic regurgitation

While the Carpentier classification for mitral valve regurgitation has seen widespread application, in recent years, a similar functional classification system for aortic regurgitation has been developed by El Khoury and colleagues [8]. In this system, the aortic valve is viewed as two components, the annulus and valve leaflets, the former consisting of the ventriculo-aortic junction and the sinotubular junction.

The system classifies aortic regurgitation as secondary to I) dilatation of the aortic root structures, II) excessive leaflet motion (ie. prolapse) or III) restriction in leaflet motion such as that in bicuspid, rheumatic and other degenerative processes. One or more of these lesions may be present in to a given case of aortic regurgitation [8].

3.2 Clinical consequences of aortic regurgitation

Untreated symptomatic aortic regurgitation carries a poor prognosis. In patients with New York Heart Association Class III or IV symptoms, 4-year survival is around 30% [9] Symptomatic patients should be offered prompt surgical intervention for aortic regurgitation. Asymptomatic patients should be considered for surgery when left ventricular dimensions increase above the normal range or when ventricular function begins to decline.

In patients with aneurysms of the aortic root, valve-sparing aortic root surgery should be considered when root diameter exceeds 50mm. In those with Marfan’s syndrome or a history of aortic dissection, surgery should be considered at 45mm regardless of the prospect of valve preservation.

<i>Conditions when 45mm is a trigger for replacement</i>	
1.	Marfan’s, Loeys-Dietz, etc
2.	Bicuspid valve needing an operation alone
3.	Strong family history of rupture/ dissection
4.	Rapid progression of aneurysm (>5mm/year)

Table 2. Conditions where aortic dilatation of 45mm is a trigger for replacement

Surgery for replacement of the ascending aorta should be considered when the diameter reaches 50mm.

Surgery may be offered earlier in the presence of a rapidly enlarging aneurysm or co-existing moderate to severe aortic regurgitation. In the case of the latter, earlier surgery before the aneurysm has reached a substantial size may increase the chances of valve preservation by limiting further stretching of valve cusps beyond repair. Aneurysms of the aortic root are the most common indication for surgery.

4. Surgical management

4.1 Peri-operative evaluation

Trans-oesophageal echo (TOE) affords an excellent tool for the diagnosis of the mechanism of aortic regurgitation and is essential intra-operatively to assess the quality of the repair. The two dimensional axial and longitudinal views of the aortic root allow measurement of the aortic annulus, STJ, ascending aorta, as well aortic cusp free margin diameters. The plane of coaptation and leaflet prolapse or folding can be easily demonstrated. Colour

doppler allows quantification of the severity of regurgitation and its direction. Eccentricity of the jet can give vital clues of leaflet prolapse or restriction.

Contrast-enhanced computed tomography of the chest is used to assess aneurysm morphology and coronary angiography should be routinely performed to determine the need for concomitant bypass grafting.

#### **4.2 Intra-operative technique**

Access to the heart is obtained via median sternotomy. Cardiopulmonary bypass with ascending aorta, femoral or axillary artery cannulation may be required depending on the specifics of concomitant ascending arch pathology.

#### **4.3 Valve sparing aortic root replacement**

Valve-sparing aortic root reconstruction involves preservation of the native aortic valve while replacing the ascending aorta. This procedure was initially described by Dr Tirone David [10] and Sir Magdi Yacoub [11]. The two main techniques in widespread practice are aortic valve re-implantation and aortic root remodelling.

Repair of the aortic valve leaflets may be essential for short and long term success of the operation, if there is significant leaflet prolapse or restriction.

##### **4.3.1 Aortic root remodelling**

The first technique for correction of aortic root dilatation was described by Sir Magdi Yacoub [11] and subsequently also by Dr Tirone David (David Remodelling procedure). This procedure corrects STJ dilatation and creates neo-aortic sinuses, but does not affect the annular size.

In this technique, the ascending aorta is transected and the aortic root is excised to within 2–3mm of the valve attachment. Subsequently, a Dacron graft sized to the ideal STJ diameter is incised to create 3 evenly spaced tongues. This mimics the aortic sinuses, thus creating a neo-aortic root (Fig. 6 and 7). The apices of the valve commissures are then anastomosed to the corresponding points on the trimmed graft with pledgeted mattress sutures. The proximal sewing line is completed with a running polypropylene suture.

In a modification of the David Remodelling procedure, a separate Teflon “annuloplasty” is added in an attempt to prevent future annular dilatation. This annular plication is not done circumferentially, but over the length of the fibrous LVOT, which is the component most often affected by dilatation.

##### **4.3.2 Aortic valve re-implantation**

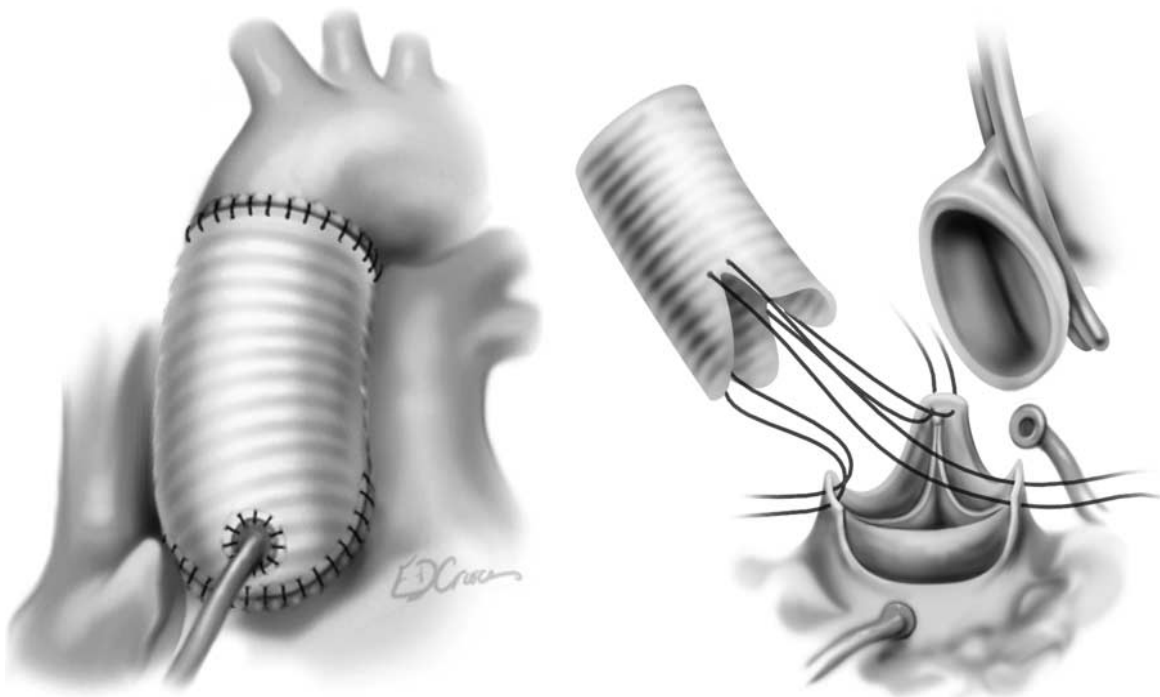
The re-implantation technique is performed by excising the aortic sinuses and placing a row of braided non-absorbable horizontal mattress sutures evenly around the left ventricular outflow tract below the level of the annulus (Fig. 8). These are passed through the proximal end of the graft which is tied in position as an external annuloplasty. The commissures are firstly secured within the graft ensuring that they are taught and vertically upright (Fig. 9 and 10), then the remnant of the aortic sinus tissue is then re-implanted inside the prosthesis with running polypropylene suture.

In the David re-implantation procedure, a single Dacron graft is used to achieve both annular and STJ plication. The advantages are greater simplicity and haemostasis. The disadvantages are incorporation of the muscular LVOT in the plication process, which if excessive may result in a higher than normal sub-annular gradient.





Fig. 6. Insertion of the fashioned graft during the root remodelling procedure



*Reprinted from Heart, Lung and Circulation, 2004;13 Suppl 3, Matalanis G, Valve sparing aortic root repairs--an anatomical approach. S13-18., Copyright (2004), with permission from Elsevier*

Fig. 7. Final appearance of the aortic root after aortic root remodelling

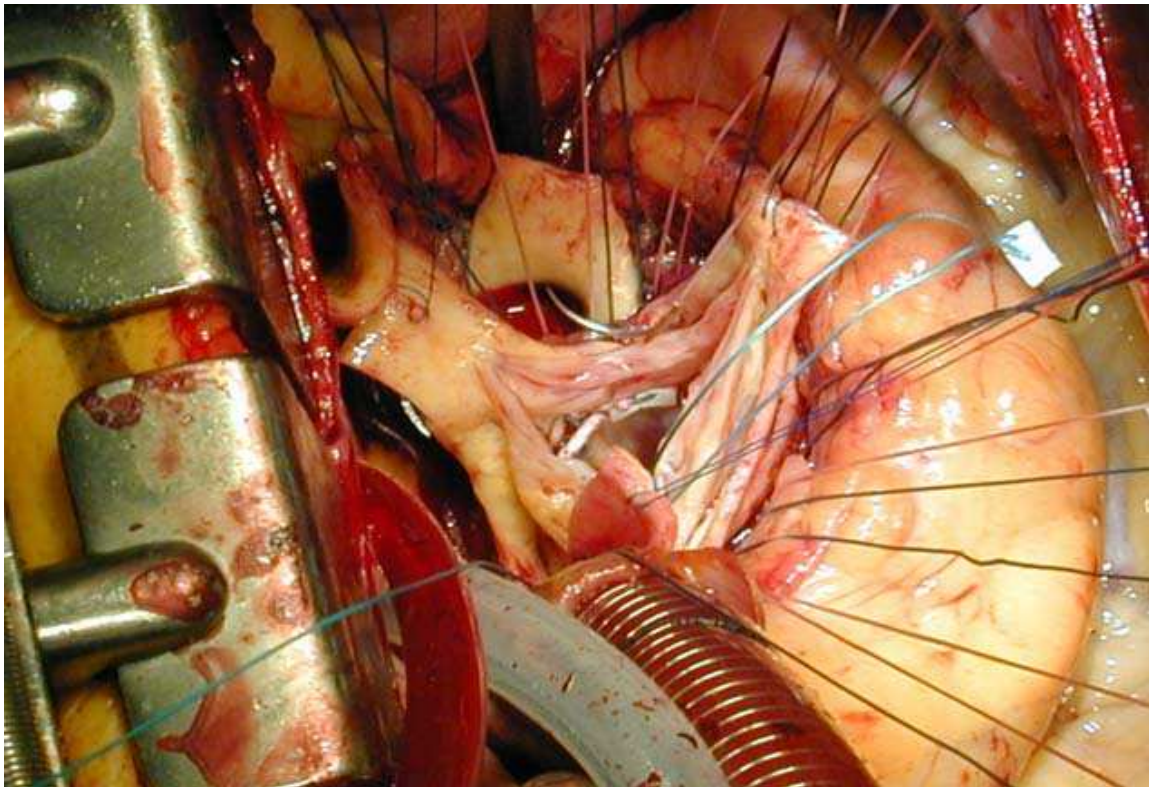


Fig. 8. Placement of horizontal mattress sutures around the left ventricular outflow tract during root re-implantation

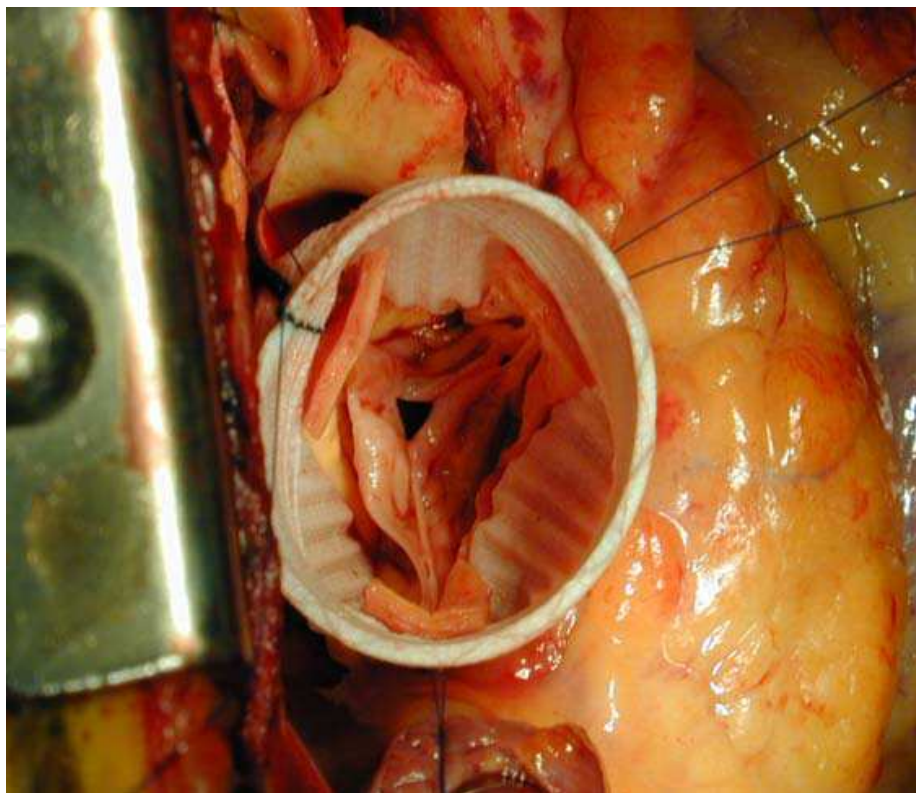
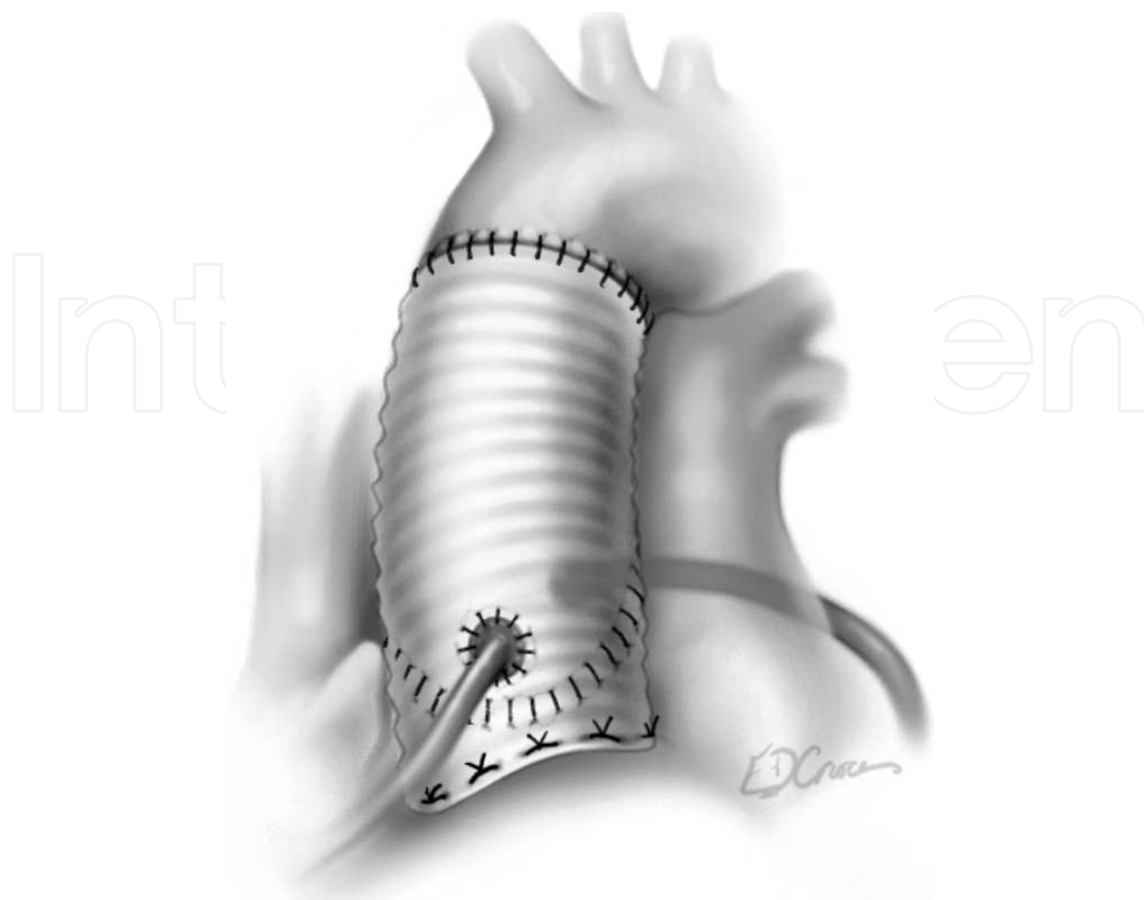


Fig. 9. Re-implantation of the native aortic valve within the vascular graft



*Reprinted from Heart, Lung and Circulation, 2004;13 Suppl 3, Matalanis G, Valve sparing aortic root repairs--an anatomical approach. S13-18., Copyright (2004), with permission from Elsevier*

Fig. 10. Final appearance of the reconstructed aortic root following the re-implantation procedure

#### 4.3.3 Recreating the sinuses of Valsalva

When the re-implantation technique was first described by David and Feindel, one perceived disadvantage was the potential physiological disturbance caused by the attachment of a tubular graft to the aortic annulus, thus eliminating the aortic sinuses. Given the role of the sinuses in preventing leaflet stress and strain, there was a concern that their absence would result in abnormal motion of the cusps and contribute toward structural deterioration and late recurrent regurgitation [3].

Subsequently, various modifications were proposed for the creation pseudosinuses to minimise physiological disturbance. The most commonly used technique involves oversizing a tubular graft (diameter which is twice the average height of the cusps) and placing plicating sutures at the level of the annulus and STJ. This acts to “pinch down” the graft, resulting in an outward bulge where the native sinuses would be located [12, 13]. This is sometimes referred to as the “David V” or “Stanford” modification [14].

To minimise the need for technical modifications to the re-implantation procedure, Ruggero De Paulis introduced the Valsava Graft, a Dacron conduit which incorporates the sinuses of Valsalva in the “skirt” portion of the graft [15]. This prosthesis recreates the normal shape of the aortic sinuses to enable normal valve motion, decrease stress, and potentially increase durability without the need for the manual fashioning of neosinuses.



#### 4.4 Sinotubular junction restoration

In cases where the sinuses of Valsalva and aortic annulus are not dilated, mere reduction of the sinotubular junction to an appropriate diameter will often cure valve incompetence. In such instances the ascending aorta is transected just above the commissures, which are pulled upward and towards each other until satisfactory coaptation of the aortic cusps are achieved. This is the diameter chosen for the graft.

In situations where the aortic cusps are asymmetric, the commissures may need to be spaced in a non-equidistant fashion such that the free margins coapt adequately. The vascular graft is subsequently anastomosed directly to the proximal ascending aorta at the sinotubular junction with a running 4-0 suture.

#### 4.5 Sizing the graft

Much has been said about formulae for choosing the correct diameter of graft. In our institution we prefer placing the three commisural sutures and then elevating them upwards and inward until adequate coaptation of the aortic valve is achieved. A standard prosthetic valve sizer is then used to obtain the diameter of this corrected annulus/STJ and a respective conduit is then chosen.

Care must be made when choosing a conduit size for a re-implantation procedure. After the prosthesis is placed over the annulus, an additional 3-5mm needs to be added to the diameter prior to selection. In our experience, most females have a diameter of 26 to 30mm and males 28 to 32mm. [16]

#### 4.6 Repair of aortic valve prolapse

It is important to note that in late presenting patients with very large aortic roots and severe aortic regurgitation, the leaflets are often overstretched with elongated free margins. Thus, after isolated correction of root dimensions the leaflets will tend to prolapse, even if they did not previously. This is not a contra indication to repair, and can be readily corrected.

Leaflets are assessed for prolapse as determined by a discrepancy in leaflet free margin height relative to its neighbours, and the cusp coaptation height. The latter is considered as indicative of prolapse if the height of coaptation above the level of the annulus is less than half of that of the top of the commissures.

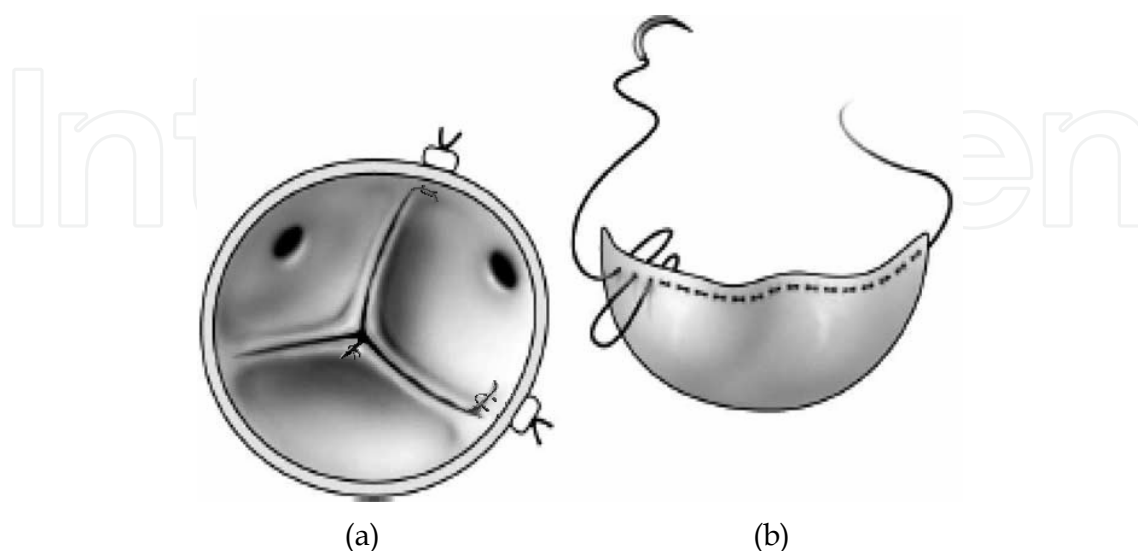
Prolapse can be readily corrected by shortening the free margin back to normal. Minor degrees can be corrected with simple fine plication sutures either at the mid-point of the free margin or at its commissural ends until satisfactory coaptation is achieved (Fig. 11a).

In patients with more extensive degrees of prolapse, or in those with stress fenestrations, a neo-free margin may be constructed with a running polytetrafluoroethylene suture, also known as leaflet "re-suspension", in addition to plication (Fig. 11b).

Patients with connective tissue pathology such as Marfan's syndrome present a unique challenge. Marfan's Syndrome has previously been reported as a predictor of recurrent aortic regurgitation after root replacement. In these patients, the valves are structurally abnormal due to altered fibrillin metabolism, resulting in greater fragility compared to normal cusps [17, 18]. As such, these patients may benefit from additional leaflet reinforcement with running polytetrafluoroethylene sutures in addition to plication, so as to pre-empt further leaflet free margin stretch or tears.

The optimal technique for correction of leaflet prolapse is yet to be established. Previous studies have found recurrence of aortic regurgitation after placing plicating sutures at the commissures, and hence have preferred placing them at the mid point of the free margin

[19]. However, at our centre, we have favored the former technique with encouraging results. It is an attractive approach as the peri-commissural areas are often the most stretched component in prolonged root dilatation and plication here provides support at the most vulnerable site.



*Reprinted from Heart, Lung and Circulation, 2004;13 Suppl 3, Matalanis G, Valve sparing aortic root repairs--an anatomical approach. S13-18., Copyright (2004), with permission from Elsevier*

Fig. 11. Methods of leaflet prolapse correction with (a) plication and (b) leaflet resuspension

#### 4.7 Isolated aortic valve repair

Isolated prolapse of trileaflet aortic valve cusps without co-existent aortic root dilatation is uncommon. However, when encountered, valve repair can be accomplished using the techniques described. Cusp perforation, such as that secondary to endocarditis, can be easily corrected by using autologous pericardium.

#### 4.8 Bicuspid aortic valves

A bicuspid valve's anterior cusp is most commonly prolapsed. Here, repair may be accomplished by placing plicating sutures at the free margin, or by placing a running polytetrafluoroethylene suture as with trileaflet valves. This approach works well for anatomically "pure" bicuspid valves (Type 0).

In functionally bicuspid valves (Type 1), attention must be paid to the raphe. If the raphe has adequate mobility and morphology, it may be shaved and preserved. However if it is severely restricted in movement or heavily calcified, a triangular resection of the raphe may be performed, the leaflet edges primarily reapproximated with running polypropylene sutures. If adequate tissue is not present, autologous or bovine pericardium may be used. Coaptation may be further enhanced with additional free margin plication and resuspension.

Where there is co-existent aortic root dilatation subcommissural triangle plication may be needed to enhance coaptation.

#### 4.9 Completion assessment / Post repair Transeophageal Echo (TOE)

Following completion of the root repair saline testing is performed and leaflets are assessed for competence, symmetry, prolapse or any restriction.

Once pulsatile flow is reestablished, intra-operative trans-oesophageal echocardiography is essential to assess the quality of the operation.

In our institution we do not accept regurgitation >1+ or eccentric jets. The level at which the FM coapts needs to be more than half way between the annulus and STJ, and the amount of coaptation needs to be greater than or equal to 5mm.

## 5. Outcomes of valve-sparing aortic root replacement and valve repair

Dr Tirone David and colleagues from the Toronto Group recently published their results on 289 patients undergoing valve-sparing aortic root replacement using both the re-implantation (n=228) and remodelling (n=61) techniques [12]. Nine percent of patients underwent surgery for acute type A dissection. Overall, freedom from recurrent regurgitation was high at 86.8%  $\pm$  3.8% at 12 years follow-up. Patients undergoing the re-implantation technique experienced greater freedom from recurrent regurgitation compared to those undergoing remodeling (91.0%  $\pm$  3.8% versus 82.6%  $\pm$  6.2%,  $p = 0.035$ ), however technique was not an independent predictor of late recurrent regurgitation. In this publication, the Toronto Group also showed that patient survival after undergoing valve-reimplantation was comparable to that of the general population when matched for age and gender.

The largest published series on the re-implantation technique is from Kallenbach and colleagues from Hannover, Germany, who in 2005, published their results of 284 consecutive patients undergoing the re-implantation procedure [20]. The series showed that the re-implantation procedure leads to excellent mid-term and late outcomes with freedom from re-operation due to recurrent aortic regurgitation was 91.1 $\pm$ 2.5% at 5 years and 87.1 $\pm$ 4.5% at 10 years. Late survival at 10 years was also high at 80.4 $\pm$ 5.7% at 10 years.

In recent years, most surgeons have favoured the re-implantation technique, given the reinforcement of the aortic annulus which prevents subsequent dilatation, which is particularly important in patients with connective tissue diseases such as Marfan syndrome. Indeed, the evidence suggests that the re-implantation technique is less likely to result in recurrent regurgitation in the long-term [12, 21].

### 5.1 Valve-sparing root replacement with concomitant valve repair

Valve-sparing aortic root replacement was principally conceived for patients with morphologically normal valve leaflets where aortic regurgitation was caused solely by a dilated root. They were initially applied to patients with early grades of aortic regurgitation and less severe aortic root dilatation where the leaflets have only been minimally stretched. However, combining leaflet prolapse correction with aortic valve sparing techniques permits extension of the benefits of valve sparing procedures to patients with advanced aortic regurgitation or aneurysms. In the past decade, there has been growing interest in such an approach.

In David and colleagues' earlier experience, published in 2001 [22], only 11% of patients underwent repair of cusp prolapse. However, almost a decade later, the group's latest report shows that 40% of patients had at least one leaflet free margin plicated while 22% underwent reinforcement of the free margin with a running polytetrafluoroethylene suture [12].

In a seminal publication, the Brussels Group, recently presented their results on 264 patients undergoing elective aortic valve repair for regurgitation occurring in isolation (43%) and in combination with aortic dilatation (57%) [8]. Leaflet repair techniques included free margin plication, resuspension as well as triangular resection with pericardial patch repair, while

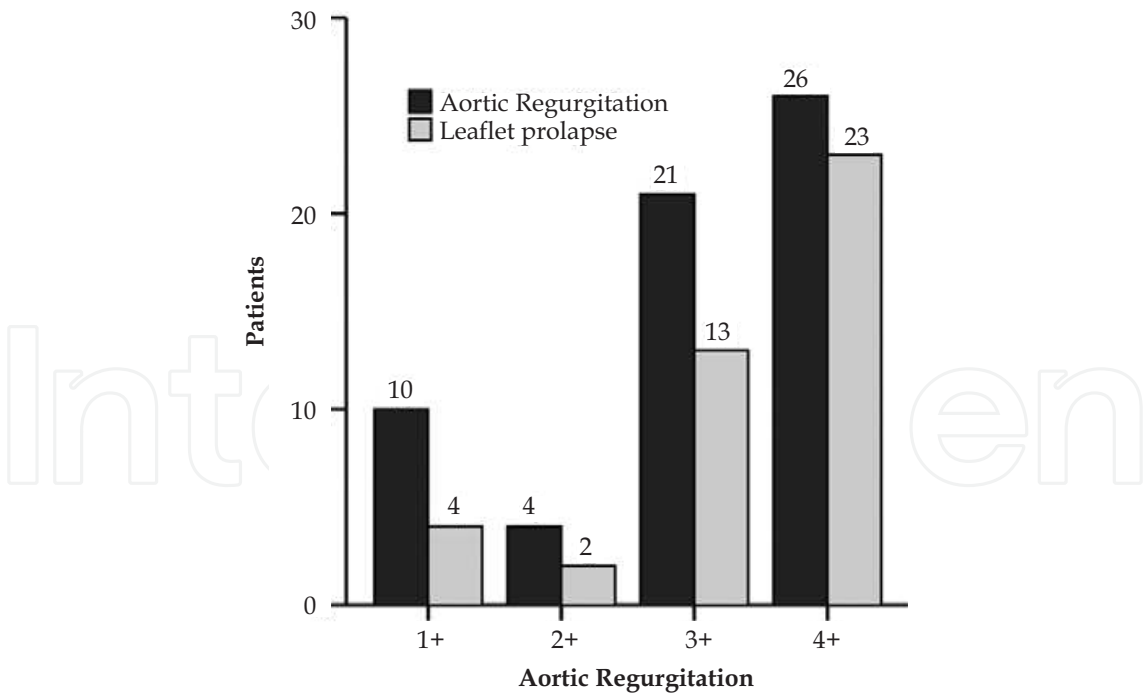


combinations of valve-sparing procedures, sinotubular plication, and subcommissural annuloplasty was used to stabilise the annulus. The series is notable in that pre-operatively, 75% of patients had >2+ aortic regurgitation with a mean aortic diameter of  $53 \pm 9$ mm, suggesting the presence of long-standing disease whereby leaflets were reasonably stretched, which a decade ago would have been viewed to be a relative contraindication to valve preservation. Despite this, Freedoms from aortic regurgitation greater than 2+ were high at  $88 \pm 3\%$  at 5 years and  $79 \pm 11\%$  at 8 years, reflecting good durability of repair [8].

In a separate paper, the group reported their results on 111 patients with tri-leaflet valves undergoing repair of cusp prolapse with (n=61) or without (n=50) an associated aortic aneurysm. The re-implantation and sub-commissural annuloplasty techniques were predominantly used to correct aortic root dimensions, while free margin plication and resuspension were performed for cusp repair. At 8 years, freedom from recurrent regurgitation was high at  $93 \pm 5\%$  and  $87 \pm 7\%$  for patients with and without aortic aneurysms respectively. The number of cusps repaired and the technique used were not associated with recurrent regurgitation [23].

Performing valve repair alongside valve-sparing root replacement has gained popularity in recent years with several groups finding it to lead to strong mid-term results, with most studies reporting 5 year freedom from recurrent regurgitation rates of 85-95%.

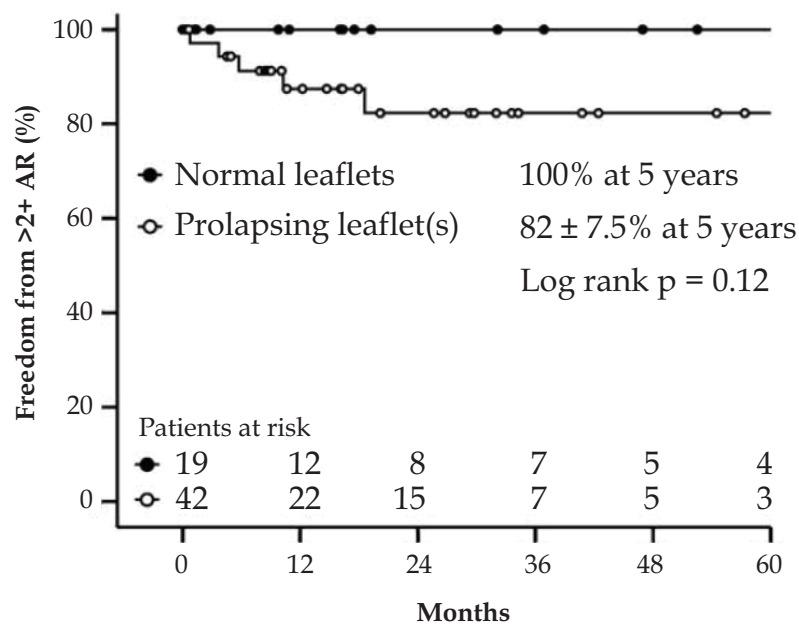
We recently reported our local experience of 61 cases [16] with a relatively aggressive approach towards valve-preservation. Seventy-seven percent of patients had >2+ aortic regurgitation pre-operatively and a total of 69% of patients in the series required aortic valve repair for prolapse (Fig. 12). At mid-term follow-up, 5-year freedom from recurrent regurgitation was encouraging at  $88 \pm 5.3\%$ .



*Reprinted from the European Journal of Cardio-Thoracic Surgery, 2010;37:6, Matalanis G, Shi WY, Hayward PAR, Correction of leaflet prolapse extends the spectrum of patients suitable for valve-sparing aortic root replacement.1311-1316., Copyright (2010), with permission from Elsevier*

Fig. 12. In our local experience, greater than 2+ regurgitation and leaflet prolapse was present in a significant proportion of patients

A recent report from Luebeck presenting data on 191 remodeling and re-implantation procedures suggested that cusp repair was associated with an increased rate of late recurrent regurgitation. The authors attributed this to a number of factors including the presence of valves unsuitable for repair, fibrotic retraction of the repaired cusps, improper surgical techniques and other tissue properties [24]. Indeed, in our recent published experience, we observed a trend towards greater recurrent regurgitation in patients who had prolapsed leaflets, which did not reach statistical significance [16] (Fig. 13). We have addressed this by use of more aggressive valve reinforcement with free margin running polytetrafluoroethylene sutures in selected patients with particularly stretched leaflets. Furthermore, in extreme cases, valve-preservation is judiciously avoided with replacement performed instead. In doing so, we hope to minimize the rate of recurrent aortic regurgitation such that it approaches the level seen in patients without leaflet prolapse.



Reprinted from the European Journal of Cardio-Thoracic Surgery, 2010;37:6, Matalanis G, Shi WY, Hayward PAR, Correction of leaflet prolapse extends the spectrum of patients suitable for valve-sparing aortic root replacement.1311-1316., Copyright (2010), with permission from Elsevier

Fig. 13. Our local experience with valve-sparing aortic root replacement with concomitant valve repair

Even if we acknowledge an early marginal reduction in valve durability after very aggressive prolapse correction, it is still an excellent option for many patients, particularly those for whom long term anticoagulation is unacceptable, as seems increasingly common in clinical practice.

5.2 Bicuspid aortic valves

The largest reported series concerning repair of bicuspid aortic valves again comes from the Brussels Group, who recently published their outcomes on 122 consecutive patients undergoing bicuspid repair [25]. Of these, 57% had aortic regurgitation due to aortic dilatation while the remaining exhibited isolated valve insufficiency. Free margin plication and resuspension was performed in the 20% of patients with anatomically bicuspid (Type 0)

valves. Those with functionally bicuspid (Type 1) valves, raphe repair was accomplished by either shaving, resection or use of a pericardial patch. At 5 years, freedom from recurrent regurgitation was high at  $94\pm 3\%$ . Furthermore, in unadjusted analyses, patients undergoing a root procedure (remodelling or reimplantation) had a greater freedom from recurrent regurgitation compared to those undergoing subcommissural annuloplasty or sinotubular junction plication ( $95\pm 5\%$  vs  $80\pm 6\%$  at 5 years,  $p=0.03$ ) [25].

### 5.3 Impact of the vascular prosthesis

De Paulis and colleagues showed that early valve motion after re-implantation inside the Valsalva prosthesis was similar to those of normal subjects, with graft distensibility being retained at the neosinuses [26]. At late follow-up, the elasticity of the graft's sinuses were also to an extent maintained, with the graft replying to the changes in pressure between systole and diastole [27]. Further studies may elucidate any haemodynamic or clinical differences between techniques used to create neosinuses. Implantation of the Valsalva prosthesis removes the need to fashion neosinuses from a tube graft, which may prove advantageous by reducing aortic cross clamp times in cases where the aortic pathology extends into the aortic arch requiring complex reconstruction.

## 6. Conclusions

Evidence thus far shows that preservation and repair of the native aortic valve can be achieved with promising mid-term outcomes. It is rapidly becoming an accepted part of routine clinical practice. We believe that further studies with long-term follow up will reveal the greater potential of valve-sparing aortic root replacement and aortic valve repair.

## 7. Acknowledgements

The authors wish to acknowledge Ms Beth Croce for her illustrative work.

## 8. Disclosures

Professor Matalanis, Dr . Shi and Dr. O'Keefe report no conflicts of interest.

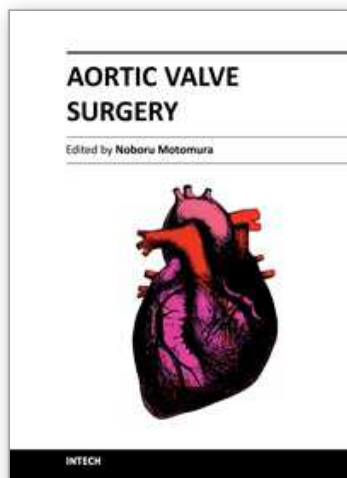
## 9. References

- [1] Swanson M, Clark RE. Dimensions and geometric relationships of the human aortic valve as a function of pressure. *Circ Res* 1974;35:871-882.
- [2] Silver MA, Roberts WC. Detailed anatomy of the normally functioning aortic valve in hearts of normal and increased weight. *Am J Cardiol* 1985;55:454-461.
- [3] Kunzelman KS, Grande KJ, David TE, Cochran RP, Verrier ED. Aortic root and valve relationships. Impact on surgical repair. *J Thorac Cardiovasc Surg* 1994;107:162-170.
- [4] Katayama S, Umetani N, Sugiura S, Hisada T. The sinus of valsalva relieves abnormal stress on aortic valve leaflets by facilitating smooth closure. *J Thorac Cardiovasc Surg* 2008 136:1528-1535.
- [5] Bellhouse BJ Bellhouse FH. Mechanism of closure of the aortic valve. *Nature* 1968;217:86-87.
- [6] Robicsek F, Thubrikar MJ. Role of sinus wall compliance in aortic leaflet function. *Am J Cardiol* 1999;84:944-946.

- [7] Girdauskas E, Borger MA, Secknus MA, Girdauskas G, Kuntze T. Is aortopathy in bicuspid aortic valve disease a congenital defect or a result of abnormal hemodynamics? A critical reappraisal of a one-sided argument. *Eur J Cardiothorac Surg* 2011;doi:10.1016/j.ejcts.2011.01.001.
- [8] Boodhwani M, de Kerchove L, Glineur D, Poncelet A, Rubay J, Astarci P, Verhelst R, Noirhomme P, El Khoury G. Repair-oriented classification of aortic insufficiency: Impact on surgical techniques and clinical outcomes. *J Thorac Cardiovasc Surg* 2009;137:286-294.
- [9] Dujardin KS, Enriquez-Sarano M, Schaff HV, Bailey KR, Seward JB, Tajik AJ. Mortality and morbidity of aortic regurgitation in clinical practice. A long-term follow-up study. *Circulation* 1999;99:1851-1857.
- [10] David TE., Feindel CM. An aortic valve-sparing operation for patients with aortic incompetence and aneurysm of the ascending aorta. *Journal of Thoracic and Cardiovascular Surgery* 1992;103:617-621.
- [11] Sarsam MA, Yacoub M. Remodeling of the aortic valve anulus. *J Thorac Cardiovasc Surg* 1993;105:435-438.
- [12] David TE, Maganti M, Armstrong S. Aortic root aneurysm: Principles of repair and long-term follow-up. *J Thorac Cardiovasc Surg* 2010;140:S14-19.
- [13] David TE. The aortic valve-sparing operation. *J Thorac Cardiovasc Surg* 2011 141:613-615.
- [14] Demers P, Miller DC. Simple modification of "T. David-v" Valve-sparing aortic root replacement to create graft pseudosinuses. *Ann Thorac Surg* 2004 78:1479-1481.
- [15] De Paulis R, De Matteis GM, Nardi P, Scaffa R, Buratta MM, Chiariello L. Opening and closing characteristics of the aortic valve after valve-sparing procedures using a new aortic root conduit. *Ann Thorac Surg* 2001;72:487-494.
- [16] Matalanis G, Shi WY, Hayward PA. Correction of leaflet prolapse extends the spectrum of patients suitable for valve-sparing aortic root replacement. *Eur J Cardiothorac Surg* 2010;37:1311-1316.
- [17] Fleischer KJ, Nousari HC, Anhalt GJ, Stone CD, Laschinger JC. Immunohistochemical abnormalities of fibrillin in cardiovascular tissues in marfan's syndrome. *Ann Thorac Surg* 1997;63:1012-1017.
- [18] Missirlis YF, Armeniades CD, Kennedy JH. Mechanical and histological study of aortic valve tissue from a patient with marfan's disease. *Atherosclerosis* 1976;24:335-338.
- [19] Hans-Joachim S, Diana A, Frank L. Correction of leaflet prolapse in valve-preserving aortic replacement: Pushing the limits? *Ann Thorac Surg* 2002;74:S1762-1764.
- [20] Kallenbach K, Karck M, Pak D, Salcher R, Khaladj N, Leyh R, Hagl C, Haverich A. Decade of aortic valve sparing reimplantation: Are we pushing the limits too far? *Circulation* 2005;112:I-253-259.
- [21] Liu L, Wang W, Wang X, Tian C, Meng YH, Chang Q. Reimplantation versus remodeling: A meta-analysis. *J Card Surg* 2011;26:82-87.
- [22] David TE, Armstrong S, Joan I, Christopher FM., Ahmad O, Gary W. Results of aortic valve-sparing operations. *Journal of Thoracic and Cardiovascular Surgery* 2001;122:39-46.
- [23] Boodhwani M, de Kerchove L, Watremez C, Glineur D, Vanoverschelde JL, Noirhomme P, El Khoury G. Assessment and repair of aortic valve cusp prolapse: Implications for valve-sparing procedures. *J Thorac Cardiovasc Surg* 2011;141:917-925.

- [24] Hanke T, Charitos EI, Stierle U, Robinson D, Gorski A, Sievers HH, Misfeld M. Factors associated with the development of aortic valve regurgitation over time after two different techniques of valve-sparing aortic root surgery. *J Thorac Cardiovasc Surg* 2009;137:314-319.
- [25] Boodhwani M, de Kerchove L, Glineur D, Rubay J, Vanoverschelde JL, Noirhomme P, El Khoury G. Repair of regurgitant bicuspid aortic valves: A systematic approach. *J Thorac Cardiovasc Surg* 2010;140:276-284.
- [26] De Paulis R, De Matteis GM, Nardi P, Scaffa R, Bassano C, Chiariello, L. Analysis of valve motion after the reimplantation type of valve-sparing procedure (david i) with a new aortic root conduit. *Ann Thorac Surg* 2002:53-57.
- [27] Monti L, Mauri G, Balzarini L, Tarelli G, Brambilla G, Vitali E, Ornaghi D, Citterio E, Settepani F. Compliance of the valsalva graft's pseudosinuses at midterm follow-up with cardiovascular magnetic resonance. *Ann Thorac Surg* 2011;91:92-96.

IntechOpen



## **Aortic Valve Surgery**

Edited by Prof. Noboru Motomura

ISBN 978-953-307-600-3

Hard cover, 246 pages

**Publisher** InTech

**Published online** 22, December, 2011

**Published in print edition** December, 2011

The aortic valve is located at the center of the heart. It is the core of cardiac anatomy and aortic valve surgery has led the field of cardiac surgery. This book describes all aspects of aortic valve surgery and it will help clarify daily questions regarding the clinical practice in aortic valve surgery, as well as induce inspiration and new insights into this field.

### **How to reference**

In order to correctly reference this scholarly work, feel free to copy and paste the following:

William Y. Shi, Michael O' Keefe and George Matalanis (2011). Valve-Sparing Aortic Root Replacement and Aortic Valve Repair, Aortic Valve Surgery, Prof. Noboru Motomura (Ed.), ISBN: 978-953-307-600-3, InTech, Available from: <http://www.intechopen.com/books/aortic-valve-surgery/valve-sparing-aortic-root-replacement-and-aortic-valve-repair>

**INTech**  
open science | open minds

### **InTech Europe**

University Campus STeP Ri  
Slavka Krautzeka 83/A  
51000 Rijeka, Croatia  
Phone: +385 (51) 770 447  
Fax: +385 (51) 686 166  
[www.intechopen.com](http://www.intechopen.com)

### **InTech China**

Unit 405, Office Block, Hotel Equatorial Shanghai  
No.65, Yan An Road (West), Shanghai, 200040, China  
中国上海市延安西路65号上海国际贵都大饭店办公楼405单元  
Phone: +86-21-62489820  
Fax: +86-21-62489821



© 2011 The Author(s). Licensee IntechOpen. This is an open access article distributed under the terms of the [Creative Commons Attribution 3.0 License](https://creativecommons.org/licenses/by/3.0/), which permits unrestricted use, distribution, and reproduction in any medium, provided the original work is properly cited.

IntechOpen

IntechOpen