

# We are IntechOpen, the world's leading publisher of Open Access books Built by scientists, for scientists

6,900

Open access books available

185,000

International authors and editors

200M

Downloads

Our authors are among the

154

Countries delivered to

TOP 1%

most cited scientists

12.2%

Contributors from top 500 universities



WEB OF SCIENCE™

Selection of our books indexed in the Book Citation Index  
in Web of Science™ Core Collection (BKCI)

Interested in publishing with us?  
Contact [book.department@intechopen.com](mailto:book.department@intechopen.com)

Numbers displayed above are based on latest data collected.  
For more information visit [www.intechopen.com](http://www.intechopen.com)



# Gamma Knife Radiosurgery in the Management of Unusual Grade I/II Primitive Neuroepithelial Tumours of the Brain

A. Nicolato<sup>1</sup>, M. Longhi<sup>1</sup>, R. Foroni<sup>2</sup>, F. Alessandrini<sup>2</sup>, A. De Simone<sup>1</sup>,  
C. Ghimenton<sup>2</sup>, A. De Carlo<sup>1</sup>, P. Mirtuono<sup>3</sup> and M. Gerosa<sup>1</sup>

*Multidisciplinary Neurooncologic Group of Verona,*

<sup>1</sup>*Department of Neurological Sciences*

<sup>2</sup>*Department of Pathology and Diagnosis*

<sup>3</sup>*Department of Neurological, Neuropsychological,  
Morphological and Movement Sciences*

*Section Anatomy, University Hospital (AOUI) of Verona,  
Italy*

## 1. Introduction

Now, Gamma Knife radiosurgery (GKRS) is considered a first choice therapeutic option in a wide setting of malignant and benign intracranial diseases. Particularly, the application of GKRS in pilocytic (GI) and diffuse (GII) astrocytomas, which currently represent the most frequent brain neoplasms in children and young adults, has been often described. In the different series, the reported overall tumor growth control (TGC) varies between 50%-100%, the Overall Survival (OS) is 78.6%-100% with a 5-year local progression free survival (PFS) comprised between 88.9% and 97.4%. The GKRS-related permanent neurologic morbidity is generally less than 5% (0%-7%) (Kano et al., 2009a; Kano et al., 2009b; Boethius et al., 2002; Hadjipanayis et al., 2002a; Hadjipanayis et al., 2002b; Kida et al., 2000; Simonova et al., 2005; Heppner et al., 2005). Therefore, GKRS is considered an effective and safe therapeutic tool in the multidisciplinary treatment of pilocytic and diffuse astrocytomas, as well. Nevertheless, the effectiveness of GKRS is much less known as concerns other unusual Low-Grade Primitive Neuroepithelial Tumors (LGPNTs) of the brain because data regarding the long-term efficacy of GKRS on a large series of patients with such tumors is lacking. The aim of this chapter is to assess the value of GKRS in the management of such cerebral tumors. The interest of this study is founded on several observations: 1) unusual LGPNTs are rare tumours; there are a few series with at least ten reported cases, only (Hasegawa et al., 2002; Kim et al., 2007); 2) these tumors are frequently deep-seated in the brain or located in functional cerebral regions, thus gross total surgical removal may often be highly risky or impossible sometimes; 3) unusual LGPNTs are more frequent in children and young adult patients (Reyns et al., 2006; Yen et al., 2007). Furthermore, the management of residual, recurrent or unresectable tumours represent a challenge for neurosurgeons and neurooncologists due to: 1) histotypes with frequently high radio- and chemo-resistance; 2) high risk of permanent delayed brain tissue radiation damage in often very young patients and with long life expectancy. The reason behind the increased

use of GKRS in unusual LGPNTs, also, is that the highly conformal treatment planning possible with this technique allows delivery of citotoxic dose of radiation to the target field while minimazing the dose delivered to neighboring vital structures. Hence, radiosurgery may be a less morbid alternative for treating deep-seated or functional-located lesions surrounded by eloquent structures. It therefore becomes possible to avoid toxic systemic side effects due to less effective antitlastic drugs, to preserve neurological function, to prevent further tumor growth and/or reinterventions in residual or recurrent tumors with remarkably low risks of acute radiation injury or delayed radiation therapy (RT)-related sequelae. In this chapter, the results of a retrospective study on 30 unusual LGPNTs of the brain treated with GKRS and followed up for at least 2 years will be presented and discussed. The end-points of this study will regard the OS, overall local TGC, actuarial Survival and local PFS (on the whole series and evaluated on different histologies) rates, and GKRS-related permanent side effects. Furthermore, a statistical analysis concerning the identification of potential prognostic factors influencing post-GKRS OS and local PFS among some selected independent variables will be performed, as well.

2. Materials and methods

2.1 Overall series

Between February 1993 and February 2009, GKRS was performed on 30 patients (Table 1) with unusual LGPNTs of the brain (Grade I-II according to the WHO classification) (Louis et al., 2007). Inclusion criteria for GKRS included: lesions deep-seated in the brain or located in eloquent regions, histology confirmation, residual or recurrent tumors, tumor volume (TV) less than 15 cc, conditions of high operative risk, and patient refusal of microsurgery or reoperation.

Histology	N° Pt M/F	Age yr Mean (Range)	Surgery /Biopsy	TV cc Mean (Range)	Pre-GK Treats.
Overall series	16/14	38.4 (7-70)	20/10	4.9 (0.7-14.5)	2 RT 1 RT+Ch
Pineocytoma	5/5	31.5 (7-58)	6/4	5.0 (0.8-11.7)	1 RT
CPP	6/2	44.2 (22-70)	5/3	3.7 (0.7-9.9)	1 RT
CN	1/3	33.2 (21-43)	4/0	6.5 (3.7-9.0)	None
PXA	1/2	48.0 (28-64)	2/1	7.3 (2.3-14.5)	None
Miscellaneous: Ganglioglioma Subependymoma Oligoastrocytoma Papillary Gl. Tum.	2/3	19,2 (11-24)	3/2	3.7 (0.7-11.3)	1 RT+Ch

N° Pt = number of treated patients; yr = year; TV = tumor volume; cc = cubic cm; Pre-GK Treats. = pre-gamma knife treatments; M = male; F = female; RT = radiotherapy; Ch = chemotherapy; Papillary Gl. Tum. = papillary glioneuronal tumor.

Table 1. Summary of clinical characteristics of 30 unusual LGPNTs treated with GKRS at University Hospital of Verona from February 1993 to February 2009.

The histologic types and grading were as follows: 10 pineocytomas (Grade I), 8 choroid plexus papillomas (CPP) (Grade I), 4 central neurocytomas (CN) (Grade II), 3 pleomorphic xanthoastrocytomas (PXA) (Grade II), 2 gangliogliomas (Grade I), 1 subependymoma (Grade I), 1 papillary glioneuronal tumor (Grade I), and 1 mixed oligoastrocytoma (Grade II). All tumors were histologically verified: 20/30 (67%) were surgical residuals or post-operative recurrences, while biopsy confirmed the diagnosis in the remaining 10/30 cases: 4 (13%) during neuroendoscopy approach and 6 (20%) with stereotactic brain intervention. There were 16 males and 14 females; the mean age of the clinical series was 34.7 years (7-70 years). Further pre-GKRS treatments were as follows: RT alone, 2/30 patients (7%), and RT followed by chemotherapy, 1/30 (3%). The TV was always less than 15 cc. In 24/30 patients, pre-GKRS neurologic deficits were documented. The mean and range values of the radiosurgical dose planning parameters are summarized in Table 2.

Histology	Dose Plan		Parameters	
	PD Gy	Mean PI %	(Range) ID mJ	# Shots
Overall series	16.5 (12-22.4)	50.2 (40-70)	104 (11.4-257.4)	9.6 (1-25)
Pineocytoma	16.7 (13-20)	50.5 (50-55)	110.1 (18.9-257.4)	13.9 (5-25)
CPP	15.1 (12-20.2)	48.7 (45-50)	72.9 (11.4-189.7)	7.1 (3-11)
CN	16.4 (14-18)	47.5 (40-50)	151.6 (84.2-185.4)	7.0 (5-10)
PXA	17.0 (13-20)	50.0 (50-50)	152.1 (69.6-248.5)	10.3 (2-25)
Miscellaneous: Ganglioglioma Subependymoma Oligoastrocytoma Papillary Gl.Tum.	18.2 (12.5-22.4)	54.0 (50-70)	74.4 (19.8-191.09)	6.8 (1-16)

PD = prescription dose; Gy = gray; PI = prescription isodose; ID = integral dose; mJ = milli Joule;  
# Shots = number of isocenters.

Table 2. Summary of radiosurgical parameters of 30 unusual LGPNTs treated with GKRS at University Hospital of Verona from February 1993 to February 2009.

The mean prescription dose (PD) was 16.5 Gy while the mean prescription isodose (PI) corresponded to 50.2%. The average value of integral dose (ID), parameter which describes the relationship between treated TV and delivered dose appropriately, was 104 mJ. The mean number of shots needed for dose planning was 9.6. Follow-up data, including causes of death, were obtained from hospital notes, imaging studies, and contact with relatives and family physicians. Medical records and MRI scans for all patients were carefully reviewed by neurosurgeons and neuroradiologists. This retrospective study was approved by the Ethical Committee of our University Hospital. All patients identifiers were removed before data analysis.

2.1.1 Pineocytoma

In the group of pineocytoma, 7 out of 10 patients were young adults, under 40-year-old. Diagnosis was confirmed by bioptic samples harvest during a neuroendoscopic procedure

in 4 cases. In the other histologic groups, there were no patients in whom the histologic diagnosis was achieved following a neuroendoscopic intervention. The treated TV was always inferior to 12 cc (mean, 5.0 cc). Only a 58-year-old woman, operated on in another institution, underwent RT following incomplete surgical removal. Neurologic deficits were present in 9/10 patients at the moment of GKRS. The 10 pineocytoma tumors were administered a radiosurgical dose comprised between 13 and 20 Gy with a mean PI of 50.5% and a mean ID of 110.1 mJ. The dose plannings for pineocytoma were particularly conformal as documented by the higher mean number of utilized isocenters (13.9) compared to the mean number of shots employed in the other histologic groups.

### **2.1.2 Choroid plexus papilloma (CPP)**

The mean age in this group of patients was 44.2 years and most cases were males. The tumors were located in the following sites: 2 cerebellum, 2 ponto-cerebellar angle, 1 basal ganglia, 1 brain stem, 1 pineal region, and 1 skull base. Diagnosis was achieved by surgical intervention in 5 out of 8 cases. The TV treated with GKRS was always small, mean 3.7 cc, inferior to the means of all the other histologic types of our series. In a 25-year-old man, two operations were performed before GKRS: the last histological examination confirmed a grade I CPP. Only in one case, RT was performed after partial surgical resection and before GKRS. All the patients complained neurologic symptoms at last evaluation prior to GKRS. From the radiosurgical point of view, the mean PD and ID were lower than those of all the other histologic groups of our series, probably due to the highly critical brain location of most of these tumors.

### **2.1.3 Central neurocytoma (CN)**

The mean age was 33.2 years. The tumor location was in the lateral ventricles in 2 cases, and one case in the basal ganglia and in the occipital lobe, respectively. Histologic diagnosis was defined by means of surgical intervention in all neoplasms. In 2 out of 4 patients, the pre-GKRS neurologic evaluation was negative. The mean TV treated with radiosurgery was 6.5 cc. None of the patients underwent to other treatments prior to GKRS. The mean PD and ID were 16.4 Gy and 151.6 mJ, respectively.

### **2.1.4 Pleomorphic xanthoastrocytoma (PXA)**

Mean age and TV treated with GKRS (48.0 years and 7.3 cc, respectively) in this group of patients were higher than in the other groups of our series. Tumor locations were as follows: 1 brain stem, 1 temporal, and 1 temporo-occipital. In 2 cases, diagnosis was achieved by surgical intervention. In a 28-year old man affected with cystic right temporo-occipital PXA, a double stereotactic procedure was performed in the same neurosurgical session (Figure 1): first, an Ommaya reservoir was inserted for cyst aspiration; secondly, a biopsy of the tumor solid nodule for histopathological diagnosis definition was performed preceded by changing of stereotactic coordinates and trajectory. All patients were symptomatic at the time of radiosurgery. No other treatment before GKRS was performed. Mean PD and ID delivered were higher than in the other groups of our series (17.0 Gy and 152.1 mJ, respectively).



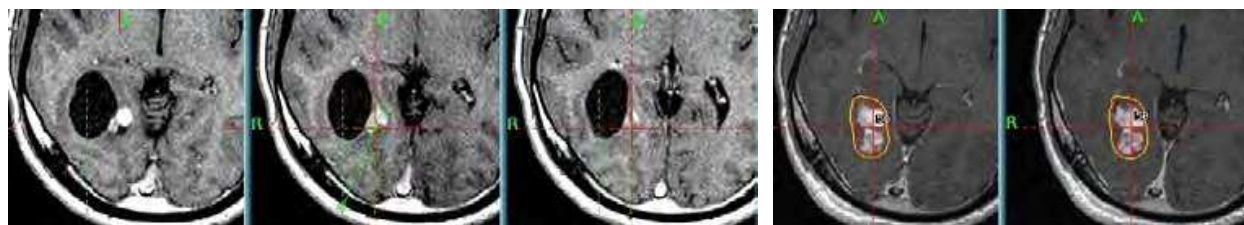


Fig. 1. A) 28-year old man with cystic temporo-occipital PXA. Calculation of stereotactic coordinates and trajectory for Ommaya reservoir insertion and tumor nodule biopsy. B) GKRS dose planning performed on shrinkaged tumor 10 days after double stereotactic intervention.

### 2.1.5 Others (Miscellaneous)

This group of patients included 2 gangliogliomas (Grade I), 1 subependymoma (Grade I), 1 papillary glioneuronal tumor (Grade I), and 1 mixed oligoastrocytoma (Grade II). The mean age (19.2 years) was lower than in all the other groups. There were 2 males and 3 females. The tumor sites were as follows: 2 deep frontal, 1 basal ganglia, 1 occipital, and 1 third ventricle. There were 3 pre-GKRS surgical interventions and 2 stereotactic brain biopsies. In 3 out of 5 patients, neurologic examination resulted negative on the day of radiosurgery. The mean TV treated with GKRS was 3.7 cc. A 24-year-old woman underwent stereotactic brain biopsy for a left frontal deep-seated tumor in another institution. Histologic diagnosis was grade II mixed oligoastrocytoma and a treatment protocol of RT and chemo-therapy was performed successively. In this group, the mean selected PI (54%) was higher than in all the other patient of our series.

## 2.2 Radiosurgical technique and procedure

Our radiosurgical technique was already described in detail in previous reports (Lunsford et al., 1989, Nicolato et al., 1997). In brief, after the application of the magnetic resonance imaging (MRI) compatible Leksell Model G stereotactic frame (Elekta Instruments AB, Stockholm, Sweden) to the patient's head, high resolution 1.0 Tesla MRI was performed in all cases. Millimetric volumetric images in axial and coronal orthogonal planes after gadolinium enhancement were used. First a sagittal MRI localizer or a 3-D scout survey (which included axial, coronal and sagittal images) were performed. Contrast enhanced Spoiled Gradient Recalled Acquisition in Steady State (SPGR) sequence was then used to image the tumor and surrounding brain. T2 weighted MR images using Fast Spin Echo technique also were acquired to assess the infiltrative tumor volume. The target volume included enhanced and non-enhanced tumor regions. Three-dimensional dose plans were developed by using commercially available software, i.e., Kula (Elekta Instruments) from February 1993 to February 1998 and Leksell Gamma Plan (versions 4.12, 5.34 and 8.3, Elekta Instruments) after February 1998. The neurological surgeon, radiation oncologist, and medical physicist created a highly conformal dose planning using multiple collimators and performed the dose selection. In all patients, the radiosurgery dose was prescribed to the entire tumor volume as defined using contrast enhanced imaging. GKRS was performed with either Model B, C 201-source Co60, or Perfexion Leksell Gamma Knife (Elekta Instruments). The procedure was performed under local anesthesia in 28/30 patients;

general anesthesia was administered in the two children younger than 14. All patients were discharged from the hospital within 24 hours after treatment, and they were evaluated clinically and with serial contrast-enhanced imaging using MRI at intervals of 6 months. The neurological status of the patient during the follow-up period was defined as no deficit pre-GKRS, if the patient were without deficits before radiosurgery and remained clinically negative, improved, in case of complaint amelioration, stable or worsened. For the evaluation of TV, the mass lesion was measured by using the Gamma Plan software or the OsiriX medical imaging program (version 4.19) developed at the University Hospital of Geneva, Switzerland. Local TGC was defined as complete disappearance of enhancing and nonenhancing neoformation, lesion shrinkage or stable disease.

### 2.3 Statistical analysis

Survival and local PFS curves were calculated using the life-table system and the Kaplan-Meier method (Kaplan & Meier, 1958). Length of survival and local PFS were evaluated on an actuarial basis from the day of GKRS treatment to the time of patient death or tumor progression and/or last follow-up, respectively. Survival and local PFS curves were compared and evaluated using Breslaw's test (Breslaw, 1974). We performed an univariate analysis using the log-rank test to detect variables that might influence the length of survival and local PFS. We matched the survival with four different variables, age, sex (male vs. female), histologic type (pineocytoma vs. choroid plexus papilloma vs. central neurocytoma vs. pleomorphic xanthoastrocytoma vs. miscellaneous), prior surgical resection vs. biopsy, and the local PFS with seven different parameters, age, sex (male vs. female), histologic type (pineocytoma vs. choroid plexus papilloma vs. central neurocytoma vs. pleomorphic xanthoastrocytoma vs. miscellaneous), prior surgical resection vs. biopsy, prescription dose, integral dose and length of follow-up. In Table 5, the statistical comparison between parameters in the different groups of patients were based on the Welch Modified Two-Sample t-Test. On the basis of internationally accepted criteria, values of  $P \leq 0.05$  were considered statistically significant. Statistical analysis was effected using the Stata version 8.2 (StataCorp, College Station, Texas) and MATLAB for graphics.

## 3. Results

### 3.1 Overall series

The results of our series are summarized in Tables 3 and 4. The median duration of follow-up was 66.8 months (range, 24.7-195.97 months). At the end of the study, February 28th, 2009, the neurologic examination remained negative or showed an improvement of previous deficits in 16 patients, in 8 cases the complaints were stable and in the other 6 a worsening due to tumor progression was observed. Among these last patients, four were deceased. The cause of death was related to distant tumour progression in 2 cases and both to local and distant disease diffusion in the other 2 cases. The overall survival was 87%, and the actuarial survival rate at 5 and 10 years was 90% and 87%, respectively (Figure 2A). The median survival in the 4 patients who died was 50 months (range, 24.7-73 months) from GKRS. The local TGC was achieved in 27/30 (90%) tumors with a 91% local actuarial PFS both at 5 and 10 years (Figure 2B). The median time to progression for the three patients with uncontrolled tumor was 18.5 months (range, 9.8-26.7 months). No GKRS-related permanent side-effect was observed on the whole series. To date, neither malignant tumor

Histology	N° Pt	Me/Med FU mos.	Clinical Results			Alive/ Dead (OS%)
			No def./Impr	Stable	Wors.	
Overall series	30	85.7/66.8	16/30	8/30	6‡/30	26/4¶ (87.0)
Pineocytoma	10	66.7/54.6	6/10	3/10	1/10	9/1 (90.0)
CPP	8	92.6/71.8	2/8	2/8	4/8	6/2 (75.0)
CN	4	172.0/180.6	4/4	-	-	4/0 (100.0)
PXA	3	45.6/43.7	1/3	1/3	1/3	2/1 (66.7)
Miscellaneous	5	68.0/68.3	3/5	2/5	-	5/0 (100.0)

N° Pt = number of treated patients with al least 2-year-follow-up; Me = Mean; Med = Median; mos. = months; No def./Impr = No pre-GK neurological deficit/Neurological improvement; Wors. = Neurological worsening; OS = Overall survival.  
‡: due to tumor distant progression in 4 cases and both to local and distant tumor diffusion in the other 2 patients.  
¶: the cause of death was tumor distant progression in 2 cases and both local and distant tumor diffusion in the other 2 patients.

Table 3. Summary of clinical results concerning 30 LGPNTs treated with GKRS at University Hospital of Verona from February 1993 to February 2009.

Histology	Act. Surv. %		Ov. TGC%	Act. Local PFS%		GK-related sequelae		Post-GK treats.
	At 5y	At 10y		At 5y	At 10y	Mort.	Perm Compl	
Overall series	90.0	87.0	90.0	91.0	91.0	0.0	0.0	3 surg.int. 1 VPS 3 RT
Pineocytoma	92.0	92.0	100.0	100.0	100.0	0.0	0.0	1 RT
CPP	90.0	80.0	87.5	90.0	90.0	0.0	0.0	1 surg.int. 1 RT
CN	100.0	100.0	75.0	83.0	83.0	0.0	0.0	1 surg.int. 1 RT
PXA	80.0	80.0	66.7	80.0	80.0	0.0	0.0	1 VPS
Miscellaneous	100.0	100.0	100.0	100.0	100.0	0.0	0.0	1 surg.int.

Act. Surv. = Actuarial survival; Ov. TGC = Overall tumor growth control; Act. Local PFS = Actuarial local progression-free survival; Mort. = Mortality; Perm. Compl = Permanent Complications; Post-GK treats. = Post-GK treatments; surg.int. = surgical intervention; VPS = Ventricolo-peritoneal shunt; RT = Radiation therapy.

Table 4. Summary of outcome results concerning 30 LGPNTs treated with GKRS at University Hospital of Verona from February 1993 to February 2009.



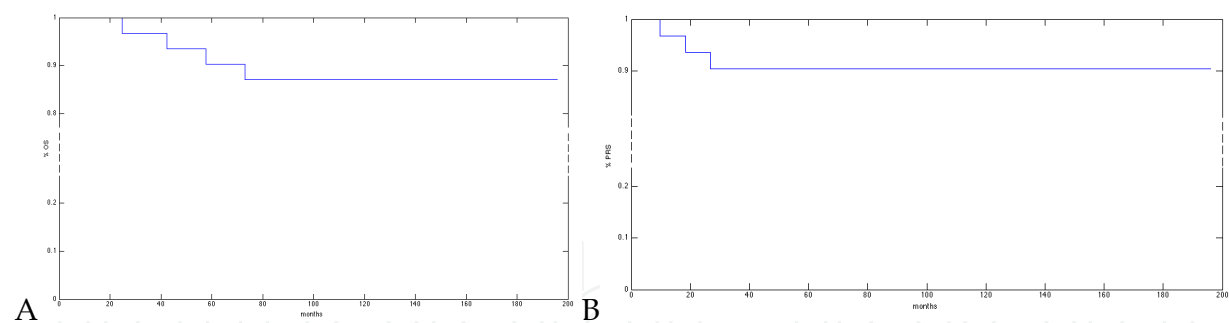


Fig. 2. Kaplan-Meier estimate of A) overall survival and B) local PFS curves in 30 LGPNTs.

transformation nor GKRS-related mortality were registered. Post-GKRS treatments were represented by: 3 surgical removals, 1 ventriculo-peritoneal shunt and 3 fractionated irradiations. No chemotherapy treatment was performed on the whole series after GKRS. All variables tested at univariate analysis on the whole series did not show a statistically significant influence either as concerns survival or local PFS rates. In particular, the different histological type analyzed did not seem to have prognostic significance, as well (Figures 3A and 3B). Therefore, multivariate analysis was not performed. Nevertheless, a positive trend for PD and ID seems to emerge from statistical analysis (Table 5): in the 3 patients with local progression, the mean dose delivered to the periphery of the neoplasms was lower

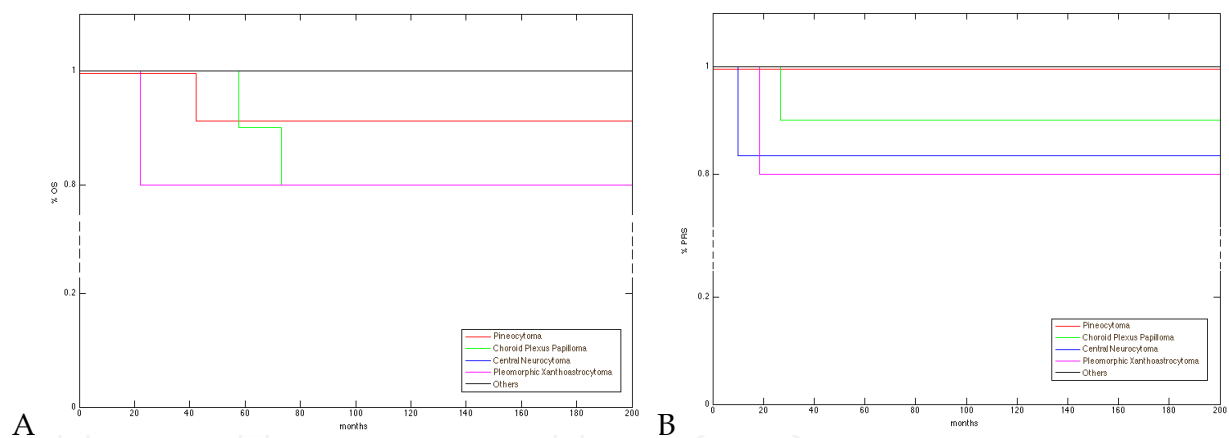


Fig. 3. Kaplan-Meier estimate of A) overall survival and B) local PFS curves after GKRS for histologic types (P = NS).

GKRS outcome	N° Pt	Mean TV (cc)	P value	Mean PD (Gy)	P value	Mean ID (mJ)	P value
Local TGC	27	4.61		16.8		98.74	
			<0.55		= 0.138		= 0.141
Local Progr.	3	7.30		14.0		151.1	

N° Pt = number of treated patients; TV = tumor volume; cc = cubic cm; PD = prescription dose; Gy = gray; ID = integral dose; mJ = milli Joule.

Table 5. statistical comparison between radiosurgical outcome and TV, PD, and ID in 30 LGPNTs treated with GKRS.

(14.0 Gy) than that of the 27 tumors with local TGC (16.8 Gy), and the mean ID was higher (151.1 mJ) compared to that of the group under control (98.74 mJ). Because the ID is the result of volume multiplied by average dose, we evaluated the mean TV between the groups of patients with under control vs. progressed neoplasms, as well. The 3 patients with tumor progression presented a mean TV of 7.3 cc versus 4.6 cc of the tumors with favourable response. Even though the statistical analysis did not show significant results, the considerable difference of the two mean TV values authorizes to think that a possible correlation between TV and local TGC after GKRS could be proposed. Finally, it must be considered that the small number of observations might represent a bias for the statistical analysis.

### 3.2 Pineocytoma

In this group of patients, the median observation time was 54.6 months (range, 25.3-130.0 months). On last follow-up day, 9 out of 10 patients were neurologically stable or improved (Table 3); only a 16-year-old boy worsened because of distant tumor progression and underwent post-GKRS RT, but unfortunately he died at 42 months from radiosurgery (OS, 90%). All the other patients did not need further treatments following GKRS. In the whole ten pineocytomas of our series, local TGC was achieved (overall TGC, 100%) (Figure 4). The 5 and 10 year actuarial survival and local TGC were 92% and 100%, respectively (Table 4).

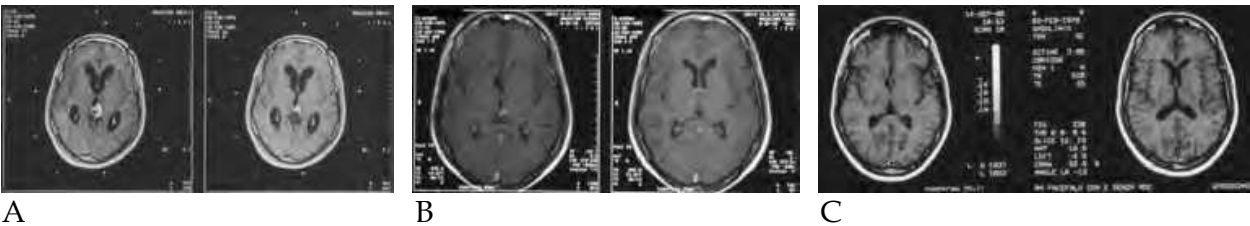


Fig. 4. A) Posterior III ventricle pineocytoma on GKRS day. The diagnosis was achieved by means of stereotactic neuroendoscopy biopsy. B) MR imaging follow-up at 3 months and C) at 18 months from GKRS showing the gradual disappearance of the tumor.

### 3.3 Choroid plexus papilloma (CPP)

The 8 patients of this group were followed-up for 71.8-month median time. A neurologic deterioration was observed in 4 patients: in 3 cases, due to tumor distant progression, and in 1 both to local and distant progression. During the follow-up period, 2 of these last patients died: 1 because of tumor distant progression and 1 due to local and distant progression (OS, 75%). The 5- and 10-year actuarial survival rates were 90% and 80%, respectively. Local TGC was reported in 7 patients (87.5%), with an actuarial local TGC of 90% both at 5- and 10-years. The 2 patients with distant progression refused further treatments: one of them is died at 57.7 months from GKRS, and the other is still alive with mild neurologic deficits 181.7 months after radiosurgery. The treatments performed after GKRS were surgical intervention for local tumor progression in one case and RT in another patient with distant progression.

### 3.4 Central neurocytoma (CN)

The median follow-up period was 180.6 months (range, 142.7-183.9 months). At last observation, all patients were neurologically intact or clinically improved. The OS and the 5-

and 10-year actuarial survival rates were 100% (Table 4). The local TGC was achieved in 3 out of 4 cases (75%) and the actuarial local TGC was 83% both at 5- and 10-years. In a 26-year-old woman with a TV at radiosurgery of 9.0 cc was decided to associate RT after GKRS. She is alive and well at 177.3 months from radiosurgery. A surgical intervention was needed in a 21-year-old man because of local progression of an intraventricular residual tumor at 9.8 months after GKRS. He underwent radiosurgery for a 5.9 cc neoplasm and the administered PD was 14.0 Gy, the lowest value than in all the other patients treated for central neurocytoma.

### 3.5 Pleomorphic xanthoastrocytoma (PXA)

The median follow-up time in this group of patients was 43.7 months (range, 25.1-70.9 months). At the end of the study, one patient showed an improvement of the neurologic complaints, the second was clinically stable and the third presented a gradual deterioration due to a brain stem tumor progression and died 25.1 months after GKRS. This patient was already operated prior to radiosurgery. She refused further RT and the only possible treatment was VPS. In this group, the OS and the local TGC rates were 66.7% and the actuarial survival and local TGC rates were 80% both at 5- and 10-years (Figure 5).

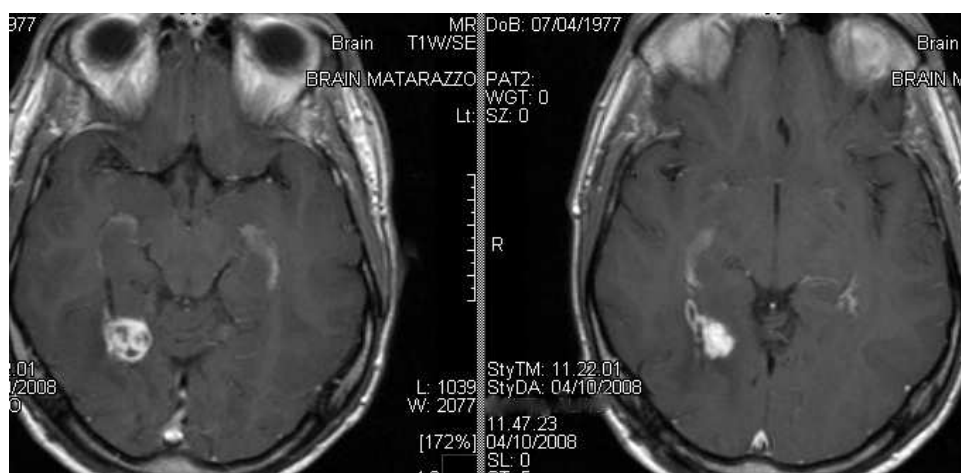


Fig. 5. Same case than in figures 1. MRI follow up at 32 months from GKRS showing a significant tumor reduction.

### 3.6 Others (Miscellaneous)

The median period of follow-up was 68.3 months (range, 27.5-109 months). All patients in this heterogeneous group of unusual LGPNTs showed a negative, improved or stable neurological status at last observation (OS 100%), with an actuarial survival rate at 5- and 10-years of 100% and 100%, respectively. All tumors treated with GKRS were under control (Table 4). A 24-year-old woman affected with a grade II mixed oligoastrocytoma and treated prior to radiosurgery with RT and chemotherapy elsewhere developed an expansive lesion with mass effect in left frontal region, far from the target volume treated with GKRS. Surgical removal was needed and histologic examination showed that it deals with radionecrosis, secondary to the previous RT. Now, she is well at 68.3 months from radiosurgery. She was the only patient in this group who needed a further treatment after GKRS.

## 4. Discussion

### 4.1 Overall series

Several series describing the results of stereotactic radiosurgery on LGPNTs of the brain including a large number of patients have been reported. However, they always dealt with low-grade gliomas. Kida (Kida et al., 2000) and Heppner (Heppner et al., 2005) presented their experience with GKRS on 51 and 49 patients with grade I and II astrocytomas, respectively. Hadjipanayis (Hadjipanayis et al., 2002a) treated 37 pilocytic astrocytomas of every age, and, more recently, Kano (Kano et al., 2009b) described the outcome following GKRS in 50 pilocytic astrocytomas in pediatric age, exclusively. Simonova (Simonova et al., 2005) reported a series of 70 cases including different types of grade I and II gliomas in whom stereotactic radiosurgery was applied. Sarkar (Sarkar et al., 2002) and Kano (Kano et al., 2009c) reported two GKRS studies on 18 and 30 patients affected with oligodendrogliomas and mixed oligodendroastrocytomas, respectively, but both series included low- and high-grade tumors. As concerns the unusual primitive neuroepithelial tumors of the brain, the largest published series always comprised low- and high-grade tumors (Kano et al., 2009d, Mori et al., 2009, Lekovic et al., 2007, Hasegawa et al., 2002, Kobayashi et al., 2001), while the studies with exclusively unusual LGPNTs were always represented by a few cases (usually, less than 15). To our knowledge, the work of our team represent the largest series of unusual LGPNTs treated with stereotactic radiosurgery. In a study performed on 10 patients (8 pineocytomas, 1 CPP, and 1 CN), Lekovic (Lekovic et al., 2007) reported an overall survival of 90%, a 100% local TGC, with neither GKRS-related mortality nor permanent morbidity. But, the patients were observed for a median period of less than 2 years (20.5 months). Our results obtained on 30 patients followed up for at least 2 years (median, 66.8 months; range, 24.7-195.97 months) confirmed this excellent outcome. In brief, the 5- and 10-year actuarial survival rates were 90% and 87%, respectively, with a 91% actuarial local PFS both at 5- and 10-year. The median time to progression for the three patients with uncontrolled tumor was 18.5 months and the median survival in the 4 patients who died was 50 months. In 2 of them, the cause of death was exclusively due to tumor distant progression. Also in our series, no complications were attributable to GKRS. The only study on a series of LGPNTs in which was performed an analysis of potential prognostic factors influencing GKRS outcome is referred to Sarkar (Sarkar et al., 2002). The authors studied a series of 18 patients with 21 tumors – 10 oligodendrogliomas and 11 mixed oligoastrocytomas – and found that factors associated with an improved survival rate included younger age and smaller tumors. In our series, univariate analysis on selected independent variables did not show any factors of significance. Nevertheless, we observed that patients with local TGC presented a smaller mean TV (4.61 cc vs. 7.0 cc), a higher mean PD (16.8 Gy vs. 14.0 Gy), and a lower mean ID (98.74 mJ vs. 151.1 mJ) than those with tumor progression. This trend could suggest that multisession GKRS with the Extend System (Elekta Instrument) should be better in those patients affected with larger tumors, thus achieving an increased dose delivery to the target volume maintaining a negligible risk of permanent side effects on the surrounding normal brain tissue. Some authors (Kobayashi et al., 2001, Kim et al., 2007) propose GKRS as primary treatment without histological diagnosis when a deep-seated or critically located brain tumor showing the imaging characteristics of an unusual LGPNTs is identified. On the contrary, other colleagues state that obtaining a histological diagnosis remains the main aim for rational treatment planning (Matsunaga et al., 2010; Martin et al., 2003; Yen et al., 2007;



Tyler-Kabara et al., 2001; Kano et al., 2009d; Lekovic et al., 2007; Reyns et al., 2007; Dershmukh et al., 2004). In our series, all tumors were histologically verified before GKRS. We do not believe that empirical treatment of brain tumors with radiosurgery is justified, as the treatment paradigm is critically dependent upon tumor histological grade. Therefore, it is of paramount importance to achieve the histological diagnosis for decision making prior to GKRS. We suggest the use of radiosurgery as a primary treatment modality for those patients in whom an adequate tissue diagnosis of an unusual LGPNTs has been obtained with endoscopy or stereotactic biopsy.

#### 4.2 Pineocytoma

Pineal region tumors are rare and account for 0.4 to 1% of intracranial tumors in Western countries and for 2.2 to 8% of intracranial tumors in northeastern Asian countries (Deshmukh et al., 2004). They are 10 times more common in children than in adults. According to the statistics of the Brain Tumor Registry of Japan, pineal parenchymal tumors such as pineocytoma or pineoblastoma account for 7% of all pineal region tumors (Kobayashi et al., 2001). Individual clinical experience of these tumors is thus limited. Pineocytoma is typically localized to the pineal area and compresses adjacent structures, including the cerebral aqueduct, brain stem and cerebellum. Their growth may extend into the third ventricle. The majority of patients exhibit neuro-ophthalmologic findings, particularly Parinaud syndromes (Grimoldi et al., 1998). MRI findings such as enhancement, calcification, and welldefined margins are suggestive of a pineocytoma but are by no means diagnostic (Chiechi et al., 1995). Therefore, tissue diagnosis is imperative. Pineocytoma is a slowly growing tumor with a relatively favorable prognosis in most cases. According to the 2007 classification, pineocytomas correspond histologically to WHO grade I. From the pathological point of view, pineocytomas tend to recapitulate the normal pineal gland (Shild et al., 1996) (Figure 6). Despite improved microsurgical technique, resection of pineocytoma

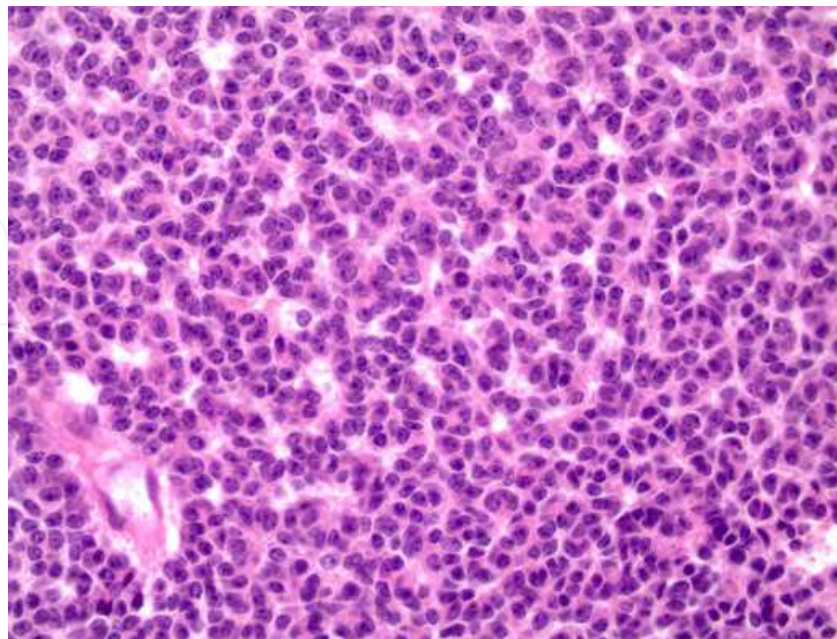


Fig. 6. Pineocytoma. X200 H-E. Classical morphological appearance of uniform cells with rosette and trabeculae.



remains a challenge because of their deep location and associated critical structures. The surgical major morbidity rate associated with pineocytomas is comprised between 3% and 6.8%, and permanent minor morbidity rate was 3-28%. The risk of surgical mortality associated with pineocytoma removal has been reduced in these last 20 years, but it remains less than 2% (Friedman et al., 2001, Bruce & Ogden, 2004). The role of adjuvant RT has not been clearly delineated. Furthermore, pineocytomas are traditionally considered radioresistant tumors. For all these reasons, the use of radiosurgery in the treatment of pineocytoma is more and more growing and diffusing worldwide and studies reporting the experience of different institutions are now available (Table 6). The first and more relevant published series always regard treatment performed with GK device. The median follow-up period varies between 11.0 and 73.5 months. Neither neurological worsening nor GKRS-related permanent complications were reported. In our studies, 10 patients were followed up for a median period of 54.6 months; we observed a clinical worsening in 1 case, only, due to distant tumor progression. As concerns outcome results (Table 7), the overall survival

Author	RS dev	N° Pt	Me/Med FU mos.	Clinical Results			Sympt. Compl.	
				No def. /Impr	Stable	Wors.	Trans. %	Perm. %
Kano 2009†	GK	13	54.1 Me	66.7	-	-	23.0	0.0
Mori 2009*	GK	5	49.0/33.5	-	-	-	0.0	0.0
Lekovic 2007¶	GK	8	17.4/11.0	-	-	-	0.0	0.0
Reyns 2006	GK	7	31.7/37.0	-	-	-	-	-
Desmukh 2004¶	GK	3	19.3/12.0	-	-	-	-	-
Hasegawa 2002†	GK	10	69.1/73.5	-	-	-	10.0	0.0
Kobayashi 2001*	GK	3	21.7 Me	-	-	-	-	-
Subach 1998†	GK	8	-	-	-	-	-	-
Backlund 1974	GK	2	-	-	-	-	-	-
Present series	GK	10	66.7/54.6	6/10	3/10	1/10‡	10.0	0.0

RS dev = Radiosurgical device; N° Pt = number of treated patients; Me = Mean; Med = Median; mos. = months; No def./Impr = No pre-GK neurological deficit/Neurological improvement; Wors. = neurological worsening; Sympt. Compl. = Symptomatic complications; Trans. = transient; Perm. = Permanent; GK = Gamma Knife.

†: Departments of Neurological Surgery and Radiation Oncology, The University of Pittsburgh, and Center for Image-Guided Neurosurgery, University of Pittsburgh Medical Center, Pittsburgh, Pa., USA.

\*: Nagoya Radiosurgery Center, Nagoya Kioritsu Hospital, and Gamma Knife Center, Komaki City Hospital, Komaki, Japan.

¶: Division of Neurological Surgery, Barrow Neurological Institute, St. Joseph's Hospital and Medical Center, Phoenix, Arizona, USA.

‡: due to tumor distant progression.

Table 6. Clinical data in previous and present series of pineocytomas treated with GKRS.

Author	N° Pt	Ov. Surv. %	Act. Surv. %		Ov. Local TGC%	Act.	Local	PFS%
			At 5y	At 10y		At 3y	At 5y	At 10y
Kano 2009†	13	–	92.3	–	100.0	100.0	100.0	–
Mori 2009*	5	–	100.0	67.0	80.0	–	85.0	–
Lekovic 07¶	8	87.5	–	–	100.0	–	–	–
Reyns 2006	7	100.0	–	–	100.0	–	–	–
Desmukh 04¶	3	–	–	–	100.0	–	–	–
Hasegawa 2002†	10	90.0	–	–	100.0	–	–	–
Kobayashi 2001*	3	100.0	–	–	100.0	–	–	–
Subach 1998†	8	–	–	–	100.0	–	–	–
Backlund 1974	2	–	–	–	100.0	–	–	–
Present series	10	90.0	92.0	92.0	100.0	–	100.0	100.0

N° Pt = number of treated patients; Ov. Surv. = Overall survival; Act. Surv. = Actuarial survival; y = years; Ov. Local TGC = Overall local tumor growth control; Act. Local PFS = Actuarial local progression-free survival.  
†: Departments of Neurological Surgery and Radiation Oncology, The University of Pittsburgh, and Center for Image-Guided Neurosurgery, University of Pittsburgh Medical Center, Pittsburgh, Pa., USA.  
\*: Nagoya Radiosurgery Center, Nagoya Kioritsu Hospital, and Gamma Knife Center, Komaki City Hospital, Komaki, Japan.  
¶: Division of Neurological Surgery, Barrow Neurological Institute, St. Joseph's Hospital and Medical Center, Phoenix, Arizona, USA.

Table 7. Radiosurgical outcome in previous and present series of pineocytomas.

ranged between 87.5% and 100%. Mori (Mori et al., 2009) is the only author who reported a 10-year actuarial survival rate of 67%. In our series, the 10-year actuarial survival rate was 92%. The local TGC and PFS were excellent in all published studies. Among 5 cases with a median follow-up of 33.5 months, Mori (Mori et al., 2009) reported that the tumors were controlled in 4 cases. Only one patient developed cerebrospinal fluid dissemination after GKRS. Lekovic (Lekovic et al., 2007) described only 1 death in a series of 8 pineocytomas. The patient died 2 months after GKRS; however, MR images obtained immediately before the patient’s death showed a 75% reduction in the size of the lesion. Kano (Kano et al., 2009d) reported a 5-year local PFS rate of 100% in 13 pineocytomas observed for a median period of 54.1 months. Reyns (Reyns et al., 2006) treated 8 pineocytomas and in 7 of them a follow-up period was available (median, 37.0 months). The author reported a 100% rate of overall survival and local TGC and he suggested that GKRS may represent a useful therapeutic modality in selected cases of pineal parenchymal tumours as part of a multidisciplinary approach. Our data achieved on a series with long term observation period strengthen the extremely encouraging results already published. Hence, GKRS has showed to be a valid, effective and safe treatment modality in benign tumors with critical surgical approach and considered relatively radioresistant to conventional fractionated RT, such as the pineocytoma. The excellent

radiosurgical outcome is still present in long-term studies, as well. Therefore, we conclude that GKRS must be taken into account when considering the treatment management of pineocytoma, also as a primary choice in selected patients providing that a previous histopathological diagnosis is assured.

### 4.3 Choroid plexus papilloma (CPP)

CPPs are epithelial tumors of the choroid plexus that account for <1% of adult brain tumors (Kim et al., 2008). The majority occur within the ventricular system, the lateral ventricle being the most frequent location in children and the IVth ventricle in adults. The usual MRI findings are characterized by large, circumscribed, contrast-enhanced intraventricular tumor with occasional cyst formation and associated hydrocephalus. Tumoral calcification may be seen on plain radiographs. CPPs are slow-growing, epithelial tumors of the choroid plexus defined as grade I according to the WHO classification. Microsurgical resection is the preferred management for these tumors. Gross total resection is expected to be curative, with infrequent recurrence (Krishnan et al., 2004). However, complete resection is not always possible because CPPs have a deep-seated location, close proximity to critical structures (e.g. brain-stem), florid vascularity, and capacity for local invasion into underlying brain parenchyma (Krishnan et al., 2004). Furthermore, microsurgery-related permanent complications are not negligible with morbidity and mortality rates up to 25% and 16.7%, respectively (Talachchi et al., 1999). Acute postoperative complications were frequent, most notably a 22% incidence of temporary swallowing dysfunction. This condition often led to placement of a percutaneous endoscopic gastrostomy tube or tracheostomy for aspiration, or both (Krishnan et al., 2004). Therefore, additional options for treatment resistant residual or recurrent tumors are needed. Additional management options in grade I CPP include repeat surgery and RT. Krishnan (Krishnan et al., 2004) noted that irradiation after subtotal resection was associated with a failure of local tumor control in one half of patients. They concluded that conventional fractionated RT after initial subtotal resection did not improve outcomes. The use of stereotactic radiosurgery for CPP has been described rarely. To date, there are 9 cases reported, only (Tables 8 and 9). Duke (Duke et al., 1997) published the first case of a third-ventricle CPP who underwent radiosurgery with an excellent neurologic and imaging result. Eder (Eder et al., 2001) reported one case of CPP in pediatric age with TV shrinkage following GKRS. Also Lekovic (Lekovic et al., 2007) reported one case with partial response at 95 months from radiosurgery. To date, the most numerous published series goes back to Kim (Kim et al., 2008), who treated with GKRS 11 locally or distant recurrent intracranial CPPs in 6 patients. He described rates of overall survival and local TGC of 66.7% and 36.4%, respectively, but the study included some aggressive tumors, also. To our knowledge, the present is the largest series ever reported before regarding 8 patients affected with intracranial CPP and treated with radiosurgery. They were followed up for a median period of 71.8 months; the 5-year actuarial survival and local PFS rates were 90% and 90%, respectively. Even though the number of reported patients is limited, the long lasting TGC in most cases without GKRS-related permanent side effects strongly suggests that radiosurgery could represent a valid alternative for the treatment of intracranial CPP, especially in resistant tumors, thus avoiding invasive and high risk repeated microsurgery and the potential long term neuropsychological sequelae associated with fractionated RT.

Author	RS dev	N° Pt	Me/Med FU mos.	Clinical Results			Perm. Sympt. Compl.
				No def. /Impr	Stable	Wors.	
Kim 2008	GK	6	57.3/55.5	-	-	-	-
Lekovic 2007	GK	1	96.0	-	-	-	0.0
Eder 2001	GK	1	-	-	1	-	0.0
Duke 1997	GK	1	17.0	Excellent	-	-	0.0
Present series	GK	8	92.6/71.8	2/8	2/8	4/8‡	0.0

RS dev = Radiosurgical device; N° Pt = number of treated patients; Me = Mean; Med = Median; mos. = months; No def./Impr = No pre-GK neurological deficit/Neurological improvement; Wors. = Neurological worsening; Perm. Sympt. Compl. = permanent symptomatic complications; GK = Gamma Knife.  
‡: 3/4 due to tumor distant progression and 1/4 due to local and distant progression.

Table 8. Clinical data in previous and present series of CPP treated with GKRS.

Author	N° Pt	Ov. Surv. %	Act. Surv. %		Ov. Local TGC%	Act. Local PFS%	
			At 5y	At 10y		At 5y	At 10y
Kim 2008	6	66.7	-	-	36.4 (with some aggressive tumors)	-	-
Lekovic 2007	1	100.0	-	-	100.0	-	-
Eder 2001	1	100.0	-	-	100.0 (Ped. Pt.)	-	-
Duke 1997	1	100.0	-	-	100.0	-	-
Present series	8	75.0‡	90.0	80.0	87.5	90.0	90.0

N° Pt = number of treated patients; Ov. Surv. = overall survival; Act. Surv. = actuarial survival; Ov. Local TGC = overall local tumor growth control; Act. Local PFS = Actuarial local progression-free survival; Ped. Pt. = Pediatric patient.  
‡: 2 deaths: 1 due to tumor distant progression and 1 due to local and distant progression.

Table 9. Radiosurgical outcome in previous and present series of CPP.

4.4 Central neurocytoma (CN)

CN was characterized by Hassoun (Hassoun et al., 1982) in the 1980's as a distinct histological entity with a typical immunohistochemical profile and ultrastructural features of neuronal differentiation. CN accounts for approximately 0.1% of all the primary CNS tumors and it is a typically disease of young adulthood, occurring in the second and third decades of life (Matsunaga et al., 2010; Tyler-Kabara et al., 2001). This unusual LGPNT



usually arise from the neuronal cells of the septum pellucidum, fornix, or subependymal plate of the lateral and third ventricle, so these tumors are surrounded by cerebrospinal fluid and occur as a small tumor attached to normal structures. CN is defined as grade II according to the WHO classification. This neoplasm is generally considered a benign, slow-growing tumor. Histological study shows a pattern composed of uniform small round cells, usually with clear cytoplasm and round nuclei (Figure 7). Its features match those of oligodendroglioma or ependymoma, leading to frequent misdiagnosis when further investigations are not performed. Immunohistochemistry is very useful for the diagnosis of neurocytoma, which shows a dot-like positivity for synaptophysin, negativity for glial fibrillary acidic protein and constant expression of neuron-specific enolase (Martin et al., 2003). Typical neurocytomas are characterized by a MIB-1 labeling index  $\leq 3\%$  and the absence of histologic atypia (Rades & Schild, 2006). Standard initial treatment for CNs is a total resection whenever possible. The prognosis is usually favorable after gross total resection, generally leading to cure and long-term survival. Furthermore, tumor resection not only provides a histological diagnosis but also restores the intracranial cerebrospinal fluid circulation. But, tumors in more than half of patients with CN cannot be completely resected. Furthermore, recurrences, even after complete resection, and tumor progression after subtotal resection have been reported up to 33% of cases (Matsunaga et al., 2010, Kim et al., 2007, Yen et al., 2007, Martin et al., 2003, Cobery et al., 2001). Finally, malignant transformation is known to occur in a few cases, resulting in tumor progression, intracerebral hemorrhage, or craniospinal dissemination (Matsunaga et al., 2010). For treatment of residual or recurrent CNs, fractionated RT has been advocated because these tumors tend to have high radiosensitivity due to their high vascularity. The results showed effective local tumor control. However, because of the benign clinical course of CN, the young mean age of the affected patients and the well-known long-term adverse effects of conventional RT, such as cognitive dysfunction and secondary tumor formation, routine use of conventional RT for residual or recurrent CN has been criticized by several authors (Kim et al., 2007, Yen et al., 2007, Martin et al., 2003). The advantage of a focused radiation is that a

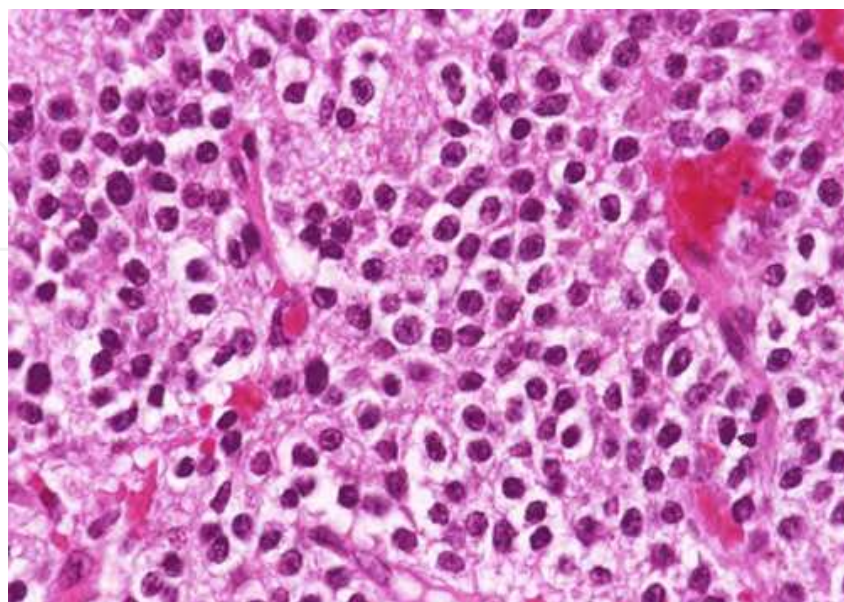


Fig. 7. CN: X100 H-E. Oligodendroglial like cells with round nuclei and clear haloes.



high dose with a steep fall off in radiation can be delivered precisely in one single treatment session. In addition, the residual or recurrent CNs are usually characterised by highly vascularized and well demarkated small volumes with generally intraventricular growth; therefore, they tend to be surrounded by CSF, and only a small part of the tumor has contact with the brain tissue. This makes them ideal targets for GKRS, as most of the dose surplus hits the CSF and the radiation burden to the neighbouring brain tissue can be kept at a minimum. In this way, the side effects of radiosurgery are minimised. All these advantages have led to the emergence of GKRS as an attractive alternative to conventional RT in the treatment of residual or recurrent CNs. The first CN patient treated with radiosurgery was described by Schild (Schild et al., 1997) in 1997. Since 1997, several studies of CNs treated with radiosurgery have demonstrated good response and high TGC. The mechanism of tumor response to GKRS is not yet clear. Several hypothesis have been formulated to explain the TV shrinkage: 1) cytotoxic effect; 2) accelerated programmed cell death; or 3) obliteration of nutritive vessels (Yen et al., 2007). The latter was reported by Kulkarni (Kulkarni et al., 2002) after they observed a decrease in contrast enhancement in the tumors after RT. The shrinkage of the residual neurocytoma began approximately 1 year after fractionated RT; this timing corresponds to the endothelial damage caused by irradiation which induces the proliferation of smooth muscle cells and the production of extracellular collagen by these cells, which leads to progressive stenosis and obliteration of the cAVM nidus. In addition, the contractile activity of these gamma ray-activated, spindle-shaped smooth muscle cells and the transformation of the resting cells into an activated form after irradiation may be relevant to the shrinking process and eventual occlusion of AVMs after radiosurgery. The activation of this obliteration mechanism is earlier in pediatric patients and young adults than in adults due to the greater number of nonresting cells found in young patients' vessels, as reported in an our previous study on cerebral arteriovenous malformations (Nicolato et al., 2005). To date, more than 50 patients treated with radiosurgery for CN has been described (Table 10). From the neurological point of view, the outcome was favourable in most cases. Only in one patient, a radiosurgery-related clinical worsening occurred: she was treated with a 6 MV LINAC system for a 8.09 cc left lateral ventricle CN. Radiation necrosis and brain edema were developed and ventriculo-peritoneal shunt was needed (Martin et al., 2003). The overall survival reported by the different authors varies between 67% and 100%, but none of the patients died due to the tumor progression. Rades (Rades & Schild, 2006) reviewed the data of all the CN patients reported since 1997. There were 21 cases treated with incomplete tumor resection followed by stereotactic radiosurgery, GK in 15 and Linac in 6 CNs. The median follow up period was 42 months. The 5-year actuarial survival and local PFS rates was 100% and 100%, respectively. The 4 patients of our series were observed for a median period of 180.6 months. The 10-year survival rate was 100%. Local tumor control was achieved in 75% of cases: in only one patient, tumor progression was documented at 9.3 months from GKRS. He was operated and he was alive and well at last follow-up. In conclusion, we suggest GKRS for residual CNs after incomplete resection or early detection of tumor recurrence with relatively small volume, which will reduce the long-term risk of radiation injury to the surrounding normal brain tissue compared with conventional RT. Because CN tends to show local recurrence leading to clinical malignant sequelae such as tumor progression, intracranial hemorrhage, or craniospinal dissemination and rarely malignant transformation, we strongly recommend GKRS for small residual or recurrent tumors rather than conservative follow up to obtain good tumor growth control.

Author	RS dev	N° Pt	Me/Med FU mos.	Clinical Results			Perm. Sympt. Compl.
				No def. /Impr	Stable	Wors.	
Matsunaga 2010	GK	7	63.6 Me	-	-	-	0.0
Kim 2007	GK	13	53.7/61.0	-	100.0	-	0.0
Yen 2007	GK	7	60.0 Me	100.0	-	-	0.0
Lekovic 2007	GK	1	54.0	-	1/1	-	0.0
Rades 2006 (reviews)	GK Linac	15 6	42 Med	-	-	-	-
Martin 2003	Linac	4	33.0/37.5	75.0	-	25.0	25.0
Javedan 2003	GK	1	25.0	1/1	-	-	0.0
Kim 2003	Linac	1	51.0	-	-	-	0.0
Hara 2003	GK	1	12.0	-	-	-	0.0
Tyler-Kabara 2001	GK	4	45.7/46.0	-	100.0	-	0.0
Anderson 2001	GK	4	16.5/13.0	100.0	-	-	0.0
Bertalanffy 2001	GK	3	32.0/24.0	67.0	33.0	-	0.0
Cobery 2001	GK	4	44.0/32.5	100.0	-	-	0.0
Pollock 2001	GK	1	34.0	1/1	-	-	0.0
Present series	GK	4	172.0/180.6	4/4	-	-	0.0

RS dev = Radiosurgical device; N° Pt = number of treated patients; Me = Mean; Med = Median; mos. = months; No def./Impr = No pre-GK neurological deficit/Neurological improvement; Wors. = Neurological worsening; Perm. Sympt. Compl. = permanent symptomatic complications; GK = Gamma Knife; Linac = Linear accelerator.

Table 10. Clinical data in previous and present series of CN treated with GKRS.

4.5 Pleomorphic xanthoastrocytoma (PXA)

PXA is a rare tumor accounting for less than 1% of all astrocytic neoplasms. At MRI, PXA does not show peculiar imaging features. This unusual LGPNT of the brain belongs to grade II according to WHO classification. Histopathological patterns includes cellular pleomorphism, focal eosinophilic protein droplets, and regions with an interstitial reticulin fiber network (Figure 8). Maximum surgical removal is considered the first treatment of choice. The efficacy of adjuvant radiotherapy has not yet been established, largely because of the relative rarity of this disease. Chemotherapy for PXA has been generally considered ineffective. The only described case of PXA treated with GKRS showed anaplastic features (Koga et al., 2009). Nevertheless, the authors chose to perform radiosurgery on 8 distinct intracranial tumor nodules in six different GKRS sessions during a 50 month follow up

Author	N° Pt	Ov. Surv. %	Act. Surv. %		Ov.Local TGC%	Act. Local PFS%	
			At 5y	At 10y		At 5y	At 10y
Matsunaga 2010	7	-	-	-	87.5	-	-
Kim 2007	13	-	-	-	84.6	-	-
Yen 2007	7	85.7	-	-	88.9	-	-
Lekovic 07	1	-	-	-	1/1	-	-
Rades 2006 (rews.)	156	100.0	100.0	-	95.2	100.0	-
Martin 2003	4	100.0	-	-	100.0	-	-
Javedan 2003	1	1/1	-	-	1/1	-	-
Kim 2003	1	1/1	-	-	1/1	-	-
Hara 2003	1	1/1	-	-	1/1	-	-
Tyler-Kabara 2001	4	100.0	-	-	100.0	-	-
Anderson 2001	4	100.0	-	-	100.0	-	-
Bertalanffy 2001	3	67.0	-	-	100.0	-	-
Cobery 2001	4	100.0	-	-	100.0	-	-
Pollock 2001	1	1/1	-	-	1/1	-	-
Present series	4	100.0	100.0	100.0	75.0	83.0	83.0

N° Pt = number of treated patients; Ov. Surv. = overall survival; Act. Surv. = actuarial survival;  
Ov. Local TGC = Overall local tumor growth control; Act. Local PFS = Actuarial local progression-free survival.

Table 11. Radiosurgical outcome in previous and present series of CN.

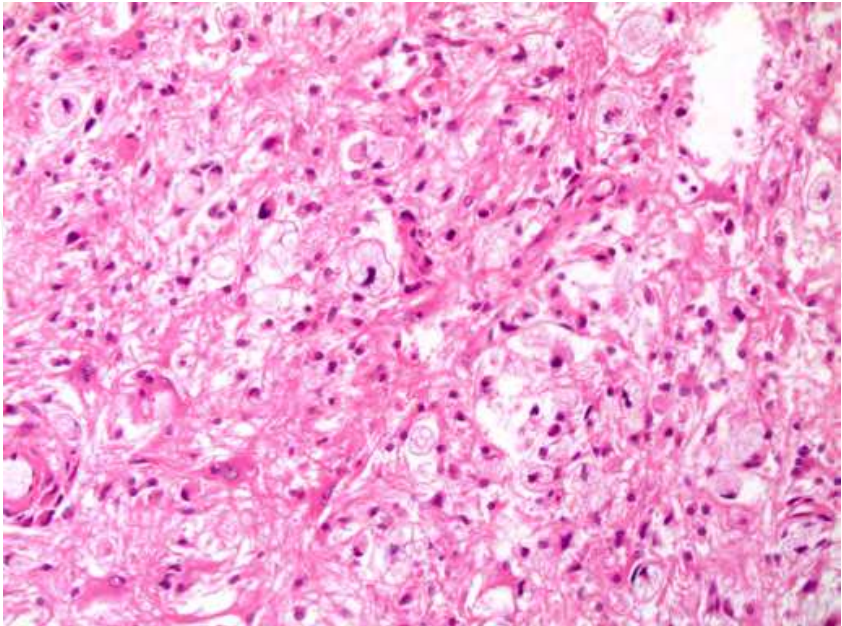


Fig. 8. PXA. X200 H-E. Presence of pleomorphic bizarre xanthomized cells in a fibrillary background.

Author	RS dev	N° Pt	Me/Med FU mos.	Clinical Results			Perm. Sympt. Compl.
				No def. /Impr	Stable	Wors.	
Koga 2009	GK	1	50.0	-	-	-	0.0
Present series	GK	3	45.6/43.7	1/3	1/3	1/3‡	0.0

RS dev = Radiosurgical device; N° Pt = number of treated patients; Me = Mean; Med = Median; mos. = months; No def./Impr = No pre-GK neurological deficit/Neurological improvement; Wors. = Neurological worsening; Perm. Sympt. Compl. = permanent symptomatic complications; GK = Gamma Knife.  
‡: due to tumor distant progression.

Table 12. Clinical data in previous and present series of PXA treated with GKRS.

Author	N° Pt	Ov. Surv %	Act. Surv %		Ov. Local TGC%	Act. Local PFS%	
			At 5y	At 10y		At 5y	At 10y
Koga 2009	1	0.0	-	-	100.0	-	-
Present series	3	66.7‡	80.0	80.0	66.7	80.0	80.0

N° Pt = number of treated patients; Ov. Surv. = overall survival; Act. Surv. = actuarial survival; Ov. Local TGC = Overall local tumor growth control; Act. Local PFS = Actuarial local progression-free survival.  
‡: dead due to tumor local and distant progression.

Table 13. Radiosurgical outcome in previous and present series of PXA.

period achieving a successful local control of all treated lesions without radiosurgery-related permanent side effects. The patient died 66 months after the disease onset; the cause of death was identified with a distant craniospinal axis tumor nodule dissemination. In this chapter, we report 3 patients affected with grade II PXA who underwent GKRS and followed up for a median period of 43.7 months. To our knowledge, this is the only reported "small" series of low-grade PXA treated with GKRS. One patient affected with a brain stem PXA died at 22.1 months from GKRS due to local and distant tumor progression. In the other 2 cases, a long term PFS was achieved and they are well and alive at last follow up performed at 43.7 months and 70.9 months from radiosurgical treatment.

4.6 Others (Miscellaneous)

This heterogeneous group of patients is represented by different histological types of extremely unusual LGPNT of the brain: ganglioglioma, mixed oligoastrocytoma, subependymoma, and papillary glioneuronal tumor. The results of our experience with GKRS is excellent: negative or stable neurologic conditions in all cases, no radiosurgery-related complications, 100% survival and local TGC rate. Obviously, other experiences with GKRS on such rare tumors are limited or even absent (Tables 14 and 15). In the few reported cases, the authors described encouraging responses to radiosurgery, as well. The results

seems to be particularly encouraging when GKRS is employed. To our knowledge, there are no other patients affected with papillary glioneuronal tumor who underwent GKRS reported in the literature; therefore, the case of the present series represents the first papillary glioneuronal tumor treated with radiosurgery.

Histology	Author	RS dev	N° Pt	FU mos.	Clinical Results			Perm. Sympt. Compl.
					No def. /Impr	Stable	Wors.	
Ganglioglioma	Kim 1999	GK	1	14.0	-	-	-	0.0
	Schröttner 2002	GK	3	-	-	-	-	-
	Present series	GK	2	68.4	-	2/2	-	0.0
Subependymoma	Ecker 2004	GK	1	54.0	-	1/1	-	0.0
	Seol 2003	Lin	1	24	-	-	-	0.0
	Im 2003	GK Lin	2	22.5	-	-	-	0.0
	Roos 2000	Lin	1	16	1/1	-	-	0.0
	Present series	GK	1	31.2	1/1	-	-	0.0
Oligoastrocytoma	Sarkar 2002	GK	11 les	-	-	-	-	0.0
	Present series	GK	1	68.3	1	-	-	0.0
Papillary Gl. Tumour	Present series	GK	1	104.0	1/1	-	-	0.0

RS dev = Radiosurgical device; N° Pt = number of treated patients; mos. = months; No def./Impr = No pre-GK neurological deficit/Neurological improvement; Wors. = Neurological worsening; Perm. Sympt. Compl. = permanent symptomatic complications; GK = Gamma Knife; Lin = Linear accelerator; les = lesions; Papillary Gl. Tumour = Papillary Glioneuronal Tumour.

Table 14. Clinical data in previous and present series of rare unusual LGPNTs treated with GKRS.



Histology	Author	RS dev	N° Pt	Ov. Surv.	Ov. Local TGC%	Act. Local PFS% At 5y	Prognostic Factors
Ganglioglioma	Kim 1999	GK	1	-	1/1 solid compon.	-	-
	Schröttner 2002	GK	3				
	Present series	GK	2	2/2	2/2	-	None
Subependymoma	Ecker 2004	GK	1	1/1	1/1	-	-
	Seol 2003	Lin	1	1/1	0/1	-	-
	Im 2003	GKLin	2	2/2	0/2	-	-
	Roos 2000	Lin	1	1/1	1/1	-	-
	Present series	GK	1	1/1	1/1	-	None
Oligoastrocytoma	Sarkar 2002	GK	11 les	-	-	42.0	Younger age Smaller TVs
	Present series	GK	1	1/1	1	100.0	None
Papillary Gl. Tumour	Present series	GK	1	1/1	1/1	100.0	None

RS dev = Radiosurgical device; N° Pt = number of treated patients; Ov. Surv. = Overall survival; Ov. Local TGC = Overall local tumor growth control; Act. Local PFS = Actuarial local progression-free survival; GK = Gamma Knife; compon. = component; Lin = Linear accelerator; TVs = Tumor volumes.

Table 15. Radiosurgical outcome in previous and present series of rare unusual LGPNTs.

4.7 Future research/perspectives

The results described with the GKRS treatment in such unusual LGPNTs are very intersting. Nevertheless, the need for further future perspectives and researches emerge from all these studies. First of all, the application of multisession GKRS with the Extend system (Elekta instruments, AB) on larger TVs with the aim of increasing the local TGC without exposing the patients to higher risk of radiation toxicity on the surrounding normal brain tissue need to be studied. Second, it should be interesting to investigate if there is any potential correlation between biomarker expression (Ki67, MGMT, PCNA, p53, etc.) in such unusual LGPNTs and GKRS outcome. Finally, basing on the literature data and our experience results, it should be suitable that GKRS is included in the international guidelines for good clinical practice as part of the therapeutic armamentarium for the management of unusual LGPNTs, particularly as concerns pineocytoma and CN.

## 5. Conclusion

GKRS may be already considered an effective and safe treatment alternative in multimodality approach for selected cases with pineocytoma and CNs, thus eliminating the need for reoperation of residual or recurrent tumors and avoiding the potential long-term side effects of conventional RT in these young adult patients. In the unusual LGPNTs with a limited number of treated patients – CPP, PXA, and other rare tumors – radiosurgery seems to be a valid complementary treatment tool in these rarer tumors, also. Nevertheless, multidisciplinary studies on large series of patients and long follow-up period with statistical analysis are needed to convincingly demonstrate the efficacy and safety of GKRS on such primary low-grade brain tumors.

## 6. Acknowledgment

The authors thank Giovanni Nicolato, for his assistance in the preparation of this manuscript.

## 7. References

- Anderson, R.C., Elder, J.B., Parsa, A.T., Issacson, S.R., Sisti, M.B. (2001). Radiosurgery for the treatment of recurrent central neurocytomas. *Neurosurgery*, Vol.48, pp 1231-1238.
- Backlund, E.O., Rahn, T., Sarby, B. (1974). Treatment of pinealomas by stereotaxic radiation surgery. *Acta Radiol Ther Phys Biol*, Vol.13, pp 368-376.
- Bertalanffy, A., Roessler, K., Dietrich, W., Aichholzer, M., Prayer, D., Ertl, A., Kitz, K. (2001). Gamma knife radiosurgery of recurrent central neurocytomas: a preliminary report. *J Neurol Neurosurg Psychiatry*, Vol.70, pp 489-493
- Boethius, J., E Ulfarsson, T Rahn, B Lippitz. (2002). Gamma Knife radiosurgery for pilocytic astrocytomas. *J Neurosurg*, Vol.(Suppl 5)97, pp 677-680.
- Breslaw, N. (1974). Covariance analysis of censored survival date. *Biometrics*, Vol.30, pp 89-99.
- Bruce, J.N., Ogden, A.T. (2004). Surgical strategies for treating patients with pineal region tumors. *J Neuro-Oncol*, Vol.69, pp 221-236.
- Chiechi, M.V., Smirniotopoulos, J.G., Mena, H. (1995). Pineal parenchymal tumors: CT and MR features. *J Comput Assist Tomogr*, Vol.19, pp 509-517.
- Cobery, S.T., Noren, G., Friehs, G.M., Chougule, P., Zheng, Z., Epstein, M.H., Taylor, W. (2001). Gamma knife surgery for treatment of central neurocytomas. Report of four cases. *J Neurosurg*, Vol.94, pp 327-330.
- Deshmukh, V.R., Smith, K.A., Rekate, H.L., Coons, S., Spetzler, R.F. (2004). Diagnosis and management of pineocytomas. *Neurosurgery*, Vol.55, pp 349-357.
- Duke, B.J., Kindt, G.W., Breeze, R.E. (1997). Pineal region choroid plexus papilloma treated with stereotactic radiosurgery: a case study. *Comput Aided Surg*, Vol.2, pp 135-138.
- Ecker, R.D., Pollock, B.E. (2004). Recurrent Subependymoma Treated with Radiosurgery. *Stereotact Funct Neurosurg*, Vol.82, pp 58-60.
- Eder, H.G., Leber, K.A., Eustacchio, S., Pendl, G. (2001). The role of gamma knife radiosurgery in children. *Childs Nerv Syst*, Vol.17, pp 341-346.

- Friedman, J.A., Lynch, J.J., Buckner, J.C., Scheithauer, B.W., Raffel, C. (2001). Management of malignant pineal germ cell tumors with residual mature teratoma. *Neurosurgery*, Vol.48, pp 518-523.
- Grimoldi, N., Tomei, G., Stankov, B., Lucini, V., Masini, B., Caputo, V., Repetti, M.L., Lazzarini, G., Gaini, S.M. (1998). Neuroendocrine, immunohistochemical, and ultrastructural study of pineal region tumors. *J Pineal Res*, Vol.25, pp 147-158.
- Hadjipanayis, C.D., Kondziolka, D., Gardner, P., Niranjan, A., Dagam, S., Flickinger, J.C., Lunsford, L.D. (2002). Stereotactic radiosurgery for pilocytic astrocytomas when multimodal therapy is necessary. *J Neurosurg*, Vol.97, pp 56-64.
- Hadjipanayis, C.G., Niranjan, A., Tyler-Kabara, E., Kondziolka, D., Flickinger, J.C., Lunsford, L.D. (2002). Stereotactic radiosurgery for well-circumscribed fibrillary grade II astrocytomas: an initial experience. *Stereotact Funct Neurosurg*, Vol.79, pp 13-24.
- Hara, M., Aoyagi, M., Yamamoto, M., Maehara, T., Takada, Y., Nojiri, T., Ohno, K. (2003). Rapid shrinkage of remnant central neurocytoma after gamma knife radiosurgery: a case report. *J Neurooncol*, Vol.62, pp 269-273.
- Hasegawa, T., Kondziolka, D., Hadjipanayis, C.G., Flickinger, J.C., Lunsford, L.D. (2002). The role of radiosurgery for the treatment of pineal parenchymal tumors. *Neurosurgery*, Vol.51, pp 880-889.
- Hassoun, J., Gambarelli, D., Grisoli, F., Pellet, W., Salamon, G., Pellissier, J.F., Toga, M. (1982). Central neurocytoma. An electron-microscopic study of two cases. *Acta Neuropathol*, Vol.56, pp 151-156.
- Heppner, P.A., Sheehan, J.P., Steiner, L.E. (2005). Gamma knife surgery for low-grade gliomas. *Neurosurgery*, Vol.57, No.6, pp 1132-1139.
- Im, S.-H., Paek, S.H., Choi, Y.-L., Chi, J.G., Kim, D.G., Jung, H.W., Cho, B.-K. (2003). Clinicopathological study of seven cases of symptomatic supratentorial subependymoma. *Journal of Neuro-Oncology*, Vol.61, pp 57-67.
- Javedan, S.P., Manwaring, K., Smith, K.A. (2003). Treatment of posterior third ventricular central neurocytoma with endoscopic biopsy, endoscopic third ventriculostomy and stereotactic radiosurgery. *Minim Invasive Neurosurg*, Vol.46, pp 165-168.
- Kano, K., Kondziolka, D., Niranjan, A., Flickinger, J.C., Lunsford, L.D. (2009). Stereotactic radiosurgery for pilocytic astrocytomas part 1: outcome in adult patients. *J Neurooncol*, Vol.95, pp 211-218.
- Kano, K., Niranjan, A., Kondziolka, D., Flickinger, J.C., Pollack, I., Jakacki, R., Lunsford, L.D. (2009). Stereotactic radiosurgery for pilocytic astrocytomas part 2: outcome in pediatric patients. *J Neurooncol*, Vol.95, pp 219-229.
- Kano, H., Niranjan, A., Khan, A., Flickinger, J.C., Kondziolka, D., Lieberman, F., Lunsford, L.D. (2009). Does radiosurgery have a role in the management of oligodendrogliomas? *J Neurosurg*, Vol.110, pp 564-571.
- Kano, H., Niranjan, A., Kondziolka, D., Flickinger, J.C., Kondziolka, D., Lunsford, L.D. (2009). Role of stereotactic radiosurgery in the management of pineal parenchymal tumors, In: *Pineal Region Tumors. Diagnosis and treatment options*, T. Kobayashi & L.D. Lunsford, (Eds.), 44-58, ISSN 0079-6492, S. Karger AG, ISBN 978-3-8055-9077-8, Basel, Switzerland.

- Kaplan, E.L.; Meier, P. (1958). Nonparametric estimation from incomplete observations. *J Am Stat Assoc*, Vol.53, pp 457-481.
- Kida, Y., T Kobayashi, Y Mori. (2000). Gamma knife radiosurgery for low-grade astrocytomas: results of long term follow-up. *J Neurosurg*, Vol.(Suppl 3)93, pp 42-46.
- Kim, M.S., Lee, S.I., Sim, J.H. (1999). Brain tumors with cysts treated with gamma knife radiosurgery: is microsurgery indicated ? *Stereotact Funct Neurosurg*, Vol. 72 (Suppl.), pp 38-44.
- Kim, C.Y., Paek, S.H., Kim, D.G. (2003). Linear accelerator radiosurgery for central neurocytoma: a case report. *J Neurooncol*, Vol.61, pp 249-254.
- Kim, C.Y., Paek, S.H., Jeong, S.S., Chung, H.T., Han, J.H., Park, C.K., Jung, H.W., Kim, D.G. (2007). Gamma Knife Radiosurgery for Central Neurocytoma. Primary and Secondary Treatment. *Cancer*, Vol.110, pp 2276-84.
- Kim, I-Y., Niranjana, A., Kondziolka, D., Flickinger, J.C., Lunsford, L.D. (2008). Gamma knife radiosurgery for treatment resistant choroid plexus papillomas. *J Neurooncol*, Vol.90, pp 105-110.
- Kobayashi, T., Kida, Y., Mori, Y. (2001). Stereotactic gamma radiosurgery for pineal and related tumors. *J Neurooncol*, Vol.54, pp 301-309.
- Koga, T., Morita, A., Maruyama, K., Tanaka, M., Ino, J., Shibahara, J., Louis, D.N., Reifenberger, G., Itami, J., Hara, R., Saito, N., Todo, T. (2009). Long-term control of disseminated pleomorphic xanthoastrocytoma with anaplastic features by means of stereotactic irradiation. *Neuro-Oncology*, Vol.11, pp 446-451.
- Krishnan, S., Brown, P.D., Scheithauer, B.W., Ebersold, M.J., Hammack, J.E., Buckner, J.C. (2004). Choroid plexus papillomas: a single institutional experience. *J Neurooncol*, Vol.68, pp 49-55.
- Kulkarni, V., Rajshekhar, V., Haran, R.P., Chandi, S.M. (2002). Long-term outcome in patients with central neurocytoma following stereotactic biopsy and radiation therapy. *Br J Neurosurg*, Vol.16, pp 126-132.
- Lekovic, G.P., Gonzales, L.F., Shetter, A.G., Porter, R.W., Smith, K.A., Brachman, D., Spetzler, R.F. (2007). Role of Gamma Knife surgery in the management of pineal region tumors. *Neurosurg Focus*, Vol.23, No.6, PP E12.
- Louis, D.N., Ohgaki H., Wiestler, O.D., Cavenee, W.K., Burger, P.C., Jouvett, A., Scheithauer, B.W., Kleihues, P. (2007). The 2007 WHO Classification of Tumours of the Central Nervous System. *Acta Neuropathol*, Vol.114, pp 97-109.
- Lunsford, L.D., Flickinger, J., Lindner, G., Maitz, A. (1989). Stereotactic radiosurgery of the brain using the first United States 201 cobalt-60 source gamma knife. *Neurosurgery*, Vol.24, pp 151-159.
- Martin, J.M., Katati, M., Lopez, E., Bullesos, J.A., Arregui, G., Busquier, H., Minguez, A., Olivares, G.; Hernandez, V., Arjona, V. (2003). Linear accelerator radiosurgery in treatment of central neurocytomas. *Acta Neurochir (Wien)*, Vol.145, pp 749-754.
- Matsunaga, S., Shuto, T., Suenaga, J., Inomori, S., Fujino H. (2010). Gamma Knife Radiosurgery for Central Neurocytomas. *Neurol Med Chir (Tokyo)*, Vol.50, pp 107-113.
- Mori, Y., Kobayashi, T., Hasegawa, T., Yoshida, K., Kida, Y. (2009). Stereotactic radiosurgery for pineal and related tumors, In: *Pineal Region Tumors. Diagnosis and treatment*

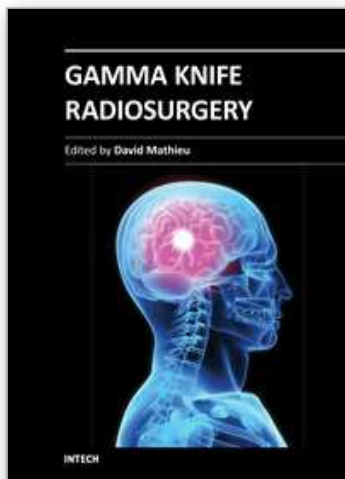
- options, T. Kobayashi & L.D. Lunsford, (Eds.), 107-118, ISSN 0079-6492, S. Karger AG, ISBN 978-3-8055-9077-8, Basel, Switzerland.
- Nicolato, A., Gerosa, M., Ferraresi, P., Piovan, E., Pasoli, A., Perini, S., Mazza, C. (1997). Stereotactic radiosurgery for the treatment of arteriovenous malformations in childhood. *J Neurosurg Sci*, Vol.41, pp 359-371.
- Nicolato, A., F Lupidi, MF Sandri, R Foroni, P Zampieri, C Mazza, A Pasqualin , A Beltramello, M Gerosa (2006). Gamma knife radiosurgery for cerebral arteriovenous malformations in children/adolescents and adults. Part II: differences in obliteration rates, treatment-obliteration intervals, and prognostic factors. *Int J Radiat Oncol Biol Phys*, Vol.64, pp 914-921.
- Pollock, B.E., Stafford, S.L. (2001). Stereotactic radiosurgery for recurrent central neurocytoma: case report. *Neurosurgery*, Vol.48, pp 441-443.
- Rades, D., Schild, S.E. (2006). Value of postoperative stereotactic radiosurgery and conventional radiotherapy for incompletely resected typical neurocytomas. *Cancer*, Vol.106, pp 1140-1143.
- Reyns, N., M Hayashi, O Chinot, L Manera, J-C Peragut, S Blond, J Regis. The role of Gamma Knife radiosurgery in the treatment of pineal parenchymal tumours. *Acta Neurochir (Wien)* 2006;148:5-11.
- Roos, D.E., Brophy, B.P., Zavgorodni, S.F., Francis, J.W. (2000). Radiosurgery at the Royal Adelaide Hospital: The first 4 1/2 years' clinical experience. *Australas Radiol*, Vol.44:, pp 85-192.
- Sarkar, A., Pollock, B.E., Brown, P.D., Gorman, D.A. (2002). Evaluation of gamma knife radiosurgery in the treatment of oligodendrogliomas and mixed oligodendroastrocytomas. *J Neurosurg*, Vol.97(5 Suppl), pp 653-656.
- Schild, S.E., Scheithauer, B.W., Haddock, M.G., Schiff, D., Burger, P.C., Wong, W.W., Lyons, M.K. (1997). Central neurocytomas. *Cancer*, Vol.79, 790-795.
- Schild, S.E., Scheithauer, B.W., Haddock, M.G., Wong, W.W., Lyons, M.K., Marks, L.B., Norman, M.G., Burger, P.C. (1996). Histologically confirmed pineal tumors and other germ cell tumors of the brain. *Cancer*, Vol.78, pp 2564-2571.
- Schröttner, O., Unger, F., Eder, H.G., Feichtinger, M., Pendl, G. (2002). Gamma-Knife radiosurgery of mesiotemporal tumour epilepsy observations and long-term results. *Acta Neurochir Suppl.*, Vol.84, pp 49-55.
- Seol, H.J., Hwang, S.-K., Choi, Y.L., Chi, J.G., Jung, H.W. (2003). A case of recurrent subependymoma with subependymal seeding: case report. *Journal of Neuro-Oncology*, Vol.62 pp 315-320.
- Simonova, G., J Novotny, R Liskac. (2005). Low-grade gliomas treated by fractionated gamma knife surgery. *J Neurosurg*, Vol.(Suppl)102, pp 19-24.
- Subach, B.R., Lunsford, L.D., Kondziolka, D. (1998). Stereotactic radiosurgery in the treatment of pineal region tumors. *Prog Neurol Surg*, Vol.14, pp 175-194.
- Talacchi, A., De Micheli, E., Lombardo, C., Turazzi, S., Bricolo, A. (1999). Choroid plexus papilloma of the cerebellopontine angle: a twelve patient series. *Surg Neurol*, Vol.51, pp 621-629.
- Tyler-Kabara, E., Kondziolka, D., Flickinger, J.C., Lunsford, L.D. (2001). Stereotactic radiosurgery for residual neurocytoma. Report of four cases. *J Neurosurg*, Vol.95, pp 879-882.



Yen, C.P., Sheehan, J., Patterson, G., Steiner, L. (2007). Gamma Knife surgery for neurocytoma. *J Neurosurg*, Vol.107, pp 7-12.

IntechOpen

IntechOpen



## **Gamma Knife Radiosurgery**

Edited by Dr. David Mathieu

ISBN 978-953-307-888-5

Hard cover, 180 pages

**Publisher** InTech

**Published online** 16, December, 2011

**Published in print edition** December, 2011

Gamma knife radiosurgery is a minimally-invasive treatment alternative for intracranial disorders, including tumors, vascular malformations, facial pain and epilepsy. This book will allow the reader to learn when gamma knife radiosurgery is appropriate and what to expect as treatment results.

### **How to reference**

In order to correctly reference this scholarly work, feel free to copy and paste the following:

A. Nicolato, M. Longhi, R. Foroni, F. Alessandrini, A. De Simone, C. Ghimenton, A. De Carlo, P. Mirtuono and M. Gerosa (2011). Gamma Knife Radiosurgery in the Management of Unusual Grade I/II Primitive Neuroepithelial Tumours of the Brain, Gamma Knife Radiosurgery, Dr. David Mathieu (Ed.), ISBN: 978-953-307-888-5, InTech, Available from: <http://www.intechopen.com/books/gamma-knife-radiosurgery/gamma-knife-radiosurgery-in-the-management-of-unusual-grade-i-ii-primitive-neuroepithelial-tumours-o>

**INTech**  
open science | open minds

### **InTech Europe**

University Campus STeP Ri  
Slavka Krautzeka 83/A  
51000 Rijeka, Croatia  
Phone: +385 (51) 770 447  
Fax: +385 (51) 686 166  
[www.intechopen.com](http://www.intechopen.com)

### **InTech China**

Unit 405, Office Block, Hotel Equatorial Shanghai  
No.65, Yan An Road (West), Shanghai, 200040, China  
中国上海市延安西路65号上海国际贵都大饭店办公楼405单元  
Phone: +86-21-62489820  
Fax: +86-21-62489821

© 2011 The Author(s). Licensee IntechOpen. This is an open access article distributed under the terms of the [Creative Commons Attribution 3.0 License](https://creativecommons.org/licenses/by/3.0/), which permits unrestricted use, distribution, and reproduction in any medium, provided the original work is properly cited.

IntechOpen

IntechOpen