

# We are IntechOpen, the world's leading publisher of Open Access books Built by scientists, for scientists

6,900

Open access books available

185,000

International authors and editors

200M

Downloads

Our authors are among the

154

Countries delivered to

TOP 1%

most cited scientists

12.2%

Contributors from top 500 universities



WEB OF SCIENCE™

Selection of our books indexed in the Book Citation Index  
in Web of Science™ Core Collection (BKCI)

Interested in publishing with us?  
Contact [book.department@intechopen.com](mailto:book.department@intechopen.com)

Numbers displayed above are based on latest data collected.  
For more information visit [www.intechopen.com](http://www.intechopen.com)



# Radiosurgical Treatment of Intracranial Meningiomas: Update 2011.

M. Gerosa et al.\*

*Multidisciplinary Neuro-Oncologic Group of Verona,  
Department of Neurosurgery,  
University Hospital (AOUI) of Verona, Verona,  
Italy*

## 1. Introduction

Meningiomas account for 16%-25% of all intracranial tumors, and quite often they rank amongst the most frequent neuro-oncological diagnostic subgroups in European or American registries (4, 5, 8, 54). As regards their natural history, (23, 29, 46, 55, 56, 59, 61) the few reported series of conservatively managed symptomatic meningiomas-bearing adequate FU- have documented a consistent progression in approximately one-third of patients, although in a wide spectrum of variability (TABLE 1).

The average annual incidence is 5-6 new cases per 100,000 (F/M ratio roughly 3:1) and it is lower in pediatrics, even though younger patients may show quite malignant oncotypes (4, 5, 8, 24, 43, 46, 59, 61, 64, 71, 73, 81). However, younger patients may show quite aggressive oncotypes (64, 71, 73). Growing human, sanitary and social costs are more pronounced in females because of the quoted demographic data.

At uni-multivariate analysis, the main factors putatively associated with more- or-less pronounced aggressiveness seem to be represented by younger age and T2-hyperintensity, or by presence of calcifications, respectively (TABLE 1). As expected, grade 2 and 3 meningiomas entail a more severe prognosis (30, 39, 40, 48, 51, 56, 62), thereby justifying the advocated multidisciplinary treatments in such instances (30, 54, 62, 84, 85).

---

\* R. Foroni<sup>1</sup>, M. Longhi<sup>1</sup>, A. De Simone<sup>1</sup>, F. Alessandrini<sup>2</sup>, P. Meneghelli<sup>1</sup>, B. Bonetti<sup>3</sup>, C. Ghimenton<sup>4</sup>, T. Sava<sup>5</sup>, S. Dall'Oglio<sup>6</sup>, A. Talacchi<sup>1</sup>, C. Cavedon<sup>7</sup>, F. Sala<sup>1</sup>, R. Damante<sup>1</sup>, F. Pioli<sup>6</sup>, S. Maluta<sup>6</sup> and A. Nicolato<sup>1</sup>

<sup>1</sup>Department of Neurosurgery,

<sup>2</sup>Department of Neuroradiology,

<sup>3</sup>Department of Neurology,

<sup>4</sup>Department of Neuropathology,

<sup>5</sup>Department of Medical Oncology,

<sup>6</sup>Department of Radiation Oncology,

<sup>7</sup>Department of Medical Physics,

Multidisciplinary Neuro-Oncologic Group of Verona, University Hospital (AOUI) of Verona, Verona, Italy

2. Treatment options

Surgery still represents the mainstay in the specific neurosurgical armamentarium. Indeed, whenever feasible, a Simpson grade 1 resection of the tumor should be considered the golden therapeutic standard, reducing immediately any mass effect, and alleviating clinical signs and symptoms (2, 10, 11, 33, 41, 45, 52- 54 , 75, 80).

Author (year) (Reference)	No. of patients	Mean follow-up (mo)	No. (%) showing growth	Average growth rate	Factors commonly associated with an aggressive cell kinetic	Factors commonly observed in resting tumors
Olivero et al. (1995) (61)	45	32	10 (22.2)	2.4 mm/year		
Go et al. (1998) (23)]	35	74	4 (11.4)	3.2 mm/year		Calcification
Kuratsu et al. (2000) (43)	63	27.8	20 (31.7)		T2 hyperintensity	Calcification
Niirö et al. (2000) (59)	40	41.8	14 (35)		Larger size, T2 hyperintensity, male sex	Calcification
Yoneoka et al. (2000) (81)	37	50.4	9 (24.3)	1.36 cm <sup>3</sup> /year	Younger age, larger tumors	
Nakamura et al. (2003) (55)	41	43	14 (34)	0.796 cm <sup>3</sup> /year	Younger age, T2 hyperintensity	Calcification
Herscovici et al. (2004) (29)	43	67	16 (37)	4 mm/year	Younger age, sphenoid ridge	Calcification, smaller tumors
Yano and Karatsu (2006) (80)	67	>60	25 (37.3)	1.9 mm/year	T2 hyperintensity	Calcification

Table 1. Natural history of meningiomas. Reported growth rates in conservatively treated series.

In facts, local recurrence rates at 10 year-follow up are **directly related** to Simpson’s grade of radicality, with 10-33% after complete resection (Simpson 1-2), and 55-75% after partial-to-minimal removal (i.e. Simpson 3-6) (33, 45, 48, 52, 53, 75, 80). This seems particularly true in the vast majority of convexity meningiomas, whereas results are less warranted in critical locations, like in skull base tumors.

Indeed, despite surgical advances, whenever these tumors are infiltrating the skull base, cranial nerves, or vascular structures, complete resection may not be feasible without unacceptable morbidity and sometimes mortality rates. Considering some of the largest published series, gross total removal of basal meningiomas sounds achievable in 60%-87.5% of the patients with 30%-56% of severe complications - particularly frequent in grade 2-3 histotypes - and a median postoperative mortality rate of 3.6 % (0%-9%) (11, 12, 45, 48, 75, 76, 79, 80). The main factors conditioning the extent of removal in skull base locations have been extensively analyzed in the literature, thereby creating the “resectability grading” where the final score represents the sum of each of the most relevant limiting factors: from cranial nerve involvement to vessel encasement, from extrafossa invasion to previous radiation treatments (45, 63, 74, 78, 82, 86).

*Three large single-institution series with 10 to 15 years’ follow-up, documenting rates of recurrence following GTR alone*

Authors & Year	No. of Patients	Local Recurrence Rate (%)		
		5-yr	10-yr	15-yr
Mirimanoff et al., 1985	145	7	20	32
Condra et al., 1997	175	7	20	24
Stafford et al., 1998	465	12	25	—

Table 2a. (53, 10, 77)

*Four single-institution series with 10- to 20-year follow-up, assessing rates of recurrence following STR alone*

Authors & Year	No. of Patients	Local Progression Rate (%)			
		5-yr	10-yr	15-yr	20-yr
Wara et al., 1975	58	47	62	—	74
Mirimanoff et al., 1985	80	37	55	91	—
Condra et al., 1997	55	47	60	70	—
Stafford et al., 1998	116	39	61	—	—

Table 2b. (83, 53, 10, 77)

Table 2. Meningiomas: analysis of recurrence rate after gross total removal (GTR: TABLE 2a) compared to subtotal removal (STR: TABLE 2b)

The observed wide spectrum of recurrence rates (from 0 to 17%), is seemingly linked not only to the pre-existing W.H.O.’s and Simpson’s grade, but also to the duration of follow up periods, although the latter is an often disregarded/underestimated parameter in the literature (10, 53, 69, 70, 75, 76, 79).

The non negligible problems with surgical radicality in crucial sites, may be further complicated by the presence of „aggressive“ cytotypes, most often responsible for early recurrences shortening patients’ survival (TABLE 2&3).

Author (ref)	Period	N.Pts	Mal. Definition	Survival
Harris (27)	1987-2001	12	WHO 2000	59% 5yr 0% 10 yr
Perry (64-65)	1970-1997	27	Frank anaplasia	32% 5yr
Hug (30)	1973-1995	16	WHO 1993	51% 5yr
Palma (62)	1951-1986	29	WHO 1993	64% 5yr 35% 10 yr
Ware (84)	1988-2002	17	WHO 1993	59% 5 yr 15% 10 yr
Ojemann (60)	1991-1999	22	WHO 1993	40% 5 yr
Goldsmith (24)	1967-1990	23	Unique grading scheme	58% 5 yr.

Table 3. Recently published series of malignant meningiomas: 5- 10 yr survival.

Finally, also the tackling issues of meningiomatosis, contribute to explain the special momentum of combined, multidisciplinary approaches including Gamma Knife Radio Surgery (GKR).

3. Gamma knife radiosurgery

The fundamental reasons for the growing role of this technique, particularly in highly critical intracranial meningiomas, may be briefly summarized as follows:

1. fine tuning of the dosimetry planning. With the advent of hardware and software stereotactic sophistication, the process of 3D recognition of the tumor – as well as to spare the adjacent critical structures has gradually become more and more refined. A major role to this regard has been played by image co-registration, morpho-functional integration (functional MRI / spectroscopy, specific metabolic PET scan mapping etc.) on one side, and by the use of “hybrid shots” with the new “Perfexion” whenever dealing with crucial targeting (7, 36, 50, 57, 58, 66).
2. the introduction of dedicated algoritms accurately “driving” the dose planning system, with probabilistic models including stockastic monitoring, quadrature-sum analysis (20) and linear-quadratic formalisms (32). These techniques, and the concomitant diffusion of phantom studies, have repeatedly confirmed the reliability of such referrals, consistently improving the main conformity indexes. To date, the recommended “surface- or “peripheral “doses” for meningiomas range from 11 - to - 15 Gy (16, 36, 37, 41, 47, 49, 54, 72).

The “ideal” – i.e. the most biologically justified – targeting dose- volume in these peculiar lesions, is still a matter of debate, with a spectrum of options: from including “only” the gross, T1 contrast enhancing tumor, plus a supposedly infiltrated margin of a few mm (39,40,50), up to the controversial inclusion either of the “dural tail”, or of the hyperostotic bone. However, the former - according to extremely refined studies – has been shown to be essentially composed by hypervascular dura with surprisingly none of the expected tumor colonies (34). The latter - according to Pieper- should be almost constantly (25/26 cases) infiltrated, even in presence of negative imaging (67). In these cases, ablative radiosurgery

on the hyperostotic bone might have the same meaning of Simpson's grade 1 in surgical approaches (67).

3. a deeper radiobiological experience. Radiosurgery, like most radiation treatments, hitting the biological target, results in the formation of free radicals as electrons are freed from their atoms. Their main in vivo effect is closely related to a variety of local conditions: first of all the particular onco-type and its cellular peculiarities ("alpha-beta ratio" (35), superoxide-enzyme characterization, sister-chromatide exchange potential etc.) defining the radio-sensitivity; then the quality and quantity of radiation dosimetry, the targeted volume etc., up to the microscopic model of energy deposition. On the basis of these features, meningiomas mostly belong to relatively radiosensitive, "late responding tissues" (LRT) frequently exploiting local hypoxic shields (3, 13, 30, 49), particularly in the elderly (59).

As a consequence effective dosages are in the lower range, not far from normal cell radiosensitivity thresholds, whilst the time-interval for the effect is close to maximum in vivo doubling time (3, 7, 16, 31, 68, 69, 70, 71, 72).

- At present, over half a million people have been treated by GKR all over the world, at a continuously increasing annual rate (in 2010 roughly 50,000 patients), with intracranial meningiomas actually representing approximately one third of these patients.

It is generally accepted that the putative mechanism of action of SRS is intimately dependent not only upon the mentioned technical variables (dose-volume integral, timing, target cytology), but as well as upon the goal we are pursuing ("tumor growth control", necrotic evolution, "epaptic block" etc.) (38, 39, 40). As regards meningiomas, routine protocols are focused on "Tumor Growth Control" (TGC) probably obtained through a combined mechanism: 1. Direct cytotoxicity, presumably promoting apoptosis; 2. Damage to the neoplastic vascular supply, mediated by inhibited growth factors (VEGF, EGF, Factor 8th etc.) 3. Inactivation/destruction of hormonal receptors (e.g. Octreotide- r) (57, 58). **Moreover, it should be stressed that meningiomas located in highly vascularized-oxygenated regions of the brain (cavernous sinus, sagittal sinus etc), due to still poorly known mechanisms (e.g. mutilation of the the superoxide dismutase chain etc.)** usually exhibit a more pronounced radiosensitivity, with sometimes spectacular results (Fig. 1).

If we examine clinical and radiological results in the largest published series of intracranial meningiomas treated during the last decade with different radiosurgical techniques (TABLE 4), some qualifying tenets of these therapeutic approaches appear certainly significant and reliable.

- A. The overall neuro-radiological results are rewarding and stable. Unfortunately, the available literature is of poor statistical quality, also because of the difficulties in performing prospective randomized, adequately stratified clinical trials. Therefore most comparative analyses are based on EBM Class III Data, with only a few studies presenting Class II informations. However, given the definition of "Local Tumor Control" as a post-treatment computerized target volume equal-to or smaller than the original, the 5yr actuarial Tumor Control Rates after GKRS range from 86.2% to 97.9%.



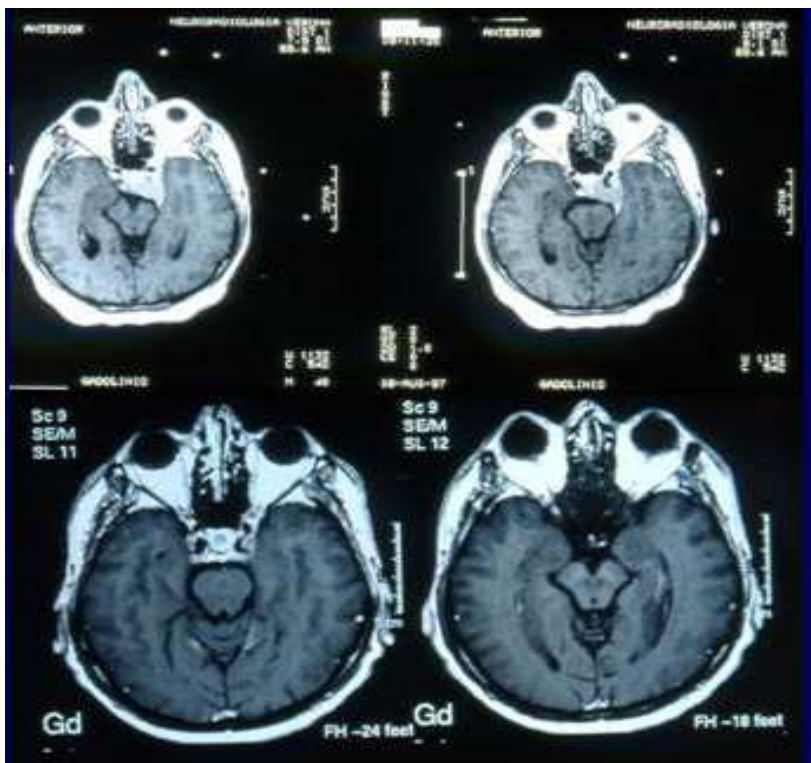


Fig. 1. Left cavernous sinus meningioma before (top) and two years after GKRS. Note the drastic shrinkage of the tumor, not unusual in these locations.

- Furthermore, in GKR treated patients, primary or “imaging diagnosed” meningiomas share a significantly higher 5yr-PFS (87%-95%) than recurrences (34%-97%).
- B. Clinical outcome usually matches these observations, also in our experience (122). Adopting the concept of clinical improvement as the resolution of neurological symptoms, and/or increased pre-operative performances, the vast majority of cases shows stable or improved KPS and neurological gradings at 5-7 years or longer FU. A recent review published by the Pittsburgh Gamma Knife Center (39, 40) confirms in a cohort of 972 patients, with a long term follow up (for some of them up to 20 years) an overall tumor control rate up to 97% a definitively low overall morbidity rate (7.7%) slightly higher for crucial locations such as the cavernous sinus and petroclival region.

As a rule, the cytological grading is the main determinant of the radiosurgical effectiveness. Malignant meningiomas maybe extremely aggressive (Fig. 2) – as mentioned above, with marked endovascular infiltration and neoangiogenesis, requiring multimodality management that include resection, fractionated radiation therapy, brachytherapy, and proton-photon therapy (84, 85, 86).

Similarly, patients with benign histotypes (gr. 1) are usually characterized by 5yr actuarial tumor control rates (87%-96%) much higher than those with atypic (49%-77%) or anaplastic (0%-19%) lesions (21, 24, 37, 49, 63, 73, 77). As shown in (TABLE 4), the still limited number of reports with a mean follow up period of 7-10 years have consistently confirmed these differential LTC levels (3, 15, 41, 63, 70)

Pubblication Year	Authors	Group	No. Pts.	SRS technique	LTC % (5 yr)
1994	Goldsmith et al <sup>(24)</sup>	San Francisco (USA)	140 (117 benign, 23 malignant)	Proton Beam	89 (ben), 48 (mal)
1998	Hakim et al <sup>(26)</sup>	Boston (USA)	127 (155 tumors, of which 106 benign)	LINAC	89.3 for the benign tumors
2001	Pendl et al <sup>63</sup>	Graz (Austria)	197 (198 tumors)	GK	98 (for 164 patients)
2001	Stafford et al <sup>77</sup>	Rochester (USA)	190 (206 tumors)	GK	93 for the benign, 68 for the atypical and 0 for the malignant tumors at 5 years
2002	Eustacchio et al <sup>18</sup>	Graz (Austria)	121	GK	98.3
2002	Nicolato et al <sup>58</sup>	Verona (Italy)	122	GK	96.5 at 5yr
2003	Chang et al <sup>16</sup>	Seoul (Korea)	179 (194 tumors)	GK	97.1
2003	Pollock et al <sup>69-70</sup>	Rochester (USA)	330 (356 tumors)	GK	94
2004	DiBiase et al <sup>13</sup>	Camden (USA)	137	GK	86.2 at 5 yr
2005	Friedman et al. <sup>21</sup>	Gainesville (USA)	210	LINAC	96 for benign, 77 for atypical and 19 for malignant tumors at 5 yr
2005	Kreil et al <sup>41</sup>	Graz (Austria)	200	GK	98.5 at 5yr
2005	Malik et al <sup>49</sup>	Sheffield (United Kingdom)	277 (309 tumors)	GK	87 (typ), 49 (atyp), 0 (mal) at 5 yr
2007	Feigl et al <sup>19</sup>	Hannover (Germany)	211 (243 tumors)	GK	86.3 at 4yr
2007	Hasegawa et al <sup>128</sup>	Komaki, (Japan)	115	GK	87 at 5 yr
2007	Kollová et al <sup>37</sup>	Prague (Czech Republic)	368 (400 tumors)	GK	98 at 5 yr
2008	Iwai et al <sup>31</sup>	Osaka (Japan)	108	GK	93 at 5 yr
2008	Kondziolka et al <sup>139-40</sup>	Pittsburgh (USA)	972 (1,045 tumors)	GK	97 (ben) at 5yr
2009	Colombo et al <sup>19</sup>	Vicenza (Italy)	199	CyberKnife	93.6 at 5yr
2009	Takanashi et al <sup>178</sup>	Sapporo (Japan)	101	GK	95.5% in cav.sin. 98.4% in post.fossa

Table 4. GKR-, PROTON BEAMLINAC- and Cyberknife-based stereotactic radiosurgery in meningiomas. Synopsis of the largest published series of the last two decades comparing local tumor control rates.



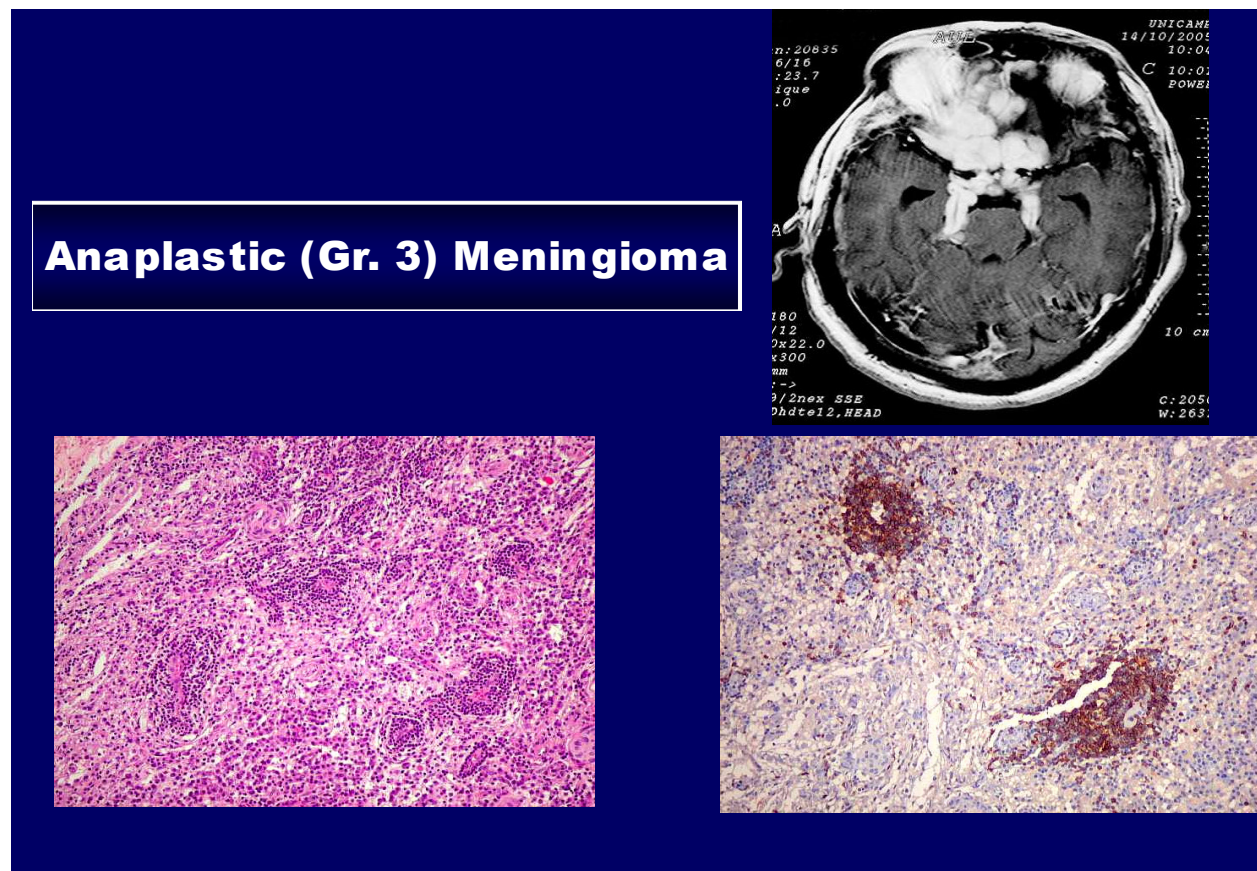


Fig. 2. Anaplastic (gr.3) meningioma. Note the pronounced endo-perivascular tumor cell coating.

Furthermore, it is worth stressing that – even treating larger volumes – either with reduced dosages or with fractionated schedules, the literature shows no evidence of significantly increased “Adverse Radiation Effects” (“ARE”). Probably because the risk of “ARE” gradually subsides with lower prescription doses (3, 18, 19, 22, 31, 38, 47, 49, 64, 65, 70).

- C. Nonetheless, also in meningioma radiosurgical treatments, several limits, pitfalls and risks remain to be tackled. Quoting some of the most intriguing:
- The satellite edema, particularly pronounced in the convexity regions or in parasagittal locations and rarely documented in skull base tumors, probably represent the dominant figure in the early stages of the “Peritumoral Imaging Changes”. The main conditioning factors that may heavily influence the severity of these processes, are essentially related to the specific radiosurgical parameters: e.g. dose volume integral, conformity index etc. (6, 20, 22, 56, 72, 83, 86) However, recent reports have emphasized the extremely high chances to maintain adequate LTC rates – without increasing side effects- by treating larger meningiomas with either fractionated schedules or reduced dosages (3, 13, 18, 19, 22, 24, 31, 32).
  - the controversial or disappointing results obtained in atypic and anaplastic lesions (17, 25, 27, 30, 51, 73), sometimes characterized by intra- or extraneuraxis metastatization (17) or by enhanced growth after radiosurgery (6, 14, 42);
  - the still pronounced morbidity rate of this technique on sensory nerves (6, 14, 77).

- d. finally, potential problems with undue hotspots on strategic vessels within the dosimetry area (1, 15).
- D. A comparative analysis of Cyberknife-based (9,44) radiosurgical experiences in meningiomas versus GKR experiences clearly shows that follow up period is longer for GKR – several reports reaching 8-10 years mean FU vs. 5-6 years for Linac series. Targeted tumor volumes are extremely variable with both approaches, whereas the relative marginal dosages (12-15 Gy) as well as the tumor control rates (usually over 90%) are quite similar. The incidence of sequelae with both techniques is quantitatively (3-13%) and qualitatively reasonable, severe neurological worsening is extremely rare, with no reported mortality.
- E. **Oncogenicity.** The relative risk of carcinogenesis after radiosurgery in the central nervous system has been calculated by means of probabilistic methods, and varies from 1.57 to 8.75 for a dose of 1 Gy, increasing in time up to 18.4 between 20 and 25 years (7, 55). The long-term (30 year) risk of newer radiation induced tumors in meningioma patients has been estimated in 1 per 1,000 treated patients (4, 5, 24, 42, 55). The natural incidence of new gliomas in the population (1/10,000 every year), and the number of meningiomas treated over 3 decades with SRS worldwide (75,000) must be the basic reference for any reliable statistical evaluation. As a consequence, the so far extremely rare (4 cases) reported instances of malignant brain tumors diagnosed in SRS - treated meningioma patients are probably an underestimation of the real incidence, that, however, does not seem to defray further development of this technique.

#### 4. References

- [1] Abeloos L, Levivier M, Devriendt D, et al: Internal carotid occlusion following gamma knife radiosurgery for cavernous sinus meningioma. *Stereotact Funct Neurosurg* 85:303-306, 2007.
- [2] Bambakidis NC, Kakarla UK, Kim LJ, et al: Evolution of surgical approaches in the treatment of petroclival meningiomas: a retrospective review. *Neurosurgery* 62(Suppl 3):1182-1191, 2008
- [3] Bledsoe JM, Link MJ, Stafford SL, et al: Radiosurgery for large-volume (> 10 cm<sup>3</sup>) benign meningiomas. *J Neurosurg* Sept 18, 2009
- [4] Central Brain Tumor Registry in the United States: Statistical report: primary brain tumors in the United States, 1992-1997. Hinsdale, IL: CBTRUS, 2001.
- [5] Central Brain Tumor Registry of the United States: Statistical report: primary brain tumors in the United States, 1998-2002. Hinsdale, IL: CBTRUS, 2005.
- [6] Chang JH, Chang JW, Choi JY, et al: Complications after gamma knife radiosurgery for benign meningiomas. *J Neurol Neurosurg Psychiatry* 74:226-230, 2003.
- [7] Clark BG, Candish C, Vollans E, et al: Optimization of stereotactic radiotherapy treatment delivery technique for base-of-skull meningiomas. *Med Dosim* 33:239-247, 2008
- [8] Claus EB, Bondy ML, Schildkraut JM, et al: Epidemiology of intracranial meningioma. *Neurosurgery* 57:1088-1095, 2005.
- [9] Colombo F, Casentini L, Cavedon C, et al: Cyberknife radiosurgery for benign meningiomas: short-term results in 199 patients. *Neurosurgery* 64:A7-13, 2009.

- [10] Condra KS, Buatti JM, Mendenhall WM, et al: Benign meningiomas: primary treatment selection affects survival. *Int J Radiat Oncol Biol Phys* 39:427-436, 1997.
- [11] Couldwell WT, Fukushima T, Giannotta SL, et al: Petroclival meningiomas: surgical experience in 109 cases. *J Neurosurg* 84:20-28, 1996.
- [12] DeMonte F, Smith HK, al-Mefty O: Outcome of aggressive removal of cavernous sinus meningiomas. *J Neurosurg* 81:245-251, 1994.
- [13] DiBiase SJ, Kwok Y, Yovino S, et al: Factors predicting local tumor control after gamma knife stereotactic radiosurgery for benign intracranial meningiomas. *Int J Radiat Oncol Biol Phys* 60:1515-1519, 2004.
- [14] Dropcho EJ: Neurotoxicity of radiation therapy. *Neurol Clin* 28:217-234, 2010.
- [15] Dufour H, Muracciole X, Metellus P, et al: Long-term tumor control and functional outcome in patients with cavernous sinus meningiomas treated by radiotherapy with or without previous surgery: is there an alternative to aggressive tumor removal? *Neurosurgery* 48:285-294, 2001.
- [16] Elia AE, Shih HA, Loeffler JS: Stereotactic radiation treatment for benign meningiomas. *Neurosurg Focus* 23:E5, 2007.
- [17] Eom KS, Kim DW, Kim TY: Diffuse craniospinal metastases of intraventricular rhabdoid papillary meningioma with glial fibrillary acidic protein expression: a case report. *Clin Neurol Neurosurg* 111:619-623, 2009.
- [18] Eustacchio S, Trummer M, Fuchs I, et al: Preservation of cranial nerve function following Gamma Knife radiosurgery for benign skull base meningiomas: experience in 121 patients with follow-up of 5 to 9.8 years. *Acta Neurochir* 84(Suppl):71-76, 2002.
- [19] Feigl GC, Bundschuh O, Gharabaghi A, et al: Volume reduction in meningiomas after gamma knife surgery. *J Neurosurg* 102(Suppl):189-194, 2005.
- [20] Fowler JF: Sensitivity analysis of parameters in linear-quadratic radiobiologic modeling. *Int J Radiat Oncol Biol Phys* 73:1532-1537, 2009.
- [21] Friedman WA, Murad GJ, Bradshaw P, et al: Linear accelerator surgery for meningiomas. *J Neurosurg* 103:206-209, 2005.
- [22] Ganz JC, Reda WA, Abdelkarim K: Adverse radiation effects after Gamma Knife Surgery in relation to dose and volume. *Acta Neurochir* 151:9-19, 2009.
- [23] Go RS, Taylor BV, Kimmel DW: The natural history of asymptomatic meningiomas in Olmsted County, Minnesota. *Neurology* 51:1718-1720, 1998.
- [24] Goldsmith B: Meningioma. In: Leibel S, Phillips T (eds): *Textbook of Radiation Oncology*. Philadelphia: WB Saunders, 1998.
- [25] Goyal LK, Suh JH, Mohan DS, et al: Local control and overall survival in atypical meningioma: a retrospective study. *Int J Radiat Oncol Biol Phys* 46:57-61, 2000.
- [26] Hakim R, Alexander E, 3rd, Loeffler JS, et al: Results of linear accelerator-based radiosurgery for intracranial meningiomas. *Neurosurgery* 42:446-453, 1998.
- [27] Harris AE, Lee JY, Omalu B, et al: The effect of radiosurgery during management of aggressive meningiomas. *Surg Neurol* 60:298-305, 2003.
- [28] Hasegawa T, Kida Y, Yoshimoto M, et al: Long-term outcomes of Gamma Knife surgery for cavernous sinus meningioma. *J Neurosurg* 107:745-751, 2007.



- [29] Herscovici Z, Rappaport Z, Sulkes J, et al: Natural history of conservatively treated meningiomas. *Neurology* 63:1133-1134, 2004.
- [30] Hug EB, Devries A, Thornton AF, et al: Management of atypical and malignant meningiomas: role of high-dose, 3D-conformal radiation therapy. *J Neurooncol* 48:151-160, 2000
- [31] Iwai Y, Yamanaka K, Yasui T, et al: Gamma knife surgery for skull base meningiomas. The effectiveness of low-dose treatment. *Surg Neurol* 52:40-44, 1999.
- [32] Iwata H, Shibamoto Y, Murata R, et al: Estimation of errors associated with use of linear-quadratic formalism for evaluation of biologic equivalence between single and hypofractionated radiation doses: an in vitro study. *Int J Radiat Oncol Biol Phys* 75:482-488, 2009.
- [33] Jung HW, Yoo H, Paek SH, et al: Long-term outcome and growth rate of subtotally resected petroclival meningiomas: experience with 38 cases. *Neurosurgery* 46:567-574, 2000.
- [34] Kawahara Y, Niino M, Yokoyama S, et al: Dural congestion accompanying meningioma invasion into vessels: the dural tail sign. *Neuroradiology* 43:462-465, 2001
- [35] Kocher M, Wilms M, Makoski HB, et al: Alpha/beta ratio for arteriovenous malformations estimated from obliteration rates after fractionated and single-dose irradiation. *Radiother Oncol* 71:109-114, 2004.
- [36] Koga T, Maruyama K., Igaki H., et al. The value of image co-registration during stereotactic radiosurgery. *Acta Neurochir. (Wien)* 151: 465-471, 2009
- [37] Kollova A, Liscak R, Novotny J Jr, et al: Gamma Knife surgery for benign meningioma. *J Neurosurg* 107:325-336, 2007.
- [38] Kondziolka D, Kano H, Kanaan H, et al: Stereotactic radiosurgery for radiation-induced meningiomas. *Neurosurgery* 64:463-469, 2009
- [39] Kondziolka D, Madhok R, Lunsford LD, et al: Stereotactic radiosurgery for convexity meningiomas. *J Neurosurg* 111:458-463, 2009
- [40] Kondziolka D, Mathieu D, Lunsford LD, et al: Radiosurgery as definitive management of intracranial meningiomas. *Neurosurgery* 62:53-58, 2008
- [41] Kreil W, Luggin J, Fuchs I, et al: Long term experience of gamma knife radiosurgery for benign skull base meningiomas. *J Neurol Neurosurg Psychiatry* 76:1425-1430, 2005
- [42] Kunert P, Matyja E, Janowski M, et al: Rapid growth of small, asymptomatic meningioma following radiosurgery. *Br J Neurosurg* 23:206-208, 2009
- [43] Kuratsu J, Kochi M, Ushio Y: Incidence and clinical features of asymptomatic meningiomas. *J Neurosurg* 92:766-770, 2000.
- [44] Lartigau E, Mirabel X, Prevost B, et al: Extracranial stereotactic radiotherapy: preliminary results with the CyberKnife. *Onkologie* 32:209-215, 2009.//
- [45] Levine ZT, Buchanan RI, Sekhar LN et al. Proposed grading system to predict the extent of resection and outcome for cranial base meningiomas. *Neurosurgery* 45: 221-230, 1999.
- [46] Longstreth WT, Jr., Dennis LK, McGuire VM, et al: Epidemiology of intracranial meningioma. *Cancer* 72:639-648, 1993

- [47] Ma L, Chuang C, Descovich M, et al: Whole-procedure clinical accuracy of gamma knife treatments of large lesions. *Med Phys* 35:5110-5114, 2008.
- [48] Mahmood A, Qureshi NH, Malik GM: Intracranial meningiomas: analysis of recurrence after surgical treatment. *Acta Neurochir* 126:53-58, 1994.
- [49] Malik I, Rowe JG, Walton L, et al: The use of stereotactic radiosurgery in the management of meningiomas. *Br J Neurosurg* 19:13-20, 2005.
- [50] Maruyama K, Kamada K, Shin M et al Integration of three dimensional corticospinal tractography into treatment planning for gamma knife surgery. *J Neurosurg* 102 673-677, 2005
- [51] Mathiesen T, Lindquist C, Kihlstrom L, et al: Recurrence of cranial base meningiomas. *Neurosurgery* 39:2-7, 1996.
- [52] McDermott MW, Quiñones-Hinojosa A, Fuller GN, et al: Meningiomas. In: Levin VA (ed): *Cancer in the Nervous System*, 2<sup>nd</sup> ed. New York: Oxford University, 2002.
- [53] Mirimanoff RO, Dosoretz DE, Linggood RM et al. Meningioma: analysis of recurrence and progression following neurosurgical resection. *J. Neurosurg.* 62: 18-24, 1985.
- [54] Modha A, Gutin PH: Diagnosis and treatment of atypical and anaplastic meningiomas: a review. *Neurosurgery* 57:538-550, 2005
- [55] Muracciole X, Regis J. : Radiosurgery amd carcinogenesis risk. *Progr. Neurol. Surg.* 21: 207-213, 2008.
- [56] Nakamura M, Roser F, Michel J, et al: The natural history of incidental meningiomas. *Neurosurgery* 53:62-70, 2003.
- [57] Nicolato A, Foroni R, Grigolato D et al.: 111 Indium-octreotide brain scintigraphy: a prognostic factor in skull base meningiomas treated with Gamma Knife Radiosurgery. *Q J Nucl Med* 48:26-32, 2004.
- [58] Nicolato A, Giorgetti P, Foroni R et al.: Gamma Knife radiosurgery in skull base meningiomas: a possibile relationship between somatostatin receptor decrease and early neurological improvement without tumor shrinkage at short-term imaging follow-up. *Acta Neurochir* 147:367-375, 2005.
- [59] Niiro M, Yatsushiro K, Nakamura K, et al: Natural history of elderly patients with asymptomatic meningiomas. *J Neurol Neurosurg Psychiatry* 68:25-28, 2000.
- [60] Ojemann SG, Sneed PK, Larson DA, et al: Radiosurgery for malignant meningioma: results in 22 patients. *J Neurosurg* 93(Suppl 3):62-67, 2000.
- [61] Olivero WC, Lister JR, Elwood PW: The natural history and growth rate of asymptomatic meningiomas: a review of 60 patients. *J Neurosurg* 83:222-224, 1995.
- [62] Palma L, Celli P, Franco C, et al: Long-term prognosis for atypical and malignant meningiomas: a study of 71 surgical cases. *J Neurosurg* 86:793-800, 1997.
- [63] Pendl G, Eustacchio S, Unger F: Radiosurgery as alternative treatment for skull base meningiomas. *J Clin Neurosci* 8(Suppl 1):12-14, 2001.
- [64] Perry A, Dehner LP: Meningeal tumors of childhood and infancy. An update and literature review. *Brain Pathol* 13:386-408, 2003
- [65] Perry A, Louis DN, Scheithauer BW, et al.: Meningeal tumors. In: Louis DN, Ohgaki H, Wiestler OD, Cavenee WK (eds): *World Health Organization Classification of Tumours of the Central Nervous System*. Lyon: IARC, 2007.

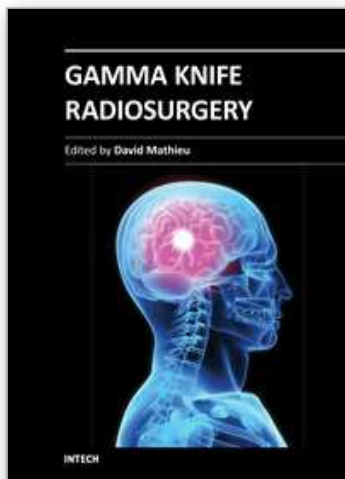
- [66] Petti PL, Larson DA, Kunwar S: Use of hybrid shots in planning Perfexion Gamma Knife treatments for lesions close to critical structures. *J Neurosurg* 109(Suppl):34-40, 2008
- [67] Pieper DR, Al-Mefty O, Hanada Y, et al: Hyperostosis associated with meningioma of the cranial base: secondary changes or tumor invasion. *Neurosurgery* 44:742-746, 1999
- [68] Pollock BE, Stafford SL, Utter A, et al: Stereotactic radiosurgery provides equivalent tumor control to Simpson Grade 1 resection for patients with small- to medium-size meningiomas. *Int J Radiat Oncol Biol Phys* 55:1000-1005, 2003
- [69] Pollock BE: Stereotactic radiosurgery for intracranial meningiomas: indications and results. *Neurosurg Focus* 14:e4, 2003
- [70] Pollock BE: Stereotactic radiosurgery of benign intracranial tumors. *J. Neurooncol.* 92:337-343, 2009
- [71] Riemenschneider MJ, Perry A., Reifenberger G: Histological classification and molecular genetics of meningiomas. *Lancet Neurol.* 5 : 1045-1054, 2006
- [72] Rogers L, Mehta M: Role of radiation therapy in treating intracranial meningiomas. *Neurosurg Focus* 23:E4, 2007.
- [73] Rosenberg LA, Prayson RA, Lee J, et al: Long-term experience with World Health Organization grade III (malignant) meningiomas at a single institution. *Int J Radiat Oncol Biol Phys* 74:427-432, 2009
- [74] Saberi K., Meybodi AT, Rezai AS. Levine-Sekhar grading system for prediction of the extent of resection of cranial base meningiomas revisited: study of 124 cases. *Neurosurg. Rev.* April 29 (2) :138-144, 2006
- [75] Samii M, Klekamp J, Carvalho G: Surgical results for meningiomas of the craniocervical junction. *Neurosurgery* 39:1086-1094,1996
- [76] Sekhar LN, Swamy NK, Jaiswal V, et al: Surgical excision of meningiomas involving the clivus: preoperative and intraoperative features as predictors of postoperative functional deterioration. *J Neurosurg* 81:860-868, 1994
- [77] Stafford SL, Pollock BE, Leavitt JA, et al: A study on the radiation tolerance of the optic nerves and chiasm after stereotactic radiosurgery. *Int J Radiat Oncol Biol Phys* 55:1177-1181, 2003.
- [78] Takanashi M, Fukuoka S, Hojyo A, et al: Gamma knife radiosurgery for skull-base meningiomas. *Prog Neurol Surg* 22:96-111, 2009.
- [79] Thomas NW, King TT: Meningiomas of the cerebellopontine angle. A report of 41 cases. *Br J Neurosurg* 10:59-68, 1996.
- [80] Yano S, Kuratsu J: Indications for surgery in patients with asymptomatic meningiomas based on an extensive experience. *J Neurosurg* 105:538-543, 2006.
- [81] Yoneoka Y, Fujii Y, Tanaka R: Growth of incidental meningiomas. *Acta Neurochir* 142:507-511, 2000.
- [82] Walsh MT, Couldwell WT: Management options for cavernous sinus meningiomas. *J Neurooncol* 92:307-316, 2009
- [83] Wara WM, Sheline GE, Newmann H, et al : Radiation therapy of meningiomas. *Am. J. Roentgenology, Radium Ther., Nucl. Med* 123: 453-458, 1975.



- [84] Ware ML, Larson DA, Sneed PK, et al: Surgical resection and permanent brachytherapy for recurrent atypical and malignant meningioma. *Neurosurgery* 54:55-63, 2004
- [85] Wenkel E, Thornton AF, Finkelstein D, et al: Benign meningioma: partially resected, biopsied, and recurrent intracranial tumors treated with combined proton and photon radiotherapy. *Int J Radiat Oncol Biol Phys* 48:1363-1370, 2000
- [86] Whittle IR, Smith C, Navoo P, et al: Meningiomas. *Lancet* 363:1535-1543, 2004

IntechOpen

IntechOpen



## **Gamma Knife Radiosurgery**

Edited by Dr. David Mathieu

ISBN 978-953-307-888-5

Hard cover, 180 pages

**Publisher** InTech

**Published online** 16, December, 2011

**Published in print edition** December, 2011

Gamma knife radiosurgery is a minimally-invasive treatment alternative for intracranial disorders, including tumors, vascular malformations, facial pain and epilepsy. This book will allow the reader to learn when gamma knife radiosurgery is appropriate and what to expect as treatment results.

### **How to reference**

In order to correctly reference this scholarly work, feel free to copy and paste the following:

M. Gerosa, R. Foroni, M. Longhi, A. De Simone, F. Alessandrini, P. Meneghelli, B. Bonetti, C. Ghimenton, T. Sava, S. Dall'Oglio, A. Talacchi, C. Cavedon, F. Sala, R. Damante, F. Pioli, S. Maluta and A. Nicolato (2011). Radiosurgical Treatment of Intracranial Meningiomas: Update 2011, Gamma Knife Radiosurgery, Dr. David Mathieu (Ed.), ISBN: 978-953-307-888-5, InTech, Available from: <http://www.intechopen.com/books/gamma-knife-radiosurgery/radiosurgical-treatment-of-intracranial-meningiomas-update-2011>

**INTech**  
open science | open minds

### **InTech Europe**

University Campus STeP Ri  
Slavka Krautzeka 83/A  
51000 Rijeka, Croatia  
Phone: +385 (51) 770 447  
Fax: +385 (51) 686 166  
[www.intechopen.com](http://www.intechopen.com)

### **InTech China**

Unit 405, Office Block, Hotel Equatorial Shanghai  
No.65, Yan An Road (West), Shanghai, 200040, China  
中国上海市延安西路65号上海国际贵都大饭店办公楼405单元  
Phone: +86-21-62489820  
Fax: +86-21-62489821

© 2011 The Author(s). Licensee IntechOpen. This is an open access article distributed under the terms of the [Creative Commons Attribution 3.0 License](https://creativecommons.org/licenses/by/3.0/), which permits unrestricted use, distribution, and reproduction in any medium, provided the original work is properly cited.

IntechOpen

IntechOpen