

We are IntechOpen, the world's leading publisher of Open Access books Built by scientists, for scientists

6,900

Open access books available

185,000

International authors and editors

200M

Downloads

Our authors are among the

154

Countries delivered to

TOP 1%

most cited scientists

12.2%

Contributors from top 500 universities



WEB OF SCIENCE™

Selection of our books indexed in the Book Citation Index
in Web of Science™ Core Collection (BKCI)

Interested in publishing with us?
Contact book.department@intechopen.com

Numbers displayed above are based on latest data collected.
For more information visit www.intechopen.com



Traumatic Chondral Lesions of the Knee Diagnosis and Treatment

Masoud Riyami
Sultan Qaboos University, Oman
Sultanate of Oman

1. Introduction

1.1 Anatomy and knee joint function

The knee joint is classified as a modified hinge joint, with its structure providing a highly mobile and complex joint (fig.1). It consists of two condylar joints between the medial and lateral condyles of the femur and the corresponding plateaus of the tibia, and anteriorly a synovial plane patellofemoral joint. The articular surface of the knee is covered by Hyaline cartilage that is supported by subchondral bone. This Hyaline cartilage is very soft and yields its interstitial water easily when compressed yet it is very stiff in tension along planes parallel to the articular surface (Buckwalter and Mow, 2003). Intact cartilage provides a smooth, lubricated gliding surface with a coefficient of friction better than most man-made bearing materials (Buckwalter and Mow, 2003). In the knee articular cartilage distributes the loads of articulation, thereby minimizing peak stresses acting on the subchondral bone whilst the tensile strength of the tissue maintains its structural integrity under loading. These biomechanical properties make the tissue remarkably durable and wear resistant, enabling it to last many decades, even under high and repetitive stresses (Buckwalter and Mow, 2003).

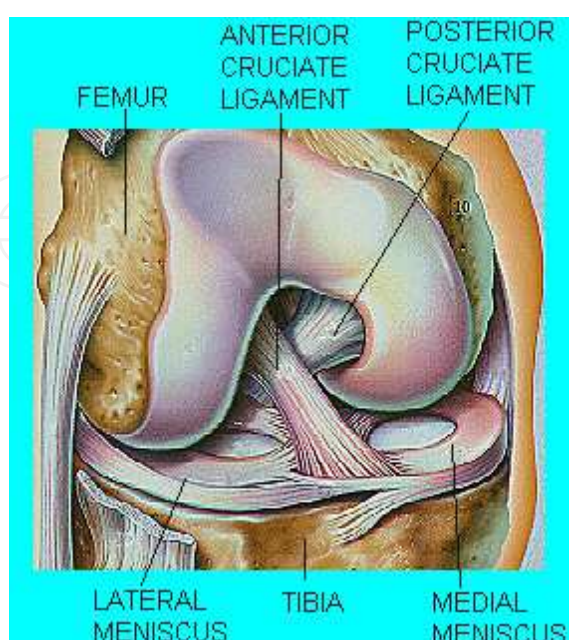


Fig. 1. Structure of knee joint (www.arthroscopy.com)

Flexion and extension are the primary movements of the knee. When the knee is flexed a small amount of rotation can occur. The patella glides along the distal portion of the femur during movements of flexion to extension.

Semi-lunar shaped fibrocartilage discs, triangular in cross-section, form the menisci that are found between the tibia and femur. They deepen the articular surface, improve joint congruency and assist in shock absorption. The medial meniscus is attached to the joint capsule and the deep fibres of the medial collateral ligament. The lateral meniscus does not have these attachments, resulting in increased mobility (Marieb, 1992).

The intra-articular ligaments consist of the anterior cruciate ligament (ACL) and the posterior cruciate ligament (PCL). The ACL provides stability to anterior translation, and prevents the posterior displacement of the femur on the tibia. The PCL prevents anterior displacement of the femur on the tibia.

The main extra-articular ligaments comprise of the medial and lateral collateral ligament and provide side-to-side stability.

Stability of the knee joint is therefore provided by two menisci, intra and extra-capsular ligaments, and the dense muscular structures surrounding the joint. Injuries frequently occur to one or more of these stabilizing structures.

1.2 Structure of articular cartilage

Articular cartilage consists of various substances, each of which contribute to its overall integrity, durability, deformability and ability to repair itself (Hayes et al, 2001).

From embryological life articular cartilage is derived from mesenchymal cells and develops at the future end of epiphyseal bone (Hayes et al, 2001). Cartilage is composed of a matrix of collagen surrounded by proteins and negatively charged proteoglycans (fig.2). The roll of collagen is to serve as an anchor to the proteoglycan matrix protecting chondrocytes.

Articular cartilage consists mainly of types II, IX, and XI collagen. Collagen helps to resist extrinsic forces during loading (Vigarita, 1999; cited by Hayes et al, 2001).

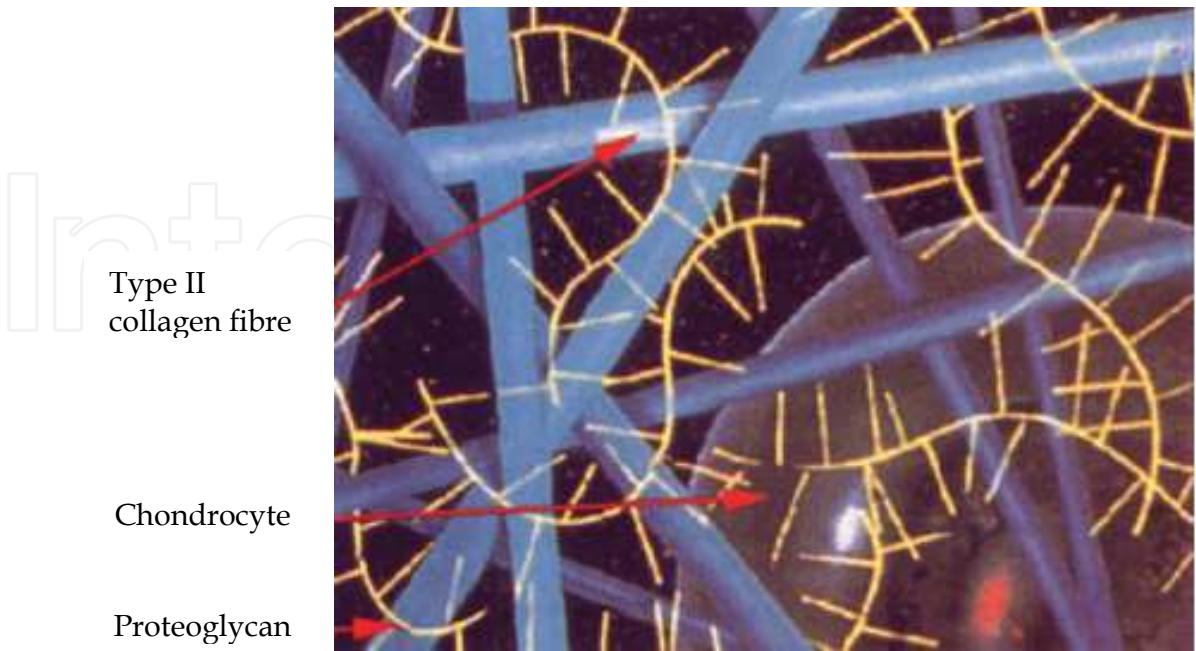


Fig. 2. Spatial relations of collagen, proteoglycans and cells in cartilage (Kocheta and Toms, 2004)

Cartilage has an organized layered structure that can be functionally and structurally divided into four zones (fig.3): Superficial zone, the middle (transitional) zone, the deep zone and a calcified cartilage zone. The superficial zone is the articulating surface that provides a smooth gliding surface and resists shear. This zone makes up approximately 10 to 20 percent of articular cartilage thickness. It has the highest collagen contents of the zones. The collagen fibrils in this zone are densely packed and have a highly ordered alignment parallel to the articular surface (Mow, 1989; cited by Pearle et al, 2005). This superficial zone has the lowest compressive modulus and will deform approximately 25 times more than the middle zone (Pearle et al, 2005).

The middle zone encompasses 40 to 60 percent of the articular cartilage volume. This zone has a higher compressive modulus than the superficial zone and a less organized arrangement of the collagen fibers. The deep zone makes up 30 percent of the cartilage, and consists of large diameter collagen fibril layers perpendicular to the articular surface. This layer has the highest compressive modulus. The tide mark separates the deep zone from the calcified cartilage, which rests directly on the subchondral bone. The calcified cartilage contains small cells in a chondral matrix speckled with apatitic salts (Mow, 1989; cited by Pearle et al, 2005).

Normal adult cartilage is composed of 75 percent water and 25 percent solids. The solids consist of collagen and proteoglycan, and a fluid phase composed of water and ions (Eichellberger, 1951; cited by Hayes et al, 2001).

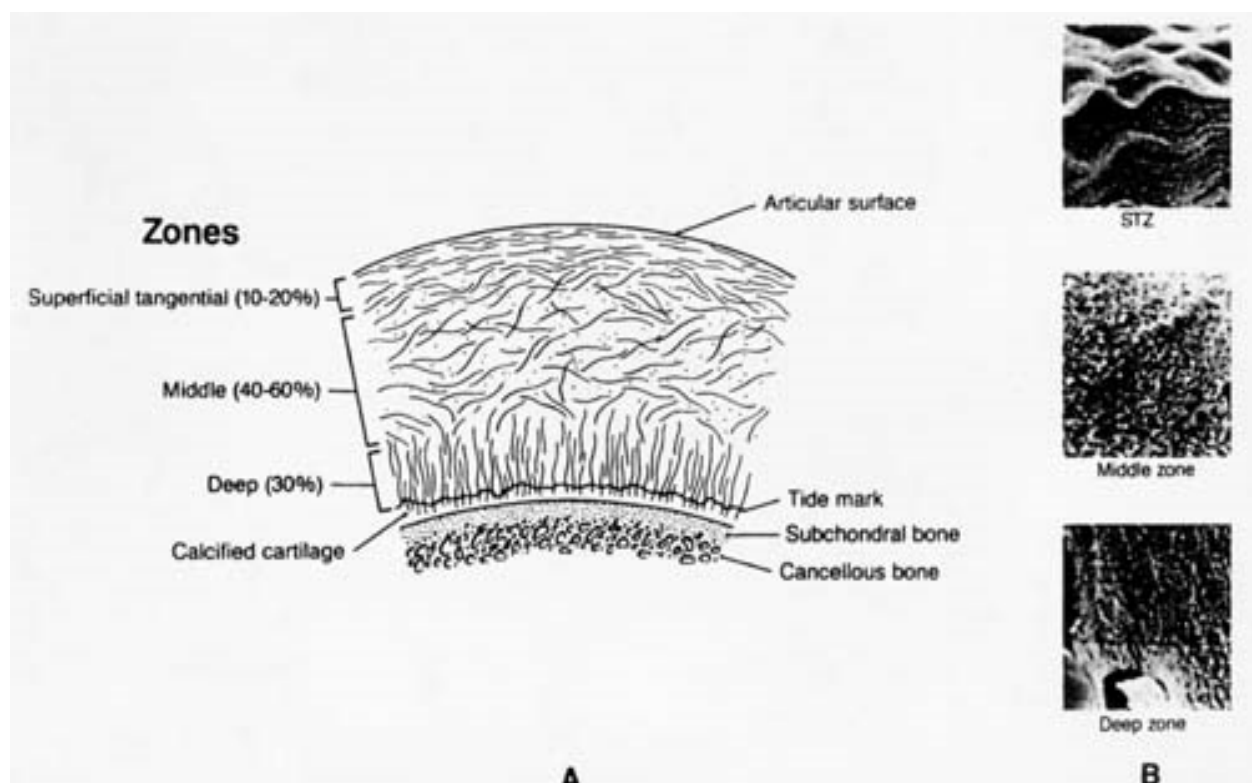


Fig. 3. Articular cartilage zones (Buckwalter and Mow, 2003)

1.3 Metabolism of articular cartilage

A high level of metabolism exists in articular cartilage. Historically, one of the factors that led to the impression that articular cartilage was inert was the early demonstration that,

although articular cartilage had a well-defined glycolytic system, oxygen use was considerably lower in articular cartilage than in other tissues. This difference subsequently was found to be related to the sparse cell (*sic*) population rather than to a lack of metabolic activity per cell. Nevertheless, articular cartilage chondrocytes rely principally on the anaerobic pathway for energy production (Oegema and Thompson, 1989).

Chondrocytes synthesize and assemble the cartilaginous matrix components and direct their distribution within the tissue. These synthetic and assembly processes are complex. They involve synthesis of proteins; synthesis of glycosaminoglycan chains, and their addition to the appropriate cores; and secretion of the completed molecules into the extra-cellular matrix (Guilak et al, 1997).

Chondrocytes are responsible for the synthesis, assembly and sulfation of the proteoglycan molecule. However, in normal tissue, in repair and degradation processes proteoglycans of articular cartilage are continually being broken down and released from the cartilage. This activity is a normal event in the maintenance of the tissue and can occur at an accelerated rate. The rate of catabolism can be affected by soluble mediators and by various types of joint loading (Mankin et al, 2005b).

Collagen is much more stable than the proteoglycan components. However, the collagen network is subject to metabolism, and in osteoarthritic or injured cartilage the collagen turnover increases, but as yet little is known about the mechanism of collagen breakdown (Mankin et al, 2005b).

The source of nutrients for articular cartilage is somewhat of an enigma. Because the tissue is avascular in adult life most investigators believe that nutrients diffuse through the matrix, either from the surrounding synovial fluid or from underlying bone (Mankin et al, 2005b).

1.4 Biomechanics of articular cartilage

The articular cartilage of diarthrodial joints is subject to high loads applied statically and repetitively for many decades. Thus, the structural molecules, which include collagens and proteoglycans must be organized into a strong, fatigue-resistant and tough solid matrix capable of sustaining the high stresses and strains developed within the tissue (Soltz and Ateshian, 2000). The solid matrix is porous and permeable, and very soft. Water, 65 to 80 percent of the total weight of normal articular cartilage, resides in the microscopic pores. This water may be caused to flow through the porous-permeable solid matrix by a pressure gradient or by matrix compaction. The biomechanical properties of articular cartilage therefore are understood best when the tissue is viewed as biphasic material composed of a solid phase and a fluid phase (Soltz and Ateshian, 2000).

1.5 Local transmission of load

Although it is porous, the solid phase of the cartilage has low permeability due largely to a high frictional resistance to fluid flow. This causes a high interstitial fluid pressurization in the fluid phase, which contributes more than 90 percent of the load transmission function of cartilage (Soltz and Ateshian, 2000). The high pressurization of the fluid phase and the low permeability of the solid phase establish both the stiffness and the visco-elastic properties of cartilage (Felson et al, 2000).

This hydraulic pressure provides a significant component of the load support of the cartilage, which protects and stress shields the solid phase of the matrix from much of the load burden (Pearle et al, 2005).

1.6 Mechanism of articular cartilage injury

Direct blunt trauma, indirect impact loading, or torsional loading of a joint can damage articular cartilage and the calcified cartilage-subchondral bone region without disrupting the surrounding soft tissue. Examples of direct blunt trauma to articular cartilage of the knee include a shoe kick, knees colliding in games such as football and rugby, and falling on a hard surface. Examples of indirect impact and torsional loading include a blow to a bone that forms the subchondral part of a joint, and severe twisting of a joint that is loaded (Williams and Wilkins, 1998).

1.7 Age related chondral lesions

Clinical experience suggests that there are age-related differences in the risk and patterns of articular surface injuries. High energy bone or joint trauma causes intra-articular osteochondral fractures in people of all age, but older people and people with more osteopenic bone tend to have more severely comminuted fractures (Buckwalter et al, 1993; Buckwalter and Lane, 1996). Chondral fractures associated with participation in sports generally occur in skeletally mature people, whilst osteochondral fractures associated with participation in sports typically occur in skeletally immature people or young adults. This difference may result from age-related changes in the mechanical properties of the articular surface, including the uncalcified cartilage, the calcified cartilage zone, and the subchondral bone (Buckwalter et al, 1993; Buckwalter and Lane, 1996). That is, age-related alteration in the articular cartilage matrix decreases the tensile stiffness and strength of the superficial zone, and the calcified cartilage zone. The subchondral bone region minimizes fully following completion of skeletal growth, presumably creating a marked difference in mechanical properties between the uncalcified cartilage and the calcified cartilage-subchondral bone region (Williams and Wilkins, 1998).

1.8 Response of articular cartilage to blunt impact

Articular cartilage can withstand single or multiple moderate and occasionally high impact loads. However, a number of studies have addressed the effects of either a single excessive high-impact force causing injury to the cartilage without a break in the surface, or repetitive below-trauma threshold loads causing an accumulation of damage to the cartilage by repeated application of the load. Both can lead to chondrocyte death, matrix damage, fissuring of surface, injury to underlying bone, and thickening of the tide mark region. At a certain threshold of impact loading, the cartilage may be sheared off the subchondral bone (Mankin et al, 2005).

Excessive impact or torsional joint loading causes three types of articular cartilage injury: chondral damage without visible tissue disruption; disruption of articular cartilage alone (chondral fractures and flaps); and disruption of articular cartilage and subchondral bone (osteochondral fractures) (Buckwalter et al, 1988). Intensity and rate of loading, muscle contractions that affect the transmission of force to the articular surface, age, and genetically determined differences in articular cartilage may influence the type of articular surface injury in a given individual (Buckwalter et al, 1988).

1.9 Healing of articular cartilage

More than a century ago articular cartilage was documented as lacking regenerative power; it had been observed that wounds in articular cartilage healed with fibrous tissue and fibrocartilage (Chen et al, 1999). As cartilage is avascular its reparative process differs significantly from the three-phase response of necrosis, inflammation and repair that occurs in vascularized tissue. Cartilage undergoes the initial phase of necrosis in response to injury, but there is less cell death, given its relative insensitivity to hypoxia (Chen et al, 1999). The second phase, inflammation, is largely absent as this response is primarily mediated by the vascular system. No fibrin clot or network is developed to act as a scaffold for the in growth of repair tissue, and no mediators or cytokines are released to stimulate cellular migration and proliferation. The third phase, repair, is also severely limited due to the lack of a preceding inflammatory response and recruitment of undifferentiated mesenchymal cells that normally proliferate and modulate the repair response. The burden of repair thus falls on the existing chondrocytes in a process termed intrinsic repair (Chen et al, 1999).

1.10 Role of chondrocytes in healing

Chondrocytes near the injured part may proliferate and form clusters or clones and synthesize new matrix, but the chondrocytes do not migrate into the lesion. The new matrix they produce remains in the immediate region of the chondrocytes, and their preoperative and synthetic activity fails to provide new tissue to repair the damage. This repair phase is initially brisk. It is, however, limited in scope and duration, disappearing within a matter of weeks (Mankin et al, 2005). Results from experimental studies of injuries limited to cartilage clearly demonstrate the inability of chondrocytes to repair cartilage defects. The results also show that limited experimental injuries to normal articular surfaces in normal synovial joints generally do not progress to full thickness loss of cartilage (Mankin et al, 2005).

1.11 Incidence of articular cartilage injuries

The incidence of articular cartilage injuries to the knee, determined arthroscopically, has been most frequently reported as part of a large series of assessment for haemarthrosis. Noyes et al (1980) reported a 20 percent incidence, Gillquist et al (1977) a 10 percent occurrence, and DeHaven (1980) a 6 percent incidence of chondral or osteochondral injuries. In a review of 1,000 knee arthroscopies Hjelle et al (2002) reported chondral or osteochondral occurrence in 61 percent of the patients, but focal chondral or osteochondral defects were found in 19 percent of the patients. With the increasing age of the patients the incidence of articular cartilage injury increased. Characteristic injury depth patterns have been found to be associated with the degree of skeletal maturity (Hopkinson et al, 1985 and Johnson-Nurse et al, 1985; cited by Speer et al, 1991). In children and adolescents osteochondral fractures are more frequent than full-thickness or partial-thickness chondral injuries. It has been suggested that the bond between articular cartilage and subchondral bone is stronger than the bone itself. With increasing age and skeletal maturity the basal layers of articular cartilage become calcified and the tide mark develops. This provides a plane of weakness through which separation may occur. Full thickness chondral lesions are most frequently seen in patients in their 30s. Beyond this age the plane of weakness moves

further from the subchondral bone into more superficial cartilage, with subsequent increasing incidence of partial thickness chondral injuries (Johnson-Nurse et al, 1985; cited by Speer et al, 1991). In a multicentral study conducted in the USA, between 1991 and 1995, Walton found the prevalence of chondral injuries in 31,516 knee arthroscopies to be 19,827 (63 %). A total of 53,569 hyaline cartilage lesions were found during these 19,827 arthroscopies, an average of 2.7 lesions per knee. The average age of the patient with lesions was 43 years. More male than female patients had lesions (61.6 and 38.4 percent, respectively). The lesions consisted of osteochondritis dissecans (0.7 %), articular fractures (1.3 %), grade I lesions (9.7 %), grade II lesions (28.1 %), grade III lesions (41.0 %), and grade IV lesions (19.2 %). Grade III lesions were the most common in patients over 30 years of age. The most common locations for grade III lesions were patella and medial femoral condyle. The medial femoral condyle was the most common location for single grade IV lesions. The patella and lateral femoral condyle were the next two most common sites (Walton et al, 1997).

1.12 Grading of articular cartilage lesions

Although there are several different classification systems for the description of articular cartilage damage, each has certain limitations and deficiencies that can lead to confusion (Noyes and Stabler, 1989). Some systems combine the surface appearance of the articular cartilage lesion and the depth of involvement under a single description category, and then make no distinction as to the depth of involvement (Noyes and Stabler, 1989). According to the Outerbridge classification Grade II and III are identical in appearance (fragmentation and fissuring). The classification does not specify the extent of involvement from surface to bone in either stage. Rather, the distinction between the grades is based on the diameter of involvement (Noyes and Stabler, 1989). In the classification system of Bentley there is no category reserved for lesions with an intact surface. Furthermore, grades I, II and III all described as fibrillation or fissuring, and the distinction between grades is based on the area of damage (Noyes and Stabler, 1989). Ficat and Hangerford distinguished between closed (grade I) and open (grade II) lesions, but do not separate lesions within each category according to severity. Grade I describes varying degrees of softening from simple to pitting oedema. Grade II distinguishes between fissures and ulcerations, but either can be superficial and localized or can extend to subchondral bone (Noyes and Stabler, 1989). The classification systems of Casscells and Insall both describe lesions that become more extensive as one moves from grade I to grade IV. Casscell's system makes no allowance for a lesion without surface changes (Noyes and Stabler, 1989). Insall's system is problematic because the specification for grade II (Fissuring) and grade III (fibrillation) are somewhat qualitative and may or may not be applied similarly by observers (Noyes and Stabler, 1989). Although according to Noyes and Stabler (1989) Goodfellow differentiates between surface degeneration and basilar degeneration, the terms fasciculation I, blister, and fasciculation II, under the general category of basilar degeneration, can cause some confusion. Most other authors seem to use the term fasciculation when referring to disruption of an intact surface (Noyes and Stabler, 1989).

1.12.1 Outerbridge classification

The Outerbridge classification system (Outerbridge, 1961) was originally designed to classify chondromalacia patellae. Over the years it has been extrapolated for use in

classifying chondral lesions throughout the body (Noyes et al, 1977). The accuracy and reproducibility of this classification system was addressed by Cameron et al, (2003) when they determined the intraobserver reliability, interobserver reproducibility and the accuracy of the system for grading chondral lesions in knees viewed arthroscopically. They compared the results obtained by using the system with observations at arthrotomy of six cadaveric donors. The accuracy rate ranged from 22 to 100 percent, with lower grade lesions diagnosed with less accuracy than higher-grade lesions (Cameron et al, 2003). The Outerbridge grading system is given in table.1 and figure 4.

1.12.2 International Cartilage Repair Society (ICRS) classification

This system classifies Hyaline cartilage lesion after debridement of loose bodies, and defines a lesion as a superficial, partial thickness, or full thickness defect (Brittberg and Winalski, 2003). The ICRS classification system focuses on the lesion depth (graded 0 to 4) and the area of damage (graded from normal to severely abnormal with use of the IKDC system) (www.cartilage.org).

Figure 5 shows the ICRS system. This classifies macroscopically normal cartilage without a notable defect as ICRS 0. If the cartilage has an intact surface but fibrillation and/or slight softening is present, it is classified as ICRS 1a, and if additional superficial lacerations and fissures are found, it is classified as ICRS 1b (nearly normal). Defects that extend deeper but involve less than 50 percent of the cartilage thickness are classified as ICRS 2 (abnormal). Lesions that extend to more than 50 percent of the cartilage thickness are classified as ICRS 3 (severely abnormal). However, there are four subgroups of this grade: 3a, 3b, 3c, and 3d depending on the involvement of a calcified layer. Joint trauma may create cartilage defect that extend into the subchondral bone. These full thickness osteochondral injuries are classified as ICRS 4 (severely abnormal). Excluded from this grade are defects that are classified as osteochondritis dissecans (OCD), which have a classification system of their own (Brittberg and Winalski, 2003).

Grade	Surface description	Lesion diameter
I	Softening and swelling	None
II	Fragmentation and fissuring	Less than half inch
III	Fragmentation and fissuring	More than half inch
IV	Exposed subchondral bone	None

Table 1. Outerbridge grading system

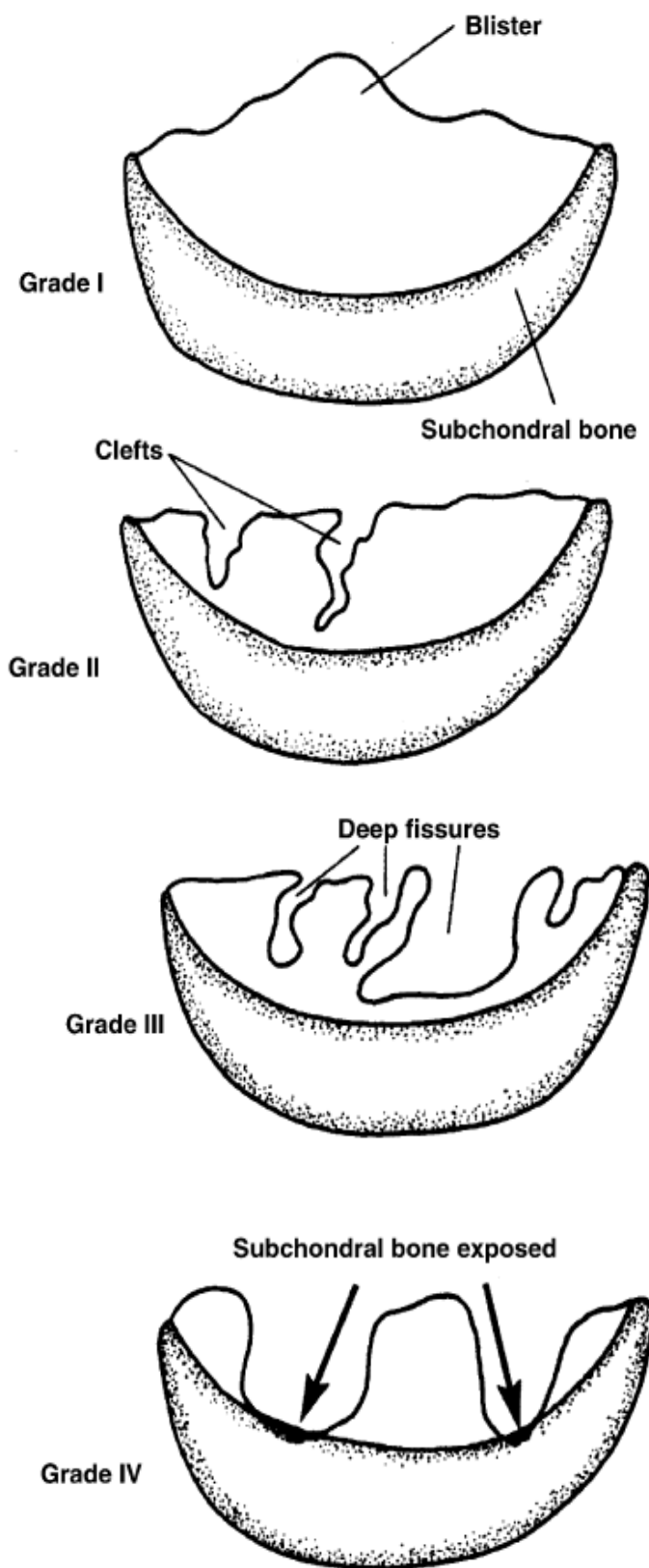



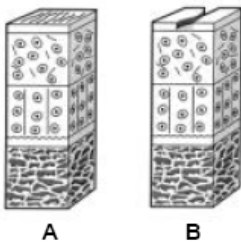
Fig. 4. Outerbridge system for grading chondral defects (Kocheta and Tomes, 2004)

ICRS Grade 0 - Normal



ICRS Grade 1 – Nearly Normal

Superficial lesions. Soft indentation (A) and/or superficial fissures and cracks (B)



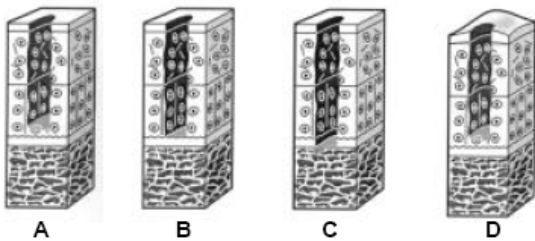
ICRS Grade 2 – Abnormal

Lesions extending down to <50% of cartilage depth

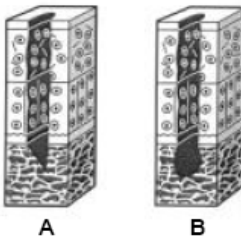


ICRS Grade 3 – Severely Abnormal

Cartilage defects extending down >50% of cartilage depth (A) as well as down to calcified layer (B) and down to but not through the subchondral bone (C). Blisters are included in this Grade (D)



ICRS Grade 4 – Severely Abnormal



Copyright © ICRS

Fig. 5. ICRS classification (www.cartilage.org)

2. Diagnosis of articular surface damage

The clinical diagnosis of a chondral injury by history and physical examination can be difficult, and may be a source of confusion (Speer et al, 1991).

The initial symptoms of this injury are often obscure, and the immediate disability may be slight. The symptoms are very suggestive of a torn meniscus because of catching, locking, and giving way of the knee (Gilley, 1981; cited by Speer et al, 1991). An accurate diagnosis of traumatic articular cartilage injury is essential as individuals with these lesions have a poor prognosis for rapid recovery. Their mean rehabilitation time is almost triple that of a routine knee meniscal injury (Speer et al, 1991).

2.1 Conventional radiographic technique

Conventional radiographic techniques have proved to be of limited value in the imaging of articular cartilage as such techniques only allows the indirect assessment of cartilage (Lund, 1980; cited by Recht et al, 1993). Plain radiographs, in general, significantly underestimate the extent of cartilage damage (Blackburn et al, 1994). However, plain X-ray may reveal osteochondral lesions, including osteochondritis dissecans and loose bodies (Morelli et al, 2002).

Scintigraphy and computerized tomographic evaluations are limited because of their lack of sensitivity and requirement for ionizing radiation (Blackburn et al, 1994). Computed tomography combined with arthrography improves both the visualization of cartilage and the detection of abnormalities, but this method is relatively insensitive in the delineation of small cartilage lesions (Handelberg et al, 1990). Bone scans may indicate osteochondral injuries, but is not specific and does not necessarily indicate pure chondral lesions or their size (Morelli, et al. 2002).

2.2 Arthroscopy

The most accurate diagnostic modality for traumatic knee articular cartilage injury is arthroscopy (DeHaven, 1980). However, even with this “Gold Standard” modality the posterior tibial and femoral lesions can be difficult to identify and may be missed (Terry, 1988; cited by Speer 1991). Although arthroscopy treatment can be performed on a chondral fracture discovered unexpectedly, it would be advantageous to know before arthroscopy whether a chondral injury is present. The surgeon then could advise the patient before surgery about treatment options and expected outcome, and decide on the type and timing of surgery (Rubin, 1998).

2.3 Magnetic resonance imaging

The MR imaging appearance of chondral fractures is analogous to their arthroscopic appearance (Rubin et al, 1997). Chondral separations manifest as a defect in the articular surface extending down to the subchondral plate, with vertically oriented walls and sharp demarcation from the surrounding cartilage. When a flap is present a fragment will be seen, attached on one side (Rubin et al, 1997). Lesion conspicuity can be increased by performing MR arthrography, especially if the patient is examined some time after the acute insult (Rubin, 1998). The presence of a joint effusion could alleviate the need for iatrogenic introduction of intra-articular contrast agents. The theory is that this would offer an

“arthrogram” effect, and allow indirect visualization of chondral lesions as well (Beltran, 1980; Spritzer 1988; cited by Speer 1991).

In a comparison study between MR and anatomic section Hodler et al (1992) concluded that standard MRI does not consistently allow detection of focal articular cartilage defects. Commonly used MRI sequences are not reliable enough to be effective in the diagnostic evaluation of degenerative changes of articular cartilage.

2.4 Can MRI replace arthroscopy in diagnosis?

The role of MRI for the diagnosis of chondral lesions of the knee joint is still unclear, and the sensitivity of the method ranges from 15 to 96 percent (Friemert et al, 2003). In a prospective study by Friemert et al (2003) of how MRI can replace arthroscopy in the routine diagnosis of cartilage damage, they found that the MRI cartilage specific sequences have a sensitivity of 33 percent and specificity of 99 percent and positive and negative prediction values of 75 and 98 percent respectively. With gadolinium enhanced MRI the sensitivity was 53 percent and the specificity was 98 percent. The positive prediction value was 48 percent and the negative prediction value was 98 percent. They concluded that the MRI examination techniques recommended in the literature are not able to replace arthroscopy for the diagnosis of cartilage damage of the knee joint, and in view of the high specificity (97 to 98 %) MRI is suitable for identifying cartilage lesions. In view of the low sensitivity of MRI to cartilage injury, a cautious attitude towards an operative cartilage treatment is justified. Because that MRI can not replace arthroscopy for the diagnosis of cartilage damage and so arthroscopy still has to be seen as the method of choice for the evaluation of cartilage damage (Friemert et al, 2003).

2.5 Best MRI sequences to visualize articular cartilage

Currently the most widely used techniques for articular cartilage imaging by MR are fat suppressed proton-density weighted fast spin-echo sequences, and fat suppressed spoiled gradient recalled echo (SPGR) sequences (Kornaat et al, 2005). SPGR sequences are often chosen for cartilage volume and thickness estimation because the 3D acquisition, along with higher intensity cartilage signal, provides robust visualization of cartilage and detection of cartilage pathology. However, new MR imaging pulse sequences, specifically steady-state free precession (SSFP), have recently attracted attention for their optimal visualization of cartilage. The new sequences give greater cartilage intensity, increased cartilage and contrast-to-noise ratio and reduced imaging time than conventional pulse sequences (Kornaat et al, 2005).

2.6 Comparison between 3-D SPGR and conventional MR imaging

Fat suppressed 3-D spoiled gradient recalled acquisition in the steady state (SPGR) MRI technique was compared with 2-D SPGR images and conventional T1 and T2 weighted spin-echo and multiplanar by Disler et al (1994). They studied ten healthy volunteers and concluded that fat-suppressed 3-D SPGR imaging is an improvement over fat-suppressed spin-echo imaging because the fluid signal is diminished relative to cartilage. As the sequence essentially suppresses all stationary tissue, it is not useful in evaluating the fibrocartilage, ligaments or soft tissues of the knee. However the technique shows cartilage as an object of high signal intensity relative to adjacent tissues, giving the technique great potential for evaluating this structure.

2.7 Advantages of 3-D SPGR

Fat-suppressed 3-D SPGR imaging has several advantages over conventional sequences. It generates positive contrast between cartilage and adjacent structures, making joint infusion unnecessary to show the cartilage margin (Kornaat et al, 2005).

Fat-suppression maximizes the contrast between cartilage and adjacent marrow, an improvement over T2-weighted spin-echo imaging, and minimizes chemical-shift artifact. Three-dimensional acquisition can generate very thin slices without loss of information.

In summary, fat-suppressed 3-D SPGR imaging of the knee provides a striking positive contrast between hyaline cartilage and adjacent structures, and may improve the accuracy of MR diagnosis of hyaline cartilage abnormalities (Disler et al, 1994).

The sensitivity of fat-suppressed 3-D SPGR imaging was compared with that of standard MR imaging for detecting hyaline cartilage defects of the knee, using arthroscopy as the standard of reference. Disler et al (1994) assessed 114 consecutive patients for hyaline cartilage defects of the knee with both standard MR imaging sequences and a sagittal fat-suppressed 3-D SPGR sequences. Forty eight patients with meniscal or ligament injury or persistent symptoms underwent subsequent arthroscopy. The standard MR and SPGR images of these 48 patients were then retrospectively analyzed for articular defects in a blinded fashion by two independent observers. Sensitivity, specificity, and intra-observer and inter-observer agreement were determined for the different imaging techniques. A quarter of the patients who went on to arthroscopy were found to have isolated hyaline cartilage lesions. The SPGR imaging sequences had a significantly higher sensitivity than the standard MR imaging sequences for detecting hyaline cartilage defects (75 to 85 % and 29 to 38 % respectively, $p < 0.001$, for each component). Significant differences in sensitivity were found for each surface except the trochlear and lateral tibial surfaces. No difference in specificity were found (97 % and 97 % respectively, $p > 0.99$). Combined evaluation of standard MR and SPGR images gave no added diagnostic advantage (sensitivity 86 %; specificity 97 %; $p > 0.42$). Except for the lateral tibial surface, reproducibility among readings and between readers was excellent. The conclusion from the study was that fat-suppressed 3-D SPGR imaging is more sensitive than standard MR imaging for the detection of hyaline cartilage defects of the knee (Disler et al, 1996). In day-to-day practice a routine clinical MRI scan has low sensitivity in diagnosing chondral damage when compared with arthroscopic findings (Bobic, 2005).

Levy et al (1996) reported that preoperative MRI scans correctly identified 21 percent of the chondral lesions seen at arthroscopic examination. However, since 1996 the new awareness of the significance of chondral problems, due to extensive laboratory and clinical research, and various attempts to repair hyaline articular surface, has resulted in an increased interest in magnetic resonance imaging as a diagnostic and evaluation tool (Bobic, 2005).

Development of refined MRI techniques and recent advantages in MRI technology appear to be very promising. Magnetic resonance imaging has the potential to replace the more conventional invasive techniques, like arthroscopy and biopsy, in the evaluation of articular cartilage damage and repair (Bobic, 2005).

2.8 Significant of focal subchondral oedema

Rubin et al (2000) retrospectively reviewed the MR studies of 18 knees with arthroscopically proven acute articular cartilage defects, noting the associated subchondral oedema.

Subchondral oedema was defined as the focal region of high signal intensity in the bone immediately underlying an articular surface defect on a T2 weighted or short inversion time inversion recovery (STIR) images. In their study the subchondral oedema was found to be associated with chondral surface defects in 83 % (Observer 1) and 72 % (observer 2) of subjects. Focal subchondral oedema is commonly visible on MR images of treatable, traumatic chondral lesions in the knee. This MR finding may prove to be an important clue to assist in the detection of these traumatic chondral defects (Rubin et al, 2000). They postulate three possible mechanisms for the generation of this marrow oedema: the injury to the subchondral bone can (1) precede the articular cartilage injury, (2) occur at the same time as the cartilage injury, or (3) follow the cartilage injury. Support for the first possibility comes from animal studies of experimentally created chondral injuries that show injury to the overlaying cartilage by several weeks (Radin et al, 1973 and 1984; cited by Rubin et al, 2000). Marrow oedema shown on MR images is thought to reflect the initial injury to the overlaying cartilage by several weeks (Thompson et al, 1993; cited by Rubin et al, 2000). The support for the second possibility is that the initial force responsible for the cartilage fracture produces a transient depression of the articular surface that is transmitted to the subchondral plate. In this instance, the subchondral marrow oedema would represent a direct contusion, or true bone "bruise". The support for the third hypothesis is that the initial insult produces a cartilage defect large enough to expose the underlying bone to direct compression against the opposing articular surface once joint loading recommences (Minas et al, 1997; cited by Rubin et al, 2000).

Characteristic subchondral oedema revealed on fat-suppressed STIR images may alert the radiologist to the presence of a defect in the overlaying chondral surface that otherwise may have been overlooked (Rubin et al, 2000).

3. Treatment of articular surface lesions

Articular cartilage injuries are notorious for their inability to produce a healing response. The management of symptomatic lesions must take into consideration several patient factors before initiating a long-term treatment plan. Most, if not all, patients should have a trial of nonoperative measures in an attempt to alleviate symptoms (Morelli et al, 2002). Patients' not responding to treatment should be considered for surgical management (Morelli et al, 2002). Although a rapid development of diagnostic and therapeutic methods of articular cartilage lesions has been made, a problem of choosing the best treatment still persists. Isolated, particularly symptomatic, deep chondral lesions seem to be problematic (Widuchowski et al, 2007).

Experimental studies have shown that variations in the treatment of articular cartilage lesions can restore some form of cartilaginous articular surface, but formation or transplantation of cartilaginous tissue in an animal model does not prove that a given method has the potential to relieve joint symptoms, or improve joint function in humans (Buckwalter, 1999). The effort to restore cartilaginous articular surfaces has now reached the point where investigators should evaluate the results of experimental methods to restore cartilaginous articular surfaces, and identify the most promising approaches to the solution of clinical problems (Buckwalter, 1999). Important issues concerning the experimental models include the types of articular surface defects studied, the age of the animal, and differences in articular cartilage among species. Important considerations in assessing the outcome of procedures designed to restore an articular surface include the overall function

of the animal or patient, the function of the joint, the structure of the joint, and the structure, composition and mechanical properties of the new tissue (Buckwalter, 1999). This approach to evaluating methods of restoring a cartilaginous articular surface assumes that the goal of any of these methods is to provide sustained improved joint function, and decrease joint symptoms in people with traumatic or degenerative joint damage. Tissues that differ from normal articular cartilage may achieve this goal (Buckwalter, 1999).

There are several choices for the treatment of articular cartilage defects. For the last few years new techniques that aim to reestablish hyaline cartilage have been introduced. They include the use of cultured cells, bone mesenchymal stem cells, as well as tissue engineering (Morcacci et al, 2002). On the other hand, there are papers suggesting that minimum invasive, simple method, or even willful negligence of a surgical treatment, might also be effective in achieving good function of the joint (Morcacci et al, 2002). Messner and Maletius (1996) showed that without treatment 22 of the 28 patients had good to excellent function 14 years after surgery. Another study, Shelbourne et al (2003), showed that at ten years follow-up there was no significant difference between the outcomes of patients with ACL-associated untreated cartilage injury and patients with no cartilage injury. It is suggested that in certain conditions conservative treatment of cartilage defects should be also considered (Aroen et al, 1998).

During the last decade, novel surgical techniques have been introduced and the mid-to long-term functional results of those procedures are awaited (Morelli et al, 2002).

3.1 Objectives of treatment

The main objective of any treatment regimen is pain modulation, with secondary objective consisting of the restoration of joint function. Non-operative treatment attempts to achieve these goals, yet long-term follow-up reveal decreased objective knee function scores whilst patients' subjective scores remain favorable (Messner and Maletius, 1996).

3.2 Indications of operative treatment

Operative management should be considered for patients who present with symptomatic partial thickness or deep chondral lesions, and for patients with intact osteochondral fragments, as commonly encountered in the skeletally immature and young adult. In the decision-making process of any treatment option, several factors must be taken into consideration, including defect size and location, acuteness of injury, age, desired activity level, alignment, arthritis, joint stability, and severity of symptoms (Minas, 2000).

3.3 Nonoperative treatment

3.3.1 Physiotherapy

The goal of physiotherapy is to reduce swelling and maintain or improve knee function by focusing on quadriceps and hamstring strengthening. It may prove beneficial in the prevention and treatment of associated morbid conditions such as joint stiffness and patellofemoral symptoms subsequent to surgery or injury (Morelli et al, 2002).

3.3.2 Nonsteroidal anti-inflammatory drugs (NSAIDs)

NSAIDs act by inhibition of prostaglandin synthesis and thereby function as modulators of pain and inflammation. Earlier works suggest that some NSAIDs may actually promote cartilage degeneration and progression to arthritis by its inhibitory action on proteoglycan synthesis (Brandt, 1991).

3.3.3 Intraarticular viscosupplementation and oral supplements


Some preliminary studies suggest that hyaluronic acid, glucosamine, and chondroitine sulfate may have beneficial effects on articular cartilage. Hyaluronan appears to have two effects in the short-term: pain modulation and improved clinical function in early arthritis, and a reduction in the size of the chondral lesions (Evanich et al, 2001; Rolf et al, 2005). Similar results have been reported in trials using glucosamine, chondroitin sulfate, and manganese ascorbate. Glucosamine appears to exert its action by stimulating glycosaminoglycan synthesis, whereas chondroitin sulfate and manganese ascorbate inhibit protease activity thereby delaying progression of cartilage degeneration (Lippiello et al, 2000). However, before definitive conclusion can be drawn with respect to these substances, large-scale randomized controlled trials are warranted.

4. Reference

- Aroen A., Deryk G., Jones DG. and Fu FH. (1998). Arthroscopic diagnosis and treatment of cartilage injuries. *Sports Med. Arthrosc. Rev.* 6: 31-40.
- Blackburn WD., Berneuter WK. and Rominger M. (1994). Arthroscopic evaluation of the knee articular cartilage: A comparison with plain radiograph and magnetic resonance imaging. *J. Rheumatol.* 21: 675-679.
- Bobic V. (2005). Magnetic resonance imaging of articular cartilage defects and repair. *Int. Soc. Arth. Knee Surg. Orth. Current concepts*. Published on line 7th June (www.isakos.com).
- Brandt KD. (1991). Mechanism of action of non-steroidal anti-inflammatory drugs. *Rheumatol Suppl.* 27: 120-121.
- Brittberg M. and Winalski CS. (2003). Evaluation of cartilage injuries and repair. *J. of Bone and joint surgery Am.* 85A: 58-68.
- Buckwalter JA. (1999). Evaluation methods of restoring cartilaginous articular surfaces. *Clin Orthop Relat Res.* 367 suppl: 224-238.
- Buckwalter JA. And Lane NE. (1996). Aging, sports and osteoarthritis. *Sports Med. Arth. Rev.* 4: 276-287.
- Buckwalter JA. and Mow VC. (2003). Basic science and injury of articular cartilage, menisci, and bone. *Orthopaedic sports medicine principles and practice*, second edition. pp: 67-87.
- Buckwalter JA., Rosenberge LC., Coutts R., Hunziker E., Reddi AH. and Mow VC. (1988). Articular cartilage: Injury and repair. *Am Academy of Orthopaedic Surgeons*. pp: 465-482.
- Buckwalter JA., Woo SL-Y., Goldberg VM., Hadley EC., Booth F., Oegma TR. And Eyre DR. (1993). Soft tissue aging and musculoskeletal function. *J. Bone Joint Surg. (Am).* 75A: 1533-1548.
- Cameron ML., Briggs KK. and Steadman JR., (2003). Reproducibility and reliability of the Outerbridge classification for grading chondral lesions of the knee arthroscopically. *Am J Sport Med.* 31: 83-86.
- Chen FS., Frenkel SR., and DiCesare PE. (1999). Repair of articular cartilage defects: Basic science of cartilage healing. *Am J Ortho.* 28: 31-33.
- DeHaven KE, (1980). Diagnosis of acute knee injuries with haemarthrosis. *Am. J. Sports Med.* 8: 9-14.

- Disler DG., McCauley TR., Kelman CG., Fuchs MD., Ratner LM., Wirth CR. and Hospodar PP. (1996). Fat-suppressed three-dimensional spoiled gradient-echo MR imaging of hyaline cartilage defects in the knee. *Am J Radol.* 167: 127-132.
- Disler DG., Peters TL., Muscoreil LM., Wagle WA., Cousins JP. And Rifkin MD. (1994). Fat-suppressed spoiled GRASS imaging of knee hyaline cartilage: technique optimization and comparison with conventional MR imaging. *Am. J. Radol.* 163: 887-892.
- Evanich JD., Evanich CJ., Wright MB. and Rydlewicz, JA. (2001). Efficacy of intraarticular hyaluronic acid injections in knee osteoarthritis. *J. Clin Ortho.* 390: 173-181.
- Felson DT., Lawrence RC. and Dieppe PA. (2000). Osteoarthritis: new insight. Part I: the disease and its risk factors. *J. Ann Intern Med.* 8: 635-646.
- Friemert B., Oberlander Y., Schwarz W., Habele HJ., Baren W., Gerngrob H. and Danz B. (2003). Diagnosis of chondral lesions of the knee joint: Can MRI replace arthroscopy?. *Knee Surg. sports Traum. Arthro.* Published on line 5th August. (www.ingentaconnect.com).
- Gillquist J., Hagberg G., Oretrop N. (1977). Arthroscopy in acute injuries of the knee joint. *Acta Ortho Scand.* 48: 190-196.
- Guilak F., Sah R. and Setton LA. (1997). Physical regulation of cartilage metabolism. *Basic Orthopaedic Biomechanics*. Second edition. pp: 179-207.
- Handelberg F., Shahapour M. and Casteleyn P. (1990). Chondral lesion of patella evaluated with computed tomography, magnetic resonance imaging and arthroscopy. *J. Arthroscopy.* 6: 24-29.
- Hayes DW., Brower RL., and John KJ. (2001). Articular cartilage anatomy, injury, and repair. *J. Clin Pod. Med. Surg.* 18: 35-53.
- Hjelle K., Solheim E., Strand T., Muri R. and Brittberg M. (2002). Articular cartilage defects in 1,000 knee arthroscopies. *J. Arthroscopy and related Surg.* 18: 730-734.
- Hodler J., Berthiaume MJ. and Resnick D. (1992). Knee joint hyaline cartilage defects: a comparative study of MR and Anatomic sections. *J Comp. Ass. Tom.* 16: 597-603.
- Kornaat PR., Reeder SB., Koo S., Brittain JH., Yu H., Andriacchi TP. and Gold GE. (2005). MR imaging of articular cartilage at 1.5 T and 3.0 T: Comparison of SPGR and SSFP sequences. *J. Osteo. and Cart.* 13: 338-344.
- Levy A., Lohnes J., Sculley S., LeCroy M. and Garrett W. (1996). Chondral delamination of the knee in soccer players. *Am. J. Sports Med.* 24(5): 634-639.
- Lippiello L., Woodward J., Karpman R., and Hammad TA., (2000). In vivo chondroprotection and metabolic synergy of glucosamine and chondroitin sulfate. *J. Clin. Orthop.* 381: 229-240.
- Mankin HJ., Mow VC. and Buckwalter JA. (2005b). Articular cartilage repair and osteoarthritis. *Am. Acad. Orth. Surg. Orthopedic Basic Science*. Ch 18:471-488.
- Mankin HJ., Mow VC., Buckwalter JA., Iannotti JP. and Ratcliffe A. (2005a). Articular cartilage structure, composition, and function. *Am. Acad. Orth. Surg. Orthopedic Basic Science*. Ch 17: 443 - 469.
- Marieb EN. (1992). *Joints. Human anatomy and physiology*. 2nd Edition. The Benjamin/Cummings Publishing Company, Inc. pp. 222-245.
- Messner K. and Maletius W. (1996). The long term prognosis for sever damage to weight-bearing cartilage in the knee: A 14 years clinical and radiographic follow-up in 28 young athletes. *J. Acta Orth . Scand.* 67: 165-168.

- Minas T. (2000). A practical algorithm for cartilage repair. *Op. Tech. Sports Med. J.* 8: 141-143.
- Morcacci M., Zaffagnini S., Kon E., Visani A., Iacono F. and Loreti I., (2002). Arthroscopic autologous chondrocyte transplantation: technical note. *J. Knee Surg. Sports Traumatol. Arthrosc.* 10: 154-159.
- Morelli M., Nagamori J. and Miniaci A. (2002). Articular lesions in the knee: evaluation and treatment options. *Curr Opin in Ortho. J.* 13: 155-161.
- Morelli M., Nagamori J. and Miniaci A. (2002). Articular lesions in the knee: evaluation and treatment options. *Curr Opin in Ortho. J.* 13: 155-161.
- Noyes FR., Bassett FW. and Grood ES. (1980). Arthroscopy in acute traumatic haemarthrosis of the knee. *J. Bone Joint Surg (Am).* 62A: 687-696.
- Noyes FR., Grood ES. and Nussbaum NS. (1977). Effect of intraarticular corticosteroids on ligament properties: a biomechanical and histological study in Rhesus knees. *J. Clin. Orthop.* 123: 197-207.
- Oegema TR. and Thompson RC. (1986). Metabolism of chondrocytes derived from normal and osteoarthritic human cartilage. *Articular Cartilage Biochemistry*. NY, Raven press. pp: 257-271.
- Pearle AD., Warren RF. and Rodeo SA. (2005). Basic science of articular cartilage and osteoarthritis. *J. Clin Sports Med.* 24: 1-12.
- Recht MP., Kramer J. and Marcelis S. (1993). Abnormalities of articular cartilage in the knee: Analysis of available MR techniques. *J. Radiol.* 187: 473-478.
- Rolf CG., Engstrom B., Ohrvik J., Valentin A., Lilja B. and Levin, DW. (2005). A comparative study of the efficacy and safety of Hyaluronan Viscosupplements and placebo in patients with symptomatic and arthroscopy-verified cartilage pathology. *J. Clin. Res.* 8: 15-32.
- Rubin DA. (1998). Magnetic resonance imaging of chondral and osteochondral injuries. *J. Topics. Mag. Res. Imag.* 9: 348-359.
- Rubin DA., Harner CD. and Costello JM. (1997). Chondral fractures in the knee: MR imaging diagnosis without cartilage specific pulse sequences. *J Radiol.* 205: 364.
- Rubin DA., Harner CD. and Costello JM. (2000). Treatable chondral injuries in the knee: Frequency of associated focal subchondral edema. *Am. J. Radiol.* 175: 1099-1106.
- Shelbourne KD., Jari S. and Gray T. (2003). Outcome of untreated traumatic articular defects of the knee: A natural history study. *J. Bone Joint Surg. (Am).* 85: 8-16.
- Soltz MA. and Ateshian GA. (2000). Interstitial fluid pressurization during confined compression cyclical loading of articular cartilage. *Ann. Biomed. Eng.* 2: 150-159.
- Speer KP., Spritzer CE., Goldner JL. and Garrett WE. (1991). Magnetic resonance imaging of traumatic knee articular cartilage injuries. *Am. J. Sports Med.* 19: 396-402.
- Walton W., Jonathan K., Stanly G., Julia R., Beth PS. and Gary GP. (1997). Cartilage injuries: A review of 31,516 knee arthroscopies. *J. Arthroscopy.* 13: 456-460.
- Widuchowski W., Widuchowski J. and Trazaska T. (2007). Articular cartilage defects: study of 25,124 knee arthroscopies. *Knee J.* 14(3): 177-182.
- Williams L. and Wilkins I. (1998). Articular cartilage: injuries and potential for healing. *J. of Ortho. sports Therapy.* 28: 192-202.



Modern Arthroscopy

Edited by Dr Jason L. Dragoo

ISBN 978-953-307-771-0

Hard cover, 302 pages

Publisher InTech

Published online 09, December, 2011

Published in print edition December, 2011

Modern Arthroscopy will assist practitioners to stay current in the rapidly changing field of arthroscopic surgery. The chapters in this book were written by a panel of international experts in the various disciplines of arthroscopy. The goals of this text are to present the classical techniques and teachings in the fields of Orthopaedics and Dentistry, but also to include new, cutting-edge applications of arthroscopy, such as temporomandibular arthroscopy and extra-articular arthroscopy of the knee, just to name a few. We hope Modern Arthroscopy becomes a core reference for your arthroscopic surgery practice.

How to reference

In order to correctly reference this scholarly work, feel free to copy and paste the following:

Masoud Riyami (2011). Traumatic Chondral Lesions of the Knee Diagnosis and Treatment, Modern Arthroscopy, Dr Jason L. Dragoo (Ed.), ISBN: 978-953-307-771-0, InTech, Available from: <http://www.intechopen.com/books/modern-arthroscopy/traumatic-chondral-lesions-of-the-knee-diagnosis-and-treatment>

INTech
open science | open minds

InTech Europe

University Campus STeP Ri
Slavka Krautzeka 83/A
51000 Rijeka, Croatia
Phone: +385 (51) 770 447
Fax: +385 (51) 686 166
www.intechopen.com

InTech China

Unit 405, Office Block, Hotel Equatorial Shanghai
No.65, Yan An Road (West), Shanghai, 200040, China
中国上海市延安西路65号上海国际贵都大饭店办公楼405单元
Phone: +86-21-62489820
Fax: +86-21-62489821

© 2011 The Author(s). Licensee IntechOpen. This is an open access article distributed under the terms of the [Creative Commons Attribution 3.0 License](https://creativecommons.org/licenses/by/3.0/), which permits unrestricted use, distribution, and reproduction in any medium, provided the original work is properly cited.

IntechOpen

IntechOpen