

We are IntechOpen, the world's leading publisher of Open Access books Built by scientists, for scientists

6,900

Open access books available

185,000

International authors and editors

200M

Downloads

Our authors are among the

154

Countries delivered to

TOP 1%

most cited scientists

12.2%

Contributors from top 500 universities



WEB OF SCIENCE™

Selection of our books indexed in the Book Citation Index
in Web of Science™ Core Collection (BKCI)

Interested in publishing with us?
Contact book.department@intechopen.com

Numbers displayed above are based on latest data collected.
For more information visit www.intechopen.com



Arthroscopic Treatment of Recurrent Anterior Glenohumeral Instability

Michael Hantes and Alexandros Tsarouhas
*Orthopaedic Department, University Hospital of Larissa
 Greece*

1. Introduction

The glenohumeral joint achieves the greatest mobility compared with all other joints in the human body. Due to its complex anatomy, its stability is conferred by a combination of bone, soft tissue and muscular structures. It is therefore the most commonly dislocated joint, with an overall incidence of approximately 17/100.000 per year (Kroner et al, 1989). The classification of shoulder instability is complex, depending on the cause (traumatic vs. atraumatic), degree (dislocation, subluxation, or microinstability), direction (anterior, posterior, inferior or multidirectional), and chronology (acute, chronic, or acute on chronic). Traumatic glenohumeral instability is defined as occurring after an inciting event that results in subjective or objective subluxation or dislocation that is reduced either spontaneously or by a health professional (Cadet, 2010). Atraumatic instability occurs as the sequel of generalized ligamentous laxity or repetitive motion, as in overhead throwing athletes. Inferior and multidirectional instabilities are less common than anterior and posterior ones and have been described to combine the presence of a sulcus sign or inferior subluxation of the humeral head with symptoms of pain or instability (Neer & Foster, 1980). Anterior shoulder instability accounts for 95% of acute traumatic dislocations. Although many patients who suffer an initial shoulder dislocation never experience a second episode of instability, a significant percentage present with recurrent instability that results in morbidity and decreased functionality in respect to the demands placed on the joint during everyday, occupational and athletic activities.

2. Anatomy and biomechanics of the glenohumeral joint

Both static structures and dynamic stabilizers of the glenohumeral joint interact to produce stability. Static stabilizers include the bony anatomy, labrum, capsule, glenohumeral ligaments and rotator interval. Dynamic stabilizers include the rotator cuff, long head of the biceps, deltoid and scapular muscles. Negative pressure within the joint also contributes to stability by producing the “suction cup effect”, which helps center the humeral head independently of muscular forces and is primarily important in the midrange, where the capsule and ligaments are not under tension.

The bony anatomy of the glenohumeral joint also plays a significant role in stability. The glenoid is more concave in the superoinferior than the anteroposterior direction. In addition, the articular cartilage is thicker towards the periphery of the glenoid, thus increasing the

depth of the concavity. Because the size of the glenoid is limited compared with the humeral head, even a relatively small bone loss may reduce considerably the surface area for articulation and consequently compromise stability. A bone loss that exceeds 20% of the glenoid surface is considered critical for the recurrence of instability (Burkhart & De Beer, 2000; Tauber et al, 2004).

The labrum is a fibrocartilaginous structure attached to the glenoid rim. It functions to increase the anteroposterior and superoinferior depth of the glenoid and the surface contact area for the humeral head. Specifically, it increases the concavity of the glenoid up to 9mm in the superior-inferior direction and the anteroposterior depth to 5mm (Howell et al, 1988). Labral resection reduces resistance to translation by 20% (Lippitt & Matsen, 1993). The labrum also provides an attachment site for the glenohumeral ligaments. Two types of labral attachments to the glenoid have been described. The first, around the periphery through a fibrocartilaginous transition zone, which creates mobility along the central border similar to the knee meniscus. The second is securely attached both peripherally and centrally. The anteroinferior attachment of the labrum to the glenoid is normally tight. On the contrary, the superior attachment inserts directly into the biceps tendon distal to the insertion on the supraglenoid tubercle, it is loose and anatomically variant. Isolated lesions of the superior labrum do not result in instability. However, if the biceps insertion is also destabilized, significant translation occurs (Pagnani et al, 1995).

The glenohumeral capsuloligamentous system provides a restraint to excessive translation in varying positions of the joint. In particular, the anterior band of the inferior glenohumeral ligament (AIGHL) attaches to the anteroinferior labrum and primarily resists anteroinferior translation in the abducted externally rotated shoulder position.

The rotator cuff compresses the humeral head into the glenoid throughout the range of motion. An association between undersurface rotator cuff tears and instability has been described (Jobe & Bradley, 1989). The rotator interval (RI), between the leading edge of the supraspinatus and the superior edge of the subscapularis, has also been implicated in glenohumeral instability. Closure of a large defect in the RI has been shown to decrease inferior instability. There may be an inverse relationship between the size of the RI and the superior glenohumeral ligament (SGHL) contributing to the instability (Nobuhara & Ikeda, 1987).

3. Natural history of anterior instability

The natural history of anterior shoulder instability has been studied extensively and recurrence has been correlated with a younger age at the time of first dislocation. In a large cohort of 255 patients with primary traumatic anterior dislocation, who were treated with a sling for 4 weeks, there was a 55% incidence of an additional episode of instability within 2 years of the initial traumatic dislocation. Furthermore, 66% of the patients had an episode of instability within 5 years (Robinson et al, 2006). In another study, 324 shoulders were followed for at least 10 years after primary anterior dislocation. Ninety-four percent of the patients younger than 20 years had a recurrence compared with 14% of those older than 40 years. The patients without shoulder immobilization had a 70% recurrence rate that decreased to 26% to 46% when immobilized for 1 to 3 weeks (Rowe, 1956). These findings suggest that younger patients with primary anterior dislocations have a significantly higher rate of recurrence.

The effectiveness of rehabilitation is still in debate. In a study evaluating the effect of rehabilitation, 115 patients with traumatic and atraumatic recurrent shoulder subluxation,

underwent a muscle-strengthening exercise regimen (Burkhead & Rockwood, 1992). Sixteen percent of the shoulders with traumatic etiology had excellent or good results in contrast to 80% of those with atraumatic etiology. The authors highlighted the importance of identifying the etiology of instability to ascertain a successful result out of conservative treatment. In a prospective randomized clinical trial, active patients aged less than 30 years who were treated with supervised physical therapy showed recurrence rates of 17 to 96% whereas arthroscopic instability repair had failure rates between 4% and 22% (Bottoni et al, 2002). These findings indicate that young, highly active patients would benefit from early, arthroscopic repair after first-time traumatic anterior shoulder dislocation compared with conventional nonoperative treatment.

4. Type of associated pathology

A **Bankart lesion** is the commonest sequel of an anterior dislocation and the main cause of instability. It is defined as a labral complex avulsion from the scapular periosteum. It usually includes some degree of capsular stretch and injury. When the lesion involves a fracture of the antero-inferior glenoid rim in addition to the soft tissue avulsion it is referred to as **bony Bankart** (Fig 1).

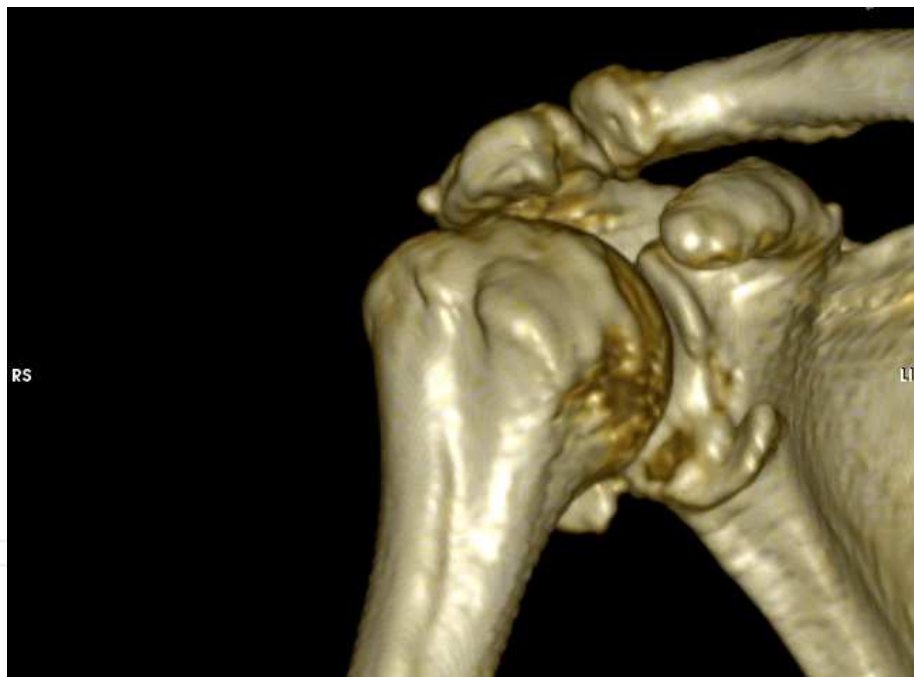

Fig. 1. A three-dimensional reconstruction CT-image demonstrating a bony-Bankart lesion.

Humeral avulsion of glenohumeral ligaments (HAGL) occurs when the capsuloligamentous structures are avulsed and torn off the humeral head and not the glenoid. An external rotation force in addition to hyperabduction commonly results in this lesion in contrast to a hyperabduction and impaction force that may produce a Bankart lesion (Matsen et al, 2006). The incidence of HAGL lesions after a traumatic dislocation has been reported at 39% (Bokor et al, 1999). A bony HAGL lesion occurs when the glenohumeral ligament is avulsed along with a bone fragment of the humeral head (Oberlander et al, 1996).

Anterior labral periosteal sleeve avulsion (ALPSA) is a soft-tissue or bony Bankart lesion that has healed in a medially displaced position on the glenoid rim and therefore, does not restrain adequately the anterior translation of the humeral head (Fig 2). In this case, the avulsed periosteum has not ruptured, causing medial and inferior displacement of the labroligamentous structures (Neviaser, 1993).

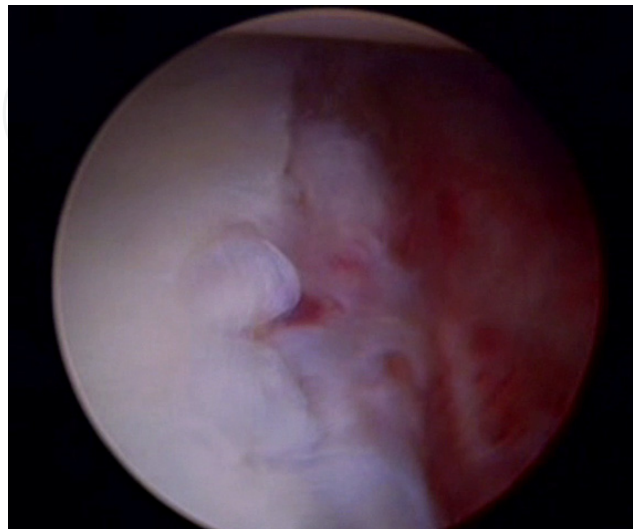


Fig. 2. An ALPSA lesion as seen from the anterosuperior arthroscopic portal. The labrum and periosteum have been avulsed and displaced medially.

A **Perthes lesion** is an incomplete avulsion without displacement of the antero-inferior labrum with a medially striped but intact periosteum.

Glenoid labral articular disruption (GLAD) lesion occurs when there is a defect in the articular cartilage of the anteroinferior glenoid in addition to the labral tear. The torn labrum is usually not fully detached from the glenoid and therefore, the predominant symptom in this case is not instability but pain.

A **Hill-Sachs lesion** is an impression fracture at the posterosuperior aspect of the humeral head that results from its impact on the glenoid rim when the humeral head dislocates anteriorly (Fig 3). They occur at 47 to 80% of anterior dislocations and in almost all cases of recurrent instability. If the posterolateral humeral head engages the anterior glenoid when abducted and externally rotated the Hill-Sachs lesion is defined as engaging (Burkhart & De Beer, 2000). The size and location of the defect mainly determine the likelihood of engagement. Although usually insignificant, in patients with glenoid bone loss a Hill-Sachs lesion can become more significant and engage the glenoid with much less force and anterior translation than those without glenoid bone loss.

A **superior labrum anterior posterior (SLAP)** lesion includes a spectrum of pathologic conditions of the superior labrum that may extend to the biceps root (Fig 4). Classification of these lesions was extended by Maffet et al to include 7 subtypes (Table 1). Type II tears are the commonest in most large series. On average, 40% of patients with Bankart lesions have an additional type II SLAP lesion (Hantes et al, 2009). SLAP lesions have been associated with glenohumeral stability. Forty-three percent of patients with SLAP lesions were found to have increased humeral head translation on examination under anesthesia (Maffet et al, 1995).

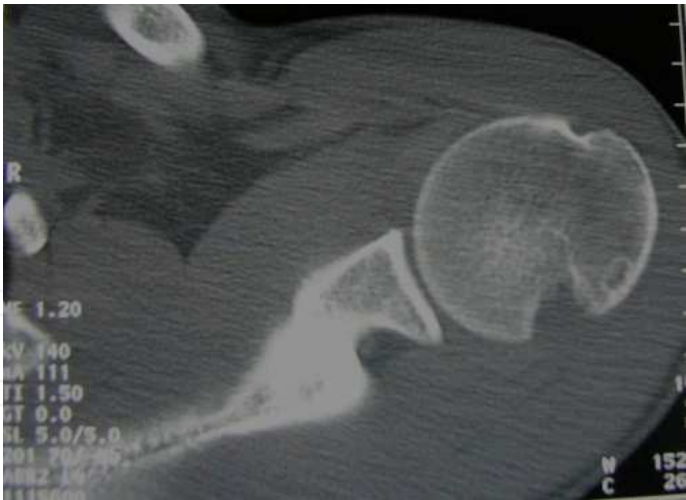


Fig. 3. A transverse plane CT image demonstrating a large Hill-Sachs lesion of the humeral head.

| | |
|--------|---|
| Type 1 | Fraying of the anterosuperior labrum |
| Type 2 | Superior labrum-biceps complex detachment from glenoid rim |
| Type 3 | Bucket-handle tear of the labrum with an intact biceps anchor |
| Type 4 | Bucket-handle tear of the labrum with detachment of the biceps complex |
| Type 5 | Bankart lesion continues superiorly and includes separation of the biceps complex |
| Type 6 | Unstable flap tear of the labrum with an unstable biceps complex insertion |
| Type 7 | Labrum-biceps complex separation extending beneath the middle glenohumeral ligament |

Table 1. Maffet classification of SLAP lesions (modified Snyder).

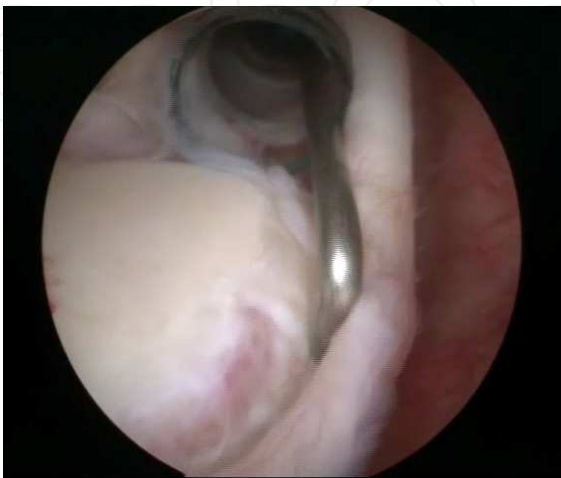

Fig. 4. A type II SLAP lesion as seen during arthroscopy.

5. Evaluation and decision-making

5.1 Patient history

The examiner should obtain a thorough history, which should offer information regarding symptoms, type and direction of instability, age and time elapsed from the initial dislocation, number of instability episodes, need for medical assistance for reduction versus self-reduction, activity level and prior treatment.

The provocative position for dislocation is indicative of the direction of instability. Patients with anterior traumatic instability generally describe the event occurring with the arm in the abducted, extended and externally rotated position. Patients who do not recall a specific dislocation event may have pathologic instability due to generalized ligamentous laxity. Pain may also be associated with instability. For example, overhead-throwing athletes with anterior instability may complain of pain due to repetitive stress on the anteroinferior capsulolabral complex.

Patients who present with a long history of recurrent instability episodes, high-energy trauma leading to dislocation, a progressive ease of symptoms or demonstrate instability in the midrange of motion should be meticulously evaluated for glenohumeral bone deficiencies. The ability to voluntarily dislocate the shoulder should be thoroughly examined because it may be attributed to psychological factors and, secondly, is generally associated with increased rates of recurrence after surgery. Similarly, patients with multiple dislocation events or whose shoulders slip out with limited force (during sleep or when reaching overhead) may have a significant glenohumeral bone defect or other pathology, such as multidirectional laxity or glenoid hypoplasia. Therefore, they would necessitate a different surgical plan. Finally, the degree of disability and loss of functionality should be thoroughly evaluated as part of decision making.

5.2 Physical examination

Both shoulders are exposed for visual inspection and comparative examination. Testing for range of motion and overall muscle strength, and neurovascular examination are performed. The opposite shoulder and other joints are examined to assess the degree of ligamentous laxity normally present in any individual. Clinical tests for glenohumeral laxity and provocative or instability tests are the hallmarks in the physical examination of an unstable shoulder.

Examination for glenohumeral laxity includes the anterior and posterior drawer, and the anterior and posterior load and shift tests, which quantitate the amount of anterior and posterior humeral head translation respectively. The Gagey hyperabduction test is used to measure the laxity of the inferior glenohumeral ligament complex. The sulcus sign also evaluates glenohumeral laxity at the inferior direction when an inferior stress is applied with the arm in adduction and both neutral and 30° external rotation. It is important for the surgeon to discern between pathologic shoulder instability and normal laxity. Instability is generally described as symptomatic laxity, which requires the patients subjectively experiencing the shoulder subluxating or recalling a frank dislocation event. On the contrary, laxity is the normal translation between the components of the glenohumeral joint to achieve full normal range of motion (Bigliani et al, 1996).

Testing for instability includes the apprehension-relocation, and the anterior release and surprise tests. The apprehension test is positive when the patient experiences pain and has a subjective feeling of the arm dislocating when the shoulder is progressively moved to abduction and external rotation. It is especially important to determine the ease with which the shoulder begins to dislocate and engage on the glenoid. If this occurs even with limited

external rotation it is highly likely that there exists an engaging hill-Sachs lesion or osseous glenoid defect. Similarly, patients with engaging Hill-Sachs lesions report episodes of instability in the midrange of shoulder abduction and external rotation.

5.3 Imaging

Routine radiographic imaging of the shoulder should include a true anteroposterior, axillary and scapular-Y views. Hill-Sachs lesions can be best appreciated on the anteroposterior view in internal rotation and the notch view (Hall et al, 1959). Avulsion fractures and glenoid bone deficiencies can be visualized with the Velpeau or West point axillary views (Rokous et al, 1972).

Advanced imaging has offered an improved ability to evaluate soft tissue lesions as well as glenohumeral deficiencies following shoulder dislocation. MRI has become the gold standard in evaluating glenohumeral instability demonstrating a high accuracy for detecting labral tears using noncontrast, enhanced imaging techniques (Ng et al, 2009). MR arthrography, however, has been found to present the highest sensitivity in detecting labral pathology compared with plain MRI and CT arthrography (Chandnani et al, 1993). It also achieved the best visualization of the inferior glenohumeral ligament and labrum. Both MRI and MR arthrography can also be helpful in evaluating bone loss. However, recently volume-rendering three-dimensional CT scans have offered a highly accurate method of measuring glenoid deficiencies and Hill-Sachs lesions. The humeral head can be digitally subtracted to allow for preoperative measurement of the inferior glenoid surface and the percentage of bone missing (Fig 5). Glenoid bone defects occur along a line parallel to its long axis. The inferior two thirds of the glenoid have been described as a well-conserved circle and the amount of bone missing is assessed in respect to surface area loss of the circle. Glenoid bone loss of between 6 to 8 mm of the anteroposterior diameter corresponds to 20-25% of the surface of the inferior glenoid. In a similar fashion, the extent and morphology of a Hill-Sachs lesion can be evaluated to assess the degree of engagement.

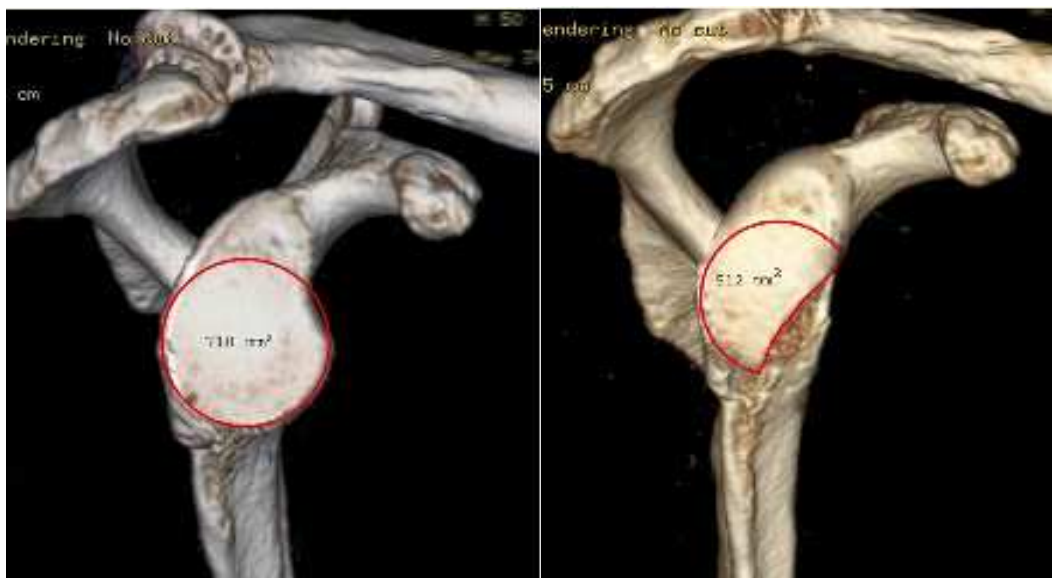


Fig. 5. Volume-rendering 3D reconstructed image of a cadaveric shoulder before (left image) and after (right image) artificially creating a glenoid bone defect. The surface area of the inferior glenoid is being measured.

6. History of the procedure

Bankart lesions, which are most commonly seen after recurrent shoulder dislocations, were first described in 1923 as “shearing of the fibrous capsule of the joint from its attachment to the fibro-cartilaginous glenoid ligament”. For decades, open repair of Bankart lesions was considered the gold standard, with success rates reaching up to 97% (Rowe et al, 1978).

Arthroscopic techniques for the repair of these lesions were not introduced until 1982, when Johnson first described the arthroscopic use of staples as a modification of the open procedure (Johnson, 1980). However, this technique produced unacceptably high rates of recurrence along with hardware loosening or migration, which subsequently limited its use. Transosseous sutures for arthroscopic Bankart repair were introduced in 1987 (Morgan & Bodenstab, 1987). The sutures were passed through the scapular neck, exited posteriorly and were tied over the posterior fascia. Although excellent results were reported originally, they were not confirmed by follow-up studies. Disadvantages of this technique included the need for knot tying over the posterior fascia and the risk of iatrogenic injury to the suprascapular nerve. Removable arthroscopic rivets and absorbable cannulated bio-tacks have also been used with promising results but without gaining wide popularity.

Suture anchors present the latest technological advance in arthroscopic shoulder instability repair. They were first introduced in 1993 (Wolf, 1993). The advantages of their use include multiple points of fixation, no posterior glenoid penetration and increased pullout strength, which in the case of later-generation suture anchors is comparable to transosseous suture fixation. Suture anchors traditionally used for labral repairs are either push-in or screw-in anchors.

Each anchor commercially available is unique with regard to its pull-out strength, type of suture, retrievability, bioabsorbability, insertion technique and cost. The ideal characteristics include strength and sturdiness at the time of insertion, fixation strength and safe biologic replacement of the glenoid as the anchor resorbs. Various types of suture anchors are currently available, including metal, bioabsorbable, and bioinert. Metallic anchors have raised concerns of migration or potentially complicating revision surgery. Absorbable anchors were developed later, but concerns remain regarding bone giant cell reaction during the dissolving process. An additional concern is raised by the friction of the sliding knots, which may increase the temperature adjacent to the eyelet of most anchors currently available, and consequently compromise fixation.

7. Arthroscopic or open treatment?

Recent advances in suture technology and instrumentation and increasing surgeon experience have broadened the application of all-arthroscopic shoulder stabilization techniques. Open surgical procedures were thought to restrict external rotation and lead to secondary osteoarthritis. Additional disadvantages included wide surgical dissection and scarring. On the contrary, arthroscopic procedures were associated with reduced post-operative pain, earlier rehabilitation and less restriction of movement (Green & Christensen, 1993). Shoulder arthroscopy also provides improved articular visualization intra-operatively and allows for the preservation of the subscapularis.

Although initial results from comparison studies between arthroscopic and open procedures indicated significantly higher rates of recurrence (13%-70% compared with

0%-30% respectively), improvements in patient selection and operative technique have steadily decreased recurrence rates to match that of open procedures (Geiger et al, 1997; Roberts et al, 1999; Fabbriciani et al, 2004). In a systematic meta-analysis, which included 62 studies and 3044 arthroscopic operations, no difference was found in failure rates between open and arthroscopic treatment of anterior shoulder instability with suture anchors or bio-absorbable tacks. On the contrary, there was a higher rate of failure compared with open techniques when staples or transglenoid sutures were used arthroscopically (Hobby et al, 2007).

However, data from prospective randomized trials are still limited. Fabbriciani et al found no difference between open and arthroscopic repair of isolated Bankart lesions in a group of 60 patients at 2-year follow-up (Fabbriciani et al, 2004). Similarly, Bottoni et al found no differences in functional scores and recurrence rates between open and arthroscopic techniques for isolated anterior instability repair. However, a trend was established towards improved external rotation and forward flexion as well as significantly reduced operative time in the group of arthroscopic repair. The authors concluded that the latter was equivalent to the open surgical technique for anterior shoulder instability repair (Bottoni et al, 2006).

8. Suture anchor surgical technique for anterior shoulder instability repair

8.1 Examination under anaesthesia

A meticulous examination under anaesthesia should be performed in all cases before arthroscopy. A sensitivity of 100% and specificity of 93% have been found for this examination as confirmed by the actual arthroscopic findings (Cofield et al, 1993). The examination should be performed either in the supine or beach chair positions. Passive range of motion is recorded first with the arm at the side and 90° of abduction. With the arm abducted at 90°, posterior and anterior forces are applied to provoke translation of the humeral head in relation to the glenoid. A sulcus sign is tested in adduction and external rotation, and also at 45° abduction that tightens the inferior capsule. Persistent sulcus sign in both positions is abnormal and indicative of rotator interval pathology.

8.2 Patient positioning

The patient can be positioned in either the lateral decubitus or beach chair positions, which is mainly based on surgeon preference. The beach chair position affords several advantages including the ease to address concomitant rotator cuff pathology and the ability to convert to open surgery if necessary. However, it is often easier to address the pathology at the anteroinferior capsulolabral complex with the patient in the lateral decubitus position, because it provides a wider distension of the glenohumeral joint (Fig 6). The arm is usually placed at 45° abduction and traction is applied both in the axial and lateral directions. One of the disadvantages of this patient setup is the difficulty to achieve rotational control during the repair. For example, subscapularis repair and rotator interval closure are best performed in 30° to 45° of external rotation, which cannot be easily done at the lateral position.

8.3 Instrumentation

Basic equipment for shoulder arthroscopy includes a tower containing a video monitor, control box, light source, shaver power and electrocautery source, and irrigation pump. A

30-degree arthroscope is usually adequate for most arthroscopic procedures in the shoulder. Fluid pressure within the joint should be kept around 30mmHg and may increase up to 70mmHg for viewing the subacromial space. Maintaining a systolic arterial pressure below 100mmHg improves visualization. Increased fluid pressure or flow may cause extravasation of fluid into the surrounding soft tissue, distort the anatomy intra-operatively and increase morbidity postoperatively.

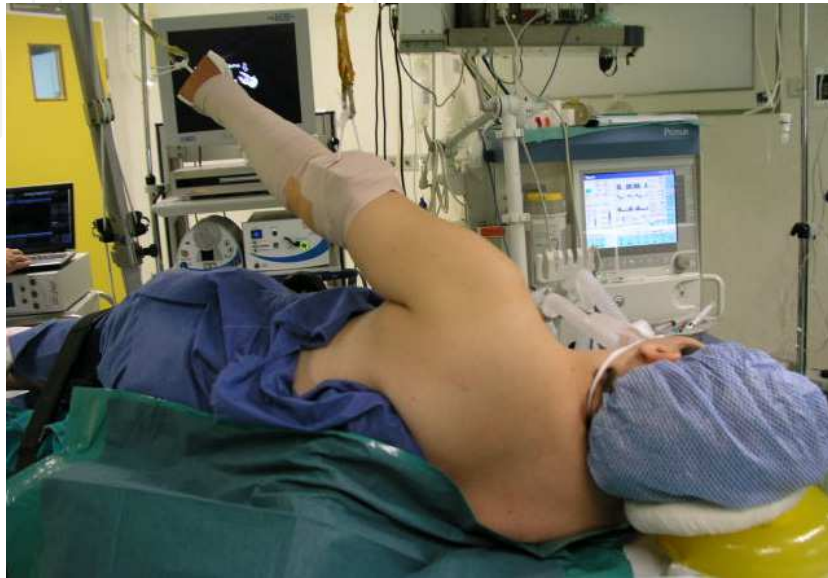

Fig. 6. Lateral decubitus setup for arthroscopic instability repair. Axial and lateral traction is applied with the arm at approximately 45° abduction.

8.4 Arthroscopic portals

Initially, a standard posterior portal is used for diagnostic arthroscopy. It can be created in line with the lateral edge of the acromion and 1cm inferior to its posterior tip to have an improved trajectory in relation to the glenoid. This portal is used for diagnostic glenohumeral arthroscopy and to localize the pathology to be addressed. An anterior-superior portal is then created with an inside-out or outside-in technique between the biceps tendon and superior edge of the subscapularis. This portal is used for mobilization of the capsulolabral complex and for subsequent suture management. It is always advisable to assess the intra-articular pathology through the anterior-superior portal as well, to better evaluate the extent of labral tear posteriorly or glenoid bone loss and avoid missing a possible ALPSA lesion. A second anterior-inferior portal is placed just above the superior edge of the subscapularis to allow for inferior placement of suture anchors on the lower aspect of the glenoid neck. Both anterior portals are created within the rotator interval and there should ideally be enough skin bridge between them (2-3cm) to allow for easier handling of arthroscopic instruments (Fig 7). Alternative portals have been described, such as a transsubscapularis portal described by Davidson and Tibone or a 7-o-clock posteroinferior portal for accessing the most inferior aspect of the glenoid.

Working cannulas are inserted into the two working portals to facilitate instrumentation handling. A wider (8mm) cannula is preferable for the anterior-inferior portal to allow for curved suture hooks, while a 5.5mm cannula is adequate for the superior portal for grasping instruments to be inserted.

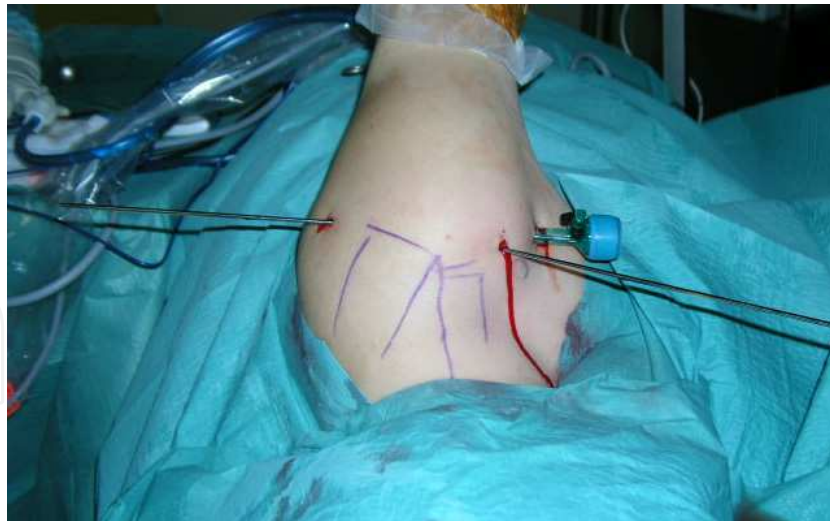

Fig. 7. Typical posterior, anterior-superior and anterior-inferior portals for arthroscopic anterior instability repair. A working cannula is inserted in the anterior-inferior and Wissinger rods in the remaining two portals.

8.5 Glenoid and labrum preparation

Assessment of the mobility of the capsuloligamentous complex is crucial to determine if the soft tissues have been displaced or are scarred in a medial position on the neck of the glenoid. A combination of probes, rasps, motorized shavers and periosteal elevators are used to mobilize the medially displaced soft tissues from the glenoid neck. Care must be taken not to debride normal tissue needed for the repair. During this step, the subscapularis muscle must be visualized underneath the mobilized labral tissue. It is recommended to release tissue inferiorly to the 6 o'clock position on the glenoid face for optimal mobilization. Attention is then turned towards the glenoid. An abradar or rasp is used to decorticate the glenoid edge while preserving the bone stock. It is important to ensure that the soft tissue remnants have been removed and there is a bleeding bed of bone at the repair site to enhance healing.

8.6 Suture anchor placement

A hole is created along the anterior and anteroinferior articular margin and the anchors are inserted below the articular surface. Accurate positioning of the anchors is critical to restore the depth of the glenoid. Ideally, the anchors are placed at 45° angle relative to the glenoid surface, perpendicular to the superior-inferior axis, and 2 to 3 mm inside the anterior glenoid rim (Fig 8). Eight to 10 mm intervals between the anchor holes are considered to limit the stress risers for more secure fixation (Abrams, 2007).

Glenoid anchors are commonly smaller than those used in rotator cuff repair because bone quality is usually better. Our current preference in our department is 2.8mm, absorbable, screw-in anchors loaded with permanent, reinforced braided sutures.

The number and positioning of suture anchors used across the glenoid rim is still controversial. A standard arthroscopic Bankart repair typically requires three anchors. Others however have suggested the routine use of four anchors, because a three-anchor configuration was associated with increased failure rates (Boileau et al, 2006). Typically, the anchors are placed below the 3 o'clock position beginning inferiorly and then progressing superiorly. In general, it is acceptable to insert as many anchors as needed to achieve an adequate restoration of the capsulolabral restraint to anterior humeral head translation.

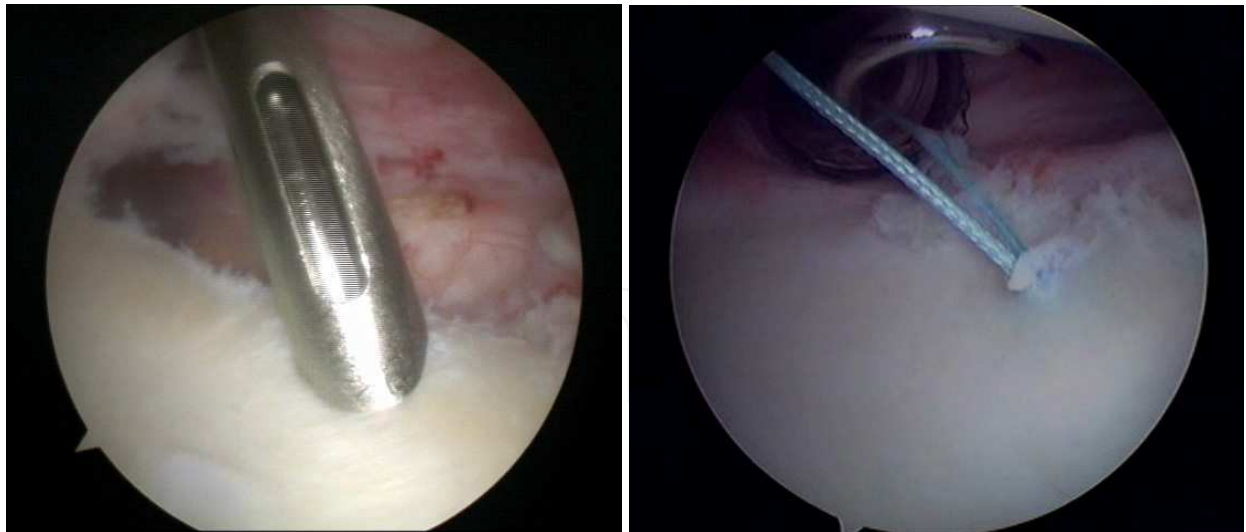


Fig. 8. Correct positioning of the suture anchor drill guide relative to the glenoid (left). The suture anchor has been inserted below the articular cartilage (right) with one arm facing the detached labrum.

Suture management is a challenge for arthroscopists performing reconstructive surgery. The anchors should be properly oriented to prevent unnecessary twists in the suture arms. Single- or double-loaded anchors may be used and should be inserted so that a single arm of the suture is facing the anticipated repair. A soft-tissue penetration device (suture passer or suture hook) is used to facilitate suture passage. We prefer to use a curved Spectrum suture hook (ConMed Linvatec, Largo, FL) and perform two separate passes through the capsule and then under the detached labrum towards the glenoid margin. A suture shuttle or a no1 monofilament suture is advanced through the hook and retrieved through the other working portal. The arm of the braided suture is passed through the eyelet of the shuttle or tied at the end of the monofilament suture and then pulled backwards to incorporate the piece of labrum and capsule (Fig 9). Sliding knots are then preformed and tied using a knot pusher and a knot cutter. The capsulolabral tissue is seen re-approximating the glenoid rim (Fig 10).

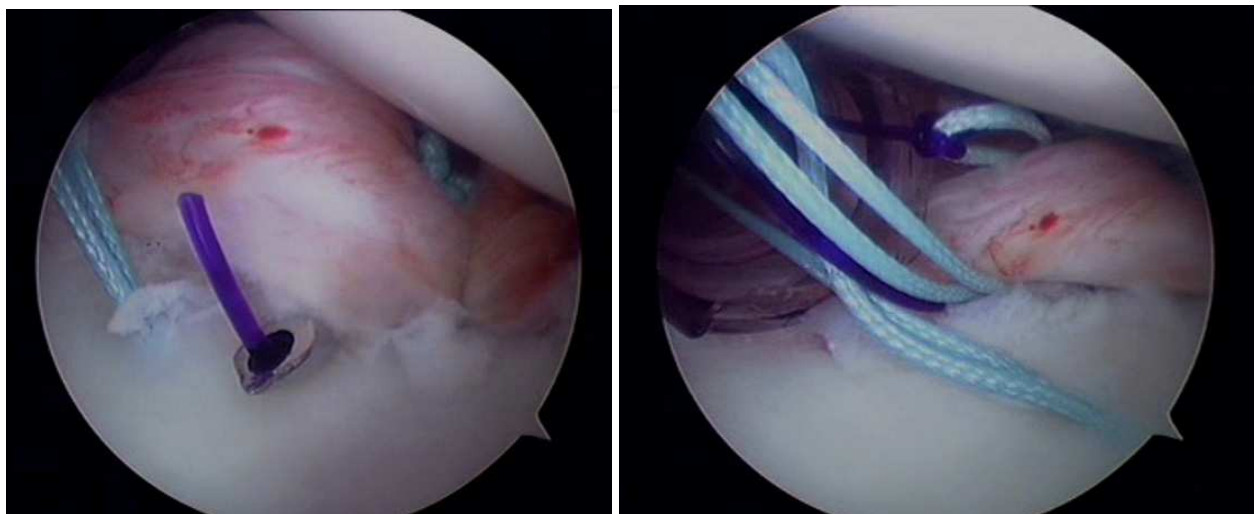


Fig. 9. Using a Spectrum suture hook, a PDS suture is passed (left) and tied (right) to the arm of the braided suture.

Capsular plication is an important aspect of correcting plastic deformation of the capsule. Sutures can be passed using suture hooks and shuttles along the posterior inferior labrum, anterior inferior pouch, and mid anterior capsule to reinforce the capsular thickness in vulnerable areas. These sutures can close defects, reinforce capsule thickness, and obliterate a pouch that developed as a result of capsular stretching. The capsule can be plicated either directly to the labrum or to itself.

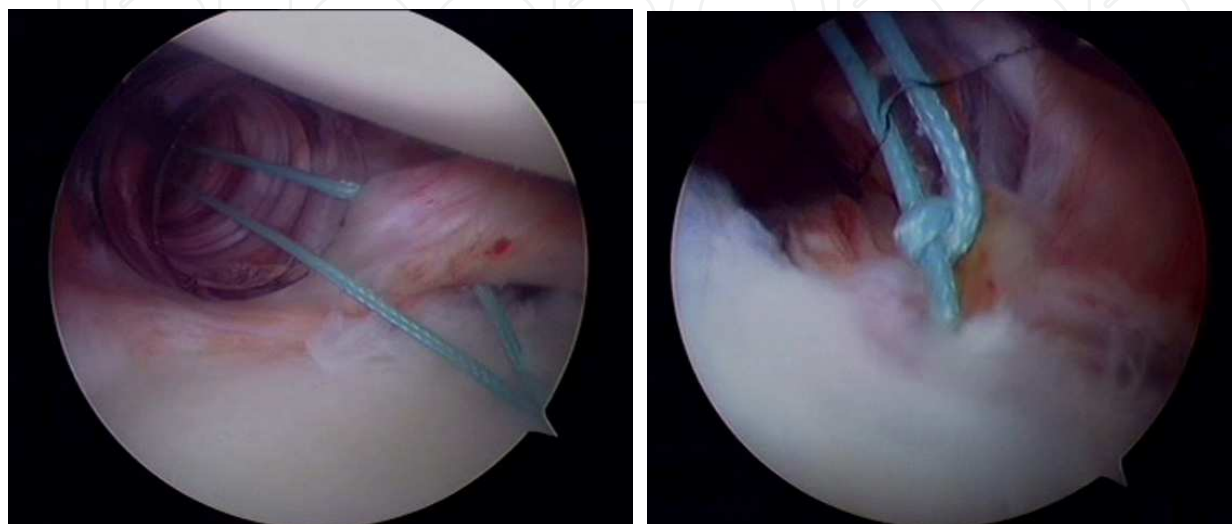


Fig. 10. The arm of the braided suture has been passed through the labrum (left) and a sliding knot is being performed.

Rotator interval closure is advisable when residual inferior translation is evident during the examination under anaesthesia or after Bankart repair. Typical Bankart repair does not require RI closure but may benefit from it. One or two sutures are passed from the middle glenohumeral ligament to the capsule anterior to the biceps tendon and tied. Consequently, the sides of this triangular interval are approximated.

Associated SLAP tears are addressed simultaneously. Typical treatment of these lesions (type II and above) involves the placement of one or two suture anchors to reattach the superior labrum and biceps root to the glenoid rim. An accessory anterior portal is commonly created lateral to the biceps tendon within the rotator interval to provide the optimal approach angle for anchor insertion (Hantes et al. 2009). Alternatively, a trans-rotator cuff portal can be used. When the lesion extends to the posterior labrum a posterolateral acromial (Wilmington) portal is created 1cm anterior and 1cm lateral to the posterolateral edge of the acromion. After debridement of the superior glenoid and labrum, suture anchors are properly placed at the superior margin of the articular cartilage and sutures are tied as described above to restore all avulsed structures.

After all suture anchors are placed, the repair is evaluated from both the posterior and anterior portals (Fig 11). It is a good practice to remove the arm and evaluate the humeral head position and rotation, to best understand the tensioning effect of the repair. The head should appear well centered on the glenoid and any Hill-Sachs lesion should rotate posteriorly. Ideally, this lesion will not come in contact with the articular surface in any position of the shoulder.

8.7 Postoperative management and rehabilitation

Following surgery, the arm is placed in a sling in slight abduction and reduced internal rotation. Passive external rotation is restricted to 0 degrees. Active flexion and extension of the elbow is encouraged. After 3 weeks, the sling is discontinued, forward flexion is increased and external rotation is allowed to 30 degrees. Isotonic rotator cuff and scapular muscles strengthening is initiated after the 6th week. The return to unrestricted activity and full contact sports is determined on an individual basis and usually is not anticipated until 4 to 6 months.

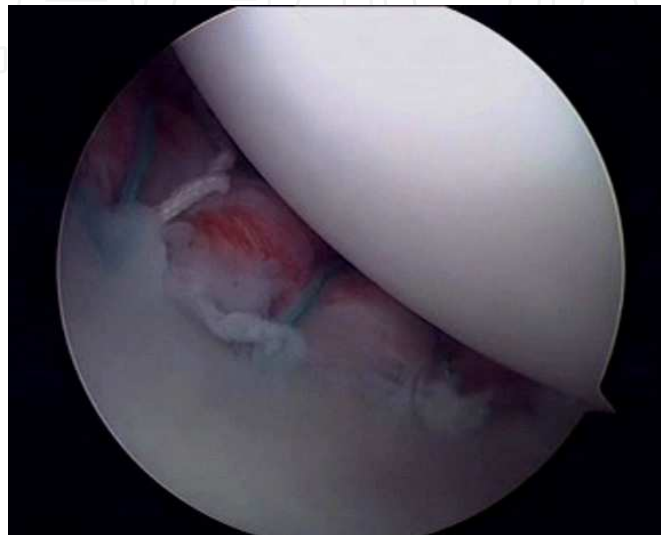

Fig. 11. Final view of the re-approximated capsulolabral complex.

8.8 Complications

The most common complication is the recurrence of instability, which may be attributed to diagnostic and technical errors, or to additional trauma. Misdiagnosis may occur when a significant glenohumeral bone loss is not properly evaluated or a multidirectional component escapes diagnosis. Inadequate capsular tensioning and restoration of the glenoid concavity are the commonest technical errors met. It is therefore crucial to reassess range of motion and humeral head alignment after the repair. In athletes, the risk of recurrence increases with return to sports, since the demands placed on the shoulder are analogous to those that caused the initial injury.

Hardware failure commonly involves misplacement of the suture anchors. Absorbable implants have reduced the occurrence of late anchor displacement and complications during revision surgery. However proper anchor placement is mandatory and a careful evaluation should be performed whenever symptoms appear. Osteopenia along the glenoid rim has been correlated with absorbable anchors along with disuse during the postoperative period.

Nerve injury is not common. Structures at risk, however, include the axillary nerve that lies 1-1.5 cm below the inferior glenohumeral capsule and the musculocutaneous nerve situated 5-8 cm below the coracoid. Manipulation at the extremes of the range of motion should be avoided.

A recent concern after arthroscopic instability repair has been chondrolysis (Levine et al, 2005). Although rare, it is devastating because it often requires additional surgery and

potentially causes permanent deficits. Intra-articular use of thermal devices, articular pain pumps, and local anesthetics within the articular space, as well as increased articular pressure during surgery have been implicated in the pathogenesis of chondrolysis.

9. Contraindications to arthroscopic instability repair

Numerous pathologic conditions have been suggested as contraindications to arthroscopic shoulder instability repair, including capsular attenuation, humeral avulsion of the glenohumeral ligament (HAGL) lesions, failure of previous stabilization, and instability in a collision athlete. However, sizeable glenohumeral bone defects represent the most important contraindication to arthroscopic shoulder stabilization.

9.1 Glenohumeral bone defects

Studies have shown that compression fractures of the posterior superior humeral head (Hill-Sachs lesion) can occur in 32% to 51% of initial anterior dislocations, while anteroinferior glenoid deficiency in 22% of primary dislocations (Rowe et al, 1978; Rowe et al, 1984). The incidence of both glenoid and humeral head bone defects approaches 100% in cases of chronic anterior shoulder instability (Burkhart and De Beer 2000).

A critical decision on shoulder stabilization today focuses on the degree of bone loss and whether soft tissue reconstruction can be successful. Diagnostic pearls for clinical and imaging evaluation of glenohumeral bone defects have been discussed above. Bone defects between 20% and 30% of the inferior glenoid have shown a high recurrence rate after arthroscopic Bankart repair. However, the size and orientation of glenoid and humeral head defects can be extremely variable, making preoperative assessment and decision making difficult. It is currently suggested that patient with glenoid bone deficiency exceeding 20 to 25% of the articular surface should better be treated with a bone-substituting procedure (Provencher et al, 2010).

Bone grafting procedures, such as iliac bone-block or distal tibia transfer, glenoid allograft augmentation and the Bristow procedure have been advocated to restore osseous glenoid defects and shoulder stability. The Latarjet procedure was introduced in 1954. It delineates an osteotomy of the coracoid just proximal to its angle, which comprises the horizontal part of the coracoid and provides a 2 to 3cm bone segment. This is then transferred along with the attached conjoint tendon and the released coracoacromial ligament through a horizontal division of the subscapularis tendon and fixed at the antero-inferior glenoid, preferably with two screws (Fig 12).

The Latarjet procedure has shown excellent and reliable results both in biomechanical testing and the clinical setting. Quantitative Computed Tomography (qCT) has shown this technique to adequately restore a mean defect of up to 28% the intact inferior glenoid (Hantes et al, 2010). Compared with a structural bone graft, it resulted in significantly less anterior and anteroinferior translation at 60° of abduction. Satisfactory clinical results have also been reported with shoulder function ranging from good to excellent with recurrence rates between 0% and 7%. Complications include bony nonunion, graft displacement, progressive impingement and hardware loosening or migration. Improper graft placement, due to lack of experience or surgical exposure, may predispose to recurrent dislocation (when placed too medially or high) or osteoarthritis (too laterally).

Routinely, the Latarjet procedure is performed through a standard deltopectoral approach. However, an all-arthroscopic alternative has been advocated recently as a consequence of the success of the open procedure and the advancements in arthroscopic instrumentation and techniques. This procedure offers the potential advantages of more accurate graft placement, management of associated joint pathology, such as bidirectional shoulder instability, ease of technique conversion, and faster rehabilitation with decreased joint stiffness and better cosmetic result (Lafosse et al, 2010). Although there is inevitably a steep learning curve, excellent results with good graft positioning and minimal complications have also been reported with arthroscopic Latarjet repair.

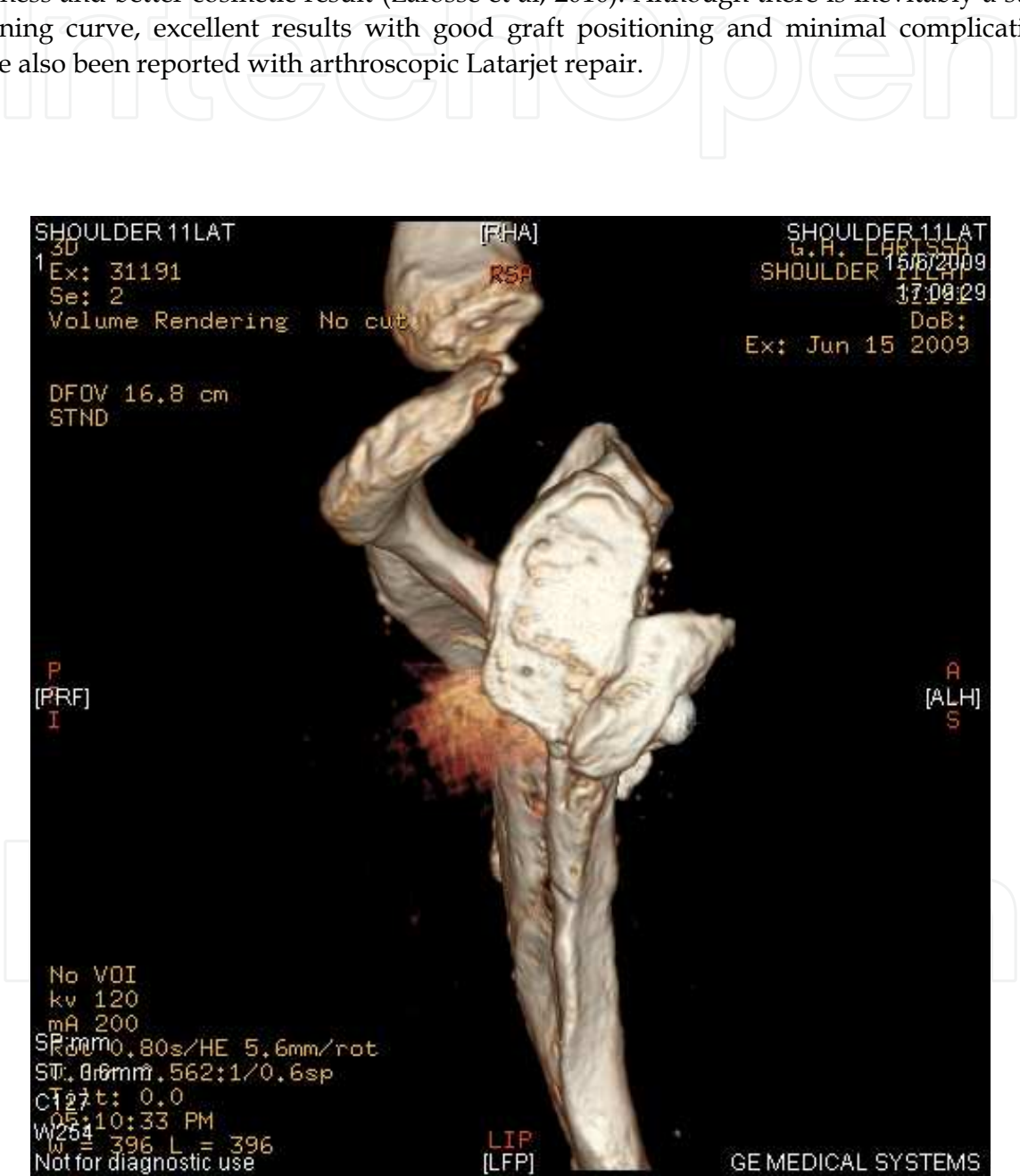


Fig. 12. The Latarjet procedure. Notice how the coracoid process graft supplements the articular surface of the original “inverted pear” glenoid to increase its anteroposterior diameter.

Significant humeral Hill-Sachs lesions also raise concerns on the success of soft-tissue instability repairs. There is a debate on what size humeral head defects require treatment with bony reconstruction. Some authors suggest that defects involving over 12.5% of the humeral head diameter should raise concerns as potentially significant lesions (Kropf et al, 2007). Open allograft humeral head or autograft transfer reconstructions are indicated for the treatment of engaging Hill-Sachs lesions through deltopectoral or mini-open approaches. The Latarjet procedure has also been used successfully in such cases. Recently, an arthroscopic “remplissage” technique was introduced consisting of an arthroscopic capsulotenodesis of the posterior capsule and infraspinatus tendon to fill the Hill-Sachs lesion (Purchase et al, 2008). In light of such progress, glenohumeral bone loss should no longer be considered an absolute contraindication for arthroscopic instability repair.

10. Conclusions

Arthroscopic treatment of shoulder instability has evolved considerably over the past decades. A detailed patient history and thorough physical examination are still considered the milestones for successful treatment planning. Advanced MRI imaging has offered a more accurate diagnosis and improved understanding of the pathology to be addressed. Presently, suture anchor stabilization is the operation that best duplicates the time-tested open procedure. Patient selection criteria, improved surgical techniques and implants available have contributed to the enhancement of clinical and functional outcomes to the point that arthroscopic treatment is considered nowadays the standard of care. However, arthroscopic techniques are demanding and there is a steep learning curve. Bone loss issues, including Hill-Sachs and glenoid rim lesions, remain a concern and a challenge for arthroscopists to manage.

11. References

- Abrams, J. S. (2007). Role of arthroscopy in treating anterior instability of the athlete's shoulder. *Sports Med Arthrosc* 15(4): 230-238.
- Bigliani, L. U., R. Kelkar, et al. (1996). Glenohumeral stability. Biomechanical properties of passive and active stabilizers. *Clin Orthop Relat Res*(330): 13-30.
- Boileau, P., M. Villalba, et al. (2006). Risk factors for recurrence of shoulder instability after arthroscopic Bankart repair. *J Bone Joint Surg Am* 88(8): 1755-1763.
- Bokor, D. J., V. B. Conboy, et al. (1999). Anterior instability of the glenohumeral joint with humeral avulsion of the glenohumeral ligament. A review of 41 cases. *J Bone Joint Surg Br* 81(1): 93-96.
- Bottoni, C. R., E. L. Smith, et al. (2006). Arthroscopic versus open shoulder stabilization for recurrent anterior instability: a prospective randomized clinical trial. *Am J Sports Med* 34(11): 1730-1737.
- Bottoni, C. R., J. H. Wilckens, et al. (2002). A prospective, randomized evaluation of arthroscopic stabilization versus nonoperative treatment in patients with acute, traumatic, first-time shoulder dislocations. *Am J Sports Med* 30(4): 576-580.
- Burkhart, S. S. and J. F. De Beer (2000). Traumatic glenohumeral bone defects and their relationship to failure of arthroscopic Bankart repairs: significance of the inverted-


- pear glenoid and the humeral engaging Hill-Sachs lesion. *Arthroscopy* 16(7): 677-694.
- Burkhead, W. Z., Jr. and C. A. Rockwood, Jr. (1992). Treatment of instability of the shoulder with an exercise program. *J Bone Joint Surg Am* 74(6): 890-896.
- Cadet, E. R. (2010). Evaluation of glenohumeral instability. *Orthop Clin North Am* 41(3): 287-295.
- Chandnani, V. P., T. D. Yeager, et al. (1993). Glenoid labral tears: prospective evaluation with MRI imaging, MR arthrography, and CT arthrography. *AJR Am J Roentgenol* 161(6): 1229-1235.
- Cofield, R. H., J. P. Nessler, et al. (1993). Diagnosis of shoulder instability by examination under anesthesia. *Clin Orthop Relat Res*, (291): 45-53.
- Fabbriciani, C., G. Milano, et al. (2004). Arthroscopic versus open treatment of Bankart lesion of the shoulder: a prospective randomized study. *Arthroscopy* 20(5): 456-462.
- Geiger, D. F., J. A. Hurley, et al. (1997). Results of arthroscopic versus open Bankart suture repair." *Clin Orthop Relat Res* (337): 111-117.
- Green, M. R. and K. P. Christensen (1993). Arthroscopic versus open Bankart procedures: a comparison of early morbidity and complications. *Arthroscopy* 9(4): 371-374.
- Hall, R. H., F. Isaac, et al. (1959). Dislocations of the shoulder with special reference to accompanying small fractures. *J Bone Joint Surg Am* 41-A(3): 489-494.
- Hantes, M. E., A. Venouziou, et al. (2010). Repair of an anteroinferior glenoid defect by the Latarjet procedure: quantitative assessment of the repair by computed tomography. *Arthroscopy* 26(8): 1021-1026.
- Hantes, M. E., A. I. Venouziou, et al. (2009). Arthroscopic repair for chronic anterior shoulder instability: a comparative study between patients with Bankart lesions and patients with combined Bankart and superior labral anterior posterior lesions. *Am J Sports Med* 37(6): 1093-1098.
- Hobby, J., D. Griffin, et al. (2007). Is arthroscopic surgery for stabilisation of chronic shoulder instability as effective as open surgery? A systematic review and meta-analysis of 62 studies including 3044 arthroscopic operations. *J Bone Joint Surg Br* 89(9): 1188-1196.
- Howell, S. M., B. J. Galinat, et al. (1988). Normal and abnormal mechanics of the glenohumeral joint in the horizontal plane. *J Bone Joint Surg Am* 70(2): 227-232.
- Jobe, F. W. and J. P. Bradley (1989). The diagnosis and nonoperative treatment of shoulder injuries in athletes. *Clin Sports Med* 8(3): 419-438.
- Johnson, L. L. (1980). Arthroscopy of the shoulder. *Orthop Clin North Am* 11(2): 197-204.
- Kroner, K., T. Lind, et al. (1989). The epidemiology of shoulder dislocations. *Arch Orthop Trauma Surg* 108(5): 288-290.
- Kropf, E. J., F. P. Tjoumakaris, et al. (2007). Arthroscopic shoulder stabilization: is there ever a need to open? *Arthroscopy* 23(7): 779-784.
- Lafosse, L., S. Boyle, et al. (2010). Arthroscopic Latarjet procedure. *Orthop Clin North Am* 41(3): 393-405.
- Levine, W. N., A. M. Clark, Jr., et al. (2005). Chondrolysis following arthroscopic thermal capsulorrhaphy to treat shoulder instability. A report of two cases. *J Bone Joint Surg Am* 87(3): 616-621.

- Lippitt, S. and F. Matsen (1993). Mechanisms of glenohumeral joint stability. *Clin Orthop Relat Res* (291): 20-28.
- Maffet, M. W., G. M. Gartsman, et al. (1995). Superior labrum-biceps tendon complex lesions of the shoulder. *Am J Sports Med* 23(1): 93-98.
- Matsen, F. A., 3rd, C. Chebli, et al. (2006). Principles for the evaluation and management of shoulder instability. *J Bone Joint Surg Am* 88(3): 648-659.
- Morgan, C. D. and A. B. Bodenstab (1987). Arthroscopic Bankart suture repair: technique and early results. *Arthroscopy* 3(2): 111-122.
- Neer, C. S., 2nd and C. R. Foster (1980). Inferior capsular shift for involuntary inferior and multidirectional instability of the shoulder. A preliminary report. *J Bone Joint Surg Am* 62(6): 897-908.
- Neviaser, T. J. (1993). The anterior labroligamentous periosteal sleeve avulsion lesion: a cause of anterior instability of the shoulder. *Arthroscopy* 9(1): 17-21.
- Ng, A. W., C. M. Chu, et al. (2009). Assessment of capsular laxity in patients with recurrent anterior shoulder dislocation using MRI. *AJR Am J Roentgenol* 192(6): 1690-1695.
- Nobuhara, K. and H. Ikeda (1987). Rotator interval lesion. *Clin Orthop Relat Res* (223): 44-50.
- Oberlander, M. A., B. E. Morgan, et al. (1996). The BHAGL lesion: a new variant of anterior shoulder instability. *Arthroscopy* 12(5): 627-633.
- Pagnani, M. J., X. H. Deng, et al. (1995). Effect of lesions of the superior portion of the glenoid labrum on glenohumeral translation. *J Bone Joint Surg Am* 77(7): 1003-1010.
- Provencher, M. T., S. Bhatia, et al. (2010). Recurrent shoulder instability: current concepts for evaluation and management of glenoid bone loss. *J Bone Joint Surg Am* 92 Suppl 2: 133-151.
- Purchase, R. J., E. M. Wolf, et al. (2008). Hill-sachs "remplissage": an arthroscopic solution for the engaging hill-sachs lesion. *Arthroscopy* 24(6): 723-726.
- Roberts, S. N., D. E. Taylor, et al. (1999). Open and arthroscopic techniques for the treatment of traumatic anterior shoulder instability in Australian rules football players. *J Shoulder Elbow Surg* 8(5): 403-409.
- Robinson, C. M., J. Howes, et al. (2006). Functional outcome and risk of recurrent instability after primary traumatic anterior shoulder dislocation in young patients. *J Bone Joint Surg Am* 88(11): 2326-2336.
- Rokous, J. R., J. A. Feagin, et al. (1972). Modified axillary roentgenogram. A useful adjunct in the diagnosis of recurrent instability of the shoulder. *Clin Orthop Relat Res* 82: 84-86.
- Rowe, C. R. (1956). Prognosis in dislocations of the shoulder. *J Bone Joint Surg Am* 38-A(5): 957-977.
- Rowe, C. R., D. Patel, et al. (1978). The Bankart procedure: a long-term end-result study. *J Bone Joint Surg Am* 60(1): 1-16.
- Rowe, C. R., B. Zarins, et al. (1984). Recurrent anterior dislocation of the shoulder after surgical repair. Apparent causes of failure and treatment. *J Bone Joint Surg Am* 66(2): 159-168.

- Tauber, M., H. Resch, et al. (2004). Reasons for failure after surgical repair of anterior shoulder instability. *J Shoulder Elbow Surg* 13(3): 279-285.
- Wolf, E. M. (1993). Arthroscopic capsulolabral repair using suture anchors. *Orthop Clin North Am* 24(1): 59-69.

IntechOpen

IntechOpen



Modern Arthroscopy

Edited by Dr Jason L. Dragoo

ISBN 978-953-307-771-0

Hard cover, 302 pages

Publisher InTech

Published online 09, December, 2011

Published in print edition December, 2011

Modern Arthroscopy will assist practitioners to stay current in the rapidly changing field of arthroscopic surgery. The chapters in this book were written by a panel of international experts in the various disciplines of arthroscopy. The goals of this text are to present the classical techniques and teachings in the fields of Orthopaedics and Dentistry, but also to include new, cutting-edge applications of arthroscopy, such as temporomandibular arthroscopy and extra-articular arthroscopy of the knee, just to name a few. We hope Modern Arthroscopy becomes a core reference for your arthroscopic surgery practice.

How to reference

In order to correctly reference this scholarly work, feel free to copy and paste the following:

Michael Hantes and Alexandros Tsarouhas (2011). Arthroscopic Treatment of Recurrent Anterior Glenohumeral Instability, Modern Arthroscopy, Dr Jason L. Dragoo (Ed.), ISBN: 978-953-307-771-0, InTech, Available from: <http://www.intechopen.com/books/modern-arthroscopy/arthroscopic-treatment-of-recurrent-anterior-glenohumeral-instability>

INTech
open science | open minds

InTech Europe

University Campus STeP Ri
Slavka Krautzeka 83/A
51000 Rijeka, Croatia
Phone: +385 (51) 770 447
Fax: +385 (51) 686 166
www.intechopen.com

InTech China

Unit 405, Office Block, Hotel Equatorial Shanghai
No.65, Yan An Road (West), Shanghai, 200040, China
中国上海市延安西路65号上海国际贵都大饭店办公楼405单元
Phone: +86-21-62489820
Fax: +86-21-62489821

© 2011 The Author(s). Licensee IntechOpen. This is an open access article distributed under the terms of the [Creative Commons Attribution 3.0 License](https://creativecommons.org/licenses/by/3.0/), which permits unrestricted use, distribution, and reproduction in any medium, provided the original work is properly cited.

IntechOpen

IntechOpen