

We are IntechOpen, the world's leading publisher of Open Access books Built by scientists, for scientists

6,900

Open access books available

186,000

International authors and editors

200M

Downloads

Our authors are among the

154

Countries delivered to

TOP 1%

most cited scientists

12.2%

Contributors from top 500 universities



WEB OF SCIENCE™

Selection of our books indexed in the Book Citation Index
in Web of Science™ Core Collection (BKCI)

Interested in publishing with us?
Contact book.department@intechopen.com

Numbers displayed above are based on latest data collected.
For more information visit www.intechopen.com



Complementary and Alternative Medicine for Vitiligo

Jimi Yoon¹, Young-Woo Sun² and Tae-Heung Kim²

¹Gyeongsang National University Hospital

²White-Line Skin Clinic & Research Center, Kyungnam
Republic of Korea

1. Introduction

We are in an era of modern medicine that is defined by rapid change. Scientists are accumulating and analyzing scores of genomic data, however, the majority of data being accumulated on vitiligo has not been appropriately archived or systemized for analysis (Alikhan *et al*, 2011; Spritz, 2011).

The pathogenesis of vitiligo is multifactorial, and includes three main factors: genetic, immunological, and environmental. Clinically, environmental factors are important in the development of vitiligo. Trauma, eczema, chemical agents, and fragility of keratinocytes play a role in development of vitiligo, so treatment decisions should be made taking these factors into account (Alikhan *et al*, 2011; Lee *et al*, 2005).

Historically, vitiligo was deemed to respond relatively poorly to treatment with a high recurrence rate, therefore, there is at times a reluctance to advise treatment. Recently, various treatment modalities have been introduced, and treatment options and outcomes have been improving. Excimer laser, phototherapy, epidermal grafts, and lifestyle modification have improved the results of treatment and quality of lives of patients with vitiligo (Felsten *et al*, 2011).

South Korea is a country (approximately 1/7th the size of Texas) with excellent modern medical facilities for the treatment of vitiligo. There are 130 practices where excimer lasers are commonly used and more than 70 practices can provide surgical management (epidermal grafts). Nevertheless, many patients seek alternative medical options, including oriental medicines and folk remedies for treatment of their vitiligo. Dermatologists should have an objective point of view on how to use and combine complementary and alternative medicine (CAM) with modern medicine. This chapter will review the various complementary and alternative medicines and evaluate their efficacy and safety to validate their reliability.

2. Vitiligo and lifestyle modification

The location of vitiligo can give clues as to its triggers or causes. In stress-induced cases, skin lesions are frequently localized to the seborrheic area (Figure 1A). In traumatic types, the lesions are usually localized to sites of injury or pressure (Figure 1B). In dermatitis-associated types, depigmented lesions tend to occur in areas of a specific pre-existing

dermatitis. Doctors can often assume predisposing and aggravating factors that can help identify vitiligo etiology, and thereby advise patients to alter modifiable living habits (Taïeb & Picardo, 2009).

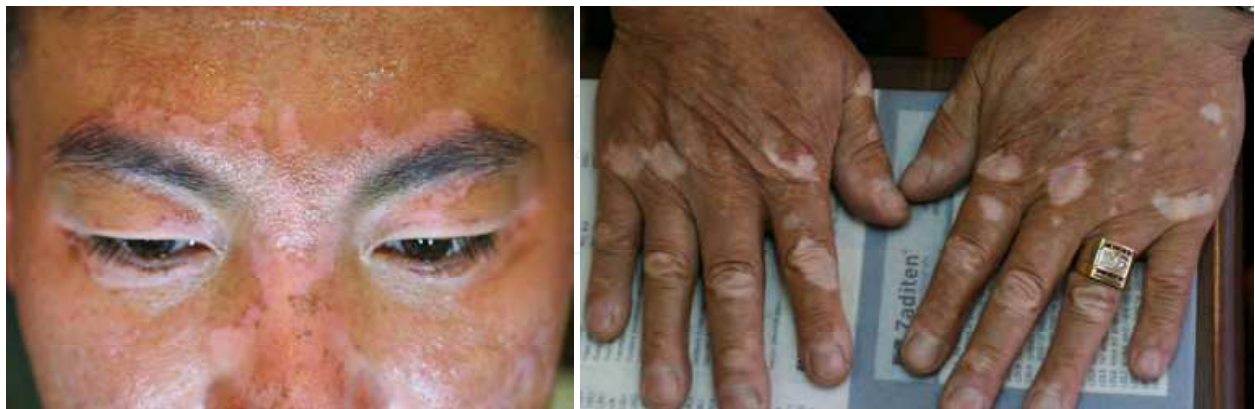

Fig. 1. A. Vitiligo in a seborrheic distribution. B. Vitiligo on the bony prominences.

2.1 Diet, food additives, antioxidants, vitamins, and microelements

Diet is not considered very important in the treatment of vitiligo. However, a healthy, balanced diet with nutrients from a variety of sources can be helpful in vitiligo. According to complementary and alternative medicine (CAM) practitioners, there are foods that are considered either beneficial for or detrimental in vitiligo, but they differ in opinion about these foods and they often lack medical evidence to substantiate their claims. Often, recommendations are determined by a food's composition of antioxidants, vitamins, and microelements. On the other hand, the detrimental effects of foods or food additives are often based on the risk of allergic reactions and irritation, either of which could trigger or exacerbate vitiligo.

2.1.1 What foods should be avoided?

Some Ayurvedic specialists insist that certain foods are harmful to the body when a patient is suffering from vitiligo. This includes tamarind, tomatoes, citrus fruits and juices, grapes, papayas, sour or pickled food items, tinned foods or drinks, chocolate and cocoa products, coffee, oily or spicy foods, blueberries, pears, eggs, dairy products, and fish (Ravish, 2011). Traditional Korean medicine specialists do not recommend consuming pork, chicken, and wheat for patients with vitiligo. There are also homeopathic doctors who suggest that sour foods, ascorbic acid, non-vegetarian foods, and flavored drinks and foods with artificial colors may worsen the condition.

Namazi & Chee Leok (2009) suggested that mangoes, cashews, pistachios, oak, cassavas, areca nuts, red chilies, cherries, raspberries, cranberries, blackberries, and tea contain naturally-occurring plant phenols and polyphenolic compounds, or tannins, that could possibly aggravate vitiligo due to their phenolic structures.

Nickel is found in foods such as instant tea (green or black), cocoa and chocolate, crisps, wheat flour, and roasted salted cashews. Nickel is eliminated through sweat, so consumption of high concentrations of nickel can cause a cutaneous reaction. If a patient is allergic to nickel, and is suffering from vitiligo in the areas prone to sweating such as the shoulders, flanks, buttocks, and sacrum, foods containing nickel should be avoided (Han *et al*, 2005; Sharma, 2007).

Eating barbecued meats increases the production of oxygen free radicals and carcinogens in the body as well as lowers levels of antioxidants. However, most patients do not adhere to restrictions on these types of foods. Patients need to be counseled on making a modest reduction of these types of foods in their diets and maximizing antioxidant intake from vegetables and fruits. They should also cut back on fast foods and other instant foods that are high in calories and have low nutritional value. Otherwise, antioxidant supplements can also be recommended.

There are differing opinions on whether these foods are actually harmful. If a patient is to avoid all of the foods listed above, he or she could easily become more stressed and lose the benefits of a balanced diet. In our personal opinion, the various fruits or nuts mentioned above are beneficial to the patient's health and vitiligo, so we usually encourage their consumption.

Patients and doctors should pay special attention to the cutaneous reactions induced by foods. The foods listed above can cause irritation that leads to skin inflammation. It can also result in Type I anaphylactic hypersensitivity (atopic dermatitis or urticaria) and Type IV delayed hypersensitivity (allergic contact dermatitis) both of which can exacerbate vitiligo. However, these adverse events rarely occur and doctors do not need to prohibit all patients from these foods.

Furthermore, patients should rinse and wash their mouths (perioral and oral cavities) and hands after meals. Patients with celiac disease (wheat or gluten-sensitive enteropathy), in particular, those with associated dermatoses such as dermatitis herpetiformis or psoriasis, should minimize their intake of wheat because wheat or gluten can aggravate cases of vitiligo. (Humbert *et al*, 2006)

The eating habits of specific ethnic groups are also important to evaluate because certain customs can lead to skin inflammation and exacerbation of vitiligo. For example, Koreans enjoy urushiol-containing foods for gastrointestinal relief. They also eat Korean chicken or duck soup made with *Rhus* plants which can result in systemic contact dermatitis (Park *et al*. 2000). For this reason, it is necessary to perform further research studies in different regions of the world so that specific native foods that cause allergic or irritant reactions can be identified.

2.1.2 What foods are recommended?

On the whole, eating a variety of fish, meats, vegetables, and fruits is encouraged in the treatment of vitiligo. However, patients can be particular or "picky" about the foods they eat, and doctors need to take this into consideration. Meats or fish such as shark and tuna can be poisoned with dioxin, mercury, or heavy metals, which can also be problematic.

Food can serve as antioxidants. It is known that various reactive oxygen species are involved in the destruction of melanocytes in vitiligo. Many studies have shown that reactive oxygen species are increased in the epidermis of active disease. Scientists have hypothesized that elimination of these reactive oxygen species could inhibit the progression of vitiligo and studied the administration of antioxidants to patients with vitiligo. Schallreuter and colleagues (1995, 1999, 2001) reported that the combination of phototherapy and antioxidants showed a statistically significantly better response in patients compared to phototherapy alone. Recently, Dell'Anna and colleagues (2007) showed that oral supplementation with alpha-lipoic acid significantly improved the clinical effectiveness of phototherapy.

There is also further evidence for using antioxidants in the treatment of vitiligo. According to the clinical experiences of the authors, high doses of antioxidants (as part of combination treatment with other vitiligo therapies) have decreased the risk of abrupt deterioration of vitiligo. Patients with vitiligo are advised to select foods rich in antioxidants. These antioxidant-rich foods include pomegranates, grapes, oranges, lemons, grape fruits, pineapples, strawberries, kiwi, blueberries, nuts (e.g., walnuts, cashew nuts), sunflower seeds, black sesame, perilla seeds, olives, black beans, tomatoes, red clover, broccoli, ginger, beets, kale, red cabbage, peppers, spinach, *Agaricus bisporus* (common/crimini mushrooms), green tea, and coffee. If the aforementioned foods are not available, patients can use commercial nutritional supplements. These include products containing genistein (black bean extract), green tea polyphenol, co-enzyme Q10, selenium, alpha-lipoic acid, omega-3 fatty acids, gamma linolenic acid, carotenoids, quercetin, vitamin C, and vitamin E, and others.

Although some specialists insist that vitamin C is harmful in vitiligo because of its skin whitening properties, we believe the advantages of vitamin C as an antioxidant outweighs the risk of hypopigmentation, and we recommend that patients to take vitamin C at a dosage of 0.5-2 grams daily.

Omega-3 fatty acids are poly-unsaturated fatty acids (PUFAs) that are known to be beneficial for psoriasis and autoimmune diseases. It may also be beneficial in vitiligo due to its anti-inflammatory, anti-oxidant, and anti-depressant effects (Simopoulos, 2002). Gamma-linolenic acid, another PUFA from evening primrose oil, is considered effective for atopic dermatitis (Kerscher & Korting, 2002). It is effective in vitiligo when vitiligo occurs with atopic dermatitis in flexural or periorbital areas, and other areas vulnerable to stimuli.

Vitamins and minerals (microelements) are also important. Some studies have demonstrated that the level of vitamin B12, folic acid, copper, and zinc in patients with vitiligo may be lower than in unaffected individuals. Microelements such as selenium, copper, and zinc are essential in the diet or as supplements. It is preferable to take vitamin B12 along with folic acid due to the considerable synergistic effects of the pairing (Jalel *et al*, 2009). It is recommended that patients obtain these nutrients from vegetables and fruits such as tomatoes, spinach, *Agaricus bisporus*, kiwi, or multivitamin supplements.

2.1.3 Food additives

Processed foods such as those found in cans or bottles, and preserved or tinned meats such as ham or sausage, contain various food additives including: dyes, color retention agents, defoaming agents, emulsifiers, flavors, fungicides, preservatives, sweeteners, thickeners, and chemicals introduced at the agricultural or animal husbandry phases, among many other possible ingredients.

While food additives are generally considered harmful in vitiligo, the medical evidence for these harmful effects is weak. In patients with atopic dermatitis, food additives like preservatives (sodium benzoate, potassium sorbate, sodium propionate), coloring agents (sodium nitrate and certain FD&C colors), or monosodium glutamate (MSG) may induce an intolerance reaction by acting on mast cells directly (Fuglsang *et al*, 1994). Consuming food additives in large amounts can also increase the risk of a stress reaction. These can have a harmful effect on vitiligo itself and accompanying skin diseases such as atopic dermatitis. Physician ought to consider the harmful effects of food additives, particularly in unstable and progressive vitiligo, although these are not so much of a concern in stable vitiligo.

2.2 Life, exercise, and stress

2.2.1 Living habits

Patients may need to change their living habits depending on their individual clinical presentation of vitiligo. For example, since severe stress can aggravate vitiligo lesions, positive thinking and reducing stress could help reduce them. Adequate rest and antioxidants are important for patients with vitiligo, particularly those with lesions in a seborrheic distribution. Patients ought to reduce smoking, a habit that siphons beneficial antioxidants from the body. It is necessary to reduce the risk of koebnerization in vitiligo through friction or trauma. For example, tight-fitting shoes or jeans, and elastic stockings should be avoided.

Identification of possible occupational trauma is important as well. Figures 2A & 2B suggest that occupational trauma such as burns or chemical irritation (*e.g.*, by discharge in an electric arc or argon welding) can exacerbate vitiligo. The patient in Figure 2C, working in a disposable mask, developed vitiligo in the perioral area where the mask was fitted. As expected, the skin lesions improved with switching to a cotton mask and excimer laser treatment for one month (Figures 2D & 2E).

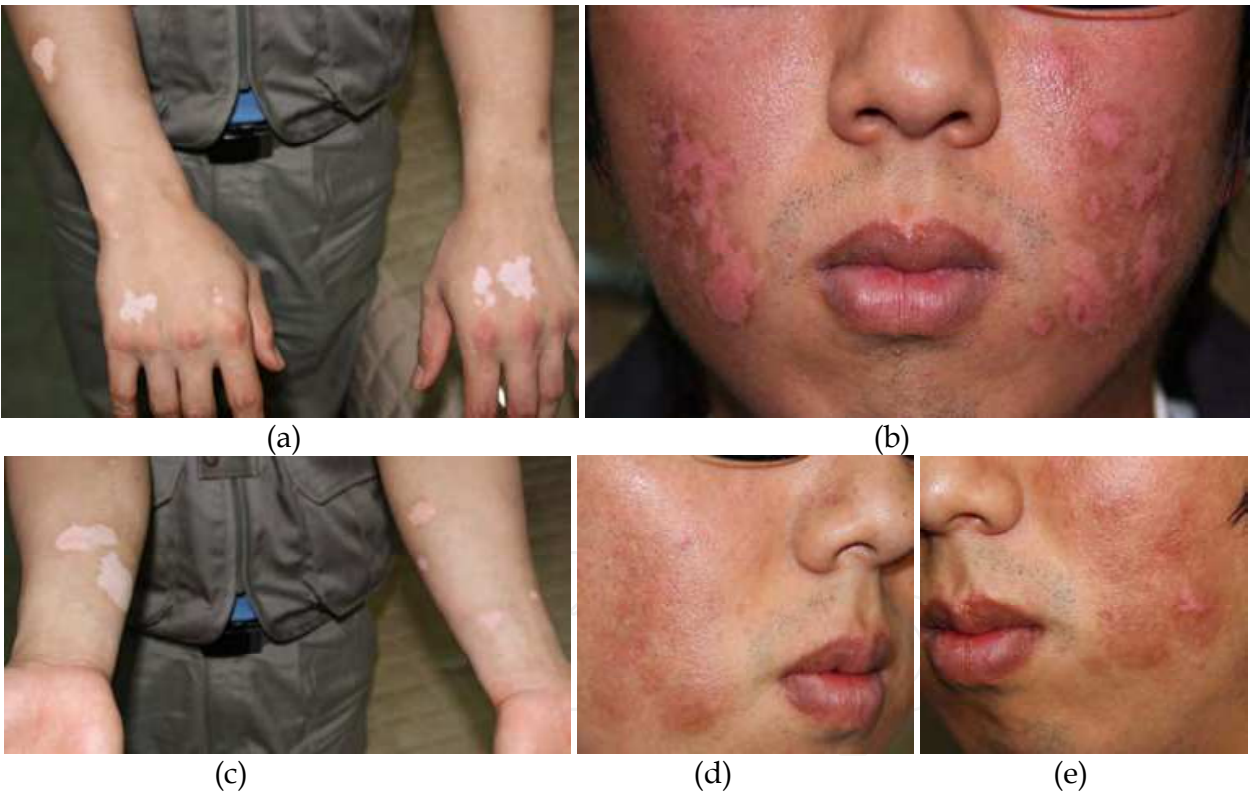

Fig. 2. (a) and (b). Occupational vitiligo induced by welding. (c) – (e). Vitiligo on areas in contact with a disposable mask, before (c) and one month after treatment (d, e)

2.2.2 UV exposure

Complementary and alternative medicine practitioners are able to take advantage of the application of photochemical reactions by treating vitiligo patients with ultraviolet rays and photosensitizers. Psoralen is the most widely used photosensitizing agent, and exhibits a very strong photochemical response to ultraviolet B (UVB) as well as ultraviolet A (UVA).

Adding UVB to psoralen plus UVA (PUVA) phototherapy is an option for inducing a tremendous treatment response in vitiligo (Mofty *et al*, 2001). Similarly, exposure to sunlight (UVB and UVA), after eating or applying photosensitizing or reactive herbal medicines can cause such a strong photochemical reaction, phototoxicity, or other adverse event that can actually be used to treat vitiligo. Fragrant substances commonly cause these types of photochemical reactions. Musk or cinnamic aldehyde is widely used in cosmetics and can cause skin inflammation and worsening of vitiligo. If an inflammatory skin lesion develops, particularly on sun-exposed areas, patients should discontinue this type of product and be cautioned as to the possible photochemical reaction that occurs with exposure to sunlight.

UV therapy is a double-edged sword in the treatment of vitiligo. The pathogenesis of phototherapy with UV rays is understood in two different aspects, direct DNA damage and radical damage. First, direct DNA damage by UV rays induce the formation of cyclobutane pyrimidine dimers (CPD) as well as 6,4-photoproducts and 6,4 pyrimidine-pyrimidones that lead to skin damage. Secondly, formation of free radicals by UV rays result in damage of the skin through production of 8-oxoguanine. (Kunisada *et al*, 2007).

In particular, the shorter ultraviolet wavelengths below 305 nm more commonly bring about DNA damage and aggravate vitiligo. Since exposure to strong sunlight without sunscreen can worsen disease, patients are recommended to use sunscreens, supplement themselves with antioxidants, and avoid the use of herbal medicines, cosmetics, or herbs that can induce photochemical reactions.

2.2.3 Exercise

Repetitive movements in exercise can induce vitiligo due to trauma to or friction with certain body areas. If this is consistent with a patient's story of the appearance of certain vitiligo lesions, the patient should consider modifying or discontinuing the exercise. Common occurrences include lesions of the dorsal shin in soccer, inner thigh and groin for horseback riders, protuberant areas in contact with protective headgear, and pressure points on the hands and palms when gripping golf clubs.

2.3 Other dermatoses and vitiligo: Atopic dermatitis and allergic contact dermatitis

Patients with vitiligo can exhibit sensitivity or form an allergic response to a variety of chemicals and products that can lead to aggravation of vitiligo.

For example, some patients have shown marked improvement of vitiligo lesions in the forehead and scalp region after changing their paraphenylenediamine (PPDA)-based hair dyes to dyes that did not contain the ingredient and therefore were not allergic or sensitive to.

Considering reports of the deterioration of vitiligo after imiquimod treatment, it is desirable to avoid imiquimod if possible.

Patients who are allergic to nickel should avoid contact with the metal as it is contained in many accessories and jewelry. If patients insist on continuing to wear such accessories, they can switch to those that are nickel-free (*e.g.*, titanium).

Cosmetics and oral hygiene products can cause problems in vitiligo. There are many cases in which patients improve after using paraben- or fragrance-free products (personal communication with Prof. Ai-Young Lee, Dong-kuk University, Ilsan, Korea, and authors' experience). Patients and doctors need to decide whether to continue the use of these

products considering the distribution of vitiligo lesions, the areas to which the products are applied, and based on the results of patch testing of specific products.

The patient in Figure 3A developed vitiligo only in the lip and perioral region. Patch testing was positive for thimerosal. She showed much improvement in skin lesions after discontinuing the use of mouthwashes and toothpastes containing thimerosal and using thimerosal-free products.

Enough rest and appropriate treatment can help vitiligo in the “T-zone” areas where seborrheic dermatitis commonly occurs. If a lesion appears in areas which have a predilection for atopic dermatitis, doctors should pay special attention to treatment of the skin lesion. Adjunctive use of ketotifen and gamma-linolenic acid is useful. For the patient in Figure 3B, phototherapy as well as treatment for atopic dermatitis and diaper dermatitis would be necessary.

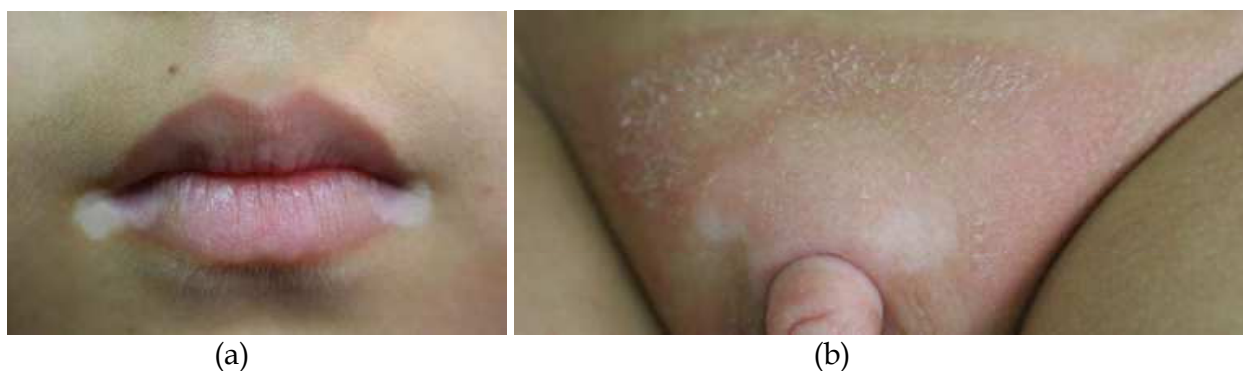

Fig. 3. A. Vitiligo on angles of mouth. B. Vitiligo associated with atopic dermatitis and diaper dermatitis.

2.4 Aesthetic treatment and vitiligo

Many patients suffering from vitiligo want purely aesthetic treatment, which can be harmful. IPL (intense pulsed light) can induce vitiligo (Shin *et al*, 2010). Authors have experienced cases of vitiligo aggravated after monopolar and bipolar radiofrequency treatments (Tenor, Alma) for rejuvenation, as well as low fluence Q-switched Nd-YAG laser for the treatment of melasma. Since keratinocytes in vitiligo are highly sensitive to stimuli (Lee *et al*, 2005), aesthetic treatment should be reserved for stable vitiligo at periods when a patient is less stressed, and at a relatively shallow depth of penetration, *i.e.*, by narrowing the interval and width of pulse of IPL and lowering the fluence of Nd: YAG laser. Doctors must be discreet in utilizing laser treatments and consider the activity and severity of vitiligo of the patients who inquire about elective cosmetic treatments.

3. Complementary and alternative medicine (CAM) for vitiligo

3.1 Traditional Chinese medicine (TCM)

The history of TCM dates back thousands of years. The variety and usage of these medicines is almost identical throughout Korea, China, and Japan thanks to long-term cultural exchange among nations (Bark *et al*, 2010).

According to TCM, wind (climate), wetness (humidity), and coldness (temperature) invade the skin and inhibit the cycle of energy and blood, and can cause discordances among them. The blockage of energy and blood paves the way for diseases, which has a cumulative effect with various internal and external factors (*e.g.*, stress, coldness). The discordance of energy and blood inhibits nutrient delivery to the skin, and allows bad spirits to invade, resulting in vitiligo. For this reason, TCM doctors insist that the recovery of circulation of energy and blood can cure vitiligo. TCM places an emphasis on the effects of *decoctions* of herbs rather than that of each herb. Some oriental herbs have different names depending on the parts utilized (*e.g.*, stalk or root) as well as preparation (*e.g.*, peeled or unpeeled, steamed or dried). Furthermore, recent studies show that there are differences in the end product which are dependent on processing methods and parts utilized. For ginseng (*Panax*), one of the most studied plants, the main ingredient ginsenoside is altered by different processing methods such as drying and steam-drying which alter them from the raw product. Each ginsenoside has a different medical mechanism of action and the effect of each has been identified (Choi, 2008; Kim *et al*, 2007).

Among the decoctions of herbs which TCM primarily uses, the most effective medicines have been shown to be the xiaobailing decoction, Chang-yee powder, and three-yellow powder. These medicines include various medicinal plants such as *Xanthium strumarium*, *Sophora flavescens*, *Atractylodes japonica*, and *Arisaema amurense*. The TCM medicines known to be effective in vitiligo are listed in Table 1.

According to Bark *et al* (2010), a quarter of 64 TCM plants have been shown to have phototoxic properties. They show strong fluorescence in phototoxicity tests and are positive in photohemolysis and *Candida albicans* tests. In a mouse experiment with 5 TCM plants, the UVA plus TCM group showed phototoxic reactions such as skin swelling, sunburn cell formation, depletion of Langerhans cells, and suppression of local contact hypersensitivity to dinitrofluorobenzene (DNFB).

Additionally, a study of 160 TCM medicines revealed the number of phototoxic drugs at a similar ratio to the previous study (Bark *et al*, in preparation). Because a number of herbal medicines have different absorbance and fluorescence patterns than psoralen, they can be considered as alternative photosensitizing agents for photochemotherapy. The phototoxic properties of *Xanthium strumarium* and *Psoralea corylifolia* have been shown to be stronger than those of psoralen (authors' unpublished data). Table 1 includes some of the medicines that the authors have examined and determined to be phototoxic.

The effectiveness of TCM is considerably lower than that of modern medicine. TCM may include harmful or ineffective components because it uses a decoction of components. Therefore, safety is our priority in TCM. Many people have consumed TCM without any safety monitoring, believing it to be a secret method passed from generation-to-generation for thousands of years. This ideology can be harmful. The use of *Aristolochia fangchi* resulted in European patients developing renal failure and kidney cancer when taken as an obesity treatment. (Arlt *et al*, 2002; Cosyns *et al*, 1994; Vanherweghem *et al*, 1993). It is necessary to further study the efficacy and safety of TCM.

Arsenic or mercury used in TCM can be effective for vitiligo, but these are dangerous materials. Even now, many Koreans develop arsenic keratosis after receiving TCM therapy previously (Figure 4). Furthermore, arsenic can also be absorbed through the skin (Lowney *et al*, 2005). The bigger issue is that the Korean Food & Drug Administration approved arsenic and mercury for TCM therapy (2007).

Scientific Name	Common name or Ayurvedic name	Proposed mechanism of action
<i>Angelica sinensis</i>		phototoxic
<i>Arisaema amurense</i>		antioxidant
<i>Astragalus membranaceus</i>		
<i>Atractylodes japonica</i>		phototoxic
<i>Carthamus tinctorius</i>	safflower	antioxidant
<i>Cassia occidentalis</i>	kasaundi, stinking weed	melanoblast differentiation and migration
<i>Cnidium officinale</i>	chuanxiong rhizome	phototoxic
<i>Codonopsis pilosula</i>	Tangshen	
<i>Cuscuta chinensis/japonica</i>	dodder seed	antioxidant
<i>Eclipta prostrata</i>	bhangrah	antioxidant
<i>Gentiana scabra</i>		anti-inflammatory
<i>Liquidambar formosana</i>	sweetgum fruit	promotes circulation
<i>Lycium chinense</i>	wolfberry fruit	nutrient, antioxidant
<i>Paeonia lactiflora</i>	white peony root	
<i>Paeonia lactiflora</i>	red peony root	
<i>Picrorhiza kurroa</i>	Katuki, kutki	phototoxic
<i>Pleuropterus multiflorus</i>		promotes circulation, antioxidant
<i>Polygala tenuifolia</i>		phototoxic
<i>Prunella vulgaris</i>	prunella spike	immunomodulatory effects
<i>Prunus persica</i>	peach kernel	
<i>Rehmania glutinosa</i>	Chinese foxglove	nutrient, antioxidant
<i>Salvia miltiorrhiza</i>	red sage	antioxidant, anti-inflammatory, promotes circulation
<i>scorpion</i>		toxin?
<i>Sesamum indicum</i>	black sesame	antioxidant
<i>Sophora flavescens</i>		
<i>Spatholobus suberectus</i>	climbing stem of <i>S. suberectus</i>	promotes circulation
<i>Spirodela polyrhiza</i>		
<i>Tribulus terrestris</i>	gokshura, sarrata	phototoxic
<i>Xanthium strumarium</i>		phototoxic

Table 1. Complementary and Alternative Medicines Utilized in Vitiligo

Koreans consider and take herbal medicine as health food. Dozens of cases of vitiligo exacerbations were observed in those taking high dose supplements of ginseng products like raw ginseng, red ginseng, white ginseng, and products from the *Acanthopanax species* (*A. sessiliflorum*, *A. gracilistylus*, *A. senticosus*), and *Phellinus linteus* (mushroom) for over one month. Therefore, patients and doctors must keep in mind that these medicines can affect immune status and aggravate vitiligo. Consuming small amounts of ginseng products or

applying them to the skin can improve vitiligo. Nevertheless, it is more beneficial not to use these in terms of potential risks involved.

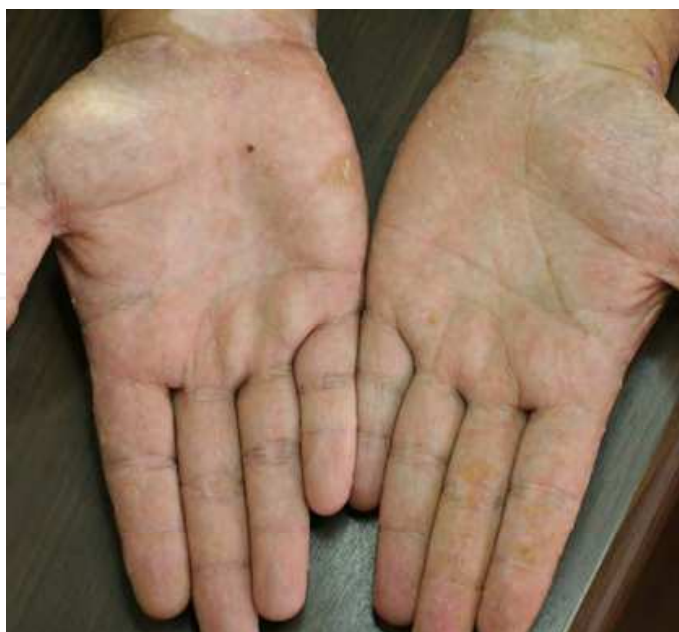

Fig. 4. Arsenic keratoses in vitiligo patient

3.2 Traditional Indian medicine

Traditional Indian medicine has thousands of years of history. Its branches include Ayurveda, Yoga & Naturopathy, Unani, and Siddha medicine. Due to a long history of active trading between China and India through the Silk Road (via Central Asia, trans-Himalayan, or sea-route), there are similarities in the medicinal plants utilized and their indications. *Cassia occidentalis*, *Eclipta prostrata*, *Curcuma longa*, *Picrorrhiza kurroa*, *Psoralea corylifolia*, and *Tribulus terrestris* are commonly used in both Ayurvedic medicine and TCM (Dharmananda, 2011).

However, there are fundamental differences between Ayurveda and TCM. Despite having common drugs, Ayurvedic medicine and TCM use them for different applications. Ayurvedic medicine primarily uses mineral-based and herbal drugs that act as photosensitizers and blood purifiers (Srivastava, 2011).

Photosensitizing agents include *Psoralea corylifolia*, *Semecarpus anacardium* (marking nut), and *Ficus hispida*. They are administered locally as well as systematically in conjunction with sun exposure. Sun exposure is advised three hours after drug administration. Blood purifiers include *Curcuma longa*, *Eclipta alba*, *Tinospora cardifolia*, *Hemidascus indicus*, *Acacia catachu*, and *Acaranthus aspara* (Srivastava, 2011).

Traditional Siddha medicine uses *Aristolochia indica*, *Tribulus terrestris*, and *Thespesia populnea* (Soni *et al*, 2010). Among these, *Aristolochia indica* root contains aristolochic acid, so it can cause a renal failure or cancer. (Arlt *et al*, 2002; Cosyns *et al*, 1994; Vanherweghem *et al*, 1993). Both the hepatotoxicity of *Psoralea corylifolia* (Teschke & Bahre, 2009, Cheung *et al*, 2009), and its phototoxicity (Bark *et al*, 2010) are mentioned due to its possible applications in vitiligo. Ayurvedic medicine as well as TCM acknowledge the risks of the use of arsenic and mercury (Saper *et al*, 2004).

Ayurvedic doctors recommend that patients avoid tea, coffee, alcoholic beverages, oranges, sweet lime, sea food, excessive salt, and sour or fermented food products. However, these foods have not been observed to cause any deterioration in vitiligo patients, and in fact, tea, red wine, orange, or fermented foods seem to be rather helpful for vitiligo. More studies should be performed to identify the efficacy of these foods.

3.3 Homeopathic treatment

Homeopathy is a form of alternative medicine that originated in 18th century Germany. Many countries have adapted and transformed these practices in accordance to their cultures. India is particularly well known for its wide application of various homeopathic treatments that claim a high “cure” rates, but there is a lack of medical evidence substantiating this. Poisonous materials such as arsenic sulph falvus, arsenic album (arsenic trioxide), baryta muriaticum (barium chloride) and baryta carbonicum (barium Carbonate), are often employed by practitioners in highly diluted preparations. The collective weight of scientific evidence has found homeopathy to be no more effective than placebo.

3.4 Folk remedies in Korea

There are various Korean folk remedies for vitiligo. Apart from TCM, folk remedies include the root of *Rumex crispus* or leaves of the common fig tree (*Ficus carica*) which contain strong phototoxic agents (mainly furocoumarine). These phototoxic agents are less effective than modern medicine (*i.e.*, psoralen) because these preparations are affected by many variables, such as active ingredient concentration, treatment frequency, and application or administration methods.

Foreign body reactions using various irritants that add pigment to the skin (*i.e.*, tattooing) are often harmful and have no benefits. Bee venom is regarded as ineffective and dangerous because it induces systemic inflammation. However, *purified* honey bee venom (apitoxin) may be effective in vitiligo (Jeon *et al*, 2007).

Rhododendron schlippenbachii and *Lespedeza bicolor* show significant improvement in vitiligo lesions when applied topically or combined with phototherapy. Though the mechanism of action has not been clearly elucidated, it is presumably related to the activation of melanocytes and the effect of antioxidants or toxins (*e.g.*, alkaloid, rhodoxin, andromedotoxin) (HY Kang, JK Yang, TH Kim, in preparation).

3.5 Suggested mechanisms of action of complementary and alternative treatments

Table 1 lists CAM therapeutics used for treatment of vitiligo. It is unclear by which mechanisms these medicines use in vitiligo. The authors do not support the motion of energy theorem suggested in TCM or Ayurvedic medicine. In modern medicine and dermatology, phototoxic reactions, melanocyte proliferation, promoting anti-inflammatory activity, and trigger reduction (*e.g.*, stress, environmental factors) are thought to be involved in vitiligo management.

Ammi visnaga (khellin), *Angelica sinensis*, *Atractylodes japonica*, *Cnidium officinale*, *Ficus carica*, *Ficus hispida*, *Hypericum sp.*, *Picrorhiza kurroa*, *Polygala tenuifolia*, *Psoralea corylifolia*, *Rumex crispus*, *Semicarpus anacardium*, *Tribulus terrestris*, and *Xanthium strumarium* have phototoxic properties. Like psoralen, they can be combined with relevant ultraviolet rays or sunlight (Bark *et al*, 2010; Bark *et al*, in preparation; Srivastava, 2011).

Bee venom, *Angelicae dahuricae*, *Astragalus membranaceus*, *Cassia occidentalis*, *Cuscuta chinensis*, *Flos Carthami*, *Psoralea corylifolia*, *Lespedeza bicolor*, *Ligustrum lucidum*, *Malytea scurfpea*,

Rhododendron schlippenbachii, *Salvia miltiorrhiza*, and *Tribulus terrestris* are known to induce melanocyte proliferation, melanogenesis, and migration of melanocytes.

There has been reports of the antioxidant effects of black sesame, *Arisaema amurense*, *Carthamus tinctorius*, *Cuscuta chinensis/japonica*, *Eclipta prostrata*, *Lycium chinense*, *Pleuropterus multiflorus*, *Psoralea corylifolia*, *Rehmania glutinosa*, and *Salvia miltiorrhiza*, among others. More studies should be performed to further evaluate the antioxidant effects of these medicines.

3.6 Commercial therapeutics for vitiligo

There are many products on the market which are targeted to patients with vitiligo. However, the efficacy and safety of these products are questionable and the authors do not particularly recommend the use of any of these products.

Vitiligo Herb™ and **Anti-Vitiligo™** contain coconut oil, *Psoralea corylifolia*, black cumin, and barberry root. *Psoralea coryli* has strongly phototoxic properties. Barberry root (*Berberis vulgaris*) containing isoquinoline alkaloid (berberine) has antioxidant and anti-inflammatory effects, and inhibits the COX-2 enzyme. Other ingredients included in these products are purported to be antioxidants or nutrients. These products *could* potentiate the effects of phototherapy or sun exposure. Unless patients understand the concerns of using photosensitizers with phototherapy and heliotherapy, treatment using these products can be dangerous.

Low levels of catalase in the epidermis of patients who have vitiligo increase hydrogen peroxide (H₂O₂) levels, which inhibits 6-BH₄ metabolism and melanogenesis. Shallreuter and colleagues (1995, 1999, 2001) suggest that antioxidants are effective for vitiligo. They reported that topical application of **pseudocatalase** and calcium in combination with UVB resulted in complete repigmentation of the face and back of the hands in 90% of a cohort of patients. However, Patel *et al* (2002) used a pseudocatalase and calcium combined with narrowband UVB (NB-UVB), and found no clear evidence of efficacy. It is unclear the differences which come from different manufacturing methods. There is controversy as to whether the effects of *Cucumis melo* extracts are similar to pseudocatalase. *Cucumis melo* extracts have shown to have vitiligo-relevant superoxide-dismutase and catalase-like activities when used with selective UVB therapy (Kostović *et al*, 2007). However, it was ineffective in other studies (Schallreuter & Rokos, 2005; Yuksel *et al*, 2009).

“Callumae” is a product which contains *Picrorhiza kurroa*, khellin, L-phenylalanine, ginkgo biloba, alpha lipoic acid, cyanocobalamin, pyridoxine and folic acid. Among these, *Picrorhiza kurroa* and khellin have psoralen-like phototoxic properties while L-phenylalanine has been shown to be effective for vitiligo combined with UVA phototherapy. Ginkgo biloba and alpha lipoic acid are known to be a natural source of antioxidants. Cyanocobalamin, pyridoxine, and folic acid are vitamins which have shown some usefulness in vitiligo. A combination of phototherapy plus these products may produce greater efficacy.

Phenylalanine, an essential amino acid, is precursor for tyrosine, the monoamine signaling molecules dopamine, norepinephrine, epinephrine, and the skin pigment melanin. There is moderate evidence that L-phenylalanine has efficacy as an adjunct to phototherapy. L-phenylalanine plus UVA (50-100 mg/kg + UVA twice weekly 30-45 min after ingestion) provided better results than L-phenylalanine alone (Siddiqui *et al*, 1994). However, some adverse events have been attributed to L-phenylalanine (Rosenbach *et al*, 1993).

“Vitilax” is a mixture of many ingredients known to be effective for vitiligo (Table 1). Its ingredients include *Psoralea corylifolia*, *Astragalus membranaceus*, Chinese peony root, *Cnidium* fruit, Chinese *Salvia* root and rhizome, *Tribulus* fruit, Chinese dodder seed, Fo-Ti root (polygonum), turmeric root (*Curcuma longa*), atractylodes rhizome, dong quai root

(*Angelica sinensis*), safflower (*Carthamus tinctorius*), fragrant *Angelica* root, and cassia twig (*Cassia occidentalis*).

Khellin is extracted from the seeds of the plant *Ammi visnaga*. Since 1982, khellin has been proposed as an oral photochemotherapy treatment for vitiligo (Abdel-Fatah *et al.* 1982). Five percent khellin in water/oil is applied to a vitiliginous lesion and an hour later, UVA (KUVA) was administered. The control group was treated with conventional systemic PUVA with oral psoralen (0.4 mg/kg). The study showed that both KUVA and PUVA treatment had similar efficacy, but since KUVA is given locally, there may be less risk involved.

Polypodium leucotomos extract (FernBlock®) is a potent antioxidant. Since oxidative stress has been implicated in the vitiligo, it has been used in vitiligo. It was shown to be effective as monotherapy or in combination with NB-UVB (Middelkamp-Hup *et al.*, 2007).

“Melagenina I and II” (placental extract) has been used topically primarily in combination with sun exposure to repigment vitiligo lesions. Its efficacy is questionable, but in recent study, the efficacy of NB-UVB plus topical placental extract caused a modest but statistically insignificant improvement in vitiligo than NB-UVB alone (Majid, 2010).

Ginkgo biloba has antioxidant and immunomodulatory properties. *Ginkgo biloba* extracts given orally can prevent the active progression of vitiligo and induce repigmentation (Parsad *et al.*, 2003; Szczurko *et al.*, 2011). Considering the mechanism of action of *Ginkgo biloba*, combination with phototherapy would theoretically be more effective than *Ginkgo biloba* alone.

Novitil® contains lipoproteins, polypeptides, *Aloe barbadensis*, carboxymethylcellulose, camphor, menthol and oligoelements. Only *aloe barbadensis* may have anti-inflammatory activity in vitiligo, but other ingredients listed do not have proven anti-vitiligo effects.

3.7 Other treatments

Serrano *et al.* (2009) reported that repeated photodynamic therapy (PDT) with low concentrations of aminolevulinic acid (ALA, 1-2%) is helpful in the vitiligo. We have had similar experiences in patients with alopecia totalis. We treated patients with a very low concentration of ALA (0.5%), and asked them to wait 2 hours before exposing themselves to window glass-filtered sunlight for 30 minutes once every two weeks. If similar treatment is repeated in vitiligo, it may work. This may be due to the protoporphyrin IX produced by ALA that strongly absorbs UVA.

Aghaei and Ardekani (2008) reported that diphenylcyclopropanone (DPCP) showed some efficacy in the treatment of vitiligo. DPCP is thought to act as a local irritant when applied topically. However, based on our clinical experience, this agent seems to be quite dangerous and unreliable. There are reports of vitiligo occurring after treatment with DPCP for alopecia areata (Hatzis *et al.*, 1988; Pires *et al.*, 2010). The authors have also experienced some cases of deterioration of vitiligo in patients treated with DPCP for their alopecia totalis or molluscum contagiosum.

4. Camouflage of vitiligo

4.1 Introduction

The majority of patients who suffer from vitiligo want to conceal their exposed vitiligo lesions because of psychosocial reasons. Patients conceal lesions on the face, head and neck, arms, legs, and hands with clothing or other methods. Concealment is a useful way to improve social functioning and patient quality of life (Tanioka *et al.*, 2010). Camouflage can take the form of: micropigmentation which lasts for months to years (tattoos and semi-

permanent tattoos/permanent makeup), dihydroxyacetone and selected fruit juices that last for several days, and dyes or makeup concealers which last for 1- 2 days.

4.2 Long-acting camouflage; Micropigmentation

Micropigmentation is a method in which pigments are injected directly into dermis and last for months to years at a time. This can be in the form of tattooing or semi-permanent tattoos (permanent makeup) depending on the features of pigments utilized.

Tattoos have been used widely throughout the world for thousands of years, as part of cultural and ethnic activities to recreational purposes. In vitiligo, the pigments that have been used in vitiligo include mercury (red), lead (yellow, green, white), cadmium (red, orange, yellow), nickel (black), zinc (yellow, white), titanium (white), iron (brown, red, black), barium (white), and carbon (black). Organic chemicals, including azo-chemicals (orange, brown, yellow, green, violet) and naptha-derived chemicals have been used. Elements such as antimony, arsenic, beryllium, calcium, lithium, selenium, and sulfur are also employed.

Tattoo ink manufacturers typically make either blends of heavy metal pigments or lightening agents (such as lead or titanium). This method has the advantage of long-lasting effects. This is useful particularly for lesions on the scalp, eyebrows, and lips, which are naturally pigmented. However, it is difficult to adjust or homogenize tone of skin color, and the results are often unsatisfactory.

Some skillful tattooists provide cosmetically good results to patients. Singh & Karki (2010) obtained cosmetically acceptable results in tattooing Indian patients who had localized, stable vitiligo on their lips. Permanent makeup is similar to conventional (temporary) makeup (*e.g.*, concealer) and is preferred by patients who want to look natural (De Cuyper, 2008). For most Koreans, pigment lasts for approximately 2-4 years, according to the authors' experience with hundreds of such cases. However, as the semi-permanent makeup fades, it leaves a reddish tint in treated areas.

Permanent makeup uses digitalized tattoo machines and need re-touching when colors begin to fade after treatment (around one month).

The primary pigments may be excreted slowly by trans-epidermal elimination. It can be predicted that the pigments deposited at the dermal papilla are much more likely to disappear gradually similarly to the mechanism by which amyloid deposition in the dermal papillae emits outward through transepidermal elimination in primary localized cutaneous amyloidosis (Kibbi *et al*, 1992). The longevity of individual pigments seems to be dependent upon composition. When red residue remains after a tattoo fades, it is after the disappearance of plant-derived organic dyes.

Permanent makeup has the advantage of lasting for a long time. Eyebrows or lips can be concealed naturally with permanent makeup. Since it is difficult to homogenize or adjust the varying skin tones for each individual, therapists make a lighter shade of color than they desire with permanent makeup and then add conventional makeup with concealer. Pigments used for diluting colors are often left in the skin for a long time. In the case of titanium dioxide, patients can experience paradoxical darkening, which is cosmetically undesirable, although dermatologists have successfully treated this with the Q-switch laser (Kirby *et al*, 2010).

The common problem with **micropigmentation** is dissatisfaction with shape and tone. It is difficult for even the most experienced tattooists to make pigments with accurate tone, depths, and symmetry, particularly for the eyebrows and lips. The deeply injected pigment can develop an unnatural look due to the Tyndall effect (scattering of light). Furthermore,

due to trauma in micropigmentation procedures, koebnerization leading to vitiligo can occur. Furthermore, adverse events are a possibility with these procedures, and include infection, allergic reactions, tattoo granulomas, keloid formation, and magnetic resonance imaging (MRI) complications. Magnetic responsive dyes in tattoo can cause cutaneous reactions when patients undergo MRI testing. (De Cuyper, 2008; FDA, 2011; Kirby 2010).

4.3 Intermediate-acting camouflage

Dihydroxyacetone (DHA) is an ingredient in self-tanning products. This dyeing method camouflages lesions of vitiligo temporarily because of browning by the Maillard reaction (Fusaro & Rice, 2005). DHA can mask lesions of vitiligo relatively well and lasts for 3-6 days. (Rajatanavin *et al*, 2008; Suga *et al*, 2002).

According to our experience, many patients combine DHA with conventional makeup. Korean patients with vitiligo effectively conceal lesions using DHA concentrations of 5-15%. Since DHA can make lesions slightly reddish brown, it is not well-suited for patients with yellow skin tones.

DHA is not very effective in damaged or inflamed stratum corneum. It may also interfere with the effects of phototherapy by inhibiting ultraviolet rays (Fusaro & Rice, 2005). Patients need to practice application techniques for the most natural-appearing camouflage because final coloring appears several hours after application.

Applying a dye from premature walnut shells is a natural pigmentation aid for vitiligo. Premature walnut shells are frozen and made into a solution. This can further be diluted to match skin color, in particular for patients with yellow undertones. However, this method can cause an allergic contact dermatitis (due to the walnut shell), and due to the instability of the dye solution, it becomes less effective after a day.

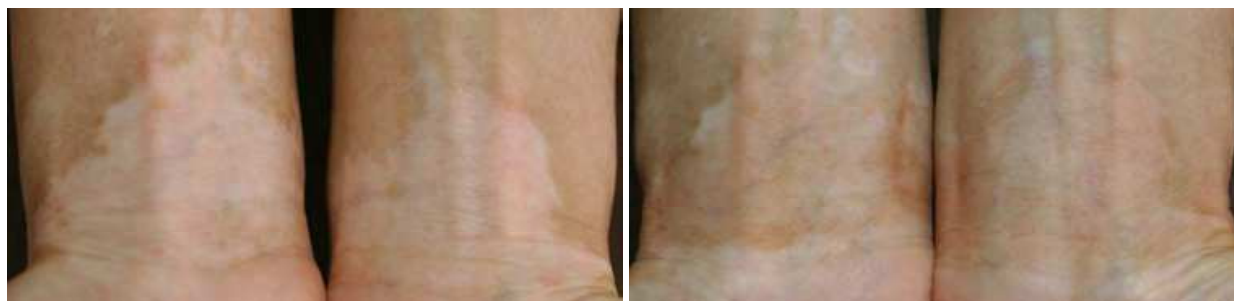

Fig. 5. Concealing with 7.5% dihydroxyacetone (left), and walnut shell extract (right). A. Before concealing. B. After concealing.

Figure 5 compares the effects of DHA solution versus that of walnut shell. The patient preferred DHA (Figure 1B, left) due to its more natural and longer-lasting effects. However, some patients do prefer the walnut shell-derived dye.

Henna (made from mehndi leaves) is sometimes recommended for vitiligo, however, the stain is generally more red than naturally occurring skin tones. Henna with a brown or black color contains added paraphenylenediamine which can often cause an allergic contact dermatitis and aggravate vitiligo.

4.4 Short-acting camouflage

Dyes such as potassium permanganate, indigo carmine, and bismarck brown can be used to camouflage vitiligo. These dyes provide an immediate, natural, amber-like shade with single or repeated applications, and can be easily removed by washing (Sarveswari, 2010).

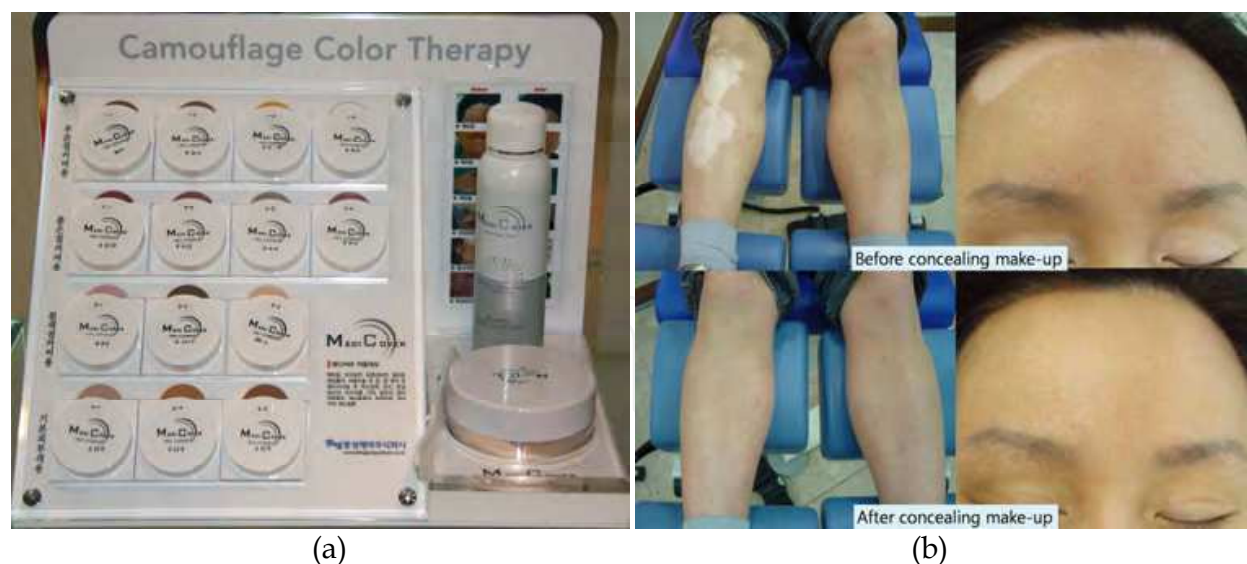

Fig. 6. (a). Concealer cosmetic set for vitiligo patients. (b). Patient before and after makeup. Courtesy of Dong-Sung Pharmaceutical, Co., Seoul, Korea.

Special makeup products are also helpful. Cosmetics are limited by their easy removability (can be washed away by sweat) and they can be messy (get on clothing), however tend to give vitiligo lesions the most natural skin color. Many patients prefer makeup, which can achieve cosmetically acceptable results in an investment of 20 minutes a day. Special makeup is acceptable, but it is more effective when combined with DHA or walnut solution. Figure 6 shows a patient before and after makeup. To maintain the stability of makeup where it is applied, non-glossy hair spray (Korean) or Caviol 3M™ spray (Tanioka & Miyachi, 2008) can be used after application of makeup. Some KAV patients use spray-on stockings on a DHA-primed leg lesion and results are often satisfactory. However, it is difficult for beginners to produce satisfactory results using various makeup products. The methods using DHA, walnut shell, and special makeup products all require hours of patient teaching and practice. Tanioka and Miyachi (2009) also emphasized the importance of lessons in camouflage techniques.

In terms of products for camouflage, a number of brands are available, including Dermablend™, Covermark™, Derma Color™, Dermage™, Elizabeth Arden Concealing Cream™, and Medi-Cover™. These are concealer-type cosmetics that are not easily washed away by sweat and come in a variety of skin colors.

Drula Pigment Cream™, Viti-color™, DY-O-Derm Vitiligo™, Chromelin Complexion Blender™, Mela-Pen™, Vitiligo Cover™ are also products for camouflage containing dihydroxyacetone (DHA). Drula Pigment Cream™ and Viti-color™ contains erythrulose, which has long-lasting effects. Vitiligo Cover™ contains both DHA and walnut shell.

5. Conclusion

Patients and doctors can safely combine modern medicines with reliable CAM all while encouraging healthy lifestyles in order to prevent vitiligo exacerbation. CAM is less effective for vitiligo compared to modern medicine although it has shown some merit in making use of the phototoxic, anti-congestion, anti-oxidant, anti-stress, and immune modulation properties of specific herbs and herbal combinations. Various natural foods and products can be another option for the treatment of vitiligo. Additionally, patients and doctors must

consider the often unexpected side effects of these products due to their unregulated ingredients. On the whole, topical treatment with CAM is relatively safe and effective. Camouflage is an efficient method for vitiligo in terms of cost-benefit ratio and improving quality of life. Various CAM modalities including TCM, health foods, good living habits, and camouflage combined with Western medicine, in the form of oral or topical medications, phototherapy, or excimer laser, can help these patients live happier lives with decreased disease burden.


6. References

- Abdel-Fattah, A.; Aboul-Enein, MN.; Wassel, GM. & El-Menshawi, BS. (1982). An approach to the treatment of vitiligo by khellin. *Dermatologica*. Vol.165, No.2, (August 1982), pp 136-140.
- Aghaei, S. & Ardekani, GS. (2008). Topical immunotherapy with diphenylcyclopropenone in vitiligo: a preliminary experience. *Indian J Dermatol Venereol Leprol*. Vol.74, No.6, (November 2008), pp628-631.
- Alikhan, A.; Felsten, LM.; Daly, M. & Petronic-Rosic, V. (2011). Vitiligo: A comprehensive overview Part I. Introduction, epidemiology, quality of life, diagnosis, differential diagnosis, associations, histopathology, etiology, and work-up. *J Am Acad Dermatol*. Vol.65, No.3, (September 2011), pp473-491.
- Arlt, VM.; Stiborova, M. & Schmeiser, HH. Aristolochic acid as a probable human cancer hazard in herbal remedies: a review. *Mutagenesis*. Vol.14, No.4, (July 2002), pp265-277.
- Bark, KM.; Heo, EP.; Han KD.; Kim, MB.; Lee, ST.; Gil, EM. & Kim, TH. (2010). Evaluation of the phototoxic potential of plants used in oriental medicine. *J Ethnopharmacol*. Vol.127, No.1, (January 2010), pp11-18.
- Cheung, WI.; Tse, ML.; Ngan, T.; Lin, J.; Lee, WK.; Poon, WT.; Mak, TW.; Leung, VK. & Chau, TN. (2009). Liver injury associated with the use of Fructus Psoraleae (Bol-gol-zhee or Bu-gu-zhi) and its related proprietary medicine. *Clin Toxicol (Phila)*. Vol.47, No.7, (August 2009), pp683-685.
- Choi, KT. (2008). Botanical characteristics, pharmacological effects and medicinal components of Korean Panax ginseng C A Meyer. *Acta pharmacol Sin*. Vol.29, No.9, (September 2008), pp1109-1118.
- Cosyns, JP.; Jadoul, M.; Squifflet JP.; De Plaen, JF.; Ferluga, D. & van Ypersele de Strihou, C. (1994). Chinese herbs nephropathy: a clue to Balkan endemic nephropathy? *Kidney Int*. Vol.46, No.6, (June 1994), pp1680-1688.
- Dharmananda, S. (August, 2011). Ayurvedic Herbal Medicine and its Relation to Chinese Herbal Medicine, 22/08/2011, Available from <http://www.itmonline.org/arts/ayurherb.htm>
- De Cuyper, C. (2008). Permanent makeup: indications and complications. *Clin Dermatol*. Vol.26, No.1, (January 2008), pp30-34.
- Dell'Anna, ML.; Mastrofrancesco, A.; Sala, R. *et al.* (2007). Antioxidants and narrow band-UVB in the treatment of vitiligo: a double-blind placebo controlled trial. *Clin Exp Dermatol*. Vol.32, No.6, (November 2007), pp631-636.
- FDA. (August 2011). Tattoos & Permanent Makeup. In: *Cosmetics*, 22/08/2011, Available from <http://www.fda.gov/Cosmetics/ProductandIngredientSafety/ProductInformation/ucm108530.htm>
- Felsten, LM.; Alikhan, A. & Petronic-Rosic, V. (2011). Vitiligo: A comprehensive overview Part II: Treatment options and approach to treatment. *J Am Acad Dermatol*. Vol.65, No.3, (September 2011), pp493-514.

- Fusaro, RM. & Rice, EG. (2005). The maillard reaction for sunlight protection. *Ann N Y Acad Sci.* Vol.1043, (June 2005), 174-183.
- Fuglsang, G.; Madsen, G.; Halken, S.; Jørgensen, S.; Ostergaard, PA. & Osterballe, O. (1994). Adverse reactions to food additives in children with atopic symptoms. *Allergy.* vol.49, No.1, (January 1994), pp31-37.
- Han, HJ.; Lee, BH.; Park, CW.; Lee, CH. & Kang, YS. (2005). A study of Nickel Content in Korean Foods. *Korean J Dermatol.* Vol.43, No.5, (May 2005), pp593-598.
- Hatzis, J.; Gourgiotou, K.; Tosca, A.; Varelzidis, A. & Stratigos, J. (1988). Vitiligo as a reaction to topical treatment with diphencyprone. *Dermatologica.* Vol.177, No.3, (September 1988), pp146-148.
- Humbert, P.; Pelletier, F.; Dreno, B.; Puzenat, E. & Aubin, F. (2006). Gluten intolerance and skin diseases. *Eur J Dermatol.* Vol.16, No.1, (January 2006), pp4-11.
- Jalel, A.; Soumaya, GS. & Hamdaoui, MH. (2009). Vitiligo treatment with vitamins, minerals and polyphenol supplementation. *Indian J Dermatol.* Vol.54, No.4, (October 2009), pp357-360.
- Jeon, S.; Kim, NH.; Koo, BS.; Lee, HJ. & Lee, AY. (2007). Bee venom stimulates human melanocyte proliferation, melanogenesis, dendricity and migration. *Exp Mol Med.* Vol.39, No.5, (October 2007), pp603-613.
- Kerscher, MJ. & Korting, HC. (1992). Treatment of atopic eczema with evening primrose oil: rationale and clinical results. *Clin Investig.* Vol.70, No.2, (February 1992), pp167-171.
- Kibbi, AG.; Rubeiz, NG.; Zaynoun, ST. & Kurban, AK. (1992). Primary localized cutaneous amyloidosis. *Int J Dermatol.* Vol.32, No.2, (February 1992), pp95-98.
- Kim, SN.; Ha, YW.; Shin, H. *et al.* (2007). Simultaneous quantification of 14 ginsenosides in Panax ginseng C.A. Meyer (Korean red ginseng) by HPLC-ELSD and its application to quality control. *J Pharm Biomed Anal.* Vol.45, No.1, (September 2007), pp164-170.
- Kirby, W.; Kaur, RR. & Desai, A. (2010). Paradoxical darkening and removal of pink tattoo ink. *J Cosmet Dermatol.* Vol.9, No.2, (June 2010), pp149-151.
- Korean Food & Drug Administration. (2007). *Instruction guide for safe use of Korean traditional medicine - mercuric sulfide, orpiment (arsenic).* (in Korean. Title translated by authors). Government Publications Registration Number (Korea) 11-1470000-001464-14, Seoul, Korea
- Kostović, K.; Pastar, Z.; Pasić, A. & Ceović, R. (2007). Treatment of vitiligo with narrow-band UVB and topical gel containing catalase and superoxide dismutase. *Acta Dermatovenereol Croat.* Vol.15, No.1, (January 2007), pp10-14.
- Kunisada, M.; Kumimoto, H.; Ishizaki, K.; Sakumi, K.; Nakabeppu, Y. & Nishigori, C. (2007). Narrow-band UVB induces more carcinogenic skin tumors than broad-band UVB through the formation of cyclobutane pyrimidine dimer. *J Invest Dermatol.* Vol.127, No.12, (December 2007), pp2865-2871.
- Lee, AY.; Kim, NH.; Choi, WI. & Youm, YH. (2005). Less keratinocyte-derived factors related to more keratinocyte apoptosis in depigmented than normally pigmented suction-blistered epidermis may cause passive melanocyte death in vitiligo. *J Invest Dermatol.* Vol.124, No.5, (May 2005), pp976-983.
- Lowney, YW.; Ruby, MV.; Wester, RC.; Schoof, RA.; Holm, SE.; Hui, XY.; Barbadillo, S. & Maibach, HI. (2005). Percutaneous absorption of arsenic from environmental media. *Toxicol Ind Health.* Vol.21, No.1-2, (March 2005), pp1-14.
- Majid, I. (2010). Topical placental extract: does it increase the efficacy of narrowband UVB therapy in vitiligo? *Indian J Dermatol Venereol Leprol.* Vol.76, No.3, (May 2010), pp 254-258.

- Middelkamp-Hup, MA.; Bos, JD.; Rius-Diaz F.; Gonzalez, S. & Westerhof, W. Treatment of vitiligo vulgaris with narrow-band UVB and oral Polypodium leucotomos extract: a randomized double-blind placebo-controlled study. *J Eur Acad Dermatol Venereol*. Vol.21, No.7, (August 2007), pp942-950.
- Mofty, ME.; Zaher, H.; Esmat, S.; Youssef, R.; Shahin, Z.; Bassioni, D. & Enani, GE. (2001). PUVA and PUVB in vitiligo--are they equally effective? *Photodermatol Photoimmunol Photomed*. Vol.17, No.4, (August 2001), pp159-163.
- Namazi, MR. & Chee Leok, GO. (2009). Vitiligo and diet: a theoretical molecular approach with practical implications. *Indian J Dermatol Venereol Leprol*. Vol.75, No.2, (March 2009), pp116-118.
- Park, SD.; Lee, SW.; Chun, JH. & Cha, SH. (2000). Clinical features of 31 patients with systemic contact dermatitis due to the ingestion of Rhus (lacquer). *Br J Dermatol*. 2000 May;142(5):937-42.
- Patel, DC.; Evans, AV. & Hawk, JL. (2002). Topical pseudocatalase mousse and narrowband UVB phototherapy is not effective for vitiligo: an open, single-centre study. *Clin Exp Dermatol*. Vol.27, No.8, (November 2002), pp641-644.
- Parsad, D.; Pandhi, R. & Juneja, A. (2003). Effectiveness of oral Ginkgo biloba in treating limited, slowly spreading vitiligo. *Clin Exp Dermatol*. Vol.28, No.3, (May 2003), pp285-287.
- Pires, MC.; Martins, JM.; Montealegre, F. & Gatti, FR. (2010). Vitiligo after diphenylprone for alopecia areata. *Dermatol Res Pract*. Vol. 2010, (May 2010), p171265.
- Rajatanavin, N.; Suwanachote, S. & Kulkollakarn, S. (2008). Dihydroxyacetone: a safe camouflaging option in vitiligo. *Int J Dermatol*. Vol.47, No.4, (April 2008), pp402-406.
- Ravish, K. (August 2011). Vitiligo diet, In: *Ayurhealthline*, 22,08,2011, Available from <http://www.ayurhealthline.com/Vitiligo-Diet.html>
- Rosenbach, T.; Wellenreuther, U.; Nurnberger, F. & Czarnetzki, BM. (1993). Treatment of vitiligo with phenylalanine and UV-A. *Hautarzt*. Vol.44, No.4, (July 1993), pp208-209.
- Saper, RB.; Kales, SN.; Paquin, J.; Burns, MJ.; Eisenberg, DM.; Davis, RB. & Phillips, RS. (2004). Heavy metal content of ayurvedic herbal medicine products. *JAMA*. Vol.292, No.23, (December 2004), pp2868-2873.
- Sarveswari, KN. (2010). Cosmetic camouflage in vitiligo. *Indian J Dermatol*. Vol.55, No.3, (July 2010), pp211-214.
- Schallreuter, KU.; Wood, JM.; Lemke, KR. & Levenig, C. (1995). Treatment of vitiligo with a topical application of pseudocatalase and calcium in combination with short-term UVB exposure: a case study on 33 patients. *Dermatology*. Vol.190, No.3, (March 1995), pp223 -229.
- Schallreuter, KU.; Moore, J.; Wood, JM.; Beazley, WD.; Gaze, DC.; Tobin, DJ.; Marshall, HS.; Panske, A.; Panzig, E. & Hibberts, NA. (1999). In vivo and in vitro evidence for hydrogen peroxide (H₂O₂) accumulation in the epidermis of patients with vitiligo and its successful removal by a UVB-activated pseudocatalase. *J Invest Dermatol Symp Proc*. Vol.4, No.1, (September 1999), pp91-96.
- Schallreuter, KU.; Moore, J.; Wood, JM.; Beazley, WD.; Peters, EM.; Marles, LK.; Behrens-Williams, SC.; Dummer, R.; Blau, N. & Thöny, B. (2001). Epidermal H₂O₂ accumulation alters tetrahydrobiopterin (6BH₄) recycling in vitiligo: identification of a general mechanism in regulation of all 6BH₄-dependent processes? *J Invest Dermatol*. Vol.116, No.1, (January 2001), pp167-174.
- Schallreuter, KU & Rokos, H. (2005). Vitix-a new treatment for vitiligo? *Int J Dermatol*. Vol.44, No.11, (November 2005), pp969-970.
- Serrano, G.; Lorente, M.; Reyes, M.; Millan, F.; Lloret, A; Melendez, J.; Navarro, M. & Navarro, M. (2009). Photodynamic therapy with low-strength ALA, repeated

- applications and short contact periods (40-60 minutes) in acne, photoaging and vitiligo. *J Drugs Dermatol*. Vol.8, No.6, (June 2009), pp562-568.
- Sharma, AD. (2007). Relationship between nickel allergy and diet. *Indian J Dermatol Venereol Leprol*. Vol.73, No.5, (September 2007), pp307-312.
- Shin, JU.; Roh, MR. & Lee, JH. (2010). Vitiligo following intense pulsed light treatment. *J Dermatol*. Vol.37, No.7, (July 2010), pp674-676.
- Siddiqui, AH.; Stolk, LM.; Bhaggoe, R.; Hu, R.; Schutgens, RB. & Westerhof, W. (1994). L-phenylalanine and UVA irradiation in the treatment of vitiligo. *Dermatology*. Vol.188, No.3, (March 1994), pp215-218.
- Simopoulos, AP. (2002). Omega-3 fatty acids in inflammation and autoimmune diseases. *J Am Coll Nutr*. Vol.21, No.6, (December 2002), pp495-505.
- Singh, AK. & Karki, D. (2010). Micropigmentation: tattooing for the treatment of lip vitiligo. *J Plast Reconstr Aesthet Surg*. Vol.63, No.6, (June 2010), pp988-991.
- Srivastava, RK. (August, 2011). *Vitiligo (leukoderma) Ayurvedic treatment*. 22/08/2011, Available from <http://ayurveda-foryou.com/treat/leucoderma.html>.
- Suga, Y.; Ikejima, A.; Matsuba, S. & Ogawa, H. (2002). Medical pearl: DHA application for camouflaging segmental vitiligo and piebald lesions. *J Am Acad Dermatol*. Vol.47, No.3, (September 2002), pp436-438.
- Szczurko, O.; Shear, N.; Taddio, A. & Boon, H. (2011). Ginkgo biloba for the treatment of vitiligo vulgaris: an open label pilot clinical trial. *BMC Complement Altern Med*. Vol.11, (March 2011), p21.
- Spritz, RA. (2011). Recent progress in the genetics of generalized vitiligo. *J Genet Genomics*. Vol.38, No.7, (July 2011), pp271-278.
- Taïeb, A. & Picardo, M. (2009). Clinical practice. Vitiligo. *N Engl J Med*. Vol.362, No.2, (January 2009), pp160-169.
- Tanioka, M. & Miyachi, Y. (2008). Waterproof camouflage for vitiligo of the face using Cavilon 3M as a spray. *Eur J Dermatol*. Vol.18, No.1, (January 2008), pp93-94.
- Tanioka, M. & Miyachi, Y. (2009). Camouflage for vitiligo. *Dermatol Ther*. Vol.22, No.1, (January 2009), pp90-93.
- Tanioka, M.; Yamamoto, Y.; Kato, M. & Miyachi, Y. (2010). Camouflage for patients with vitiligo vulgaris improved their quality of life. *J Cosmet Dermatol*. Vol.9, No.1, (March 2010), pp72-75.
- Teschke, R. & Bahre, R. (2009). Severe hepatotoxicity by Indian Ayurvedic herbal products: a structured causality assessment. *Ann Hepatol*. Vol.8, No.3, (July 2009), pp258-266.
- Vanherweghem, JL.; Depierreux, M.; Tielemans, C.; Abramowicz, D.; Dratwa, M.; Jadoul, M.; Richard, C. *et al.* (1993). Rapidly progressive interstitial renal fibrosis in young women: association with slimming regimen including Chinese herbs. *Lancet*. Vol.341, No.8842, (February 1993), pp387-391.
- Yuksel, EP.; Aydin, F.; Senturk, N.; Canturk, T. & Turanli, AY. (2009). Comparison of the efficacy of narrow band ultraviolet B and narrow band ultraviolet B plus topical catalase-superoxide dismutase treatment in vitiligo patients. *Eur J Dermatol*. Vol.19, No.4, (July 2009), pp341-344.



Vitiligo - Management and Therapy

Edited by Dr. Kelly KyungHwa Park

ISBN 978-953-307-731-4

Hard cover, 174 pages

Publisher InTech

Published online 14, December, 2011

Published in print edition December, 2011

Vitiligo: Management and Therapy is a practical guide to vitiligo that reflects current research related to the fundamentals of vitiligo and its management. Vitiligo experts and researchers from all over the world have contributed to this text, accounting for its comprehensive nature and diverse array of topics. The recent advances in medicine and technology have led to a better understanding of the disease and have broadened available treatment options. The essentials are captured in this book and are complemented by useful clinical photographs and reference tables. This concise tool will serve as an invaluable resource for clinicians in daily practice.

How to reference

In order to correctly reference this scholarly work, feel free to copy and paste the following:

Jimi Yoon, Young-Woo Sun and Tae-Heung Kim (2011). Complementary and Alternative Medicine for Vitiligo, Vitiligo - Management and Therapy, Dr. Kelly KyungHwa Park (Ed.), ISBN: 978-953-307-731-4, InTech, Available from: <http://www.intechopen.com/books/vitiligo-management-and-therapy/complementary-and-alternative-medicine-for-vitiligo>

INTech
open science | open minds

InTech Europe

University Campus STeP Ri
Slavka Krautzeka 83/A
51000 Rijeka, Croatia
Phone: +385 (51) 770 447
Fax: +385 (51) 686 166
www.intechopen.com

InTech China

Unit 405, Office Block, Hotel Equatorial Shanghai
No.65, Yan An Road (West), Shanghai, 200040, China
中国上海市延安西路65号上海国际贵都大饭店办公楼405单元
Phone: +86-21-62489820
Fax: +86-21-62489821

© 2011 The Author(s). Licensee IntechOpen. This is an open access article distributed under the terms of the [Creative Commons Attribution 3.0 License](https://creativecommons.org/licenses/by/3.0/), which permits unrestricted use, distribution, and reproduction in any medium, provided the original work is properly cited.

IntechOpen

IntechOpen