

We are IntechOpen, the world's leading publisher of Open Access books Built by scientists, for scientists

6,900

Open access books available

186,000

International authors and editors

200M

Downloads

Our authors are among the

154

Countries delivered to

TOP 1%

most cited scientists

12.2%

Contributors from top 500 universities



WEB OF SCIENCE™

Selection of our books indexed in the Book Citation Index
in Web of Science™ Core Collection (BKCI)

Interested in publishing with us?
Contact book.department@intechopen.com

Numbers displayed above are based on latest data collected.
For more information visit www.intechopen.com



Segmental Vitiligo

Ji-Hye Park and Dong-Youn Lee

*Department of Dermatology, Samsung Medical Center
Sungkyunkwan University, Seoul
South Korea*

1. Introduction

Vitiligo is largely classified into segmental and non-segmental types (Table 1).¹ This classification is based on the original report by Koga in 1977.² Koga proposed that vitiligo in a non-dermatomal distribution be referred to as *Type A* and vitiligo in a dermatomal distribution be *Type B*, the latter of which corresponds to what is known today as **segmental vitiligo (SV)**. Since then, the distinctive characteristics of SV have been described.³⁻⁶ Recently, it was proposed that vitiligo be classified into four major types: segmental, non-segmental, mixed, and unclassified.⁷

The incidence of SV is not well-established because different investigators report variable percentages of patients having SV. El-Mofty *et al* reported that only 5% of patients with vitiligo had the segmental type.⁸ Koga and Tango described that in their population, 27.9% had SV.³ Several studies in Korea revealed the prevalence of SV to range from 5.5% to 29.6%.^{4,9,10}

The typical lesion of SV is not significantly different from that of NSV. Both can initially appear as focal vitiligo, which involves a small area.¹¹ However, SV has a distinct natural history and unique clinical features.^{1,3,4} In addition, SV shows different therapeutic characteristics when compared with NSV.^{1,12}

SV can appear at any age, but the majority of cases occur early in life between the ages of 5 and 30 years old. Koga and Tango reported that 82% of type B vitiligo (SV) patients noticed their first depigmented patches before the age of 30.³ In the pivotal SV study by Hann and Lee, the mean age of onset was 15.6 years, and SV developed before 10 years of age in 41% of cases, and before 30 years of age in 87%.⁴ In our study, the mean age of onset was 19.8 years; 32% of SV started before 10 years of age and 62% before 20 years of age.⁶

SV typically presents with unilateral involvement of depigmented macules surrounded by normal skin. The color of the macules is usually white and more distinguishable with Wood's light examination. However, macules may have a more irregular border and less homogeneous pattern of pigment loss than NSV.¹¹ Trichrome vitiligo, which is characterized by both depigmented and hypopigmented macules, is reported in SV.¹³

SV shows a quasi-dermatomal mode of distribution, but seems to be different from the pattern of herpes zoster. SV often involves a segment that includes the parts of several dermatomes and may at times, go over the midline partially. Some cases may involve lines or large bands consistent with Blaschko's lines.^{14,15} There is no preferential distribution between right and left sides of the body. Very rarely, SV involves two or more different segments with ipsilateral or contralateral distribution. Lee and Hann reported that 5 of 240 SV cases showed bilateral SV on the same or different dermatomes that appeared on both sides of the body.¹⁶

The face is the most common site of SV regardless of gender (Figure 1). According to the Hann and Lee study, 51% of SV involved the face, 25% the trunk (Figure 2), and 11% the extremities. In our own study, 54% of SV involved only the face.⁴ An additional 17% had both face and neck involvement of SV (Figure 3).⁶

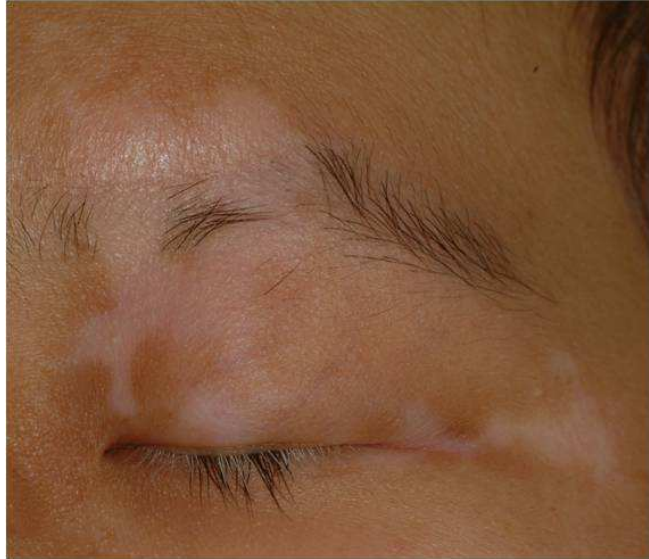

Fig. 1. Segmental vitiligo on the face.

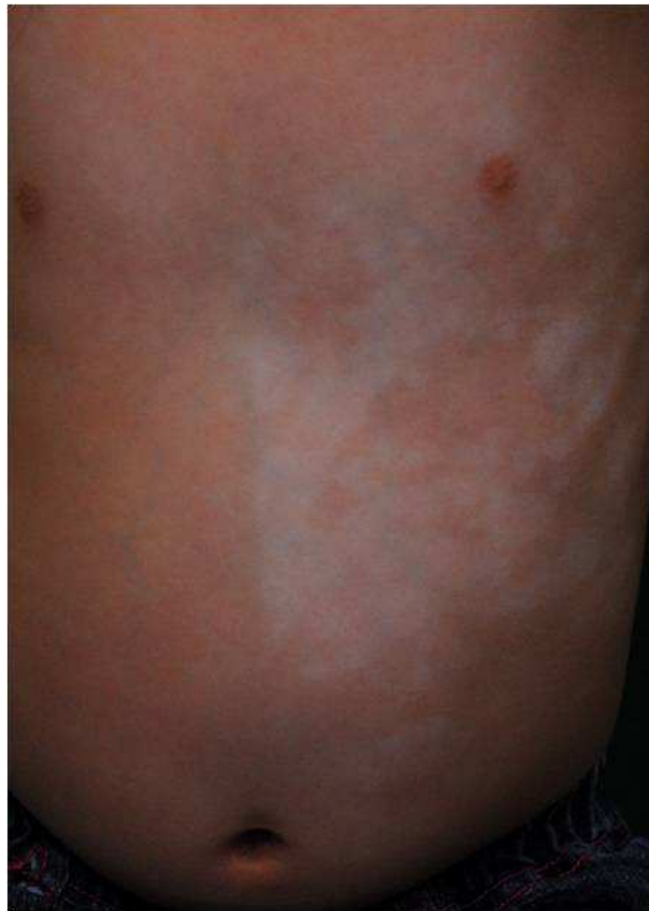

Fig. 2. Segmental vitiligo on the abdomen.

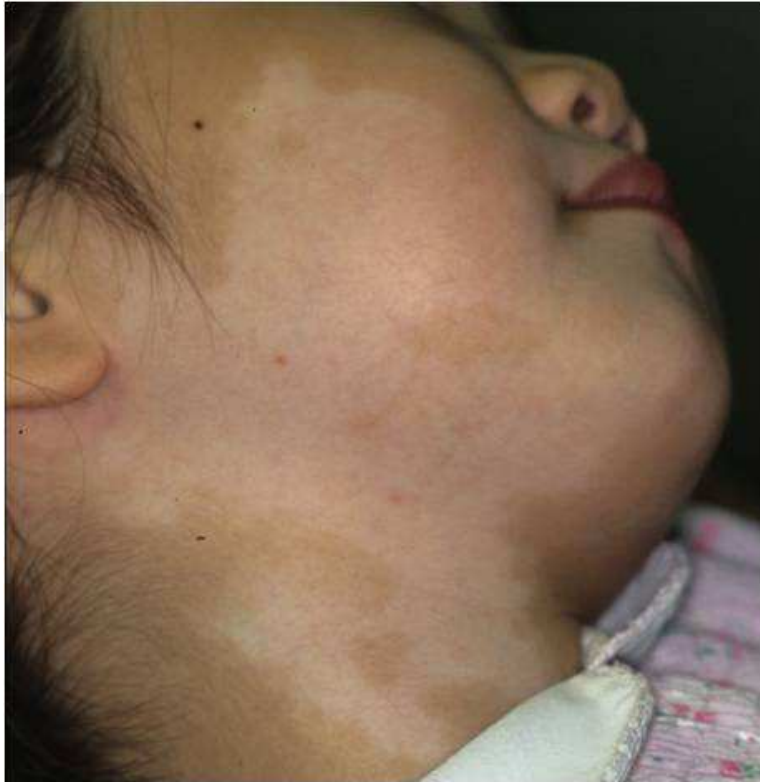

Fig. 3. Segmental vitiligo on the face and neck.

Hann *et al* proposed the original classification of the SV distribution of the face.¹⁷ This was revised to include 6 types depending on pattern and area of involvement.¹⁵ This classification may be valuable for certain aspects of prognosis, such as the likely degree and path of lesional spread.

SV is often associated with the occurrence of white hair (*i.e.*, poliosis, leukotrichia) in lesional skin. SV tends to involve the hair compartment soon after onset compared to NSV.¹ Hann and Lee reported that poliosis was found in 49% of 208 patients with SV.⁴ The eyebrow (Figure 4) and eyelashes commonly show white hair and other hair-bearing sites including the scalp, pubis, and axilla can be involved. However, it is very difficult to notice the presence of white hairs on other areas of the body with the naked eye because the hairs consist of tiny, thin vellus hairs. We examined 82 patients for the presence of leukotrichia in SV lesions using a digital portable microscope. All of the patients demonstrated leukotrichia independent of age and disease duration (Figure 5).^{6,18} The amount of white hair was variable. These results suggest that a very high percentage of patients with SV have associated leukotrichia.

It has been reported that SV usually spreads within a segment in a short period of time and then tends to stop.^{3,4} However, in our own study, we observed 87 patients who had SV for mean of 29.5 months (maximum 150 months), 19 cases (21.8%) showed disease progression 4 years after disease onset (2011 IPCC presentation). Therefore, more long-term follow-up data are needed in order to more accurately understand the natural course and the long-term recurrence rate of SV.

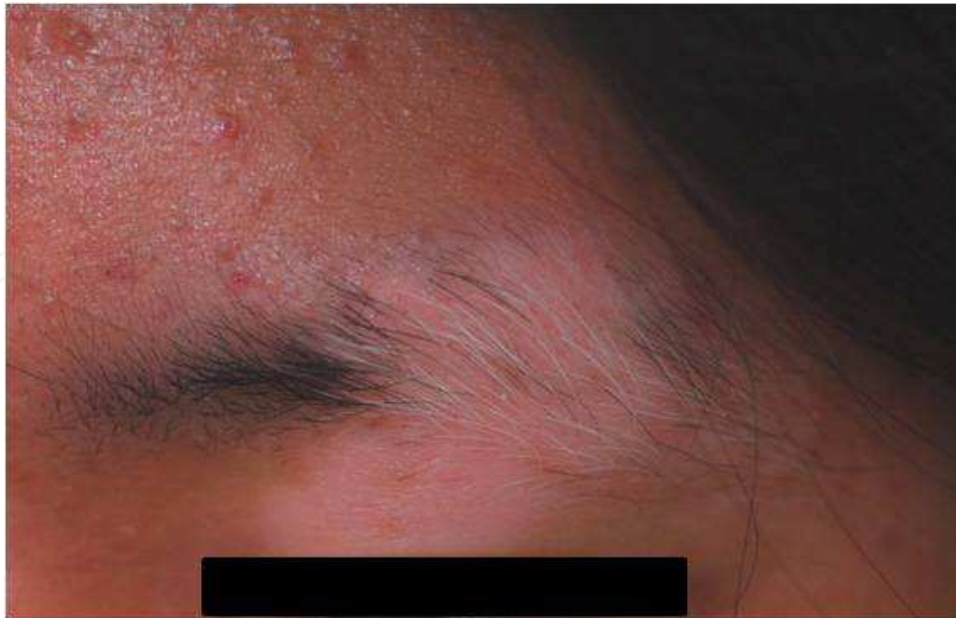

Fig. 4. White hairs of the eyebrow in segmental vitiligo can be seen.



Fig. 5. Leukotrichia in a segmental vitiligo lesion can be seen easily using portable digital microscopy (magnified 30x)

It has been proposed that the rare instance of SV progresses into a generalized form, that this be called mixed vitiligo.¹⁹ However, this likely represents only the rare circumstance of concurrent SV and NSV rather than its own independent vitiligo type.

SV is not usually accompanied by other autoimmune diseases contrary to NSV.^{1,3,8} However, Park *et al* reported that about 9.5% of SV cases were associated with other diseases²⁰ and Hann *et al* described that 6.7% of 208 patients had an associated disease, including atopic dermatitis, halo nevus, thyroid disease, diabetes mellitus, and alopecia areata.⁴

Segmental Vitiligo	Non-Segmental Vitiligo
Often early age of onset	Variable age of onset
Usually unilateral	Usually bilateral
Is known to spread rapidly and stabilize in a few years*	Usually chronic and progressive course
Predictable course	Unpredictable course
Very high percentage of white hairs (leukotrichia) of lesional skin in early stage disease	Variable percentage of white hairs (leukotrichia) of lesional skin
Shows good response to autologous grafting	Shows unpredictable results after autologous grafting
Is not usually associated with autoimmune disease	Is often associated with personal or family history of autoimmune disease

*Long-term data is still warranted.

Table 1. Comparison of Segmental Vitiligo and Non-Segmental Vitiligo

2. Treatment of segmental vitiligo

Segmental vitiligo (SV) is a distinct type of vitiligo in terms of its clinical features, natural course, and response to treatment, that make it distinguishable from non-segmental vitiligo (NSV).^{1,2} In SV, white macules are usually localized to one segment on only one side of the body, however, in NSV white macules can occur at any body location and disease activity tends to persist throughout the life of the patient. Thus, the course of SV is predictable while that of NSV is unpredictable. Treatment guidelines of SV may be easier to determine than those of NSV.

Until now, many articles about vitiligo treatment have been published. However, many of these studies were not randomized, controlled, and double-blinded, but rather retrospective studies or case reports. In addition, many studies did not distinguish between the types of vitiligo or they did not provide demographic information about SV in detail. Thus, reliable publications about the treatment of SV are scarce.

The treatment modalities for vitiligo largely consist of medical and surgical therapies.²¹ Medical management includes topical corticosteroids and immunomodulators, and phototherapy such as narrow-band UVB (NB-UVB) and excimer laser. If medical treatment is unsatisfactory, surgical treatments such as autologous skin grafting may be considered. Taïeb and Picardo presented treatment guidelines for vitiligo in a review.¹

2.1 Topical corticosteroids

Topical corticosteroids have been used for the treatment of vitiligo for decades. There have only been a few studies about the effects of topical corticosteroids in SV.

Koga evaluated the effect of topical corticosteroids in vitiligo patients.² In this study, only five patients with SV were included and received topical steroid therapy (0.12% betamethasone-17-valerate, 0.01% fluocinolone acetonide, or 0.1% triamcinolone acetonide cream or ointment) for a minimum of 2 months. However, no improvement was found in any of these patients.

Khalid and Mujtaba treated forty SV patients with 0.05% clobetasol propionate cream twice daily.²² Therapy was interrupted every 6 weeks for a 2-week treatment-free period. Some

response was observed in the majority of patients (79%, 30 out of 38) and more than 50% repigmentation was observed in 34% (13) of patients. The best results were found on the face. Out of the 23 patients who presented within 1 year of SV onset, 11 (47.8%) showed more than 50% repigmentation; on the other hand, only two out of 15 (13.3%) patients who presented after one year of the onset of SV achieved the same degree of response. The side effects were mild skin atrophy in six patients, telangiectasias in four patients, and acneiform papules in eight patients. These results suggest that disease duration may be an important indicator of prognosis because most of the patients showing more than 50% repigmentation presented within one year of SV onset.

2.2 Topical immunomodulators (calcineurin inhibitors)

Several studies have demonstrated the efficacy of tacrolimus ointment and pimecrolimus cream in the treatment of vitiligo patients. However, most of them did not disclose the inclusion of SV.

Silverberg *et al* assessed the efficacy of topical tacrolimus ointment in the treatment of childhood vitiligo.²³ Fifty-seven patients were treated with tacrolimus ointment (0.03% or 0.1%) once or twice daily for a minimum of three months. In their series, 37% of the patients had SV, most commonly of the head and/or neck. Among the SV patients, 86% responded to tacrolimus ointment, especially those with facial involvement (94%). One patient showed complete repigmentation on the chin and neck after eight weeks of summer sun exposure along with twice daily tacrolimus 0.03% ointment.

Udompataikul *et al* evaluated the effectiveness of 0.1% tacrolimus ointment in 42 vitiligo patients, of whom eleven patients had SV.²⁴ The overall response rate, defined as at least some evidence of repigmentation, was 76% and the response rate for SV was 77%.

2.3 Phototherapy

Phototherapy has been widely used for the treatment of vitiligo. However, most studies about phototherapy in vitiligo were performed in patients with NSV.

1. NB-UVB

Anbar *et al* evaluated the clinical response of vitiligo patients to NB-UVB. Their study included 150 patients with SV (10%) or NSV (90%).²⁵ NB-UVB therapy was given twice weekly. In the NSV group, 48% of patients showed a marked response (more than 75% repigmentation) and 27% showed a moderate response (between 26% and 75% repigmentation). However, in the SV group, 92.3 % showed no more than a mild response (less than 25% repigmentation) to treatment regardless of the lesion site, and only 7.7% of SV patients showed a moderate response.

NB-UVB microphototherapy uses a device that delivers a focused beam with wavelengths from 300 to 320 nanometers (nm) with a peak emission of 311 nm. Lotti *et al* evaluated the effectiveness of UVB microphototherapy for eight SV patients for six months.²⁶ Five patients achieved normal pigmentation on more than 75% of their treated areas.

2. PUVA

Tallab *et al* evaluated the efficacy of systemic psoralen and ultraviolet A (PUVA) in the treatment of vitiligo retrospectively.²⁷ Thirty-two patients with vitiligo were studied, including five patients with SV. All of the SV patients showed no or poor repigmentation. They concluded that SV was very resistant to PUVA therapy.

3. Excimer laser

The 308 nm excimer laser has demonstrated promising efficacy and appealing side effect profile for localized vitiligo.^{28,29} Compared with conventional NB-UVB, excimer laser generally provides more rapid repigmentation in limited forms of vitiligo.

Do *et al* performed a retrospective analysis to evaluate the treatment response to excimer laser in SV patients.³⁰ Eighty patients with SV were included. Repigmentation was graded as: grade 0, no repigmentation; grade 1, 1–24%; grade 2, 25–49%; grade 3, 50–74%; grade 4, 75–99%; grade 5, complete repigmentation. The mean grade of repigmentation was 2.3 after a mean of 20.6 months of treatment; 23.8% showed grade 4, 20% showed grade 3, and 56.2% showed grade 1–2 repigmentation. However, none of them achieved complete repigmentation. They observed that SV had a better repigmentation response rate when the excimer laser was used at earlier stages of the disease for longer treatment durations with high cumulative UV energy. However, the limitation of their study was that many patients received other concurrent treatments such as oral corticosteroids, topical steroids, or topical tacrolimus ointment during the study period.

4. Miscellaneous Therapies

We retrospectively evaluated the effect of phototherapy in nine patients with SV depending on the disease duration.³¹ All patients except one had SV for longer than two years when they started on a phototherapy regimen of PUVA, NB-UVB, or excimer laser. All patients showed a poor response to phototherapy irrespective of the type of phototherapy administered. Our results suggest that phototherapy is not helpful in long-duration SV.

It has been reported that the combination of NB-UVB and tacrolimus ointment is effective in vitiligo.³² However, this combination treatment of NB-UVB and tacrolimus ointment in SV is limited to case reports.

We presented two cases of recent onset SV that showed good or excellent response to targeted phototherapy (Dualight®) in combination with drug therapy.³³ Our results suggest that SV can be improved with combination therapy if SV onset is recent, emphasizing that early treatment may be essential for this type of vitiligo. In addition, we reported a case of SV that showed a marked response to combination NB-UVB and 0.1% topical tacrolimus compared with 0.1% topical tacrolimus alone.³⁴ This case suggests that combination therapy is necessary for SV.

Low-energy helium-neon laser (632.8 nm) has applications in a variety of clinical conditions including vitiligo. Yu *et al* evaluated the efficacy of the helium-neon laser on thirty patients with SV on the head and/or neck.³⁵ Marked repigmentation (more than 50%) was observed in 60% of patients.

2.4 Surgical treatment

Generally, surgical treatment is indicated for stable vitiligo that does not respond to medical treatment.³⁶ Patients with SV are considered a good candidates for surgical treatment.²¹ Although medical treatment is often helpful in SV, complete repigmentation is almost always difficult to obtain. Thus, surgical treatment is necessary for complete repigmentation in many cases of SV. Surgical treatment includes autologous epidermal grafting (Figure 6), mini-grafting, and transplantation of epidermal cell suspensions.²¹

Gupta and Kumar analyzed a retrospective, uncontrolled case series and literature review of 143 patients treated with epidermal grafting. They found that repigmentation success rates for generalized and segmental (including focal) vitiligo were 53 and 91%, respectively.³⁷

In epidermal grafting surgeries, oral corticosteroids may be a helpful adjunct. We reported that in a case of SV with failure to repigment with surgery alone, that response occurred

when oral corticosteroid was added to the grafting procedure.³⁸ In addition, we also presented that achieving better results in SV may be contingent on combination therapy utilizing epidermal grafting with systemic corticosteroids.³⁹ SV may continue to spread even a few years after onset of disease. We presented a case of SV which continued to spread after epidermal grafting; the new lesions did not involve the area of previous epidermal grafting, but repeated epidermal grafting was successful.⁴⁰ This case indicates that epidermal grafting can be useful for the treatment of SV although recurrence may arise.

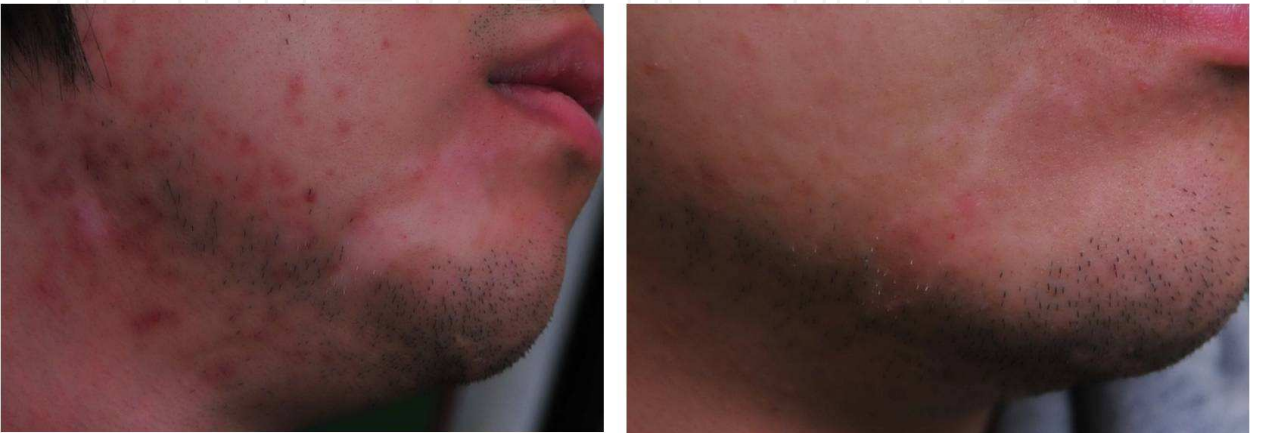

Fig. 6. Before (left) and after (right) epidermal grafting in segmental vitiligo.

In vitiligo lesions with leukotrichia present, the possibility of repigmentation may be minimal or absent because the loss of hair melanocytes is usually permanent, and repigmentation may not occur even with medical treatment. We found that the majority of white hairs in SV may contribute to the lack of response to medical treatment and require surgical treatment such as epidermal grafting.⁶

First-Line
- Topical treatment (topical corticosteroids, calcineurin inhibitors) and narrow-band UVB (NB-UVB) therapy or targeted phototherapy (<i>i.e.</i> , excimer laser) for at least 3 months. If there is treatment response, continue the regimen for 1 year.
- If the majority of hairs in the lesional skin are white (leukotrichia), consider surgical treatment.
Second-Line
- Consider surgical treatment if medical treatment is unsatisfactory.

Table 2. Treatment Guidelines for Segmental Vitiligo


Based on previous reports and our experiences, we recently proposed a set of treatment guidelines in SV.¹² Treatments such as topical corticosteroids and topical calcineurin inhibitors, as well as phototherapy, including NB-UVB and targeted phototherapy (*e.g.*, excimer laser) are helpful for SV.^{23,26,30} Available data suggests that combination topical treatment and phototherapy is more efficacious in SV than any type of monotherapy.^{33,34} In addition, disease duration in SV is very important to consider to gauge response to medical treatment.^{22,24,30} Thus, as first-line therapy, we recommend the combination of topical treatment and phototherapy to be initiated as early as possible. However, our experience suggests that phototherapy is not helpful in SV patients with the majority of hairs in lesional

skin being white.⁶ Therefore, in these cases, we recommend first-line treatment be surgery in order to avoid delay as well as unnecessary and inefficacious treatment. These guidelines will contribute to future definitive treatment guidelines for SV (Table 2).

3. References

- [1] Taïeb A, Picardo M. Clinical practice. Vitiligo. *N Engl J Med* 2009;360:160-169
- [2] Koga M. Vitiligo: a new classification and therapy. *Br J Dermatol* 1977;97:255-261
- [3] Koga M, Tango T. Clinical features and course of type A and type B vitiligo. *Br J Dermatol* 1988;118:223-228
- [4] Hann SK, Lee HJ. Segmental vitiligo: clinical findings in 208 patients. *J Am Acad Dermatol* 1996;35:671-674
- [5] Mazereeuw-Hautier J, Bezio S, Mahe E, et al. Segmental and nonsegmental childhood vitiligo has distinct clinical characteristics: a prospective observational study. *J Am Acad Dermatol*. 2010;62:945-9.
- [6] Lee DY, Kim CR, Park JH, et al. The incidence of leukotrichia in segmental vitiligo: implication of poor response to medical treatment. *Int J Dermatol* 2011;50:925-927
- [7] Taïeb A, Picardo M. Epidemiology, definitions and classification. In: Picardo M, Taïeb A, eds. *Vitiligo*, 1st edn. Berlin: Springer, 2010: 13-24.
- [8] El-Mofty AM, el-Mofty M. Vitiligo. A symptom complex. *Int J Dermatol* 1980;19:237-244
- [9] Song MS HS, Ahn PS, Im S, Park YK. Clinical study of vitiligo: Comparative study of type A and type B vitiligo. *Ann Dermatol* 1994;6:22-30
- [10] Bang JS Lee JW, Kim TH, et al. Comparative clinical study of segmental and non-segmental vitiligo. *Kor J Dermatol* 2000;38:1037-1044
- [11] Taïeb A, Picardo M. The definition and assessment of vitiligo: a consensus report of the Vitiligo European Task Force. *Pigment Cell Res* 2007;20:27-35
- [12] Lee DY, Choi SC. A proposal for the treatment guideline in segmental vitiligo. *Int J Dermatol* 2011 in press
- [13] Lee DY, Kim CR, Lee JH. Trichrome vitiligo in segmental type. *Photodermatol Photoimmunol Photomed* 2011;27:111-112
- [14] Taïeb A, Morice-Picard F, Jouary T, et al. Segmental vitiligo as the possible expression of cutaneous somatic mosaicism: implications for common non-segmental vitiligo. *Pigment Cell Melanoma Res* 2008;21:646-652
- [15] Kim DY, Oh SH, Hann SK. Classification of segmental vitiligo on the face: clues for prognosis. *Br J Dermatol* 2011;164:1004-1009
- [16] Lee HS, Hann SK. Bilateral segmental vitiligo. *Ann Dermatol* 1998;10:129-131
- [17] Hann SK, Chang JH, Lee HS, et al. The classification of segmental vitiligo on the face. *Yonsei Med J* 2000;41:209-212
- [18] Lee DY, Park JH, Lee JH, et al. Is segmental vitiligo always associated with leukotrichia? Examination with a digital portable microscope. *Int J Dermatol* 2009;48:1262.
- [19] Ezzedine K, Gauthier Y, Leaute-Labreze C, et al. Segmental vitiligo associated with generalized vitiligo (mixed vitiligo): A retrospective case series of 19 patients. *J Am Acad Dermatol* 2011 in pres
- [20] Park KC, Youn JI, Lee YS. Clinical study of 326 cases of vitiligo. *Korean J Dermatol* 1988;26:200-205
- [21] Falabella R, Barona MI. Update on skin repigmentation therapies in vitiligo. *Pigment Cell Melanoma Res* 2009;22:42-65

- [22] Khalid M, Mujtaba G. Response of segmental vitiligo to 0.05% clobetasol propionate cream. *Int J Dermatol* 1998;37:705-8
- [23] Silverberg NB, Lin P, Travis L, et al. Tacrolimus ointment promotes repigmentation of vitiligo in children: a review of 57 cases. *J Am Acad Dermatol* 2004;51:760-6
- [24] Udompataikul M, Boonsupthip P, Siri wattanagata R. Effectiveness of 0.1% topical tacrolimus in adult and children patients with vitiligo. *J Dermatol* 2011;38:536-40
- [25] Anbar TS, Westerhof W, Abdel-Rahman AT, et al. Evaluation of the effects of NB-UVB in both segmental and non-segmental vitiligo affecting different body sites. *Photodermatol Photoimmunol Photomed* 2006;22:157-163
- [26] Lotti TM, Menchini G, Andreassi L. UV-B radiation microphototherapy. An elective treatment for segmental vitiligo. *J Eur Acad Dermatol Venereol*. 1999;13:102-8
- [27] Tallab T, Joharji H, Bahamdan K, et al. Response of vitiligo to PUVA therapy in Saudi patients. *Int J Dermatol* 2005;44:556-558
- [28] Spencer JM, Nossa R, Ajmeri J. Treatment of vitiligo with the 308-nm excimer laser: a pilot study. *J Am Acad Dermatol* 2002;46:727-731
- [29] Nicolaidou E, Antoniou C, Stratigos A, et al. Narrowband ultraviolet B phototherapy and 308-nm excimer laser in the treatment of vitiligo: a review. *J Am Acad Dermatol* 2009;60:470-477
- [30] Do JE, Shin JY, Kim DY, et al. The effect of 308nm excimer laser on segmental vitiligo: a retrospective study of 80 patients with segmental vitiligo. *Photodermatol Photoimmunol Photomed* 2011;27:147-151
- [31] Lee DY, Park JH, Lee JH, et al. Surgical treatment is indicated in long-duration segmental vitiligo. *Dermatol Surg* 2010;36:568-9
- [32] Fai D, Cassano N, Vena GA. Narrow-band UVB phototherapy combined with tacrolimus ointment in vitiligo: a review of 110 patients. *J Eur Acad Dermatol Venereol*. 2007;21:916-20
- [33] Lee DY, Kim CR, Lee JH. Targeted phototherapy in combination with drug therapy for segmental vitiligo. *Photodermatol Photoimmunol Photomed* 2011;27:108-110
- [34] Kim CR, Lee DY. Combination of narrow band UVB and topical tacrolimus is effective for segmental vitiligo 2011 *Int J Dermatol* in press
- [35] Yu HS, Wu CS, Yu CL, et al. Helium-neon laser irradiation stimulates migration and proliferation in melanocytes and induces repigmentation in segmental-type vitiligo. *J Invest Dermatol* 2003;120:56-64
- [36] Parsad D, Gupta S; IADVL Dermatosurgery Task Force. Standard guidelines of care for vitiligo surgery. *Indian J Dermatol Venereol Leprol*. 2008;74 Suppl:S37-45.
- [37] Gupta S, Kumar B. Epidermal grafting in vitiligo: influence of age, site of lesion, and type of disease on outcome. *J Am Acad Dermatol* 2003;49:99-104
- [38] Lee KJ, Choi YL, Kim JA, et al. Combination therapy of epidermal graft and systemic corticosteroid for vitiligo. *Dermatol Surg* 2007;33:1002-1003
- [39] Lee DY, Lee KJ, Choi SC, et al. Segmental vitiligo treated by the combination of epidermal grafting and systemic corticosteroids. *Dermatol Surg* 2010;36:575-576
- [40] Lee DY, Park JH, Lee JH, et al. Recurrence of segmental vitiligo after epidermal grafting does not involve epidermal grafting area. *Clin Exp Dermatol* 2010;35:205-6



Vitiligo - Management and Therapy

Edited by Dr. Kelly KyungHwa Park

ISBN 978-953-307-731-4

Hard cover, 174 pages

Publisher InTech

Published online 14, December, 2011

Published in print edition December, 2011

Vitiligo: Management and Therapy is a practical guide to vitiligo that reflects current research related to the fundamentals of vitiligo and its management. Vitiligo experts and researchers from all over the world have contributed to this text, accounting for its comprehensive nature and diverse array of topics. The recent advances in medicine and technology have led to a better understanding of the disease and have broadened available treatment options. The essentials are captured in this book and are complemented by useful clinical photographs and reference tables. This concise tool will serve as an invaluable resource for clinicians in daily practice.

How to reference

In order to correctly reference this scholarly work, feel free to copy and paste the following:

Ji-Hye Park and Dong-Youn Lee (2011). Segmental Vitiligo, Vitiligo - Management and Therapy, Dr. Kelly KyungHwa Park (Ed.), ISBN: 978-953-307-731-4, InTech, Available from:
<http://www.intechopen.com/books/vitiligo-management-and-therapy/segmental-vitiligo>

INTECH
open science | open minds

InTech Europe

University Campus STeP Ri
Slavka Krautzeka 83/A
51000 Rijeka, Croatia
Phone: +385 (51) 770 447
Fax: +385 (51) 686 166
www.intechopen.com

InTech China

Unit 405, Office Block, Hotel Equatorial Shanghai
No.65, Yan An Road (West), Shanghai, 200040, China
中国上海市延安西路65号上海国际贵都大饭店办公楼405单元
Phone: +86-21-62489820
Fax: +86-21-62489821

© 2011 The Author(s). Licensee IntechOpen. This is an open access article distributed under the terms of the [Creative Commons Attribution 3.0 License](https://creativecommons.org/licenses/by/3.0/), which permits unrestricted use, distribution, and reproduction in any medium, provided the original work is properly cited.

IntechOpen

IntechOpen