

We are IntechOpen, the world's leading publisher of Open Access books Built by scientists, for scientists

6,900

Open access books available

186,000

International authors and editors

200M

Downloads

Our authors are among the

154

Countries delivered to

TOP 1%

most cited scientists

12.2%

Contributors from top 500 universities



WEB OF SCIENCE™

Selection of our books indexed in the Book Citation Index
in Web of Science™ Core Collection (BKCI)

Interested in publishing with us?
Contact book.department@intechopen.com

Numbers displayed above are based on latest data collected.
For more information visit www.intechopen.com



Clinical Aspects of Anti-NMDA Receptor Encephalitis

Haruo Shimazaki

Division of Neurology, Department of Internal Medicine, Jichi Medical University, Tochigi Japan

1. Introduction

Paraneoplastic limbic encephalitis (PLE) is a rare neurological syndrome characterized by short-term memory impairment, seizures and various psychiatric disturbances. It is often associated with small-cell lung cancer, germ-cell tumors of the testis and breast cancer, but rarely with ovarian teratomas (Gultekin et al., 2000). Several cases of PLE with ovarian teratomas had been reported in Japan (Okamura, Oomori, and Uchitomi, 1997; Nokura et al., 1997), but the autoantigens in this disease remained unknown. In 2005, Dalmau et al. reported an antibody to the membranes of neurons of the hippocampus (antigens colocalized with exchange factor for ADP-ribosylation factor 6 A (EFA6A)) in association with PLE and ovarian teratomas (Ances et al., 2005; Vitaliani et al., 2005).

We sent samples from a patient suffering from limbic encephalitis with an ovarian teratoma to Prof. Dalmau's Laboratory in November 2005. They identified antibodies to the antigens colocalized with EFA6A in our patient's samples (Figure 1) (Shimazaki et al., 2007), and in another Japanese one (Koide et al., 2007).

Their further analysis of the antibodies disclosed that were ones against NR1/NR2 heteromers of N-methyl-D-aspartate (NMDA) receptors. They diagnosed and reported twelve women (including our case) as having 'paraneoplastic anti-NMDA receptor encephalitis associated with an ovarian teratoma', the cases developing prominent psychiatric symptoms, amnesia, seizures, frequent dyskinesias, autonomic dysfunction, and a decreased level of consciousness often requiring ventilatory support (Dalmau et al., 2007). After this publication, several reports about anti-NMDA receptor encephalitis have appeared in Japan (Iizuka et al., 2008; Seki et al., 2008; Kataoka, Dalmau, and Ueno, 2008; Ishiura et al., 2008; Shindo et al., 2009). Analysis of a worldwide one hundred anti-NMDA receptor encephalitis case series revealed that about 60% of them had associated tumors such as ovarian teratomas (Dalmau et al., 2008).

Meanwhile, Kamei et al. proposed 'acute juvenile female non-herpetic encephalitis (AJFNHE)' (Kamei et al., 2009). The clinical symptoms and course of AJFNHE are similar to those of anti-NMDA receptor encephalitis. These two diseases are considered to be the same clinical entity, anti-NMDA receptor antibodies being detected in samples from some AJFNHE cases.

We herein describe five young Japanese cases who had fever, psychiatric symptoms and orofacial dyskinesias, and whose sera and cerebrospinal fluids (CSF) contained antibodies against NMDA receptors.

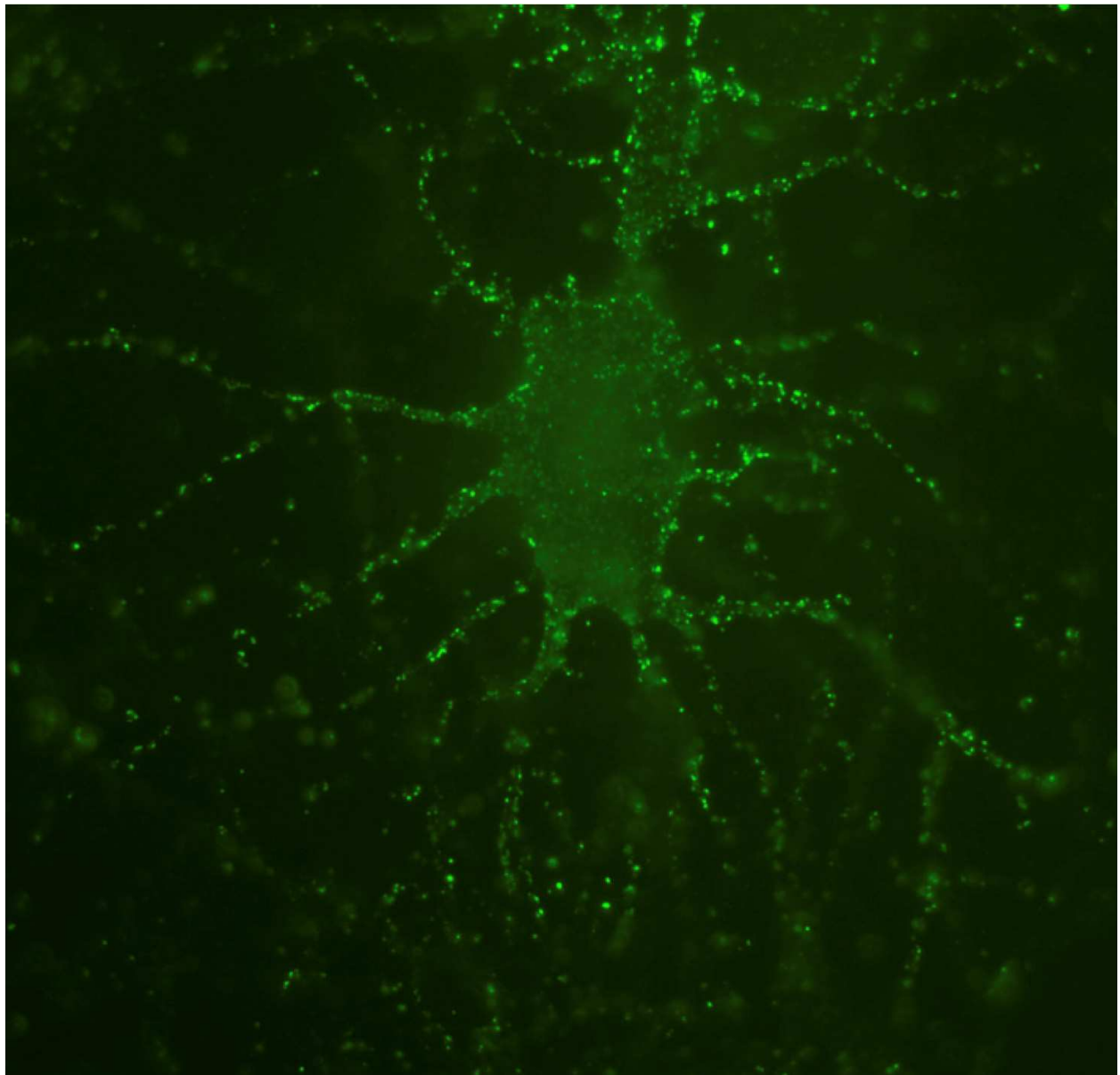


Fig. 1. Detection of anti-NMDA receptor antibodies in cerebrospinal fluid of case 3. Antibodies for the NR1/NR2 heteromers of NMDA receptors caused intense immunolabelling of cultured rat neuronal cell membranes and processes.

2. Characteristic clinical features of anti-NMDA receptor encephalitis

The clinical symptoms of 100 cases of anti-NMDA receptor encephalitis have been reported in detail (Dalmau et al., 2008). According to this report, the median age of patients was 23 years (range, 5-76 years), and 91 out of the 100 cases were women.

In our cases (Table 1), the time of disease onset ranged from 17 to 30 of age. Four cases were female and one was male. Headache, fever and flu-like symptoms preceded other encephalitis features in our cases and about 90% of the above 100 cases (Dalmau et al., 2008). To our knowledge, antecedent infection has not been described for this disease, but case 5 had suffered from influenza B infection before his psychiatric symptoms emerged.

2.1 Psychiatric symptoms

Seventy-seven of 100 anti-NMDA receptor encephalitis cases developed marked schizophrenia-like psychiatric symptoms at onset (Dalmau et al., 2008), and they tended to have visited a psychiatric clinic initially. The psychiatric symptoms were as follows: anxiety, agitation, bizarre behavior, delirium, visual and auditory hallucination, and short-term memory disturbance. Catatonia-like symptoms have been reported (Lee, Glick, and Dinwiddie, 2006; Iizuka et al., 2008; Kleinig et al., 2008; Schimmel et al., 2009). Emotional incontinence and disorientation were observed in our series.

Notably, our case 5 showed prominent psychiatric symptoms such as abnormal behavior, hallucination and agitation with mild orofacial dyskinesia, although convulsions, abnormal eye movements, autonomic instability, hypoventilation and CSF pleocytosis were not observed. Modified electroconvulsive therapy was effective for his psychiatric symptoms that were uncontrolled with medications due to their side effects (Ando et al., 2011).

Recently, anti-NMDA receptor antibodies were detected in a small percentage of patients with a first episode of psychosis (Zandi et al., 2011), and in cases with a pure neuropsychiatric disorder (De Nayer, Myant, and Sindic, 2009). A good response to electroconvulsive therapy has been reported for anti-NMDA receptor encephalitis (Braakman et al., 2010).

2.2 Involuntary movements

Involuntary movements are one of the most characteristic symptoms of anti-NMDA receptor encephalitis. They were seen in 85 of 100 anti-NMDA receptor encephalitis cases. The most frequent types were orofacial dyskinesia including grimacing, masticatory-like movements, and forceful jaw opening and closing (Dalmau et al., 2008). Other types of involuntary movement were also observed, as follows: choreiform movement, dystonic posture and myoclonus. It is suggested that interruption of forebrain corticostriatal inputs by anti-NMDA receptor antibodies removes tonic inhibition of brainstem pattern generators releasing primitive patterns of bulbar and limb movement (Kleinig et al., 2008).

In our cases, we observed blinking and grimacing, to and fro dyskinesia of the tongue, tremorous movements of the extremities, and increasing paroxysmal muscle tonus throughout the whole body. In patients 1 and 3, the orofacial dyskinesia was too severe to break their teeth, whereas that in case 5 was mild and of short duration.

2.3 Oculomotor symptoms

Oculogyric crisis has been reported as the most frequent oculomotor finding in anti-NMDA receptor encephalitis (Ko, Dalmau, and Galetta, 2008). Moreover, nystagmus and deviation of the ocular position have been observed in some cases (Dalmau et al., 2008).

In our cases, we observed oculogyric crisis in case 1, disconjugation in case 2, and skew deviation and inverse ocular bobbing in case 3 (Shimazaki et al., 2008) (Fig. 2)(Table 1). Inverse ocular bobbing, referred to as ocular dipping, consists of a slow, spontaneous downward eye movement with fast return to midposition. It may be observed in anoxic coma (Ropper, 1981) or following prolonged status epileptics (Mehler, 1988), and is thought to be a marker of diffuse brain damage (Stark, Masucci, and Kurtzke, 1984). This case had not only signs of brainstem involvement such as skew deviation and hypoventilation, but also of diffuse encephalopathy, causing the inverse ocular bobbing.

Patient No.	1	2	3	4	5
Onset age, Gender	22, F	19, F	30, F	16, F	18, M
Initial symptoms (Prodromes)	emotional incontinence, restlessness, fever, headache	disorientation, emotional incontinence, fever, headache, nausea	disorientation, fever, headache, nausea	abnormal behavior, convulsions, fever, headache	fever (influenza B), abnormal behavior, hallucination, agitation
Seizures	clonic	clonic	tonic	tonic	-
Orofacial & limb dyskinesia	++	+++	++	+	+-
Duration of dyskinesia	9 weeks	> 5 weeks	2 weeks	4 weeks	2 days
Eye position, movement	oculogyric crisis	disconjugation	skew deviation, inverse ocular bobbing	horizontal nystagmus like	-
Autonomic instability	++	++	++	+	-
Hypersalivation	++	+++	+++	+-	-
Ventilatory assistance	12 weeks	> 6 weeks	6 weeks	-	-
Hospital stay (months)	5.5	2	3.5	2	4
CSF cells (/μl)	104	242	40	10	1
CSF protein (mg/dl)	26	55	67	32	20
CSF glucose (mg/dl)	70	48	67	72	70
MRI (FLAIR) high intensity	unremarkable	unremarkable	medial temporal, hippocampus	right pontine base, right cerebellum	unremarkable
EEG	δ	δ	θ-δ	θ-δ	normal
Ovarian teratoma	mature cystic (dermoid cyst)	(not detected)	immature, rapid enlargement	(not detected)	(not detected)
Tumor markers (CA19-9, CA125)	CA19-9 <1 CA125 18	(not examined)	CA19-9 138 CA125 65	CA19-9 52 CA125 19	CA19-9 2
Time to tumor diagnosis	47 months	-	0.5 months	-	-
NR1 antibody titer in CSF (rfu, normal < 5000)	444556	2197200	31360	NR1/NR2 antibody +	NR1/NR2 antibody +
Therapy	CS, tumor resection	CS, PP, IVIg	CS, PP, IVIg, tumor resection	IVIg, CS	electroconvulsive therapy
Outcome	recovery (1 year 8 months) w/epilepsy	death (2 months)	full recovery (1 year)	full recovery (11 months)	full recovery (1 year)

Table 1. Clinical and laboratory findings in five cases of anti-NMDA receptor encephalitis.
rfu: relative fluorescence units.

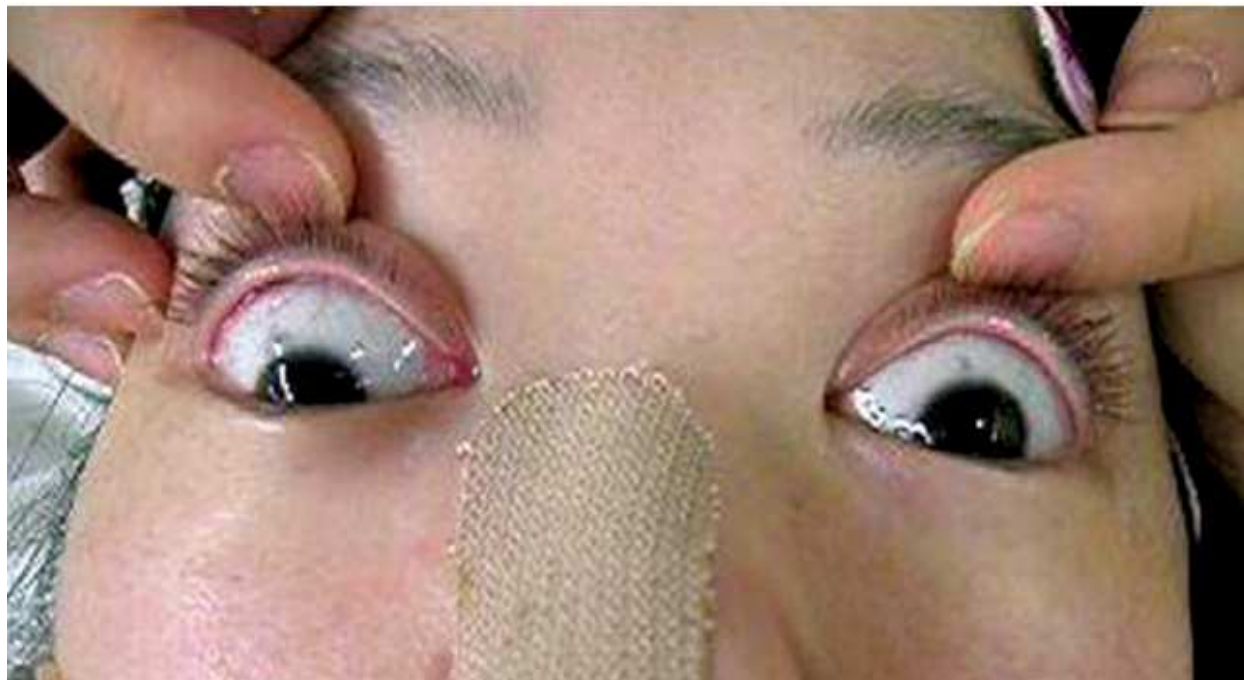

Fig. 2. The position of the eyes in case 3 showed skew deviation when the inverse ocular bobbing resolved.

2.4 Autonomic symptoms

Anti-NMDA receptor encephalitis is complicated by autonomic instability, which is indicated by an unstable blood pressure level or pulse rate, hypersalivation, central hypoventilation, etc.

We found excess salivary excretion of up to 1400ml/day in all cases except for patients 4 and 5. Case 3 suffered from sudden hypotension and bradycardia. Three of the five cases were intubated and required mechanical ventilatory support due to the central hypoventilation, the other two cases not needing assisted ventilation.

2.5 Ovarian teratomas

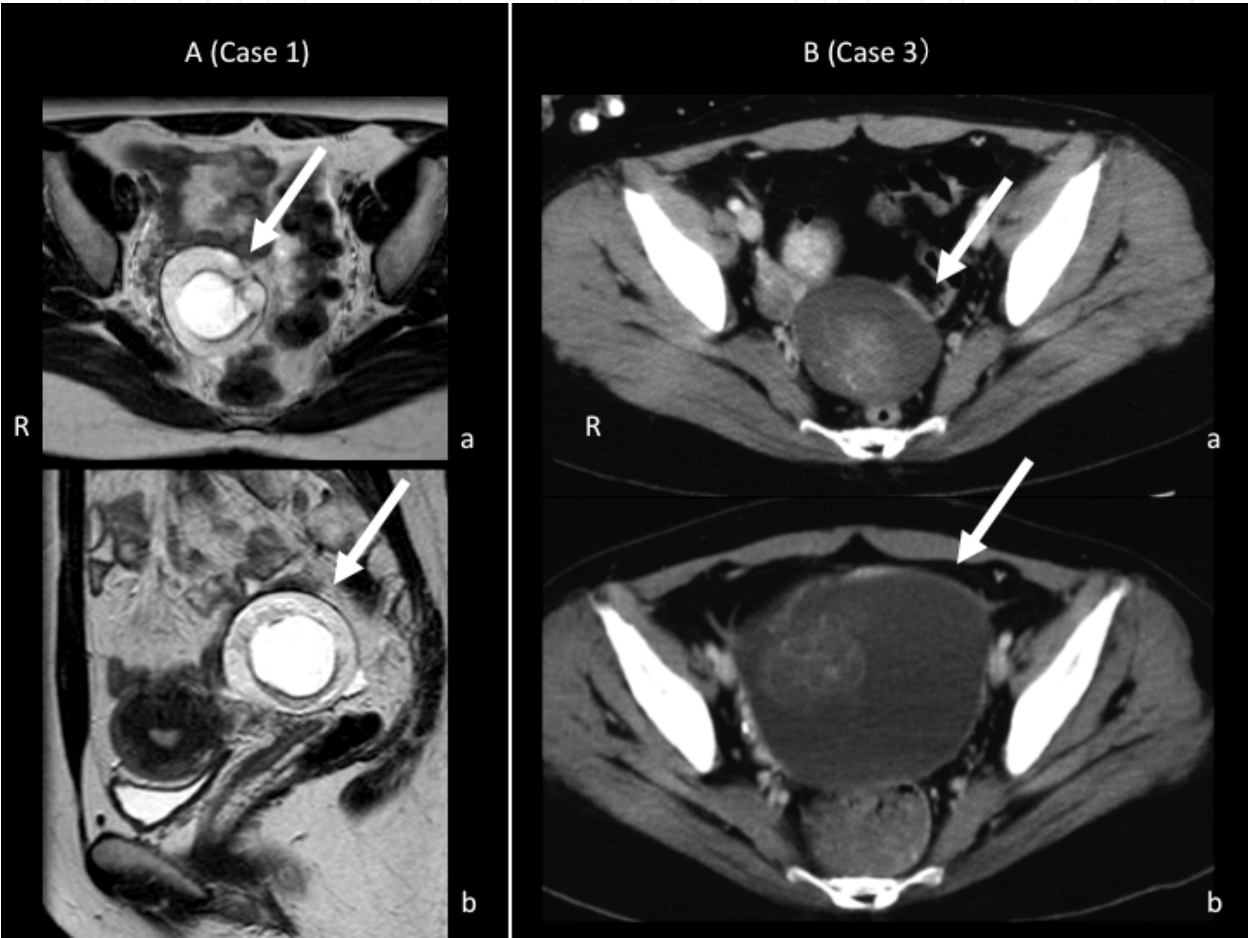
Fifty-eight of 98 anti-NMDA receptor encephalitis patients had a neoplasm, the most frequent one being an ovarian teratoma (Dalmau et al., 2008). Analysis of 400 patients confirmed that the younger the patient, the less likely that a tumor will be detected (Dalmau et al., 2011), and that in female patients older than 18 years, the frequency of an underlying teratoma is much the same as they previously reported (Dalmau et al., 2008).

Of our cases, two (22 and 30 years old) had ovarian teratomas, the other three (16, 18 and 19 years old) had no associated tumor. The mature teratoma of an ovary in case 1 was not discovered in hospital with encephalitis symptoms, but was diagnosed four years after onset (Figure 3A-a, b). The immature teratoma of an ovary in case 3 was detected at two weeks after onset (Figure 3B-a). Pelvic MRI showed her enlarged teratoma, double in diameter, at two months after onset (Figure 3B-b) (Shimazaki et al., 2007). Both teratomas were resected, but the tumors in the other three cases were not identified until now.

2.6 Brain MRI findings

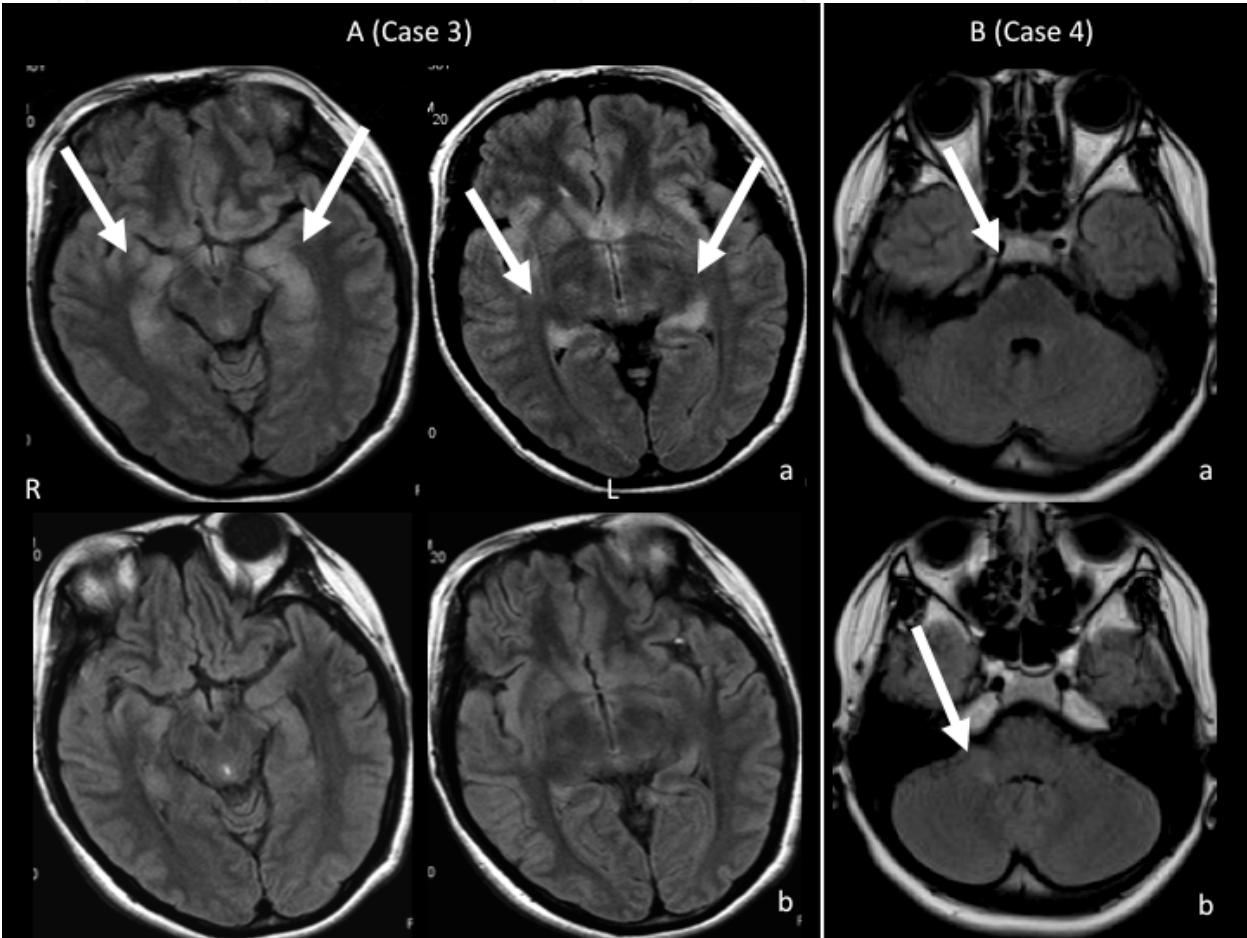
Brain MRI showed abnormal findings in 55 of 100 cases with anti-NMDA receptor encephalitis (Dalmau et al., 2008).

Of our cases, cases 1, 2 and 5 exhibited no remarkable findings on the brain MRI. FLAIR images of case 3 disclosed areas of high intensity in the bilateral medial temporal and hippocampal areas (Figure 4A-a), which disappeared after two months (Figure 4A-b)(Shimazaki et al., 2007). FLAIR images of case 4 showed areas of high intensity in the right ventral pons (Figure 4B-a) and the right cerebellum (Figure 4B-b).



A. Pelvic T2-weighted MRI (a: axial, b: sagittal image) in case 1 at four years after onset. It revealed a right ovarian teratoma with a diameter of 5 cm. It was resected and the pathological diagnosis was a mature teratoma (dermoid cyst).
B. Pelvic enhanced CT in case 3. CT at two weeks after onset (a) revealed a 5 cm tumor in the right ovary, which was considered to be a benign cyst unrelated to the neurological disorder. At two months after onset, the patient developed progressive constipation and a bulging appearance of the lower abdomen. Follow-up abdominal computed tomography (b) and MRI showed an enlarged ovarian tumor, with a transverse diameter of 10 cm. Resection of the tumor revealed an immature teratoma that contained hair follicles, cartilage tissue, glandular structures and cerebral cortex-like tissue with normal appearing neurons. No inflammatory infiltrates were evident in the tumor.

Fig. 3. Ovarian teratomas in cases 1 and 3.



A. Brain MRI in case 3. Axial plane and Gadolinium-enhanced T1-weighted MRI were unremarkable, but MRI fluid-attenuated inversion recovery images of the brain showed areas of hyperintensity in the medial temporal lobes and hippocampus on admission (A-a). These abnormalities had resolved by two months after admission (A-b).
B. Brain MRI in case 4. Axial plane and Gadolinium-enhanced T1-weighted MRI were unremarkable, but T2-weighted and FLAIR images showed areas of slightly high intensity in the right ventral pons (a) and cerebellum (b).

Fig. 4. Brain MRI (FLAIR) findings in two patients (cases 3 and 4).

2.7 Electroencephalography (EEG)

Generalized or frontotemporal slow waves were observed in 71 of 100 cases with anti-NMDA receptor encephalitis. Epileptic discharges were only recorded in 22 of the 100 cases (Dalmau et al., 2008). The EEG records for all our cases except for case 5 mainly showed slow waves in the theta to delta ranges.

2.8 Cerebrospinal fluid findings

Cerebrospinal fluid (CSF) examination disclosed abnormal findings in 95 of 100 cases (Dalmau et al., 2008). Lymphocytic pleocytosis was found in 91 cases, and increased protein concentrations in 32 of the 100 cases.

In our cases, mild to moderate pleocytosis was found in all patients except for patient 5. CSF protein elevation was only observed in two cases (patients 2 and 3).

3. Treatment and prognosis

Several effective treatments have been reported for anti-NMDA receptor encephalitis other than the administration of steroids, immunoglobulin, and plasmapheresis. Ovarian tumor removal in the acute phase (Sansing et al., 2007; Seki et al., 2008), chemotherapy for the tumors (Eker et al., 2008), cyclophosphamide (Sansing et al., 2007; Wilder-Smith and Ng, 2008), and rituximab (Ishiura et al., 2008) were also effective treatments for a small number of cases.

In our cases (Table 1), corticosteroids were administered to four cases, and high-dose intravenous gammaglobulin to three cases. We performed plasmapheresis for two cases. Two women underwent resection of ovarian teratomas. Modified electroconvulsive therapy was found to be dramatically effective for the psychiatric symptoms in case 5.

The severity of anti-NMDA receptor encephalitis is incompletely correlated with the titer of anti-NMDA receptor antibodies in the acute phase. (Prof. Dalmau, written communication Jul 2008).

In our cases, we did know the titers in three (Table 1). Case 3 exhibited the lowest titer with a full recovery, whereas case 2 exhibited the highest titer with severe involuntary movements and poor prognosis.

The prognosis of anti-NMDA receptor encephalitis had relatively good compared to that of herpes simplex encephalitis. Of 100 cases, 47 exhibited full recovery, 28 mild stable deficits, 18 severe deficits, and seven died as a result of the neurological disorder (Dalmau et al., 2008). Our three cases exhibited a complete recovery, one had mild sequelae with epilepsy, and one died.

4. Conclusions

We have discussed five cases of anti-NMDA receptor encephalitis compared to the other numerous reported cases. From the clinical aspect, our cases and the reported ones had some symptoms in common, for example, preceding psychiatric symptoms, and characteristic orofacial dyskinesia.

Meanwhile, the clinical manifestations in our cases included a peculiar ocular symptom (ocular dipping) in case 3 and an atypical clinical presentation (predominant schizophrenic

psychiatric symptoms) in case 5. In particular, case 5 was initially misdiagnosed as having schizophrenia by a psychiatrist because of no findings of encephalitis (no CSF pleocytosis, normal brain MRI and EEG). Ovarian teratomas were found in two patients, one became rapidly enlarged in hospital, and the other was found at four years after onset. Therefore, we should carefully follow up patients even if the tumors are not identified during hospitalization. In our experience, anti-NMDA receptor encephalitis exhibits severe symptoms such as convulsions and hypoventilation in the acute phase, but this disease could be curable. Characteristic symptoms and antibody measurement can be useful for prompt diagnosis of this disease, and early immunosuppressive treatment and tumor resection are important as well as general care of critically ill patients.

5. Acknowledgements

We thank Professor Josep Dalmau (Department of Neuro-oncology, University of Pennsylvania) and Professor Keiko Tanaka (Department of Neurology, Kanazawa Medical University) for measurement of the anti-NMDA receptor antibodies. We also thank Professor Imaharu Nakano (Division of Neurology, Department of Internal Medicine, Jichi Medical University) for supervision.

This work was supported by a Grant-in-Aid for Scientific Research (C) (23591253 to Dr Shimazaki) from The Ministry of Education, Culture, Sports, Science and Technology of Japan.

6. References

- Ances, B. M., R. Vitaliani, R. A. Taylor, D. S. Liebeskind, A. Voloschin, D. J. Houghton, S. L. Galetta, M. Dichter, A. Alavi, M. R. Rosenfeld, and J. Dalmau. (2005). Treatment-responsive limbic encephalitis identified by neuropil antibodies: MRI and PET correlates. *Brain*, Vol.128, No.Pt 8, (Aug 2005), pp. 1764-1777, ISSN 1460-2156
- Ando, Y., M. Sawada, H. Shimazaki, K. Yoshida, S. Sakamoto, K. Tanaka, and I. Nakano. (2011). Modified electroconvulsive therapy is effective for psychiatric symptoms in a man with anti-NMDAR encephalitis. *Rinsho Shinkeigaku*, Vol.51, No.1, (Jan 2011), pp. 73, ISSN 0009-918X
- Braakman, H. M., V. M. Moers-Hornikx, B. M. Arts, R. M. Hupperts, and J. Nicolai. (2010). Pearls & Oysters: electroconvulsive therapy in anti-NMDA receptor encephalitis. *Neurology*, Vol.75, No.10, (Sep 7 2010), pp. e44-46, ISSN 0028-3878
- Dalmau, J., A. J. Gleichman, E. G. Hughes, J. E. Rossi, X. Peng, M. Lai, S. K. Dessain, M. R. Rosenfeld, R. Balice-Gordon, and D. R. Lynch. (2008). Anti-NMDA-receptor encephalitis: case series and analysis of the effects of antibodies. *Lancet Neurol*, Vol.7, No.12, (Dec 2008), pp. 1091-1098, ISSN 1474-4422
- Dalmau, J., E. Lancaster, E. Martinez-Hernandez, M. R. Rosenfeld, and R. Balice-Gordon. (2011). Clinical experience and laboratory investigations in patients with anti-NMDAR encephalitis. *Lancet Neurol*, Vol.10, No.1, (Jan 2011), pp. 63-74, ISSN 1474-4465


- Dalmau, J., E. Tuzun, H. Y. Wu, J. Masjuan, J. E. Rossi, A. Voloschin, J. M. Baehring, H. Shimazaki, R. Koide, D. King, W. Mason, L. H. Sansing, M. A. Dichter, M. R. Rosenfeld, and D. R. Lynch. (2007). Paraneoplastic anti-N-methyl-D-aspartate receptor encephalitis associated with ovarian teratoma. *Ann Neurol*, Vol.61, No.1, (Jan 2007), pp. 25-36, ISSN 0364-5134
- De Nayer, A. R., N. Myant, and C. J. Sindic. (2009). A subacute behavioral disorder in a female adolescent. Autoimmune anti-N-methyl-D-aspartate receptor encephalitis associated with ovarian teratoma. *Biological psychiatry*, Vol.66, No.6, (Sep 15 2009), pp. e13-14, ISSN 0006-3223
- Eker, A., E. Saka, J. Dalmau, A. Kurne, C. Bilen, H. Ozen, D. Ertoy, K. K. Oguz, and B. Elibol. (2008). Testicular teratoma and anti-N-methyl-D-aspartate receptor-associated encephalitis. *J Neurol Neurosurg Psychiatry*, Vol.79, No.9, (Sep 2008), pp. 1082-1083, ISSN 0022-3050
- Gultekin, S. H., M. R. Rosenfeld, R. Voltz, J. Eichen, J. B. Posner, and J. Dalmau. (2000). Paraneoplastic limbic encephalitis: neurological symptoms, immunological findings and tumour association in 50 patients. *Brain*, Vol.123 (Pt 7), (Jul 2000), pp. 1481-1494, ISSN 0006-8950
- Iizuka, T., F. Sakai, T. Ide, T. Monzen, S. Yoshii, M. Iigaya, K. Suzuki, D. R. Lynch, N. Suzuki, T. Hata, and J. Dalmau. (2008). Anti-NMDA receptor encephalitis in Japan: long-term outcome without tumor removal. *Neurology*, Vol.70, No.7, (Feb 12 2008), pp. 504-511, ISSN 1526-632X
- Ishiura, H., S. Matsuda, M. Higashihara, M. Hasegawa, A. Hida, R. Hanajima, T. Yamamoto, J. Shimizu, J. Dalmau, and S. Tsuji. (2008). Response of anti-NMDA receptor encephalitis without tumor to immunotherapy including rituximab. *Neurology*, Vol.71, No.23, (Dec 2 2008), pp. 1921-1923, ISSN 1526-632X
- Kamei, S., S. Kuzuhara, M. Ishihara, A. Morita, N. Taira, M. Togo, M. Matsui, M. Ogawa, K. Hisanaga, T. Mizutani, and S. Kuno. (2009). Nationwide survey of acute juvenile female non-herpetic encephalitis in Japan: relationship to anti-N-methyl-D-aspartate receptor encephalitis. *Internal Medicine*, Vol.48, No.9, (2009), pp. 673-679, ISSN 1349-7235
- Kataoka, H., J. Dalmau, and S. Ueno. (2008). Paraneoplastic encephalitis associated with ovarian teratoma and N-methyl-D-aspartate receptor antibodies. *Eur J Neurol*, Vol.15, No.1, (Jan 2008), pp. e5-6, ISSN 1468-1331
- Kleinig, T. J., P. D. Thompson, W. Matar, A. Duggins, T. E. Kimber, J. G. Morris, C. S. Kneebone, and P. C. Blumbergs. (2008). The distinctive movement disorder of ovarian teratoma-associated encephalitis. *Movement Disorders*, Vol.23, No.9, (Jul 15 2008), pp. 1256-1261, ISSN 1531-8257
- Ko, M. W., J. Dalmau, and S. L. Galetta. (2008). Neuro-ophthalmologic manifestations of paraneoplastic syndromes. *J Neuroophthalmol*, Vol.28, No.1, (Mar 2008), pp. 58-68, ISSN 1536-5166
- Koide, R., T. Shimizu, K. Koike, and J. Dalmau. (2007). EFA6A-like antibodies in paraneoplastic encephalitis associated with immature ovarian teratoma: a case report. *J Neurooncol*, Vol.81, No.1, (Jan 2007), pp. 71-74, ISSN 0167-594X

- Lee, A., D. B. Glick, and S. H. Dinwiddie. (2006). Electroconvulsive therapy in a pediatric patient with malignant catatonia and paraneoplastic limbic encephalitis. *J ECT*, Vol.22, No.4, (Dec 2006), pp. 267-270, ISSN 1095-0680
- Mehler, M. F. (1988). The clinical spectrum of ocular bobbing and ocular dipping *J Neurol Neurosurg Psychiatry*, Vol.51, No.5, (May 1988), pp. 725-727, ISSN 0022-3050
- Nokura, K., H. Yamamoto, Y. Okawara, H. Koga, H. Osawa, and K. Sakai. (1997). Reversible limbic encephalitis caused by ovarian teratoma. *Acta Neurol Scand*, Vol.95, No.6, (Jun 1997), pp. 367-373, ISSN 0001-6314
- Okamura, H., N. Oomori, and Y. Uchitomi. (1997). An acutely confused 15-year-old girl. *Lancet*, Vol.350, No.9076, (Aug 16 1997), pp. 488, ISSN 0140-6736
- Ropper, A. H. (1981). Ocular dipping in anoxic coma. *Arch Neurol*, Vol.38, No.5, (May 1981), pp. 297-299, ISSN 0003-9942
- Sansing, L. H., E. Tuzun, M. W. Ko, J. Baccon, D. R. Lynch, and J. Dalmau. (2007). A patient with encephalitis associated with NMDA receptor antibodies. *Nat Clin Pract Neurol*, Vol.3, No.5, (May 2007), pp. 291-296, ISSN 1745-834X
- Schimmel, M., C. G. Bien, A. Vincent, W. Schenk, and J. Penzien. (2009). Successful treatment of anti-N-methyl-D-aspartate receptor encephalitis presenting with catatonia. *Arch Dis Child*, Vol.94, No.4, (Apr 2009), pp. 314-316, ISSN 1468-2044
- Seki, M., S. Suzuki, T. Iizuka, T. Shimizu, Y. Nihei, N. Suzuki, and J. Dalmau. (2008). Neurological response to early removal of ovarian teratoma in anti-NMDAR encephalitis. *J Neurol Neurosurg Psychiatry*, Vol.79, No.3, (Mar 2008), pp. 324-326, ISSN 1468-330X
- Shimazaki, H., Y. Ando, I. Nakano, and J. Dalmau. (2007). Reversible limbic encephalitis with antibodies against the membranes of neurones of the hippocampus. *J Neurol Neurosurg Psychiatry*, Vol.78, No.3, (Mar 2007), pp. 324-325, ISSN 1468-330X
- Shimazaki, H., M. Morita, I. Nakano, and J. Dalmau. (2008). Inverse ocular bobbing in a patient with encephalitis associated with antibodies to the N-methyl-D-aspartate receptor. *Arch Neurol*, Vol.65, No.9, (Sep 2008), pp. 1251, ISSN 0003-9942
- Shindo, A., K. Kagawa, Y. Ii, R. Sasaki, Y. Kokubo, and S. Kuzuhara. (2009). Anti-N-methyl-D-aspartate receptor-related grave but reversible encephalitis with ovarian teratoma in 2 Japanese women presenting with excellent recovery without tumor resection. *Eur Neurol*, Vol.61, No.1, 2009, pp. 50-51, ISSN 1421-9913
- Stark, S. R., E. F. Masucci, and J. F. Kurtzke. (1984). Ocular dipping. *Neurology*, Vol.34, No.3, (Mar 1984), pp. 391-393, ISSN 0028-3878
- Vitaliani, R., W. Mason, B. Ances, T. Zwerdling, Z. Jiang, and J. Dalmau. (2005). Paraneoplastic encephalitis, psychiatric symptoms, and hypoventilation in ovarian teratoma. *Ann Neurol*, Vol.58, No.4, (Oct 2005), pp. 594-604, ISSN 0364-5134
- Wilder-Smith, E. P., and E. S. Ng. (2008). The writing on the wall. *Lancet*, Vol.372, No.9635, (Jul 26 2008), pp. 344, ISSN 0140-6736

Zandi, M. S., S. R. Irani, B. Lang, P. Waters, P. B. Jones, P. McKenna, A. J. Coles, A. Vincent, and B. R. Lennox. (2011). Disease-relevant autoantibodies in first episode schizophrenia. *J Neurol*, Vol.258, No.4, (Apr 2011), pp. 686-688, ISSN 0340-5354

IntechOpen

IntechOpen



Pathogenesis of Encephalitis

Edited by Dr. Daisuke Hayasaka

ISBN 978-953-307-741-3

Hard cover, 344 pages

Publisher InTech

Published online 09, December, 2011

Published in print edition December, 2011

Many infectious agents, such as viruses, bacteria, and parasites, can cause inflammation of the central nervous system (CNS). Encephalitis is an inflammation of the brain parenchyma, which may result in a more advanced and serious disease meningoencephalitis. To establish accurate diagnosis and develop effective vaccines and drugs to overcome this disease, it is important to understand and elucidate the mechanism of its pathogenesis. This book, which is divided into four sections, provides comprehensive commentaries on encephalitis. The first section (6 chapters) covers diagnosis and clinical symptoms of encephalitis with some neurological disorders. The second section (5 chapters) reviews some virus infections with the outlines of inflammatory and chemokine responses. The third section (7 chapters) deals with the non-viral causative agents of encephalitis. The last section (4 chapters) discusses the experimental model of encephalitis. The different chapters of this book provide valuable and important information not only to the researchers, but also to the physician and health care workers.

How to reference

In order to correctly reference this scholarly work, feel free to copy and paste the following:

Haruo Shimazaki (2011). Clinical Aspects of Anti-NMDA Receptor Encephalitis, Pathogenesis of Encephalitis, Dr. Daisuke Hayasaka (Ed.), ISBN: 978-953-307-741-3, InTech, Available from:
<http://www.intechopen.com/books/pathogenesis-of-encephalitis/clinical-aspects-of-anti-nmda-receptor-encephalitis>

INTECH
open science | open minds

InTech Europe

University Campus STeP Ri
Slavka Krautzeka 83/A
51000 Rijeka, Croatia
Phone: +385 (51) 770 447
Fax: +385 (51) 686 166
www.intechopen.com

InTech China

Unit 405, Office Block, Hotel Equatorial Shanghai
No.65, Yan An Road (West), Shanghai, 200040, China
中国上海市延安西路65号上海国际贵都大饭店办公楼405单元
Phone: +86-21-62489820
Fax: +86-21-62489821

© 2011 The Author(s). Licensee IntechOpen. This is an open access article distributed under the terms of the [Creative Commons Attribution 3.0 License](https://creativecommons.org/licenses/by/3.0/), which permits unrestricted use, distribution, and reproduction in any medium, provided the original work is properly cited.

IntechOpen

IntechOpen