

We are IntechOpen, the world's leading publisher of Open Access books Built by scientists, for scientists

6,900

Open access books available

186,000

International authors and editors

200M

Downloads

Our authors are among the

154

Countries delivered to

TOP 1%

most cited scientists

12.2%

Contributors from top 500 universities



WEB OF SCIENCE™

Selection of our books indexed in the Book Citation Index
in Web of Science™ Core Collection (BKCI)

Interested in publishing with us?
Contact book.department@intechopen.com

Numbers displayed above are based on latest data collected.
For more information visit www.intechopen.com



The Management of Small Renal Tumours by Ablative Therapies

Seshadri Sriprasad¹ and Howard Marsh²

¹Consultant Urological Surgeon - Darent Valley Hospital, Dartford, Kent,

²Consultant Urological Surgeon- Medway Maritime Hospital, Gillingham, Kent,
UK

1. Introduction

Renal cell carcinoma (RCC) was the 9th commonest malignancy in Europe in 2008 [1] with an estimated 88400 new cases and 39300 deaths [2] making it the most lethal urological malignancy. Over the last 2 decades there has been a significant increase in the incidence of small renal masses (SRMs) at diagnosis often as an incidental finding as a result of abdominal imaging for the investigation of pain or other abdominal symptoms [3]. This has resulted in a stage migration to smaller and lower stage lesions in asymptomatic patients [4]. Many of these SRMs are slow growing and of low malignant potential although the precise natural history remains unclear [5]. The rate of radiographic growth in most series which have followed renal masses usually for 3 years is between 0 and 0.86 cm/yr with a meta-analysis by Chawla et al reporting an overall median growth rate of 0.28cm/year [6]. Some tumours however will behave more aggressively and at present it is not possible to determine in advance which tumours these are. Nephron sparing surgery (NSS) represents the gold standard for the small renal mass and radical surgery for the T2 and larger tumours.

Although laparoscopic nephron sparing surgery has been demonstrated to be both feasible and oncologically equivalent to open nephron sparing surgery it is widely acknowledged to be technically demanding with a steep learning curve and associated morbidity. This particularly relates to keeping warm ischaemia time to a minimum. In one of the largest series Gill et al reported a median surgical time of 3 hours and a median warm ischemia time of 27.8 minutes [7]. Although robotically assisted partial nephrectomy is gaining acceptance, active surveillance and minimally invasive alternatives including ablative techniques have emerged as alternatives to nephron sparing surgery or radical nephrectomy.

The main ablative techniques in clinical use are cryotherapy and radiofrequency ablation. Cryotherapy is more frequently applied laparoscopically and radiofrequency ablation percutaneously. In some institutions including the Cleveland Clinic selected tumours are preferentially treated with minimally ablative techniques rather than with partial nephrectomy [8]. In addition other emerging techniques that have been described include High Intensity Focused Ultrasound, Microwave thermotherapy, Interstitial Laser ablation and CyberKnife. Whilst there is increasing evidence in support of radiofrequency ablation

and cryotherapy, there is less clear evidence in support of the other minimally invasive techniques at present.

2. Cryotherapy

Tissue destruction by freezing and thawing has been used in a variety of medical problems for over 150 years with minimal clinical significance. However, with the development of vacuum-insulated liquid nitrogen and argon cooled probes, a real breakthrough was made and targeted cryoablation of renal tumours became a reality. Currently cryoablation is performed using an argon gas based system which operates on the Joule- Thompson principle (i.e., rapid cooling of the tip of a probe by highly compressed liquid nitrogen or argon expanding through a restricted orifice to the gaseous state). Using this principle, very low temperatures of -175°C to -190°C can be focused on to kidney tissue to freeze tumours. Based on the same principle helium gas can be used for thawing [9]. Cryoprobes of varying diameters are now available and they produce ice balls of varying shapes [10].

3. Mechanism of cryoablation

Although the exact mechanism of tissue injury resulting from freezing is not completely understood, experimental studies have provided us with a fair knowledge of the mode of action of cryotherapy. The physiological changes of freezing are described as acute and delayed. When the tissues are exposed to temperature of -5°C , ice is formed in the extracellular space. This changes the osmotic gradient and draws water from the intracellular to the extracellular compartment, leading to changes, in the intracellular solute composition, pH and eventually leads to protein denaturation [11,12]. When the temperature reaches to -20°C , ice forms both intra and extracellularly. It is believed that the intracellular ice shears the cell membrane with irreversible cell damage. Complete destruction of normal renal parenchyma occurs at temperatures below -19.4°C [13, 14]. Delayed tissue injury also occurs after cryoablation. This is due to damage to the microvasculature of the target tissue and formation of microthrombi. This phenomenon leads to delayed cell death and is believed to be the significant mechanism of action of cryotherapy [15]. Tissue destruction is achieved better by the combination of freezing and thawing processes. Double freezing, as compared to a single- freeze approach, has been shown to produce large areas of necrosis in animal models with significantly increased cell death [16].

4. Indications and contraindications for renal cryotherapy

The indications for cryotherapy are the same as that for partial nephrectomy. A peripherally situated, enhancing, well- circumscribed tumour which is less than 4cm is the ideal lesion for cryotherapy. In general younger patients are offered partial nephrectomy. In older patients or those with comorbidities such as diabetes, hypertension, congestive cardiac failure cryotherapy is considered. In certain special situations such as tumour less than 4cms in solitary or transplant kidney; hereditary conditions such as Von Hippel- Lindau disease and tuberous sclerosis, cryotherapy may be ideal [17].

The relative contraindications for cryotherapy are young age, tumours greater than 4cms, hilar tumours, intrarenal tumours, and cystic tumours. The only absolute contraindication is untreatable or irreversible coagulopathy [18].

5. Technique of cryotherapy

Most patients are treated with laparoscopic or percutaneous image guided minimally invasive techniques. Open cryotherapy may occasionally be necessary and is also described.

6. Laparoscopic cryotherapy

Tumours that are situated in the anterior aspect of kidney and in the polar region are ideally treated by a transperitoneal laparoscopic technique and the posterior tumours by the retroperitoneal approach. The transperitoneal technique that we use is as follows:

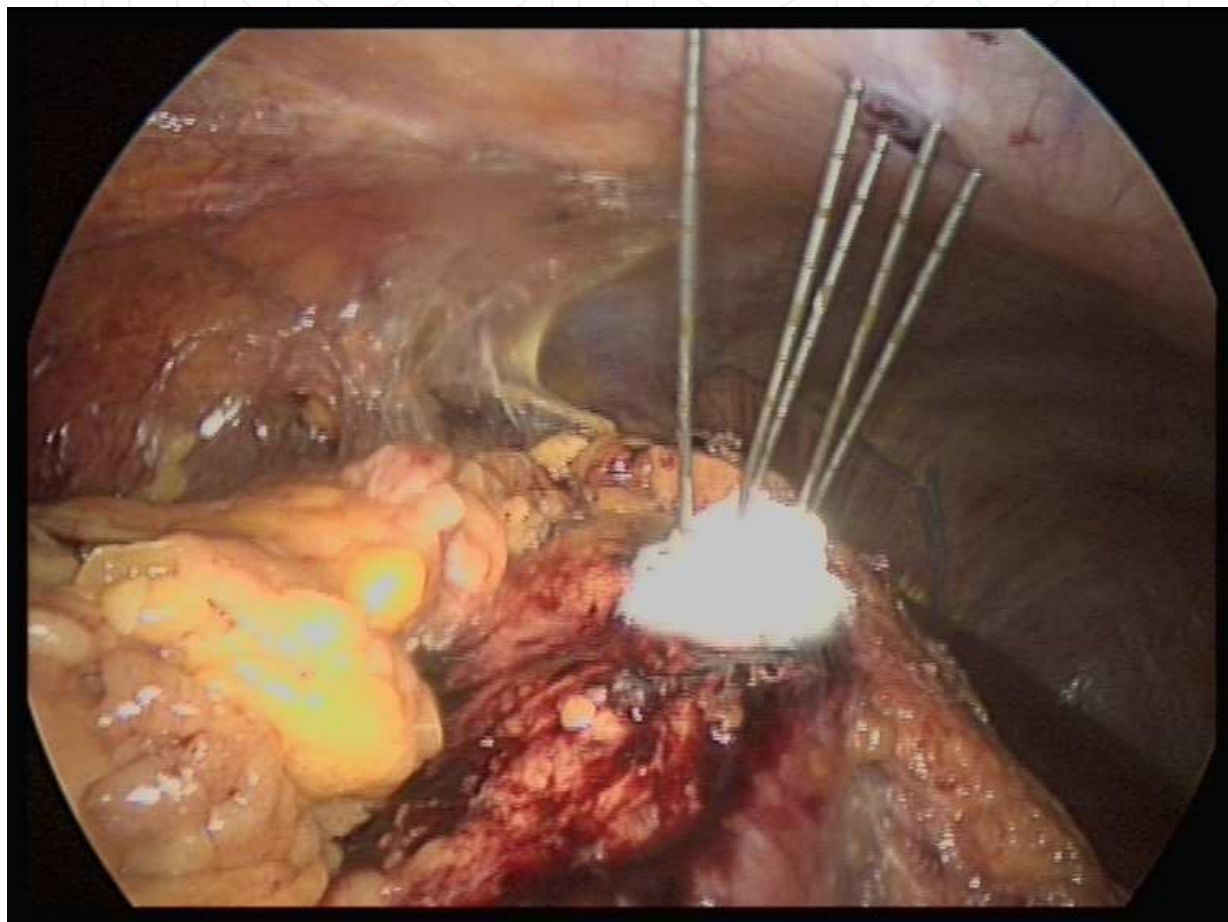


Fig. 1. Showing kidney tumour treated with argon gas cryotherapy- note the spectacular freezing of the tumour.

After placing the ports, the kidney is well mobilised. Gerota's fascia is incised and the perirenal fat is dissected from the surface of the kidney. The exophytic tumour is well seen at this stage and is defined. The position and the depth of the tumour are confirmed and measured using a laparoscopic ultrasound probe. Two to three good core biopsies are taken for histology. Cryoprobes are then placed perpendicularly into the tumour with the tip extending about 5mm beyond. The number of probes placed is determined by the size of the tumour. Two thermosensors are placed one in the centre of the lesion and the other beyond the margin of the tumour to monitor the temperature during cryoablation. The cryoablation starts with a freeze cycle with delivery of the argon gas through the probes. The cryolesion

is readily visible as an ice ball and visible in the ultrasound. Typically the first freeze cycle is for 10 minutes. The target temperature in the centre of the lesion is -40°C and below. This is followed by a thaw cycle with helium gas. Like many other centres we follow a two freeze and two thaw cycle protocol. At the end of the procedure, a passive and an active thaw are performed and then the probes are removed slowly, after the ice has fully melted. Retrieval of the probes should not be attempted if any resistance is noted as it may lead to fracture of the tumour. In this situation continuing passive thaw for some time allows easy removal of the probes (Fig 1)

7. Percutaneous image-guided cryoablation

Most cryoablations are performed under CT and MRI guidance. Tumours situated in the posterior and inferior aspect of the kidneys are ideal for image guided cryoablation. The upper pole tumours are difficult to reach. The procedure of cryotherapy is essentially similar to laparoscopic techniques. The advantages of percutaneous techniques are short hospital stay, ice ball monitoring by cross-sectional imaging, decreased analgesic requirement and lower cost compared to laparoscopy. Currently however, only 25% of tumours are treated by percutaneous image guided cryoablation and the techniques are still evolving [19].

8. Success and follow up

The absence of enhancement in a post contrast CT-scan at three months following cryoablation is considered as a successful procedure. Although no algorithm exists the patients are closely followed with contrast CT-scans at six, nine and twelve months and ideally the tumour should show regression. Periodic long-term follow up should continue till the tumour is regressed completely and then annual surveillance to ensure that there is no recurrence from the margin. The presence of enhancement would indicate incomplete treatment. Rim enhancement only with no increase in size seems to occur commonly in the first few months after cryoablation and this usually settles. This usually is not an indication for biopsies as it is difficult to take and the yield is low [20]. A recent study from the Cleveland clinic concluded that biopsies did not provide sufficient additional information to contrast enhanced MRI or CT findings in the six months post treatment period and hence did not recommend biopsies [21].

9. Results

The accumulating medium and long term data suggests that cryoablation is associated with high efficacy and low morbidity. The oncological control seems to be promising. The recent review by Berger and associates indicated a five and 10-year cancer specific survival of 93% and 81% respectively [22]. A meta-analysis showed that local recurrence (treatment failure) ranges from 4.6% to 5.2% and metastatic progression ranged from 1% to 1.2% [23].

10. Complications

Cryotherapy is a minimally invasive treatment modality which ablates the renal tumour *in situ*. Although, it is reasonably safe it has a few complications. Minor renal laceration and

bleeding from the needle site is common but settles with pressure. Renal fracture and haemorrhage can be avoided by perpendicular placement of the cryoprobes and waiting for complete thawing before removing the probes. The area of skin surrounding the cryoprobes needs to be protected, by warm gauze, to prevent cold injury to the skin. The adjacent internal organs also need protection from cryo injury. Pancreatic injury and ureteropelvic junction stricture has been reported [24]. Data from a retrospective multi centre study for 139 patients revealed that the major and minor complication rates associated with cryoablation were 1.8% and 9.2% respectively. The five major complications were ileus, haemorrhage, conversion to open surgery, scarring with ureteropelvic junction obstruction and urinary leakage. Overall, the most common complication as well as the most common minor complication was pain or paraesthesia at the probe insertion site [25].

11. Conclusions

Renal cryotherapy has proven its safety with good oncological control at medium term with some long term data. Currently the main application of cryotherapy in kidney tumours is for peripheral lesions less than 4cm in patients who would benefit from or require nephron sparing surgery but are not candidates because of comorbidity. Laparoscopic cryotherapy is also on the rise in patients with normal kidneys and relatively normal fitness. The percutaneous approach is constantly evolving and the field is very promising. We have to wait for the long term oncological data but it appears that cryotherapy is here to stay.

12. Radiofrequency ablation

First used in the targeted destruction of hepatic lesions radiofrequency ablation (RFA) has been used since the 1990s. It was first used in the kidney in 1997 [26]. Many of the treatment protocols in RFA are derived from the liver experience.

Although, it can be deployed laparoscopically it is most commonly applied percutaneously by interventional radiologists. The technique involves the insertion of 2 electrodes into the target tissue, in this case a renal tumour and conversion of electrical current between the two electrodes to ultrahigh (radio) frequency. This in turn ablates the intervening tissue with a margin of surrounding normal tissue. The mechanism of tissue destruction is immediate cellular damage and delayed microvascular impairment with the denaturation of proteins and the coagulation of tissue and the disruption of lipid cell membranes. The tissue needs to be heated to a temperature range of 50 to 100°C [27,28]. Over 105°C, the heat distribution and so tissue destruction becomes patchy and unreliable.

Real time imaging of RFA with intra operative USS CT or MRI has proved to be unreliable because of the similarity between normal and ablated tissue and because of the formation of gas bubble artefact. As a result imaging is usually confined to assisting initial probe placement with the RFA being monitored by temperature and or impedance changes.

The advantages of this minimally invasive technique include the ability to apply the energy percutaneously under light sedation, avoiding a general anaesthetic and allowing a more rapid recovery with low morbidity.

The disadvantages of the technique include a lower success rate compared to cryotherapy or nephron sparing surgery. In addition there are only short to medium term results available and the long term efficacy is not established. Also a significant proportion of the reported studies did not establish histological confirmation of a tumour before treatment and so

histological confirmation of successful ablation or cure is problematic. It is difficult to interpret the results if it is not certain that the original lesion was malignant. Furthermore as the natural history of the small renal mass is still not completely clear it may be that a significant proportion of the lesions that are tumours would have followed an indolent course without treatment and that the application of an ablative technique is an over treatment. As with cryotherapy, proximity to large vessels may lead to the draining of ablative energy by conduction that in turn reduces efficacy of the procedure. Another challenge is confirmation of successful ablation or cure. Most series report biopsy of the lesion at 6 months together with serial imaging with CT, usually at 6 monthly intervals. A successful outcome is taken as a lack of contrast enhancement of the lesion on CT. In addition the lesion should show progressive shrinking on subsequent imaging.

13. Results

Early experience has shown promising short and medium term tumour control [29]. McDougal et al [30] have reported on patients with over 4 years follow-up and showed successful ablation of exophytic masses smaller than 5cm in diameter. 13 masses in 11 patients with a mean tumour size 3.2cm were followed over a mean of 4.6 years. 12 (92.3%) of the 13 masses treated showed complete ablation.

Zagoria et al [31] reported a retrospective series of 125 treated tumours in which 116 (93%) were completely ablated with a mean follow up of 13.8 months. All 95 tumours smaller than 3.7cm were completely ablated and 21 (70%) of 30 larger tumours were completely ablated with 9 showing evidence of residual viable tumour on follow-up scans. They reported that with each 1cm increase in tumour diameter over 3.6cm the likelihood of tumour free survival decreased by a factor of 2.19 ($p < 0.001$). There were 8 (8%) complications none of which resulted in long-term morbidity.

Stern reported with a mean follow up of 30 months that RFA had the same outcome as partial nephrectomy for T1a lesions with a disease specific survival of 93.4% [32]. Levinson described over a period of at least 40 months a recurrence free survival of 90.3% in patients undergoing RFA for SRM in a single kidney [33].

There are concerns regarding the reliability of imaging to assess treatment response. Lack of enhancement of an ablated mass on CT does not always correlate with histological confirmation of no viable tumour tissue on biopsy. Weight reported that over 45% of renal tumours that showed no enhancement following RFA demonstrated viable tumour on biopsy at 6 months [34]. Others however have suggested that the presence of tumour on biopsy less than 12 months post treatment may be unreliable and have shown no viable tumour in 20 lesions that were biopsied over 12 months following treatment [35]. Where recurrences or cases of persistent disease do occur they tend to be demonstrated within 12 months of treatment. In one study from several institutions 92.1% of renal tumour recurrences were detectable 12 months or fewer after ablation [36].

One study reported the presence of pathological skip areas where tissue remains that has not been ablated. In this study this was found in seven of nine treated renal tumours [37].

A meta-analysis examining 47 studies comparing RFA and cryoablation for SRM has been published [38]. No differences were detected between the modalities in patient age, tumour size or follow-up. Pre-treatment biopsy was performed more often for lesions treated with cryoablation (82.3%) than with RFA (62.2%) ($p < 0.0001$). There was a significantly higher rate of unknown pathology in lesions treated with RFA (40.4%) compared to those treated with

cryoablation (24.5%) ($p < 0.0001$). Repeat ablation was more frequently performed after RFA (8.5%) than after cryoablation (1.3%) ($p < 0.0001$) and the rate of local tumour progression was significantly higher for RFA (12.9%) than for cryoablation (5.2%) ($p < 0.0001$). Metastasis was reported more frequently for RFA (2.5%) than for cryoablation (1%) ($p = 0.06$).

The authors of this large meta-analysis concluded that ablation of SRMs is a viable strategy based on short term oncological outcomes and that cryoablation results in fewer retreatments and improved local tumour control and may be associated with a lower risk of metastatic progression compared with RFA.

A further meta-analysis by the same authors looked at all studies reporting on the management of SRMs whether by open or laparoscopic partial nephrectomy, RFA, cryoablation or observation [39]. The analysis included 99 studies involving 6471 renal masses. Local recurrence was reported in 2.6% of masses treated with partial nephrectomy, 4.6% of cases treated with cryotherapy and 11.7% of masses treated with RFA.

Morbidity although low includes perinephric haematomas, bile and urinary fistulae, pancreatic pseudocysts and a ureteric stricture [40, 41].

14. Conclusions

Tumours most suitable for RFA are the same as those most suitable for nephron sparing surgery, that is those < 3.5 cm in diameter, peripheral, solid, exophytic lesions and away from the renal hilum and collecting system.

In addition RFA may be recommended for patients with conditions predisposing them to repeated development of renal tumours requiring multiple treatments such as Von Hippel Lindau disease.

A number of series have been reported with short and medium term follow up. The results appear to depend upon the position of the tumour with small exophytic peripheral tumours responding better than central lesions.

Although the majority of incomplete ablations are apparent by 12 months ongoing surveillance imaging much the same as following partial nephrectomy is recommended.

What remains to be seen is whether focal ablation actually alters the natural history of the small renal mass or whether the encouraging short and intermediate results are a function of the favourable nature of the lesion.

15. High Intensity Focused Ultrasound (HIFU)

HIFU is very attractive as a completely non-invasive treatment option. The focused ultrasound beam has a thermal and a cavitation effect. The thermal effect is caused by the absorption of ultrasonic sound waves by the tissues resulting in protein denaturation and coagulative necrosis [42]. The cavitation effect is caused by bubble implosion leading to mechanical disruption.

The first feasibility study was reported by Vallencien in 1993 [43] who found evidence of ablation in 8 patients with renal tumours. The limitations of the technique include difficulty in lesion localisation and targeting, small ablation zones and side effects including bowel injury and skin burns. In addition, in renal tumours the overlying ribs and respiratory movements can present a problem [44].

One study applied HIFU to the healthy renal tissue of patients requiring nephrectomy for tumour and found the tissue effects were variable and did not correspond well with the

amount of HIFU energy applied [45]. Other studies have also not demonstrated complete tumour ablation [46, 47]. At present therefore, HIFU although very attractive is not recommended as a treatment option.

16. Microwave thermotherapy

Microwave thermotherapy involves the insertion of flexible antennae into tissue and the formation of a rapidly alternating electromagnetic field which in turn causes coagulative necrosis [48]. Experimental studies in rabbits have suggested oncological equivalence with nephrectomy [49].

The disadvantages of the limited zone of ablation and the large antenna size have limited the minimally invasive application of microwave thermotherapy. The technique remains largely experimental although some early clinical experience has been described [50, 51]. The technique has also been described as an adjunct to open partial nephrectomy in order to provide a bloodless plane before resection [52].

17. Interstitial LASER coagulation

Interstitial LASER therapy works by inserting a bare-tip laser fibre directly into tissue. Laser light is converted to heat $>55^{\circ}\text{C}$ and causes tissue necrosis. Nd-YAG and diode lasers have been used. Although the technique has been described experimentally with the laparoscopic approach [53] and in a small number of clinical studies [54] it should still be regarded as experimental.

18. Cyberknife (radiosurgery)

This technique was pioneered in neurosurgery for the treatment of intracranial tumours and uses stereotactic techniques to apply highly focused radiation. The cyberknife is a frameless image-guided radiosurgery device with a linear accelerator on a robotic arm which delivers an adequate conformal dose of radiation by focusing a large number of radiation beams at the target area such that each individual beam does not damage the surrounding normal tissue. Ponsky et al reported initial results in porcine kidneys and demonstrated complete fibrosis of the lesions with preservation of the surrounding normal tissue [55]. A phase 1 study of radiosurgery involving 3 patients showed necrotic tumour in 1 of the 3 patients at subsequent nephrectomy and further trials are awaited [56].

19. Conclusion

In this chapter we have discussed the management of small renal tumours by ablative therapies. These treatments have emerged as an alternative to nephron sparing or radical surgery. The most common ablative techniques are cryotherapy and radiofrequency ablation (RFA). The indications for ablative techniques are the same as for partial nephrectomy and the ideal lesion is a peripheral, enhancing, well circumscribed lesion less than 4cm in diameter (Fig2)

Cryotherapy is most commonly applied laparoscopically and depends upon repeated freeze thaw cycles to achieve tissue destruction. There is good oncological control in the medium term and long term data is continuing to emerge.

Radiofrequency ablation is more commonly applied percutaneously. Several meta-analyses have suggested that short term oncological outcomes are good but that local recurrence, retreatment rates and progression to metastatic disease may be higher than with cryotherapy.

Other ablative techniques include High Intensity Focused Ultrasound (HIFU), Microwave Thermoablation, Interstitial Laser Coagulation and Radiosurgery (Cyberknife). Although attractive as treatment options these techniques are yet to be established as viable treatments for the small renal mass.

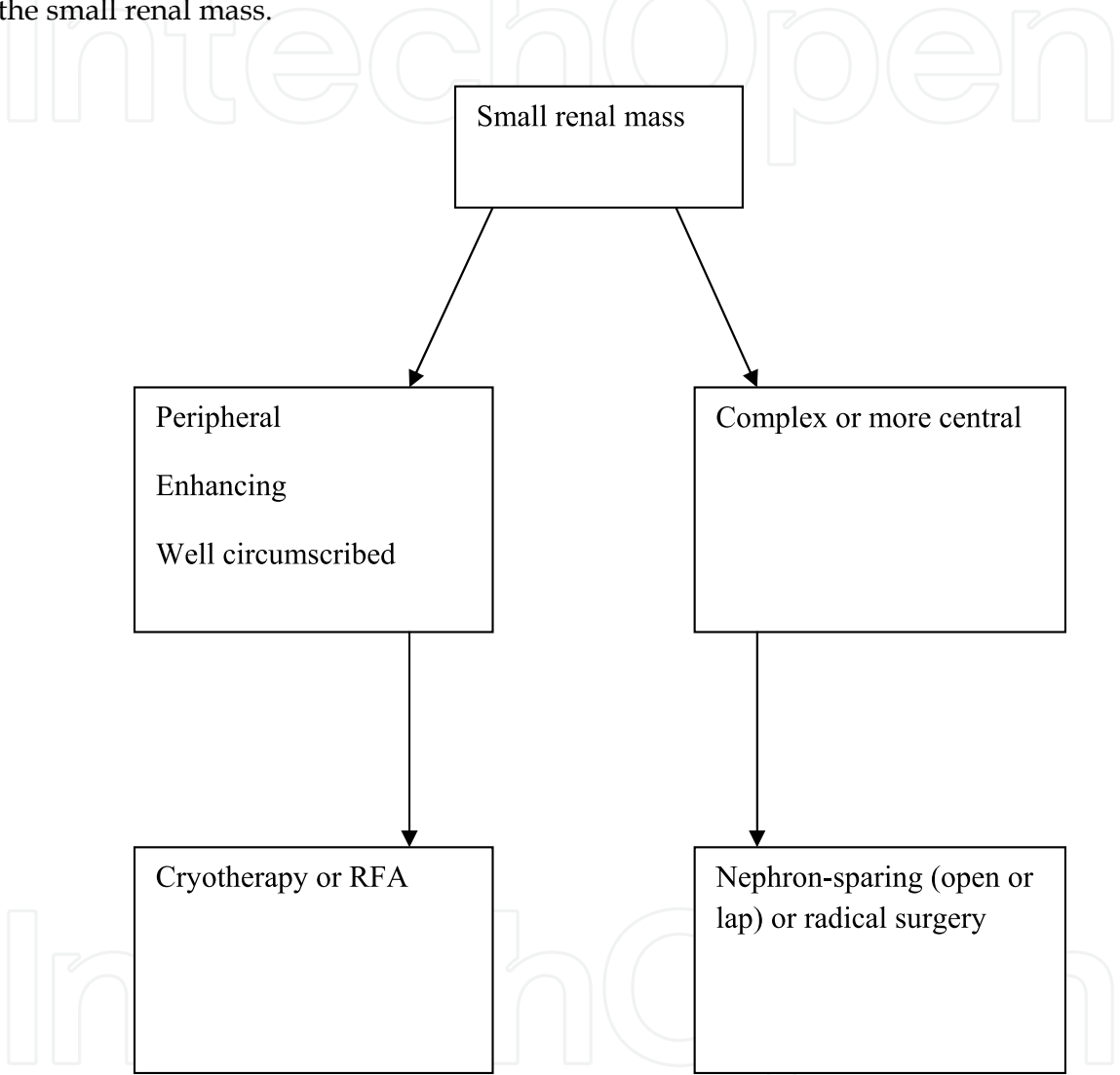


Fig. 2. The Management of Small Renal Tumours by Ablative Therapies

20. References

[1] Ljungberg, B., et al., *EAU guidelines on renal cell carcinoma: the 2010 update*. Eur Urol. 58(3): p. 398-406.

[2] Ferlay, J., D.M. Parkin, and E. Steliarova-Foucher, *Estimates of cancer incidence and mortality in Europe in 2008*. Eur J Cancer. 46(4): p. 765-81.


[3] Jayson, M. and H. Sanders, *Increased incidence of serendipitously discovered renal cell carcinoma*. Urology, 1998. 51(2): p. 203-5.

- [4] Chow, W.H., et al., *Rising incidence of renal cell cancer in the United States*. *Jama*, 1999. 281(17): p. 1628-31.
- [5] Crispen, P.L. and R.G. Uzzo, *The natural history of untreated renal masses*. *BJU Int*, 2007. 99(5 Pt B): p. 1203-7.
- [6] Chawla, S.N., et al., *The natural history of observed enhancing renal masses: meta-analysis and review of the world literature*. *J Urol*, 2006. 175(2): p. 425-31.
- [7] Gill, I.S., *Minimally invasive nephron-sparing surgery*. *Urol Clin North Am* 2003.30:551-579.
- [8] Weight, C.J., et al., *The impact of minimally invasive techniques on open partial nephrectomy: a 10-year single institutional experience*. *J Urol*, 2008. 180(1): p. 84-8.
- [9] Rewcastle, J.C., et al., *Considerations during clinical operation of two commercially available cryomachines*. *J Surg Oncol* 1999.71: p.106-111.
- [10] Rehman, J., et al., *Needle- based ablation of renal parenchyma using microwave, cryoablation, impedance- and temperature based monopolar and bipolar radiofrequency, and liquid and gel chemoablation; laboratory studies and review of literature*. *J Endourol* 2004.18:p.83-104
- [11] Ackler, J.P., et al., *Intracellular ice formation is affected by cell interactions*. *Cryobiology* 1999.38:p.363-371..
- [12] Bichof, J.C., et al., *Cryosurgery of Dunning AT-1rat prostate tumour:thermal,biophysical,and viability response at tissue level*. *Cryobiology*1997.34:p.42-69
- [13] Chosy, S.G., et al., *Monitoring kidney cryosurgery: Predictors of tissue necrosis in swine*. *J Urol* 1998.159:p1370-1374.
- [14] Campbell, S.C., et al., *Renal cryosurgery: experimental evaluation of treatment parameters*. 1998. *Urology* 1998. 52:p29-33.
- [15] Daum, P.S.,et al.*Vascular casts demonstrate microcirculatory insufficiency in acute frost bite*.*Cryobiology*1987.24:p65-73.
- [16] Clarke, D.M., et al. *Cryoablation of renal tumours: variables involved in freezing-induced cell death*. *Technology in Cancer Research & Treatment*.2007.6: P69-79.
- [17] Delworth, M.G., et al. *Cryotherapy for renal cell carcinoma and angiomyolipoma*. *J Urol* 1996.155: p252-254
- [18] Janzen, N., et al. *Minimally invasive ablative approaches in the treatment of renal cell carcinoma*. *Curr Urol Rep* 2002.3:13 p13-320.
- [19] Kunkle, D. A, Uzzo, R.G., *Cryoablaion or radiofrequency ablation of the small renal mass*. *Cancer* 2008.113: p2671-2680.
- [20] Beemster, P., et al. *Follow -up of renal masses after cryosurgery using computed tomography; enhancement patterns and cryolesion size*.*BJU Int*.2008.101:p1237-1242.
- [21] Weight, C.J., et al. *Correlation of radiographic imaging and histopathology following cryoablation and radiofrequency ablation for renal tumours*. *J Urol*.2008.179:p1277-1281.
- [22] Berger, A, Kamoi, K, Gill, I.S, Aron M. *Cryoablation of renal tumours the current status*. *Curr Opin Urol* 2009.19(2):p138-42.
- [23] Kunkle, D.A., B.L. Egleston, and R.G. Uzzo, *Excise, ablate or observe: the small renal mass dilemma--a meta-analysis and review*. *J Urol*, 2008. 179(4): p. 1227-33; discussion 1233-4.
- [24] Desai, M.M, Gill, I.S., *Current status of cryoablation and radiofequency ablation in the management of renal tumours*. *Curr Opin Urol* 2002.12:p387-393
- [25] Johnson, D.B., et al. *Defining the complications of cryoablation and radiofrequency ablation of small renal tumours: a multi- institutional study*. *J Urol*, 2004.172: p874-877.

- [26] Weight, C.J., et al., *The impact of minimally invasive techniques on open partial nephrectomy: a 10-year single institutional experience*. J Urol, 2008. 180(1): p. 84-8.
- [27] Zlotta, A.R., et al., *Radiofrequency interstitial tumor ablation (RITA) is a possible new modality for treatment of renal cancer: ex vivo and in vivo experience*. J Endourol, 1997. 11(4): p. 251-8.
- [28] Goldberg, S.N., G.S. Gazelle, and P.R. Mueller, *Thermal ablation therapy for focal malignancy: a unified approach to underlying principles, techniques, and diagnostic imaging guidance*. AJR Am J Roentgenol, 2000. 174(2): p. 323-31.
- [29] Aron, M. and I.S. Gill, *Minimally invasive nephron-sparing surgery (MINSS) for renal tumours. Part II: probe ablative therapy*. Eur Urol, 2007. 51(2): p. 348-57.
- [30] McDougal, W.S., et al., *Long-term follow up of patients with renal cell carcinoma treated with radio frequency ablation with curative intent*. J Urol, 2005. 174(1): p. 61-3.
- [31] Zagoria, R.J., et al., *Oncologic efficacy of CT-guided percutaneous radiofrequency ablation of renal cell carcinomas*. AJR Am J Roentgenol, 2007. 189(2): p. 429-36.
- [32] Stern, J.M., et al., *Intermediate comparison of partial nephrectomy and radiofrequency ablation for clinical T1a renal tumours*. BJU Int, 2007. 100(2): p. 287-90.
- [33] Levinson, A.W., et al., *Long-term oncological and overall outcomes of percutaneous radio frequency ablation in high risk surgical patients with a solitary small renal mass*. J Urol, 2008. 180(2): p. 499-504; discussion 504.
- [34] Weight, C.J., et al., *Correlation of radiographic imaging and histopathology following cryoablation and radio frequency ablation for renal tumors*. J Urol, 2008. 179(4): p. 1277-81; discussion 1281-3.
- [35] Raman, J.D., et al., *Absence of viable renal carcinoma in biopsies performed more than 1 year following radio frequency ablation confirms reliability of axial imaging*. J Urol, 2008. 179(6): p. 2142-5.
- [36] Matin, S.F., et al., *Residual and recurrent disease following renal energy ablative therapy: a multi-institutional study*. J Urol, 2006. 176(5): p. 1973-7.
- [37] Michaels, M.J., et al., *Incomplete renal tumor destruction using radio frequency interstitial ablation*. J Urol, 2002. 168(6): p. 2406-9; discussion 2409-10.
- [38] Kunkle, D.A. and R.G. Uzzo, *Cryoablation or radiofrequency ablation of the small renal mass : a meta-analysis*. Cancer, 2008. 113(10): p. 2671-80.
- [39] Kunkle, D.A., B.L. Egleston, and R.G. Uzzo, *Excise, ablate or observe: the small renal mass dilemma--a meta-analysis and review*. J Urol, 2008. 179(4): p. 1227-33; discussion 1233-4.
- [40] Johnson, D.B., et al., *Defining the complications of cryoablation and radio frequency ablation of small renal tumors: a multi-institutional review*. J Urol, 2004. 172(3): p. 874-7.
- [41] Zagoria, R.J., et al., *Percutaneous CT-guided radiofrequency ablation of renal neoplasms: factors influencing success*. AJR Am J Roentgenol, 2004. 183(1): p. 201-7.
- [42] Chapelon, J.Y., et al., *Effects of high-energy focused ultrasound on kidney tissue in the rat and the dog*. Eur Urol, 1992. 22(2): p. 147-52.
- [43] Vallancien, G., et al., *Focused extracorporeal pyrotherapy: experimental study and feasibility in man*. Semin Urol, 1993. 11(1): p. 7-9.
- [44] Marberger, M., et al., *Extracorporeal ablation of renal tumours with high-intensity focused ultrasound*. BJU Int, 2005. 95 Suppl 2: p. 52-5.
- [45] Hacker, A., et al., *Extracorporeally induced ablation of renal tissue by high-intensity focused ultrasound*. BJU Int, 2006. 97(4): p. 779-85.

- [46] Ritchie, R.W., et al., *Extracorporeal high intensity focused ultrasound for renal tumours: a 3-year follow-up*. BJU Int. 106(7): p. 1004-9.
- [47] Kohrmann, K.U., et al., *High intensity focused ultrasound as noninvasive therapy for multilocal renal cell carcinoma: case study and review of the literature*. J Urol, 2002. 167(6): p. 2397-403.
- [48] Ankem, M.K. and S.Y. Nakada, *Needle-ablative nephron-sparing surgery*. BJU Int, 2005. 95 Suppl 2: p. 46-51.
- [49] Kigure, T., et al., *Laparoscopic microwave thermotherapy on small renal tumors: experimental studies using implanted VX-2 tumors in rabbits*. Eur Urol, 1996. 30(3): p. 377-82.
- [50] Clark, P.E., et al., *Microwave ablation of renal parenchymal tumors before nephrectomy: phase I study*. AJR Am J Roentgenol, 2007. 188(5): p. 1212-4.
- [51] Liang, P., et al., *Ultrasound guided percutaneous microwave ablation for small renal cancer: initial experience*. J Urol, 2008. 180(3): p. 844-8; discussion 848.
- [52] Naito, S., et al., *Application of microwave tissue coagulator in partial nephrectomy for renal cell carcinoma*. J Urol, 1998. 159(3): p. 960-2.
- [53] Lotfi, M.A., P. McCue, and L.G. Gomella, *Laparoscopic interstitial contact laser ablation of renal lesions: an experimental model*. J Endourol, 1994. 8(2): p. 153-6.
- [54] Deane, L.A. and R.V. Clayman, *Review of minimally invasive renal therapies: Needle-based and extracorporeal*. Urology, 2006. 68(1 Suppl): p. 26-37.
- [55] Ponsky, L.E., et al., *Initial evaluation of Cyberknife technology for extracorporeal renal tissue ablation*. Urology, 2003. 61(3): p. 498-501.
- [56] Ponsky, L.E., et al., *Renal radiosurgery: initial clinical experience with histological evaluation*. Surg Innov, 2007. 14(4): p. 265-9.

IntechOpen



Current Cancer Treatment - Novel Beyond Conventional Approaches

Edited by Prof. Oner Ozdemir

ISBN 978-953-307-397-2

Hard cover, 810 pages

Publisher InTech

Published online 09, December, 2011

Published in print edition December, 2011

Currently there have been many armamentaria to be used in cancer treatment. This indeed indicates that the final treatment has not yet been found. It seems this will take a long period of time to achieve. Thus, cancer treatment in general still seems to need new and more effective approaches. The book "Current Cancer Treatment - Novel Beyond Conventional Approaches", consisting of 33 chapters, will help get us physicians as well as patients enlightened with new research and developments in this area. This book is a valuable contribution to this area mentioning various modalities in cancer treatment such as some rare classic treatment approaches: treatment of metastatic liver disease of colorectal origin, radiation treatment of skull and spine chordoma, changing the face of adjuvant therapy for early breast cancer; new therapeutic approaches of old techniques: laser-driven radiation therapy, laser photo-chemotherapy, new approaches targeting androgen receptor and many more emerging techniques.

How to reference

In order to correctly reference this scholarly work, feel free to copy and paste the following:

Seshadri Sriprasad and Howard Marsh (2011). The Management of Small Renal Tumours by Ablative Therapies, Current Cancer Treatment - Novel Beyond Conventional Approaches, Prof. Oner Ozdemir (Ed.), ISBN: 978-953-307-397-2, InTech, Available from: <http://www.intechopen.com/books/current-cancer-treatment-novel-beyond-conventional-approaches/the-management-of-small-renal-tumours-by-ablative-therapies>

INTECH
open science | open minds

InTech Europe

University Campus STeP Ri
Slavka Krautzeka 83/A
51000 Rijeka, Croatia
Phone: +385 (51) 770 447
Fax: +385 (51) 686 166
www.intechopen.com

InTech China

Unit 405, Office Block, Hotel Equatorial Shanghai
No.65, Yan An Road (West), Shanghai, 200040, China
中国上海市延安西路65号上海国际贵都大饭店办公楼405单元
Phone: +86-21-62489820
Fax: +86-21-62489821

© 2011 The Author(s). Licensee IntechOpen. This is an open access article distributed under the terms of the [Creative Commons Attribution 3.0 License](https://creativecommons.org/licenses/by/3.0/), which permits unrestricted use, distribution, and reproduction in any medium, provided the original work is properly cited.

IntechOpen

IntechOpen