

We are IntechOpen, the world's leading publisher of Open Access books Built by scientists, for scientists

6,900

Open access books available

185,000

International authors and editors

200M

Downloads

Our authors are among the

154

Countries delivered to

TOP 1%

most cited scientists

12.2%

Contributors from top 500 universities



WEB OF SCIENCE™

Selection of our books indexed in the Book Citation Index
in Web of Science™ Core Collection (BKCI)

Interested in publishing with us?
Contact book.department@intechopen.com

Numbers displayed above are based on latest data collected.
For more information visit www.intechopen.com



The Treatment of Metastatic Liver Disease of Colorectal Origin

Tsoulfas Georgios and Pramateftakis Manousos-Georgios
Aristotle University of Thessaloniki
Greece

1. Introduction

Colorectal carcinoma (CRC) is one of the most frequent cancers in western societies, with an incidence of approximately 700 per million people. Every year there are approximately 125,000 new cases of colon cancer in the U.S. Fifteen percent of these patients will have liver metastases at the time of diagnosis, and another 50% will develop liver metastatic disease during the course of their disease (Kemeny et al., 2004). Although median survival of patients with untreated metastatic CRC is around 6 months, recent advances in adjuvant therapy after the colon resection offer the promise of a decrease in the number of cases with metastatic disease (Andre et al., 2004). Just as important, for the patients with liver metastatic disease, newer chemotherapeutic agents such as irinotecan and oxaliplatin, as well as new targeted agents such as cetuximab and bevacizumab in the current protocols have improved response rates and survival (Cunningham et al., 2004; Douillard et al., 2000; De Gramont et al., 2000; Hurwitz et al., 2004; Tournigand et al., 2004). Unfortunately, even with these combinations, the two-year survival is limited to 40% at best for patients with metastatic disease and only about 10% of patients with metastatic CRC survive beyond 5 years (McCarter & Fong, 2000).

These findings make surgical treatment the cornerstone of the therapeutic approach to this disease. Although only 10-25% of patients with liver metastatic disease are candidates for surgical resection, a combined therapeutic approach has shown the most promise, especially since it has been possible to convert around 15%-30% of previously considered unresectable patients and achieve survivals similar to the ones deemed resectable from the beginning (Bismuth et al., 1996). The majority of patients who undergo liver resection for metastases will experience intra- and/or extra-hepatic relapse of the disease. Even so, it has been demonstrated that resection of liver metastases increases survival, with 5-year survival rates of 30-50% in patients undergoing curative resections for their metastatic disease compared to 5-10% for non-operated patients (Fong et al., 1997; Kemeny et al., 2004; Scheele et al., 1990).

2. Defining resectable disease

The first question that has to be answered is what is considered resectable disease, a concept that has evolved significantly over time. Originally, it was felt that more than three metastatic liver lesions or patients with bilobar disease were not appropriate for resection.

However, more recent studies have shown that even in patients with poor prognostic signs, 5-year survival can be achieved after curative liver resection (Poston et al., 2005; Fong et al., 1999; Nordlinger et al., 1996). Despite the potential for cure, formal staging for liver metastases has not changed and remains stage IV along with incurable metastatic disease. The effort has thus been to identify appropriate selection criteria that allow discrimination of patients that would or would not benefit from surgical intervention. The value of these prognostic scoring systems is based on a combination of ability to predict outcome, as well as simplicity. Different studies have used a variety of prognostic features including age, number of metastases, size of the largest lesion, carcino-embryonic antigen (CEA) level, primary tumor stage, positive tumor resection margins, disease-free interval, positive lymph nodes from the primary, and have attempted to provide risk scores based on these factors (Fong et al., 1999; Nordlinger et al., 1996; Poston et al., 2005). Normograms have also been proposed as a potential improvement upon previous scoring systems. Rather than count risk factors, a normogram takes the specific value for each factor into account and calculates a specific score for each patient (Kattan et al., 2008). This leads to a potentially more accurate prediction, as it is specific to each patient. There is common agreement, however, in all these studies that although poor characteristics and high risk scores will definitely decrease survival, 5-year survival was still better compared to those patients with liver metastatic disease that had not undergone resection. As a result, none of these series suggested that patients with poor prognostic signs should not undergo surgery.

The indications have changed over time to the extent that currently a surgical resection would be of benefit if it is possible after resection to get an R0 resection, leave behind at least two contiguous segments and functional liver volume >20%. As it will be discussed later, even extra-hepatic metastatic disease is not necessarily a contraindication and more patients are being considered for resection (Khatri et al., 2005). Advances that have played a central role in this include preoperative portal vein embolization to induce hypertrophy of the nondiseased part of the liver that would remain behind, better vascular clamping techniques, controlled anatomic resection, the use of radiofrequency and microwave ablation for small lesions that may remain in the liver left behind after a resection, and more recently the use of image-guided liver surgery (Cash et al., 2007; Couinaud 1957; Curley et al., 1999; Fong & Wong 2009; Makuuchi et al., 1987, 1990).

Portal vein embolization (Figure 1) has allowed surgeons to be more aggressive in the treatment of CRC hepatic metastases, as one of the contraindications was a small future liver remnant (FLR) in patients with a small left lateral lobe who require an extended right hepatectomy. The small residual liver volume increases the risk of postoperative hepatic failure, and so in patients without cirrhosis a FLR of non-tumor volume of 25-30% is considered safe for hepatic resection. Selective portal vein embolization can produce atrophy of the segments affected by the cancer and compensatory hypertrophy of the contralateral segments, providing an increase of 10-30% in the FLR. Overall, there is no agreement that any specific substance is significantly better for the embolization. As helpful as this technique is, there have been several concerns raised. One potential difficulty for patients with metastatic CRC is that portal vein embolization may end up promoting tumor growth, thereby increasing the incidence of recurrence following liver resection. However, in a study of the long term survival following portal vein embolization, with 41 patients with CRC liver metastases, there was no evidence to suggest that patients whose surgery had been made possible by this technique were associated with a poorer long term survival (Elias et al., 2002). Given that the waiting time between embolization and resection is

usually around 6 weeks, an additional concern is the effect of chemotherapy administered during the periprocedural period on the FLR hypertrophy and on the tumor growth in embolized segments in patients with CRC liver metastases. In a study of patients receiving chemotherapy after the portal vein embolization, FLR hypertrophied whether the patient had received chemotherapy or not; however, the hypertrophy was significantly less in those patients that had received post-embolization chemotherapy suggesting that although chemotherapy is not contraindicated, it should be considered carefully in those patients requiring a large compensatory hypertrophy (Beal et al., 2006).

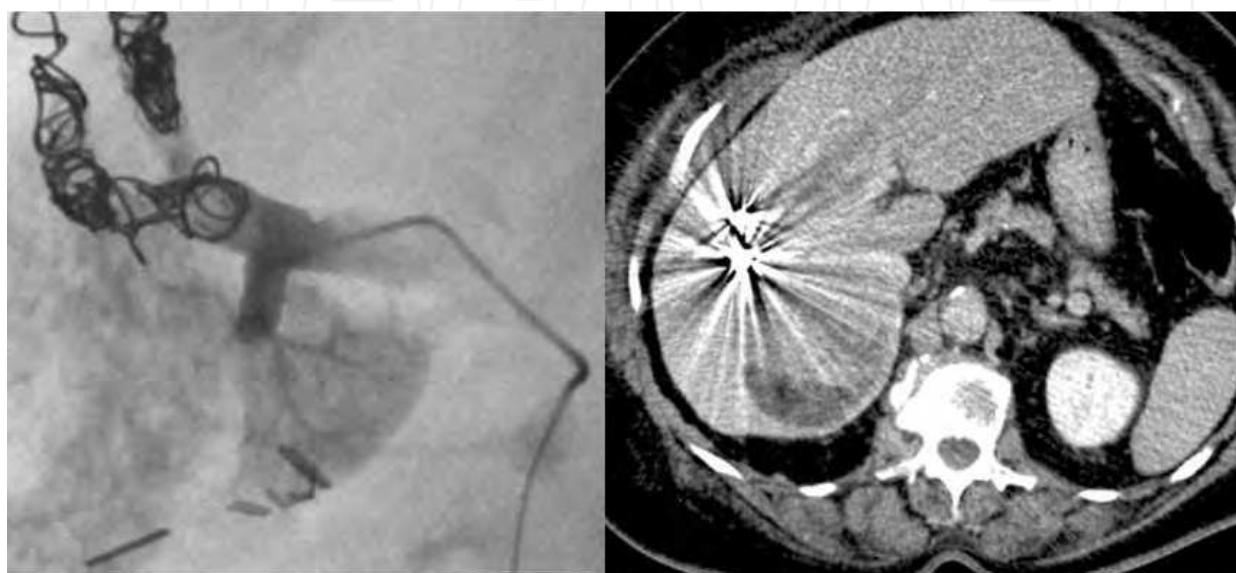
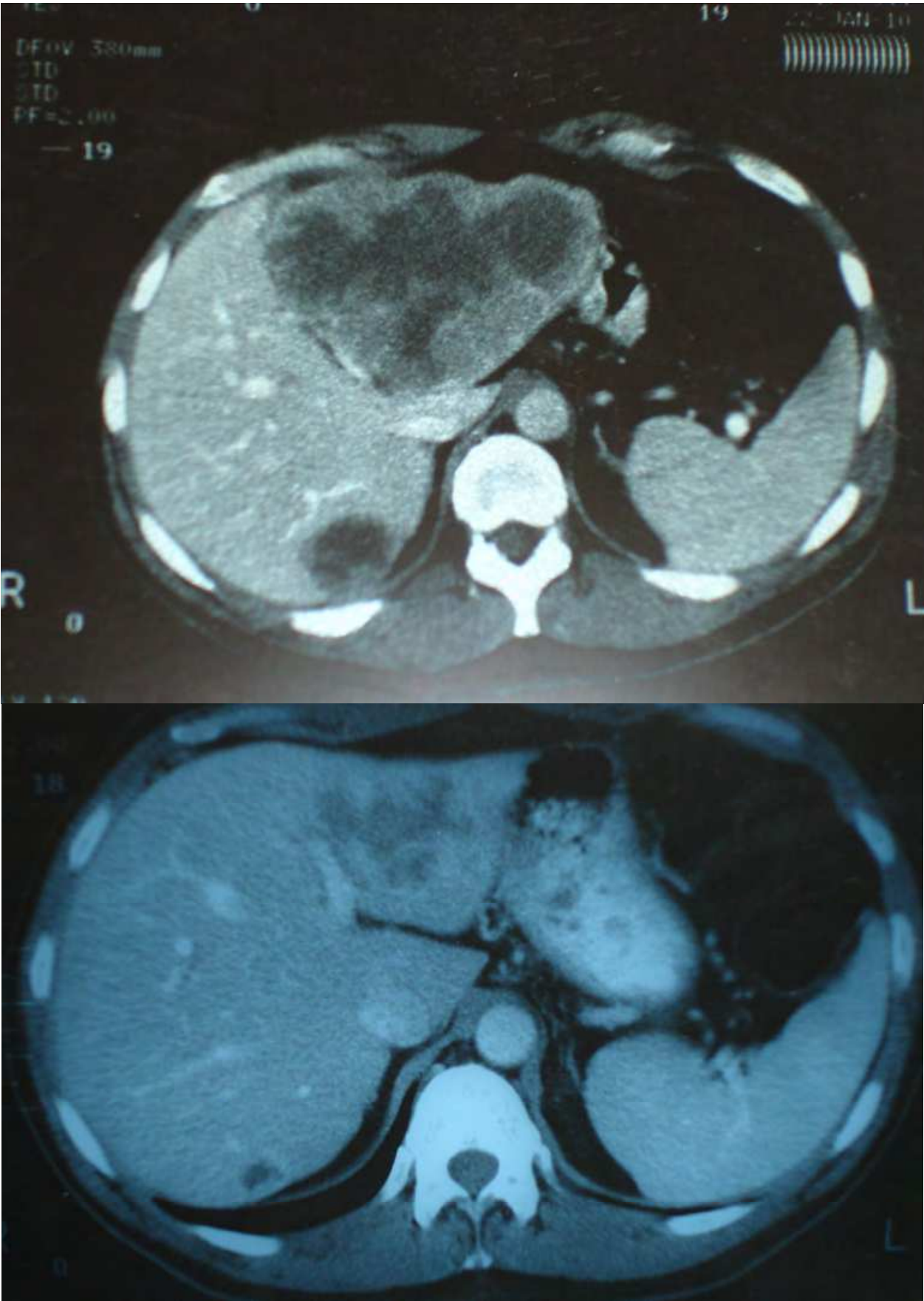

Fig. 1. Embolization of right portal vein branch to induce hypertrophy of the future left lobe remnant in anticipation of planned hepatectomy.

3. The role of chemotherapy

The targeted use of chemotherapy, such as 5-fluorouracil, Leucovorin and Oxaliplatin (FOLFOX) and 5-fluorouracil, Leucovorin and Irinotecan (FOLFIRI) has been critical in increasing resectability with rates ranging from 10% to 35% (Alberts et al., 2005; Ho et al., 2005; Masi et al., 2006; Wein et al., 2003). Comparisons have been somewhat difficult because of the different ways that unresectability is perceived or defined. Some studies include number of lesions or bilobar disease, whereas others look at more technical issues, such as involvement of all three hepatic veins, both portal veins, or the retrohepatic vena cava, or that resection would leave less than two segments or not an adequate liver reserve. Even with these limitations, there is definitely a role for neoadjuvant treatment in moving from unresectable disease to surgical cure (Figure 2 a, b, c).

More interesting is the question of the use of chemotherapy prior to resection in the case of resectable lesions. Arguments in favor include the decrease in tumor size, the potential control of micrometastatic disease, the assessment of the activity of chemotherapy as a method of in vivo chemosensitivity, improved chemotherapy tolerance, and a potential marker for the success of liver surgery (Adam et al., 2004; Fong et al., 1999; Nordlinger et al., 1996; Poston et al., 2005; Sauer et al., 2004). Arguments against preoperative chemotherapy use in resectable patients include liver toxicity (chemotherapy-associated steatohepatitis or CASH), risk of progression or growth in other sites, selection of resistant clones and the fact



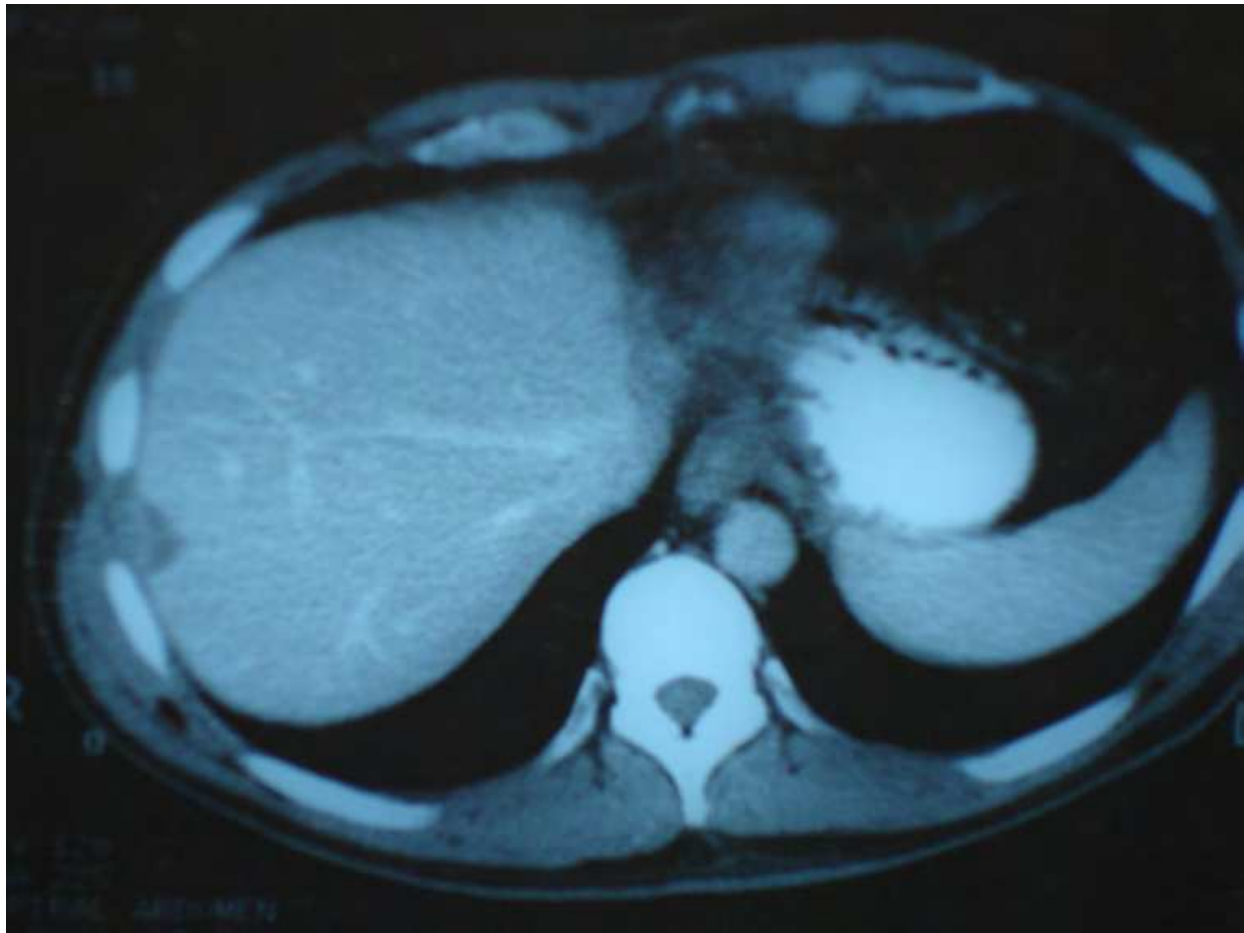

Fig. 2. a, b, c: Example of a good response to chemotherapy leading to resection of the metastatic disease. (a) CT of a patient with a large left lobe liver metastatic lesion from CRC. (b) Decrease in size of metastatic lesion after a full course of chemotherapy. (c) CT scan after the patient underwent a left hepatectomy and a radiofrequency ablation of a lesion on the right.

that response may make the surgery more difficult (Fernandez et al., 2005; Karakousis & Fong, 2009; Kooby et al., 2003). Specifically, as 70% of patients respond to cetuximab and FOLFOX chemotherapy and another 25% have stable disease, it is a very small percentage of 5-10% who may experience disease progression while receiving first line chemotherapy (Nordlinger et al., 2008; Tabernero et al., 2007). As a result, it is only after failure of first line chemotherapy that the concept of *in vivo* chemosensitivity makes sense. More importantly, advances in identifying molecular patterns and predictors of response have increased the value of resection, as such a strategy would make it possible to interrogate the tissues completely and potentially choose the best chemotherapy. One such example is the finding that tumor analysis for K-ras mutation status can be used as a predictor of response to cetuximab and oxaliplatin (Bibeau et al., 2009). Another problem with neoadjuvant chemotherapy for resectable lesions is that in a recent study only 66% of disappearing liver metastases following chemotherapy were complete responses, which means that a significant percentage of metastatic lesions were still present as the result of a reduction in the sensitivity of imaging during chemotherapy (Auer et al., 2010). This could lead to incomplete, noncurative resections. Overall, the prevailing opinion appears to be that,

unless the lesions are metachronous and of borderline resectability, they should be resected first with chemotherapy to follow (Figure 3).

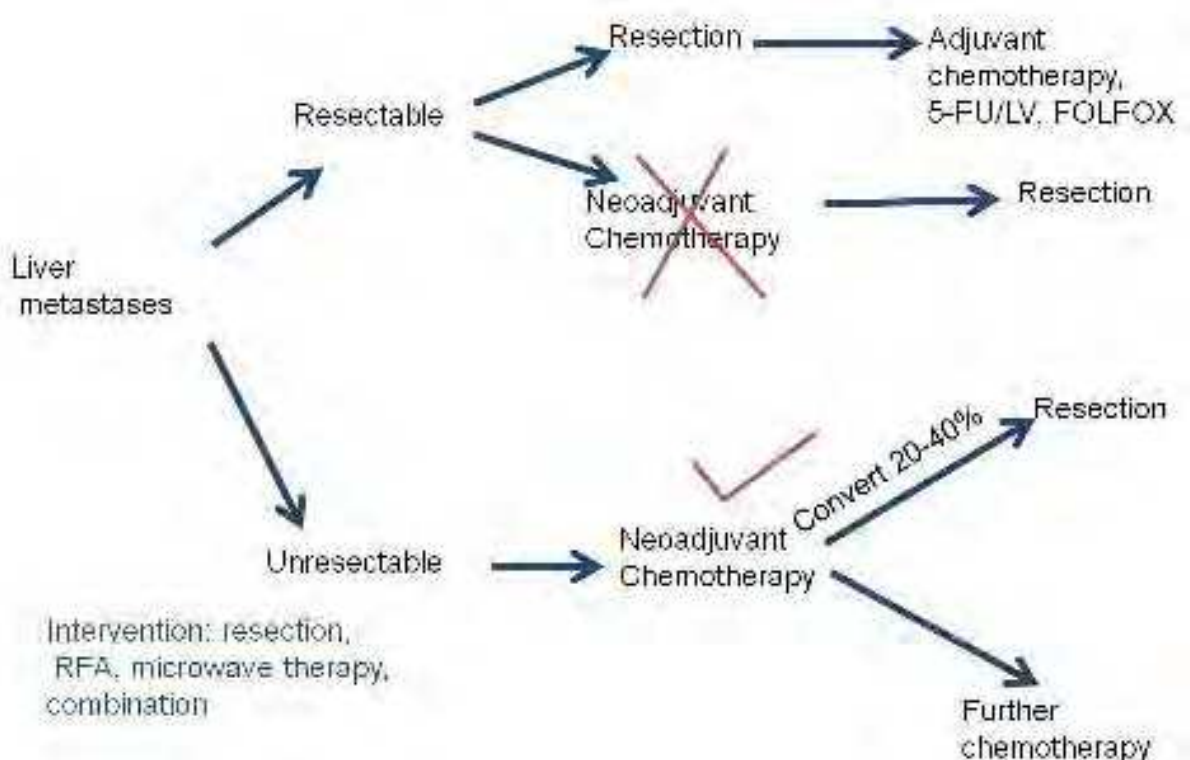


Fig. 3. Proposed algorithm for the treatment of liver metastases from CRC regarding the role of surgery and chemotherapy.

Regarding the question of adjuvant treatment of choice, there is agreement that adjuvant therapy after liver resection is useful. If a patient has not received any prior chemotherapy, treatment with 5-fluorouracil/leucovorin or FOLFOX are both reasonable choices, although there is definitely a need for further trials in the adjuvant setting (Park et al., 2007; Portier et al., 2006). For patients that fail first line adjuvant therapy molecular profiles, when available, may help in determining the optimal treatment. If a patient's disease has failed to respond to FOLFOX or FOLFIRI, then there exist options such as irinotecan/cetuximab or Xeloda/bevacizumab, treatments with a high cost of about \$100,000 for 6 months. These patients need to be enrolled in registries and treated under protocols, so that decisions can be made based on available data.

4. Pre- and intra-operative plan

4.1 Pre-operative planning

It was not unusual having percentages as high as 40% of patients found to be unresectable during surgery, mainly because of the difficulties in properly assessing the location and number of metastatic lesions (Steele et al., 1991). Progress has been made and in order to determine the resectability of the lesion preoperatively, radiologic studies can offer valuable information. Specifically, a triple phase CT with volumetry can be used to identify the location and vascular supply of the lesions and serve as a road map, as well as an estimate

of whether a resection would leave behind an adequate liver remnant. More advanced versions of this are the computer-generated models that allow an image-guided approach to the resection of these lesions, even in real time (Cash et al., 2007; Fong & Wong, 2009). One example is the MeVis software package from HepaVision (Bremen, Germany) which allows a computer-assisted 3D surgery planning. This leads to improved pre-operative planning on how to gain better access to the metastatic lesions even in regions at risk for devascularization or impaired drainage. Also, the volume of the remaining liver parenchyma is calculated separately for each resection proposal (Figure 4).

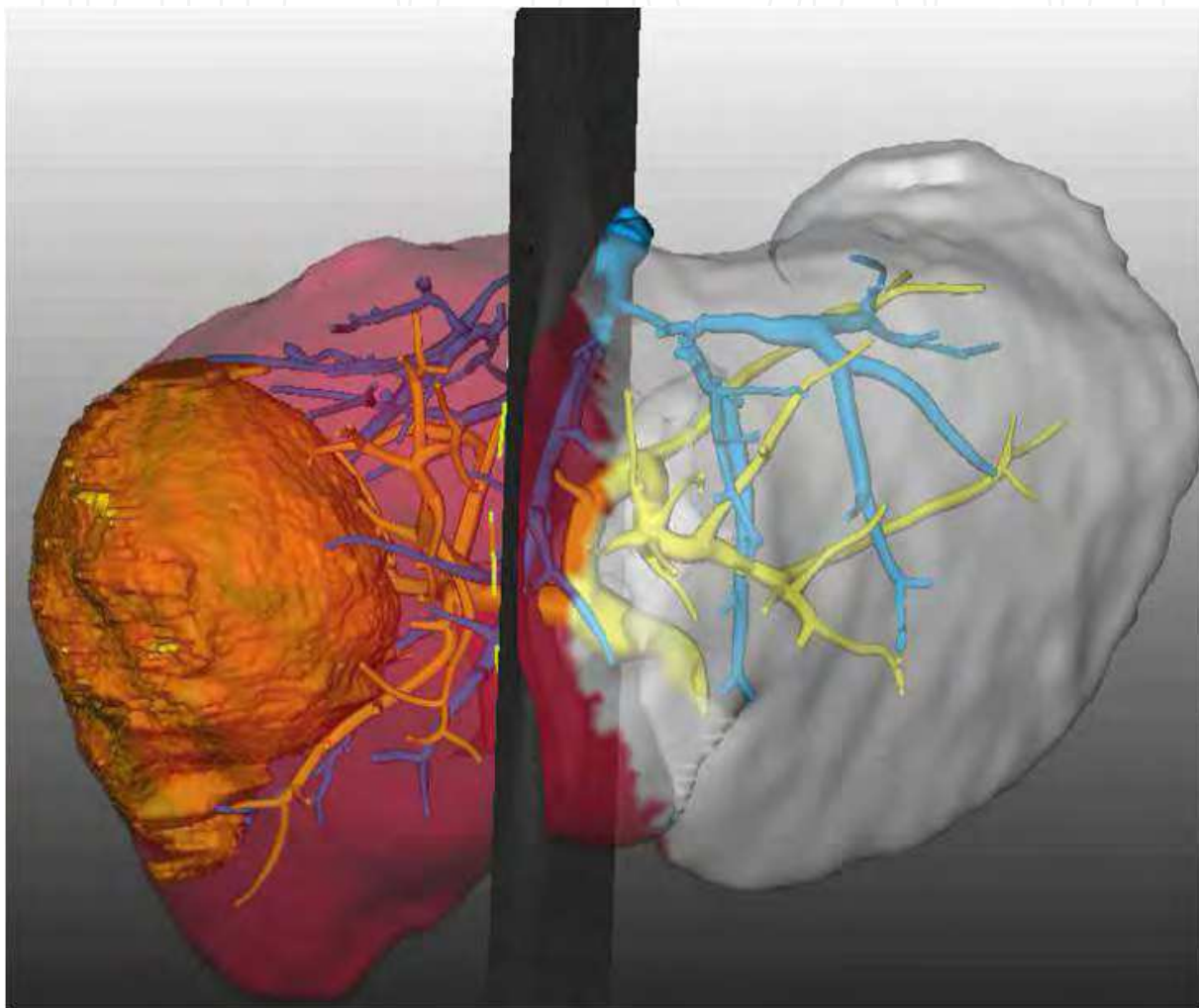


Fig. 4. 3D modelling of a large right lobe metastatic lesion based on CT data obtained using the MeVis system (HepaVision, Bremen, Germany), that allows visualization of the vasculature of the mass, as well as its relation to the venous drainage system of the liver and an estimation of the remaining liver volume based on the proposed resection plane.

It is also important to perform a thorough search for extrahepatic disease, to either exclude the patient from resection, or at least have a plan that would address the different sites of metastatic disease. For a patient with isolated liver metastatic disease, a CT of the chest, abdomen and pelvis is performed at first to identify the full extent of the hepatic disease, as well as discover any extrahepatic disease. FDG-PET has also been used to both identify the presence of hepatic colorectal metastases and to improve the staging of patients under

consideration for resection (Truant et al., 2005). Although PET can be a valuable resource in helping define whether a lesion is metastatic or not, there are limitations, such as the fact that it may miss small lesions, it is expensive, and that it may be affected by recent administration of chemotherapy. Hepatic lesions identified should not be biopsied as there is a real risk of extrahepatic dissemination of tumor with percutaneous biopsies (Metcalf et al., 2004).

4.2 Intra-operative planning

This diligence should continue intraoperatively, where laparoscopy at the beginning of the surgery may identify occult metastatic disease that may prevent an unnecessary laparotomy. Furthermore, the use of intraoperative ultrasound is almost mandatory, both to identify the known lesions and their location in relation to the surrounding vessels, as well as to look for other lesions that may not have been detected preoperatively (Figure 5). Intraoperative ultrasound allows confirmation of expected sites of disease and may detect additional lesions in 10-50% of cases (Machi et al., 1991; Makuuchi et al., 1991). Confirmation of the hepatic vascular anatomy in relation to the lesion and identification of specific segmental pedicles give the surgeon the opportunity to obtain a clear demarcation line in the parenchyma by occluding the vascular pedicle responsible. This allows resection of only the involved parenchyma with an exact transection plane.

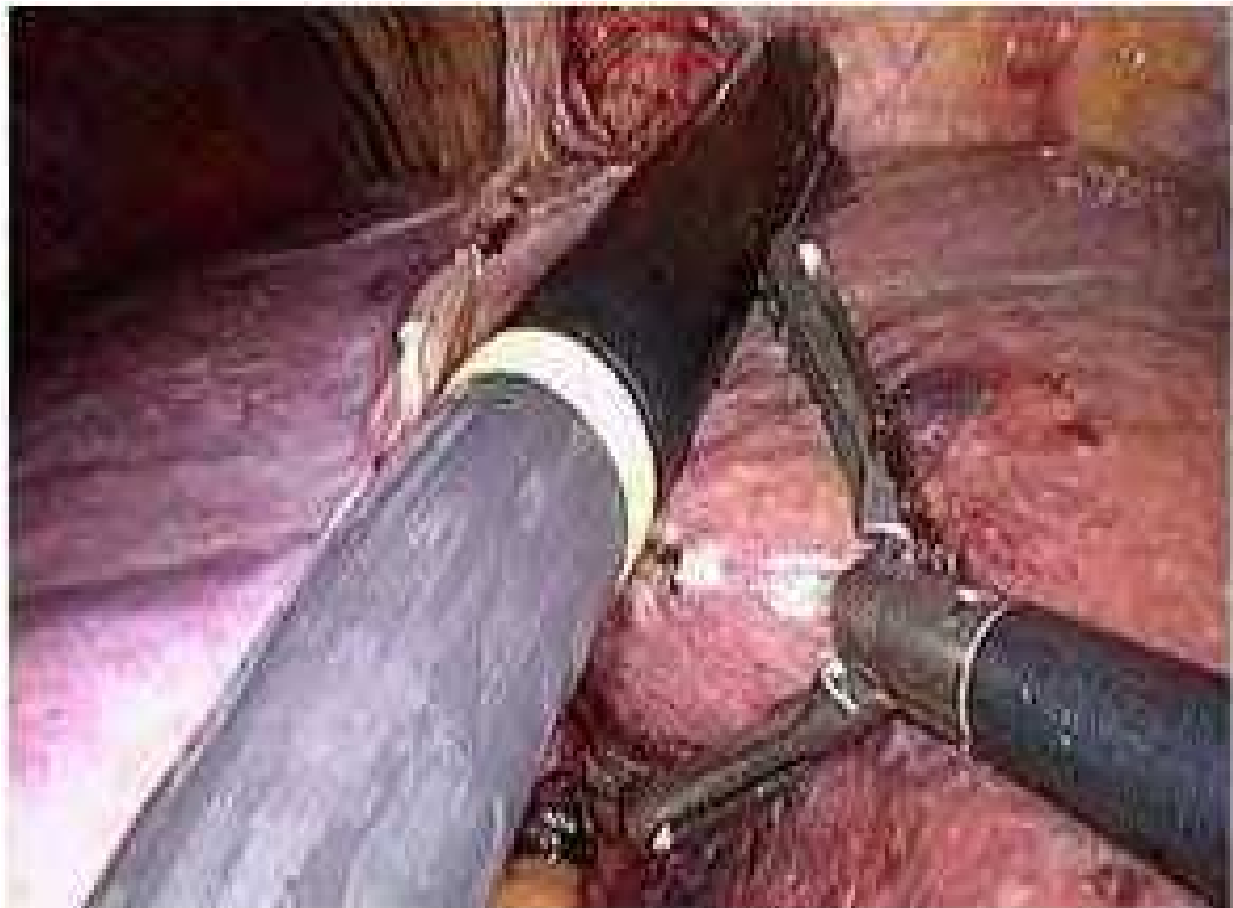
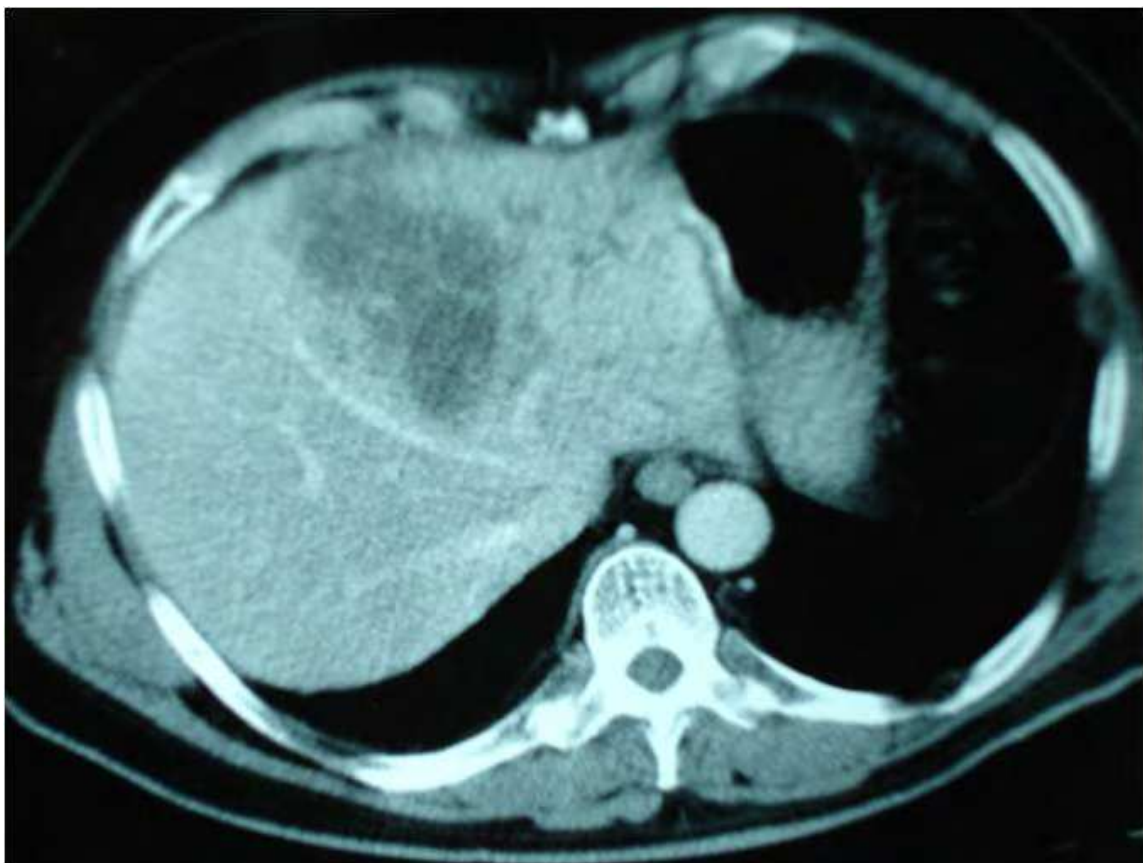
Fig. 5. Intraoperative US of the liver during a laparoscopic liver resection.

Regarding the technical part of the resection, the aim is to resect the liver parenchyma with minimal bleeding, avoiding biliary leaks and leaving adequate functional liver. Various techniques can be used according to surgeon preference to achieve this, including the use of hemostatic clamps, the handle of a scalpel, or finger fracture. More recently, there is widespread use of ultrasonic dissection using ultrasonic aspirators (an acoustic vibrator, perfused with saline, which disrupts the liver parenchyma by producing a cavitation force), or other instruments such as water-jet dissection or ultrasonic cutting. Prior to division of the parenchyma, whenever possible, vascular occlusion can be attempted to minimize bleeding, and which is subsequently released at the end of the parenchymal dissection.

Over the last several years there has been a more aggressive approach undertaken by many surgeons in the treatment of CRC liver metastases, based on the significant improvements in surgical techniques, adjunctive treatments such as portal vein embolization and radiofrequency ablation, and the effectiveness of newer chemotherapeutic regimens. This has led to a change in surgical approach with an increase of nonanatomical resections (Gold et al., 2008). This technique maximizes the amount of residual parenchyma, which is important for patients at risk for hepatic insufficiency, as well as in those that have received chemotherapy (Figure 6 a,b).



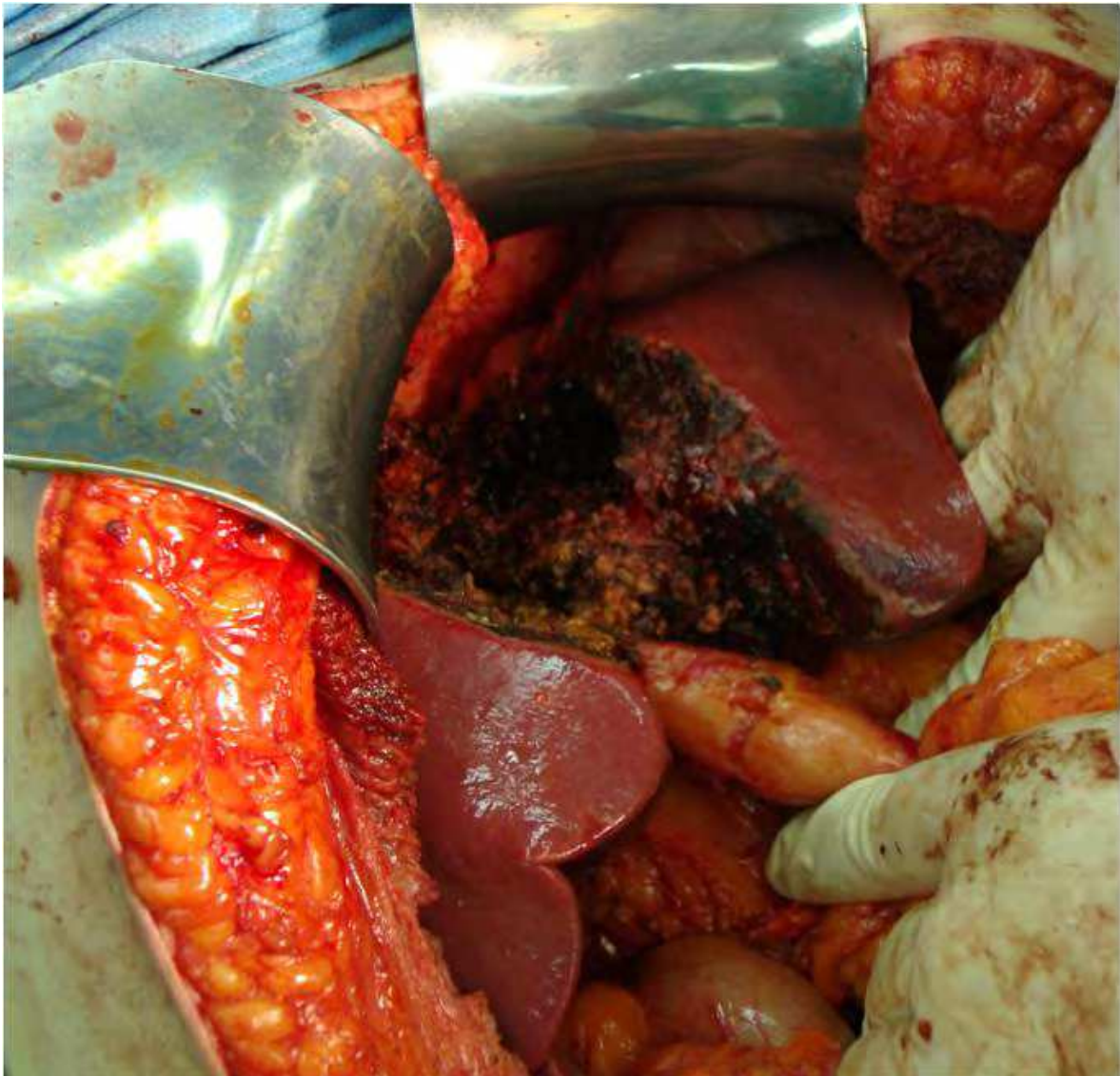

Fig. 6. a, b: (a) CT of a large CRC hepatic metastatic lesion. (b) Nonanatomical resection of central CRC hepatic metastatic lesion.

Additionally, in case of intrahepatic recurrences after partial liver resection in patients with liver metastatic disease, a sufficient liver remnant allows the possibility of further surgical or ablative treatments (Figure 7 a,b). Sparing liver parenchyma may also mean minimizing the surgical stress involved for the patients as the surgery becomes more targeted, something which can translate to shorter operating times and decreased blood loss (Stewart et al., 2004).

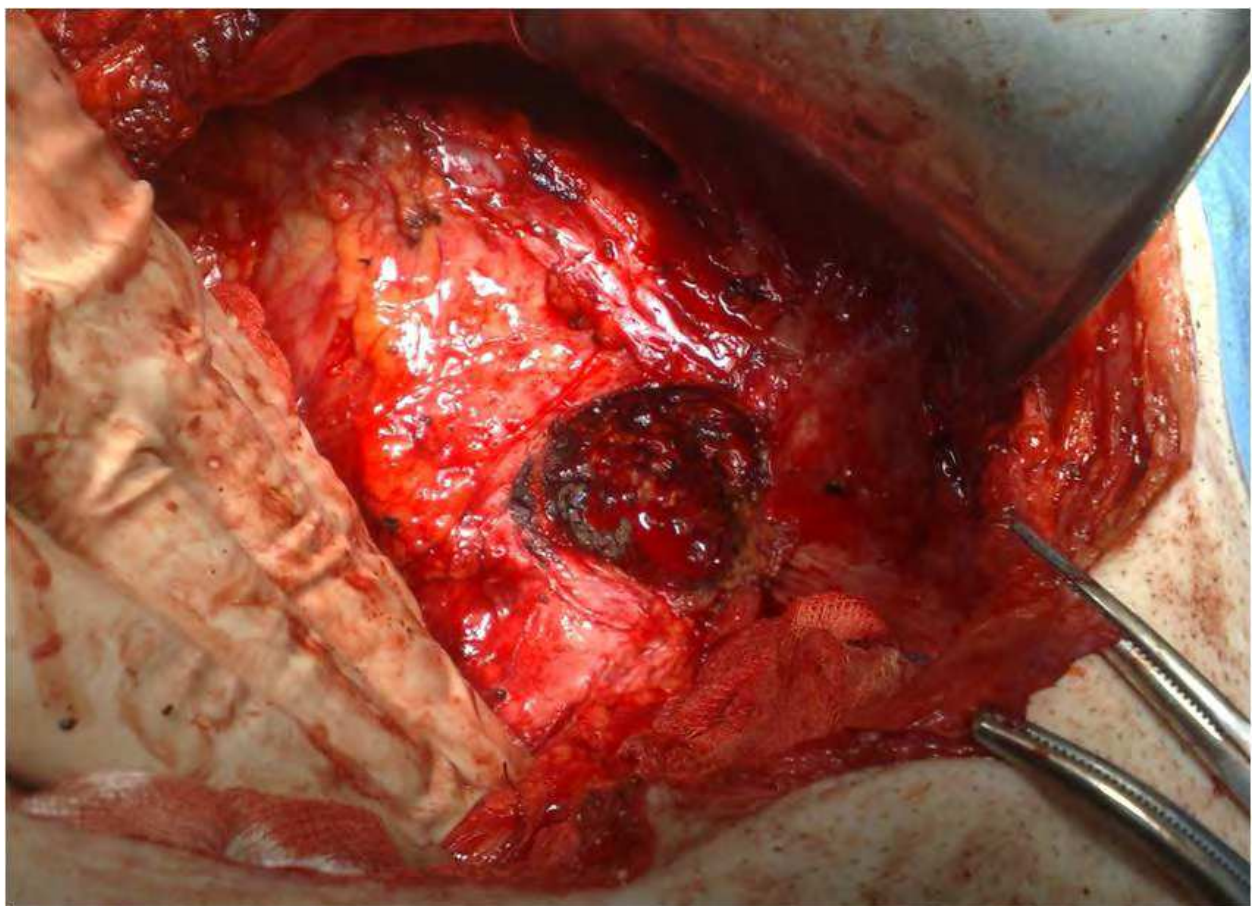
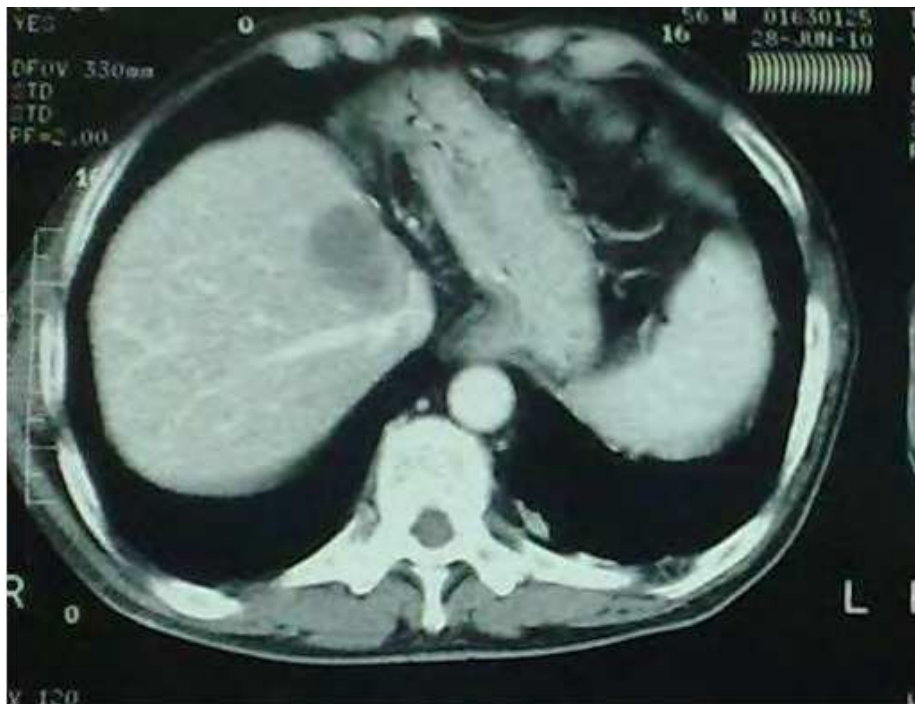

Fig. 7. a, b: (a) CT of a CRC hepatic metastatic lesion in a patient that had undergone a previous left hepatectomy for another metastatic lesion. (b) Nonanatomical repeat resection of metastatic lesion in close proximity to the hepatic veins.

5. Technical considerations & controversies

5.1 Laparoscopic resection

Since the first laparoscopic liver resection was reported in 1992, the number has increased significantly, numbering in the several thousands, as the technique offers the advantages over open surgery of reduced postoperative pain, less operative morbidity, shorter hospital stay, and faster recovery (Buell et al., 2008; Koffron et al., 2007). These lesions can be resected using a totally laparoscopic technique, a robotic-assisted minimally invasive technique, or a hand-assisted laparoscopic approach. The latter is considered as a safe first step in the learning curve, as it offers the surgeon the safety of having a hand inside the abdomen, thus making it easier to obtain vascular control, should that become necessary (Figure 8).

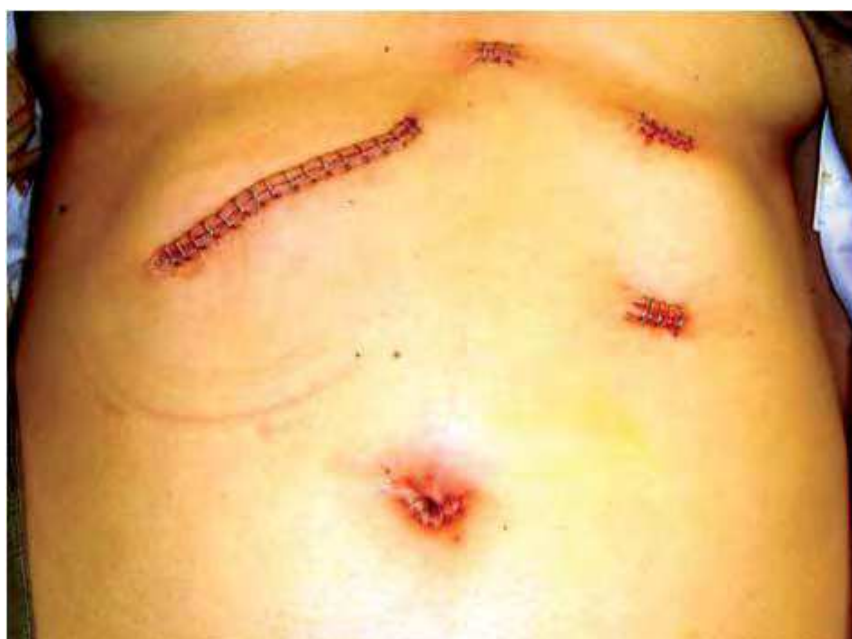

Fig. 8. Port placement for the performance of a hand-assisted laparoscopic liver resection.

Despite the early introduction of laparoscopic liver resection, the technique has not gained widespread acceptance. Most hepatobiliary centers perform only open liver surgery, and even in centers performing laparoscopic liver resections, the open procedures are still the majority. One reason is the technical challenge of the procedure, as it is time-consuming and difficult to master laparoscopic liver resection. Especially for senior surgeons skilled in traditional hepatobiliary techniques, achieving mastery with a skill as complicated as laparoscopic liver resection may seem as a challenge not worth the effort. This can restrain the rapid development of laparoscopic hepatic resections in hepatobiliary centers. Another reason for the limited use of this technique is the fear that it represents a less oncologically sound method, by being less radical than the open procedure. This has not been shown to be the case, as laparoscopic liver resection does not appear to compromise oncological measures, such as margin status, disease-free survival and overall survival (Nguyen et al., 2011). In a multicenter, international series of laparoscopic resection for colorectal carcinoma metastases in 109 patients there were no perioperative deaths and a complication rate of 12% (Nguyen et al., 2009). The series included a significant number of major resections (45% were more than 3 segments) and negative margins were achieved in 94% of patients, with

overall survivals at 1-, 3- and 5-years of 88%, 69% and 50% respectively. These numbers are highly comparable to the open procedure regarding outcome.

Although the outcome between open and laparoscopic liver resection may be similar, there are areas where the laparoscopic procedure appears to have the upper hand, including median hospital stay and morbidity (Buell et al., 2008; Koffron et al., 2007). Another increasingly relevant question is that of the cost. It has been found that patients undergoing laparoscopic surgery have higher operating room costs compared to patients undergoing an open liver resection; however, the total hospital costs are not different between the two groups, mainly because the laparoscopic group of patients are able to leave the hospital sooner (Nguyen et al., 2011).

5.2 Treatment of synchronous metastases

Synchronous liver metastases, commonly defined as liver metastases occurring within 12 months of the colon primary, offer the challenge of the optimal timing for surgical resection. The original paradigm of the staged resection (colon primary first with the liver metastatic resection 2 to 3 months later), has begun to change and has evolved to one where good results can be achieved with simultaneous resection (Martin et al., 2003; Lyass et al., 2001). A study of 230 patients (70 undergoing simultaneous resection and 130 staged) revealed no difference in morbidity and mortality, but a significantly shorter hospital stay for the group undergoing simultaneous resection (Martin et al., 2009). The main limitation of this strategy is that it can only be offered to a limited number of patients with synchronous disease and that it is associated with an increased risk of postoperative complications as the patient undergoes two major surgeries in the same setting (Reddy et al., 2007). Recently, a “reverse strategy” has been advocated, in which preoperative chemotherapy is followed by resection of the CRC liver metastases first, followed by resection of the colorectal primary at a second stage (Mentha et al., 2006). This has been proposed for patients with advanced CRC liver metastases and a stable primary cancer, especially if it is a rectal one. The rationale is that complications (bleeding, perforation, obstruction) from the primary are rare in patients with stage IV CRC being treated with chemotherapy, and also that this way treatment of the metastatic disease is not delayed till completion of the treatment of the primary. A recent study has shown that all 3 strategies, namely the classic, the combined and the reverse in patients with synchronous presentation of liver metastases have similar outcomes (Brouquet et al., 2010). For this reason it is important to individualize the strategy according to the extent of the disease of both the primary and the metastases for each patient.

5.3 Management of extrahepatic disease

What was previously not an option, has gained significant ground as an aggressive multidisciplinary approach leads to long term survival in cases of serial metastasectomy of hepatic and pulmonary metastases from colon cancer. Studies have reported 5-year survivals of 51%, with the key being an aggressive approach where every time a metastatic lesion is identified, it is resected (Mineo et al., 2003; Nagakura et al., 2001; Shah et al., 2006). Although there have been reports of resection of portal lymph-nodes and peritoneal metastatic lesions, in addition to the hepatic ones, these should be viewed very cautiously as the results are rather disappointing (Adam et al., 2008; Yan et al., 2006). However, the possibility does remain that in time as our experience grows it may be possible to better

define long-term outcomes and identify biological markers that will predict tumor behavior, and thus enable a more aggressive approach.

5.4 Is there a role for liver transplantation?

The past experiences of liver transplantation for colorectal cancer liver metastases have led to long-term survival and even cure in some cases (Hoti & Adam, 2008; Kappel et al., 2006). This is not surprising since liver transplantation for liver-only metastatic disease is by definition an R0 resection and as such from an oncological perspective acceptable. However, from the perspective of liver transplantation, given the organ shortage, the outcome has to be comparable to other indications for liver transplantation. If we add to this the fact that overall survival following liver transplantation has dramatically improved and that patients with hepatic metastatic disease of colorectal origin present less of a technical challenge, given the lack of cirrhosis and portal hypertension, these patients should be considered relatively low-risk for liver transplantation. An additional argument is the use of a class of immunosuppressive medications, the mTOR inhibitors that have shown clinical effect and stabilization of disease for a variety of cancers, in their role as antiproliferative agents (Atkins et al., 2004; Chan et al., 2005; Fung et al., 2005).

Based on these premises, a group from Norway, taking advantage of the surplus of donor organs in that country, initiated a study where 16 patients underwent liver transplantation for isolated hepatic metastatic colorectal disease (Foss et al., 2010). Although 2-year survival was 94%, there was a high recurrence rate of 63%, with an excellent quality of life. These preliminary data seem promising; however, it is too early to tell whether this is a beneficial strategy. Specifically, it is important to evaluate the 5-year survival in order to see whether it is comparable to other indications for liver transplantation so as to justify the use of a limited organ supply. In addition, selection criteria for the candidates need to be refined to be able to decrease the high recurrence rate.

5.5 The role of combination therapy

The same aggressive approach to the treatment of colorectal liver metastases, has led to the use of several treatment modalities in combination, which in turn has led to renewed efforts towards dealing with more advanced lesions. In a series of 224 patients, where a very high number had multiple (five or more) bilateral liver lesions, treatment consisted of a combination of hepatic arterial chemotherapy, cryotherapy and resection (Yan et al., 2006). This led to 1-, 3-, and 5-year survival rates of 87%, 43% and 23% respectively in this high risk group of patients. The surgeon and the medical team have a wide armamentarium in their hands and it is up to them to find the right treatment modality for the right patient.

5.6 The role of ablative therapy

A special mention should be made regarding the role of ablative therapy in the treatment of liver metastatic disease from colorectal cancer, and especially that of radiofrequency ablation (RFA). With this technique a probe is inserted into the lesion and through the transfer of current the lesion is heated to the level of 90 to 100 degrees centigrade (Figure 9). The use of this method has grown exponentially with the combined use of intraoperative ultrasound as smaller lesions can be localized more accurately. Additionally, advances such as the use of multiple tines on these probes have made possible the ablation of bigger lesions up to 5 or 6cm.

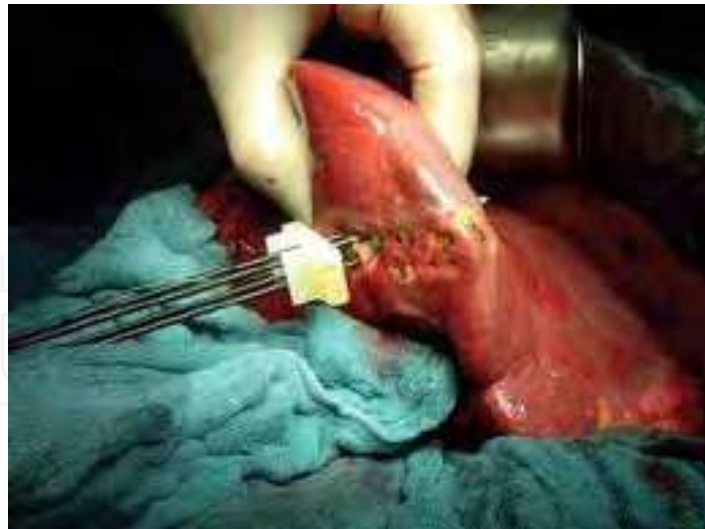

Fig. 9. Radiofrequency ablation of hepatic metastatic lesion from colorectal cancer.

As experience with RFA has increased over the last several years, there has been an effort to comprehensively evaluate the results. The American Society of Clinical Oncology in 2009 in a Clinical Evidence Review regarding RFA of hepatic metastases from colorectal cancer, suggests that, based on the existing evidence, hepatic resection improves overall survival compared to RFA, especially for patients with resectable tumors without extrahepatic disease (Wong et al., 2010). RFA investigators report a wide variability in the 5-yr survival rate (14% to 55%) and local tumor recurrence rate (3.6% to 60%). The reported mortality rate was low (0% to 2%), and the rate of major complications was commonly reported to be 6% to 9%. In another systematic review of the clinical benefit and role of radiofrequency ablation as treatment of colorectal liver metastases, the authors found that comparative studies indicated significantly improved overall survival after RFA versus chemotherapy alone, RFA plus chemotherapy versus RFA alone and up-front RFA versus RFA following second-line chemotherapy (Stang et al., 2009). The findings of these authors support the notion that RFA prolongs time without toxicity and survival as an adjunct to hepatectomy and/or chemotherapy in well-selected patients, but not as an alternative to resection.

6. Outcomes and keys to success

Treatment outcomes for patients with hepatic metastatic lesions from CRC have improved significantly over the last decade. This has been a result of a variety of factors, including improvements in surgical techniques and instrumentation, advances in chemotherapy, our understanding of tumor biology, but more importantly the use of multidisciplinary teams where the combined expertise of different specialties is used for the patient's benefit.

6.1 Outcome and recurrence after liver resection

Five-year overall survival for patients with hepatic metastases from CRC treated with the combination of surgery and chemotherapy ranges anywhere from 45% to 65% for both open and laparoscopic liver resections (Castaing et al., 2009; Ito et al., 2008; Kazaryan et al., 2010). Recurrence can occur in as many as 60% of patients following liver resection of colorectal metastatic disease, with the most frequent site of recurrence being the liver; in approximately 20% of these patients the liver may be the only site of recurrence and as a

result these patients may be suitable for re-resection (Wong et al., 2010). The vast majorities of these recurrences occur in the first two years and for that reason frequent surveillance with CT is critical for early detection. This becomes even more important if we consider that the reported morbidity and mortality rates, as well as overall survival rates after re-resection, despite the potential greater technical difficulty, are similar to those reported for the initial hepatectomy (Stang et al., 2009; Wong et al., 2010). In the current cost-conscious environment, the fact that intensive 3-monthly CT surveillance detects recurrence that is amenable to further resection in a considerable number of patients, leads to significantly better survival for these patients with a reasonable cost per life-year gained (Wanebo et al., 1996).

6.2 Use of multidisciplinary teams

A key component for a successful outcome for patients with hepatic metastases from colorectal cancer is the close cooperation between the colorectal and the hepatobiliary team. Both of these should consist of specialist surgeons, in addition to an oncologist, gastroenterologist, diagnostic and interventional radiologist, histopathologist and clinical nurse specialist. The goal is to achieve a multidisciplinary input, as well as develop protocols that will be the cornerstone of developing a “best practices” approach. The improved outcomes that we are witnessing in the management of liver metastatic lesions from colorectal cancer are most likely the result of this concerted effort, as well as possibly a volume effect.

7. Conclusion

Patients with hepatic metastases from colorectal cancer represent a difficult challenge for the medical and surgical team caring for them, as we are dealing with an advanced stage of a disease. However, the coordinated effort of the different specialties has made it possible to achieve 5-year survivals of 50% and in certain cases even talk about a cure. Central to this effort are the surgical advances and techniques that have allowed resection of these metastatic lesions in a safe and precise manner and have transformed the essential question from “what can be removed” to “what needs to be left behind”. Patients and physicians undertaking this endeavour need to be prepared for a “marathon”, as when dealing with metastatic lesions one has to be prepared for recurrences and find ways to address them. However, with a combination of proper patient selection, choice of the appropriate strategy in terms of combining surgery with chemotherapy, and application of the right mixture of resection and ablation techniques, it is possible to achieve optimal oncologic results in this very challenging group of patients.

8. References

- Adam R, de Haas RJ, Wicherts DA, et al. (2008). Is hepatic resection justified after chemotherapy in patients with colorectal liver metastases and lymph node involvement? *J Clin Oncol*, Vol.26, No.22, p. 3672-3680
- Adam R, Pascal G, Castaing D, et al. (2004). Tumor progression while on chemotherapy: a contraindication to liver resection for multiple colorectal metastases? *Ann Surg*, Vol.240, No.6, pp. 1052-1061

- Alberts SR, Horvath WL, Sternfeld WC, et al. (2005). Oxaliplatin, fluorouracil, and leucovorin for patients with unresectable liver-only metastases from colorectal cancer: a North Central Cancer Treatment Group phase II study. *J Clin Oncol*, Vol.23, No.36, pp. 9243-9249
- Andre T, Boni C, Mounedji-Boudiaf L et al. (2004). Oxaliplatin, fluorouracil, and leucovorin as adjuvant treatment for colon cancer. *N Engl J Med*, Vol.350, No.23, pp. 2343-2351
- Atkins MB, Hidalgo M, Stadler WM, et al. (2004). Randomized phase II study of multiple dose levels of CCI-779, a novel mammalian target of rapamycin kinase inhibitor, in patients with advanced refractory renal cell carcinoma. *J Clin Oncol*, Vol.22, No.5, pp. 909-918
- Auer RC, White RR, Kemeny NE, et al. (2010). Predictors of a true complete response among disappearing liver metastases from colorectal cancer after chemotherapy. *Cancer*, Vol.116, No.6, pp. 1502-1509
- Beal IK, Anthony S, Papadopolou A, et al. (2006). Portal vein embolisation prior to hepatic resection for colorectal liver metastases and the effects of periprocedure chemotherapy. *Br J Radiol*, Vol.79, No.942, pp. 473-478
- Bibeau F, Lopez-Crapez E, Di Fiore F, et al. (2009). Impact of Fc {gamma} RIIa-Fc{gamma}RIIIa polymorphisms and KRAS mutations on the clinical outcome of patients with metastatic colorectal cancer treated with cetuximab plus irinotecan. *J Clin Oncol*, Vol.27, No.7, pp. 1122-1129.
- Bismuth H, Adam R, Levi F, et al. (1996). Resection of nonresectable liver metastases from colorectal cancer after neoadjuvant chemotherapy. *Ann Surg*, Vol.224, No.4, pp.509-522
- Brouquet A, Mortenson M, Vauthey JN, et al. (2010). Surgical strategies for synchronous colorectal liver metastases in 156 consecutive patients: classic, combined or reverse strategy? *J Am Coll Surg*, Vol.210, No.6, pp. 934-941
- Buell JF, Thomas MT, Rudich S, et al. (2008). Experience with more than 500 minimally invasive hepatic procedures. *Ann Surg*, Vol.248, No.3, pp.475-486
- Cash DM, Miga MI, Glasgow SC, et al. (2007). Concepts and preliminary data toward the realization of image-guided liver surgery. *J Gastrointest Surg*, Vol.11, No.7, pp. 844-859
- Castaing D, Vibert E, Ricca L, et al. (2009). Oncologic results of laparoscopic versus open hepatectomy for colorectal liver metastases in two specialized centers. *Ann Surg*, Vol.250, No.5, pp. 849-855
- Chan S, Scheulen ME, Johnston S, et al. (2005). Phase II study of temsirolimus (CCI-779), a novel inhibitor of mTOR, in heavily pretreated patients with locally advanced or metastatic breast cancer. *J Clin Oncol*, Vol.23, No.23, pp. 5314-5322
- Couinaud C. (1957). *Le Foie, Etudes Anatomiques et Chirurgicales*. Masson & Cie, Paris.
- Cunningham D, Humblet Y, Siena S et al. (2004). Cetuximab monotherapy and cetuximab plus irinotecan in irinotecan-refractory metastatic colorectal cancer. *N Engl J Med*, Vol.351, No.4, pp. 337-345
- Curley SA, Izzo F, Delrio P, et al. (1999). Radiofrequency ablation of unresectable primary and metastatic hepatic malignancies: results in 123 patients. *Ann Surg*, Vol.230, No. 1, pp. 1-8

- De Gramont A, Figer A, Seymour M et al. (2000). Leucovorin and fluorouracil with or without oxaliplatin as first-line treatment in advanced colorectal cancer. *J Clin Oncol*, Vol.18, No.16, pp. 2938-2947
- Douillard JY, Cunningham D, Roth AD et al. (2000). Irinotecan combined with fluorouracil compared with fluorouracil alone as first-line treatment for metastatic colon cancer: a multicentre randomized trial. *Lancet*, Vol.355, No. 9209, pp. 1041-1047
- Elias D, Quellet JF, de Baere T, et al. (2002). Portal vein embolization before hepatectomy for liver metastases: long-term results and impact on survival. *Surgery*, Vol.131, No.3, pp. 294-299
- Fernandez FG, Ritter J, Goodwin JW, et al. (2005). Effect of steatohepatitis associated with irinotecan or oxaliplatin pretreatment on resectability of hepatic colorectal metastases. *J Am Coll Surg*, Vol.200, No.6, pp. 845-853
- Fong Y, Wong J. (2009). Evolution in surgery: influence of minimally invasive approaches on the Hepatobiliary surgeon. *Surg Infect*, Vol.10, No.5, pp. 399-406
- Fong Y, Fortner J, Sun RL, et al. (1999). Clinical score for predicting recurrence after hepatic resection for metastatic colorectal cancer: analysis of 1001 consecutive cases. *Ann Surg*, Vol.230, No.3, pp. 309-318
- Fong Y, Cohen AM, Fortner JG et al. (1997). Liver resection for colorectal metastases. *J Clin Oncol*, Vol.15, No.3, pp. 938-946
- Foss A, Adam R, Dueland S. (2010). Liver transplantation for colorectal liver metastases: revisiting the concept. *Transpl Int*, Vol.23, No.7, pp. 679-685
- Fung J, Kelly D, Kadry Z, et al. (2005). Immunosuppression in liver transplantation: beyond calcineurin inhibitors. *Liver Transpl*, Vol.11, No. 3, pp. 267-280
- Gold JS, Are C, Kornprat P, et al. (2008). Increased use of parenchymal-sparing surgery for bilateral liver metastases from colorectal cancer is associated with improved mortality without change in oncologic outcome: trends in treatment over time in 440 patients. *Ann Surg*, Vol.247, No.1, pp. 109-117
- Ho WM, Ma B, Mok T, et al. (2005). Liver resection after irinotecan, 5-fluorouracil, and folinic acid for patients with unresectable colorectal liver metastases: a multicenter phase II study by the Cancer Therapeutic Research group. *Med Oncol*, Vol.22, No.3, pp. 303-312
- Hoti E, Adam R. (2008). Liver transplantation for primary and metastatic liver cancers. *Transpl Intl*, Vol.21, No.12, pp. 1107-1117
- Hurwitz H, Fehrenbacher L, Novotny W, et al. (2004). Bevacizumab plus irinotecan, fluorouracil, and leucovorin for metastatic colorectal cancer. *N Engl J Med*, Vol.350, No.23, pp. 2335-2342
- Ito H, Are C, Gonen M, et al. (2008). Effect of postoperative morbidity on long-term survival after hepatic resection for metastatic colorectal cancer. *Ann Surg*, Vol.247, No.6, pp. 994-1002
- Kappel S, Kandioler D, Steininger R, et al. (2006). Genetic detection of lymph node micrometastases: a selection criterion for liver transplantation in patients with liver metastases after colorectal cancer. *Transplantation*, Vol.81, No.1, pp. 64-70

- Karakousis G, Fong Y. (2009). The case of selective use of pre-operative chemotherapy for hepatic colorectal metastases: more is not always better. *Ann Surg Oncol*, Vol.16, No.8, pp. 2086-2088
- Kattan MW, Gonen M, Jarnagin WR, et al. (2008). A nomogram for predicting disease-specific survival after hepatic resection for metastatic colorectal cancer. *Ann Surg*, Vol.247, No.2, pp. 282-287
- Kazaryan AM, Pavlik Marangos I, Rosseland AR, et al. (2010). Laparoscopic liver resection for malignant and benign lesions: ten-year Norwegian single-center experience. *Arch Surg*, Vol.145, No.1, pp. 34-40
- Kemeny N, Kemeny MM, Lawrence TS. (2004). *Liver Metastases*. In: Abeloff MD, Armitage JO, Niederhuber JE et al (eds) *Clinical Oncology*, Third Edition. Elsevier Philadelphia, pp 1141-1178
- Khatr VP, Petrelli NJ, Belghiti J. (2005). Extending the frontiers of surgical therapy for hepatic colorectal metastases: is there a limit? *J Clin Oncol*, Vol.23, No.33, pp. 8490-8499
- Koffron AJ, Auffenberg G, Kung R, et al. (2007). Evaluation of 300 minimally invasive liver resections at a single institution: less is more. *Ann Surg*, Vol.246, No.3, pp. 385-392
- Kooby DA, Fong Y, Suriawinata A, et al. (2003). Impact of steatosis on perioperative outcome following hepatic resection. *J Gastrointest Surg*, Vol.7, No.8, pp. 1034-1044
- Lyass G, Zamir G, Matot I, et al. (2001). Combined colon and hepatic resection for synchronous colorectal liver metastases. *J Surg Oncol*, Vol.78, No.1, pp. 17-21
- Machi J, Isomoto H, Kurohiji T. (1991). Accuracy of intraoperative ultrasonography in diagnosing liver metastasis from colorectal cancer: evaluation with postoperative follow-up results. *World J Surg*, Vol.15, No.4, pp. 551-556
- Makuuchi M, Takayama T, Kosuge T, et al. (1991). The value of ultrasonography for hepatic surgery. *Hepatogastroenterology*, Vol.38, No.1, pp 64-70
- Makuuchi M, Thai BL, Takayasu K, et al. (1990). Preoperative portal embolization to increase safety of major hepatectomy for hilar bile duct carcinoma: a preliminary report. *Surgery*, Vol. 107, No.5, pp. 521-527
- Makuuchi M, Mori T, Gunven P, et al. (1987). Safety of hemihepatic vascular occlusion during resection of the liver. *Surg Gynecol Obstet*, Vol.164, No.2, pp. 155-158
- Martin RCG, Augenstein V, Reuter N, et al. (2009). Simultaneous versus staged resection for synchronous colorectal cancer liver metastases. *J Am Coll Surg*, Vol.208, No.5, pp. 842-85
- Martin R, Paty P, Fong Y, et al. (2003). Simultaneous liver and colorectal resections are safe for synchronous colorectal liver metastasis. *J Am Coll Surg*, Vol.197, No.2, pp. 233-241
- Masi G, Cupini S, Marcucci L, et al. (2006). Treatment with 5-fluorouracil/folinic acid, oxaliplatin, and irinotecan enables surgical resection of metastases in patients with


- initially unresectable metastatic colorectal cancer. *Ann Surg Oncol*, Vol.13, No.1, pp. 58-65
- McCarter MD, Fong Y. (2000). Metastatic liver tumors. *Semin Surg Oncol*, Vol.19, No.2, pp. 177-188
- Mentha G, Majno PE, Andres A, et al. (2006). Neoadjuvant chemotherapy and resection of advanced synchronous liver metastases before treatment of colorectal primary. *Br J Surg*, Vol.93, No.7, pp. 872-878
- Metcalf MS, Bridgewater FH, Mullin EJ, et al. (2004). Useless and dangerous – fine needle aspiration of hepatic colorectal metastases. *BMJ*, Vol.328, No.7438, pp. 507-508
- Mineo TC, Ambrogi V, Tonini G, et al. (2003). Longterm results after resection of simultaneous lung and liver metastases from colorectal carcinoma. *J Am Coll Surg*, Vol.197, No.3, pp. 386-391
- Nagakura S, Shirai Y, Yamato Y, et al. (2001). Simultaneous detection of colorectal carcinoma liver and lung metastases does not warrant resection. *J Am Coll Surg*, Vol.193, No.2, pp. 153-160
- Nguyen KT, Marsh JW, Tsung A, et al. (2011). Comparative benefits of laparoscopic vs open hepatic resection. *Arch Surg*, Vol.146, No.3, pp. 348-356
- Nguyen KT, Laurent A, Dagher I, et al. (2009). Minimally invasive liver resection for metastatic colorectal cancer: a multi-institutional, international report of safety, feasibility and early outcomes. *Ann Surg*, Vol.250, No.5, pp. 842-848
- Nordlinger B, Sorbye H, Glimelius B, et al. (2008). Perioperative chemotherapy with FOLFOX4 and surgery versus surgery alone for resectable liver metastases from colorectal cancer (EORTC intergroup trial 40983): a randomized controlled trial. *Lancet*, Vol.371, No.9617, pp.1007-1016
- Nordlinger B, Guiguet M, Vaillant JC, et al. (1996). Surgical resection of colorectal carcinoma metastases to the liver. A prognostic scoring system to improve case selection, based on 1568 patients. *Cancer*, Vol.77, No.7, pp. 1254-1262
- Park R, Gonen M, Kemeny N, et al. (2007). Adjuvant chemotherapy improves survival after resection of hepatic colorectal metastases: analysis of data from two continents. *J Am Coll Surg*, Vol.204, No.5, pp/ 753-761
- Portier G, Elias D, Bouche O, et al. (2006). Multicenter randomized trial of adjuvant fluorouracil and folinic acid compared with surgery alone after resection of colorectal liver metastases: FFCD ACHBTH AURC 9002 trial. *J Clin Oncol*, Vol.24, No.31, pp. 4976-4982
- Poston GJ, Adam R, Alberts S, et al. (2005). OncoSurge: a strategy for improving resectability with curative intent in metastatic colon cancer. *J Clin Oncol*, Vol.23, No.28, pp. 7125-7134
- Reddy SK, Pawlik Tm, Zorzi D, et al. (2007). Simultaneous resection of colorectal cancer and synchronous liver metastases: a multi-institutional analysis. *Ann Surg Oncol*, Vol.14, No.12, pp. 3481-3491

- Sauer R, Becker H, Hohenberger W, et al. (2004). Preoperative versus postoperative chemoradiotherapy for rectal cancer. *N Engl J Med*, Vol.351, No.17, pp. 1731-1740
- Scheele J, Stangl R, Altendorf-Hofmann A. (1990). Hepatic metastases from colorectal carcinoma: impact of surgical resection on the natural history. *Br J Surg*, Vol.77, No.11, pp. 1241-1246
- Shah SA, Haddad R, Al-Sukhni W, et al. (2006). Surgical resection of hepatic and pulmonary metastases from colorectal carcinoma. *J Am Coll Surg*, Vol.202, No.3, pp. 468-475
- Stang A, Fischbach R, Teichmann W, et al. (2009). A systematic review on the clinical benefit and role of radiofrequency ablation as treatment of colorectal liver metastases. *Eur J Cancer*, Vol.45, No.10, pp. 1748-1756
- Steele G, Bleday R, Mayer RJ, et al. (1991). A prospective evaluation of hepatic resection for colorectal carcinoma metastases to the liver: Gastrointestinal tumor study group protocol 6584. *J Clin Oncol*, Vol.9, No.7, pp. 1105-1112
- Stewart GD, O'Suilleabhain CB, Madhavan KK, et al. (2004). The extent of resection influences outcome following hepatectomy for colorectal liver metastases. *Eur J Surg Oncol*, Vol.30, No.4, pp. 370-376
- Tabernero J, Van CE, az-Rubio E, et al. (2007). Phase II trial of cetuximab in combination with fluoracil, leucovorin, and oxaliplatin in the first-line treatment of metastatic colorectal cancer. *J Clin Oncol*, Vol.25, No.33, pp. 5225-5232
- Tournigand C, Andre T, Achille E et al. (2004). FOLFIRI followed by FOLFOX6 or the reverse sequence in advanced colorectal cancer: a randomized GERCOR study. *J Clin Oncol*, Vol.22, No.2, pp. 229-237
- Truant S, Huglo D, Hebbar M, et al. (2005). Prospective evaluation of the impact of [18F] fluoro-2-deoxy-D-glucose positron emission tomography of resectable colorectal liver metastases. *Br J Surg*, Vol.92, No.3, pp. 362-369
- Wanebo HJ, Chu QD, Avradopoulos KA, et al. (1996). Current perspectives on repeat hepatic resection for colorectal carcinoma: a review. *Surgery*, Vol.119, No.4, pp. 361-371
- Wein A, Riedel C, Bruckl W, et al. (2003). Neoadjuvant treatment with weekly high-dose 5-fluorouracil as 24-hour infusion, folinic acid and oxaliplatin in patients with primary resectable liver metastases of colorectal cancer. *Oncology*, Vol.64, No.2, pp. 131-138
- Wong SL, Mangu PB, Choti MA, et al. (2010). American Society of Clinical Oncology 2009 Clinical Evidence Review on Radiofrequency Ablation of hepatic metastases from colorectal cancer. *J Clin Oncol*, Vol.28, No.3, pp. 493-508
- Verwaal VJ, van Ruth S, de Bree E, et al. (2003). Randomized trial of cytoreduction and hyperthermic intraperitoneal chemotherapy versus systemic chemotherapy and palliative surgery in patients with peritoneal carcinomatosis of colorectal cancer. *J Clin Oncol*, Vol.21, No.20, pp. 3737-3743

Yan TD, Padang R, Morris DL. (2006). Longterm results and prognostic indicators after cryotherapy and hepatic arterial chemotherapy with or without resection for colorectal liver metastases in 224 patients: longterm survival can be achieved in patients with multiple bilateral liver metastases. *J Am Coll Surg*, Vol.202, No.1, pp. 100-111

IntechOpen

IntechOpen



Current Cancer Treatment - Novel Beyond Conventional Approaches

Edited by Prof. Oner Ozdemir

ISBN 978-953-307-397-2

Hard cover, 810 pages

Publisher InTech

Published online 09, December, 2011

Published in print edition December, 2011

Currently there have been many armamentaria to be used in cancer treatment. This indeed indicates that the final treatment has not yet been found. It seems this will take a long period of time to achieve. Thus, cancer treatment in general still seems to need new and more effective approaches. The book "Current Cancer Treatment - Novel Beyond Conventional Approaches", consisting of 33 chapters, will help get us physicians as well as patients enlightened with new research and developments in this area. This book is a valuable contribution to this area mentioning various modalities in cancer treatment such as some rare classic treatment approaches: treatment of metastatic liver disease of colorectal origin, radiation treatment of skull and spine chordoma, changing the face of adjuvant therapy for early breast cancer; new therapeutic approaches of old techniques: laser-driven radiation therapy, laser photo-chemotherapy, new approaches targeting androgen receptor and many more emerging techniques.

How to reference

In order to correctly reference this scholarly work, feel free to copy and paste the following:

Tsoulfas Georgios and Pramateftakis Manousos-Georgios (2011). The Treatment of Metastatic Liver Disease of Colorectal Origin, Current Cancer Treatment - Novel Beyond Conventional Approaches, Prof. Oner Ozdemir (Ed.), ISBN: 978-953-307-397-2, InTech, Available from: <http://www.intechopen.com/books/current-cancer-treatment-novel-beyond-conventional-approaches/the-treatment-of-metastatic-liver-disease-of-colorectal-origin>

INTeCH
open science | open minds

InTech Europe

University Campus STeP Ri
Slavka Krautzeka 83/A
51000 Rijeka, Croatia
Phone: +385 (51) 770 447
Fax: +385 (51) 686 166
www.intechopen.com

InTech China

Unit 405, Office Block, Hotel Equatorial Shanghai
No.65, Yan An Road (West), Shanghai, 200040, China
中国上海市延安西路65号上海国际贵都大饭店办公楼405单元
Phone: +86-21-62489820
Fax: +86-21-62489821

© 2011 The Author(s). Licensee IntechOpen. This is an open access article distributed under the terms of the [Creative Commons Attribution 3.0 License](https://creativecommons.org/licenses/by/3.0/), which permits unrestricted use, distribution, and reproduction in any medium, provided the original work is properly cited.

IntechOpen

IntechOpen