

# We are IntechOpen, the world's leading publisher of Open Access books Built by scientists, for scientists

6,900

Open access books available

185,000

International authors and editors

200M

Downloads

Our authors are among the

154

Countries delivered to

TOP 1%

most cited scientists

12.2%

Contributors from top 500 universities



WEB OF SCIENCE™

Selection of our books indexed in the Book Citation Index  
in Web of Science™ Core Collection (BKCI)

Interested in publishing with us?  
Contact [book.department@intechopen.com](mailto:book.department@intechopen.com)

Numbers displayed above are based on latest data collected.  
For more information visit [www.intechopen.com](http://www.intechopen.com)



# Electrical Stimulation of Primary Motor Cortex for Parkinson's Syndrome

Naoki Tani<sup>1</sup> and Youichi Saitoh<sup>1,2</sup>

<sup>1</sup>*Department of Neurosurgery,*

*Osaka University Graduate School of Medicine,*

<sup>2</sup>*Department of Neuromodulation and Neurosurgery,*

*Osaka University,*

*Japan*

## 1. Introduction

Deep brain stimulation (DBS) of several nuclei at the basal ganglia, mainly globus pallidus interna (GPi), and subthalamic nucleus (STN) is highly effective in controlling motor symptoms in patients with advanced Parkinson's disease (PD) (Krack et al., 1998; Limousin et al., 1998). However, several complications have been published by different groups with a large experience in DBS (Lyons et al., 2004; Umemura et al., 2003), and patients with poor response to levodopa or those with cognitive impairment, advanced age, considerable brain atrophy, cerebral ischemic foci in the white matter or Unified Parkinson's Disease Rating Scale (UPDRS) part III < 30 to 40 in the *off* condition are considered unsuitable patients for DBS, because of the increased surgical risk (Lopiano et al., 2002; Pahwa et al., 2005). On the other hand, STN DBS may improve axial symptoms at the beginning, but results are less rewarding at long-term follow-up (Bejjani et al., 2000; Kleiner-Fisman et al., 2003).

At the early of the 1990s, Tsubokawa introduced electrical motor cortex stimulation (EMCS) for the relief of central pain (Tsubokawa et al., 1991a, b). Its use has been extended to peripheral neuropathic pain conditions, and very recently to patients with movement disorders. EMCS might represent an alternative in patients who would not fulfill all DBS inclusion criteria. There has been some evidence that EMCS may relieve motor symptoms of patients with PD (Canavero et al., 2002; Pagni et al., 2005). However, there have also been a number of contradictory reports regarding the efficacy of EMCS in patients with PD. A number of reasons could account for the apparent discrepancies among different studies which may include different selection criteria, different surgical (i.e. extradural vs. subdural electrode) or methodological (i.e. stimulation frequencies) approaches, and importantly, different way of motor performance assessments. This report attempts to summarize current evidence on these topics.

## 2. Transcranial magnetic stimulation on primary motor cortex

Several studies have shown the transient benefit of the stimulation of primary motor cortex (M1) using repetitive transcranial magnetic stimulation (rTMS) for the symptoms of patients

with PD, such as akinesia, tremor, rigidity and depression. The benefits depend on stimulus frequency and the site of the stimulation; high frequency rTMS of M1 (5-25 Hz) improved the motor performance (Khedr et al., 2006; Lefaucheur et al., 2004), rTMS of the supplementary motor area (SMA) worsened performance of motor tasks at high frequencies (5-10 Hz) or improved UPDRS (Hamada et al., 2008) but reduced levodopa-induced dyskinesias at low frequency (1 Hz) (Boylan et al., 2001; Koch et al., 2005), and 5 Hz rTMS of the dorsolateral prefrontal cortex (DLPFC) demonstrated the benefit on depression of patients with PD (Pal et al., 2010). Recently, rTMS on M1 is expected to predict the efficacy of EMCS for patients with PD, for instance, we experienced a patient with akinesia in whom high frequency rTMS on M1 showed similar beneficial effect on motor symptom to the subsequent EMCS. In the patients with intractable pain, Andre-Obadia demonstrated that 20 Hz rTMS on M1 predicted the efficacy of subsequent EMCS for pain reduction (Andre-Obadia et al., 2006) and Hosomi et al reported that there is good correlation between the pain reduction with 5 Hz rTMS and that with EMCS (Hosomi et al., 2008). Thus, the rTMS technique might be used to better define the targets and the parameters of stimulation subsequently applied in chronic EMCS.

### 3. Surgical procedure

Basically, the surgical procedure of EMCS for Parkinson's Syndrome is same as that for intractable pain. Because of the small number of the reported case of EMCS for PD, there is still controversy, such as unilateral stimulation or bilateral stimulation, epidural electrode or subdural electrode. Detailed procedure of EMCS will be mentioned in this session. Previously the detailed methods were reported (Saitoh and Hosomi, 2009).

#### 3.1 Pre-surgical preparation

Prior to the surgical procedure, the hand motor area is identified as a target of EMCS using fMRI or anatomical MRI. Because the lower limb motor area locates in the inter-hemispheric fissure, implanting an electrode on the lower limb motor area is difficult. Functional MRI (fMRI) (Figure 1) is useful to precisely localize the site of the M1, otherwise some anatomical landmarks can help to identify the central sulcus. The central sulcus is characterized by the lack of sulcal branches, and lies just anterior to the pars marginalis of the cingulate sulcus on the interhemispheric surface (Naidich et al., 2001; Naidich et al., 1995). The precentral knob sign corresponding to the hand motor area is easily identified on surface view of MRI (Figure 2).

#### 3.2 Neuronavigation

After the identification of targeted area, neuronavigation is used to precisely identify M1 intraoperatively. Several kinds of navigation systems for neurosurgical assistance can be used to estimate the position of the central sulcus from skin surface (Tirakotai et al., 2007). Neuronavigation combined with fMRI data help to decide the best position for craniotomy and for placement of the stimulating paddle (Rasche et al., 2006). A drawback of neuronavigation is the requirement that the patient's head be fixed in a 3-point pin holder or vacuum headrest (Tirakotai et al., 2007), which several patients may not tolerate under local anesthesia. For this reason, other surgeons prefer not to fix the patient's head and operate without neuronavigation, and use the Taylor-Haughton instead of neuronavigation lines (Figure 3) (Greenberg, 2010).

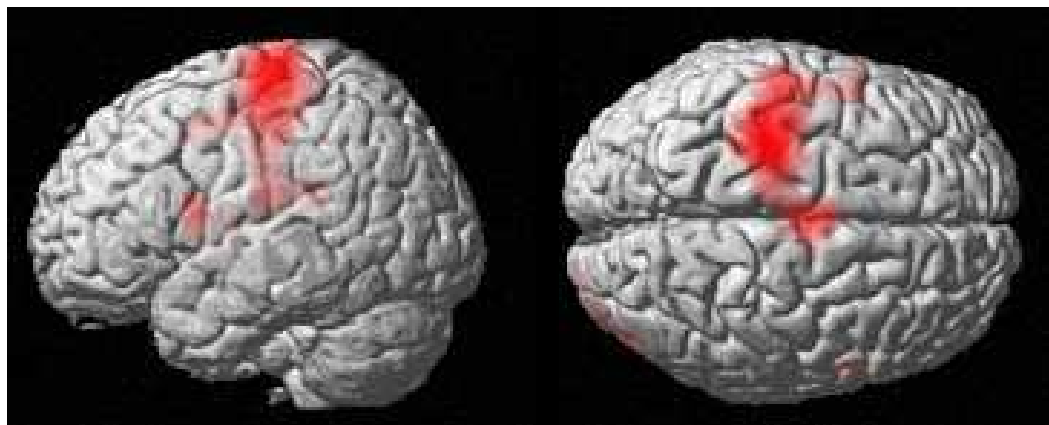


Fig. 1. Motor cortex localization using fMRI. During the acquisition of fMRI data (echo planar imaging), the patient performed twelve 30-second epochs of right hand grasp with identical rest epochs. Data analysis was performed in MATLAB 2008a (Math Works, Inc., Natick, MA) using Statistical Parametric Mapping software (SPM@; Wellcome Department of Imaging Neuroscience, London, England).

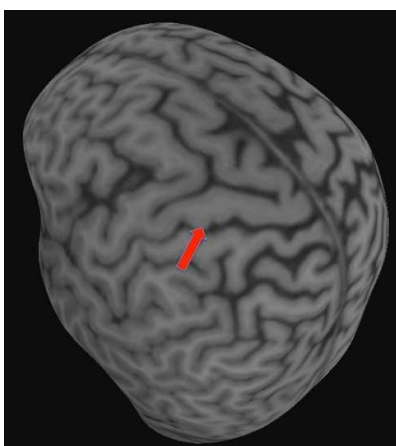


Fig. 2. Brain surface view of MRI. Red arrow indicates the left primary motor cortex hand area.

### 3.3 Anesthesia

Implantation of electrode is done under local anesthesia or general anesthesia. General anesthesia is induced with a loading dose of Remifentanyl 3–4 ng/ml in continuous infusion followed after 5–8 min by Propofol 5.5 µg/ml as induction dose (Total intravenous anesthesia, TIVA). Endotracheal intubation is facilitated by vecuronium bromide 0.1 mg/kg; no further doses of muscle relaxants are administered throughout surgery. The lungs are mechanically ventilated with a 50% O<sub>2</sub> in air mixture, in order to maintain end tidal concentrations of CO<sub>2</sub> (ETCO<sub>2</sub>) at 30–35 mmHg. Anesthesia is maintained with Remifentanyl (5–6 ng/ml, up to 7–8 ng/ml if necessary) and Propofol (2.5–3.0 µg/ml). At the end of the surgical procedure, all patients are awakened within 15–30 min from cessation of TIVA.

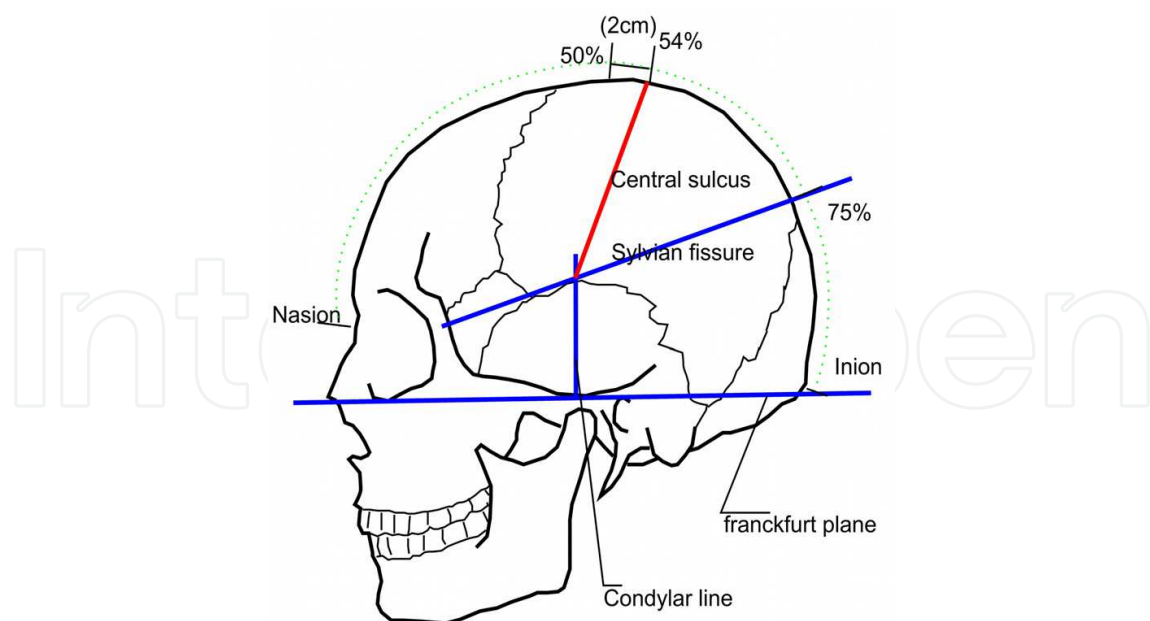


Fig. 3. Taylor-Haughton line indicates the position of the central sulcus from the scalp. The Frankfurt plane is the line from the inferior margin of the orbit through the upper margin of the external auditory meatus. The distance from the nasion to the inion is measured across the top of the calvaria and is divided into quarters. The condylar line runs perpendicular to the baseline through the mandibular condyle (intersecting the line representing the sylvian fissure). The Sylvian fissure is approximated by a line connecting the lateral canthus to the point 3/4 of the way posterior along the arc running over convexity from nasion to inion. Central sulcus is drawn from 54% point on naso-inion line to the point where the Sylvian line cuts the condylar line.

### 3.4 Electrophysiological localization of hand motor area

For localizing central sulcus, most neurosurgeons employ somatosensory evoked potential (SSEP) using contralateral median nerve stimulation. The phase reversal of the N20 (sensory cortex) /P20 (motor cortex) waves is used to confirm the location of the central sulcus (Wood et al., 1988), using a multi-contact grid and the central scalp EEG leads or directly using the definitive 4-contact strip overlying the dura matter (Figure 4). Recently, an enlarged and displaced motor map for the hand area was described in patients with PD. Map shifts were found in the majority of the patients (Thickbroom et al., 2006). Therefore, electrode placement only with SSEP is often inadequate or impossible. According to Velasco et al. (Velasco et al., 2002), recording corticocortical evoked responses (CCER) is simple and reliable and superior to SSEPs. M1 stimulation elicits negative CCER over the frontal scalp, whereas the stimulation of primary sensory cortex (S1) elicits positive responses over parietal and occipital scalp regions.

Most neurosurgeons attempt intraoperative test stimulation by using the quadripolar or the grid electrodes. Test bipolar stimulation (210-1000  $\mu$ s –generally 400-500- $\mu$ s, 1-5 Hz up to 500Hz, at increasing voltage or intensity –up to 50 mA, anodally, but also cathodally) is applied by means of the contacts situated over M1. In general, the amplitude needed to produce motor responses is higher using epidural rather than subdural stimulation. Motor contraction can be elicited at relatively lower amplitudes when general anesthesia is not employed. 1Hz stimulation is preferred to higher frequencies, since the former does not



habituate and has less potential to trigger seizures. Muscle responses are recorded from muscle bellies of the contralateral upper limb, with EMG electrodes or visually.

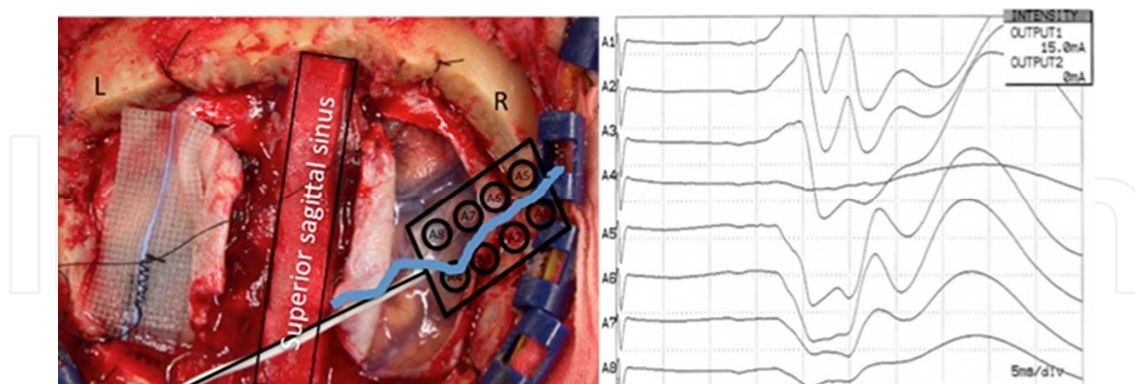


Fig. 4. SSEP recording on the right central sulcus using an eight contact subdural electrode. An eight-polar plate electrode (Specify Lead, 3998; Medtronic, Minneapolis, MN) was placed on the right central sulcus. Left median nerve was stimulated at wrist with stimuli consist of single shocks (0.5 ms, 4.7 Hz, 20 mA) to produce a small, but consistent contraction of the thumb. SSEPs were recorded from each cortical electrode referenced to the ipsilateral ear lobe. Individual SSEP signals were differentially amplified and filtered: 200 were averaged through a digital signal analyzer with sample interval of 100 msec. Blue line indicates the central sulcus confirmed by SSPE.

### 3.5 Electrode implantation

For EMCS, the great majority of investigators prefer epidural electrode to subdural electrode. This attitude is attributed largely to the greater risk of developing complications with subdural EMCS, such as cerebrospinal fluid leakage, difficulty in fixing the electrode, hemorrhage, and iatrogenic seizures. However, according to the physical model suggested by Holsheimer et al. (Holsheimer et al., 2007) and Manola et al. (Manola et al., 2007), subdural EMCS appears to be more energy-efficient, as compared with epidural EMCS. In some patients with brain atrophy, the cortical surface and the dura mater are wide apart, in which case patients may fail to respond to extradural stimulation: a subdural approach may be considered in selected cases.

There is no direct comparison study between unilateral EMCS and bilateral EMCS. Some investigator reported the bilateral effects in clinical outcome by unilateral EMCS (Cilia et al., 2008; Pagni et al., 2005). These bilateral effects of unilateral cortical stimulation are probably due to bilateral afferent and efferent connections between cortical and subcortical structures (Leichnetz, 1986).

The four-contact electrode array or 2 side-by-side 4-contact electrode strips is placed on the hand motor area. Some surgeons place the electrode perpendicular to the central sulcus above the precentral (cathode) and postcentral (anode) gyri for the supposed improved selectivity (Nguyen et al., 1999), others in a parallel fashion, i.e. with all contacts on the M1 or S1 (Canavero and Bonicalzi, 2002; Rasche et al., 2006). Moreover, no polarity-related difference in pain relief is seen for most patients with epidural electrodes (Katayama et al., 1998).

#### 3.5.1 Epidural electrode

Canavero (Canavero et al., 2002, 2003) makes an oblique linear skin incision (6-10cm) parallel to and 1 cm ahead of or behind the projection of the central sulcus and then drills

two burr holes at a distance of 2-4 cm (plus a bony groove parallel to the paddle to accommodate the connector between the looping lead and the extension). A stimulating paddle is inserted from the edge of one burr hole into the epidural space overlying the precentral gyrus contralateral to more disabled side for movement disorders. The bony bridge between the two holes will then hold the plate in place and simultaneously reduce the durocortical gap (Figure 5). This technique entails no risk of epidural hematoma, and accidental displacement of the electrode has never been observed (S Canavero, personal communication)

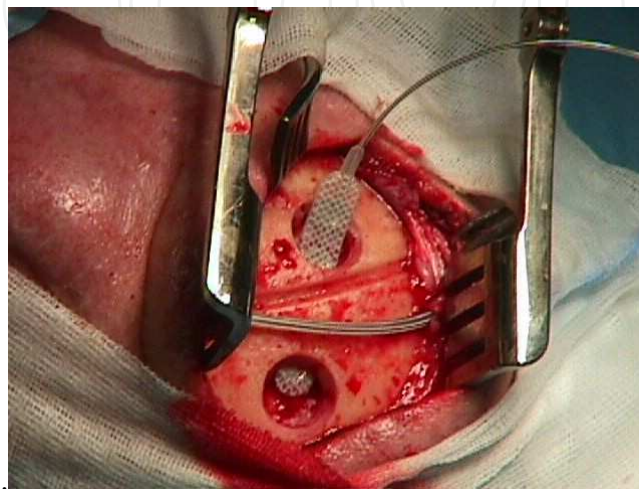


Fig. 5. Two burr-hole surgery is shown. The locations of burr holes are marked on the scalp depending on the anatomical landmarks (courtesy of Prof. Canavero).

### 3.5.2 Subdural electrode

In patients with advanced cortical atrophy, epidural stimulation may fail due to the durocortical separation. The cortical surface and interhemispheric surfaces subdurally may be elected as targets for stimulation. However, large bridging veins sometimes interfere with implantation on the interhemispheric surface. We perform bilateral craniotomy over superior sagittal sinus. After the opening of dura mater, the location of central sulcus is confirmed using phase reverse of the N20 component upon stimulation of the median nerve. A subdural quadripolar electrodes (Resume II, model 3587A; Medtronic, Minneapolis, MN) are then placed bilaterally on the M1 adjacent to the superior sagittal sinus. At the end of surgery, the lead extension is fixed to the dura or the border of the burr hole with a silk suture to prevent dislocation. However, migration of the electrodes seems to be more of a problem with a subdural than an extradural approach. A meticulous, watertight dural closure is mandatory to minimize the risk of cerebrospinal fluid leakage.

### 3.6 Test stimulation

After closure of the craniotomy, the electrode cable(s) is/are connected to trial stimulator. After 3 to 14 days period of test stimulation, the best stimulation parameters and electrodes are decided. There is considerable variation in the stimulation parameters; amplitudes range from 2 V to 6 V, rates from 10 Hz to 130 Hz, and pulse widths from 60  $\mu$ sec to 450  $\mu$ sec (Canavero et al., 2003; Canavero et al., 2002; Cilia et al., 2007; Cilia et al., 2008; Fasano et al., 2008; Gutierrez et al., 2009; Pagni et al., 2005; Strafella et al., 2007; Tani et al., 2007). The best

location and orientation of the electrode array are generally determined in such a way that bipolar stimulation with an appropriate pair of electrodes. Once the pulse width and frequency have been optimized, most investigators will increase stimulus intensities during the trial using a percentage of the motor threshold as a guide. Many investigators begin by increasing the intensity by 20% of the motor threshold and then increase by 20% increments thereafter to 80% of motor threshold.

### 3.7 Implantation of IPG

If the test stimulation improves the motor symptom, patients would be returned to the operating room and the electrode(s) is/are connected to implanted pulse generator(s) (Itrel III IPG; Medtronic Inc., Minneapolis, MN, USA), usually placed subcutaneously over the pectoralis muscle under general anesthesia (Figure 6).

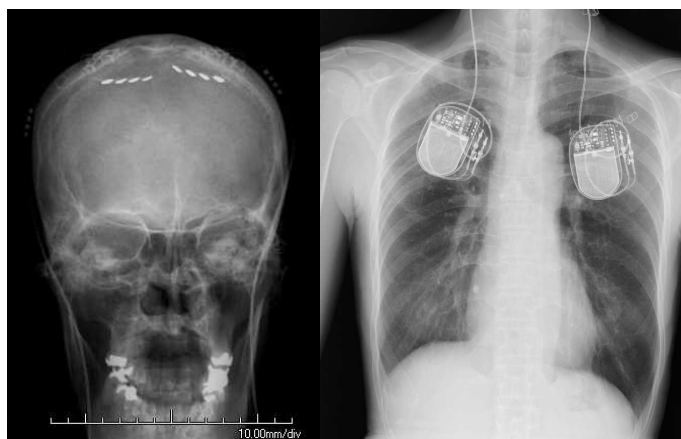


Fig. 6. Subdural electrodes implanted bilaterally on the primary motor cortex and pulse generators. The two Resume II electrodes are connected to pulse generators (Itrel III; Medtronic) that are implanted in the bilateral anterior chests.

## 4. Clinical outcome

Clinical outcomes from several studies were summarised in Table 1. Variable clinical outcomes after EMCS have been reported in the patients with PD. The limited case series available on literature and the differences in patient selection criteria and stimulus parameters may partly account for the variable clinical benefit reported so far. Basically, the degree of the clinical improvement obtained with EMCS is lower than that reported with DBS (Cilia et al., 2008; Gutierrez et al., 2009). Most of EMCS studies did not find significant mean changes between stimulation-on and stimulation-off in UPDRS part II and III (Cilia et al., 2008; Gutierrez et al., 2009; Strafella et al., 2007). On the other hand, motor evaluation in individual patients revealed clinical improvement during stimulation in comparison to STIM-OFF condition (Cilia et al., 2008; Fasano et al., 2008; Gutierrez et al., 2009; Strafella et al., 2007; Tani et al., 2007). These published data must be interpreted very cautiously, because they are from open labelled studies that involved only small numbers of patients from a few centres. The clinical benefits from EMCS were observed mainly in axial symptoms, such as gait, stooped posture and postural instability. Because axial symptom has small proportion in UPDRS-III (20/108), the benefit of EMCS for axial symptom does not change a lot in UPDRS-III score. Additionally, clinical improvement by EMCS occurs



Authors	Cases	Stimulation condition	clinical outcome
Cilla	6	epidural, unilateral, monopolar, 40-60 Hz, 3.0 ± 0.67 V, 180 -210 µsec	No significant mean changes in UPDRS-II (40% improvement), UPDRS-III (20% improvement), as well as medication dose (15% reduction) between baseline, 6-month STIM-ON and 6-month STIM-OFF. Objective motor benefit was observed mainly in axial symptoms, such as gait, stooped posture and postural instability.
Pagni	6	epidural, unilateral, bipolar, 25-40 Hz, 2.5-6 V, 100-180 µsec	UPDRS: tremor;bilateraly more than 80% reduction in 3 of 4 cases, rigidity; more than 50% reduction in 5 of 6 cases in contralateral side and in 4 of 6 cases in ipsilateral side, activities of daily living; more than 50 % reduction in 3 of 6 cases, axial symptom.; more than 50% reduction in 3 of 6 cases, dyskinesia; more than 50% reduction in 4 of 5 cases, 11-70 % reduction of L-dapa daily dose
Strafella	4	subdural, unilateral, 50 or 130 Hz, 3-5 V, 60-90 µsec	No reduction of daily L-dopa dose, no significant difference in the UPDRS motor score between OFF stimulation (43.0 ± 7.9) and ON stimulation (39.5 ±12.5).
Gutierrez	6	epidural, unilateral, bipolar, 10-30 Hz, 3-4.5 V, 330-450 µsec	Mild improvement in 2 of 6 cases (14.7% and 7.3% improvement in UPDRS-III)(on stimulation on medication vs off stimulation on medication), 17.1 ± 11.1% reduction of L-dopa daily dose.
Canavero	3	epidural, unilateral, bipolar, 20-31 Hz, 2-3.5 V, 90-330 µsec	Case 1; independent walk, absence of rigidity, trochlea, and tremor to all four limbs, 80% reduction of L-dopa daily dose. Case 2; 50% improvement of UPDRS-III, absense of freezing gait, tremor, improvement of bradykinesia, 70% reduction of L-dopa daily dose. Case 3; absence of tremor, rigidity, improvement of gait and speech.
Fasano	1	epidural, bilateral, bipolar, 130 Hz, subthreshold intensity, 120 µsec	20% improvement of UPDRS-III, mainly in Axial score (UPDRS items 27-30).
Tani	1	subdural, bilateral, bipolar, 100 Hz, 1.8 V, 210 µsec	50% improvement of UPDRS-III and dramatic improvement in walking

Table 1. Summery of clinical outcomes

after a variable time interval - most often several days up to 4 weeks - after stimulation parameters modifications (Cilia et al., 2008). Several investigators reported that rigidity and tremor were abolished within several minutes of stimulation, but the full effect on bradykinesia and axial symptom, especially gait disturbance, were appreciated only after a longer period of stimulation, with a slow worsening over more than 2 days period after stimulation-off (Canavero et al., 2002; Cilia et al., 2008; Pagni et al., 2003; Tani et al., 2007). In some studies, the motor symptom assessments were done in shorter period after the modification of stimulation parameter, so the benefit in motor symptom could be underestimated.

## 5. Mechanisms of action

The exact mechanisms of action of EMCS are poorly understood. It is noteworthy that, whereas the effects of EMCS on rigidity and tremor are almost immediate (observed within the first minute of stimulation), the clinical benefit on akinesia and axial symptom necessitate a longer stimulation time to become detectable. The latency of the clinical effects of high-frequency STN-DBS is also known to vary from one type of parkinsonian motor symptoms to another with short latency benefit (less than 1 min) observed for rigidity and tremor and longer time delay (a few minutes, up to a few days) observed for other symptoms such as bradykinesia and akinesia (Krack et al., 2002). As discussed by others, the delays of clinical benefits observed with EMCS may be due to synaptic plasticity, long-term potentiation, long-term depression, expression of secondary messengers or polarization of brain tissue (Drouot et al., 2004; Krack et al., 2002; Priori and Lefaucheur, 2007), and the immediate effects may be due to the dual effect - imposing a specific pattern of activity and suppress abnormal, disease-associated rhythmicity of oscillation in corticobasal ganglia-cortical circuit (Brown, 2006; Fasano et al., 2008; Garcia et al., 2003; Priori and Lefaucheur, 2007).

Studies of rTMS of M1 reveal that PD is associated with excess excitability or reduced inhibition at the M1 (Cantello et al., 2002), and rigidity and tremor might be caused by hyperactivity of the M1 (Haslinger et al., 2001; Rodriguez-Oroz et al., 2009). In the patients with PD, during production of a voluntary output, its activation is inadequately modulated, owing, for instance, to reduction of intracortical inhibitory mechanisms mediated by  $\gamma$ -aminobutyric acid A (GABA) and GABA receptors (Cantello et al., 2002). Canavero et al. suggests that EMCS increases the cortical GABA in patients affected by central pain syndromes (Canavero and Bonicalzi, 1995, 1998). EMCS might reduce cortical hyperactivity, increasing GABA concentration and activating inhibitory neurons (Hanajima et al., 2002). Indeed, ECD SPECT data demonstrated a resting state reduction of neuronal activity in motor cortical areas during EMCS (Cilia et al., 2008).

Finally, functional neuroimaging studies showed a significant increase of cerebral perfusion in the SMA and the DLPFC in STIM-ON condition (Drouot et al., 2004; Fasano et al., 2008; Tani et al., 2007). The SMA and the DLPFC are known to be under-active in patients with PD, probably underlying bradykinesia (Haslinger et al., 2001; Jahanshahi et al., 1995; Rascol et al., 1992), and these cortical metabolic abnormalities can be reversed by antiparkinsonian therapies such as dopaminergic treatment (Jenkins et al., 1992), pallidotomy (Grafton et al., 1995), STN-DBS (Limousin et al., 1997) or GPi-DBS (Fukuda et al., 2001). The similarity of these results suggests that these strategies may induce a similar therapeutic benefit in the patients with PD and might have some common mechanism.

Authors	Cases	Stimulation	Modality	Neuroimaging
Cilla	6	unilateral, 40-60 Hz	Tc-SPECT STIM-ON vs STIM-OFF under rest	Decrease in bilateral M1, bilateral premotor cortex, left DLPFC, right caudate nucleus and left middle occipital gyrus Increase in right cerebellar lobe, left inferior occipital gyrus, left cerevellar lobe and vermis.
Strafella	4	unilateral, 50 or 130 Hz	[ <sup>15</sup> O] H <sub>2</sub> O PET movement vs rest	the changes in rCBF were not significantly different when comparing across different stimulation setting (OFF vs 50 Hz vs 130 Hz).
Canavero	3	unilateral, 20 - 31 Hz	IBZM-SPECT	Before EMCS, asymmetrical binding (right less than left) in the basal ganglia During EMCS, renormalization of basal ganglia anomalies
			ECD-SPECT	Before EMCS, bilateral parieto-temporal hypoperfusion. During EMCS, renormalization of cortical metabolism on the side of stimulation but not contralaterally.
Fasano	1	bilateral, 130 Hz	ECD-SPECT STIM-OFF vs STIM-ON (medication off)	increase in the right frontal, right parietal cortex and left frontal cortex.
Tani	1	bilateral, 100 Hz	[ <sup>15</sup> O] H <sub>2</sub> O PET STIM-OFF vs STIM-ON (medication on)	increase in the left SMA and right DLPFC.

Table 2. Summery of the functional neuroimaging

6. Complication

The only complication reported concerning EMCS for PD was misplaced electrode (Pagni et al., 2005). Because of the small number of the cases of EMCS for PD, we summarize the reported complication of EMCS for intractable pain patients in this section.

While a majority of studies have reported no adverse events with EMCS (Gharabaghi et al., 2005; Saitoh et al., 2000; Tsubokawa et al., 1991b), serious complications have been reported. Montes et al. (Montes et al., 2002) analyzed event-related potentials (ERPs) and behavioral performance during an auditory target-detection task in 11 consecutive patients obtained during EMCS and 10 minutes after switching off stimulation. While sensory responses remained unaffected by EMCS, there was a significant delay of brain potentials reflecting

target detection in the older patients, rapidly reversible after EMCS discontinuation. No effect was observed in patients younger than 50 years. Cognitive effects of EMCS appeared as mild and non-specific, directly related to the stimulation period (i.e. with no post-effect), in a manner reminding of cognitive effects reported during rTMS on M1. Thus, EMCS may interfere with relatively simple cognitive processes such as those underlying target detection, notably in the elderly and in the presence of preexistent cerebral lesions.

Occurrence of epileptic seizures has been reported during test stimulation in a minority of patients. The low rate of epileptic seizures during chronic stimulation (0.2%) means that stimulation of M1 within an appropriate range of parameters is reasonably safe. The most serious reported complications are epidural or subdural hematomas. These are definitely exceptional with an extradural approach, and some surgeons never observed one, making the risk of peri-operative hemorrhage much lower compared to DBS.

Some wound infections have been reported by most neurosurgeons. If the infection occurs, all devices including the paddle, extension leads, and pulse generators must be removed temporally. The implanted pulse generator (IPG) can accidentally turn off due to electromagnetic interference from household devices in close (<10 cm) proximity, such as electric appliances of any kind, but also anti-theft devices and metal detectors or magnets in loudspeakers.

At impedances >2000  $\Omega$ , a connection problem, such as a broken cable or a lead fracture, must be suspected. The operator should thus measure impedance in a unipolar configuration in order to assign a value to the single contact.

## 7. Conclusion

EMCS can provide some different benefit for the patients with PD from STN-DBS. Although the degree of clinical improvement of EMCS is lower than that of DBS, the fact that EMCS can improve axial symptom of PD, which is difficult even with STN-DBS, is an irreplaceable gift for some part of patients with PD, and its less surgical invasiveness than DBS can make the surgery safer for the patients with advanced age or severe brain atrophy.

## 8. References

- Andre-Obadia, N., Peyron, R., Mertens, P., Mauguiere, F., Laurent, B., Garcia-Larrea, L. (2006). Transcranial magnetic stimulation for pain control. Double-blind study of different frequencies against placebo, and correlation with motor cortex stimulation efficacy. *Clin Neurophysiol*, 117, 1536-1544, ISSN 1388-2457
- Bejjani, B.P., Gervais, D., Arnulf, I., Papadopoulos, S., Demeret, S., Bonnet, A.M., Cornu, P., Damier, P., Agid, Y. (2000). Axial parkinsonian symptoms can be improved: the role of levodopa and bilateral subthalamic stimulation. *J Neurol Neurosurg Psychiatry*, 68, 595-600, ISSN 0022-3050
- Boylan, L.S., Pullman, S.L., Lisanby, S.H., Spicknall, K.E., Sackeim, H.A. (2001). Repetitive transcranial magnetic stimulation to SMA worsens complex movements in Parkinson's disease. *Clin Neurophysiol*, 112, 259-264, ISSN 1388-2457
- Brown, P. (2006). Bad oscillations in Parkinson's disease. *J Neural Transm Suppl*, 27-30, ISSN 0303-6995

- Canavero, S., Bonicalzi, V. (1995). Cortical stimulation for central pain. *J Neurosurg*, 83, 1117, ISSN 0022-3085
- Canavero, S., Bonicalzi, V. (1998). The neurochemistry of central pain: evidence from clinical studies, hypothesis and therapeutic implications. *Pain*, 74, 109-114, ISSN 0304-3959
- Canavero, S., Bonicalzi, V. (2002). Therapeutic extradural cortical stimulation for central and neuropathic pain: a review. *Clin J Pain*, 18, 48-55, ISSN 0749-8047
- Canavero, S., Bonicalzi, V., Paolotti, R., Castellano, G., Greco-Crasto, S., Rizzo, L., Davini, O., Maina, R. (2003). Therapeutic extradural cortical stimulation for movement disorders: a review. *Neurol Res*, 25, 118-122, ISSN 0161-6412
- Canavero, S., Paolotti, R., Bonicalzi, V., Castellano, G., Greco-Crasto, S., Rizzo, L., Davini, O., Zenga, F., Ragazzi, P. (2002). Extradural motor cortex stimulation for advanced Parkinson disease. Report of two cases. *J Neurosurg*, 97, ISSN 1208-1211
- Cantello, R., Tarletti, R., Civardi, C. (2002). Transcranial magnetic stimulation and Parkinson's disease. *Brain Res Brain Res Rev*, 38, 309-327, ISSN 0165-0173
- Cilia, R., Landi, A., Vergani, F., Sganzerla, E., Pezzoli, G., Antonini, A. (2007). Extradural motor cortex stimulation in Parkinson's disease. *Mov Disord*, 22, 111-114, ISSN 0885-3185
- Cilia, R., Marotta, G., Landi, A., Isaias, I.U., Vergani, F., Benti, R., Sganzerla, E., Gerundini, P., Pezzoli, G., Antonini, A. (2008). Cerebral activity modulation by extradural motor cortex stimulation in Parkinson's disease: a perfusion SPECT study. *Eur J Neurol*, 15, 22-28, ISSN 1468-1331
- Drouot, X., Oshino, S., Jarraya, B., Besret, L., Kishima, H., Remy, P., Dauguet, J., Lefaucheur, J.P., Dolle, F., Conde, F., Bottlaender, M., Peschanski, M., Keravel, Y., Hantraye, P., Palfi, S. (2004). Functional recovery in a primate model of Parkinson's disease following motor cortex stimulation. *Neuron*, 44, 769-778, ISSN 0896-6273
- Fasano, A., Piano, C., De Simone, C., Cioni, B., Di Giuda, D., Zinno, M., Daniele, A., Meglio, M., Giordano, A., Bentivoglio, A.R. (2008). High frequency extradural motor cortex stimulation transiently improves axial symptoms in a patient with Parkinson's disease. *Mov Disord*, 23, 1916-1919, ISSN 1531-8257
- Fukuda, M., Mentis, M., Ghilardi, M.F., Dhawan, V., Antonini, A., Hammerstad, J., Lozano, A.M., Lang, A., Lyons, K., Koller, W., Ghez, C., Eidelberg, D. (2001). Functional correlates of pallidal stimulation for Parkinson's disease. *Ann Neurol*, 49, 155-164, ISSN 0364-5134
- Garcia, L., Audin, J., D'Alessandro, G., Bioulac, B., Hammond, C. (2003). Dual effect of high-frequency stimulation on subthalamic neuron activity. *J Neurosci*, 23, 8743-8751, ISSN 1529-2401
- Gharabaghi, A., Hellwig, D., Rosahl, S.K., Shahidi, R., Schrader, C., Freund, H.J., Samii, M. (2005). Volumetric image guidance for motor cortex stimulation: integration of three-dimensional cortical anatomy and functional imaging. *Neurosurgery*, 57, 114-120; discussion 114-120, ISSN 1524-4040
- Grafton, S.T., Waters, C., Sutton, J., Lew, M.F., Couldwell, W. (1995). Pallidotomy increases activity of motor association cortex in Parkinson's disease: a positron emission tomographic study. *Ann Neurol*, 37, 776-783, ISSN 0364-5134
- Greenberg, M., (2010). *Handbook of neurosurgery*, (5 ed), Thieme, ISBN 1604063262, New York




- Gutierrez, J.C., Seijo, F.J., Alvarez Vega, M.A., Fernandez Gonzalez, F., Lozano Aragonese, B., Blazquez, M. (2009). Therapeutic extradural cortical stimulation for Parkinson's Disease: report of six cases and review of the literature. *Clin Neurol Neurosurg*, 111, 703-707, ISSN 1872-6968
- Hamada, M., Ugawa, Y., Tsuji, S., (2008) High-frequency rTMS over supplementary motor area for treatment of Parkinson's disease. *Mov Disord* 23, 1524-1531
- Hanajima, R., Ashby, P., Lang, A.E., Lozano, A.M. (2002). Effects of acute stimulation through contacts placed on the motor cortex for chronic stimulation. *Clin Neurophysiol*, 113, 635-641, ISSN 1388-2457
- Haslinger, B., Erhard, P., Kampfe, N., Boecker, H., Rummeny, E., Schwaiger, M., Conrad, B., Ceballos-Baumann, A.O. (2001). Event-related functional magnetic resonance imaging in Parkinson's disease before and after levodopa. *Brain*, 124, 558-570, ISSN 0006-8950
- Holsheimer, J., Nguyen, J.P., Lefaucheur, J.P., Manola, L. (2007). Cathodal, anodal or bifocal stimulation of the motor cortex in the management of chronic pain? *Acta Neurochir Suppl*, 97, 57-66, ISSN 0065-1419
- Hosomi, K., Saitoh, Y., Kishima, H., Oshino, S., Hirata, M., Tani, N., Shimokawa, T., Yoshimine, T. (2008). Electrical stimulation of primary motor cortex within the central sulcus for intractable neuropathic pain. *Clin Neurophysiol*, 119, 993-1001, ISSN 1388-2457
- Jahanshahi, M., Jenkins, I.H., Brown, R.G., Marsden, C.D., Passingham, R.E., Brooks, D.J. (1995). Self-initiated versus externally triggered movements. I. An investigation using measurement of regional cerebral blood flow with PET and movement-related potentials in normal and Parkinson's disease subjects. *Brain*, 118 ( Pt 4), 913-933, ISSN 0006-8950
- Jenkins, I.H., Fernandez, W., Playford, E.D., Lees, A.J., Frackowiak, R.S., Passingham, R.E., Brooks, D.J. (1992). Impaired activation of the supplementary motor area in Parkinson's disease is reversed when akinesia is treated with apomorphine. *Ann Neurol*, 32, 749-757, ISSN 0364-5134
- Katayama, Y., Fukaya, C., Yamamoto, T. (1998). Poststroke pain control by chronic motor cortex stimulation: neurological characteristics predicting a favorable response. *J Neurosurg*, 89, 585-591, ISSN 0022-3085
- Khedr, E.M., Rothwell, J.C., Shawky, O.A., Ahmed, M.A., Hamdy, A. (2006). Effect of daily repetitive transcranial magnetic stimulation on motor performance in Parkinson's disease. *Mov Disord*, 21, 2201-2205, ISSN 0885-3185
- Kleiner-Fisman, G., Fisman, D.N., Sime, E., Saint-Cyr, J.A., Lozano, A.M., Lang, A.E. (2003). Long-term follow up of bilateral deep brain stimulation of the subthalamic nucleus in patients with advanced Parkinson disease. *J Neurosurg*, 99, 489-495, ISSN 0022-3085
- Koch, G., Brusa, L., Caltagirone, C., Peppe, A., Oliveri, M., Stanzione, P., Centonze, D. (2005). rTMS of supplementary motor area modulates therapy-induced dyskinesias in Parkinson disease. *Neurology*, 65, 623-625, ISSN 1526-632X
- Krack, P., Fraix, V., Mendes, A., Benabid, A.L., Pollak, P. (2002). Postoperative management of subthalamic nucleus stimulation for Parkinson's disease. *Mov Disord*, 17 Suppl 3, S188-197, ISSN 0885-3185

- Krack, P., Pollak, P., Limousin, P., Hoffmann, D., Xie, J., Benazzouz, A., Benabid, A.L. (1998). Subthalamic nucleus or internal pallidal stimulation in young onset Parkinson's disease. *Brain*, 121 ( Pt 3), 451-457, ISSN 0006-8950
- Lefaucheur, J.P., Drouot, X., Von Raison, F., Menard-Lefaucheur, I., Cesaro, P., Nguyen, J.P. (2004). Improvement of motor performance and modulation of cortical excitability by repetitive transcranial magnetic stimulation of the motor cortex in Parkinson's disease. *Clin Neurophysiol*, 115, 2530-2541, ISSN 1388-2457
- Leichnetz, G.R. (1986). Afferent and efferent connections of the dorsolateral precentral gyrus (area 4, hand/arm region) in the macaque monkey, with comparisons to area 8. *J Comp Neurol*, 254, 460-492, ISSN 0021-9967
- Limousin, P., Greene, J., Pollak, P., Rothwell, J., Benabid, A.L., Frackowiak, R. (1997). Changes in cerebral activity pattern due to subthalamic nucleus or internal pallidum stimulation in Parkinson's disease. *Ann Neurol*, 42, 283-291, ISSN 0364-5134
- Limousin, P., Krack, P., Pollak, P., Benazzouz, A., Ardouin, C., Hoffmann, D., Benabid, A.L. (1998). Electrical stimulation of the subthalamic nucleus in advanced Parkinson's disease. *N Engl J Med*, 339, 1105-1111, ISSN 0028-4793
- Lopiano, L., Rizzone, M., Bergamasco, B., Tavella, A., Torre, E., Perozzo, P., Lanotte, M. (2002). Deep brain stimulation of the subthalamic nucleus in PD: an analysis of the exclusion causes. *J Neurol Sci*, 195, 167-170, ISSN 0022-510X
- Lyons, K.E., Wilkinson, S.B., Overman, J., Pahwa, R. (2004). Surgical and hardware complications of subthalamic stimulation: a series of 160 procedures. *Neurology*, 63, 612-616, ISSN 1526-632X
- Manola, L., Holsheimer, J., Veltink, P., Buitenweg, J.R. (2007). Anodal vs cathodal stimulation of motor cortex: a modeling study. *Clin Neurophysiol*, 118, 464-474, ISSN 1388-2457
- Montes, C., Mertens, P., Convers, P., Peyron, R., Sindou, M., Laurent, B., Mauguier, F., Garcia-Larrea, L. (2002). Cognitive effects of precentral cortical stimulation for pain control: an ERP study. *Neurophysiol Clin*, 32, 313-325, ISSN 0987-7053
- Naidich, T.P., Blum, J.T., Firestone, M.I. (2001). The parasagittal line: an anatomic landmark for axial imaging. *AJNR Am J Neuroradiol*, 22, 885-895, ISSN 0195-6108
- Naidich, T.P., Valavanis, A.G., Kubik, S. (1995). Anatomic relationships along the low-middle convexity: Part I--Normal specimens and magnetic resonance imaging. *Neurosurgery*, 36, 517-532, ISSN 0148-396X
- Nguyen, J.P., Lefaucheur, J.P., Decq, P., Uchiyama, T., Carpentier, A., Fontaine, D., Brugieres, P., Pollin, B., Feve, A., Rostaing, S., Cesaro, P., Keravel, Y. (1999). Chronic motor cortex stimulation in the treatment of central and neuropathic pain. Correlations between clinical, electrophysiological and anatomical data. *Pain*, 82, 245-251, ISSN 0304-3959
- Pagni, C.A., Zeme, S., Zenga, F. (2003). Further experience with extradural motor cortex stimulation for treatment of advanced Parkinson's disease. Report of 3 new cases. *J Neurosurg Sci*, 47, 189-193, ISSN 0390-5616
- Pagni, C.A., Zeme, S., Zenga, F., Maina, R. (2005). Extradural motor cortex stimulation in advanced Parkinson's disease: the Turin experience: technical case report. *Neurosurgery*, 57, E402; discussion E402, ISSN 1524-4040

- Pahwa, R., Wilkinson, S.B., Overman, J., Lyons, K.E. (2005). Preoperative clinical predictors of response to bilateral subthalamic stimulation in patients with Parkinson's disease. *Stereotact Funct Neurosurg*, 83, 80-83, ISSN 1011-6125
- Pal, E., Nagy, F., Aschermann, Z., Balazs, E., Kovacs, N. (2010). The impact of left prefrontal repetitive transcranial magnetic stimulation on depression in Parkinson's disease: a randomized, double-blind, placebo-controlled study. *Mov Disord*, 25, 2311-2317, ISSN 1531-8257
- Priori, A., Lefaucheur, J.P. (2007). Chronic epidural motor cortical stimulation for movement disorders. *Lancet Neurol*, 6, 279-286, ISSN 1474-4422
- Rasche, D., Ruppolt, M., Stippich, C., Unterberg, A., Tronnier, V.M. (2006). Motor cortex stimulation for long-term relief of chronic neuropathic pain: a 10 year experience. *Pain*, 121, 43-52, ISSN 0304-3959
- Rascol, O., Sabatini, U., Chollet, F., Celsis, P., Montastruc, J.L., Marc-Vergnes, J.P., Rascol, A. (1992). Supplementary and primary sensory motor area activity in Parkinson's disease. Regional cerebral blood flow changes during finger movements and effects of apomorphine. *Arch Neurol*, 49, 144-148, ISSN 0003-9942
- Rodriguez-Oroz, M.C., Jahanshahi, M., Krack, P., Litvan, I., Macias, R., Bezard, E., Obeso, J.A. (2009). Initial clinical manifestations of Parkinson's disease: features and pathophysiological mechanisms. *Lancet Neurol*, 8, 1128-1139, ISSN 1474-4465
- Saitoh, Y., Shibata, M., Hirano, S., Hirata, M., Mashimo, T., Yoshimine, T. (2000). Motor cortex stimulation for central and peripheral deafferentation pain. Report of eight cases. *J Neurosurg*, 92, 150-155, ISSN 0022-3085
- Saitoh Y, Hosomi K: Chapter 2. From localization to surgical implantation. In Textbook of therapeutic cortical stimulation Ed: Sergio Canavero, Nova Science Publishers, Inc. Hauppauge NY, 2009
- Strafella, A.P., Lozano, A.M., Lang, A.E., Ko, J.H., Poon, Y.Y., Moro, E. (2007). Subdural motor cortex stimulation in Parkinson's disease does not modify movement-related rCBF pattern. *Mov Disord*, 22, 2113-2116, ISSN 0885-3185
- Tani, N., Saitoh, Y., Kishima, H., Oshino, S., Hatazawa, J., Hashikawa, K., Yoshimine, T. (2007). Motor cortex stimulation for levodopa-resistant akinesia: case report. *Mov Disord*, 22, 1645-1649, ISSN 0885-3185
- Thickbroom, G.W., Byrnes, M.L., Walters, S., Stell, R., Mastaglia, F.L. (2006). Motor cortex reorganisation in Parkinson's disease. *J Clin Neurosci*, 13, 639-642, ISSN 0967-5868
- Tirakotai, W., Hellwig, D., Bertalanffy, H., Riegel, T. (2007). Localization of precentral gyrus in image-guided surgery for motor cortex stimulation. *Acta Neurochir Suppl*, 97, 75-79, ISSN 0065-1419
- Tsubokawa, T., Katayama, Y., Yamamoto, T., Hirayama, T., Koyama, S. (1991a). Chronic motor cortex stimulation for the treatment of central pain. *Acta Neurochir Suppl (Wien)*, 52, 137-139, ISSN 0065-1419
- Tsubokawa, T., Katayama, Y., Yamamoto, T., Hirayama, T., Koyama, S. (1991b). Treatment of thalamic pain by chronic motor cortex stimulation. *Pacing Clin Electrophysiol*, 14, 131-134, ISSN 0147-8389
- Umemura, A., Jaggi, J.L., Hurtig, H.I., Siderowf, A.D., Colcher, A., Stern, M.B., Baltuch, G.H. (2003). Deep brain stimulation for movement disorders: morbidity and mortality in 109 patients. *J Neurosurg*, 98, 779-784, ISSN 0022-3085

- Velasco, M., Velasco, F., Brito, F., Velasco, A.L., Nguyen, J.P., Marquez, I., Boleaga, B., Keravel, Y. (2002). Motor cortex stimulation in the treatment of deafferentation pain. I. Localization of the motor cortex. *Stereotact Funct Neurosurg*, 79, 146-167, ISSN 1011-6125
- Wood, C.C., Spencer, D.D., Allison, T., McCarthy, G., Williamson, P.D., Goff, W.R. (1988). Localization of human sensorimotor cortex during surgery by cortical surface recording of somatosensory evoked potentials. *J Neurosurg*, 68, 99-111, ISSN 0022-3085



## **Diagnostics and Rehabilitation of Parkinson's Disease**

Edited by Dr. Juliana Dushanova

ISBN 978-953-307-791-8

Hard cover, 528 pages

**Publisher** InTech

**Published online** 07, December, 2011

**Published in print edition** December, 2011

Diagnostics and Rehabilitation of Parkinson's Disease presents the most current information pertaining to news-making topics relating to this disease, including etiology, early biomarkers for the diagnostics, novel methods to evaluate symptoms, research, multidisciplinary rehabilitation, new applications of brain imaging and invasive methods to the study of Parkinson's disease. Researchers have only recently begun to focus on the non-motor symptoms of Parkinson's disease, which are poorly recognized and inadequately treated by clinicians. The non-motor symptoms of Parkinson's disease have a significant impact on patient quality of life and mortality and include cognitive impairments, autonomic, gastrointestinal, and sensory symptoms. In-depth discussion of the use of imaging tools to study disease mechanisms is also provided, with emphasis on the abnormal network organization in parkinsonism. Deep brain stimulation management is a paradigm-shifting therapy for Parkinson's disease, essential tremor, and dystonia. In the recent years, new approaches of early diagnostics, training programmes and treatments have vastly improved the lives of people with Parkinson's disease, substantially reducing symptoms and significantly delaying disability. Written by leading scientists on movement and neurological disorders, this comprehensive book should appeal to a multidisciplinary audience and help people cope with medical, emotional, and practical challenges.

### **How to reference**

In order to correctly reference this scholarly work, feel free to copy and paste the following:

Naoki Tani and Youichi Saitoh (2011). Electrical Stimulation of Primary Motor Cortex for Parkinson's Syndrome, *Diagnostics and Rehabilitation of Parkinson's Disease*, Dr. Juliana Dushanova (Ed.), ISBN: 978-953-307-791-8, InTech, Available from: <http://www.intechopen.com/books/diagnostics-and-rehabilitation-of-parkinson-s-disease/electrical-stimulation-of-primary-motor-cortex-for-parkinson-s-syndrome>

**INTECH**  
open science | open minds

### **InTech Europe**

University Campus STeP Ri  
Slavka Krautzeka 83/A  
51000 Rijeka, Croatia  
Phone: +385 (51) 770 447  
Fax: +385 (51) 686 166  
[www.intechopen.com](http://www.intechopen.com)

### **InTech China**

Unit 405, Office Block, Hotel Equatorial Shanghai  
No.65, Yan An Road (West), Shanghai, 200040, China  
中国上海市延安西路65号上海国际贵都大饭店办公楼405单元  
Phone: +86-21-62489820  
Fax: +86-21-62489821



© 2011 The Author(s). Licensee IntechOpen. This is an open access article distributed under the terms of the [Creative Commons Attribution 3.0 License](https://creativecommons.org/licenses/by/3.0/), which permits unrestricted use, distribution, and reproduction in any medium, provided the original work is properly cited.

IntechOpen

IntechOpen