

# We are IntechOpen, the world's leading publisher of Open Access books Built by scientists, for scientists

6,900

Open access books available

186,000

International authors and editors

200M

Downloads

Our authors are among the

154

Countries delivered to

TOP 1%

most cited scientists

12.2%

Contributors from top 500 universities



WEB OF SCIENCE™

Selection of our books indexed in the Book Citation Index  
in Web of Science™ Core Collection (BKCI)

Interested in publishing with us?  
Contact [book.department@intechopen.com](mailto:book.department@intechopen.com)

Numbers displayed above are based on latest data collected.  
For more information visit [www.intechopen.com](http://www.intechopen.com)



## Developing an MRI-Based Biomarker for Early Diagnosis of Parkinson's Disease

Jorge E. Quintero<sup>1</sup>, Xiaomin Wang<sup>3</sup> and Zhiming Zhang<sup>1,2,\*</sup>

<sup>1</sup>*Department of Anatomy and Neurobiology, Morris K. Udall Parkinson's Disease Research Center of Excellence,*

<sup>2</sup>*Magnetic Resonance Imaging and Spectroscopy Center, University of Kentucky Chandler Medical Center, Lexington,*

<sup>3</sup>*Department of Physiology, Key Laboratory for Neurodegenerative Disorders of the Ministry Education, Capital Medical University, Beijing*  
<sup>1,2</sup>USA

<sup>3</sup>PR of China

### 1. Introduction

Parkinson's disease (PD) is a relentlessly progressive disorder causing disability in most individuals and cannot be controlled with available medication. PD is currently considered a systemic disease with complex motor disorders and non-motor deficits which appear before or in parallel with motor deficits and then worsen with disease progression (Chaudhuri *et al.*, 2006; Ferrer *et al.*, 2010). In a recent survey, the projected number of individuals with PD will dramatically increase in 20 years especially in the most populated countries like China, India, Brazil and the United States (Dorsey *et al.*, 2007). Current causative theories for PD include complex interactions between genetic susceptibility and environmental factors. These and possibly other mechanisms lead to a progressive and variable degree of dopamine (DA) neuron loss in the substantia nigra compacta (SNc) resulting in DA depletion in the striatum (Hornykiewicz & Kish, 1987; Marsden & Obeso, 1994) that then leads to the clinical manifestation of PD. Studies have demonstrated that PD is characterized by a presymptomatic phase, likely lasting years, or even decades, during which neuronal degeneration is occurring but before clinical symptoms appear (Hubble, 2000; DeKosky & Marek, 2003; Katzenschlager & Lees, 2004). In addition, studies have demonstrated that most patients when diagnosed with PD have already lost a significant amount of SNc DA neurons in the range of 50% cell loss. Based on detailed pathological studies, Fearnley and Lees (1991) have proposed the notion that the loss of nigral neurons would occur exponentially, with greater loss occurring within the first decade in the disease process, and then reaching over 90% loss at the time of death.

While our understanding of PD has grown over the course of the last two centuries and PD is one of the best understood neurodegenerative diseases, our ability to treat PD remains limited. Given the progressive nature of the disease, the question becomes is it possible to divert or change the rate of the progression? Inherent to this question is our ability to identify where an individual is along the path of this disease. Thus it would behoove us to

be able to establish indicators of the disease stage while intervention remains a possibility. Here we describe the development of using non-invasive functional imaging as a biomarker for the early diagnosis of PD.

### 1.1 Difficulty of early detection of PD

The diagnosis and treatment of PD is fraught with problems: 1) so far, no objective measures are available for the diagnosis of PD (Wu *et al.*, 2011); 2) it is unknown whether a linear relationship exists between a worsening in the Unified Parkinson's Disease Rating Scale (UPDRS), or other clinical scales, and the progressive degeneration of the nigrostriatal system; 3) no objective measures are available for testing responsiveness of therapy. Therefore, biomarkers of disease progression before the appearance of symptoms would be of considerable value; thus, neuroimaging techniques may be good candidates for meeting the challenges. In the past decade, radiotracer imaging of the nigrostriatal dopaminergic system has been extensively explored with positron emission tomography (PET) and single photon emission computed tomography (SPECT) imaging protocols and has become a prominent biomarker in PD although these techniques are still controversial in some aspects such as the interpretation of imaging data and disconnection with clinical outcomes (Brooks *et al.*, 2003; Ravina *et al.*, 2005). However, the spatial resolution of these techniques is relatively poor, thus reducing their utility in mapping subtle changes in neuroanatomy and neurochemistry with PD progression (Snow *et al.*, 2000). Furthermore, PET imaging is not widely available and is expensive (~US\$3,000-\$6,000) because of the need to generate and use radioactive nucleotides onsite. Clearly there is a need for imaging techniques that do not require radioactive isotopes but ones that would still be sensitive enough to usefully and longitudinally monitor the development, progression, and treatment of PD. The ideal technique would 1) permit high-resolution imaging of brain sites affected by PD processes, 2) provide valid assessment of the underlying neuroanatomical state, and 3) be safe to allow repeated tests. A hypothesis for PD is that the disease severity corresponds to the magnitude and pattern of histological and neuroimaging abnormalities (DeKosky & Marek, 2003; Eckert & Eidelberg, 2004; Seibyl *et al.*, 2005). Based on our own previous studies, and those of others in rodents, nonhuman primates, and humans, pharmacological MRI (phMRI; or functional MRI with specific pharmacological stimulation) would be a good candidate because of its high resolution, sensitivity, reproducibility, wide availability, and low cost (Nguyen *et al.*, 2000; Tracey, 2001; Honey & Bullmore, 2004; Jenkins *et al.*, 2004; Chin *et al.*, 2008; Thiel, 2009; Rasmussen Jr, 2010).

### 1.2 Why is a new imaging protocol needed for PD?

In the past decade, PET and SPECT have become the most widely used and accepted imaging methods for PD research (de la Fuente-Fernandez & Stoessl, 2002; Eckert & Eidelberg, 2004). Worsening motor disability along with  $^{18}\text{F}$ -dopa uptake decreases in the putamen (Brooks *et al.*, 1990) correlate with the storage of DA within vesicles (Hoshi *et al.*, 1993) and with the number of functioning DA terminals in the striatum (Snow *et al.*, 1993). Currently, *in vivo* measurements can be conducted using SPECT with ligands for the DA transporter (DAT) such as  $[(^{123}\text{I})\text{N-}\omega\text{-fluoropropyl-2}\beta\text{-carbomethoxy-3}\beta\text{-[4-iodophenyl]nortropane (FP-CIT)}$  that provide a measure of DA terminal integrity (DeKosky & Marek, 2003; Andringa *et al.*, 2005). Although the aforementioned studies have shown that these neuroimaging techniques are capable of mapping changes in dopaminergic function in

the basal ganglia, much controversy still exists. Recent problems have been encountered in clinical trials that have used radioligand imaging to quantify medication response. For example, there appears to be a discrepancy between current imaging protocols and clinical outcomes. In National Institutes of Health (NIH) sponsored randomized double-blind studies on PD patients receiving either fetal tissue transplants or sham surgery, a 40% increase in  $^{18}\text{F}$ -dopa uptake in the putamen contrasted with a modest (non-significant) 18% improvement in the mean UPDRS in one study involving 40 patients (Freed *et al.*, 2001). In the second study involving 34 patients, a 20-30% increase of  $^{18}\text{F}$ -dopa uptake was seen in the striatum, but clinical changes failed to reach statistical significance (Brooks, 2004). Most recently, a significant increase was found in  $^{18}\text{F}$ -dopa uptake in the putamen of PD patients receiving trophic therapy, while clinical improvements did not differ significantly from the control group (Lang *et al.*, 2006).

### 1.3 What are imaging biomarkers for PD?

In general, biomarkers must be biologically and clinically relevant, analytically sound, operationally practical, timely, interpretable and cost effective. On the other hand, biomarkers must be objectively measured indicators of biological and pathobiological process or pharmacologic responses to treatment. The biomarkers should be used to substitute for a clinical endpoint (predict benefit or harm) based on epidemiologic, therapeutic, pathophysiologic or other scientific evidence (Biomarkers definition working group, 2001). Specifically for PD, the biomarkers must be indicators of biological processes that change with the progression of the nigrostriatal system. The biomarkers should 1) correlate to some extents with severity of PD assessed by behavior and with pathophysiological changes such as the number of surviving neurons in the SNc; 2) reflect true disease status or predict clinical outcomes; 3) be used to assess efficacy and/or responsiveness of treatment, and 4) be used as surrogate endpoints.

### 1.4 What is BOLD-phMRI?

Our preliminary studies have shown evidence that blood-oxygenation-level-dependent (BOLD)-phMRI can be used as a non-invasive imaging modality to detect functional changes of the dopamine system in parkinsonian monkeys. More importantly, the studies were conducted in a conventional clinical MRI scanner without the injection of contrast agents. Using this imaging method, a significant correlation was found between the amphetamine-evoked BOLD response and the number of surviving dopamine neurons in the substantia nigra, which was also significantly correlated with bradykinesia scores on the nonhuman primate parkinsonian rating scale (Ovadia *et al.*, 1995), suggesting that phMRI may be used as a biomarker to assess dopamine neuronal loss in PD. Recently, fMRI has become a popular tool for imaging of functionally active brain regions in healthy and diseased brains. The use of fMRI is promoting the emergence of a new area of research, one that is complementary to more invasive techniques for measuring neural activity in animal models while better understanding the function and dysfunction of the human brain. The most common method of fMRI is the BOLD imaging technique. fMRI takes advantage of the coupling between neural activity and hemodynamics (the local control of blood flow and oxygenation) in the brain to allow the non-invasive localization and measurement of brain activity (Fig. 1).

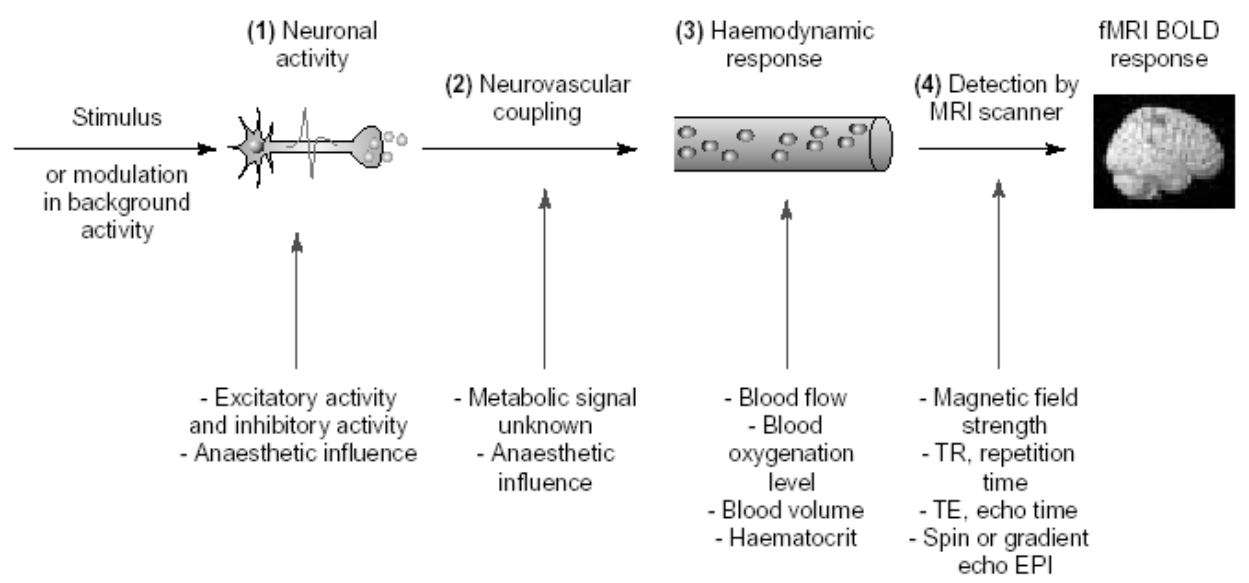


Fig. 1. fMRI provides an insight into neural activity. The BOLD signal has several constituents: (1) the neuronal response to a stimulus or background modulation; (2) the complex relationship between neuronal activity and triggering a haemodynamic response (termed neurovascular coupling); (3) the haemodynamic response itself; and (4) the detection of the response by an MRI scanner (from Arthurs & Boniface, 2002).

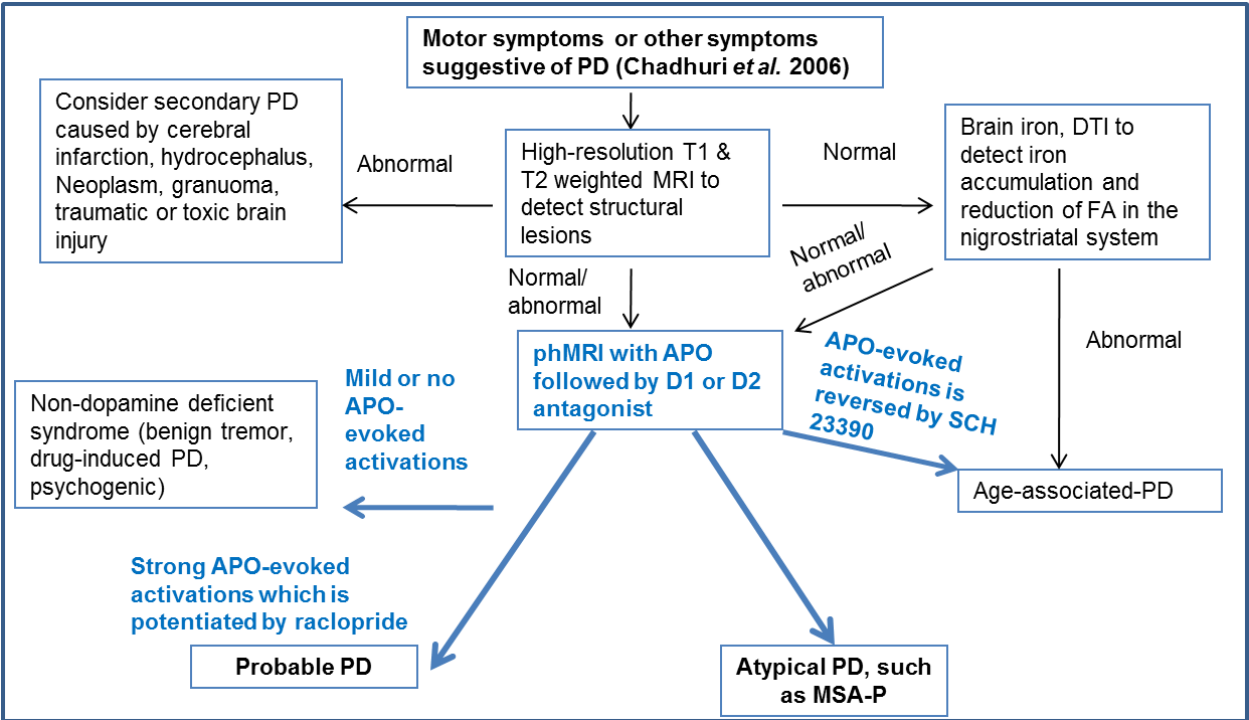


Fig. 2. Using phMRI for the early diagnosis of PD. As part of a multi-factor approach, phMRI provides a possible means of screening for the underlying neurological changes in parkinsonism or PD.



We hypothesize that the BOLD-fMRI response to a specific DA stimulation could serve as a potential biomarker for PD because of its unique features which are different from other neuroimaging technologies as follows: 1) High sensitivity and reproducibility, and relatively high specificity, 2) Minimal invasiveness or patient discomfort ("subject friendly"), 3) Low per-usage cost (this is especially important if widespread screening is contemplated), and 4) wide availability.

## **2. pHMRI detects dopamine deficiency in parkinsonian monkeys**

### **2.1 An animal model of dopamine deficiency in rhesus monkeys**

A reliable and reproducible model of dopamine deficiency/a model simulating human PD is developed by unilateral administration of neurotoxin 1-methyl-4-phenyl-1,2,3,6-tetrahydropyridine (MPTP) through the carotid artery. The specific neurotoxic actions of MPTP are produced when it is metabolized by monoamine oxidase B into 1-methyl-4-phenylpyridinium (MPP<sup>+</sup>), a complex I mitochondrial neurotoxin with relative specificity for dopamine neurons in the substantia nigra (Langston & Ballard, 1983; Nicklas *et al.*, 1987; Richardson *et al.*, 2007). Ding and colleagues (2008) described the key features modeled by MPTP toxicity including 1) all animals show parkinsonian features often seen in idiopathic PD such as bradykinesia, rigidity, postural, and balance instability, 2) these PD features can be partially normalized by levodopa treatment, which is the most efficacious drug to treat PD motor symptoms and is widely considered the "gold standard" treatment for the disease, 3) massive neuronal loss of dopaminergic neurons in the SNc and dopaminergic fibers in the striatum, and 4) remarkable declines in DA and DA metabolites.

### **2.2 pHMRI procedures**

1) Mapping of MPTP-induced functional changes with d-amphetamine stimulations (from a pre-synaptic perspective) and 2) Mapping of MPTP-induced functional changes with APO challenge (from a post-synaptic perspective). In early studies, the scans were conducted on a Siemens VISION 1.5 T MRI scanner using the body coil to transmit radio frequency and an 8 cm diameter surface coil placed above the monkey's head for RF signal reception. The anatomical structures of interest were visualized using a 3D FLASH sequence with 1 mm isotropic resolution (TR/TE=21/6 ms, flip angle = 30°, image matrix size = 128x128x90, field of view = 128 mm). The functional MR images from pharmacological challenges were acquired continuously using a FLASH 2D multiple gradient-recalled-echo (MGRE) navigator sequence (Chen *et al.*, 1996). The ROI dimensions were 3x3x3 mm, each representing a 27 mm<sup>3</sup> volume. ROIs were manually selected in both hemispheres of MPTP-lesioned and normal control animals based on the co-registered 3D anatomical images acquired from the FLASH sequence. Because of variability in the inherent noise level due to differences in positioning animals for each scan and the movements during scanning, the replicate scans were treated as independent observations in the analysis. For later studies, images were acquired on a Siemens 3T Trio clinical MRI system using a dedicated receive-only coil for reception, which was designed and developed by our group. The BOLD-effect weighted MR images used to measure the pHMRI response were acquired in an anatomically coronal plane. The image planes of the acquisition were arranged to cover the motor cortex and the basal ganglia. A segmented gradient-echo EPI sequence with TE=28 ms and a turbo factor of 7 was used to reduce echo train length and minimize magnetic susceptibility-related artifacts. The EPI sequence acquisition parameters are FOV=112x98 mm and image matrix 64x56 for an in-plane resolution of 1.75 mm. A total of 15 contiguous

slices, each 2 mm-thick, were acquired at a rate of 15 s per EPI volume. The overall scan duration was 80 minutes with 128 volumes acquired prior to apomorphine (APO) administration as a baseline and 192 after APO to track the response. Images were motion corrected and spatially smoothed using a Gaussian kernel of width 3.5 mm. phMRI response was calculated as the fractional signal change in % of the average of the post-APO image data relative to the pre-APO baseline. A co-registered high-resolution (0.67×0.67×1 mm) T1-weighted anatomical MRI scan was acquired in each session for spatial localization of the activation response. Prior to the administration of d-amphetamine (2.0mg/kg) or APO (0.1 mg/kg), a total of 40 image frames were collected over 20 min to determine the baseline state. Following injection of d-amphetamine or APO, an additional 40 frames were collected to track the dynamic response (Zhang *et al.*, 2001; Andersen *et al.*, 2002). The change in  $R_2^*$ , i.e.  $\Delta R_2^*$  which represents the phMRI activation response to drug, was determined as the difference between the mean  $R_2^*$  across 20 images post drug administration during the period of peak response (5-15 min) and the mean  $R_2^*$  within the 40 baseline images. A reduction (“negative” change) in  $R_2^*$  associated with a local decrease of paramagnetic deoxyhemoglobin is an indicator of BOLD-effect activation (Chen *et al.*, 1996).

2.3 phMRI-responses correlate with severity of PD

Six out of six animals responded positively to APO treatment represented by 44% improvements in parkinsonian symptoms. The same dose of APO also evoked phMRI responses by increasing the phMRI signal intensity. The typical phMRI (BOLD effect) responses to APO were gradually increased after APO administration only in the structure on the ipsilateral side receiving MPTP administration. Interestingly, but not surprising, APO-induced behavioral changes (PD features) were significantly correlated with APO-induced phMRI responses in the putamen, premotor cortex, and cingulate gyrus. When compared with standard but objective measures, there was a significant negative correlation between the phMRI responses in the putamen and distance travelled and movement speed. Similar relationships were also seen between phMRI responses in the motor cortex and daytime home-cage activity and between phMRI responses in the caudate nucleus and movement speed.

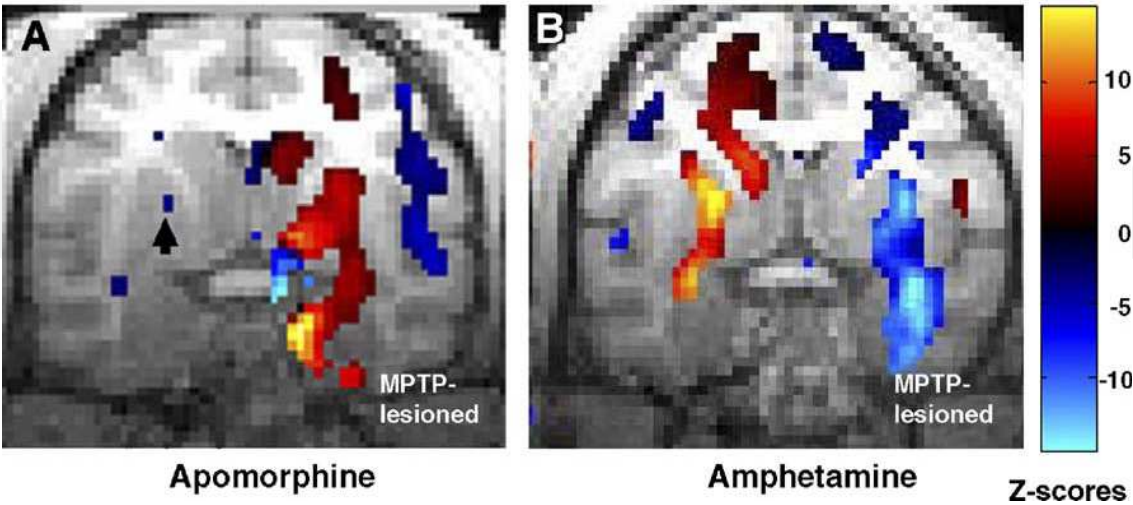


Fig. 3. phMRI reveals nigrostriatal system responsiveness to dopamine stimulation. Coronal MRI scans depicting areas of activation and deactivation (represented by the pseudocolor) in the brain after an APO or amphetamine challenge in unilateral MPTP-lesioned nonhuman primates (from Zhang *et al.*, 2006).

2.4 pHMRI-response and MPTP-induced dopamine deficiency

2.4.1 pHMRI responses in MPTP-lesioned structures

Apomorphine administration strongly activated the MPTP-denervated putamen (Figs. 3A and 4C) and substantia nigra (Fig.4D). An opposite response (a positive  $\Delta R_2^*$  value) was evident in the contralateral putamen (Fig. 4G) and substantia nigra (Fig. 4H). The differences between the intact and lesioned substantia nigra and between the intact and lesioned putamen were highly significant,  $P < 0.01$  ( $t$ -test), in both cases. In contrast,  $\Delta R_2^*$  responses in the caudate nucleus and in the corpus callosum were not significant, nor were there significant hemispheric differences in activation or deactivation with the contralateral caudate or with a comparable region in the contralateral callosum (Figs. 4A and 4E). The pHMRI responses to amphetamine treatment in the putamen (Figs. 3B and 4G) and substantia nigra (Fig. 4H) were the inverse of those seen with apomorphine. Amphetamine-induced decreases (positive  $\Delta R_2^*$  values) in the lesioned putamen and substantia nigra suggested diminished neuronal activity in both sites. In contrast, amphetamine induced the opposite  $\Delta R_2^*$  response in the intact left side, tending to increase activation in the putamen and substantia nigra. The responses in the intact putamen and intact substantia nigra were significantly different from their lesioned counterparts. Again, the corpus callosum and the caudate nucleus displayed only small, insignificant changes in response to amphetamine stimulation (Figs. 4E and 4F).

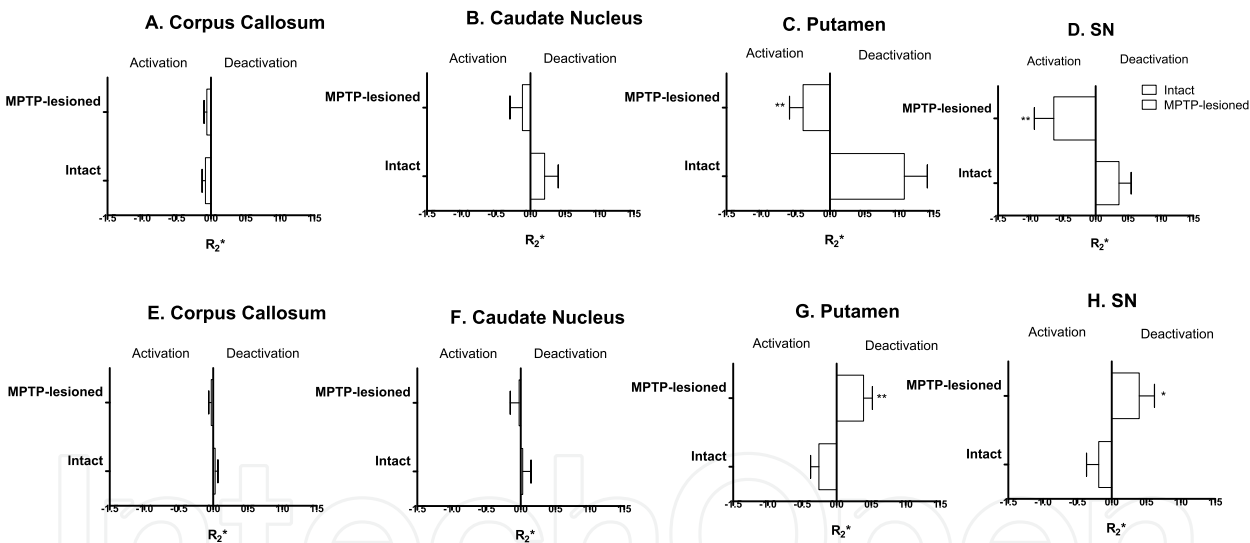


Fig. 4. pHMRI responses in the nigrostriatal system. Depending on the means of stimulation, pHMRI reveals a differential activations and deactivations in the nigrostriatal system. After APO stimulation (A-D) or *d*-amphetamine stimulation (E-H). \*\* $P < 0.01$ ; \* $P < 0.05$ ; unpaired  $t$ -test (from Zhang *et al.*, 2006).

2.4.2 pHMRI-responses and loss of DA neurons in the SN

In a later study, post-mortem histopathological evaluation revealed that the unilateral MPTP administration (received 5 years before the analysis) produced a massive (85%) loss of the rate-limiting enzyme for DA formation, tyrosine hydroxylase, ( $TH^+$ ) cells in the midbrain on the ipsilateral side receiving the infusion of the neurotoxin.  $TH^+$  cell numbers were significantly higher on the un-lesioned side compared to the MPTP-lesioned side. More importantly, the number of  $TH^+$  cells was strongly correlated with the pHMRI responses in



the caudate nucleus and in the cingulate gyrus. When comparing d-amphetamine-induced DA release in the putamen and DA neuron counts in the SNc, a significant correlation was also seen. In an earlier study (Zhang *et al.*, 2006), amphetamine administration evoked a BOLD response in the SN that correlated with the number of TH<sup>+</sup> dopamine neurons in the same structure. These data support that there is a strong relationship between BOLD-responses to dopaminergic challenge and the number of dopaminergic neurons in the midbrain.

**2.4.3 phMRI-responses and loss of DA fibers in the striatum**

Similar to the effect on dopaminergic neurons, the MPTP administration also produced a remarkable reduction of TH<sup>+</sup> fibers on the ipsilateral side of the lesion. A comparison of the fiber density in the putamen on the MPTP-lesioned side with other elements of the cortico-basal ganglia-cortical circuit (Braak & Del Tredici, 2008) such as ipsilateral phMRI responses in the motor cortex (Fig. 5A) and caudate nucleus (Fig. 5B) showed strong correlations. In addition, the fiber density in the MPTP-lesioned caudate nucleus was strongly correlated with phMRI responses in the premotor cortex, caudate nucleus, and cingulate gyrus. Those changes in TH<sup>+</sup> fiber density were also correlated with behavior and DA levels in the striatum and with the number of DA neurons in the SNc.

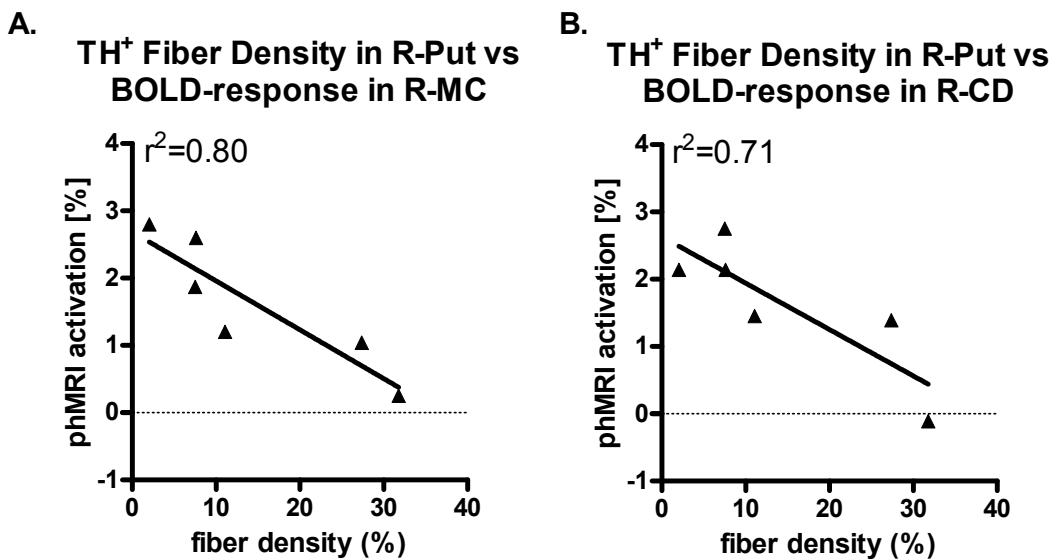


Fig. 5. Lower TH<sup>+</sup> fiber density in the ipsilesional putamen corresponds with higher phMRI activation. TH<sup>+</sup> fiber density in the right putamen (R-Put) is inversely correlated with phMRI activation in A) the right motor cortex (R-MC) and B) the right caudate nucleus (R-CD).

**2.4.4 phMRI-responses correlate with dopamine overflow**

The microdialysis experiments were conducted months after the parkinsonian symptoms had been fully developed and stabilized. First, the single administration of MPTP produced significant reduction in both potassium- and d-amphetamine-evoked overflow of DA in the putamen (Fig. 6A) and SNc (Fig.6B) on the ipsilateral side of the lesion. Second, there were several important correlations between DA levels in the putamen and SNc and the phMRI responses. For example, both potassium- and d-amphetamine-evoked overflow of DA in

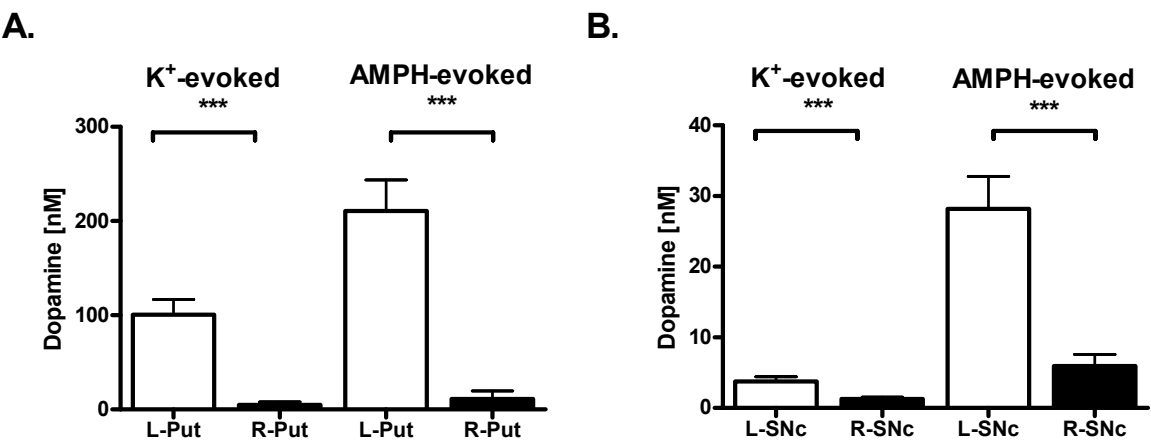


Fig. 6. Hemiparkinsonian nonhuman primates have markedly diminished dopaminergic function. K<sup>+</sup> (100 mM)- and amphetamine (250 μM)-evoked DA release was significantly attenuated in the ipsilesional A) putamen (Put) and B) SNc; \*\*\*: P < 0.0001 (paired *t*-test).

the putamen (each measured for a single time point, 30 minutes after stimulus administration) had significant correlations with phMRI responses in the putamen. DA levels in the putamen were also significantly correlated with phMRI responses in the premotor cortex and cingulate gyrus, as well as in the caudate nucleus. Finally, d-amphetamine-evoked DA release in the SNc was found to have a significant, but negatively correlated relationship with the motor cortex (Fig. 7).

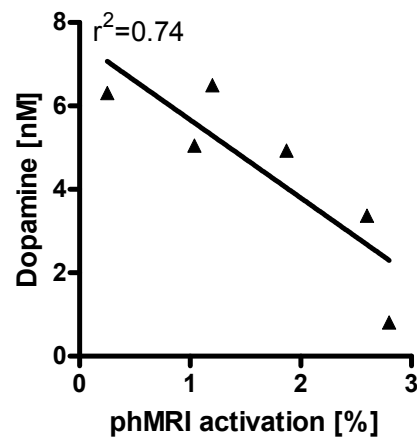


Fig. 7. DA levels in the right SNc correlate with the BOLD responses in the right motor cortex. In animals with lower DA levels in the right SNc, less activation was observed in the right motor cortex

3. Using phMRI to monitor therapeutic effects in parkinsonian monkeys

There is a great need for the development of noninvasive, highly sensitive, and widely available imaging methods which can potentially be used to longitudinally monitor treatment of PD. We reported the monitoring of glial-cell-line-derived neurotrophic factor (GDNF) induced functional changes of the basal ganglia in hemiparkinsonian monkeys via phMRI measuring the BOLD response to a direct dopamine agonist, APO, (Luan *et al.*, 2008). The effectiveness of GDNF to protect and restore the nigrostriatal dopaminergic system in rodent and nonhuman primate models of PD has been extensively documented (Beck *et al.*,

1995; Tomac *et al.*, 1995; Gash *et al.*, 1996; Kordower *et al.*, 2000; Grondin *et al.*, 2002). This trophic factor has also shown promise in Phase I clinical trials for the treatment of PD (Gill *et al.*, 2003; Slevin *et al.*, 2005). Ample evidence supports the idea that GDNF can protect and promote survival of pre-synaptic dopaminergic neurons in the SNc and axons in the striatum (Gash *et al.*, 1996). After testing BOLD responses to APO in their normal state, additional scans were taken with the same dose of APO stimulation after MPTP-induced hemiparkinsonism. Then, the animals were chronically treated with GDNF for 18 weeks by a programmable pump and catheter system. The catheter was surgically implanted into the right putamen and connected to the pump via flexible polyurethane tubing. phMRI scans were taken at both 6 and 18 weeks while they received 22.5 $\mu$ g of GDNF per day (Fig. 8). In addition, behavioral changes were monitored throughout the entire study. The primary finding of this study was that APO-evoked activations in the DA denervated putamen were attenuated by the chronic intraputamenal infusion of GDNF accompanied by improvements of parkinsonian features, movement speed and APO-induced rotation compared to data collected before the chronic GDNF treatment. The results suggest that phMRI methods in combination with administration of a selective DA agonist may be useful for monitoring neurorestorative therapies in PD patients in the future.

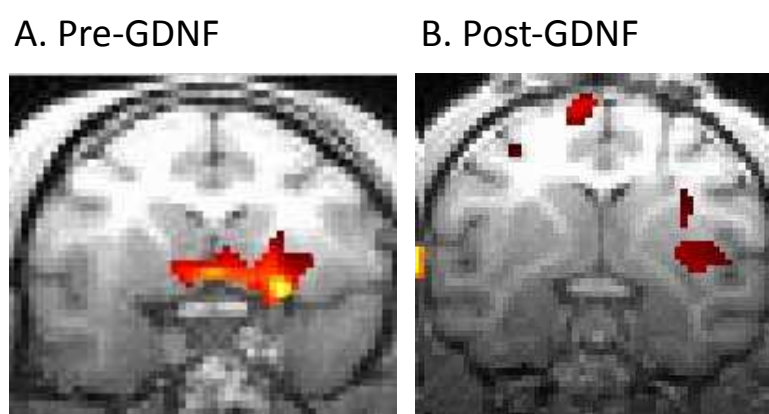


Fig. 8. phMRI (BOLD)-responses to APO can be used to monitor GDNF-induced neurorestorative therapeutic effects in rhesus monkeys with MPTP-induced hemiparkinsonisms. phMRI activation reveals differences in dopaminergic activity after GDNF treatment (from Luan *et al.*, 2008).

#### 4. Brain iron and motor deficits in rhesus monkeys

Schuff (2009) notes in a recent review, perhaps the most consistently reported MRI findings in PD have been the detection of signal changes related to excessive iron, most likely related to ferritin, the main iron-storage protein within the brain. Under normal condition, iron is essential for normal metabolism and used in production of DA. Brain iron may also play an essential role in learning and memory (Fretham *et al.*, 2011). Several years ago, we reported a correlation of  $R_2$  with total iron concentration in the brains of rhesus monkeys (Hardy *et al.*, 2005). The results show that the transverse relaxation rate  $R_2 = 1/T_2$  is highly correlated to and varies linearly with iron content. In the study, Hardy and colleagues demonstrated that  $R_2$  was highly correlated with the total iron concentration and that the relationship between  $R_2$  and tissue iron concentration appeared to depend upon the iron concentration. In another multidiscipline study of brain iron in a large group of rhesus monkeys ranging in age from 4

to 32 years old, Cass and colleagues (2006) found significant decreases in motor performance, decreases in striatal DA release, and increases in striatal iron levels in rhesus monkeys as they aged from young adulthood. A comprehensive statistical analysis relating age, motor performance, DA release, and iron content indicated that the best predictor of decreases in motor ability, above and beyond levels of performance that could be explained by age alone, was iron accumulation in the striatum. Compared to the young animals, the relaxation rate  $1/T_2^*$  used as an indicator of iron content was elevated by 38-43% in all three regions in the middle-aged monkeys (Fig. 9). In the aged animals, iron content was increased by 55%, 61%, and 79% in the caudate, putamen, and nigra, respectively, compared to the young animals (Fig. 9). Iron content in the nigra of the aged animals was also 30% higher than in the middle-aged animals. ROI data for  $1/T_2^*$  measures are not shown but exhibited a similar dependence on age. Regression analysis extended the group statistics and further confirmed the strong age-associated increase of the MRI relaxation rate  $1/T_2^*$  (equivalent to a  $T_2^*$ -shortening) in each of the three regions of interest ( $n = 24$ ;  $p < 0.0001$ ). The intercept and rate of increase were  $16.537 + 0.598 \text{ sec}^{-1}/\text{year}$ ,  $15.728 + 0.734 \text{ sec}^{-1}/\text{year}$ , and  $19.047 + 0.791 \text{ sec}^{-1}/\text{year}$  for the caudate, putamen, and substantia nigra, respectively. This suggests that striatal iron levels may be a biomarker of motor dysfunction in aging; and as such, can be monitored non-invasively by longitudinal brain MRI scans.

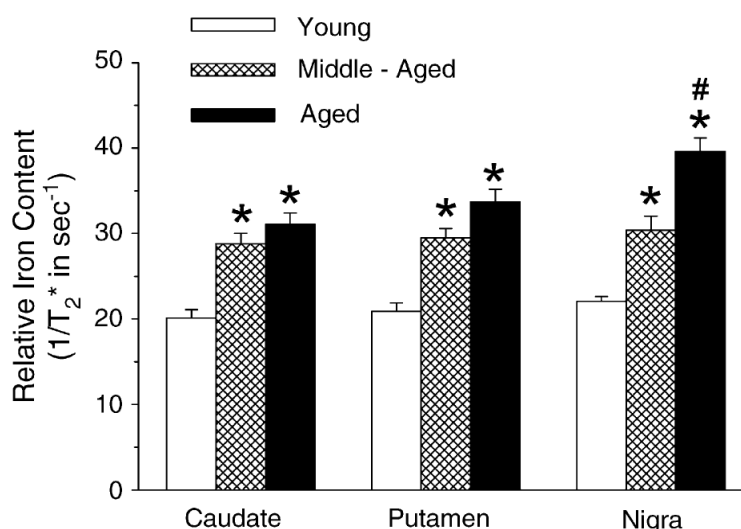


Fig. 9. Using MR imaging of iron content to identify alterations in the aging brain. The use of MR imaging to identify the relative iron content in particular brain structures illustrates the potential usefulness for a non-invasive means of assessing changes in the nigrostriatal system with aging. \*:  $P < 0.05$ ; #:  $P < 0.01$  (one-way ANOVA). (from Cass *et al.*, 2006)

## 5. Diffusion Tensor Image (DTI) and dopamine deficiency in rhesus monkeys

Diffusion tensor imaging (DTI) has been increasingly used in PD related research (Schuff, 2009). DTI can be used to noninvasively investigate and identify white matter (WM) changes associated with PD. DTI is able to obtain quantitative information about fractional anisotropy (FA) and mean diffusivity (MD). A diminished FA is thought to reflect axonal loss and demyelination. A recent DTI study was conducted by our group in normal ( $n=9$ ) and hemiparkinsonian ( $n=8$ ) monkeys to explore the MPTP-effects on WM using the DTI parameters of FA and MD. Under general anesthesia, DTI data was obtained on a 3T Siemens

Trio MRI scanner with a custom-built, single channel, receive-only coil, built on a fiberglass frame and used to enhance the received signal. Imaging consisted of single shot (SS), double pulsed gradient spin echo (double-PGSE), diffusion weighted, echo planar imaging (EPI) with a spatial resolution of  $1.23 \times 1.23 \times 2.0 \text{ mm}^3$ . Images were processed and analyzed by using the publicly available image processing software FSL (<http://www.fmrib.ox.ac.uk/fsl>) (Smith *et al.*, 2004; Smith *et al.*, 2006). All of the processing tools referred to by their FSL acronyms are available for download at the website. First, we observed a WM tract in the vicinity of the basal ganglia (BG) with FA greater ( $P < 0.01$ , *t*-test) in the aged-matched control animals than MPTP-treated animals in the same structure. Second, we observed multiple WM tracts in the sensory cortex, with FA greater ( $P < 0.05$ , *t*-test) in the MPTP-treated than untreated side in the same animals. The result from the pilot study supports the idea that high resolution DTI has the potential to distinguish animals with a MPTP-lesioned nigrostriatal system from normal age-matched, healthy controls on an animal-by-animal basis.

## 6. Conclusion and perspectives

Since a diagnosis of PD still solely depends on the judgment of the clinician, there is an urgent demand for the development of reliable and applicable test systems or biomarkers to provide a level of certainty to the diagnosis. Objective biomarkers of PD are pivotal to tracking the disease progression and confirm the therapeutic effects. Non- or minimally-invasive imaging techniques provide a unique, real-time opportunity to assess the changes that occur with neurodegenerative diseases. In addition, with the rapidly expanding use of fMRI to provide a dramatically greater understanding of brain function, imaging techniques such as phMRI are only bound to benefit from this new wealth of knowledge.

The advantage of MRI is that MRIs are far more widely available than other imaging modalities and are most commonly used in clinical practice to differentiate idiopathic PD from secondary cause of parkinsonism (Pavese & Brooks, 2009). Recent advancement in high field MRI technology offers even better opportunities for noninvasively, longitudinally, and objectively assessing brain alterations in PD. For example functional and pharmacological MRI has been increasingly employed for preclinical and clinical research of the disease. Ample evidence supports that MRI signals have the potential to be developed as a noninvasive state biomarker in PD. For example, several MRI methodologies such as structural MRI, imaging of brain iron, DTI, functional MRI and pharmacological MRI have provided meaningful insight of brain alteration in PD. That said, we note that while we have gained greater understanding of the changes that occur in disorders of dopaminergic dysfunction with the use of phMRI in the rhesus model of PD, nevertheless the studies are works in progress and ones that still require cautious interpretation because conditions in patients with PD are more complex than in the animal model used in these studies.

In our hands, MRI studies conducted at the University of Kentucky have demonstrated that phMRI-responses to dopaminergic challenges in MPTP-treated monkeys are highly correlated with 1) the severity of parkinsonism, 2) the loss of dopamine neurons and terminals, 3) the decline of dopamine overflow and 4) the functional recovery from GDNF treatment. In addition, results from imaging brain iron suggest that striatal iron levels may constitute a biomarker for motor dysfunction in aged animals with parkinsonism. As shown in Fig. 10, combining various MRI methodologies may be used to screen populations at high risk, to differentiate idiopathic PD from second causes of parkinsonisms, and to monitor progression of the disease and the therapeutic effects.



### Developing an MRI-based diagnostic kit for early detection of Parkinson's disease

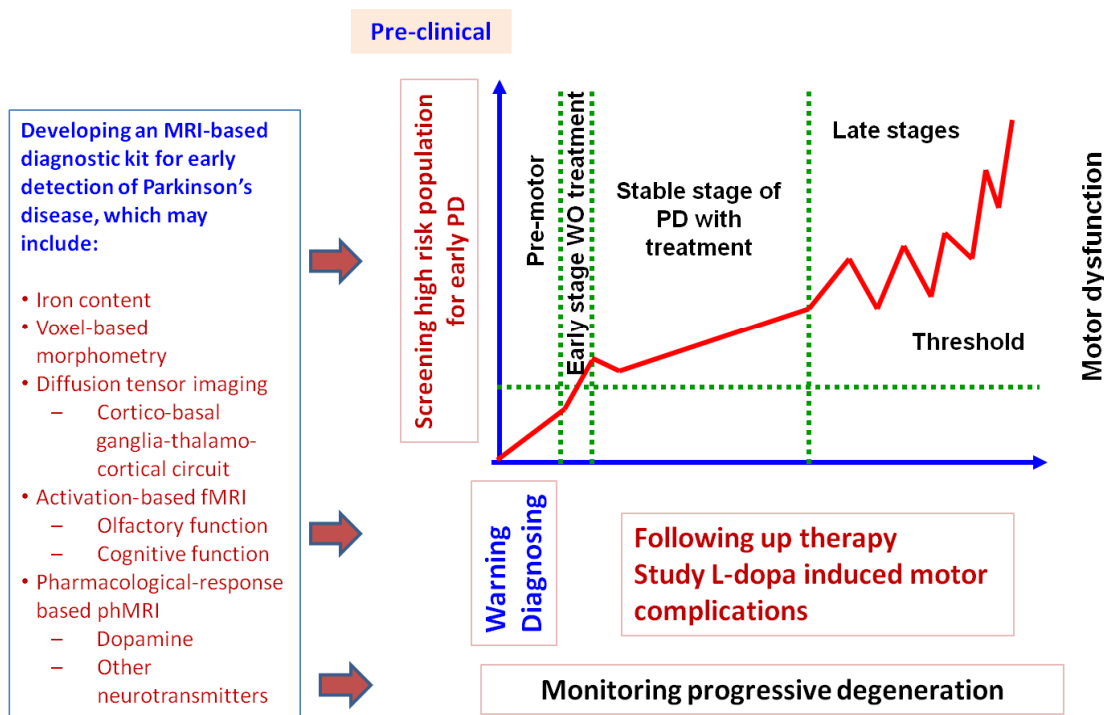


Fig. 10. Employing MRI methodologies in the clinic for PD.

## 7. Acknowledgment

We thank Drs. Anders Andersen, Peter Hardy, and Richard Grondin for their technical help in data analysis, behavioral evaluation, and discussions. Support provided by USPHS NIH grants NS50242, NS39787, and AG13494.

## 8. References


- Andersen, A.H., Zhang, Z., Barber, T., Rayens, W.S., Zhang, J., Grondin, R., Hardy, P., Gerhardt, G.A. & Gash, D.M. (2002) Functional MRI studies in awake rhesus monkeys: methodological and analytical strategies. *J Neurosci Methods*, 118, 141-152.
- Andringa, G., Drukarch, B., Bol, J.G., de Bruin, K., Sorman, K., Habraken, J.B. & Booij, J. (2005) Pinhole SPECT imaging of dopamine transporters correlates with dopamine transporter immunohistochemical analysis in the MPTP mouse model of Parkinson's disease. *Neuroimage*, 26, 1150-1158.
- Arthurs, O.J. & Boniface, S. (2002) How well do we understand the neural origins of the fMRI BOLD signal? *Trends Neurosci*, 25, 27-31.
- Beck, K.D., Valverde, J., Alexi, T., Poulsen, K., Moffat, B., Vandlen, R.A., Rosenthal, A. & Hefti, F. (1995) Mesencephalic dopaminergic neurons protected by GDNF from axotomy-induced degeneration in the adult brain. *Nature*, 373, 339-341.
- Braak, H. & Del Tredici, K. (2008) Cortico-basal ganglia-cortical circuitry in Parkinson's disease reconsidered. *Exp Neurol*, 212, 226-229.
- Brooks, D.J. (2004) Neuroimaging in Parkinson's disease. *NeuroRx*, 1, 243-254.
- Brooks, D.J., Frey, K.A., Marek, K.L., Oakes, D., Paty, D., Prentice, R., Shults, C.W. & Stoessl, A.J. (2003) Assessment of neuroimaging techniques as

- biomarkers of the progression of Parkinson's disease. *Exp Neurol*, 184 Suppl 1, S68-79.
- Brooks, D.J., Ibanez, V., Sawle, G.V., Quinn, N., Lees, A.J., Mathias, C.J., Bannister, R., Marsden, C.D. & Frackowiak, R.S. (1990) Differing patterns of striatal 18F-dopa uptake in Parkinson's disease, multiple system atrophy, and progressive supranuclear palsy. *Ann Neurol*, 28, 547-555.
- Cass, W.A., Grondin, R., Andersen, A.H., Zhang, Z., Hardy, P.A., Hussey-Andersen, L.K., Rayens, W.S., Gerhardt, G.A. & Gash, D.M. (2006) Iron accumulation in the striatum predicts aging-related decline in motor function in rhesus monkeys. *Neurobiol.Aging*.
- Chaudhuri, K.R., Healy, D.G. & Schapira, A.H.V. (2006) Non-motor symptoms of Parkinson's disease: diagnosis and management. *The Lancet Neurology*, 5, 235-245.
- Chen, Q., Andersen, A.H., Zhang, Z., Ovadia, A., Gash, D.M. & Avison, M.J. (1996) Mapping drug-induced changes in cerebral R2\* by Multiple Gradient Recalled Echo functional MRI. *Magn Reson Imaging*, 14, 469-476.
- Chin, C.L., Tovcimak, A.E., Hradil, V.P., Seifert, T.R., Hollingsworth, P.R., Chandran, P., Zhu, C.Z., Gauvin, D., Pai, M., Wetter, J., Hsieh, G.C., Honore, P., Frost, J.M., Dart, M.J., Meyer, M.D., Yao, B.B., Cox, B.F. & Fox, G.B. (2008) Differential effects of cannabinoid receptor agonists on regional brain activity using pharmacological MRI. *British Journal of Pharmacology*, 153, 367-379.
- de la Fuente-Fernandez, R. & Stoessl, A.J. (2002) Parkinson's disease: imaging update. *Curr Opin Neurol*, 15, 477-482.
- DeKosky, S.T. & Marek, K. (2003) Looking backward to move forward: early detection of neurodegenerative disorders. *Science*, 302, 830-834.
- Ding, F., Luan, L., Ai, Y., Walton, A., Gerhardt, G.A., Gash, D.M., Grondin, R. & Zhang, Z. (2008) Development of a stable, early stage unilateral model of Parkinson's disease in middle-aged rhesus monkeys. *Exp Neurol*, 212, 431-439.
- Dorsey, E.R., Constantinescu, R., Thompson, J.P., Biglan, K.M., Holloway, R.G., Kieburtz, K., Marshall, F.J., Ravina, B.M., Schifitto, G., Siderowf, A. & Tanner, C.M. (2007) Projected number of people with Parkinson disease in the most populous nations, 2005 through 2030. *Neurology*, 68, 384-386.
- Eckert, T. & Eidelberg, D. (2004) The role of functional neuroimaging in the differential diagnosis of idiopathic Parkinson's disease and multiple system atrophy. *Clin Auton Res*, 14, 84-91.
- Fearnley, J.M. & Lees, A.J. (1991) Ageing and Parkinson's disease: substantia nigra regional selectivity. *Brain*, 114 ( Pt 5), 2283-2301.
- Ferrer, I., Martinez, A., Blanco, R., Dalfó, E. & Carmona, M. (2010) Neuropathology of sporadic Parkinson disease before the appearance of parkinsonism: preclinical Parkinson disease. *Journal of Neural Transmission*, 1-19.
- Freed, C.R., Greene, P.E., Breeze, R.E., Tsai, W.Y., DuMouchel, W., Kao, R., Dillon, S., Winfield, H., Culver, S., Trojanowski, J.Q., Eidelberg, D. & Fahn, S. (2001) Transplantation of embryonic dopamine neurons for severe Parkinson's disease. *N Engl J Med*, 344, 710-719.
- Fretham, S.J.B., Carlson, E.S. & Georgieff, M.K. (2011) The Role of Iron in Learning and Memory. *Advances in Nutrition: An International Review Journal*, 2, 112-121.
- Gash, D.M., Zhang, Z., Ovadia, A., Cass, W.A., Yi, A., Simmerman, L., Russell, D., Martin, D., Lapchak, P.A., Collins, F., Hoffer, B.J. & Gerhardt, G.A. (1996) Functional recovery in parkinsonian monkeys treated with GDNF. *Nature*, 380, 252-255.
- Gill, S.S., Patel, N.K., Hutton, G.R., O'Sullivan, K., McCarter, R., Bunnage, M., Brooks, D.J., Svendsen, C.N. & Heywood, P. (2003) Direct brain infusion of glial cell line-derived neurotrophic factor in Parkinson disease. *Nat Med*, 9, 589-595.

- Grondin, R., Zhang, Z., Yi, A., Cass, W.A., Maswood, N., Andersen, A.H., Elsberry, D.D., Klein, M.C., Gerhardt, G.A. & Gash, D.M. (2002) Chronic, controlled GDNF infusion promotes structural and functional recovery in advanced parkinsonian monkeys. *Brain*, 125, 2191-2201.
- Group, B.D.W. (2001) Biomarkers and surrogate endpoints: Preferred definitions and conceptual framework\*. *Clin Pharmacol Ther*, 69, 89-95.
- Hardy, P.A., Gash, D., Yokel, R., Andersen, A., Ai, Y. & Zhang, Z. (2005) Correlation of R2 with total iron concentration in the brains of rhesus monkeys. *J Magn Reson Imaging*, 21, 118-127.
- Honey, G. & Bullmore, E. (2004) Human pharmacological MRI. *Trends Pharmacol Sci*, 25, 366-374.
- Hornykiewicz, O. & Kish, S.J. (1987) Biochemical pathophysiology of Parkinson's disease. *Adv Neurol*, 45, 19-34.
- Hoshi, H., Kuwabara, H., Leger, G., Cumming, P., Guttman, M. & Gjedde, A. (1993) 6-[18F]fluoro-L-dopa metabolism in living human brain: a comparison of six analytical methods. *J Cereb Blood Flow Metab*, 13, 57-69.
- Hubble, J.P. (2000) Pre-clinical studies of pramipexole: clinical relevance. *Eur J Neurol*, 7 Suppl 1, 15-20.
- Jenkins, B.G., Sanchez-Pernaute, R., Brownell, A.L., Chen, Y.C. & Isacson, O. (2004) Mapping dopamine function in primates using pharmacologic magnetic resonance imaging. *J Neurosci*, 24, 9553-9560.
- Katzenschlager, R. & Lees, A.J. (2004) Olfaction and Parkinson's syndromes: its role in differential diagnosis. *Curr Opin Neurol*, 17, 417-423.
- Kordower, J.H., Emborg, M.E., Bloch, J., Ma, S.Y., Chu, Y., Leventhal, L., McBride, J., Chen, E.Y., Palfi, S., Roitberg, B.Z., Brown, W.D., Holden, J.E., Pyzalski, R., Taylor, M.D., Carvey, P., Ling, Z., Trono, D., Hantraye, P., Deglon, N. & Aebischer, P. (2000) Neurodegeneration prevented by lentiviral vector delivery of GDNF in primate models of Parkinson's disease. *Science*, 290, 767-773.
- Lang, A.E., Gill, S., Patel, N.K., Lozano, A., Nutt, J.G., Penn, R., Brooks, D.J., Hotton, G., Moro, E., Heywood, P., Brodsky, M.A., Burchiel, K., Kelly, P., Dalvi, A., Scott, B., Stacy, M., Turner, D., Wooten, V.G., Elias, W.J., Laws, E.R., Dhawan, V., Stoessl, A.J., Matcham, J., Coffey, R.J. & Traub, M. (2006) Randomized controlled trial of intraputamenal glial cell line-derived neurotrophic factor infusion in Parkinson disease. *Ann Neurol*, 59, 459-466.
- Langston, J.W. & Ballard, P.A., Jr. (1983) Parkinson's disease in a chemist working with 1-methyl-4-phenyl-1,2,5,6-tetrahydropyridine. *N Engl J Med*, 309, 310.
- Luan, L., Ding, F., Ai, Y., Andersen, A., Hardy, P., Forman, E., Gerhardt, G.A., Gash, D.M., Grondin, R. & Zhang, Z. (2008) Pharmacological MRI (phMRI) monitoring of treatment in hemiparkinsonian rhesus monkeys. *Cell Transplant*, 17, 417-425.
- Marsden, C.D. & Obeso, J.A. (1994) The functions of the basal ganglia and the paradox of stereotaxic surgery in Parkinson's disease. *Brain*, 117 ( Pt 4), 877-897.
- Nguyen, T.V., Brownell, A.L., Iris Chen, Y.C., Livni, E., Coyle, J.T., Rosen, B.R., Cavagna, F. & Jenkins, B.G. (2000) Detection of the effects of dopamine receptor supersensitivity using pharmacological MRI and correlations with PET. *Synapse*, 36, 57-65.
- Nicklas, W.J., Youngster, S.K., Kindt, M.V. & Heikkila, R.E. (1987) MPTP, MPP+ and mitochondrial function. *Life Sci*, 40, 721-729.
- Ovadia, A., Zhang, Z. & Gash, D.M. (1995) Increased susceptibility to MPTP toxicity in middle-aged rhesus monkeys. *Neurobiol Aging*, 16, 931-937.
- Pavese, N. & Brooks, D.J. (2009) Imaging neurodegeneration in Parkinson's disease. *Biochim Biophys Acta*, 1792, 722-729.

- Rasmussen Jr, I. (2010) Psychopharmacological MRI. *Acta Neuropsychiatrica*, 22, 38-39.
- Ravina, B., Eidelberg, D., Ahlskog, J.E., Albin, R.L., Brooks, D.J., Carbon, M., Dhawan, V., Feigin, A., Fahn, S., Guttman, M., Gwinn-Hardy, K., McFarland, H., Innis, R., Katz, R.G., Kieburtz, K., Kish, S.J., Lange, N., Langston, J.W., Marek, K., Morin, L., Moy, C., Murphy, D., Oertel, W.H., Oliver, G., Palesch, Y., Powers, W., Seibyl, J., Sethi, K.D., Shults, C.W., Sheehy, P., Stoessl, A.J. & Holloway, R. (2005) The role of radiotracer imaging in Parkinson disease. *Neurology*, 64, 208-215.
- Richardson, J.R., Caudle, W.M., Guillot, T.S., Watson, J.L., Nakamaru-Ogiso, E., Seo, B.B., Sherer, T.B., Greenamyre, J.T., Yagi, T., Matsuno-Yagi, A. & Miller, G.W. (2007) Obligatory role for complex I inhibition in the dopaminergic neurotoxicity of 1-methyl-4-phenyl-1,2,3,6-tetrahydropyridine (MPTP). *Toxicol Sci*, 95, 196-204.
- Schuff, N. (2009) Potential role of high-field MRI for studies in Parkinson's disease. *Mov Disord*, 24 Suppl 2, S684-690.
- Seibyl, J., Jennings, D., Tabamo, R. & Marek, K. (2005) The role of neuroimaging in the early diagnosis and evaluation of Parkinson's disease. *Minerva Med*, 96, 353-364.
- Slevin, J.T., Gerhardt, G.A., Smith, C.D., Gash, D.M., Kryscio, R. & Young, B. (2005) Improvement of bilateral motor functions in patients with Parkinson disease through the unilateral intraputaminial infusion of glial cell line-derived neurotrophic factor. *J Neurosurg.*, 102, 216-222.
- Smith, S.M., Jenkinson, M., Johansen-Berg, H., Rueckert, D., Nichols, T.E., Mackay, C.E., Watkins, K.E., Ciccarelli, O., Cader, M.Z., Matthews, P.M. & Behrens, T.E. (2006) Tract-based spatial statistics: voxelwise analysis of multi-subject diffusion data. *Neuroimage*, 31, 1487-1505.
- Smith, S.M., Jenkinson, M., Woolrich, M.W., Beckmann, C.F., Behrens, T.E., Johansen-Berg, H., Bannister, P.R., De Luca, M., Drobnjak, I., Flitney, D.E., Niazy, R.K., Saunders, J., Vickers, J., Zhang, Y., De Stefano, N., Brady, J.M. & Matthews, P.M. (2004) Advances in functional and structural MR image analysis and implementation as FSL. *Neuroimage*, 23 Suppl 1, S208-219.
- Snow, B.J., Tooyama, I., McGeer, E.G., Yamada, T., Calne, D.B., Takahashi, H. & Kimura, H. (1993) Human positron emission tomographic [18F]fluorodopa studies correlate with dopamine cell counts and levels. *Ann Neurol*, 34, 324-330.
- Snow, B.J., Vingerhoets, F.J., Langston, J.W., Tetud, J.W., Sossi, V. & Calne, D.B. (2000) Pattern of dopaminergic loss in the striatum of humans with MPTP induced parkinsonism. *J Neurol Neurosurg Psychiatry*, 68, 313-316.
- Thiel, C.M. (2009) Neuropharmacological fMRI. *Neuropharmacologisches fMRT*, 40, 233-238.
- Tomac, A., Lindqvist, E., Lin, L.F., Ogren, S.O., Young, D., Hoffer, B.J. & Olson, L. (1995) Protection and repair of the nigrostriatal dopaminergic system by GDNF in vivo. *Nature*, 373, 335-339.
- Tracey, I. (2001) Prospects for human pharmacological functional magnetic resonance imaging (phMRI). *J Clin Pharmacol*, Suppl, 21S-28S.
- Wu, Y., Le, W. & Jankovic, J. (2011) Preclinical Biomarkers of Parkinson Disease. *Arch Neurol*, 68, 22-30.
- Zhang, Z., Andersen, A., Grondin, R., Barber, T., Avison, R., Gerhardt, G. & Gash, D. (2001) Pharmacological MRI mapping of age-associated changes in basal ganglia circuitry of awake rhesus monkeys. *Neuroimage*, 14, 1159-1167.
- Zhang, Z., Andersen, A.H., Ai, Y., Loveland, A., Hardy, P.A., Gerhardt, G.A. & Gash, D.M. (2006) Assessing nigrostriatal dysfunctions by pharmacological MRI in parkinsonian rhesus macaques. *Neuroimage*, 33, 636-643.





## **Diagnostics and Rehabilitation of Parkinson's Disease**

Edited by Dr. Juliana Dushanova

ISBN 978-953-307-791-8

Hard cover, 528 pages

**Publisher** InTech

**Published online** 07, December, 2011

**Published in print edition** December, 2011

Diagnostics and Rehabilitation of Parkinson's Disease presents the most current information pertaining to news-making topics relating to this disease, including etiology, early biomarkers for the diagnostics, novel methods to evaluate symptoms, research, multidisciplinary rehabilitation, new applications of brain imaging and invasive methods to the study of Parkinson's disease. Researchers have only recently begun to focus on the non-motor symptoms of Parkinson's disease, which are poorly recognized and inadequately treated by clinicians. The non-motor symptoms of Parkinson's disease have a significant impact on patient quality of life and mortality and include cognitive impairments, autonomic, gastrointestinal, and sensory symptoms. In-depth discussion of the use of imaging tools to study disease mechanisms is also provided, with emphasis on the abnormal network organization in parkinsonism. Deep brain stimulation management is a paradigm-shifting therapy for Parkinson's disease, essential tremor, and dystonia. In the recent years, new approaches of early diagnostics, training programmes and treatments have vastly improved the lives of people with Parkinson's disease, substantially reducing symptoms and significantly delaying disability. Written by leading scientists on movement and neurological disorders, this comprehensive book should appeal to a multidisciplinary audience and help people cope with medical, emotional, and practical challenges.

### **How to reference**

In order to correctly reference this scholarly work, feel free to copy and paste the following:

Jorge E. Quintero, Xiaomin Wang and Zhiming Zhang (2011). Developing an MRI-Based Biomarker for Early Diagnosis of Parkinson's Disease, *Diagnostics and Rehabilitation of Parkinson's Disease*, Dr. Juliana Dushanova (Ed.), ISBN: 978-953-307-791-8, InTech, Available from:  
<http://www.intechopen.com/books/diagnostics-and-rehabilitation-of-parkinson-s-disease/developing-an-mri-based-biomarker-for-early-diagnosis-of-parkinson-s-disease>

**INTeCH**  
open science | open minds

### **InTech Europe**

University Campus STeP Ri  
Slavka Krautzeka 83/A  
51000 Rijeka, Croatia  
Phone: +385 (51) 770 447  
Fax: +385 (51) 686 166

### **InTech China**

Unit 405, Office Block, Hotel Equatorial Shanghai  
No.65, Yan An Road (West), Shanghai, 200040, China  
中国上海市延安西路65号上海国际贵都大饭店办公楼405单元  
Phone: +86-21-62489820  
Fax: +86-21-62489821

[www.intechopen.com](http://www.intechopen.com)



IntechOpen

IntechOpen

© 2011 The Author(s). Licensee IntechOpen. This is an open access article distributed under the terms of the [Creative Commons Attribution 3.0 License](https://creativecommons.org/licenses/by/3.0/), which permits unrestricted use, distribution, and reproduction in any medium, provided the original work is properly cited.

IntechOpen

IntechOpen