

We are IntechOpen, the world's leading publisher of Open Access books Built by scientists, for scientists

6,900

Open access books available

186,000

International authors and editors

200M

Downloads

Our authors are among the

154

Countries delivered to

TOP 1%

most cited scientists

12.2%

Contributors from top 500 universities



WEB OF SCIENCE™

Selection of our books indexed in the Book Citation Index
in Web of Science™ Core Collection (BKCI)

Interested in publishing with us?
Contact book.department@intechopen.com

Numbers displayed above are based on latest data collected.
For more information visit www.intechopen.com



Video-Assisted Gastrostomy in Children

Torbjörn Backman, Malin Mellberg, Helén Sjöwie,
Magnus Anderberg and Einar Arnbjörnsson

*Department of Pediatric Surgery, Skåne University Hospital, Lund and Lund University
Sweden*

1. Introduction

A gastrostomy is frequently used as an alternative to a nasogastric tube in children who are unable to manage normal oral feeding for a long time and in whom the nasogastric tube causes respiratory or other problems. Gastrostomy tube placement is associated with frequent postoperative complications and considerable help from the emergency department and outpatient clinic is required for children with gastrostomy tubes.

The history of gastrostomy, from the first known publications through its surgical evolution, is thoroughly described in a previous publication (Gauderer & Stellato, 1986). This work summarizes the different operative procedures that have been described for operatively performing a gastrostomy. These include the time-honored open surgical methods and the more recently introduced minimal invasive methods for gastrostomy. The publication ended with the introduction in 1979 of the percutaneous endoscopic gastrostomy (PEG) procedure (Gauderer et al., 1980). It has been named the world's first natural orifice trans-luminal endoscopic surgery (NOTES). The video-assisted or laparoscopic technique, that was developed before 1990 and entered the scene on a broad scale after 1990, has since then become firmly established and is still widely used.

The PEG method is cheap, fast, and easy to perform but has serious flaws. A shortcoming with the method is that it does not take into account the consequences of the blind puncture through the abdominal cavity and hampers the safety of the child subjected to an operative intervention for a gastrostomy button placement. The serious complications with the PEG procedures in children are well documented and are mainly related to the blind puncture of the abdominal wall (Gauderer, 1991, 2001; Khattak et al., 1998; Kimber et al., 1998; Lantz et al., 2009, 2010) with a risk of perforation of internal organs, bleeding, obstruction or development of a gastroenteric fistula in up to 3.5% (Lantz et al., 2009, 2010; Patwardhan, 2004) of the children.

In order to avoid the complications associated with PEG, the laparoscopy or video-assisted gastrostomy (VAG) technique was developed and used since soon after 1990 (Anderson et al., 1997; Mikaelsson et al., 1995). Laparoscopy reduces the risk of unnoticed intra-abdominal injury and allows for the exact positioning of the gastrostomy site on the stomach as well as on the abdominal wall. Suture of the stomach to the anterior abdominal wall decreases the risk of dislodgement. Placement of a primary low profile gastrostomy button eliminates the need for anesthesia later when changing the gastrostomy device used when performing the PEG technique. The VAG technique may be more technically demanding but

is mastered by surgeons today. Furthermore, the VAG technique is more time consuming and may be more expensive. The safety of the children is well worth more time and cost. With time, evidence of the greater safety of the video-assisted technique as compared with the PEG technique has been repeatedly proved and collected in reports (Lantz et al., 2009, 2010) Table 1. Laparoscopy-aided gastrostomy has been found to be a significantly safer procedure than PEG (Aprahamian et al., 2006; Fanelli & Ponsky, 1992; Jones et al., 2007; Kellnar et al., 1999; Rothenberg el al., 1999; Tomicic el al., 2002; Zanakshary el al., 2005;).

	Percutaneous Endoscopic Gastrostomy PEG	Video- Assisted Gastrostomy VAG	Statistics Method: Fisher's Exact Test
Number of children reported, n = 3441	2599	842	
Number of gastrointestinal complications	40 (1.54%)	0	p < 0.001
Number of publications, total: 48, and four publications reported both PEG and VAG	28	16	

Table 1. A summary of the reports in the literature describing complications after minimally invasive gastrostomy in children using Percutaneous Endoscopic Gastrostomy (PEG) or Video-Assisted Gastrostomy (VAG) or laparoscopic gastrostomy. Abstract presented in EUPSA + BAPS Common Congress in Graz, Austria in 17-20 June 2009 (Lantz et al., 2009)

1.1 Indications

The indications for a gastrostomy are nutritional problems in severely ill or neurologically impaired children. Gastrostomy feeding is advocated if nasogastric feeding is likely to persist for more than 6 months (Behrens et al., 1997; Norton et al., 1996). The operation should be carried out only when it is considered that the child’s condition would safely allow surgical intervention and when the need for nutritional support is considered necessary for more than 6 months. The VAG procedure is not performed prophylactically.

1.2. Work up

The work up includes an upper GI X- ray to rule out gastric outlet obstruction, hiatal hernia or some gastro-intestinal anomalies. A gastric emptying scan can reveal any gastric emptying problem. All patients should be clinically evaluated for gastro esophageal reflux disease (GERD) before the gastrostomy placement. An endoscopy and 24 h pH measurements should be performed whenever considered necessary. Impedance measurement can be considered especially in younger children with no acid gastro esophageal reflux, in order to evaluate the volume of vomiting and regurgitation into the esophagus and to rule out the indications for surgery for GER. Gastrostomy operations may be performed on children without being influenced by the child’s state of nutrition. This has been motivated by the idea that a gastrostomy would

enable fast and secure improvement in the state of nutrition. However, since there is a report on a significant correlation between the child's state of nutrition and the postoperative complications during the first six postoperative months, a routine of nutritional evaluation and support through a nasogastric tube should be considered prior to performing a gastrostomy operation (Backman et al., 2009).

2. The method

The method now used is described here (Backman et al., 2010).

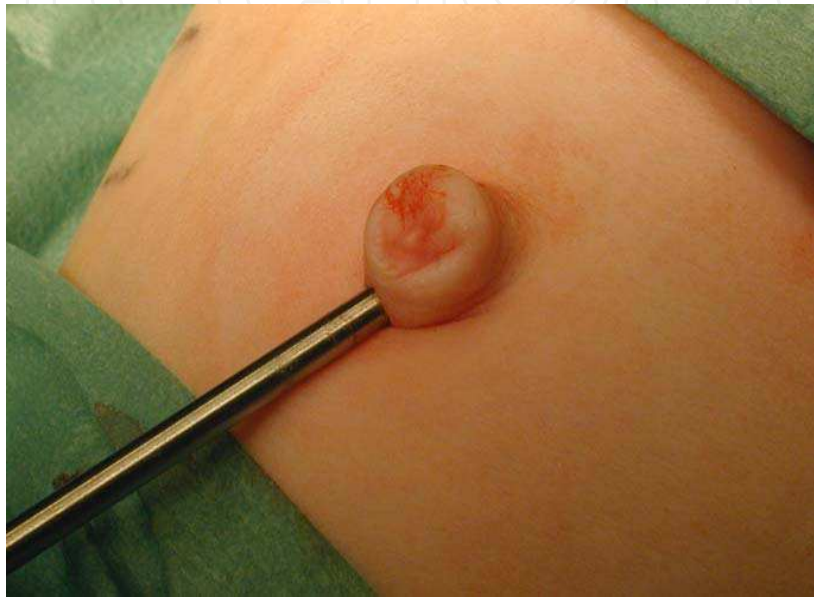


Fig. 1. Two, three or five millimeters trocar is introduced by a mini laparotomy through the umbilicus

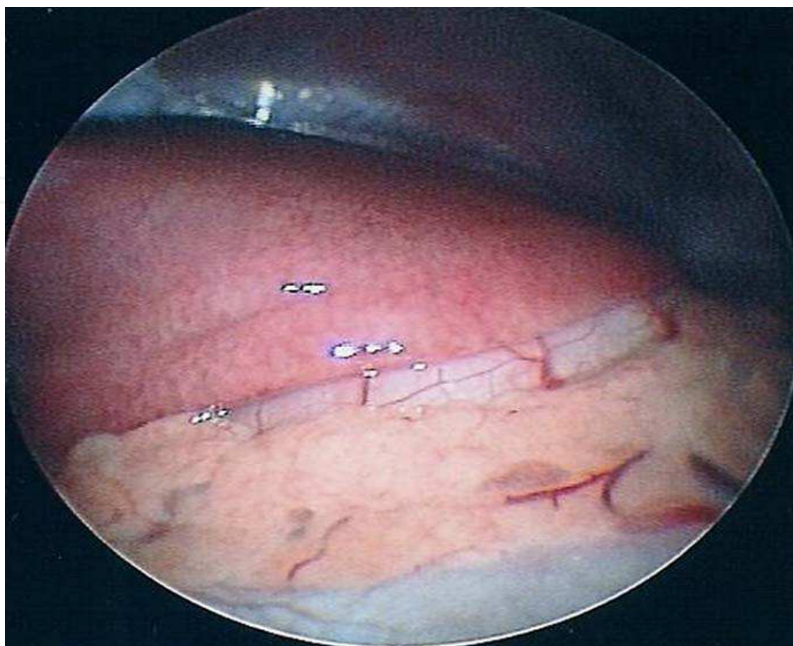


Fig. 2. The stomach is seen under the liver

Prophylactic antibiotics were given prior the operative intervention. All operations were performed under general and local anesthesia. The method of VAG is described in several variations (Mikaelsson et al., 1995; Mikaelsson & Arnbjörnsson, 1998). A 2 to 5 mm trocar is inserted by performing a mini laparotomy through the umbilicus, Figure 1. The abdomen is insufflated with CO₂ up to a pressure of 8 - 10 mmHg at a flow rate of 0.5 - 1.5 l / min. In order to visualize the abdominal cavity a 2 to 5 mm, 0 ° or 30 ° laparoscope optic is used, Figures 2 and 3.

A site for the gastrostomy is chosen approximately at the midpoint from the left costal margin to the umbilicus, through the left rectus muscle, and far enough from the costal margin to ensure that the button does not ride against cartilage when the abdomen is desufflated. At that site, a single 5 mm trocar is placed. Through the trocar, a grasper is passed and used under direct vision to catch the stomach wall at the site selected for the gastrostoma, Figure 4. The grasping site needs to be far enough away from the pylorus to prevent gastric outlet obstruction by the intraluminal balloon on the button, especially in small infants. The stomach wall is then exteriorized when the trocar and the instrument are withdrawn, Figures 5 and 6. If necessary, a clamp is used to mildly dilate the tract. In patients with a thicker abdominal wall, this procedure may be more difficult and the incision may have to be enlarged to allow adequate access to the stomach.

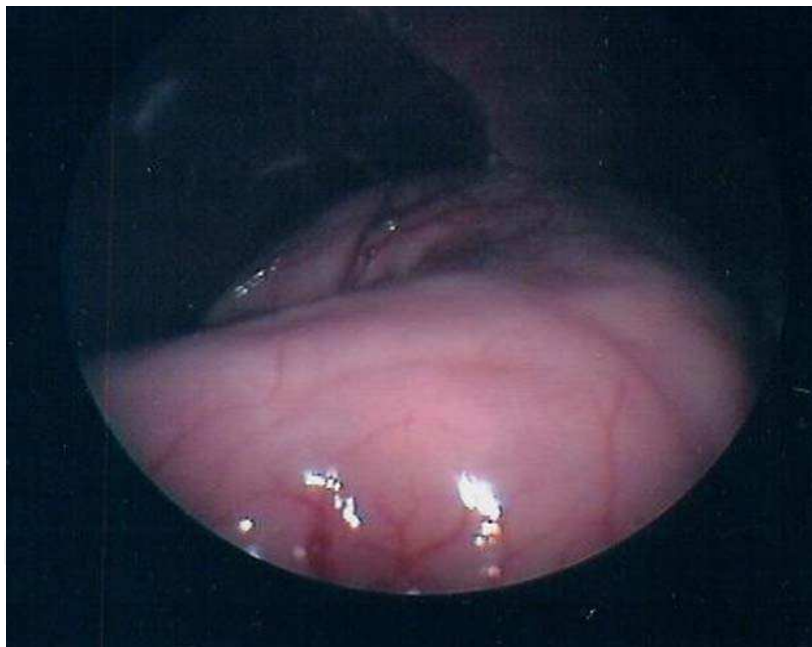


Fig. 3. When the liver is lifted up the stomach is visualized

With the grasper holding the stomach wall, a needle with an absorbable suture is inserted through the abdominal wall, beginning through a small incision half a centimeter from the gastrostoma, Figure 7. The suture is passed through the abdominal wall and then the anterior wall of the stomach and visualized using either the video-scope or under direct vision on the abdominal wall. The suture is then pulled up through the abdominal wall on the contra lateral side half a centimeter from the gastrostoma. The needle is then turned 180 degrees and the procedure repeated, passing the suture back through the two small incisions on each side of the gastrostoma and the stomach, Figure 8. Thus, the stomach is fixated to the abdominal wall with two continuous double U-stitches forming a purse string

suture on the stomach wall around the gastrostoma in the center of the loop. To facilitate placement of this suture, the retracted stomach is returned into the abdomen to allow greater exposure of the fascia. It is important not to tighten these sutures until the button is in place, since they pull the stomach back into the abdomen and close the gastrostomy.

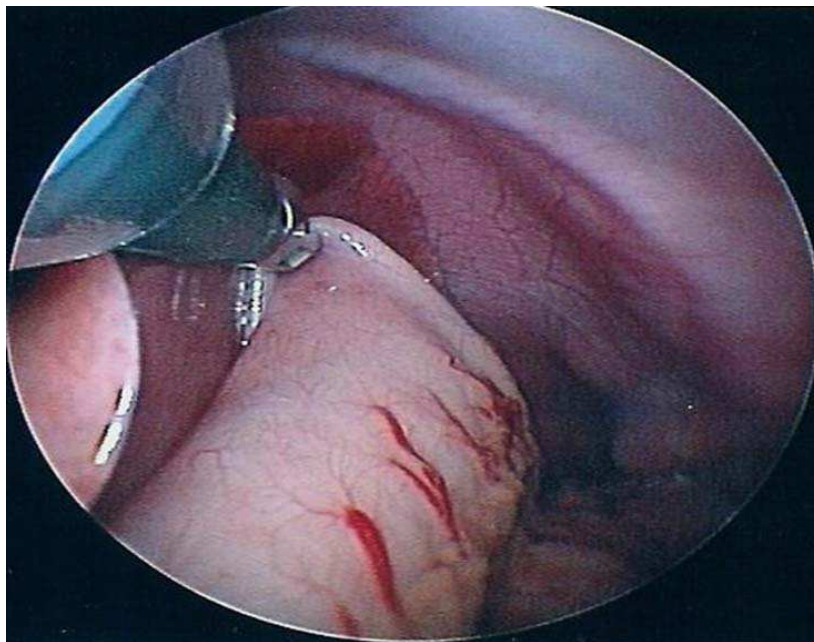


Fig. 4. Where the operating surgeon decides to place the gastrostomy on the stomach the latter is grasped with a two, three or five millimeter grasper through a trocar placed through the abdominal wall where the surgeons decide to place the gastrostomy

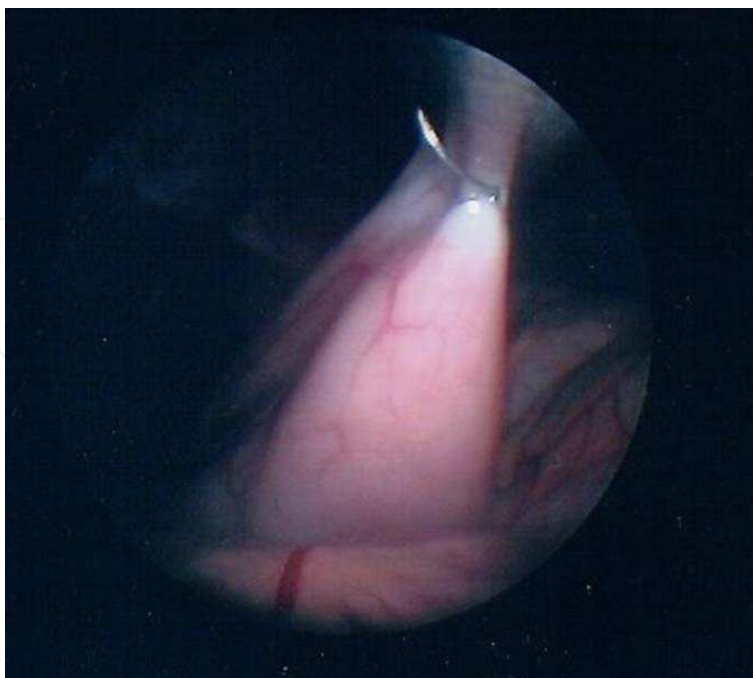


Fig. 5. The stomach wall is grasped and pulled out through the hole in the abdominal wall left when the trocar is withdrawn

After the stitches are placed, the stomach is opened with a needle diathermy or scissors and a catheter inserted, leading the button into the stomach. After measurement, an appropriately sized button (12 – 14 French 1.0- 2.0 cm) with a balloon tip is then placed through the gastrostomy. We use mainly a MicKey® gastrostomy button type (provided by Ballard Medical Product, Draper, UT, USA) or the Mini ONE™ (provided by Applied Medical Technology Inc, Breckville, OH, USA). Lubrication of the button with water may be needed to ease its placement, as the tract is usually quite snug. The suture is tightly tied and the balloon inflated with three to five cc of water. The incision is usually not sutured around the button.

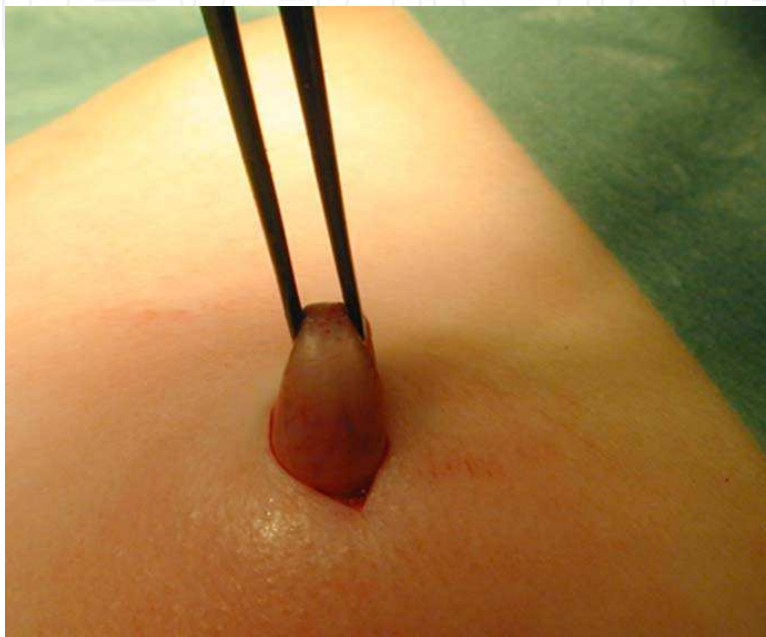

Fig. 6. The stomach wall sticking out through the abdominal wall

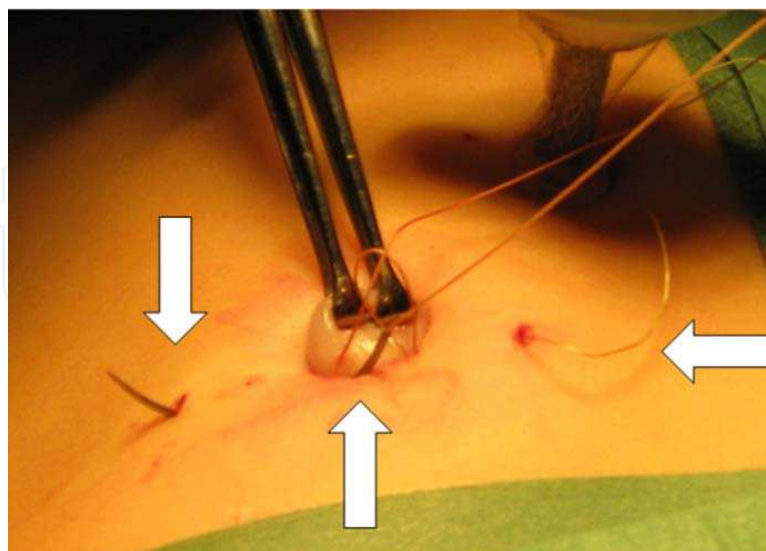


Fig. 7. A photo showing the trocar for the laparoscopy optic in the background and the right arrow pointing to the entrance for the U-stitch suture. The stomach exteriorized and held by graspers indicated by the arrow in the middle and the needle used for the suturing is sticking out as pointed out by the left arrow

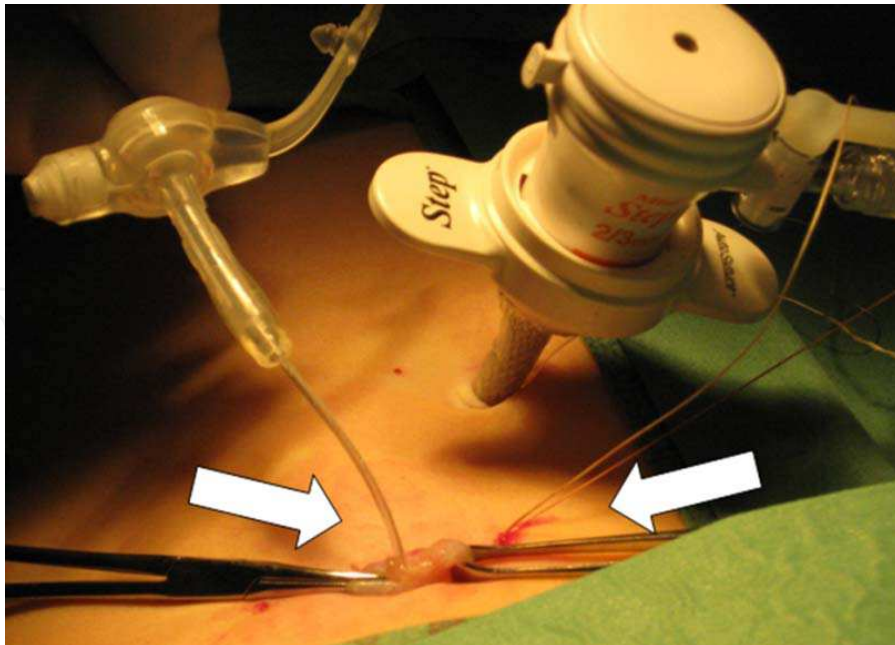


Fig. 8. The double U-stitch suture that forms a purse-string suture around the gastro stoma on the stomach, emerges from the abdomen at the place indicated by the right arrow. The left arrow indicates the stomach, which has been opened and a thin catheter has been inserted and used as a guide for the insertion of the gastrostomy button

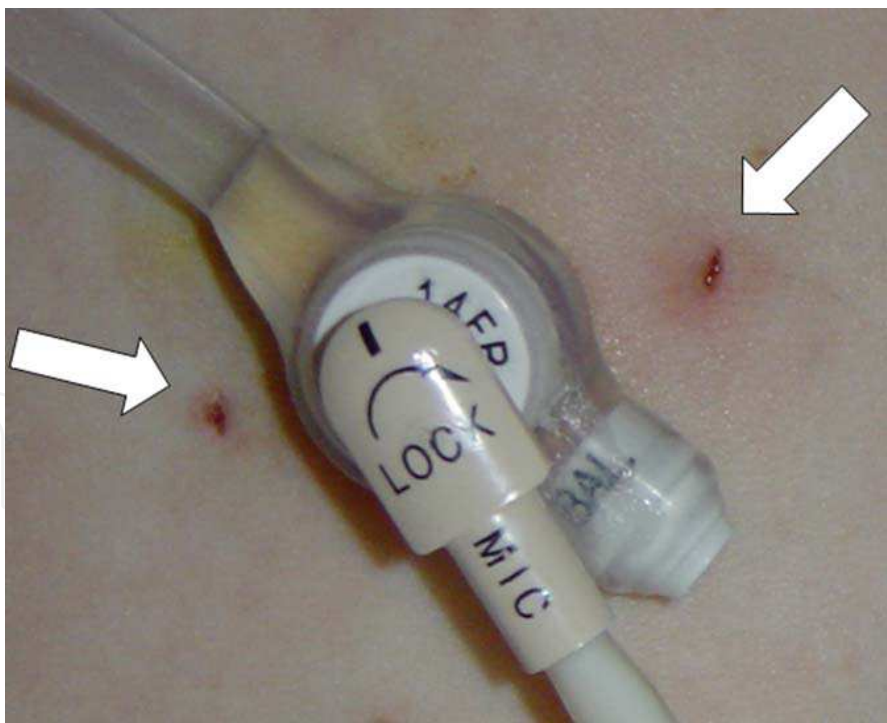


Fig. 9. The gastrostomy button in place. The arrows indicate the locations of the double U-stitch suture

The gastrostomy button in place is shown in Figure 9. On each side of the button two small wounds can be seen. These are the places of the double U-stitch holding the button in place

and forming a purse string suture around the button and the gastro stoma on the stomach. A gastroscopy is performed as the last part of the operative intervention. The view from the stomach through the gastroscopy is shown on Figure 10. The gastroscopy can verify the placement of the gastrostomy button and disclose any anomaly such as hiatal hernia or esophagitis.

Oral feeding is started as soon as the child is awake. Nutrition through the gastrostomy is usually started within 4 hours and continued with increasing amounts of fluid, as tolerated by the child. Bolus or continuous feeding is continued as preoperatively. When it is no longer needed, the gastrostomy button can be removed. We recommend a routine expectance after the removal of a gastrostomy device for at least 1 month. If no spontaneous closure occurs a gastroraphy should be performed (Arnbjörnsson et al., 2005).

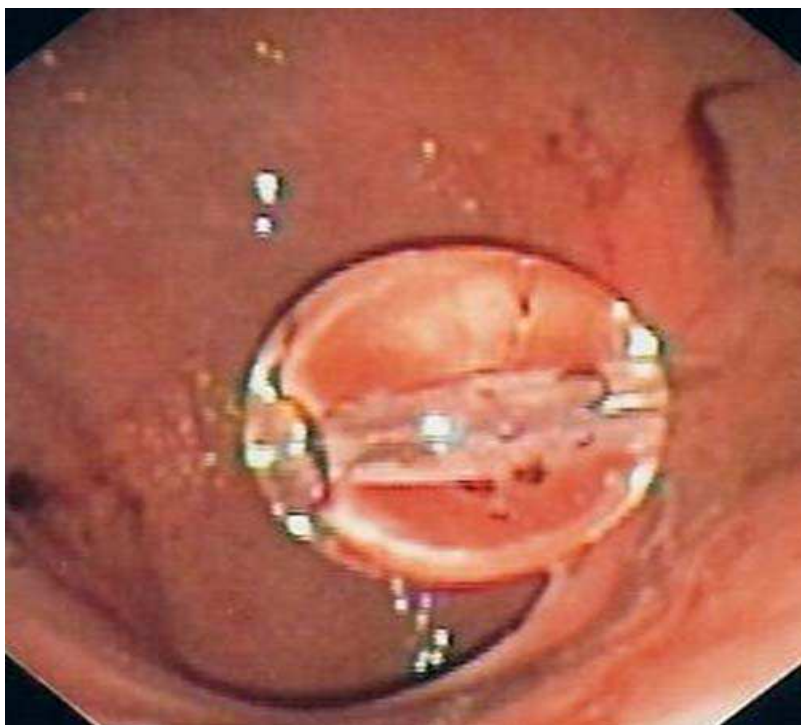


Fig. 10. A view from the gastroscopy showing the balloon on the tip of the gastrostomy button

3. Children

A prospective study was conducted on a heterogeneous group of children who underwent gastrostomy tube placement from June 2006 through February 2011 at a tertiary center for pediatric surgery. The children's comorbidities, Table 2 and demographics, Table 3 are summarized. The children's BMI (Body mass index) is demonstrated in Figure 11.

3.1 Follow-up

The endpoint of the study was six months after the surgery reached by 125 children. All the patients had contact with a dietician and all were prospectively followed up by specially trained nurses during the first postoperative days in hospital and at one and six months after the operation. Additional follow-ups were performed at any time at the request of the

child’s guardians. All postoperative complications were documented according to a standardized protocol including only those requiring treatment. The registered postoperative complications requiring treatment included:

Severe complications:

- Complications demand emergency re-operations, including bleeding, gastrointestinal fistula or intestinal obstruction.

Minor complications:

- Infectious complications treated with antibiotics and frequent changes of dressing of the wound.
- Granuloma resulting in intervention, such as cauterization or operative intervention.
- Leakage, that required further management, including a change to a new button with a different length or size, or a change of volume in the balloon of the button, or frequent, greater than two times a day, change of dressings.
- Pain around the gastrostoma after the first two postoperative days, treated with analgesics.
- Any discomfort leading to the change of device in the gastrostomy.
- The number of parents’ consultations for the child’s gastrostomy.

Diagnosis in 135 children	Number of children
Cerebral pares	43 (32%)
Cardiac malformation	25 (19%)
Epilepsy	21 (16%)
Metabolic diseases	18 (13%)
Syndrome	14 (10%)
Cerebral anomaly	12 (9%)
Malformations of the gastrointestinal tract	11 (8%)
Malignancy	8 (6%)
Respiratory insufficiency	7 (5%)
Ventricular - peritoneal shunt	5 (4%)
Mitochondrial disease	4 (3%)
Myopathia	3 (2%)

Table 2. The diagnosis and comorbidity of the included group of 135 children

Age in years	MEAN ± STD	3 ± 3
N = 135	Median (range)	2 (1 month - 14 years)
Weight in kg	MEAN ± STD	11.4 ± 7.6
	Median (range)	9.2 (3.7 - 41)
SD*	MEAN ± STD	- 2.2 ± 1.7
	Median (range)	- 2.1 (-7.1 - 1.3))
Length i cm	MEAN ± STD	82.4 ± 24.4
	Median (range)	78 (36.2 - 162)
SD*	MEAN ± STD	- 1.8 ± 1.7
	Median (range)	- 1.7 (-7.4 - 1.5)
BMI (kg/m²)	MEAN ± STD	16 ± 2
	Median (range)	15 (11 - 22)

*The individual weight and length at the time of the VAG procedure are shown and assessed by using charts for gender- and age-matched growth standard deviation (SD) scores for Swedish children. Age was approximated to age in months, and weight scores were approximated to the closest whole number in standard deviation. These figures are expressed as weight-for-age Z-scores calculated as: (actual weight-mean weight)/standard deviation (Liou et al., 2001), according to the nationally standardized weight curves (Albertsson-Wikland & Karlberg, 1994).

Table 3. The demography of the children included in the study

4. Results

One hundred and thirty five patients underwent laparoscopic-assisted gastrostomy with the double U-stitch technique and were prospectively evaluated. Three children died from their underlying disease, two after five weeks and one after six months. There were no major complications as bleeding or enteric fistulas requiring emergency reoperations. One hundred and twenty five children reached the endpoint of the study and had been followed for at least six months and were thus included in the report of the results. Granulation tissue was the most common postoperative complication, occurring in 24% of patients. Two out of three of the patients with granulation tissue had full resolution by the sixth postoperative month, Table 4. At six months postoperatively, a granuloma had developed in 11% of those without any previous granuloma, Table 5. Infection and leakage were also common. Both these minor complications decreased in frequency with time. However, even after six months none of the most usual minor complications disappeared

completely. Tube dislodgement was an uncommon complication, occurring 13 times in 125 patients (10%) and resulting in emergency department visits for replacement of the gastrostomy button under general anesthesia in 5 children less than two weeks after the gastrostomy operation, Table 4.

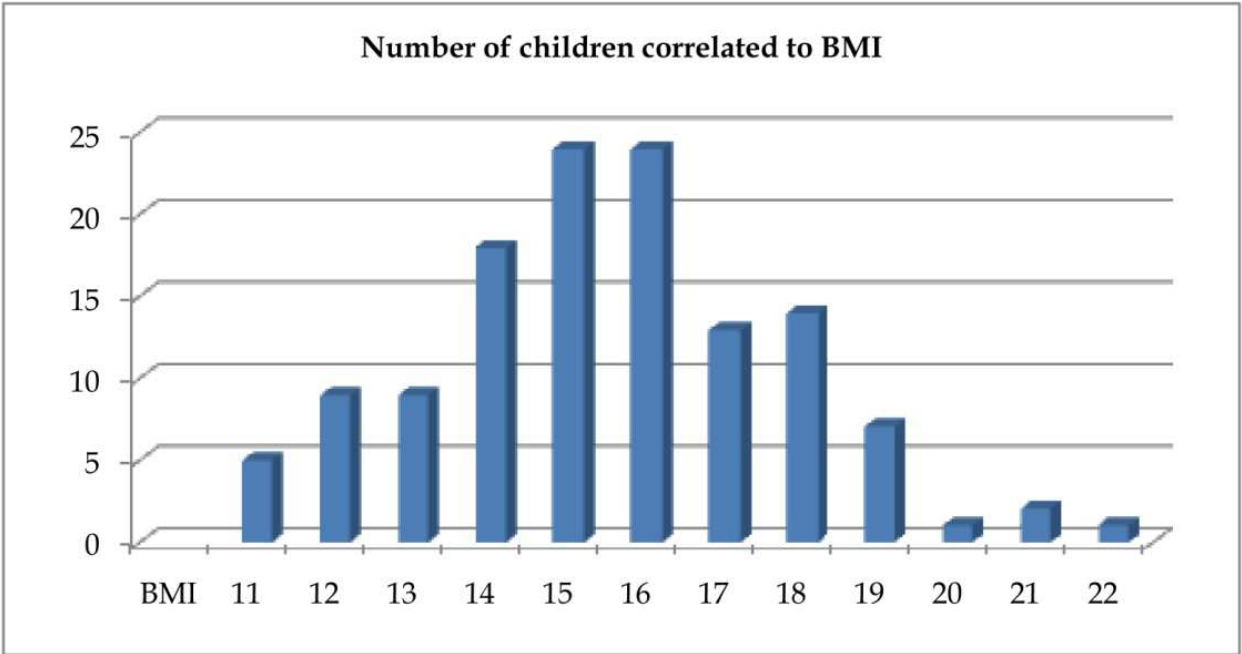


Fig. 11. The summary of the Body mass index (BMI) of the children included in the report

Minor complications	After:		Statistical method: Fisher’s exact test
n = 125	1 month	6 months	p value*
Granuloma	30 (24%)	20 (16%)	0.0365
Vomiting	29 (23%)	20 (16%)	0.2022
Infection	26 (21%)	3 (2%)	<0.0001
treated with antibiotics	20 (16%)	1 (1%)	<0,0001
Leakage	18 (14%)	4 (3%)	0,0012
Tube dislodgement	6 (5%)	7 (6%)	1

Table 4. A summary of the minor complications found at prospective follow-up in 125 out of the 135 children included

A summary of the frequency of minor complications after a video-assisted gastrostomy operation from the perspective of their fate over time is shown in Table 5. A minor complication was not always present directly postoperatively. It could occur later in the progression of the patient. This suggests that the minor complications were not only due to the insertion of the gastrostomy button, but were partly due to the child’s clinical situation during the course of their underlying disease.

Vomiting was an exception to the rule that the minor complications reduced in frequency with time Table 6. The gastrostomy operation does not significantly influence the vomiting which probably depends on the underlying disease and its progress as well as the child’s clinical situation.

Minor complications	After:		Statistical method: CHI2 TEST
N = 125	1 month	6 months	p value
Granuloma	30	10 (33%)	
- No granuloma	95	10 (11%)	< 0.0001
Infection	26	1	
- No infection	99	2	< 0.0001
Leakage	18	1	
- No leakage	102	3	< 0.0001

Table 5. Summary of the frequency of minor complications after a video-assisted gastrostomy operation from the perspective of their fate over time

Vomiting:					
Preoperatively		Postoperatively, after 6 months:			Statistical method: Mann-Whitney U test
N=125		Not vomiting	Kept on vomiting	Started vomiting	P value
Yes	29 (23%)	16 (55%)	13 (45%)	0	
No	96	89 (93%)	0	7 (7%)	0.6650

Table 6. The pre- and postoperative frequency of vomiting in patients undergoing a video-assisted gastrostomy operation

The described method used for the operation is easier the smaller the child and the thinner the abdominal wall. Therefore it was of interest to compare the infants, less than two years of age, with those who were older, with respect to postoperative complications. This comparison is summarized in Table 7 disclosing no practical differences and not suggesting that infants are less prone to postoperative complications, despite the surgeons’ impression that the operative intervention is easier with these small patients.

5. Discussion

The primary laparoscopic placement of gastrostomy buttons for feeding tubes is a safe and simple technique and the preferred method of gastrostomy in children (Aprahamian et al., 2006; Fanelli & Ponsky, 1992; Jones et al., 2007; Kellnar et al., 1999; Rothenberg el al., 1999; Tomicic el al., 2002; Zanakshary el al., 2005;). However, the results show that gastrostomy

tube placement is associated with many early and late complications as has been reported (Arnbjörnsson et al., 1999).

The complication rates with VAG in pediatric patients are reported and the subgroups of children who run the highest risk for postoperative complications have been identified. No major complications, defined as life-threatening, have so far been reported in children operated on with VAG. Minor problems including leakage, irritation, and granuloma formation were frequently noted and need care (Arnbjörnsson et al, 1998, 1999; Arnbjörnsson & Larsson, 2005; Backman et al, 2007).

5.1 The treatment of minor complications

In order to avoid the minor problems appearing postoperatively after the placement of a gastrostomy button the following measures can be taken:

- Increase the length of the gastrostomy canal by increasing the distance between two purse string sutures on the stomach wall.
- Wash the skin around the gastrostoma with chlorhexidine (Hibiscrub®) daily during the first five postoperative days.
- Reduce the movements of the gastrostomy button by leaving the feeding catheter in place and fastening it with tape onto the skin during the first five postoperative days.
- The gastrostomy button dimension has been studied and led to the conclusion that a reduction of postoperative gastrostomy site leakage may be gained with the use of gastrostomy buttons of a smaller dimension (Sjövie et al, 2010).

Solid scientific support for the most of these measures is still missing from the literature.

Minor complications	Children’s age groups				Statistical method: Fisher’s exact test
n = 125	< 2 years, n = 78		>2 years, n = 47		
Age in years, MEAN ± STD MEDIAN (range)	1 ± 1 1 (0 - 2)		6 ± 4 5 (2 - 14)		
Weight in kg, MEAN ± STD MEDIAN (range)	8 ± 3 8 (2 - 14)		20 ± 9 16 (9 - 42)		
Number of:	After		After		p value after:
	1 month	6 months	1 month	6 months	1 month/6 months
Granuloma	22	12	8	8	0.0649/0.1909
Vomiting	22	14	7	6	0.0415*/0.1536
Infection	14	2	12	1	0.1069/0.4442
Leakage	12	2	6	2	0.1945/0.3350

*The difference is not statistically significant when using the chi square test or Pearson’s test.

Table 7. Comparison of the number of minor postoperative complications between infants, < 2 years, and older children

5.2 The preoperative state of nutrition

Gastrostomy operations have been performed on children referred to the pediatric surgical clinic without any regard taken to the results of the routine evaluation of the nutritional status of the patient. This has been motivated by the idea that a gastrostomy would enable a fast and secure improvement of the patient in this regard. The question arises whether an improvement in the preoperative nutritional status would reduce the number of

postoperative complications. In a prospective registration (Backman et al., 2009) the nutritional parameters before a gastrostomy operation in a heterogeneous sample of 50 children with nutritional problems were collected. The children were followed up according to a protocol and the occurrence of postoperative complications was correlated to their nutritional status at operation. The hypothesis was that the better the patients' preoperative nutritional status, the fewer the postoperative complications. The aim was to collect information that can be used to improve the practice when performing gastrostomy operations in children, thus increasing the quality of the work as well as improving safety when performing a gastrostomy operation in cases where it is needed.

The routine preoperative evaluation of the children's nutritional status included laboratory tests, as well as weight and length. The age-adjusted Z-score of weight and length to normalize the data relative to a reference population was used. These figures are expressed as weight-for-age Z-scores calculated as: (actual weight-mean weight)/standard deviation (Liou et al., 2001), according to the nationally standardized weight curves (Albertsson-Wikland & Karlberg, 1994). The children were ranked according to the frequency and severity of these postoperative problems up to six months after the gastrostomy operation which was the endpoint of the study. The results disclosed that there was a significant correlation between the frequency of postoperative problems and the low Z-score for weight and length as well as for low phosphate, magnesium and iron levels in the blood at the time of the operation. The results support the necessity of preoperative nutrition evaluation and treatment before a video-assisted gastrostomy operation. These findings are influenced by the fact that the children included had already had a period of treatment and care, and been given a sufficient amount of nutrition through a naso-gastric tube or intravenous nutritional support. The diet anamnesis was intended to be included. However, when this was to be registered, the dietitian had already met the patient and for a while administered the amount of nutrition considered necessary for the child's age and weight. The children under one year of age usually received 100 – 120 kcal/kg/day. The older children received Kcal according to the formula: $\text{Kcal/kg/day} = 95 - (3 \times \text{ages in years})$, or more when considered necessary. Thus the children's problems were failure to thrive due to complex medical issues and not malnutrition. Therefore, this parameter could not be used. Preoperatively, all the children had had a nasogastric tube for feeding while waiting for the operative intervention to provide the child with a gastrostomy. The latter took place within six weeks from the time when the decision to operate was taken. In spite of this treatment, the difference in the children's nutrition status correlated with the frequency and severity of the postoperative complications. The preoperative intake of nutrition was, in all the patients, considered sufficient for the child's age and weight, and took into account the increased need seen in some patient groups, i.e. children with congenital cardiac anomalies who are in need of up to 40% more nutrition than other children of the same age and weight. Therefore the Z-scores used are not any direct marker of malnutrition, but are more a reflection of a failure to thrive. Postoperatively, no changes were made in the amount of nutrition the child had been given preoperatively.

During the period studied there were no children with tracheostomies. These are well known to have considerable problems with their gastrostomies; the greater effort required to breathe leads to increased abdominal pressure and subsequently more leakage around the gastrostomy tube. The rate of serious complications in this group of patients is lower than that previously reported for PEG or standard Stamm gastrostomies, which is as high as 40% (Rothenberg et al., 1999). The most serious complications were wound infections that,

in this series of patients, were resolved with oral antibiotics or just frequent changes of dressing.

The study revealed a significant correlation between the patients' state of nutrition and the postoperative complications during the first six postoperative months. Thus, the findings bear out a routine of nutritional evaluation and support prior to performing a gastrostomy operation.

5.3 Video-assisted gastrostomy in infants of less than one year of age

The experience with the VAG technique in infants operated on during their first year of life encourages the use of VAG as a safe technique to provide a route for long-term nutritional support even in such young infants (Backman et al, 2005). Aspiration and chest infections, as well as reduction in feeding time and parents' stress are the major reasons for direct enteral feeding using either a nasogastric tube or gastrostomy (Haynes L et al., 1996; Heine et al., 1995). The gastrostomy feeding regimen provides adequate nutrition to promote normal growth and development and supports the increased or special requirements for those patients with an underlying disease condition.

To analyze the nutritional consequences of gastrostomy in infants operated on during their first year of life, an age-adjusted Z-score (Albertsson-Wikland & Karlberg, 1994) was used to normalize the data in relation to a reference population. The body weight was recorded on the day before the operation and at follow-up 6 months later. The weights at operation and at follow-up were compared using the age-adjusted Z-score of weight as describes in the text in Table 3. No corrections were made for prematurity. If the Z-score of weight after operation is higher than before, it indicates an accelerated weight gain i.e. catch-up. The study (Backman et al, 2005) comprised a consecutive series of 53 severely disabled infants aged six months, varying from three weeks to 11 months, who underwent a video-assisted gastrostomy and were prospectively followed up. Included were infants with neurological dysfunction, chromosomal anomalies, metabolic disorders, cardiac anomalies or respiratory insufficiency.

The infants were followed with a scheduled control at 1 and 6 months postoperatively, documenting complications and weight gain. The main outcome measure was the number and type of complications as well as weight gain using the age-adjusted Z-score of weight to normalize the data relative to a reference population. The Z-score increased significantly, illustrating the postoperative weight gain and catch-up. Short- and long-term complications included minor local wound infection, leakage around the gastrostomy tube and granuloma, but none of these were severe.

The results encourage the use of video-assisted gastrostomy as a safe technique to provide a route for long-term nutritional support even in infants less than one year of age. The present study did not reveal any difference between infants less than two years of age, and older children with respect to minor postoperative complications. As in other reports we found an improvement in the patients' nutritional status after supplementary enteral feeding via gastrostomy (Andersson et al., 1997; Chang et al., 2003), in spite of the fact that the children were preoperatively fed by a nasogastric tube. The complication rate was lower than that reported by others in the literature for both PEG and surgical gastrostomy (Gauderer, 1991; Grant, 1988; Haws et al., 1966; Hogan et al., 1986; Kimber et al., 1998; Larson et al., 1987; Marin et al., 1994; Patwardhan et al., 2004). Gastro-colic fistulas, bleeding, leakage to the peritoneal cavity, peritonitis, dislodgement or occlusion of the gastrostomy button were not seen. The problems met by the infants and their parents are scarcely reported in the

literature, although they are well known and often seen after a surgical gastrostomy or PEG. These problems, albeit not life-threatening, affect the lives of the infants and their families; they should be taken into account in patient counseling and when discussing the need for a gastrostomy for each individual patient.

The procedure was well tolerated by all the children younger than one year (Backman et al, 2005). No mortality was related to the video-assisted gastrostomy placement. Four infants died of underlying diseases later. Two patients died of intracranial bleeding, one with an astrocytoma and one with a progressive neurological disease. Two died of circulatory failure, one due to a constrictive cardiomyopathy and one due to a cardiac anomaly. There were no deaths related to gastro-oesophageal reflux or pneumonia.

When correlating the incidence of complications in this group of infants (Backman et al, 2005) with different groups of diagnosis, there was no significant difference found between the groups. This is not in agreement with previous reports on 98 children, 0–18 years, where children with congenital heart disease, chronic respiratory failure and metabolic diseases were found to experience the highest rate of minor postoperative complications (Arnbjornsson et al., 1999). Using the method described here as well as the open surgical procedure, the gastrostomy button is put in place directly, eliminating the need for a later change to a gastrostomy button as is the case after a PEG, where this is usually done after 3–6 weeks (Marin et al., 1994). The results encourage the use of video-assisted gastrostomy as a long-term route for safe and effective nutritional support even in children less than one year of age. This is supported by the findings in the present report comparing children younger than two years and those who were older, Table 7.

5.4 Gastro-oesophageal reflux (GER) before and after a video-assisted gastrostomy

Vomiting was a problem before and after a VAG operation in 23% of the children reported here, Table 6. GER has been described as a frequent complication of surgical gastrostomy (Hament et al., 2001; Isch et al., 1997; Launay et al., 1996; Samuel & Holmes, 2002; Doyle & Kennedy 1994; Gottrand & Michaud, 2002). Three prospective studies used 24-h pH monitoring before and after a gastrostomy performed with the percutaneous endoscopic technique (PEG) (Launay et al., 1996; Razeghi et al., 2002; Samuel & Holmes, 2002). In one study (Razeghi et al., 2002) the localization of a PEG-catheter in the antrum of the stomach caused an increase in GER. In an animal study the localization of the gastrostomy to the lesser curvature was associated with a reduced incidence of GER. The ambition was to localize the gastrostomy button at the lesser curvature well above the antrum on the anterior wall of the stomach, thereby reducing the angle of His and increasing the intraabdominal length of the oesophagus (Seekri et al., 1991).

Although gastroesophageal reflux (GER) has been described as a frequent complication of surgical gastrostomy, available data concerning GER and gastrostomy have been conflicting, possibly because of different study designs (Hament et al., 2001; Isch et al., 1997; Launay et al., 1996; Razeghi et al., 2002; Samuel & Holmes, 2002). The risk of developing a gastro esophageal reflux (GER) after a gastrostomy operation is reported. When studying the frequency of GER after VAG the authors concluded that a gastrostomy using the video-assisted technique and placing the stoma on the anterior wall of the stomach close to the lesser curvature does not cause aggravation of acid reflux (Plantin et al, 2006). The question of whether the addition of an antireflux procedure to the gastrostomy might promote better weight gain than a gastrostomy alone remains to be answered. A conclusive comparison is lacking. Theoretically, an antireflux operation should lead to an increase in weight by

reducing the losses of energy by vomiting the food. An antireflux operation was not performed in any of the children included in this study at the time it was performed. Vomiting was not a great concern and could be coped with by continuous feeding or frequent feeding with smaller meals. Furthermore, the children's gastroesophageal reflux problems, such as vomiting, disappeared with time and after successful reconstructive cardiac surgery in children with congenital cardiac anomalies. In these situations, an antireflux operation would have been unnecessary.

In a prospective uncontrolled study including 23 neurologically disabled children, from 10 months to 15 years of age, all with severe nutritional problems and in need of a gastrostomy, the frequency of GER pre- and postoperatively was studied (Plantin et al., 2006). The children all had a history of clinical GER problems including vomiting, choking and chest infections. A 24-h pH monitoring was used for a quantitative assessment of GER the day before surgery and 12 months (range 7–22 months) postoperatively. Before the preoperative pH investigation the naso-gastric tube was removed. A Synectics 24 antimony electrode and the DigiTrapper recording device (Medtronic Functional Diagnostics A/S, Tonsbakken, Denmark) were used for the 24-h pH monitoring. The electrode was placed fluoroscopically two vertebrae above the diaphragm according to ESPGAN criteria (Vandenplas et al., 1993). The reflux index (RI) was calculated as the percentage of time with pH below 4.

The gastrostomy was placed on the anterior wall of the stomach near the lesser curvature. The main outcome measure was the comparison of the pre- and postoperative 24-h pH monitoring and the reflux index (RI), i.e. the percentage of time with pH below 4. The results showed a no significant reduction of RI from 6.8 ± 4.5 preoperatively to 3.7 ± 2.0 postoperatively. The authors conclude that a gastrostomy using the video-assisted technique and placing the stoma on the anterior wall of the stomach close to the lesser curvature does not cause aggravation of acid reflux. During the observation period the RI decreased in 19 patients and increased in 4. Preoperative gastroscopy disclosed macroscopic oesophagitis in 10 of 23 patients whereas postoperative (7–22 months later) endoscopy performed in 21 patients showed macroscopic signs of oesophagitis in only 3. Two children were later operated on with a fundoplication due to a GER. All the patients had clinical symptoms of GER preoperatively. Two had been treated medically during a short period of 2–4 months postoperatively and at follow-up 12 months (range 7–22 months) later all the patients showed a gain in weight (from 0.6 to 3.8 kg) and regression of clinical reflux symptoms.

The slight decrease in RI in the patient group may be explained not only by the beneficial effect of the gastrostomy technique but also by physiological improvement over time. The decrease in reflux symptoms registered in the group of neurologically disabled patients could, of course, be explained by the need of these particular patients for enteral nutrition. Preoperatively, this had entailed the use of a naso-gastric tube which may have caused reflux as well as upper respiratory problems. This study does not compare the results of this method with any other technique. The important question whether one surgical approach is superior to the other remains unanswered. There is no reason to believe that the method here described is superior to the open surgical technique from the point of view of the exact placement of the gastrostomy tube. With both methods it is possible to place the tube at the same preferred place on the lesser curvature. On the other hand, using the PEG method the site of placement of the tube cannot be easily decided. In conclusion, the data suggest that there is no significant risk for accentuation of GER after a gastrostomy operation using the

laparoscopic technique as described, and that a routine performance of concomitant fundoplication cannot be recommended (Georgeson, 1993).

5.5 Gastrostomy in children with cardiac malformations

Cardiac malformations were found in 19% of the children included in this study, Table 2. This high frequency may be due to the fact that the hospital is a tertiary center for cardiac surgery on children. Malnutrition and failure to thrive is a common and well-known problem in the treatment of children with severe congenital heart disease (Mitchell et al., 1995). Three main factors contribute to malnutrition: insufficient oral intake raised metabolic demands, and malabsorption. Adequate growth improves the success of cardiac surgery and influences postoperative morbidity (Blackburn et al., 1977). Previous studies have shown that children with ventricular septal defects have 140% of normal total energy expenditure and 250% of normal energy expenditure of activity (Ackerman et al., 1998). This indicates that children with congenital heart disease may not be able to meet their elevated energy demands. Continuous nasogastric tube feeding has been successful regarding weight gain in children with congenital heart disease (Vanderhoof et al., 1982). Long-term feeding is, however, associated with several disadvantages, such as repeated tube dislocations, gastroesophageal reflux, esophagitis, aspiration, and impaired development of oromotor feeding skills (Warady et al., 1990; Strologo et al., 1997). Retrospective studies of percutaneous endoscopic gastrostomy in children with congenital heart disease have reported an increase in weight (Hofner et al., 2000; Ciotti et al., 2002).

Children with congenital heart disease are reported to have an increased risk of complications after VAG procedures compared to other subgroups of children operated on with VAG (Norén et al., 2007). The aim of that retrospective study was to study the type and frequency of complications and change in weight after a laparoscopic gastrostomy procedure in 31 children with congenital heart disease, comparing patient groups of children with univentricular and biventricular circulation, and with completed and uncompleted cardiac surgery. The main outcome measures were the body weight changes and postoperative complications during follow-up. The results disclosed that minor stoma-related problems were common in both groups. Two severe complications, dislodgements, requiring an operative intervention occurred in the univentricular circulation group. This, together with our previous results of laparoscopy-aided gastrostomy procedures in 98 children with various diseases with no major complications (Arnbjörnsson et al., 1999) might indicate that children with congenital heart disease are at a higher risk of complications than children with other diseases. This is probably more true for children with univentricular circulation, who most likely are more catabolic and, therefore, at an even higher risk of complications than other children with congenital heart disease. Weight was normal at birth, low at the time of the gastrostomy procedure, and did not catch up completely during the follow-up period of a mean of 20 months. There were no significant differences regarding mean weight gain between the groups with univentricular and biventricular circulation.

Children with congenital heart disease seem to have an increased risk of complications after laparoscopy aided gastrostomy procedures, than other children. The laparoscopy-aided gastrostomy procedure has previously been shown to have a low rate of complications and, therefore, we still recommend it to be the first method of choice for the placement of a gastrostomy in children with congenital heart disease. Although there were no significant differences, growth seemed to be slower in children with univentricular circulation as well

as those with uncompleted cardiac surgery. This suggests that the energy expenditure in these children could be higher than previously assumed. Possibly the caloric intake, 140% of normal energy expenditure, is insufficient. Further studies are needed to investigate the true energy expenditure in this group of children with severe congenital heart disease and uncompleted cardiac surgery.

5.6 Gastrostomy in children with malignancies

Nutrition in children with a malignant disease often poses serious problems. 6% of the children included in this study had a malignant disease, Table 2. The malignant disease as well as the intensive chemotherapy may result in malnutrition as it may lead to loss of appetite, food aversions, mucositis, nausea and vomiting (Mathew et al., 1996; Pedersen et al., 1999; Skolin et al., 1997). A nasogastric tube has previously been the standard method for administering enteral nutrition to a child with malignant disease who is unable to eat adequately. Tube feeding is associated with several side effects, especially pain from severe mucositis as well as infection and perforation of the esophagus (Doyle & Kennedy 1994). Parenteral nutrition carries the risk of catheter-related infections, and a lack of enteral nutrition may contribute to the passage of bacteria into the systemic circulation (Christensen et al., 1993). Surgery in children with malignancies has been uncertain regarding the relation to the timing of cytostatic drug treatment, posing several questions. Should cytostatic drugs be withheld during the week before surgery and/or the postoperative days? Is the rate of postoperative complications influenced by the immediate administration of cytostatic drugs, and is it higher than when performed in children with neurological disability?

A study was undertaken to test the hypothesis whether the administration of cytostatic drugs close to surgery in children with malignancies influences the rate of postoperative complications after a VAG procedure (Arnbjornsson et al., 2006). The study group comprised a heterogeneous group of 27 children, aged from 6 months to 18 years, with malignancies treated with cytostatic drugs and a VAG procedure. The control group consisted of 27 neurologically impaired children matched for age, sex and operative procedure, selected from a cohort of 154 patients with neurological disabilities operated on with VAG during the same period. The decision to operate did not depend on the timing of the chemotherapy. In the study group the complications were correlated to the time elapsed from completion of the last preoperative or the first postoperative cytostatic drug treatment. The number of days after finishing the last cytostatic treatment and the performance of the VAG were documented. The number of days after surgery to the start of postoperative treatment with cytostatic drugs was also documented. All complications were documented according to a special protocol and correlated to the time elapsed from the last cytostatic drug treatment before and the time of the first treatment after the operation. Significant postoperative complications requiring treatment were included only, e.g. granuloma resulting in intervention such as cauterization or extirpation, infection requiring antibiotics and external leakage demanding some form of management. The complications in the two groups were compared.

The results disclosed no difference in postoperative complications between the study group and the control group. There was no increase in postoperative complications related either to a shorter interval from the last preoperative treatment with cytostatic drugs or timing of the first postoperative cytostatic drug treatment. There was no correlation between white blood cell count, neutrophil count and platelet count at the time of surgery and the frequency of post-surgery complications. In conclusion, the children with malignant

diseases did not have more postoperative complications from the VAG than those with neurological defects. There was no correlation to complications regarding timing of the operation and administration of cytostatic drugs.

Surgical intervention in children with malignancies could potentially be more dangerous and subject to a higher frequency of complications as a consequence of the treatment with cytostatic drugs. It has been speculated that children with malignancies and a gastrostomy often have more problems from their gastrostomy while on treatment with cytostatic drugs. It therefore seemed a reasonable assumption that surgery in a child undergoing treatment with cytostatic drugs would lead to more postoperative complications than in neurologically impaired children. The findings of previous studies do not support this suggestion (Arnbjornsson et al., 1999). The study population receiving chemotherapy was heterogeneous and varied widely in age, from 6 months to 18 years, in the type of disease and in the administered chemotherapy. This is significant. For example, age would have had a major effect on the ability of the child to tolerate chemotherapy. Furthermore, age matching with neurologically impaired children does not negate these problems. These children also vary widely in terms of operative risk and complications. A more logical study would have compared oncology children with and without cytotoxic effects, e.g. bone marrow depression. VAG complications in this study were recorded prospectively and therefore were probably more reliable than retrospective information obtained from other reported series in the medical literature. Complications resulting from the VAG button including local infections and mechanical problems with leakage as well as feeding intolerance with nausea, vomiting and diarrhea were reported (Aquino et al., 1995).

There was no increased frequency of complications in the children receiving cytostatic drugs within a few days before or even within one week after surgery. The same types and frequency of complications were encountered in the control group of disabled children with no malignant disease or cytostatic drug treatment (Arnbjornsson et al., 1999). Moreover, the time of cytostatic drug administration did not significantly change the rate of complications. White blood cell count at the time of the operation would be a better marker of chemotherapy effect than the time from chemotherapy. However, this was not statistically verified in this study. The study revealed no aggravated influence of cytostatic drug treatment on early postoperative problems of VAG. The timing of cytostatic drug administration in relation to the surgical intervention did not influence the frequency of postoperative complications. As a conclusion of the study a VAG procedure was recommended even in children with a malignant disease. A postponement of cytostatic treatment for some days after surgery was suggested despite the lack of clear evidence supporting this statement.

5.7 Gastrostomy in children with ventricular-peritoneal shunt (VPS)

Ventricular-peritoneal shunt (VPS) occurring in 4% of the included children, Table 2, is frequently associated with complications, such as shunt obstruction, infection and migration with or without erosion into nearby structures. These complications may occur at the abdominal site of a VPS raising the question of whether concurrent use of a separate intra-abdominal catheter such as a PEG, is safe and effective. Surgical intervention in children with VPS could potentially be more dangerous and subject to a higher frequency of complications. Many of the complications from VPS could preclude a VAG operation or raise serious concern with respect to VAG placement. Thus, it is acknowledged that the rate of peritonitis may be increased by the presence of a VPS. This issue remains unresolved and

is influenced by institutional and individual expertise of which some have concluded that simultaneous placement of a VPS and PEG should be avoided since some 5–10% of all inserted VP shunts eventually require revision for infection (Taylor et al., 2001).

The infective complications of PEG include stoma site infection in 3–9% and peritonitis in 1–7% (Sane et al., 1998). The standard pull-through technique of PEG insertion exposes the gastrostomy tube to oropharyngeal bacterial flora. Thus, following PEG, there are a number of factors that could lead to an intra-peritoneal catheter becoming exposed to bacterial pathogens. This theoretically increased risk for VP shunt infections after PEG insertion has however, not yet been established. On the contrary, previous reports have shown that there was no significant morbidity associated with a PEG in the presence of a VPS (Graham et al., 1993; Baird & Salasidis, 2004).

The safety of VAG was prospectively studied in children who had a ventriculoperitoneal shunt (VPS) (Backman et al., 2007). The study was undertaken to test the hypothesis whether the presence of a VPS influences the type and frequency of complications after a VAG procedure in children. The study group comprised a heterogeneous sample of 15 consecutive children, aged from 2 months to 12 years, with VPS, operated on with the VAG procedure and prospectively included. The control group consisted of 15 neurologically disabled children without VPS, matched for age, sex and operative procedure, retrospectively selected from a cohort of 167 patients with neurological disabilities operated on with VAG during the study period. All the patients were clinically evaluated for GER before the gastrostomy placement. In nine studied patients and in eight control patients an endoscopy and 24 h pH measurements were performed. None had the indications for surgery for GER. No patient in the present study had clinical signs of an intra-abdominal infection at the time of PEG placement and none were on steroid or cytostatic medication. All the VPS had been placed at least 8 weeks prior to the placement of the gastrostomy button. There were no serious operative complications, such as puncture of hollow organs or bleeding. In the immediate postoperative period, no wound or intra-abdominal complications occurred. There were no reoperations of the VAG due to adhesions or leakage. There was no difference in postoperative complications between the study and the control group.

Although the study does not indicate that children with VPS who undergo the VAG procedure are at greater risk of infection and subsequent shunt malfunction, there are other studies recommending prophylactic antibiotic therapy to cover skin and oral flora (Baird & Salasidis, 2004; Taylor et al., 2001). The patients in the presented study all received antibiotic prophylaxis. The placement of a percutaneous gastrostomy feeding tube, in the acute phase, in children with brain tumors and VP shunts may increase the risk of ascending meningitis especially if there are early gastrostomy-related complications (Gassas et al., 2006). Greatly disabled patients often have other potential risk factors for VP shunt infections, such as poor nutritional status, long-term hospitalization, subclinical infections and pressure ulcers. There seems to be consensus in the literature that antibiotic prophylaxis for PEG insertion is desirable in order to reduce the percentage of PEG site infection (Nicholson et al., 2000).

Co-placement of PEG and a VPS is reported (Nabika et al., 2006). The authors recommended at least 1 month between the procedures as well as administration of antibiotic prophylaxis. In the case series presented here, there was a lapse of at least 2 months between VPS and VAG. The VAG complications in this study were recorded prospectively and were, therefore, more reliable than retrospective information obtained from other reported series

in the medical literature. The complications from the VAG button were recorded, including local infections and mechanical problems with pain and leakage. Contrary to expectations, no increased frequency of complications was found following VAG in the children with VPS. The same types and frequency of complications were encountered in the control group of disabled children with no malignant disease or cytostatic drug treatment as had been reported earlier (Arnbjornsson et al., 2006).

Placement of a gastrostomy button in patients with VPS raises valid concern for CNS infection and shunt malfunction. Thus the gastrostomy button should be put in place several weeks after VPS placement, and the patients should be given an antibiotic prophylactically to prevent infection with skin flora. Using the laparoscopy and visualizing the VPS catheter is preferable to a blind trans-abdominal puncture as when using the PEG technique. The study indicates that children with VPS who undergo a VAG are at no greater risk of infection and subsequent shunt malfunction. Until the results of larger clinical trials are available, it is recommended to use VAG in patients with VPS when long-term enteral nutrition is required. The children with ventricular-peritoneal shunt (VPS) who underwent a VAG button placement were not at high risk for infection and subsequent shunt malfunction. They did not have more postoperative problems than a matched control group of neurologically disabled children (Backman et al, 2007).

5.8 Closure after gastrostomy button removal

A gastrostomy device is removed from the gastrostomy when no longer needed and the stoma usually closes within a short period of time without any surgical measures. Occasionally spontaneous closure does not occur and the stoma has to be closed surgically. For the patient the operative procedure includes a laparotomy and closure of the stomach wall and the abdominal wall in separate layers. The question is whether it is possible for the surgeon to decide which stoma has to be closed with a gastroraphy and which to leave for a spontaneous closure within a reasonable period of time. It would be of importance to find a factor correlating to the spontaneous closure of a gastrostomy after the device or button had been removed from the stoma. This knowledge regarding when to decide which gastrostomy has to be closed surgically and which to leave for spontaneous closure within a short time would be valuable to the surgeon. Gastrostomies constructed by using VAG or PEG are considered equal when it comes to spontaneous closure or the need for a gastroraphy. Although not studied we have no reason to believe that gastrostomy after a PEG would behave otherwise. The resulting gastrostomy has similar anatomical structures and thus it seems logical that a PEG and a VAG behaves similar.

Out of a cohort of 321 patients, who had been operated on with a video-assisted gastrostomy, all the 48 (15%) patients who had their gastrostomy button removed were included. The children were postoperatively carefully followed up and the closure of the gastrostomy was registered. According to the old institutional routine the child waited at least 3 months after the removal of the gastrostomy device before suggesting to the child's guardians an operative closure of the stoma (Arnbjornsson et al., 2005). Spontaneous closure of the gastrostomy happened in 26 patients within a 3-month expectance. In 14 of these 26 children the closure occurred within 2 weeks and in a further six children within 1 month. In only one child did the gastrostomy close spontaneously after 2 months. With the same expectance period the stoma did not close in 22 patients and they were consequently operated on with a gastroraphy. In 13 patients this procedure was performed within 5 weeks.

There was no difference found between the two groups regarding the patients' diagnoses, the duration of the gastrostomy use or the patient's age at the time of removal of the gastrostomy device. The small numbers of patients in each group of diagnosis made statistical calculations insignificant. Thus the hypothesis that any factor could predict the closure of the gastrostomy was consequently rejected. Thus, a routine expectance after the removal of a gastrostomy device for a short time of one month is recommended. If no spontaneous closure occurs, then a gastroraphy should be performed. A randomized study should replace the kind of observations reported here. However, such a randomized study would lead to an unnecessary gastroraphy in some patients or a long waiting time to a gastroraphy in others.

From the surgical point of view it is important that the gastroraphy is performed under general anesthesia. The procedure starts with a circular incision around the gastrostomy and the dissection is performed through the abdominal wall down to the stomach wall without opening the abdomen. We routinely close the stomach wall and the abdominal wall separately. This routine is based on our previous experience of cases where the opening was simply closed by a small local procedure suturing only the skin and subcutaneous tissue without layered closure. In all the patients, the postoperative course was complicated by a subcutaneous leakage from the stomach causing an infection. A third option doing a laparotomy into free abdomen would be too extensive in these cases. Evidence based on a randomized study comparing these methods is still missing.

6. The future

The future will provide better materials and design of the gastrostomy buttons and thereby avoid complications reported to be due to the design of the gastrostomy button (Arnbjörnsson et al., 1998). The materials used in the gastrostomy buttons and feeding tubes are still under development as is the construction of gastrostomy buttons. As technology improves so will its use for the children in need of a gastrostomy. Time will tell if the method described here can be further improved or replaced with still safer and better procedures for the children in need of a gastrostomy.

The way of performing a gastrostomy in children described here is certainly not the only way. Nor is it the definite final solution to the problem of performing a gastrostomy operation in children. Surgeons have been very creative in performing this simple communication between the stomach and the external surface of the body and let us hope that their ingenious talents and inventions will continue to flourish in the future for the benefit of the small patients. The equipment used in surgery today will improve and new technique inventions will enter the scene. The rapid development seen in the surgical field will also lead to new technology in the field of gastrostomies, unknown today.

7. Acknowledgments

We are indebted to Gillian Sjö Dahl, Lexis English for Writers, Lund, Sweden, for linguistic revision of the manuscript.

8. Ethical considerations

Intention to treat was the main analysis strategy and encompassed all the patients included in the studies reported. The regional research ethics committee approved the studies.

9. Competing interests

When performing this work, there were no external influences or conflicts of interests. All authors declare:

1. No financial support for the submitted work from anyone other than their employer;
2. No financial relationships with commercial entities that might have an interest in the submitted work;
3. No spouses, partners, or children with relationships with commercial entities that might have an interest in the submitted work;
4. No non-financial interests that may be relevant to the submitted work.

10. Legal requirements

This report complies with the current laws of the country in which it was performed.

11. Funding

This study was funded only by the Pediatric Surgical center involved.

12. References


- Ackerman, IL; Karn, CA.; Denne, SC.; Ensing, GJ. & Leitch, CA. (1998). Total but not resting energy expenditure is increased in infants with ventricular septal defects. *Pediatrics*, 102:1172-1177
- Albertsson-Wikland, K. & Karlberg, J. (1994). Natural growth in children born small for gestational age with and without catchup growth. *Acta Paediatr Suppl* 399:64-70
- Andersson, L.; Mikaelsson, C.; Arnbjörnsson, E. & Larsson, LT. (1997). Laparoscopy aided gastrostomy in children. *Ann Chir Gynaecol*. 86:19-22
- Aprahamian, CJ.; Morgan, TL.; Harmon, CM.; Georgeson, KE. & Barnhart, DC. (2006). U-stitch laparoscopic gastrostomy technique has a low rate of complications and allows primary button placement: experience with 461 pediatric procedures. *J Laparoendosc Adv Surg Tech A*. 16:643-9
- Aquino, VM.; Smyrl, CB.; Hagg, R.; McHard, KM.; Prestridge, L. & Sandler, ES. (1995). Enteral nutritional support by gastrostomy tube in children with cancer. *J Pediatr* 127:58-62
- Arnbjörnsson, E.; Larsson, LT. & Lindhagen T. (1999). Complications of laparoscopy-aided gastrostomies in pediatric practice. *J Pediatr Surg* 34:1843-1846
- Arnbjörnsson, E.; Backman, T.; Berglund, Y. & Kullendorff, CM. (2005). Closure after gastrostomy button. *PediatrSurg Int*. Oct; 21(10):797-799. Epub 2005 Oct 21
- Arnbjörnsson, E.; Backman, T.; Mörse, H.; Berglund Y.; Kullendorff, CM. & Lövkqvist, H. (2006). Complications of video-assisted gastrostomy in children with malignancies or neurological diseases. *ActaPaediatr*. Apr; 95(4):467-470
- Arnbjörnsson, E.; Jakobsson, I.; Larsson, LT. & Mikaelsson, C. (1998). Gastrostomy button causing perforation of the posterior gastric wall. *ActaPaediatr*. Nov; 87(11):1203-1204
- Arnbjörnsson, E. & Larsson, LT. (1998). Laparoscopic button is a safe method in pediatric gastrostomy. *Lakartidningen*. Sep 9; 95(37):3919. Swedish

- Arnbjörnsson, E. & Larsson, LT. (2005). Video-assisted placing of a gastrostomy button in children. Ten years of experiences show advantages of the method. *Lakartidningen* Nov 14-20; 102(46):3451-3455. Swedish.
- Backman, T.; Arnbjörnsson, E.; Berglund, Y. & Larsson, LT. (2006). Video-assisted gastrostomy in infants less than 1 year. *Pediatr Surg Int*. Mar; 22(3):243-246. Epub 2006 Jan 10
- Backman, T.; Arnbjörnsson, E. & Kullendorff, CM. (2005). Omentum herniation at a 2-mm trocar site. *J Laparoendosc Adv Surg Tech A*. Feb; 15:87-88
- Backman, T.; Berglund, Y.; Sjövie, H. & Arnbjörnsson E. (2007). Complications of video-assisted gastrostomy in children with or without a ventriculoperitoneal shunt. *Pediatr Surg Int*. Jul;23(7):665-8. Epub 2007 May 9
- Backman, T.; Sjövie, H.; Kullendorff, CM. & Arnbjörnsson, E. (2009). Correlation between the preoperative state of nutrition and the frequency of postoperative problems after video-assisted gastrostomy in children. *Gastroenterology Insights* volume 1:e2
- Backman, T.; Sjövie, H.; Kullendorff, CM. & Arnbjörnsson, E. (2010). Continuous double U-stitch gastrostomy in children. *Eur J Pediatr Surg*. Jan;20(1):14-17. Epub 2009 Oct 14
- Baird, R. & Salasidis, R. (2004). Percutaneous gastrostomy in patients with a ventriculoperitoneal shunt: case series and review. *Gastrointest Endosc* 59:570-574
- Behrens, R.; Lang, T.; Muschweck, H.; Richter, T. & Hofbeck, M. (1997). Percutaneous endoscopic gastrostomy in children and adolescents. *J Pediatr Gastroenterol Nutr*. 25:487-491
- Blackburn, GI.; Gibbons, GW.; Bothe, A.; Benotti, PN.; Harken, DE. & McEnany, TM. (1977). Nutritional support in cardiac cachexia. *J Thorac Cardiovasc Surg* 1977; 73:489-496
- Chang, PF.; Ni, YH. & Chang, MH. (2003). Percutaneous endoscopic gastrostomy to set up a long-term enteral feeding route in children: an encouraging result. *Pediatr Surg Int* 19:283-285
- Christensen, ML.; Hancock, M.; Gattuso, J.; Hurwitz, CA.; Smith, C.; McCormick, J. & Mirro J Jr. (1993). Parenteral nutrition associated with increased infection rate in children with cancer. *Cancer* 72:2732-2738
- Ciotti, G.; Holzer, R.; Pozzi, M. & Dalzell, M. (2002). Nutritional support via percutaneous endoscopic gastrostomy in children with cardiac disease experiencing difficulties with feeding. *Cardiol Young* 12:537-541
- Doyle, FM. & Kennedy, NP. (1994). Nutritional support via percutaneous endoscopic gastrostomy. *Proc Nutr Soc* 53:473-482
- Fanelli, RD. & Ponsky, JL (1992). A simplified technique for percutaneous endoscopic gastrostomy. *Surg Endosc*.6:261-262
- Gassas, A.; Kennedy, J.; Green, G.; Connolly, B.; Cohen, J.; Dag-Ellams, U.; Kulkarni, A. & Bouffet, E. (2006). Risk of ventriculoperitoneal shunt infections due to gastrostomy feeding tube insertion in pediatric patients with brain tumors. *Pediatr Neurosurg* 42:95-99
- Gauderer, MW.; Ponsky, JL. & Izant, RJ Jr. (1980). Gastrostomy without laparotomy: a percutaneous endoscopic technique. *J Pediatr Surg*. Dec;15(6):872-5
- Gauderer, MW. & Stellato, TA. (1986). Gastrostomies: evolution, techniques, indications, and complications. *Curr Probl Surg*. Sep;23(9):657-719
- Gauderer, MW. (1991). Percutaneous endoscopic gastrostomy: A 10-year experience with 220 children. *J Pediatr Surg* 26:288-294

- Gauderer, MW. (2001). Percutaneous endoscopic gastrostomy-20 years later: a historical perspective. *J Pediatr Surg* 36:217-219
- Georgeson, KE. (1993). Laparoscopic gastrostomy and fundoplication. *Pediatr Ann* 22:675-677
- Gottrand, F. & Michaud, L. (2002). Percutaneous endoscopic gastrostomy and gastroesophageal reflux: are we correctly addressing the question? *J Pediatr Gastroenterol Nutr.* 35:22-24
- Graham, SM.; Flowers, JL.; Scott, TR.; Lin, F. & Rigamonti, D. (1993). Safety of percutaneous endoscopic gastrostomy in patients with a ventriculoperitoneal shunt. *Neurosurgery* 32:932-934
- Grant, JP. (1988). Comparison of percutaneous endoscopic gastrostomy with Stamm gastrostomy. *Ann Surg* 207:598-603
- Hament, JM.; Bax, NM.; van der Zee, DC.; De Schryver, JE. & Nesselaar, C. (2001). Complications of percutaneous endoscopic gastrostomy with or without concomitant antireflux surgery in 96 children. *J Pediatr Surg* 36:1412-1415
- Haws, EB.; Sieber, WK. & Kiesewetter, WB (1996). Complications of tube gastrostomy in infants and children. 15-year review of 240 cases. *Ann Surg* 164:284-290
- Haynes, L.; Atherton, DJ.; Ade-Ajayi, N.; Wheeler, R. & Kiely, EM. (1996). Gastrostomy and growth in dystrophic epidermolysis bullosa. *Br J Dermatol* 134:872-879
- Heine, RG.; Reddiough, DS. & Catto-Smith, AG. (1995). Gastroesophageal reflux and feeding problems after gastrostomy in children with severe neurological impairment. *Dev Med Child Neurol* 37:320-329
- Hofner, G.; Behrens, R.; Koch, A.; Singer, H. & Hofbeck, M. (2000). Enteral nutritional support by percutaneous endoscopic gastrostomy in children with congenital heart disease. *Pediatr Cardiol* 21:341-346
- Hogan, RB.; DeMarco, DC.; Hamilton, JK.; Walker, CO. & Polter, DE. (1986). Percutaneous endoscopic gastrostomy—to push or pull. A prospective randomized trial. *Gastrointest Endosc* 32:253-258
- Isch, JA.; Rescorla, FJ.; Scherer, LR 3rd.; West, KW. & Grosfeld, JL. (1997). The development of gastroesophageal reflux after percutaneous endoscopic gastrostomy. *J Pediatr Surg* 32:321-323
- Jones, VS.; La Hei, ER. & Shun, A. (2007). Laparoscopic gastrostomy: the preferred method of gastrostomy in children. *Pediatr Surg Int.* 23:1085-9
- Kellnar, ST.; Till, H. & Bohn, R. (1999). Laparoscopically assisted performance of gastrostomy—a simple, safe and minimal invasive technique. *Eur J Pediatr Surg* 9:297-298
- Khattak, IU.; Kimber, C.; Kiely, EM. & Spitz, L. (1998). Percutaneous endoscopic gastrostomy in paediatric practice: Complications and outcome. *J Pediatr Surg* 33:67-72
- Kimber, CP.; Khattak, IU.; Kiely, EM. & Spitz, L. (1998). Peritonitis following percutaneous gastrostomy in children: management guidelines. *ANZ J Surg* 68:268-270
- Lantz, M.; Hultin Larsson, H. & Arnbjörnsson, E. (2010). Literature review comparing laparoscopic and percutaneous endoscopic gastrostomies in a pediatric population. *Int J Pediatr.* 2010:507616. Epub 2010 Mar 10
- Lantz, M.; Larsson, HH. & Arnbjörnsson, E. (2009). Video-assisted technique is best when performing laparoscopic gastrostomy in children. Meta-analysis of the frequency of

- fistulas following two different methods. *Lakartidningen*. Nov 11-17; 106(46):3078, 3080-3082. Swedish
- Larson, DE.; Burton, DD.; Schroeder, KW. & DiMagno, EP. (1987). Percutaneous endoscopic gastrostomy. Indications, success, complications, and mortality in 314 consecutive patients. *Gastroenterology* 93:48-52
- Launay, V.; Gottrand, F.; Turck, D.; Michaud, L.; Ategbo, S. & Farriaux, JP. (1996). Percutaneous endoscopic gastrostomy in children: influence on gastroesophageal reflux. *Pediatrics* 97:726-728
- Liou, TG.; Adler, FR.; Fitzsimmons, SC.; Cahill, BC.; Hibbs, JR. & Marshall, BC. (2001). Predictive 5-year survivorship model of cystic fibrosis. *Am J Epidemiol* 53:345-352
- Marin, OE.; Glassman, MS.; Schoen, BT. & Caplan, DB. (1994). Safety and efficacy of percutaneous endoscopic gastrostomy in children. *Am J Gastroenterol* 89:357-361
- Mathew, P.; Bowman, L.; Williams, R.; Jones, D.; Rao, B.; Schropp, K.; Warren, B.; Klyce, MK.; Whittington, G. & Hudson, M. (1996). Complications and effectiveness of gastrostomy feedings in pediatric cancer patients. *J Pediatr Hematol Oncol* 18:81-85
- Mikaelsson, C.; Arnbjörnsson, E. & Larsson, LT. (1995). The laparoscopy button. A new method with minimal surgical trauma in gastrostomy in children. *Lakartidningen*. Sep 6; 92(36):3237-3238. Swedish
- Mikaelsson, C. & Arnbjörnsson, E.(1998). Single-puncture laparoscopic gastrostomy in children. *Pediatr Surg Int*. Nov; 14(1-2):43-44
- Mitchell, IM.; Logan, RW.; Pollock, JC. & Jamieson, MP. (1995). Nutritional status of children with congenital heart disease. *Br Heart J* 73:277-283
- Nabika, S.; Oki, S.; Sumida, M.; Isobe, N.; Kanou, Y. & Watanabe Y. (2006). Analysis of risk factors for infection in coplacement of percutaneous endoscopic gastrostomy and ventriculoperitoneal shunt (discussion 229- 230). *Neurol Med Chir (Tokyo)* 46:226-229
- Nicholson, FB.; Korman, MG. & Richardson, MA. (2000). Percutaneous endoscopic gastrostomy: a review of indications, complications and outcome. *J Gastroenterol Hepatol* 15(1):21-25
- Norén, E.; Gunnarsdóttir, A.; Hanséus, K. & Arnbjörnsson, E. (2007). Laparoscopic gastrostomy in children with congenital heart disease. *J Laparoendosc Adv Surg Tech A*. Aug; 17(4):483-494
- Norton, B.; Homer-Ward, M.; Donnelly, MT.; Long, RG. & Holmes, GK. (1996). A randomised prospective comparison of percutaneous endoscopic gastrostomy and nasogastric tube feeding after acute dysphagic stroke. *BMJ* 312:13-16
- Patwardhan, N.; McHugh, K.; Drake, D. & Spitz, L. (2004). Gastroenteric fistula complicating percutaneous endoscopic gastrostomy. *J Pediatr Surg* 39:561-564
- Pedersen, AM.; Kok, K.; Petersen, G.; Nielsen, OH.; Michaelsen, KF. & Schmiegelow, K. (1999). Percutaneous endoscopic gastrostomy in children with cancer. *Acta Paediatr* 88:849-852
- Plantin, I.; Arnbjörnsson, E. & Larsson, LT. (2006). No increase in gastroesophageal reflux after laparoscopic gastrostomy in children. *Pediatr Surg Int*. Jul; 22(7):581-4. Epub 2006 Jun 1
- Razeghi, S.; Lang, T. & Behrens, R. (2002). Influence of percutaneous endoscopic gastrostomy on gastroesophageal reflux: a prospective study in 68 children. *J Pediatr Gastroenterol Nutr* 35:27-30

- Rothenberg, SS.; Bealer, JF.; & Chang, JH. (1999). Primary laparoscopic placement of gastrostomy buttons for feeding tubes: A safer and simpler technique. *Surg Endosc* 13:995–997
- Samuel, M. & Holmes, K. (2002). Quantitative and qualitative analysis of gastroesophageal reflux after percutaneous endoscopic gastrostomy. *J Pediatr Surg* 37:256–261
- Sane, SS.; Towbin, A.; Bergey, EA.; Kaye, RD.; Fitz, CR.; Albright, L. & Towbin, RB. (1998). Percutaneous gastrostomy tube placement in patients with ventriculoperitoneal shunts. *Pediatr Radiol* 28:521–523
- Seekri, IK.; Rescorla, FJ.; Canal, DF.; Zollinger, TW.; Saywell, R Jr. & Grosfeld, JL. (1991). Lesser curvature gastrostomy reduces the incidence of postoperative gastroesophageal reflux. *J Pediatr Surg* 26:982–985
- Sjövie, H.; Larsson, LT. & Arnbjörnsson, E. (2010). Postoperative gastrostomy site leakage correlated to the dimension of the gastrostomy button in children. *Gastroenterology Insights* volume 2:e9
- Skolin, I.; Axelsson, K.; Ghannad, P.; Hernell, O. & Wahlin, YB. (1997). Nutrient intake and weight development in children during chemotherapy for malignant disease. *Oral Oncol* 33:364–368
- Strologo, LD.; Principato, F.; Sinibaldi, D.; Appiani, AC.; Terzi, F.; Dartois, AM. & Rizzoni, G. (1997). Feeding dysfunction in infants with severe chronic renal failure after long-term nasogastric tube feeding. *Pediatr Nephrol* 11:84–86
- Taylor, AL.; Carroll, TA.; Jakubowski, J. & O'Reilly, G. (2001). Percutaneous endoscopic gastrostomy in patients with ventriculoperitoneal shunts. *Br J Surg* 88:724–727
- Tomicic, JT.; Luks, FI.; Shalon, L. & Tracy, TF. (2002). Laparoscopic gastrostomy in infants and children. *Eur J Pediatr Surg* 12:107–110
- Vandenplas, Y.; Ashkenazi, A.; Belli, D.; Boige, N.; Bouquet, J.; Cadranel, S.; Cezard, JP.; Cucchiara, S.; Dupont, C. & Geboes, K. (1993). A proposition for the diagnosis and treatment of gastro-esophageal reflux disease in children: a report from a working group on gastro-esophageal reflux disease. *Eur J Pediatr* 152:704–711
- Vanderhoof, JA.; Hofschire, PJ.; Baluff, MA.; Guest, JE.; Murray, ND.; Pinsky, WW.; Kugler, JD. & Antonson, DL. (1982). Continuous enteral feedings: An important adjunct to the management of complex congenital heart disease. *Am J Dis Child* 136:825–827
- Warady, BA.; Kriley, M.; Belden, B.; Hellerstein, S. & Alan, U. (1990). Nutritional and behavioural aspects of nasogastric tube feeding in infants receiving chronic peritoneal dialysis. *Adv Perit Dial* 6:256–268
- Zanakhshary, M.; Jamal, M.; Blair, GK.; Murphy, JJ.; Webber, EM. & Skarsgard, ED. (2005). Laparoscopic versus percutaneous endoscopic gastrostomy tube insertion: A new pediatric gold standard? *J Pediatr Surg*. 40:859–862



Gastrostomy

Edited by Dr. Pavel Kohout

ISBN 978-953-307-365-1

Hard cover, 152 pages

Publisher InTech

Published online 02, December, 2011

Published in print edition December, 2011

The gastrostomy placement is a method of providing nutrition to the patients who are unable to eat. In this book you can find chapters focused on the use of gastrostomy in children, patients with neurological impairment and patients with head and neck tumours. Home enteral nutrition is suitable for all of these groups of patients and is far easier with gastrostomy. The new indications (especially in very young children) required new techniques such as: laparoscopic gastrostomy, laparoscopy assisted endoscopic gastrostomy with/without fundoplication, ultrasonography assisted gastrostomy. All information about these techniques can be found in this book. This book does not serve as a basic textbook, but as an interesting reading material and as an aid for physicians who are already familiar with the indication for gastrostomy and want to know more.

How to reference

In order to correctly reference this scholarly work, feel free to copy and paste the following:

Torbjörn Backman, Malin Mellberg, Helén Sjöwie, Magnus Anderberg and Einar Arnbjörnsson (2011). Video-Assisted Gastrostomy in Children, *Gastrostomy*, Dr. Pavel Kohout (Ed.), ISBN: 978-953-307-365-1, InTech, Available from: <http://www.intechopen.com/books/gastrostomy/video-assisted-gastrostomy-in-children>

INTECH
open science | open minds

InTech Europe

University Campus STeP Ri
Slavka Krautzeka 83/A
51000 Rijeka, Croatia
Phone: +385 (51) 770 447
Fax: +385 (51) 686 166
www.intechopen.com

InTech China

Unit 405, Office Block, Hotel Equatorial Shanghai
No.65, Yan An Road (West), Shanghai, 200040, China
中国上海市延安西路65号上海国际贵都大饭店办公楼405单元
Phone: +86-21-62489820
Fax: +86-21-62489821

© 2011 The Author(s). Licensee IntechOpen. This is an open access article distributed under the terms of the [Creative Commons Attribution 3.0 License](https://creativecommons.org/licenses/by/3.0/), which permits unrestricted use, distribution, and reproduction in any medium, provided the original work is properly cited.

IntechOpen

IntechOpen