

We are IntechOpen, the world's leading publisher of Open Access books Built by scientists, for scientists

6,900

Open access books available

186,000

International authors and editors

200M

Downloads

Our authors are among the

154

Countries delivered to

TOP 1%

most cited scientists

12.2%

Contributors from top 500 universities



WEB OF SCIENCE™

Selection of our books indexed in the Book Citation Index
in Web of Science™ Core Collection (BKCI)

Interested in publishing with us?
Contact book.department@intechopen.com

Numbers displayed above are based on latest data collected.
For more information visit www.intechopen.com



Treatment and Long Term Follow-Up of a Patient with an Impacted Transmigrant Canine

Neslihan Üçüncü¹, Belma Işık Aslan¹ and H. Tuğçe Oğuz Türel²

¹*Gazi University/Faculty of Dentistry/ Department of Orthodontics*

²*Bayındır Hospital / Ankara
Turkey*

1. Introduction

Impacted teeth are those with a delayed eruption time or those which are not expected to erupt completely based on clinical and radiographic assessment (Richardson & Russell, 2000). All teeth can be impacted. However, third molars, maxillary canines, maxillary and mandibular premolars, and maxillary central incisors are the teeth most frequently involved (Rajic et al., 1996).

Impactions are twice as common in females (1.17 %) as in males (0.51 %). The prevalence of impacted maxillary canines is 0.9–2.2%, but mandibular canine impaction occurs 20 times less frequently than maxillary canines (Alaejos-Algarra et al., 1998; Aydin et al., 2004; D'Amico et al., 2003). It is an even more rare phenomenon when such an impacted mandibular canine migrates to the other side of the mandible, crossing the mandibular midline (Joshi, 2001). Shah et al. (1978) found 8 unerupted mandibular canines in 7886 individuals. Grover and Lorton (1985) found 11 impacted mandibular canines in 5000 individuals. Ericson and Kural (1986) estimated the incidence of mandibular canine impaction to be 0.35 %.

The etiology of impacted teeth is unknown, though several mechanisms have been proposed. Tumors, cysts, and odontomes may cause malposition of teeth if they lie in the path of eruption of teeth. Other possible etiologic factors suggested by some authors are premature loss of deciduous teeth, prolonged retention or early loss of the deciduous canine, crowding, spacing, supernumerary teeth, abnormal position of the tooth bud, excessive length of the crown of the mandibular canines, dilaceration of the root, iatrogenic origin and idiopathic condition with no apparent cause cystic lesions, an abnormally strong eruption force and heredity (Bishara, 1992; Javid, 1985; Joshi & Shetye, 1994).

The treatment options for impacted canines are no treatment, surgical intervention, removal, transplantation, prosthetic or restorative treatment or surgical exposure with or without orthodontic traction to align the malpositioned tooth. The preferred option is surgical exposure and alignment (Blair et al., 1998). Successful treatment of impacted canines is dependent on the position of the tooth in both the sagittal and transversal planes, ankylosis and dilaceration of the tooth. It has generally been accepted that the more a canine is horizontally impacted, the less successful the tooth will be brought into its correct position (Odegard, 1997). Since prevention of impacted canines provides the best long-term results, intervention with surgical attachment of an orthodontic button or bracket should be implemented only as a second alternative (Crawford, 2000).

Transmigration was defined as a phenomenon of an unerupted mandibular canine crossing the mandibular midline (Tarsitino et al., 1971). Later Javid (1985) stated that the midline was required to be crossed by one-half or more of the length of the tooth. However in 2006, Auluck et al., suggested that the tendency of a canine to cross the barrier of the mandibular midline suture is a more important consideration than the distance of migration after crossing the midline.

Until recently most studies have reported that the mandibular canine is the only tooth in the dental arch that migrated across the midline. Yet recently, Kara et al. (2011) have encountered two transmigrant laterals and three transmigrant premolars in 90 transmigrant teeth. In other studies, transmigration of a lateral incisor (Camilleri, 2007), a premolar (Alves et al., 2008) and maxillary canines (Aydin & Yilmaz, 2003; Shapira & Kuftinec, 2005) have been detected.

Different incidences have been reported in the rate of transmigrant teeth. Zvolanek (1986) failed to find any cases in a sample of 4,000 patient series. Javid (1985) reported that a radiographic survey of 1000 students revealed only 1 transmigrated impacted mandibular canine. In the studies considering the Turkish population, Aydın et al. (2004) observed 0.31%; Aktan et al. (2010) found 0.34%; Büyükkurt et al. reported (2007) 0.33 ratio of transmigration and recently Kara et al. (2011) found 0.075 percentages of transmigrant teeth. Joshi (2001) stated that 89 % of the transmigratory mandibular canines were impacted and 91 % were unilateral. The left canine is more involved than the right canine, and women tend to have this condition more frequently than do men (Joshi, 2001; Kara et al., 2011). Although unilateral migration is more common, bilateral transmigration of mandibular canines has also been reported (Kuftinec et al., 1995). Transmigrant teeth may erupt ectopically at the midline or on the opposite side of the arch (Camilleri & Scerri, 2003). The transmigrated teeth maintain their nerve supply from the original side (Fiedler & Alling, 1968).

Stafne (1963) reported that a transmigrated mandibular canine always moves in the direction of the cusp tip and deviates mesially. The transmigrant canine usually travels along the labial side of the incisor roots and migrates as far as the roots of the first molar on the opposite side (Camilleri & Scerri, 2003; Javid, 1985). Ando et al. (1964) and Stafne (1963) stated that movement of transmigratory canine is more rapid before the formation of its root, yet Dhooria et al. (1986) observed a fairly rapid movement even after completion of the root formation.

The exact mechanism of transmigration is not yet known although numerous theories exist in the literature to explain their occurrence. One of the theory is that the transmigrant teeth could be the result of a malpositioning of the dental lamina during the embryonic stage of tooth development (Joshi, 2001). Heredity has been hinted as a causative factor. Most of the time, the canine just migrates without any pathological entity, but rarely a cyst or odontoma accompanies such a tooth (Kara et al., 2011).

Clinical and radiographic examination is usually required to diagnose transmigrant teeth for they are usually detected within the symphysis of the mandible. In the existence of overretention of the primary canine, a radiographic examination should have be done to check the permanent mandibular canines. (Joshi & Bhatt, 1971).

When a transmigrant mandibular canine reaches a horizontal position where there is no obstruction by the roots of the incisors, it may travel forward toward the midline, cross the symphysis and assume a position where the entire tooth may be situated on the opposite

side of the mandible (Stafne, 1963). Thoma (1963) states that horizontally impacted transmigrated canine “almost always have to be removed”.

The aim of this case report is to demonstrate that a horizontally transmigrated mandibular canine can be treated by using surgical exposure and orthodontic treatment mechanics and to show the long-term results.

2. Case report

The patient was a 10 year 1 month-old white female when she first applied for an orthodontic consultation. The medical history revealed no medical problems. There was no history of trauma to the craniofacial complex. She was in the early mixed dentition and complete orthodontic records were obtained. In clinical investigation, a crossbite in upper left region and Angle Class III malocclusion were observed. Panoramic and cephalometric radiograph analysis revealed a horizontally impacted mandibular right canine with its crown located slightly distal to the right central incisor root apex (Figure 1,2,3,4).

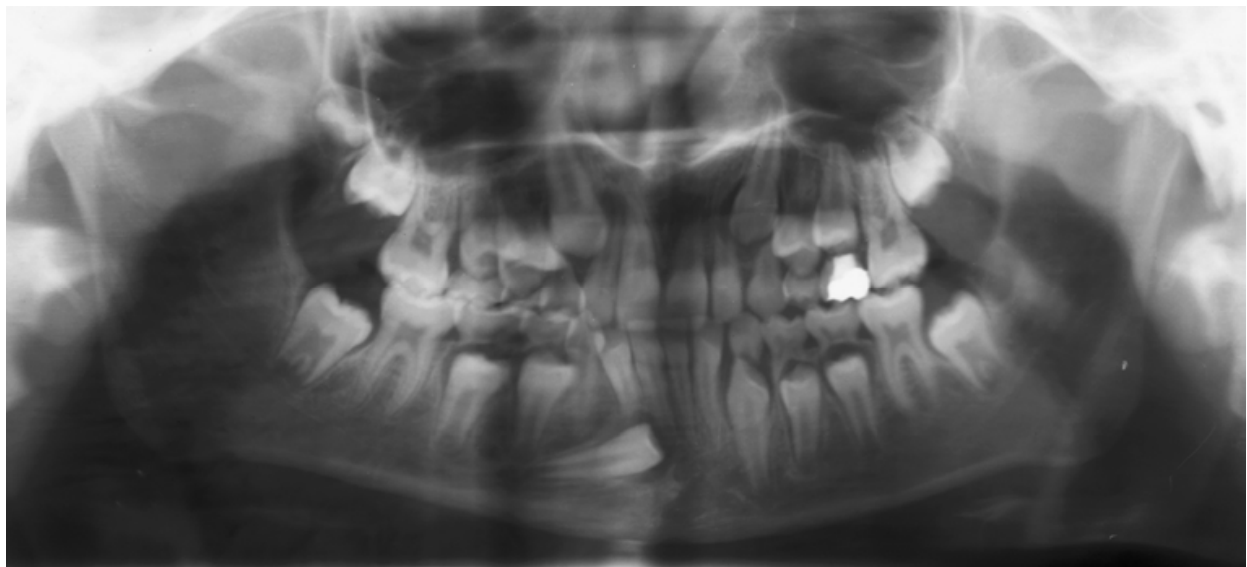


Fig. 1. Panoramic radiograph of patient at age 10 years, 1 month.

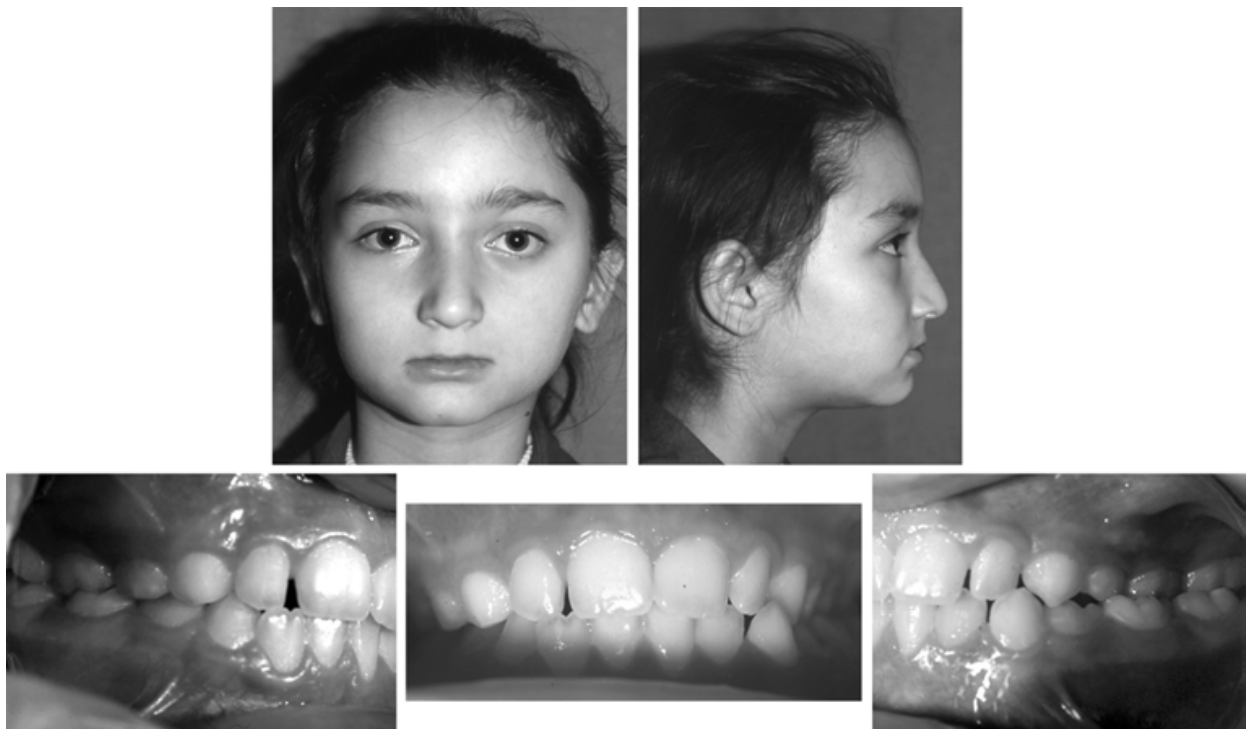
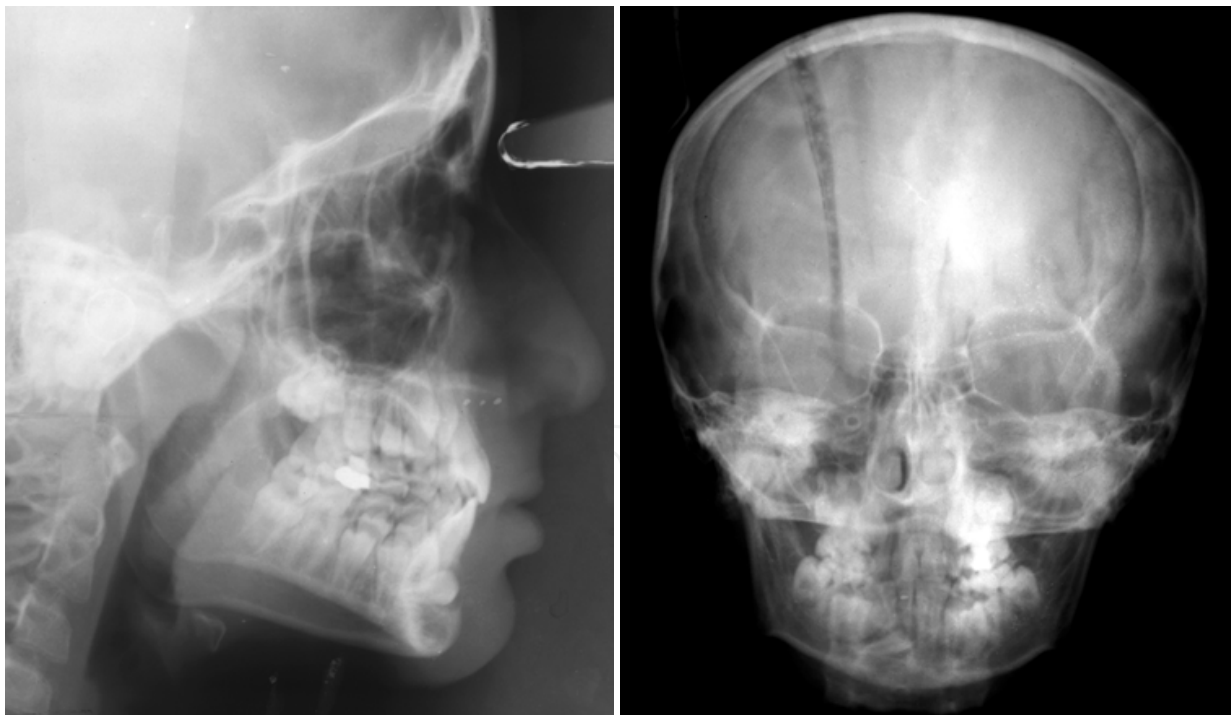
Fig. 2. Intraoral and extraoral photographs of patient at age 10 years,1 month.



Figs. 3.4. Lateral cephalometric and anteroposterior radiographs of patient at age 10 years 1 month.

A maxillary Schwarz appliance was used to correct the posterior crossbite. In the retention period of the Schwarz appliance, a panoramic radiograph of the patient was taken. According to the panoramic radiograph, it was observed that the horizontally right

impacted canine migrated mesially, crossed the midline and became a transmigrant tooth (Figure 5).

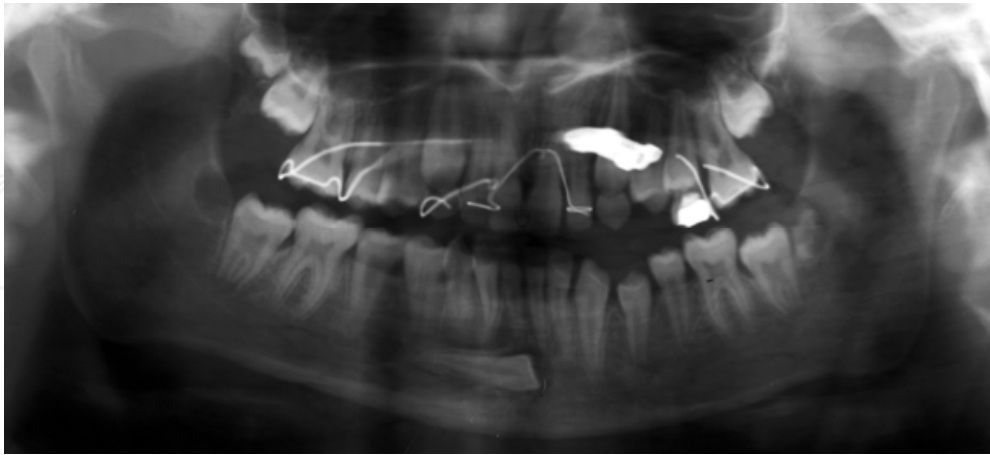


Fig. 5. Panaromic radiograph of patient at the retention period of Schwarz appliance.

2.1 Treatment plan

Treatment options were surgical removal, surgical exposure and orthodontic traction or autotransplantation of the impacted tooth. We didn't prefer the autotransplantation option since the root of the tooth was already completed. All of the treatment alternatives were explained to the patient and her parents. They accepted the surgical exposure and orthodontic traction option. If orthodontic traction had not been successful, the impacted tooth would have been extracted and implant or prothetic approaches could have been performed.

2.2 Treatment progress and results

First, the patient was referred to an oral surgeon for the elimination of follicle epithelium. Three weeks later, an open approach was performed and a window was opened on the mucosa through cauterization, then an orthodontic bracket with 0.30 mm. ligature wire extending into the oral cavity was surgically attached to the canine (Figure 6).

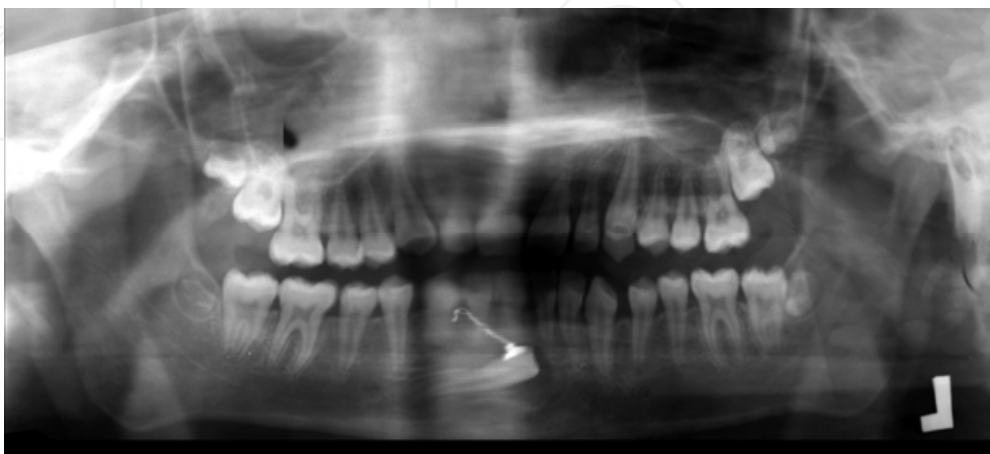


Fig. 6. Panaromic radiograph of patient showing surgically attached of an orthodontic attachment to the canine.

Two weeks later, 50 gr orthodontic force was applied to transmigrated canine through elastics hanged between Schwartz appliance and the canine (Figure 7).

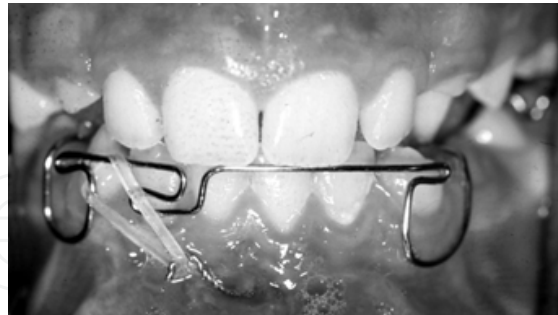

Fig. 7. 50 gr orthodontic force applied to transmigrated canine with elastics towards the Schwartz appliance.

This application continued for 9 months. At the end of 9 months, a new appliance was done and the traction force was increased to 90 grams. After one year, the crown of the transmigrant canine was seen intraorally (Figure 8,9,10).

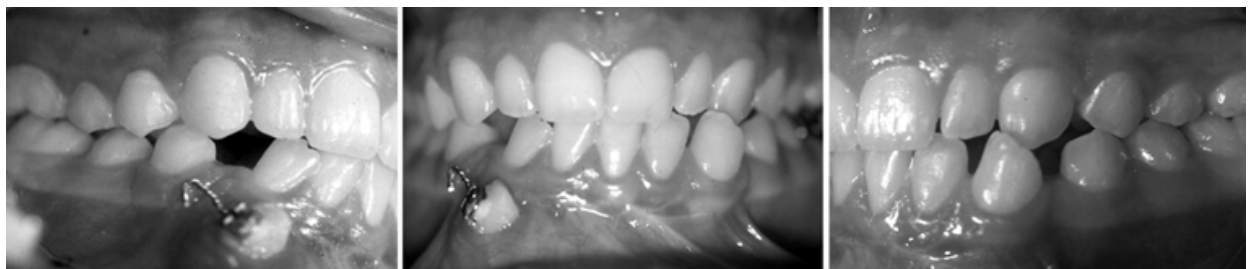

Fig. 8. Intraoral photographs of patient when the transmigrant canine seen intraorally.

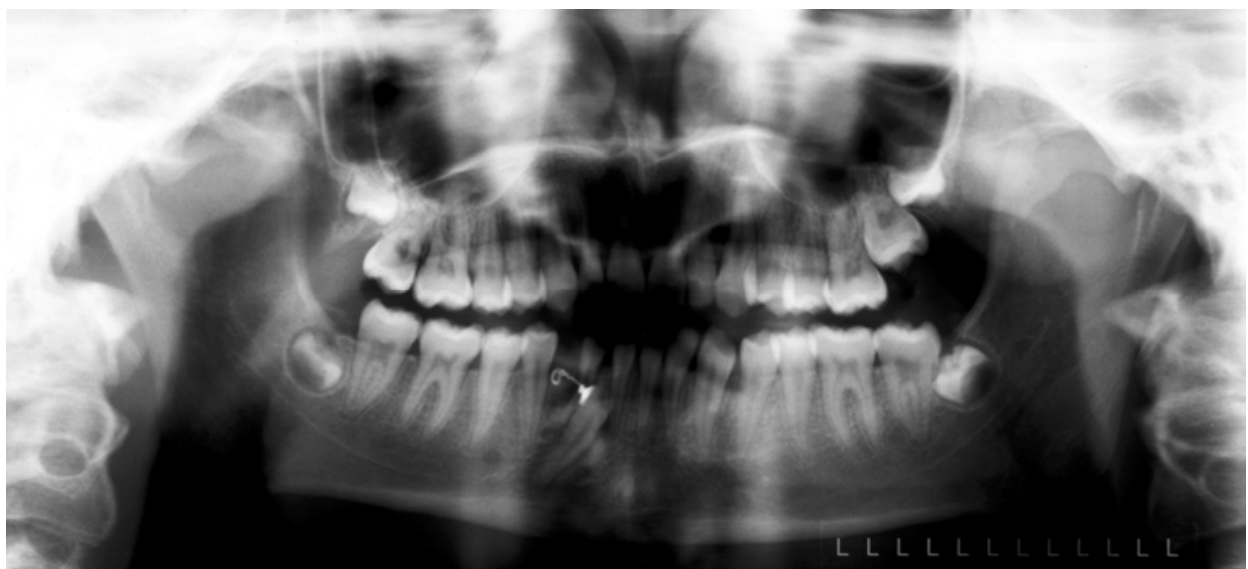

Fig. 9. Panoramic radiograph of patient when the transmigrant canine seen intraorally.

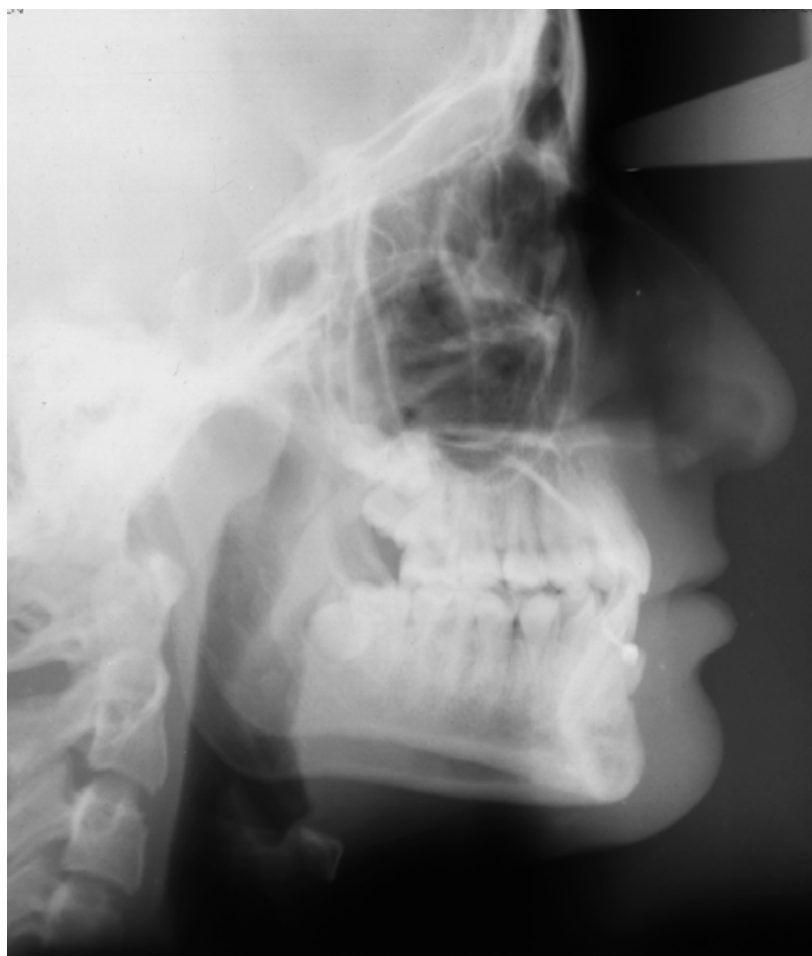

Fig. 10. Lateral cephalometric radiograph of patient when the transmigrant canine seen intraorally.

Comprehensive orthodontic records were secured, and it was decided to attempt a non-extraction mode of treatment, with 0.018" x 0.022" slot Roth appliances. In the aligning period of the mandibular arch, 0.014" and 0.016" NiTi was used with an open coil spring which was placed between 42 and 44 to create space for the transmigratory tooth. After providing adequate space, 0.016" SS arch wire with stopper bends was applied to the mandibular arch. An intra-mandibular elastic applying 90 grams force was hanged between 43 and 46 for the distalization of 43. Then 44, 45, 46 and 41, 42, 31, 32, 33 were figured to strengthen their anchorage. An extrusive force was applied to 43 by a chain elastic hanged between 44 and 42. Meanwhile 0.014" and 0.016" NiTi arch wires were applied for the alignment of the maxillary arch. Then 0.016" x 0.022" NiTi, 0.017" x 0.022" Ni-Ti and SS arch wires were applied respectively to maxillary and mandibular arches to maintain torque. The fixed orthodontic treatment elapsed 2 years. Class I molar and canine relationship bilaterally were achieved. The arches were successfully aligned and leveled, and ideal overbite and overjet were established. Comprehensive orthodontic records were obtained and Hawley appliances were prepared for retention (Figure 11,12,13). Superimposition and cephalometric analysis of the patient before and after orthodontic treatment are shown in Figure 14 and Table 1. The Hawley appliances were used for 8 months all day and the following 8 months only at night.

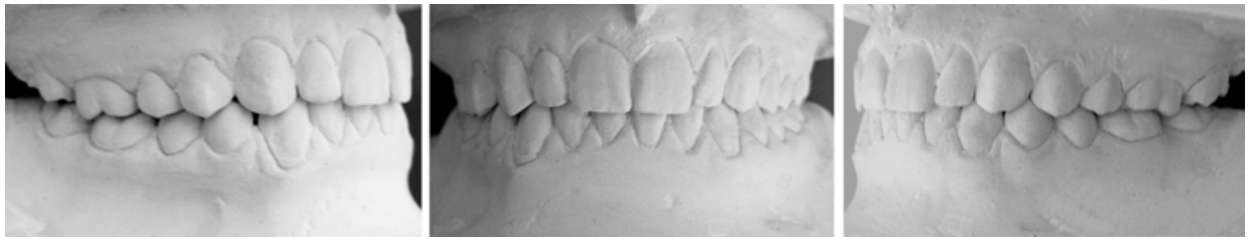

Fig. 11. Intraoral photographs of patient after fixed orthodontic treatment

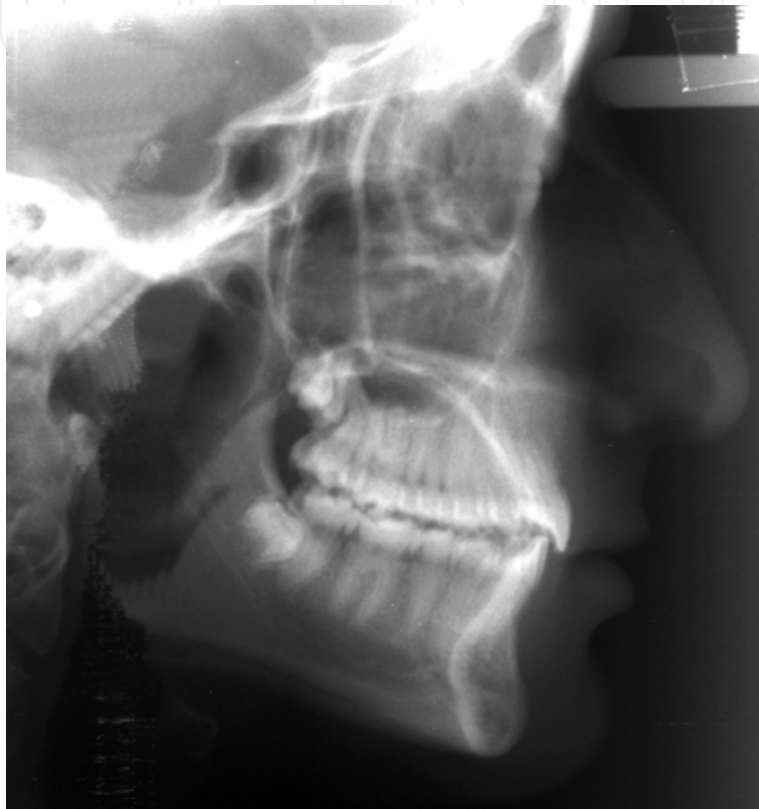

Fig. 12. Lateral cephalometric radiograph of patient after fixed orthodontic treatment

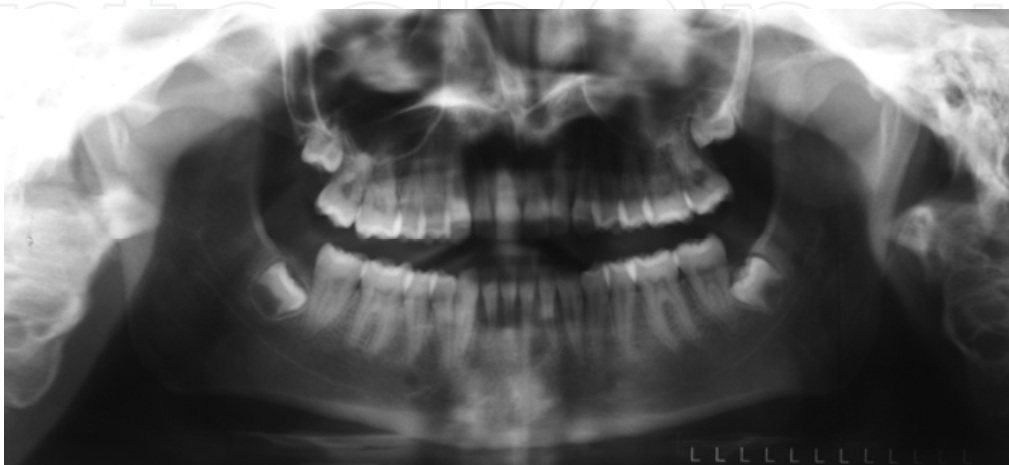


Fig. 13. Panoramic radiograph of patient after fixed orthodontic treatment.

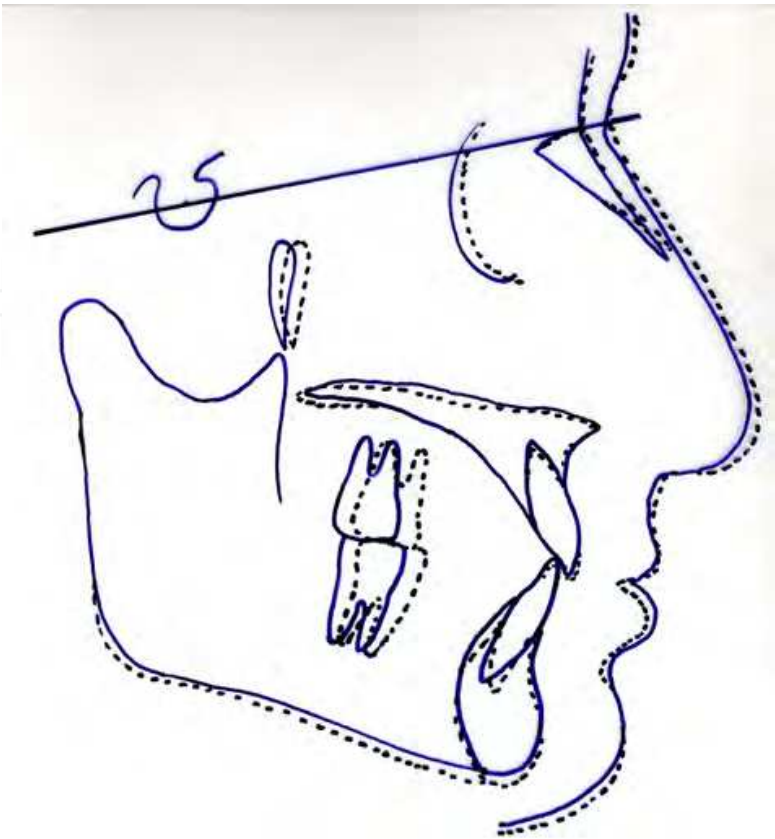


Fig. 14. Cephalometric superimpositions of patient before and after full fixed orthodontic treatment

	T1	T2
SNA	76°	76°
SNB	73.5°	73°
ANB	2.5°	3°
SNGoGn	27.5°	27.5°
N-ANS	49 mm	50 mm
N-Me	109 mm	111 mm
S-Go	75 mm	76.5mm
U1-NA	1 mm/16.5°	2.5mm/20°
L1-NB	2.5 mm/25°	3.5 mm/21°
U1/L1	136°	137.5°
Overjet	1.5mm	2mm
Overbite	3mm	3mm

Table 1. Cephalometric measurements at the beginning (T1) and the end (T2) of full fixed therapy

Three years later from retention which is in fact four and a half years later from fixed orthodontic treatment, the patient was recalled to check the stability of the treatment and the position of third molars. Full orthodontic records were obtained (Figure 15,16). The patient was referred to oral surgeon for the removal of 18, 28 and 48 to provide the occlusion stability. The retention records demonstrated good results.

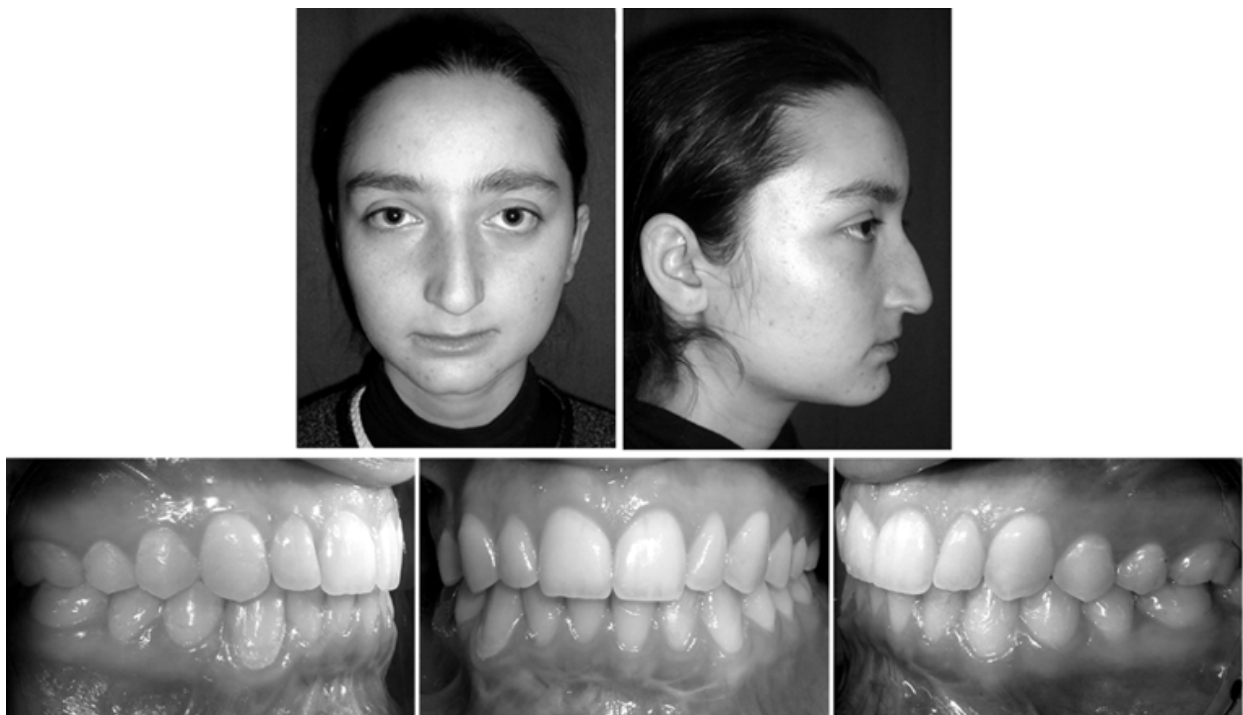

Fig. 15. Intraoral and extraoral photographs of patient 4.5 years after fixed orthodontic treatment.

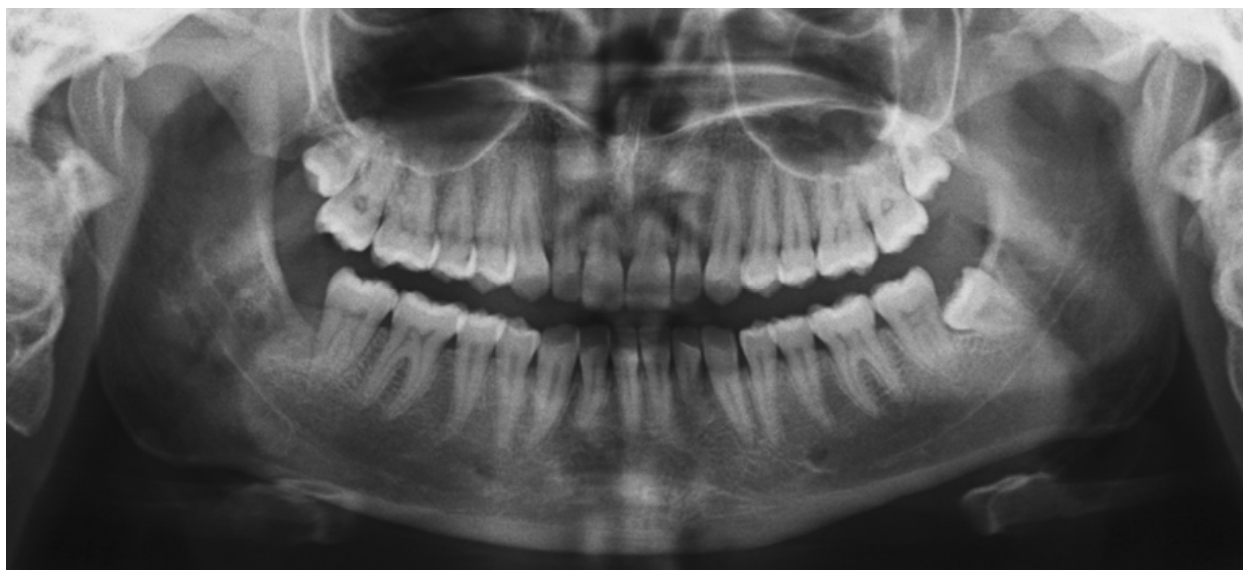


Fig. 16. Panaromic radiograph of patient 4.5 years after fixed orthodontic treatment.

3. Discussion

Transmigration of the mandibular canine across the mandibular midline is a rare and elusive phenomenon. Mupparapu (2002) described five patterns of canine transmigration: Type 1 for a canine impacted mesio-angularly across the midline, labial or lingual to the anterior teeth; Type 2 for a canine horizontally impacted near the inferior border of the mandible inferior to the apices of the incisors; Type 3 for a canine erupting on the opposite side of the jaw; Type 4 for a canine horizontally impacted near the inferior border of the contralateral side and Type 5 regardless of eruption status, canine positioned vertically in the midline with the long axis of the tooth crossing the midline. Type 2 corresponds to our case. According to Mupparapu (2002), the most frequently encountered type of transmigrant teeth was type 1, followed by type 2 and then type 4. Type 5 was the least frequently seen.

Impacted and transmigrated mandibular canines are often symptomless. Patients in deciduous dentition demonstrating the absence of the permanent canine from the mandibular arch, may be suspected to have an impacted or transmigrated canine (McDonald & Yap, 1986).

Treatment considerations for transmigratory teeth depend on the stage of development, distance of migration and the symptoms. When the root apices are closed, extraction often is the only choice. Clinical clues can help to diagnose this problem at an early stage to avoid extraction. Axial inclination of the canines can help to predict the likelihood of canine impaction and transmigration (Joshi, 2001). Canines lying within 25° to 30° of the midsagittal plane have a tendency for impaction, but they do not migrate to the midline. If canines are within an angle of 30° to 50° , they tend to cross the midline yet those that are found at an angle greater than 50° , transmigration is almost always the rule (Pratt, 1969). Stafne (1963) found that the greatest amount of tooth migration occurred before the root is completely formed. If these malpositioned teeth can be detected early, they may be surgically exposed and moved using orthodontic forces.

The other treatment options proposed for impacted mandibular canines include observation, surgical removal and transplantation (McDonald & Yap, 1986).

If the impacted teeth is asymptomatic, it can be left in its place, but a series of radiographs should be taken periodically (Plumpton, 1966). Surgical extraction could be planned in the following situations (Camilleri & Scerri, 2003):

1. Progressive deterioration of the position of the mandibular canine during a one year follow-up period.
2. If the patient has any associated abnormalities, such as a developing apical cyst, neuralgia, displacement of teeth or resorption of an adjacent tooth root.
3. Severe mandibular crowding which requires therapeutic extractions to correct the incisor crowding. This would reduce the orthodontic treatment time and also the hazardous orthodontic tooth movement.

Wertz (1994) advocated that, if a nonextraction method of orthodontic treatment is indicated, a surgical repositioning should probably be attempted just before extracting the transmigrated canine. However, if the diagnosis indicates an extraction mode of treatment in the lower arch, then the transmigrated canine should be extracted instead of the usual premolar, eliminating excessive treatment time. Howard (1976) expressed a similar viewpoint.

If adequate space for alignment of an impacted mandibular canine exists and it is mechanically possible to reposition an impacted mandibular canine into proper position,

then surgical exposure and orthodontic treatment is indicated (Ferguson, 1990; McDonald & Yap, 1986).

In published reports, transmigrant canines were treated mostly by surgical extraction (Gonzalez-Sanchez, 2007). Only Wertz (1994) reported three transmigrant canines corrected successfully by surgical exposure and orthodontic treatment.

Wertz (1994) reported that, if the tip of the crown has migrated past the opposite incisor area or if the apex has migrated past the apex of the adjacent lateral incisor root apex, it might be mechanically impossible to bring the aberrant canine into its normal place.

Autotransplantation is another approach to correct this problem. Camilleri and Scerri (2003) stated that when the mandibular incisors are in a normal position and space for transmigrated canine is sufficient, autotransplantation may be undertaken. However, an immature tooth is required for success, and the difficulty in removing the tooth in one piece complicates the procedure (Rebellato & Schabel, 2003).

In this case, the root development of the transmigrated mandibular canine was already completed. Therefore, surgical exposure and orthodontic traction was preferred instead of autotransplantation.

Some authors believe that the age of patient is an important factor in the success of proposed tooth movement (Machen, 1989). In patients under 14 years old, before extracting the tooth, other options should be considered and the case should be carefully assessed. In patients over 14 years old, significant changes are not expected and extraction should only be considered (Ando et al., 1964). In a recent retrospective study, Aras et al. (2011) reported that forced eruption in four teeth out of twenty mandibular impacted canine teeth applying a traction force resulted in failure. They claimed that high mean age could be the reason of failure. Orton et al. (1995) states that treatments starting after the end of a pubertal growth spurt are likely to be protracted. In this case, successful forced eruption of the transmigrated canine may also be due to the orthodontic treatment of the case at an early age.

Experimental studies have shown that the loss of periodontal attachment does not occur during orthodontic tooth movement providing the periodontium is maintained in a healthy state (Ericsson & Thilander, 1978). However, in clinical studies, the variable loss of periodontal support is observed which may reflect the hygiene challenge associated with fixed orthodontic appliances (Alstad & Zachrisson, 1979; Zachrisson & Alnaes, 1973). Except this condition, various periodontal problems can occur due to the surgical approach. Either an open or a closed surgical approach can be used to uncover the crown of impacted tooth and to place an orthodontic attachment. Open approach may lead to gingival recession, bone loss, decreased width of keratinized gingiva, delayed periodontal healing and gingival inflammation. With close approach method, less complications and more esthetically pleasing results are obtained (Frank & Long, 2002).

In this case, open approach was performed to uncover the crown of the impacted tooth because of the localization of the tooth and the direction of the orthodontic forces that would be applied. In the long term, no periodontal complications except mild gingival recession was detected. No root resorption or pulpal damage was observed in both the transmigrated canine and the adjacent teeth. An ideal Class I occlusion was maintained at the end of the treatment. The results were satisfying and stable 4.5 years after from the fixed orthodontic treatment.

4. Conclusion

This case demonstrated that a horizontally impacted transmigrant mandibular canine can be successfully treated without the risk of root resorption, periodontal and pulpal damage by maintaining adequate plaque control, applying small and constant forces and preferring the appropriate surgical approach.

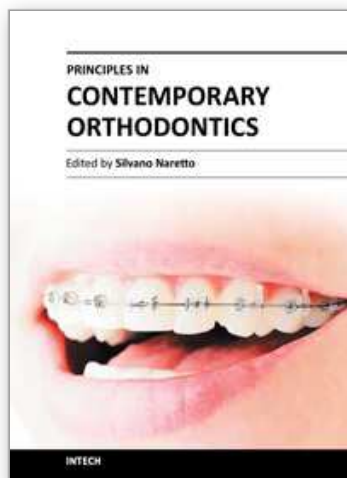
5. References

- Aktan, A.M.; Kara, S.; Akgünlü, F. & Malkoç, S. (2010). The Incidence of Canine Transmigration and Tooth Impaction in a Turkish Subpopulation. *European Journal of Orthodontics*, Vol.32, No.5, (Epub March 2010), pp. 575-581, ISSN 1460-2210.
- Alaejos-Algarra, C.; Berini-Aytes, L. & Gay-Escoda, C. (1998). Transmigration of Mandibular Canines: Report of Six Cases and Review of the Literature. *Quintessence International*, Vol.29, No.6, (June 1998), pp. 395-398, ISSN 0033-6572.
- Alstad, S. & Zachrisson, B.U. (1979). Longitudinal Study of Periodontal Condition Associated with Orthodontic Treatment in Adolescents. *American Journal of Orthodontics*, Vol.76, No.3, (September 1979), pp. 277-286, ISSN 0889-5406.
- Alves, D.B.; Pedrosa, E.F.; Andreo, J.C.; de Carvalho, I.M. & Rodrigues Ade, C. (2008). Transmigration of Mandibular Second Premolar in a Patient with Cleft Lip and Palate- Case Report. *Journal of Applied Oral Science*, Vol.16, No.5, (September-October 2008), pp. 360-363, ISSN 1678-7765.
- Ando, S.; Aizawa, K.; Nakashima, T.; Sanka, Y.; Shimbo K, Kiyokawa K. (1964). Transmigration Process of the Impacted Mandibular Cuspid. *Journal of Nihon University School of Dentistry*, Vol.6, pp. 66-71, ISSN 0029-0432.
- Aras, M.H.; Halicioğlu, K; Yavuz, M.S. & 3, Çağlaroğlu M. (2011). Evaluation of surgical-orthodontic treatments on impacted mandibular canines. *Medicina Oral Patologia Oral y Cirugia Bucal*, (January 2011), Available from: >PMID:21196853>.
- Auluck, A.; Nagpal, A.; Setty, S., Pai, K. & Sunny, J. (2006). Transmigration of Impacted Mandibular Canines: Report of Four Cases. *Journal of the Canadian Dental Association*, Vol.72, No.3, (April 2006), pp. 249-252, ISSN 0709-8936.
- Aydin, U. & Yilmaz, H.H. (2003). Transmigration of Impacted Canines. *Dentomaxillofacial Radiology*, Vol.32, No.3, (May 2003), pp. 198-200, ISSN 0007-1285.
- Aydin, U.; Yilmaz, H.H. & Yildirim, D. (2004). Incidence of Canine Impaction and Transmigration in a Patient Population. *Dentomaxillofacial Radiology*, Vol.33, No.3, (May 2004), pp. 164-169, ISSN 0007-1285.
- Bishara, S.E. (1992). Impacted Maxillary Canines: A Review. *American Journal of Orthodontics and Dentofacial Orthopedics*, Vol.101, No.2, (February 1992), pp. 159-71, ISSN 0889-5406.
- Blair, G.S.; Hobson, R.S. & Leggat, T.G. (1998). Posttreatment Assesment of Surgically Exposed and Orthodontically Aligned Impacted Maxillary Canines. *American Journal of Orthodontics and Dentofacial Orthopedics*, Vol.113, No.3, (March 1998), pp. 329-332, ISSN 0889-5406.
- Büyükkurt, M.C.; Aras, M.H.; Çağlaroğlu, M. & Gungormus, M. (2007). Transmigrant Mandibular Canines. *Journal of Oral and Maxillofacial Surgery*, Vol.65, No.10, (October 2007), pp. 2025-2029, ISSN 0278-2391.

- Camilleri, S. & Scerri, E. (2003). Transmigration of Mandibular Canines. A Review of the Literature and a Report of Five Cases. *Angle Orthodontist*, Vol.73, No.6, (December 2003), pp. 753-762, ISSN 0003-3219.
- Camilleri, S. (2007) Double Transmigration and Hyperdontia. *Angle Orthodontist*, Vol.77, No.4, (July 2007), pp. 742-744, ISSN 0003-3219.
- Crawford, L.B. (2000). Four Impacted Permanent Canines: An Unusual Case. *Angle Orthodontist*. Vol.70, No.6, (December 2000), pp. 484-489, ISSN 0003-3219.
- D'Amico, R.M.; Bjerklin, K.; Kurol, J. & Falahat, B. (2003). Long-term Results of Orthodontic Treatment of Impacted Maxillary Canines. *Angle Orthodontist*, Vol.73, No.3, (June 2003), pp. 231-238, ISSN 3219.
- Dhooria, H.S.; Sathawane, R.S.; Mody, R.N. & Sakharde, S.B. (1986). Transmigration of Mandibular Canines. *Journal of the Indian Dental Association*, Vol.58, No.9, (September 1986), pp. 348-351, ISSN 0019-4611.
- Ericson, S.; Kurol, J. (1986). Radiographic Assessment of Maxillary Canine Eruption in Children with Clinical Signs of Eruption Disturbances. *European Journal of Orthodontics*. Vol.8, pp. 133-140, ISSN 0141-5387.
- Ericsson, I. & Thilander, B. (1978). Orthodontic Forces and Recurrence of Periodontal Disease. An Experimental Study in the Dog. *American Journal of Orthodontics*, Vol.74, No.1, (July 1978), pp. 41-50, ISSN 0889-5406.
- Ferguson, J.W. (1990). Management of the Unerupted Maxillary Canine. *British Dental Journal*, Vol.169, No.1, (July 1990), pp. 11-17, ISSN 0007-0610.
- Fiedler, L.D. & Alling, C.C. (1968). Malpositioned Mandibular Canine: Report of a Case. *Journal of Oral Surgery*, Vol.26, No.6, (June 1968), pp. 405-407.
- Frank, C.A. & Long, M. (2002). Periodontal Concerns Associated with the Orthodontic Treatment of Impacted Teeth. *American Journal of Orthodontics and Dentofacial Orthopedics*, Vol.121, No.6, (June 2002), pp. 639-649, ISSN 0889-5406.
- Gonzalez-Sanchez, M.A.; Berini-Aytés, L. & Gay-Escoda, C. (2007). Transmigrant Impacted Mandibular Canines: A Retrospective Study of 15 Cases. *The Journal of The American Dental Association*, Vol.138, No.11, (November 2007), pp. 1450-1455, ISSN 0002-8177.
- Grover, P.S. & Lorton, L. (1985). The Incidence of Unerupted Permanent Teeth and Related Clinical Cases. *Oral Surgery Oral Medicine Oral Pathology*, Vol.59, No.4, (April 1985), pp. 420-425, ISSN 1079-2104.
- Howard, R.D. (1976). The Anomalous Mandibular Canine. *British Journal of Orthodontics*, Vol.3, No.2, (April, 1976), pp. 117-119, ISSN 0007-0610.
- Javid, B. (1985). Transmigration of Impacted Mandibular Cuspids. *International Journal of Oral Surgery*, Vol.14, No.6, (December 1985), pp. 547-549, ISSN 0300-9785.
- Joshi, M.R. & Bhatt, N.A. (1971). Canine Transposition. *Oral Surgery Oral Medicine Oral Pathology*, Vol.31, No.1, (January 1971), pp. 49-53, ISSN 1079-2104.
- Joshi, M.R.; Shetye, S.B. (1994). Transmigration of Mandibular Canines: A Review of the Literature and Report of Two Cases. *Quintessence International*, Vol.25, No.4, (April 1994), pp. 291-294, ISSN 0033-6572.
- Joshi, M.R. (2001). Transmigrant Mandibular Canines: A Record of 28 Cases and a Retrospective Review of the Literature. *Angle Orthodontist*, Vol. 71, No.1, (February 2001), pp. 12-22, ISSN 0003-3219.

- Kara, M.I.; Ay, S.; Aktan, A.M.; Şener, I.; Bereket, C.; Ezirganlı, Ş. & Demirkol, M. (2011). Analysis of Different Type of Transmigrant Mandibular Teeth. *Medicina Oral Patologia Oral y Cirugia Bucal*, (January 2011), Available from: > PMID:21196850>.
- Kuftinec, M.M.; Shapira, Y. & Nahlieli, O. (1995). Bilateral Transmigration of Impacted Mandibular Canines. *The Journal of the American Dental Association*, Vol.126, pp. 1022-1024, ISSN 0002-8177.
- Machen, D.E. (1989). Legal Aspects of Orthodontic Practice: Risk Management Concepts. The Impacted Canine. *American Journal of Orthodontics and Dentofacial Orthopedics*, Vol.96, pp. 270-271, ISSN 0889-5406.
- McDonald, F. & Yap, W.L. (1986). The Surgical Exposure and Application of Direct Traction of Unerupted Teeth. *American Journal of Orthodontics and Dentofacial Orthopedics*, Vol.89, pp. 331-340, ISSN 0889-5406.
- Mupparapu, M. (2002). Patterns of Intra-osseous Transmigration and Ectopic Eruption of Mandibular Canines: Review of Literature and Report of Nine Additional Cases. *Dentomaxillofacial Radiology*, Vol.31, pp. 355-60, ISSN 0007-1285.
- Odegard, J. (1997). The Treatment of a Class I Malocclusion with Two Horizontally Impacted Maxillary Canines. *American Journal of Orthodontics and Dentofacial Orthopedics*, Vol.111, pp. 357-65, ISSN 0889-5406.
- Orton, H.S.; Garvey, M.T. & Pearson, M.H. (1995). Extrusion of the Ectopic Maxillary Canine Using a Lower Removable Appliance. *American Journal of Orthodontics and Dentofacial Orthopedics*, Vol.107, pp. 349-59, ISSN 0889-5406.
- Plumpton, S. (1966). The Extraction of Mandibular Teeth via an Extra-oral Approach. *British Journal of Oral Surgery*, Vol.4, pp. 127-131.
- Pratt, R.J. (1969). Migration of Canine Across the Mandibular Mid-line. *British Dental Journal*, Vol.126, pp. 463-464, ISSN 0007-0610.
- Rajic, S.; Muretic, Z. & Percac, S. (1996). Impacted Canine in a Prehistoric Skull. *Angle Orthodontist*, Vol.66, pp. 477-80, ISSN 0003-3219.
- Rebellato, J. & Schabel, B. (2003). Treatment of a Patient with an Impacted Transmigrant Mandibular Canine and a Palatally Impacted Maxillary Canine. *Angle Orthodontist*, Vol.73, pp. 328-336, ISSN 0003-3219.
- Richardson, G. & Russell, K.A. (2000). A Review of Impacted Permanent Maxillary Cuspids: Diagnosis and Prevention. *Journal of the Canadian Dental Association*, Vol.66, pp. 497-501, ISSN 0709-8936.
- Shah, R.M.; Boyd, M.A. & Vakil, T.F. (1978). Studies of Permanent Tooth Anomalies in 7886 Canadian Individuals II: Congenital Missing, Supernumerary and Peg Teeth. *Dental Journal*, Vol.44, pp. 265-268, ISSN 0007-0610.
- Shapira, Y. & Kuftinec, M.M. (2005). Unusual Intraosseous Transmigration of a Palatally Impacted Canine. *American Journal of Orthodontics and Dentofacial Orthopedics*, Vol.127, pp. 360-3, ISSN 0889-5406.
- Stafne, E.C. (1963). Malposed Mandibular Canine. *Oral Surgery Oral Medicine Oral Pathology*, Vol.16, pp. 1330, ISSN 1079-2104.
- Tarsitano, J.; Wooten, J. & Burditt, J. (1971). Transmigration of Nonerupted Mandibular Canines: Report of Cases. *The Journal of the American Dental Association*, Vol.82, No.6, pp. 1395-7, ISSN 0002-8177.

- Thoma, K.H. (1963). Oral Surgery 4 th ed., CV Mosby, St Louis, pp. 273 (as quoted) Wertz, R.A. (1994) Treatment of Transmigrated Mandibular Canines. *American Journal of Orthodontics and Dentofacial Orthopedics*, Vol.106, pp. 419-427, ISSN 0889-5406.
- Wertz, R.A. (1994). Transmigrated Mandibular Canines. *American Journal of Orthodontics and Dentofacial Orthopedics*, Vol.106, pp. 419-27, ISSN 0889-5406.
- Zachrisson, B.U. & Alnaes, L. (1973). Periodontal Condition in Orthodontically Treated and Untreated Individuals I. Loss of Attachment, Gingival Pocket Depth and Clinical Crown Height. *Angle Orthodontist*, Vol.43, pp. 402-11, ISSN 0003-3219.
- Zvolanek, J.W. (1986). Transmigration of an Impacted Mandibular Canine. *Illinois Dental Journal*, Vol.55, pp. 86-7, ISSN 0019-1973.



Principles in Contemporary Orthodontics

Edited by Dr. Silvano Naretto

ISBN 978-953-307-687-4

Hard cover, 584 pages

Publisher InTech

Published online 25, November, 2011

Published in print edition November, 2011

Orthodontics is a fast developing science as well as the field of medicine in general. The attempt of this book is to propose new possibilities and new ways of thinking about Orthodontics beside the ones presented in established and outstanding publications available elsewhere. Some of the presented chapters transmit basic information, other clinical experiences and further offer even a window to the future. In the hands of the reader this book could provide an useful tool for the exploration of the application of information, knowledge and belief to some orthodontic topics and questions.

How to reference

In order to correctly reference this scholarly work, feel free to copy and paste the following:

Neslihan Üçüncü, Belma Işık Aslan and H. Tuğçe Oğuz Türel (2011). Treatment and Long Term Follow-Up of a Patient with an Impacted Transmigrant Canine, Principles in Contemporary Orthodontics, Dr. Silvano Naretto (Ed.), ISBN: 978-953-307-687-4, InTech, Available from: <http://www.intechopen.com/books/principles-in-contemporary-orthodontics/treatment-and-long-term-follow-up-of-a-patient-with-an-impacted-transmigrant-canine>

INTECH
open science | open minds

InTech Europe

University Campus STeP Ri
Slavka Krautzeka 83/A
51000 Rijeka, Croatia
Phone: +385 (51) 770 447
Fax: +385 (51) 686 166
www.intechopen.com

InTech China

Unit 405, Office Block, Hotel Equatorial Shanghai
No.65, Yan An Road (West), Shanghai, 200040, China
中国上海市延安西路65号上海国际贵都大饭店办公楼405单元
Phone: +86-21-62489820
Fax: +86-21-62489821

© 2011 The Author(s). Licensee IntechOpen. This is an open access article distributed under the terms of the [Creative Commons Attribution 3.0 License](https://creativecommons.org/licenses/by/3.0/), which permits unrestricted use, distribution, and reproduction in any medium, provided the original work is properly cited.

IntechOpen

IntechOpen