

We are IntechOpen, the world's leading publisher of Open Access books Built by scientists, for scientists

6,900

Open access books available

185,000

International authors and editors

200M

Downloads

Our authors are among the

154

Countries delivered to

TOP 1%

most cited scientists

12.2%

Contributors from top 500 universities



WEB OF SCIENCE™

Selection of our books indexed in the Book Citation Index
in Web of Science™ Core Collection (BKCI)

Interested in publishing with us?
Contact book.department@intechopen.com

Numbers displayed above are based on latest data collected.
For more information visit www.intechopen.com



Endoscopy in the Evaluation and Management of the Pediatric Airway

Kris R. Jatana¹ and Jeffrey C. Rastatter²

¹Nationwide Children's Hospital and The Ohio State University Columbus, Ohio

²Children's Memorial Hospital and Northwestern University Chicago, Illinois
USA

1. Introduction

The airway starts at the anterior nasal vestibule and ends at the lung parenchyma. This includes the nasal cavity, nasopharynx, oral cavity, oropharynx, larynx, hypopharynx, trachea, and bronchi. When evaluating a child with noisy breathing, it is important to assess the airway in a systematic manner.

A thorough history is important. This includes assessment of the severity or progression of symptoms, and whether the symptoms are worse with feeding or increased exertion. The severity determines the urgency of complete evaluation. Apparent life-threatening events (ALTE) warrant prompt multidisciplinary evaluation (McMurray, 1997).

Inspiratory stridor generally originates from the larynx, while expiratory stridor from the trachea or bronchi. Stridor that is biphasic (both inspiratory and expiratory) typically indicates a fixed obstructive lesion is present. Depending on symptomatology, the addition of endoscopic evaluation of the airway to the basic physical examination can be extremely beneficial. A definitive diagnosis is critical to proper treatment intervention.

2. Types of endoscopy

Endoscopic evaluation of the pediatric airway can be accomplished with both rigid and flexible endoscopes. It can be done awake in the office or under general anesthesia. In the office, awake flexible endoscopic examination of the nasal cavity, nasopharynx, oropharynx, hypopharynx, and larynx can be performed. Rigid endoscopy, using various sizes and degrees of scopes, is used to evaluate the nasal cavity and nasopharynx. Transoral rigid endoscopy with an angled scope to evaluate the oropharynx, hypopharynx, or larynx is not well-tolerated in children. Awake flexible fiberoptic endoscopy allows for full assessment of the upper airway to the level of the true vocal cords. An advantage to awake examination is that direct visualization of the airway can be correlated with the noisy breathing of the child, helping to identify the cause. Vocal cord function is best assessed using awake flexible fiberoptic laryngoscopy. In the past, awake evaluation of the upper airway in children was limited to the level of the true vocal cords, however there is some evidence that flexible fiberoptic laryngoscopy with tracheoscopy can be performed in the office setting without complications (Hartzell, 2010). Due to potential risk of laryngospasm and airway

compromise, such evaluation is generally done in the operating room. Under general anesthesia, the assessment of the airway is best for static lesions, however, if the patient can be kept breathing spontaneously, a more dynamic assessment of the lower airways (trachea and bronchi) can be performed. A rigid bronchoscope allows for ventilation (providing adequate time for complete inspection) as well as visualization of the segmental bronchi. While some advocate using a telescope alone to evaluate the trachea and proximal main bronchus, it is difficult to examine the distal portions of each main bronchus and the segmental bronchi.



Fig. 1. Equipment

An operating room with systematic organization of various sizes of rigid bronchoscopes, telescopes, laryngoscopes, and flexible fiberoptic scopes.

3. Abnormalities of the nasal cavity

3.1 Nasal vestibular stenosis and pyriform aperture stenosis

Nasal vestibular stenosis results from disruption of the vestibular lining with proliferation of granulation and fibrous tissue. It has occurred in association with nasal CPAP use (Jatana 2008,2010), prior nasal surgical procedures, nasal packing (Karen 2000), excessive cautery for epistaxis (Bajaj, 1969), birth trauma (Jablon, 1997), and flash burn injury (Salvado, 2008). Anterior nasal endoscopy may be required to look for vestibular stenosis, and it can be significant in a neonate who is an obligate nasal breather.

Congenital nasal pyriform aperture stenosis, is a different entity causing a narrowing at the level of the pyriform aperture (Ramadan, 1995).

3.2 Nasal septal deviation

This is a common finding on endoscopy of the nasal cavity. The nasal septum is composed of cartilage and bone, and deformities can contribute to nasal obstruction. This can be developmental or acquired due to nasal trauma. A statistically significant higher incidence of nasal septal deformities has been shown with a history of nasal injury (Zielnik-Jurkiewicz, 2006)

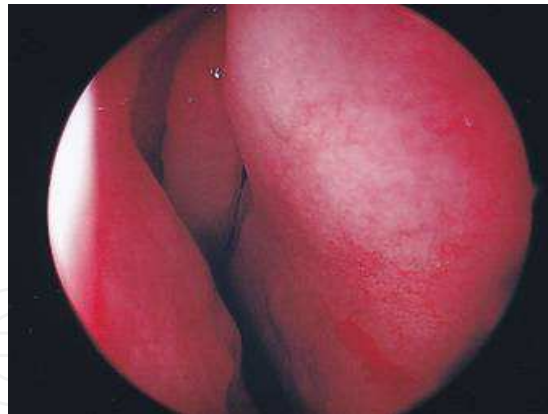


Fig. 2. Nasal septal deviation

Nasal endoscopy using a 0 degree endoscope in the right nasal cavity, showing a nasal septal deformity to the right compromising the nasal airway.

3.3 Nasal polyposis

Nasal endoscopy can be useful in the diagnosis of nasal polyps which generally result from chronic inflammation. The development may be related to chronic rhinosinusitis, asthma, allergic rhinitis, or cystic fibrosis (Triglia, 1997). Patients with cystic fibrosis, an autosomal recessive condition, frequently develop chronic rhinosinusitis with or without nasal polyps (Franco, 2009; Weber, 2008). Imaging is critical prior to any surgical intervention as tumors or masses with intracranial extension can be present in the sinonasal cavity of children. Endoscopic sinus surgery can be used to remove polyps as indicated.

3.4 Anterior cranial fossa masses

Dermoid sinus (with/without intracranial extension), encephaloceles, and gliomas are the most common midline nasal masses (Hughes, 1980), and imaging must be performed prior to any surgical intervention. If intracranial extension is not known, there is risk of CSF leak, meningitis, or intracranial injury (Hedlund, 2006). If a skull base defect is present, it may need to be repaired simultaneously which can be done either endoscopically or by craniotomy depending on the size and intracranial extent.

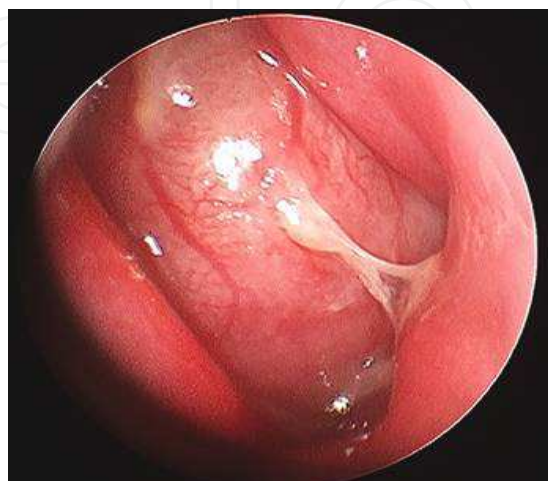


Fig. 3. Cystic mass, nasal cavity

This rare nasal mass, a chondromesenchymal hamartoma, is a benign congenital lesion that has known propensity to have intracranial extension. This can mimic the appearance of a meningoencephalocele (Kim 2004).

3.5 Choanal atresia

A failure of the posterior nasal aperture to canalize results in choanal atresia, and this can be unilateral or bilateral. It was first described in 1755 by Roederer and occurs in 1 of 5000-7000 live births. A newborn is an obligate nasal breather. Neonates with bilateral choanal atresia require endotracheal intubation at the time of birth (Deutsch, 1997). It has been shown that 71% of these are mixed (bony and membranous), and 29% are bony atresia (Brown, 1996). Nasal endoscopy can be used to show the atretic plate in the back of the nasal cavity along the nasal floor. In most cases, repair can be successfully performed endoscopically (Hengerer, 2008; Ramsden, 2009).

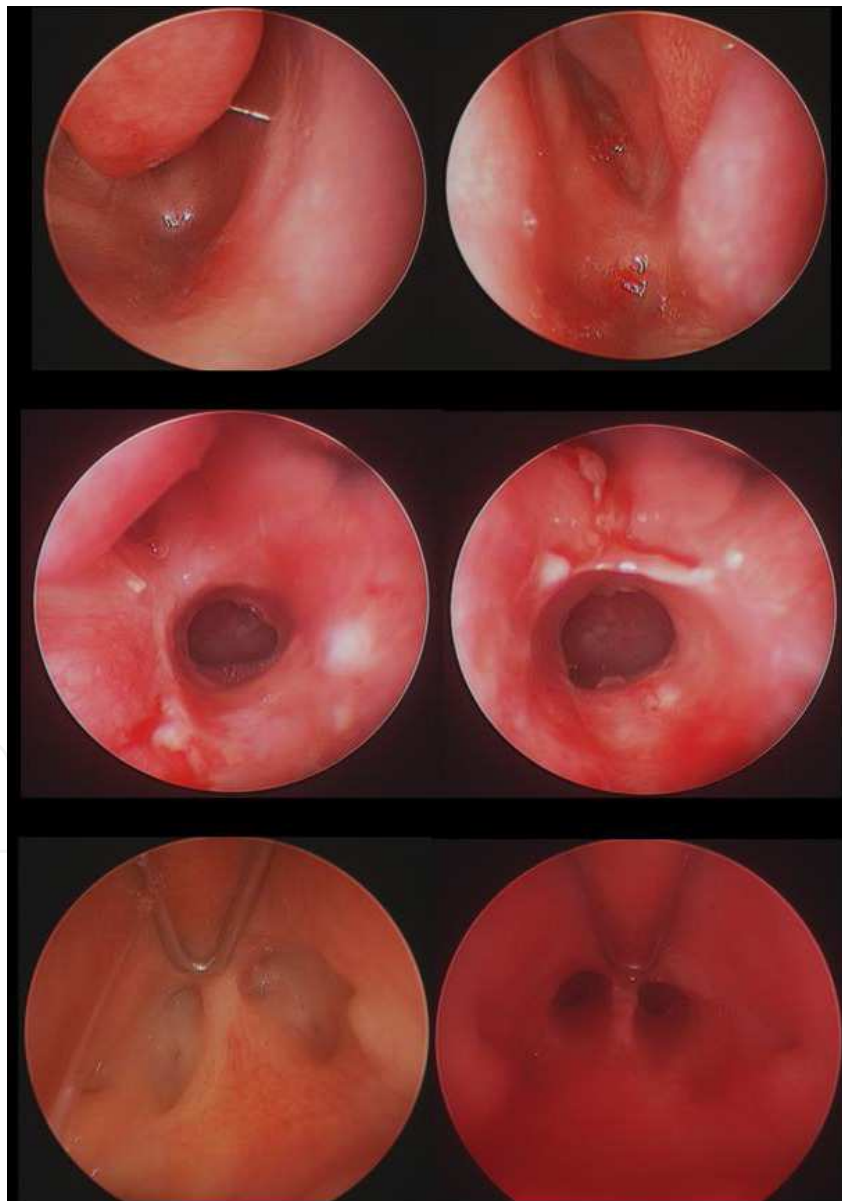


Fig. 4. Bilateral choanal atresia

At the top, a 0 degree endoscope in the nasal cavity of a newborn child who had respiratory distress immediately at birth. Note the blocked choana bilaterally (right & left). The middle image shows the right and left posterior nasal cavity, 2 weeks after endoscopic repair. At the bottom is a view through a 120 degree endoscope with the soft palate retracted anteriorly. Note the posterior choana before (left) and after (right) endoscopic repair.

3.6 Nasal septal perforation

The nasal septum, consisting of both cartilage and bone, divides the left and right nasal cavities. A perforation, or hole, in the septum can cause non-specific symptoms, including epistaxis, obstruction, crusting, whistling, and pain. Causes of perforation include: chronic trauma, piercings, intranasal placement of button batteries, drug use (including cocaine), industrial metal plating solutions, intranasal steroid use, surgical trauma, nasal cautery, Wegener granulomatosis, sarcoidosis, and syphilis (Diamantopoulos, 2001; Lanier, 2009). Some large nasal septal perforations have been repaired using an endoscope-assisted approach (Giacomini, 2011).

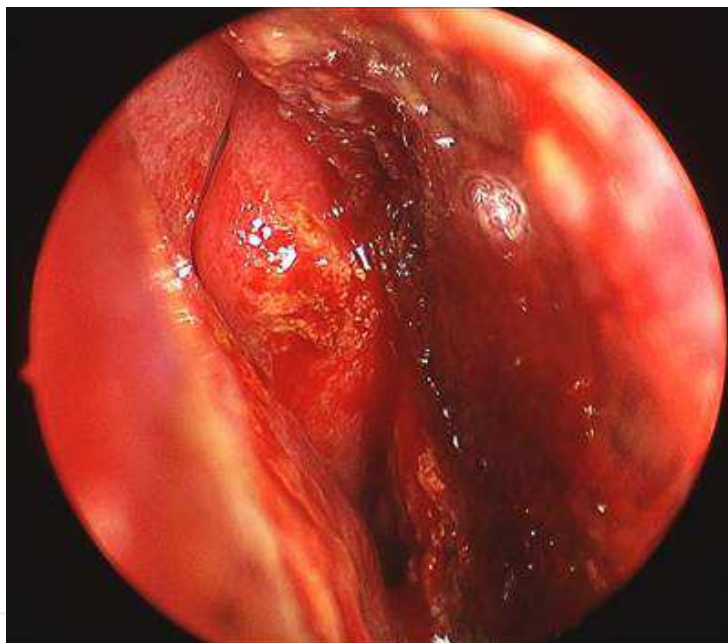


Fig. 5. Right nasal cavity. When placed inside of the body, button batteries need to be removed as soon as possible (emergently), to avoid serious complications.

Note early tissue necrosis (black) after removal of button battery, often resulting in a nasal septal perforation.

4. Abnormalities of the nasopharynx

4.1 Adenoid hypertrophy

The adenoid tissue in the nasopharynx, consists of lymphoid tissue, which is typically small at birth and enlarges to various degrees during early childhood. It often involutes during late childhood. Obstructive adenoid tissue can be related to nasal obstruction symptoms (snoring), eustachian tube dysfunction, and chronic sinusitis. Adenoidectomy is one of the most common surgical procedures done in children.

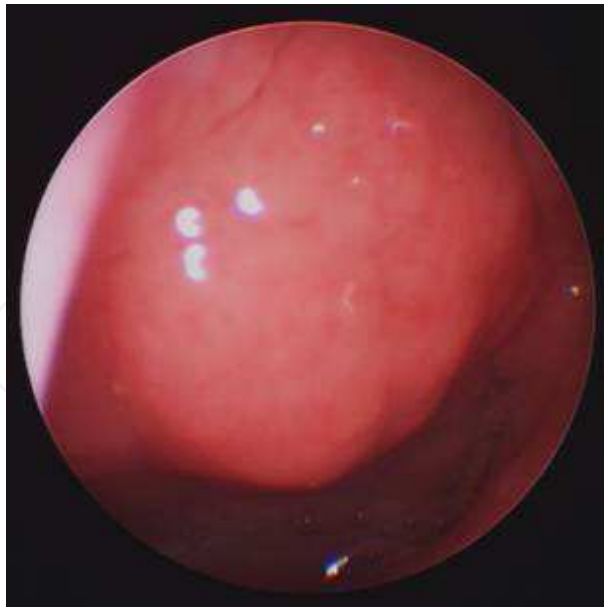

Fig. 6. Adenoid tissue, nasopharynx

The adenoid tissue can be easily visualized transnasally with a 0 degree endoscope, note the moderate obstruction in this patient.

4.2 Meningocele

A meningocele in the nasopharynx must be kept in the differential diagnosis of pediatric nasopharyngeal masses. It has a cystic appearance, originates intracranially from herniation of meninges, and is filled with cerebral spinal fluid (CSF). A congenital defect in the skull base is usually present, and both CT and MRI are critical for surgical planning.

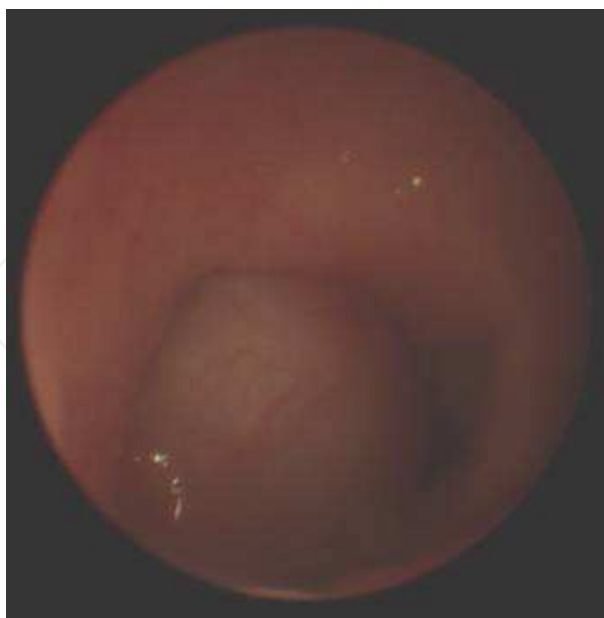

Fig. 7. Cystic mass, nasopharynx

This was a skull base meningocele in a 6 week old child. It was filled with clear fluid (CSF), repair of the skull base defect is necessary to avoid CSF leak and reduce risk of meningitis.

Note the limitation of picture definition and brightness when the surgeon has to use a smaller diameter telescope lens.

4.3 Juvenile Nasopharyngeal Angiofibroma (JNA)

JNA is a benign vascular tumor that arises in the nasopharynx of adolescent males. It often presents with unilateral recurrent epistaxis or nasal obstruction. JNAs originate from the sphenopalatine foramen, commonly extend to the nasal cavity and nasopharynx, and can also extend to the pterygopalatine fossa, infratemporal fossa, orbit, or intracranially. Transnasal rigid or flexible endoscopy typically gives good visualization of the lesion. JNAs can often be removed with minimally invasive endoscopic surgery (Douglas, 2006), while some require traditional open surgical approaches (Bales, 2002).

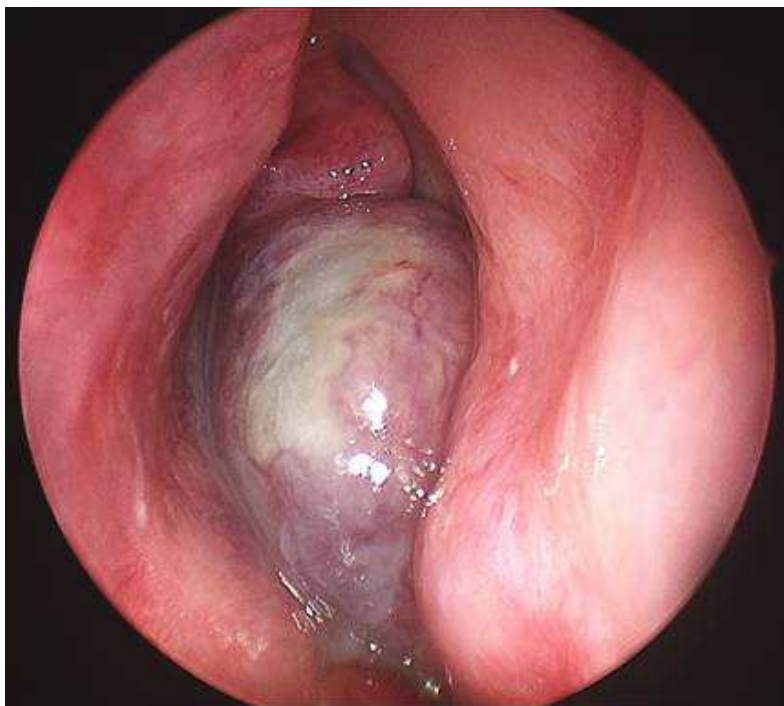


Fig. 8. Right nasal cavity

A JNA originating from the right sphenopalatine foramen, some tumor necrosis is present (white) after pre-resection arterial embolization.

4.4 Nasopharyngeal hamartoma

A hamartoma is a benign, abnormal proliferation of normal tissue. It can be composed of tissue from all 3 germ layers. In the head and neck region they can be found in the oral cavity, nasal cavity, and nasopharynx (Hulsmann, 2009). The overall incidence of nasal hamatomas is 1 in 20,000 to 40,000 live births (Harley, 1991).

5. Abnormalities of the oropharynx

5.1 Lingual Thyroglossal Duct Cyst

Thyroglossal duct cysts (TGDCs) are congenital and can arise at any point along the typical path of the thyroid gland during embryogenesis. Initially formed in the midline base of

tongue, the thyroid gland descends to the final location low in the anterior midline of the neck. TGDC is the most common congenital pediatric neck mass (Koeller, 1999). When found in the oropharynx at the base of tongue, these lesions are termed lingual TGDCs. Transnasal flexible fiberoptic laryngoscopy can often visualize these at the tongue base. Endoscopic surgery for removal has also been described (Burkhart, 2009). Proper diagnosis and treatment is important as swelling or growth can lead to airway obstruction (Kuint, 1997; Fu, 2008).

5.2 Vallecular cyst

A vallecular cyst is simple cyst, typically lined with respiratory epithelium and mucous glands, which forms on the lingual surface of the epiglottis (Gutierrez, 1999). They typically present with stridor, feeding problems, and upper airway obstruction (Gluckman, 1992, LaBagnara, 1989). They can be visualized and diagnosed with flexible fiberoptic laryngoscopy. Marsupialization of the cyst is typically curative.

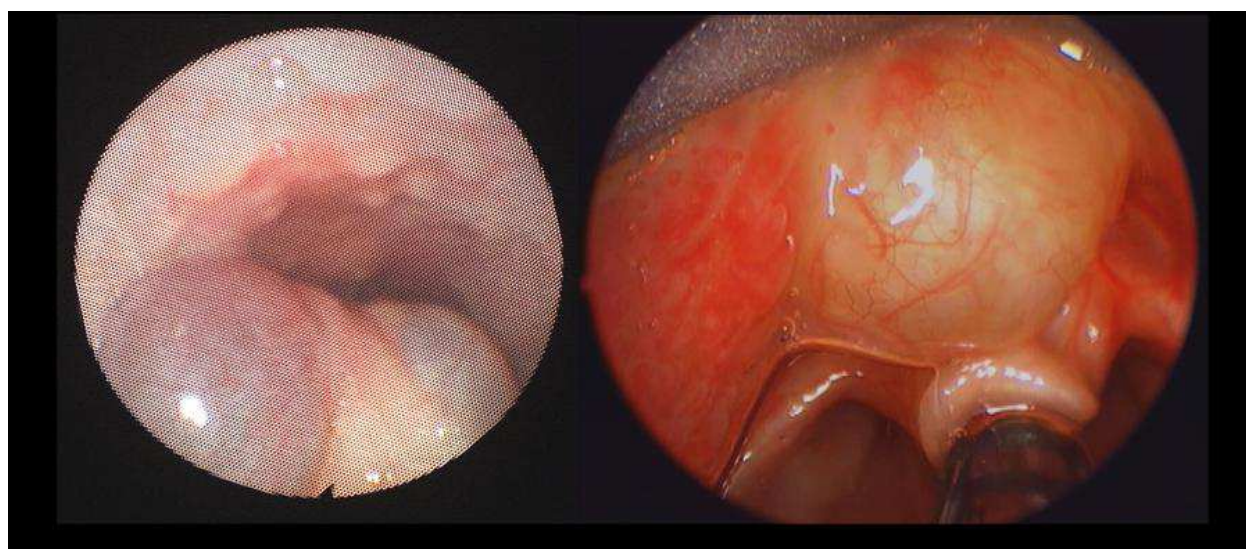


Fig. 9. Vallecular Cyst

On left, using a flexible fiberoptic laryngoscope placed into the nasopharynx (looking down at the tongue base), a large cystic mass originating from vallecula. Posteriorly there is evidence of cobblestoning of the pharyngeal wall. On right a vallecular cyst in a neonate which caused an apparent life-threatening event (ALTE).

6. Abnormalities of the hypopharynx

6.1 Pyriform sinus tracts

Tracts originating from the pyriform sinus within the hypopharynx have also been referred to as third or fourth branchial sinuses, fistulas, or remnants. The vast majority are left-sided, but rarely can occur on the right or be bilateral. These can be the etiology of recurrent neck abscesses or thyroiditis. Treatment options include cauterization of the sinus orifice and definitive surgical excision of the tract including thyroid lobectomy. Recently, endoscopic cauterization has been advocated as the initial treatment option as it carries less potential morbidity than open excision. (Chen, 2009; Verret, 2004)

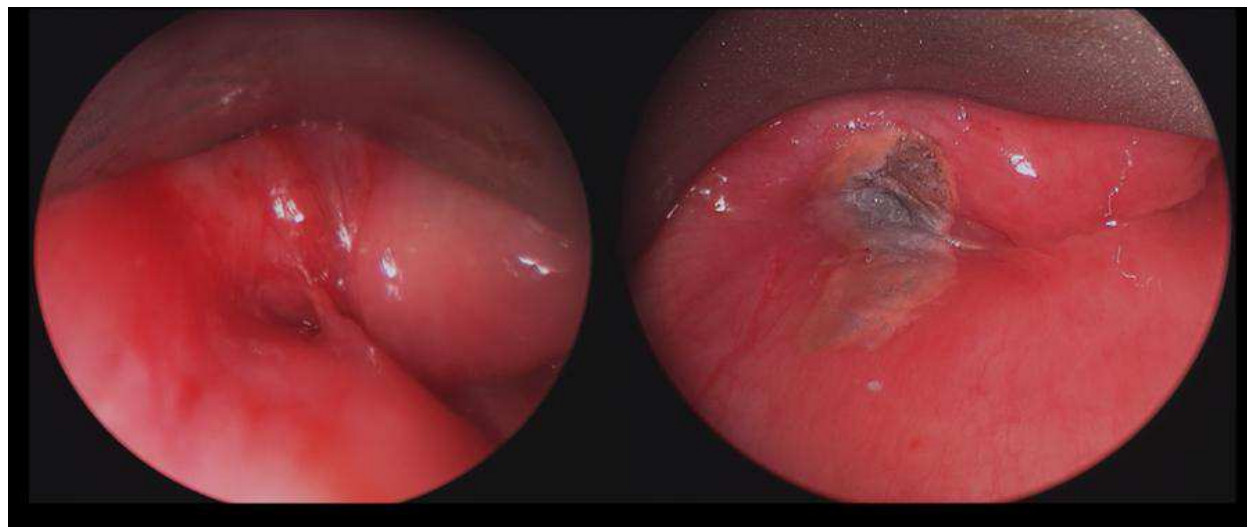


Fig. 10. Pyriform sinus fistula

On the left, note the fistula opening in the left pyriform sinus. On the right, endoscopic cautery was performed using silver nitrate to obliterate the opening which is the source of bacterial contamination of the tract.

7. Abnormalities of the larynx

7.1 Supraglottis and glottis

Flexible fiberoptic laryngoscopy can be used for excellent visualization of the supraglottis and glottis. This is often done initially in the outpatient clinic setting as this procedure is very well tolerated in awake infants and children. Laryngomalacia is the most common congenital laryngeal anomaly causing stridor in infants (Thompson, 2007). Inspiration leads to dynamic collapse of supraglottic structures, the cause of the upper airway obstruction and stridor. Failure of the primitive larynx to recanalize during the tenth week of embryogenesis can lead to laryngeal web formation (McGill, 2000). As they are most

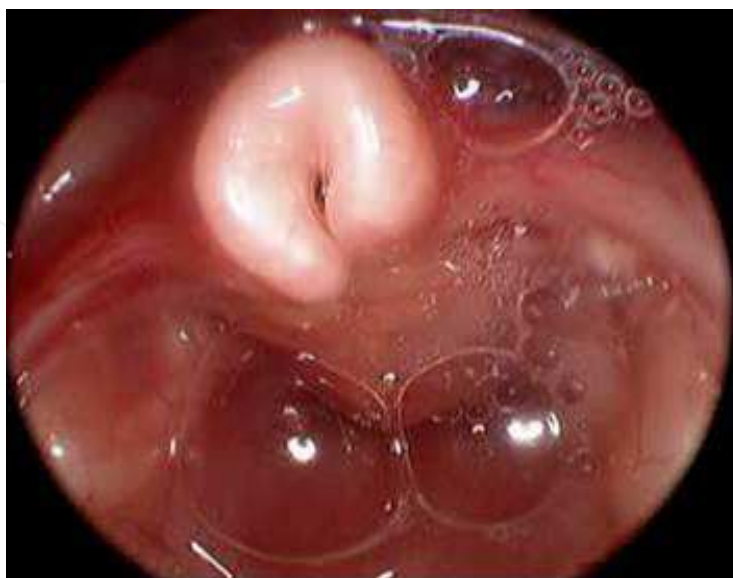

Fig. 11. Laryngomalacia

common at the level of the glottis with variable extension to the subglottis, symptoms include a weak voice and/or upper airway obstruction. Saccular cysts and laryngoceles also are abnormal dilations of the laryngeal saccule that contain either mucoid fluid or air respectively. They can present as swellings in the area of the false vocal fold as seen on flexible fiberoptic laryngoscopy. These relatively rare lesions have been characterized in detail in the literature (Holinger, 1978; DeSanto, 1970). Vocal cord paralysis is best assessed on awake flexible fiberoptic laryngoscopy. Static evaluation of the posterior larynx with a probe is necessary to look for a laryngeal cleft (type I-IV). Children can present with symptoms of stridor, aspiration, and/or respiratory distress (Rahbar 2006). While all type IV clefts require open surgical repair, correction can be done endoscopically in type I-II clefts, and even some type III clefts (Garabedian 2010).

Note the “omega” or “tubular” shaped epiglottis. The aryepiglottic folds are shortened, pulling arytenoids anteriorly. Collapse on inspiration causes stridor and can be directly correlated in the office setting. In severe cases, on awake flexible fiberoptic laryngoscopy the vocal cords cannot be visualized due to this supraglottic obstruction. Supraglottoplasty can be performed in severe cases with failure to thrive or respiratory compromise.

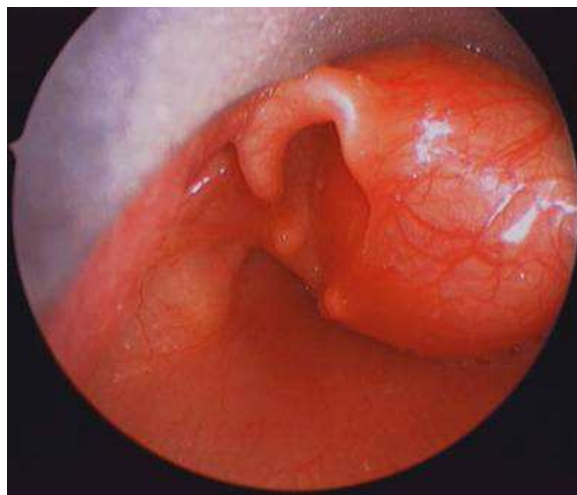


Fig. 12. Right saccular cyst

Note the significant upper airway obstruction that can be present.

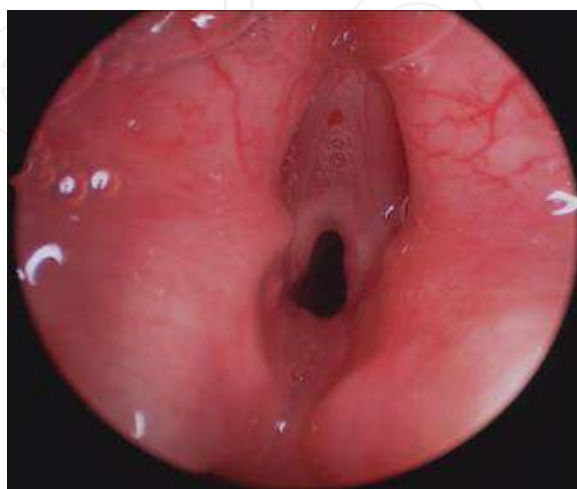


Fig. 13. Glottic web

The vocal cords have limited mobility due to an anterior glottic web. This narrows the glottic airway causing biphasic stridor. Endoscopic surgical repair can be performed.

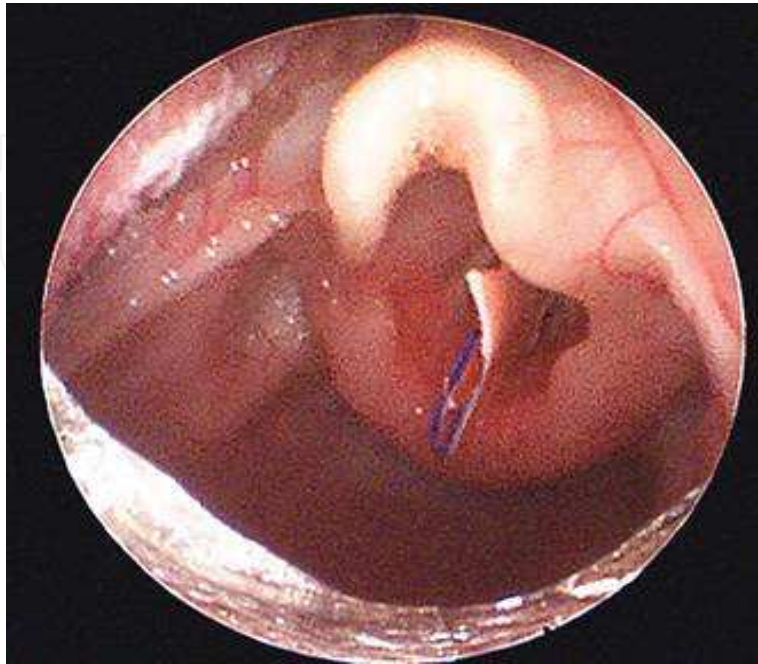


Fig. 14. Glottic foreign body

A pencil shaving lodged in the glottis of a child with severe stridor. This was emergently removed in the operating room.

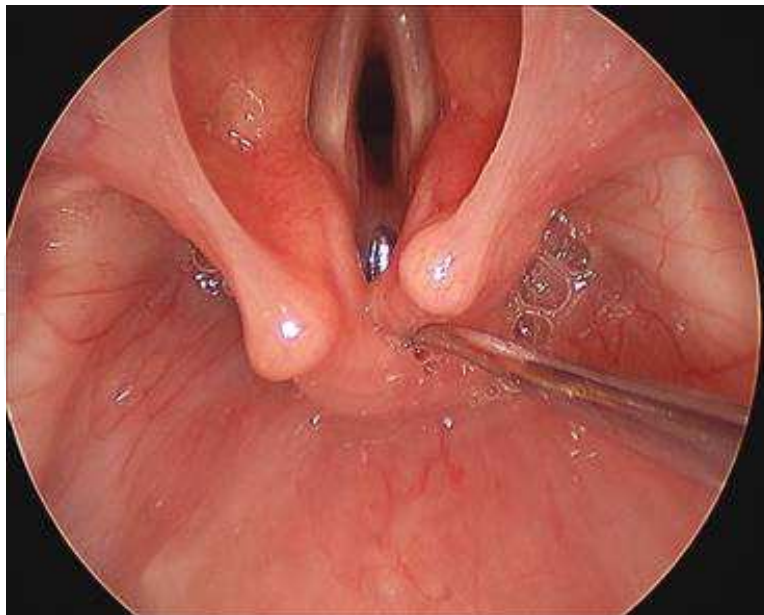


Fig. 15. Normal larynx

A right angle probe can be used to palpate the interarytenoid notch to check for a posterior laryngeal cleft. It is also helpful to palpate the posterior cricoid lamina with a right angle probe to ensure there is no divot or absence of cartilage.

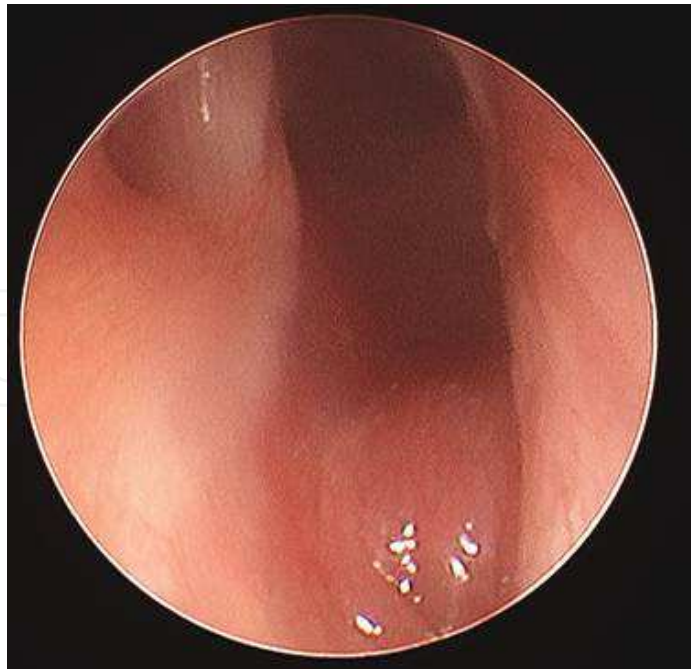

Fig. 16. Type I posterior laryngeal cleft

The interarytenoid notch is below the level of the true vocal cord. With palpation, the cricoids cartilage is intact. Aspiration of thin liquids often can occur, but many infants do well with a thickened diet. If aspiration fails to resolve with time, endoscopic repair can be performed.

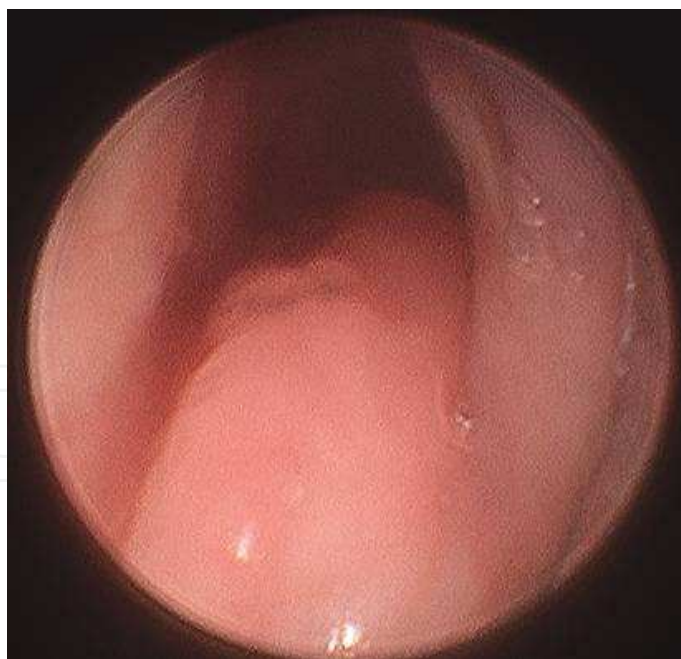

Fig. 17. Type III posterior laryngeal cleft

The cleft extends down through the cricoid cartilage below the vocal cords. With palpation, there is only a cleft of soft tissue posteriorly, no posterior cricoid lamina. It does not enter the thoracic cavity, so is therefore a type III. This cleft is a direct connection between the esophagus and trachea leading to aspiration with feeding.

7.2 The subglottis

The subglottic region is generally difficult to visualize on awake flexible fiberoptic laryngoscopy in the office setting. Subglottic stenosis can be congenital or acquired, and open laryngotracheal reconstruction has been successful (Cotton 2000). Endoscopic management including dilation, laser, mitomycin c, and steroids have also been used (Quensel 2011).

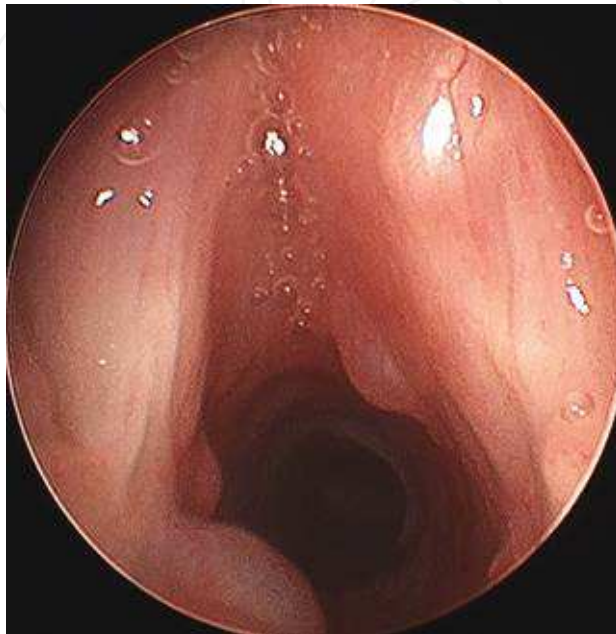


Fig. 18. Glottic and subglottic cysts

Commonly as a result of intubation, sometimes ductal cysts form from occluded submucosal glands. These can be asymptomatic if small.

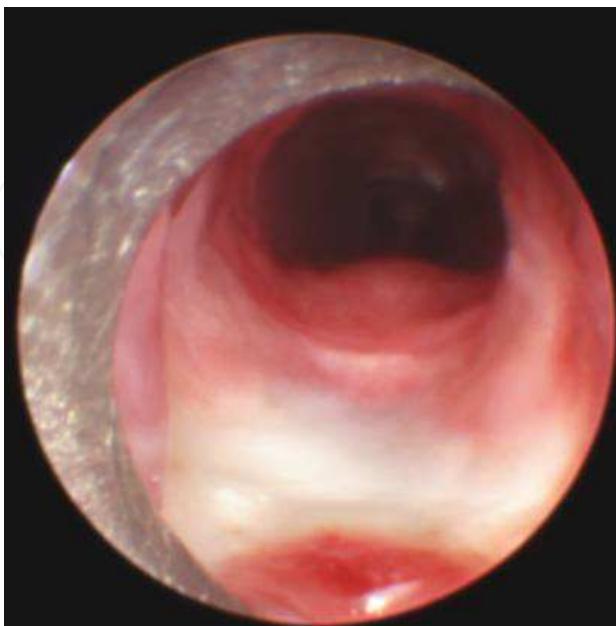

Fig. 19. Intubation injury

Erosion of mucosa overlying posterior cricoid lamina, due to direct pressure from endotracheal tube. Exposed cartilage is seen posteriorly (white). This can lead to subglottic stenosis after intubation.

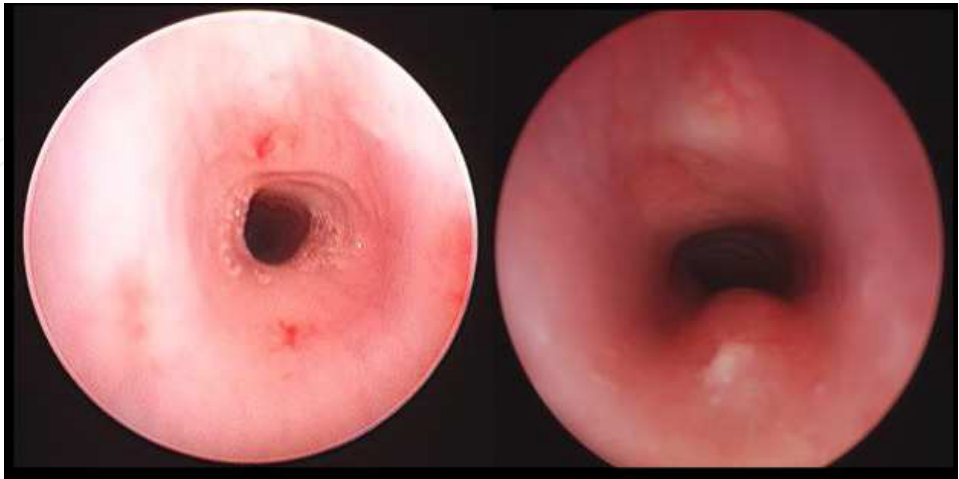


Fig. 20. Congenital subglottic stenosis

Note the narrowing below the vocal cords at the level of the cricoid cartilage and first tracheal ring, Grade III in this patient. This same patient, after a laryngotracheal reconstruction with anterior thyroid ala cartilage graft, the post-operative bronchoscopy shows a well-mucosalized graft.

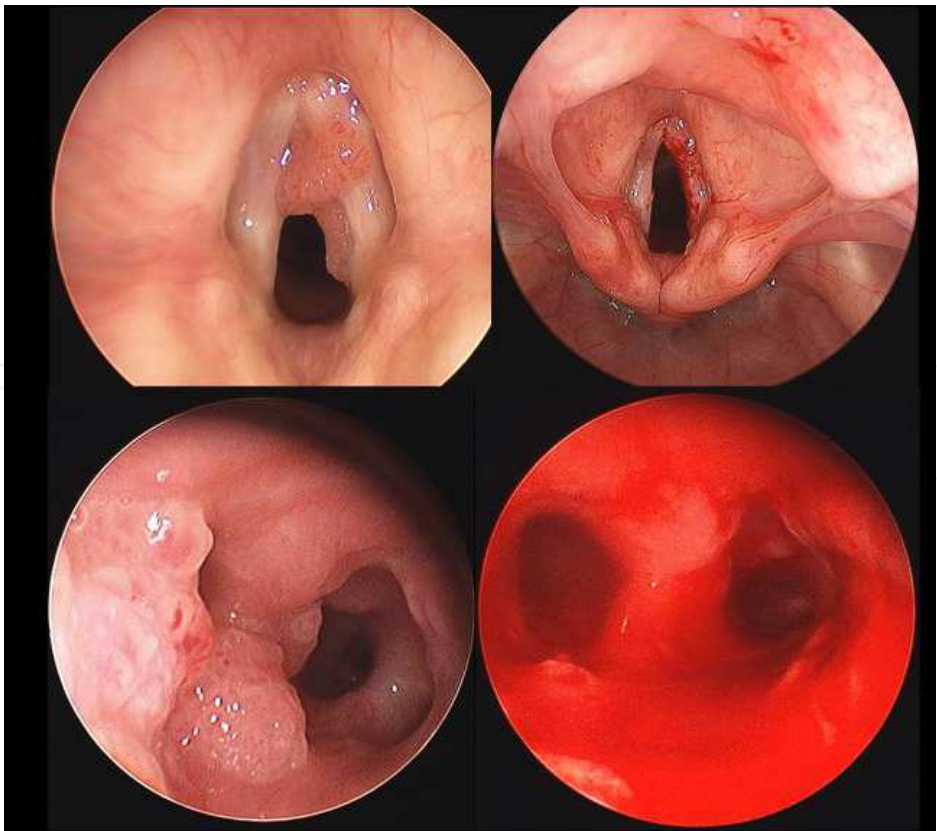


Fig. 21. Laryngeal and tracheal papilloma

Top left: Endoscopic view of the true vocal cords, showing laryngeal papilloma of the right true vocal cord; Top right: After endoscopic removal using microdebrider. Bottom left, tracheal papilloma at the carina; bottom right, after endoscopic surgical removal.

7.3 Recurrent Respiratory Papillomatosis (RRP)

RRP is the most common benign neoplasm of the larynx and the second most common cause of hoarseness in children. It is caused by human papilloma virus and can have either childhood or adult onset. There is no cure for RRP and malignant transformation can rarely occur. Due to location and airway obstruction, surgical debulking is necessary in symptomatic patients. Adjuvant therapies include cidofovir, acyclovir, ribavirin, interferon, photodynamic therapy, indole-3-carbinol, cox-2 inhibitors, and retinoids. A quadravalent HPV vaccine is available and may help reduce the incidence of RRP in the future. (Derkay, 2008). Extra-esophageal reflux has been linked to the disease course in some patients with RRP (McKenna, 2005; Pignatari, 2007).

8. Abnormalities of the tracheobronchial tree

8.1 Tracheobronchomalacia

A condition where there is collapse of the lumen due either intrinsic (primary) or extrinsic factors (secondary). The extraluminal pressure exceeds the intraluminal pressure and can be most significant on expiration. This can cause significant airway obstruction (Austin, 2003; Boogaard 2005). Tracheomalacia is commonly seen in patients with tracheoesophageal fistula.

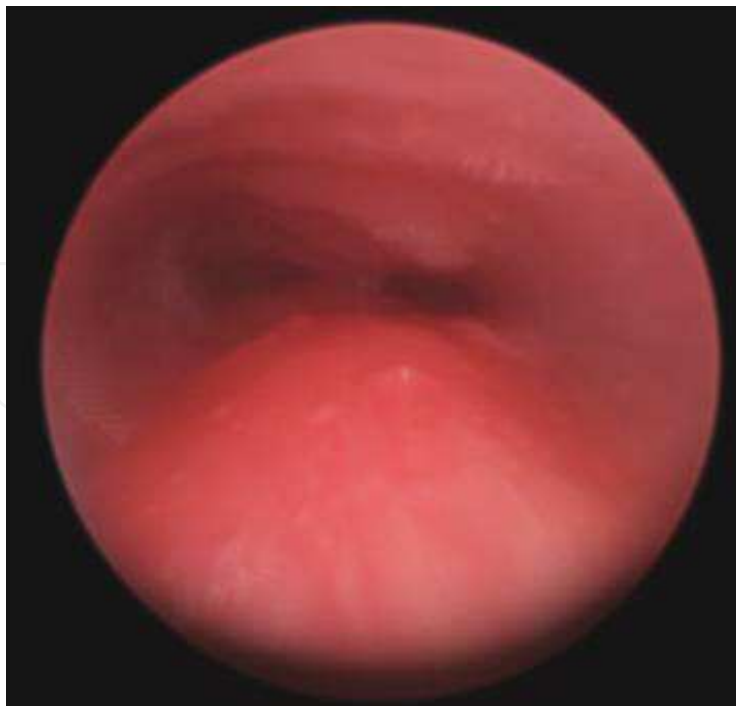

Fig. 22. Severe tracheomalacia

Narrowing of tracheal lumen is seen in a child with tracheoesophageal fistula.

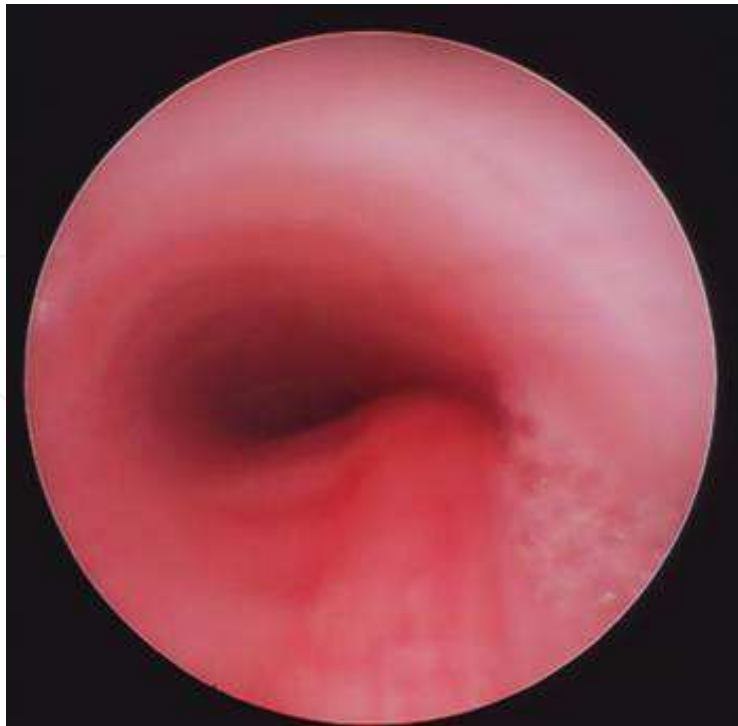

Fig. 23. Severe tracheomalacia

Narrowing of the tracheal lumen is seen with a coin in the esophagus causing external compression of the tracheal airway.

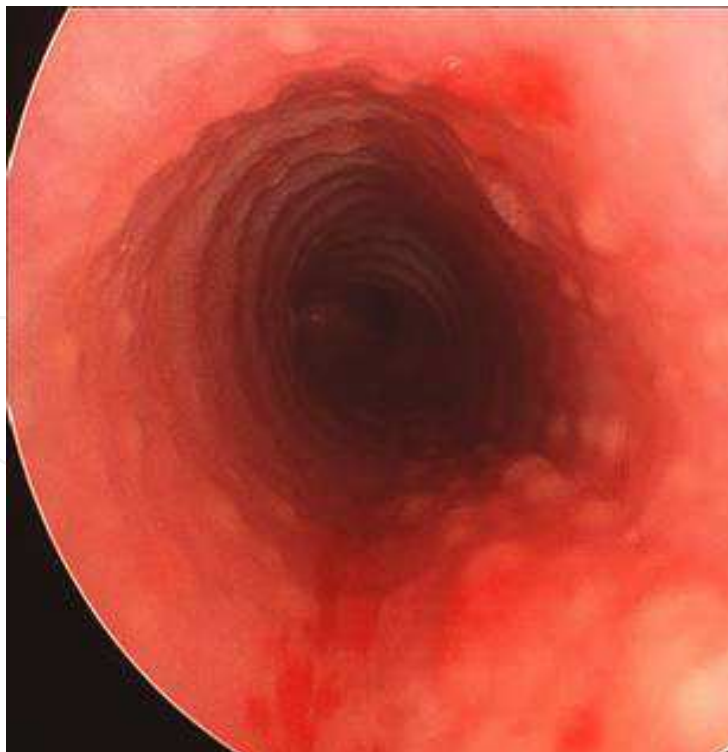

Fig. 24. Chronic follicular tracheitis

Raised mucosal follicles, often seen with acid reflux into the airway.

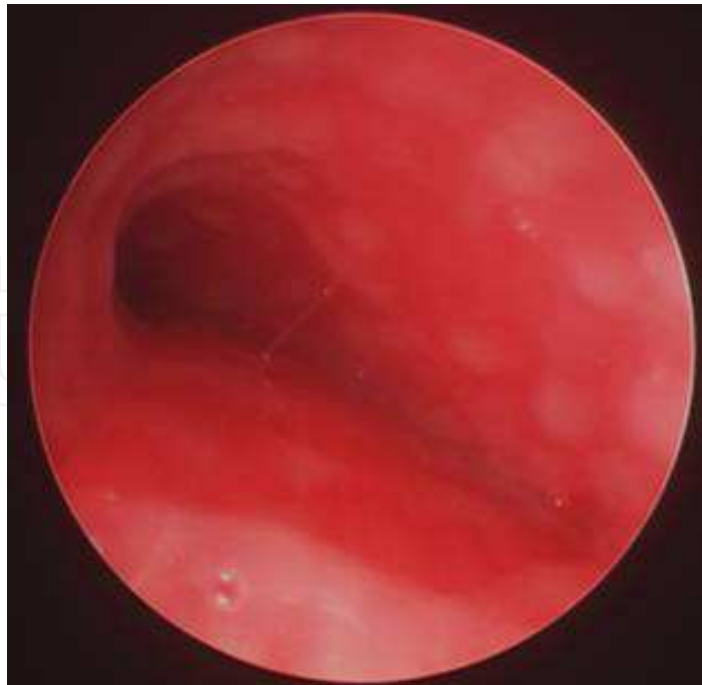

Fig. 25. Bronchomalacia

Narrowing of the left bronchial lumen is seen through a rigid bronchoscope as well as follicular changes of the mucosa.

8.2 Complete tracheal rings

A rare condition characterized by complete cartilaginous rings of the trachea, which can be of short segments or the entire length of the trachea. The surgical management of this condition has evolved over the past two decades (Backer, 2001). Currently, reconstruction methods can include excision of short segments with end-to-end anastomosis and slide tracheoplasty for longer segments (Russell, 2010). A slide tracheoplasty, unless done in a cervical tracheal location, is often done on cardiopulmonary bypass. Often a vascular anomaly, such as pulmonary artery sling is present, and it can be repaired simultaneously (Rutter 2003). Tracheal reconstruction has been successful in even patients with unilateral lung agenesis or severe hypoplasia (Backer, 2009).

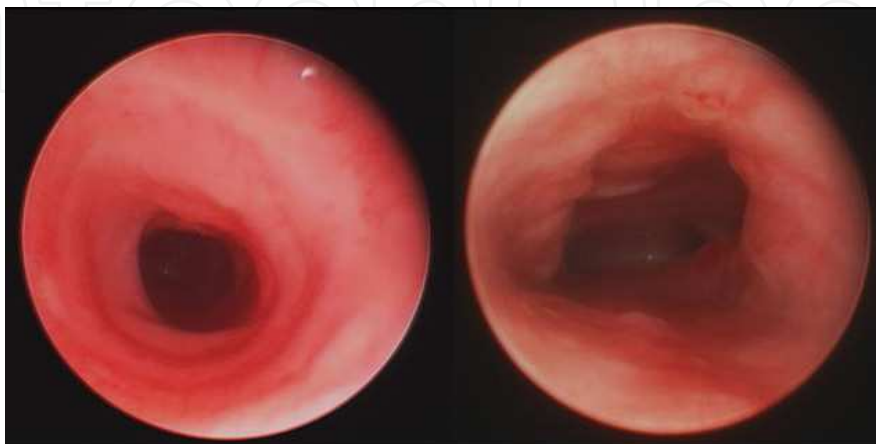


Fig. 26. Complete tracheal rings

Note the concentric complete rings, absent membranous trachea posteriorly, resulting in a distal tracheal stenosis. On the right, the same patient 6 weeks after undergoing a slide tracheoplasty

8.3 Airway hemangioma

A hemangioma is a benign, vascular tumor. Rarely, these arise in the airway and can cause airway obstruction in the first year of life. Treatment options have included endoscopic resection, open resection, systemic or injectable steroids, tracheostomy (to bypass obstruction), interferon, observation (Rahbar, 2004) and more recently, propranolol therapy (Maturo, 2010).

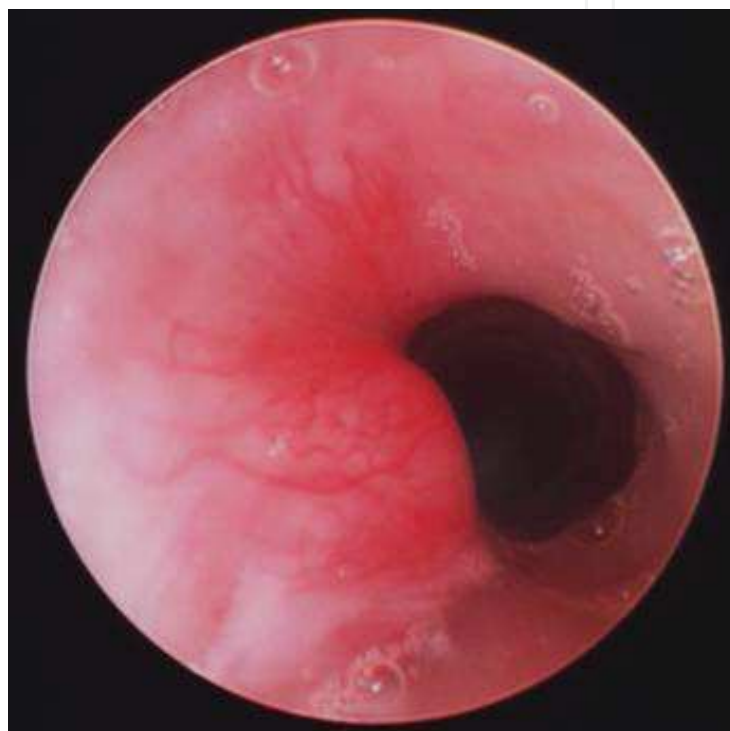


Fig. 27. Tracheal hemangioma

A left-posterior tracheal hemangioma at the level of the 3rd tracheal ring. These are more commonly seen in the subglottis.

8.4 Tracheobronchial foreign body and plastic bronchitis

Bronchial foreign bodies can be life-threatening due to acute airway obstruction. Anatomically, an inhaled foreign body is most likely to enter the right bronchial tree in children of all ages as the proximal right main bronchus is generally steeper and wider than the left (Tahir, 2009). Rigid bronchoscopy is not only diagnostic but also therapeutic using optical forceps to remove foreign bodies under direct visualization. While ventilating the patient through the scope. Communication between the surgeon and anesthesiologist is critical for optimal results (Zur, 2009).

Plastic bronchitis is rare condition where bronchial casts form resulting in life-threatening obstruction. This has been associated with congenital heart disease, particularly after patients undergo a Fontan procedure (Tzifa, 2005; Ishman, 2003; Preciado,

2010). Other causes of bronchial casts include cystic fibrosis, asthma, and influenza H1N1 (Terano 2010). The exact etiology for these is unknown, and treatment includes immediate endoscopic removal of the airway obstruction. Various adjuvant therapies including chest physiotherapy, aerosolized urokinase and tissue plasminogen activator, corticosteroids, DNase, and macrolides have been used with limited success (Brogan, 2002; Preciado, 2010)

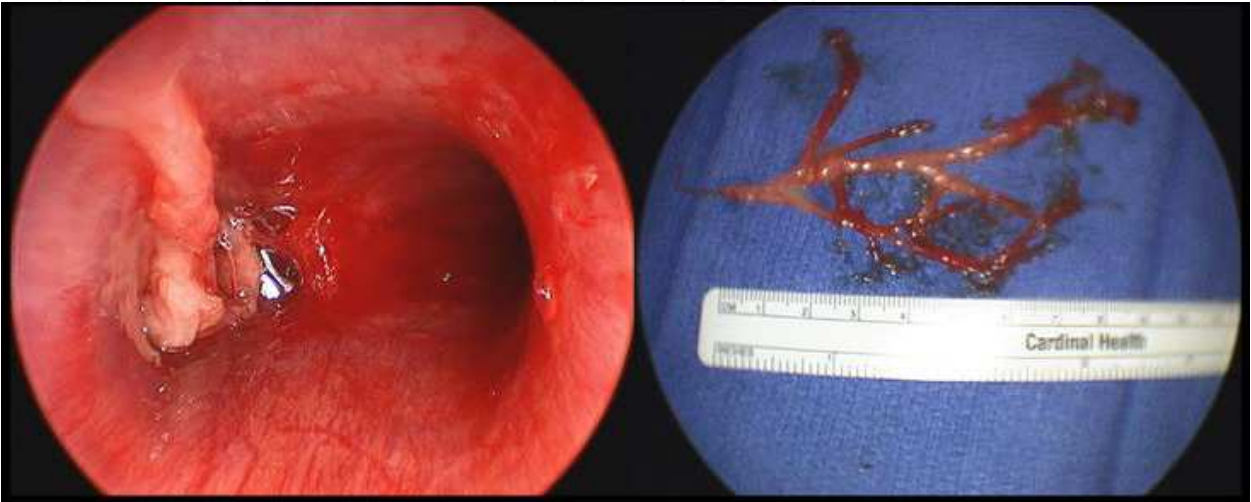


Fig. 28. Plastic bronchitis
Cast formation within the left bronchus before (left) and after (right) endoscopic removal.

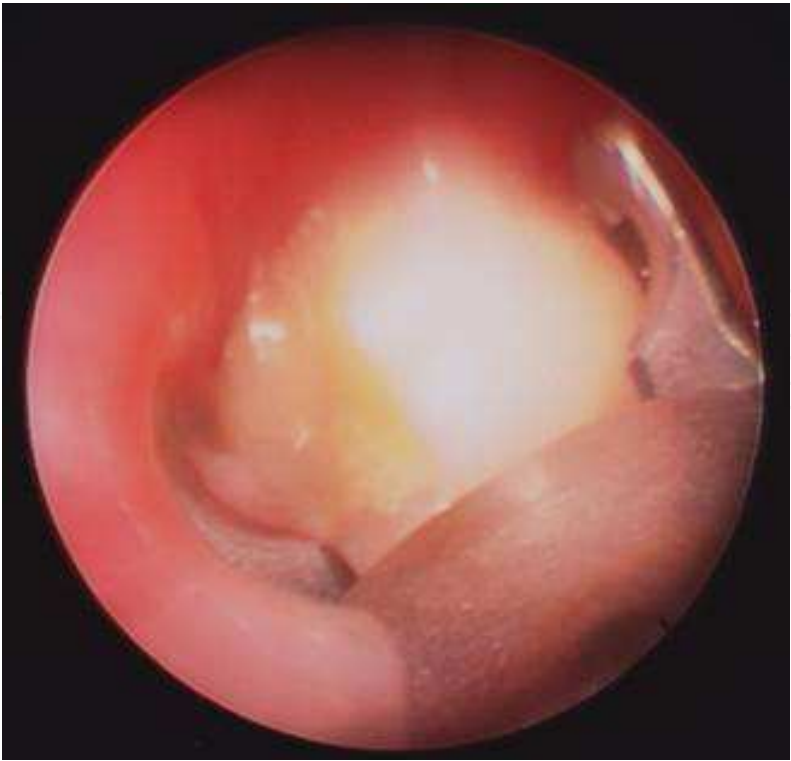

Fig. 29. Bronchial foreign body removal

The optical graspers (telescope with attached camera) through a rigid bronchoscope are used to remove a molar tooth unusually lodged in the the left upper bronchus.

8.5 Vascular rings

A “vascular ring” refers to any anomaly of the aortic arch that leads to compression of the trachea, and/or esophagus. Most children will present early in life with breathing and feeding difficulties. Only the double aortic arch and right aortic arch with left ligament are true complete vascular rings; the innominate artery compression and pulmonary artery sling are incomplete from an anatomical standpoint. Endoscopic evaluation with laryngoscopy and bronchoscopy is helpful to assess the degree of airway compression (Shah, 2007; Russell, 2010).

The double aortic arch occurs when two arches arise at the ascending aorta, pass around both sides of the trachea and esophagus, to join the descending aorta. The right aortic arch occurs when the apex of the arch is to the right side of the trachea; various configurations are possible. Innominate artery compression of the anterior trachea is often due to a more left and posterior origination from the aorta (Russell 2010). If severe, suspension of the innominate artery to the posterior aspect of the sternum has been performed (Moes, 1975). Bronchoscopic evaluation after suspension confirms adequate relief. Pulmonary artery sling occurs when the left pulmonary artery originates from the right pulmonary artery, coursing around the right main bronchus and distal trachea, between the trachea and esophagus, to return to the left side. Pulmonary artery sling is often associated with complete tracheal rings and surgical correction of both can be performed simultaneously (Russell 2010).

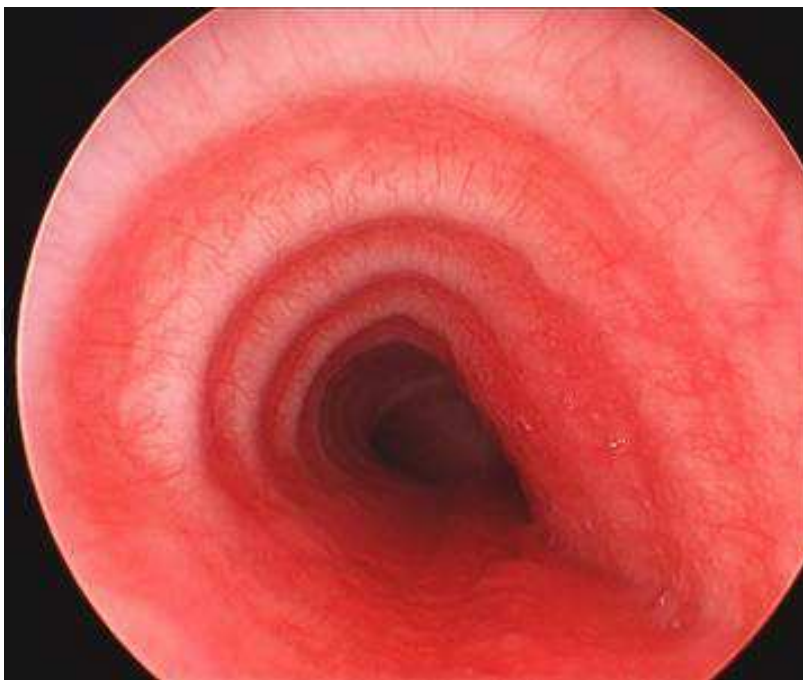


Fig. 30. Tracheomalacia, secondary to vascular ring

A child with a double aortic arch, prior to surgical repair, note the external tracheal compression causing airway obstruction.

8.6 Blunt laryngotracheal trauma

Blunt trauma to the anterior neck can be a life-threatening injury. Significant injury in children is not common as the larynx is higher in location within the neck, and the laryngeal cartilage structures are more flexible than adults. Symptoms can include hoarseness, stridor, respiratory distress, subcutaneous emphysema, dysphagia, neck pain, and hemoptysis. In a stable child with suspected injury, flexible endoscopic evaluation of the larynx can be performed to determine if further surgical intervention would be needed (Gold, 1997). Endotracheal intubation of such cases can be catastrophic resulting in laryngotracheal separation and death (Bernat, 2005). In severe injury, tracheotomy is required for obtaining a stable airway. Children often cannot undergo an awake tracheotomy procedure under local anesthesia, so rigid bronchoscopy using a ventilating scope is critical in securing the airway prior to tracheotomy and open surgical repair.

9. Conclusion

The advancement in endoscopic technology combined with contemporary surgical applications has helped progress the field of diagnostic airway evaluation in children, as well as therapeutic interventions. Certainly, with enhanced visualization, the ability to more safely manage the airway allows for optimal care of children with congenital and acquired anomalies. There is a definite role for endoscopic surgery in pediatric otolaryngology.


10. References

- Austin J, Ali T. Tracheomalacia and bronchomalacia in children: pathophysiology, assessment, treatment and anaesthesia management. *Paediatr Anaesth* 2003;13:3-11.
- Backer CL, Kelle AM, Mavroudis C, Rigsby CK, Kaushal S, Holinger LD. Tracheal reconstruction in children with unilateral lung agenesis or severe hypoplasia. *Ann Thorac Surg* 2009;88:624-30; discussion 30-1.
- Backer CL, Mavroudis C, Gerber ME, Holinger LD. Tracheal surgery in children: an 18-year review of four techniques. *Eur J Cardiothorac Surg* 2001;19:777-84.
- Bajaj PS, Bailey BN. Stenosis of the nostrils: a report of three cases. *Br J Plast Surg* 1969;22:269-73.
- Bales C, Kotapka M, Loevner LA, et al. Craniofacial resection of advanced juvenile nasopharyngeal angiofibroma. *Arch Otolaryngol Head Neck Surg* 2002;128:1071-8.
- Bernat RA, Zimmerman JM, Keane WM, Pribitkin EA. Combined laryngotracheal separation and esophageal injury following blunt neck trauma. *Facial Plast Surg* 2005;21:187-90.
- Boogaard R, Huijsmans SH, Pijnenburg MW, Tiddens HA, de Jongste JC, Merkus PJ. Tracheomalacia and bronchomalacia in children: incidence and patient characteristics. *Chest* 2005;128:3391-7.
- Brogan TV, Finn LS, Pyskaty DJ, Jr., et al. Plastic bronchitis in children: a case series and review of the medical literature. *Pediatr Pulmonol* 2002;34:482-7.

- Brown OE, Pownell P, Manning SC. Choanal atresia: a new anatomic classification and clinical management applications. *Laryngoscope* 1996;106:97-101.
- Burkart CM, Richter GT, Rutter MJ, Myer CM, 3rd. Update on endoscopic management of lingual thyroglossal duct cysts. *Laryngoscope* 2009;119:2055-60.
- Chen EY, Inglis AF, Ou H, et al. Endoscopic electrocauterization of pyriform fossa sinus tracts as definitive treatment. *Int J Pediatr Otorhinolaryngol* 2009;73:1151-6.
- Cotton RT. Management of subglottic stenosis. *Otolaryngol Clin North Am* 2000;33:111-30.
- Derkay CS, Wiatrak B. Recurrent respiratory papillomatosis: a review. *Laryngoscope* 2008;118:1236-47.
- DeSanto LW, Devine KD, Weiland LH. Cysts of the larynx--classification. *Laryngoscope* 1970;80:145-76.
- Deutsch E, Kaufman M, Eilon A. Transnasal endoscopic management of choanal atresia. *Int J Pediatr Otorhinolaryngol* 1997;40:19-26.
- Diamantopoulos, II, Jones NS. The investigation of nasal septal perforations and ulcers. *J Laryngol Otol* 2001;115:541-4.
- Douglas R, Wormald PJ. Endoscopic surgery for juvenile nasopharyngeal angiofibroma: where are the limits? *Curr Opin Otolaryngol Head Neck Surg* 2006;14:1-5.
- Franco LP, Camargos PA, Becker HM, Guimaraes RE. Nasal endoscopic evaluation of children and adolescents with cystic fibrosis. *Braz J Otorhinolaryngol* 2009;75:806-13.
- Fu J, Xue X, Chen L, Fan G, Pan L, Mao J. Lingual thyroglossal duct cyst in newborns: previously misdiagnosed as laryngomalacia. *Int J Pediatr Otorhinolaryngol* 2008;72:327-32.
- Garabedian EN, Pezzettigotta S, Leboulanger N, et al. Endoscopic surgical treatment of laryngotracheal clefts: indications and limitations. *Arch Otolaryngol Head Neck Surg* 2010;136:70-4.
- Giacomini PG, Ferraro S, Di Girolamo S, Ottaviani F. Large Nasal Septal Perforation Repair by Closed Endoscopically Assisted Approach. *Ann Plast Surg* 2011;66(6):633-6.
- Gluckman PG, Chu TW, van Hasselt CA. Neonatal vallecular cysts and failure to thrive. *J Laryngol Otol* 1992;106:448-9.
- Gold SM, Gerber ME, Shott SR, Myer CM, 3rd. Blunt laryngotracheal trauma in children. *Arch Otolaryngol Head Neck Surg* 1997;123:83-7.
- Gutierrez JP, Berkowitz RG, Robertson CF. Vallecular cysts in newborns and young infants. *Pediatr Pulmonol* 1999;27:282-5.
- Harley EH. Pediatric congenital nasal masses. *Ear Nose Throat J* 1991;70:28-32.
- Hartzell LD, Richter GT, Glade RS, Bower CM. Accuracy and safety of tracheoscopy for infants in a tertiary care clinic. *Arch Otolaryngol Head Neck Surg* 2010;136:66-9.
- Hedlund G. Congenital frontonasal masses: developmental anatomy, malformations, and MR imaging. *Pediatr Radiol* 2006;36:647-62; quiz 726-7.
- Hengerer AS, Brickman TM, Jeyakumar A. Choanal atresia: embryologic analysis and evolution of treatment, a 30-year experience. *Laryngoscope* 2008;118:862-6.
- Holinger LD, Barnes DR, Smid LJ, Holinger PH. Laryngocele and saccular cysts. *Ann Otol Rhinol Laryngol* 1978;87:675-85.

- Hughes GB, Sharpino G, Hunt W, Tucker HM. Management of the congenital midline nasal mass: a review. *Head Neck Surg* 1980;2:222-33.
- Hulsmann AR, de Bont N, den Hollander JC, Borgstein JA. Hamartomas of the oro- and nasopharyngeal cavity in infancy: two cases and a short review. *Eur J Pediatr* 2009;168:999-1001.
- Ishman S, Book DT, Conley SF, Kerschner JE. Plastic bronchitis: an unusual bronchoscopic challenge associated with congenital heart disease repair. *Int J Pediatr Otorhinolaryngol* 2003;67:543-8.
- Jablon JH, Hoffman JF. Birth trauma causing nasal vestibular stenosis. *Arch Otolaryngol Head Neck Surg* 1997;123:1004-6.
- Jatana KR, Oplatek A, Elmaraghy CA. Bilateral vestibular stenosis from nasal continuous positive airway pressure/cannula oxygen administration. *Otolaryngol Head Neck Surg* 2008;138:690-1.
- Jatana KR, Oplatek A, Stein M, Phillips G, Kang DR, Elmaraghy CA. Effects of nasal continuous positive airway pressure and cannula use in the neonatal intensive care unit setting. *Arch Otolaryngol Head Neck Surg* 2010;136:287-91.
- Karen M, Chang E, Keen MS. Auricular composite grafting to repair nasal vestibular stenosis. *Otolaryngol Head Neck Surg* 2000;122:529-32.
- Kim B, Park SH, Min HS, Rhee JS, Wang KC. Nasal chondromesenchymal hamartoma of infancy clinically mimicking meningoencephalocele. *Pediatr Neurosurg* 2004;40:136-40.
- Koeller KK, Alamo L, Adair CF, Smirniotopoulos JG. Congenital cystic masses of the neck: radiologic-pathologic correlation. *Radiographics* 1999;19:121-46; quiz 52-3.
- Kuint J, Horowitz Z, Kugel C, Topper L, Birenbaum E, Linder N. Laryngeal obstruction caused by lingual thyroglossal duct cyst presenting at birth. *Am J Perinatol* 1997;14:353-6.
- LaBagnara J, Jr. Cysts of the base of the tongue in infants: an unusual cause of neonatal airway obstruction. *Otolaryngol Head Neck Surg* 1989;101:108-11.
- Lanier B, Kai G, Marple B, Wall GM. Pathophysiology and progression of nasal septal perforation. *Ann Allergy Asthma Immunol* 2007;99:473-9; quiz 80-1, 521.
- Maturo S, Hartnick C. Initial experience using propranolol as the sole treatment for infantile airway hemangiomas. *Int J Pediatr Otorhinolaryngol*;74:323-5.
- McGill TJ. Congenital anomalies of the larynx. London: Arnold Publisher; 2000.
- McKenna M, Brodsky L. Extraesophageal acid reflux and recurrent respiratory papilloma in children. *Int J Pediatr Otorhinolaryngol* 2005;69:597-605.
- McMurray JS, Holinger LD. Otolaryngic manifestations in children presenting with apparent life-threatening events. *Otolaryngol Head Neck Surg* 1997;116:575-9.
- Moes CA, Izukawa T, Trusler GA. Innominate artery compression of the Trachea. *Arch Otolaryngol* 1975;101:733-8.
- Pignatari SS, Liriano RY, Avelino MA, Testa JR, Fujita R, De Marco EK. Gastroesophageal reflux in patients with recurrent laryngeal papillomatosis. *Braz J Otorhinolaryngol* 2007;73:210-4.
- Preciado D, Verghese S, Choi S. Aggressive bronchoscopic management of plastic bronchitis. *Int J Pediatr Otorhinolaryngol*;74:820-2.

- Quesnel AM, Lee GS, Nuss RC, Volk MS, Jones DT, Rahbar R. Minimally invasive endoscopic management of subglottic stenosis in children: Success and failure. *Int J Pediatr Otorhinolaryngol* 2011;75:652-656.
- Rahbar R, Nicollas R, Roger G, et al. The biology and management of subglottic hemangioma: past, present, future. *Laryngoscope* 2004;114:1880-91.
- Rahbar R, Rouillon I, Roger G, et al. The presentation and management of laryngeal cleft: a 10-year experience. *Arch Otolaryngol Head Neck Surg* 2006;132:1335-41.
- Ramadan H, Ortiz O. Congenital nasal pyriform aperture (bony inlet) stenosis. *Otolaryngol Head Neck Surg* 1995;113:286-9.
- Ramsden JD, Campisi P, Forte V. Choanal atresia and choanal stenosis. *Otolaryngol Clin North Am* 2009;42:339-52, x.
- Russell HM, Backer CL. Pediatric thoracic problems: patent ductus arteriosus, vascular rings, congenital tracheal stenosis, and pectus deformities. *Surg Clin North Am*;90:1091-113.
- Rutter MJ, Cotton RT, Azizkhan RG, Manning PB. Slide tracheoplasty for the management of complete tracheal rings. *J Pediatr Surg* 2003;38:928-34.
- Salvado AR, Wang MB. Treatment of complete nasal vestibule stenosis with vestibular stents and mitomycin C. *Otolaryngol Head Neck Surg* 2008;138:795-6.
- Shah RK, Mora BN, Bacha E, et al. The presentation and management of vascular rings: an otolaryngology perspective. *Int J Pediatr Otorhinolaryngol* 2007;71:57-62.
- Tahir N, Ramsden WH, Stringer MD. Tracheobronchial anatomy and the distribution of inhaled foreign bodies in children. *Eur J Pediatr* 2009;168:289-95.
- Terano C, Miura M, Fukuzawa R, et al. Three Children with Plastic Bronchitis Associated with 2009 H1n1 Influenza Virus Infection. *Pediatr Infect Dis J*. 2011;30(1):80-2.
- Thompson DM. Abnormal sensorimotor integrative function of the larynx in congenital laryngomalacia: a new theory of etiology. *Laryngoscope* 2007;117:1-33.
- Triglia JM, Nicollas R. Nasal and sinus polyposis in children. *Laryngoscope* 1997;107:963-6.
- Tzifa A, Robards M, Simpson JM. Plastic bronchitis; a serious complication of the Fontan operation. *Int J Cardiol* 2005;101:513-4.
- Verret DJ, McClay J, Murray A, Biavati M, Brown O. Endoscopic cauterization of fourth branchial cleft sinus tracts. *Arch Otolaryngol Head Neck Surg* 2004;130:465-8.
- Weber SA, Ferrari GF. Incidence and evolution of nasal polyps in children and adolescents with cystic fibrosis. *Braz J Otorhinolaryngol* 2008;74:16-20.
- Zielnik-Jurkiewicz B, Olszewska-Sosinska O. The nasal septum deformities in children and adolescents from Warsaw, Poland. *Int J Pediatr Otorhinolaryngol* 2006;70:731-6.
- Zur KB, Litman RS. Pediatric airway foreign body retrieval: surgical and anesthetic perspectives. *Paediatr Anaesth* 2009;19 Suppl 1:109-17.



Advances in Endoscopic Surgery

Edited by Prof. Cornel Iancu

ISBN 978-953-307-717-8

Hard cover, 444 pages

Publisher InTech

Published online 25, November, 2011

Published in print edition November, 2011

Surgeons from various domains have become fascinated by endoscopy with its very low complications rates, high diagnostic yields and the possibility to perform a large variety of therapeutic procedures. Therefore during the last 30 years, the number and diversity of surgical endoscopic procedures has advanced with many new methods for both diagnoses and treatment, and these achievements are presented in this book. Contributing to the development of endoscopic surgery from all over the world, this is a modern, educational, and engrossing publication precisely presenting the most recent development in the field. New technologies are described in detail and all aspects of both standard and advanced endoscopic maneuvers applied in gastroenterology, urogynecology, otorhinolaryngology, pediatrics and neurology are presented. The intended audience for this book includes surgeons from various specialities, radiologists, internists, and subspecialists.

How to reference

In order to correctly reference this scholarly work, feel free to copy and paste the following:

Kris R. Jatana and Jeffrey C. Rastatter (2011). Endoscopy in the Evaluation and Management of the Pediatric Airway, *Advances in Endoscopic Surgery*, Prof. Cornel Iancu (Ed.), ISBN: 978-953-307-717-8, InTech, Available from: <http://www.intechopen.com/books/advances-in-endoscopic-surgery/endoscopy-in-the-evaluation-and-management-of-the-pediatric-airway>

INTECH
open science | open minds

InTech Europe

University Campus STeP Ri
Slavka Krautzeka 83/A
51000 Rijeka, Croatia
Phone: +385 (51) 770 447
Fax: +385 (51) 686 166
www.intechopen.com

InTech China

Unit 405, Office Block, Hotel Equatorial Shanghai
No.65, Yan An Road (West), Shanghai, 200040, China
中国上海市延安西路65号上海国际贵都大饭店办公楼405单元
Phone: +86-21-62489820
Fax: +86-21-62489821

© 2011 The Author(s). Licensee IntechOpen. This is an open access article distributed under the terms of the [Creative Commons Attribution 3.0 License](https://creativecommons.org/licenses/by/3.0/), which permits unrestricted use, distribution, and reproduction in any medium, provided the original work is properly cited.

IntechOpen

IntechOpen