

We are IntechOpen, the world's leading publisher of Open Access books Built by scientists, for scientists

6,900

Open access books available

186,000

International authors and editors

200M

Downloads

Our authors are among the

154

Countries delivered to

TOP 1%

most cited scientists

12.2%

Contributors from top 500 universities



WEB OF SCIENCE™

Selection of our books indexed in the Book Citation Index
in Web of Science™ Core Collection (BKCI)

Interested in publishing with us?
Contact book.department@intechopen.com

Numbers displayed above are based on latest data collected.
For more information visit www.intechopen.com



Trachoma and Conjunctivitis

Imtiaz A. Chaudhry¹, Yonca O. Arat² and Waleed Al-Rashed³

¹*Senior Academic Consultant, Ophthalmic Plastic Reconstructive Surgeon
Oculoplastic and Orbit Division, King Khaled Eye Specialist Hospital, Riyadh*

²*Department of Ophthalmology, University of Wisconsin
School of Medicine, Madison, Wisconsin*

³*Senior Consultant Ophthalmologist, Division of Anterior Segment
King Khaled Eye Specialist Hospital and Vice Dean for Medical Services
Al-Imam Muhammad ibn Saud Islamic University Faculty of Medicine, Riyadh*

^{1,3}*Saudi Arabia*

²*USA*

1. Introduction

Trachoma remains the leading cause of preventable corneal blindness worldwide and especially in the developing countries. It afflicts some of the poorest regions of the globe, predominantly in Africa and Asia. The disease is initiated in early childhood by repeated infection of the ocular surface by *Chlamydia trachomatis*. Initial clinical manifestation is a follicular conjunctivitis which if not treated on timely basis, may lead to conjunctival and eyelid scarring that may eventually result in corneal scarring and loss of vision. Despite the remarkable progress in our understanding of Chlamydial infection, the basic mechanisms involved in tissue damage, scarring and repeated episodes of conjunctivitis remain to be elucidated. However, over the past 2 decades, a remarkable reduction in the prevalence of active trachoma in poor countries has occurred due to the World Health Organization's (WHO) program GET 2020 for the elimination of trachoma, with adoption of the SAFE strategy incorporating Surgery, Antibiotic treatment, Facial cleanliness and Environmental hygiene. Immunohistochemical studies of conjunctival biopsies from children with active trachoma demonstrate the presence of both humoral and cell-mediated immune responses. Recurrent chronic inflammatory episodes cause conjunctivitis which leads to the development of conjunctival scarring/contractures, distorting the eyelids in the form of trichiasis and entropion. This compromises the cornea and blinding opacification often ensues. Since trachoma is a disease of poverty, overcrowding, and poor sanitation, active disease affects mainly children, but adults are at increased risk of scarring. Its prevalence is disproportionately high among women and children in poor rural communities.

Improvement in socio-economic status/health facilities within the last 20 years has led to the public awareness, prevention and treatment of bulk of active trachoma. In the active trachomatous conjunctivitis, macrophages may play an active role in conjunctival scarring by upregulated local production of extracellular matrix by the expression of the fibrogenic and angiogenic connective tissue growth factor. It is believed that the chronic

trachomatous follicular conjunctivitis may lead to canaliculitis, canalicular obstruction, dacryocystitis and nasolacrimal duct obstruction. Entropion has been found to be the most significant predictor of corneal opacity. Among the lacrimal complications of trachoma, dry eye syndrome, punctal phimosis, punctal occlusion, canalicular occlusion, nasolacrimal-duct obstruction, dacryocystitis, dacryocystocele, and dacryocutaneous fistula are the most common findings. Trachoma may cause dryness of the eye by decreasing mucus production and aqueous secretions. Severe cases of trachoma may lead to contracture of the conjunctiva, deeper tissues including Müller muscle and the tarsal plate, which supports the insertion of the levator aponeurosis. The upper eyelid of these patients may show eyelid retraction which also may show eyelid lag on patient's down-gaze. Four major eyelid complications: cicatricial entropion, eyelid retraction, secondary blepharospasm and brow ptosis may be seen. Entropion/trichiasis may be the most common with significant blinding complication. Eyelids of patients with inactive trachoma may be thickened. This thickening could be attributed to trachomatous changes in the conjunctiva and tarsus. Light microscopy studies of tarsal plates obtained during biopsies of tarsal plates and palpebral conjunctivae obtained from upper eyelids of patients with inactive trachoma show a thick and compact subepithelial fibrous membrane adherent to the tarsal plate. Other histopathologic findings include atrophy of the meibomian glands with thickening of the acinar basement membrane, loss of goblet cells, retention cysts, and hyaline degeneration of the tarsal plate with focal replacement by adipose tissue.

The prevalence of active trachoma infection has dropped significantly in some African countries attributable to both improvements in socioeconomic standards and the training of village health workers and traditional birth attendants in eye care. Azithromycin oral single dose has been found to be safe and effective in children with active trachoma. However, patients who already have infection at young age continue to present with adnexal related complications of trachomatous scarring which continue to cause corneal scarring and visual loss. Management of trachomatous cicatricial entropion of the upper eye lid causing chronic conjunctivitis presents a difficult problem. Many surgical approaches have been developed to address it. Most effective surgery is full-thickness incision of the tarsal plate and rotation of the terminal tarsal strip 180 degrees. With the modified surgical technique, a combination of bilamellar tarsal margin rotation procedure with blepharoplasty may be advocated. With this technique, the eye lids as well as the normal eyelashes can be rotated away from the surface of the eye and eyes have adequate lid closure and regular lid margin. The modified technique prevents any overhanging baggy fold of skin at operation site. In developing countries, where manpower and other resources are limited and patient-load high, ophthalmic surgeons are recommended to choose a procedure that is simple, quick and effective. Surgery for entropion results in healing of superficial keratopathy, improved tear film stability. The realigned eyelid margin may spread tears evenly and efficiently, thus contributing to improvement of chronic conjunctivitis and vision.

2. Trachoma in history

The word "trachoma", derived from ancient Greek, means "rough eye", due to the "cobblestone" appearance of the conjunctival lining of the globe as a result of reactive lymphoid follicles.¹ Treatment of trachoma and its complications have been recorded in the

ancient Egyptian writings. It is reported that both Hippocrates and Galen, had access to ancient Egyptian methods of treating both acute as well as chronic complications of trachoma.¹

2.1 Trachoma: Extent of the problem

Trachoma remains the leading infectious cause of ocular morbidity in some parts of the world.^{2,3} The disease is caused by an obligate intracellular bacterium *Chlamydia trachomatis* (*C. trachomatis*).⁴ The transmission of the disease occurs primarily in children during their early years of life.⁵ Repeated episodes of re-infection within the family members cause chronic conjunctivitis resulting in scarring in later years and continued loss of vision. The scarring is mostly in the conjunctiva and cornea but can affect nasolacrimal drainage system causing ocular complications as a result of its blockage. Eyelid scarring may result in distortion of the upper tarsal plate leading to trichiasis, entropion of eyelids and conjunctivitis. Chronic abnormality of the eyelids may cause corneal scarring, recurrent infections and decreased vision.⁶

2.2 Clinical presentation of trachomatous conjunctivitis

The initial response of an eye to infection with *C. trachomatis* is conjunctivitis involving the palpebral and bulbar conjunctiva.^{7,8} In these eyes, the conjunctiva may be inflamed, swollen along with papillary hypertrophy prominent in the palpebral conjunctiva (Figure 1). The initial conjunctival response may be followed by lymphoid follicle formation, most

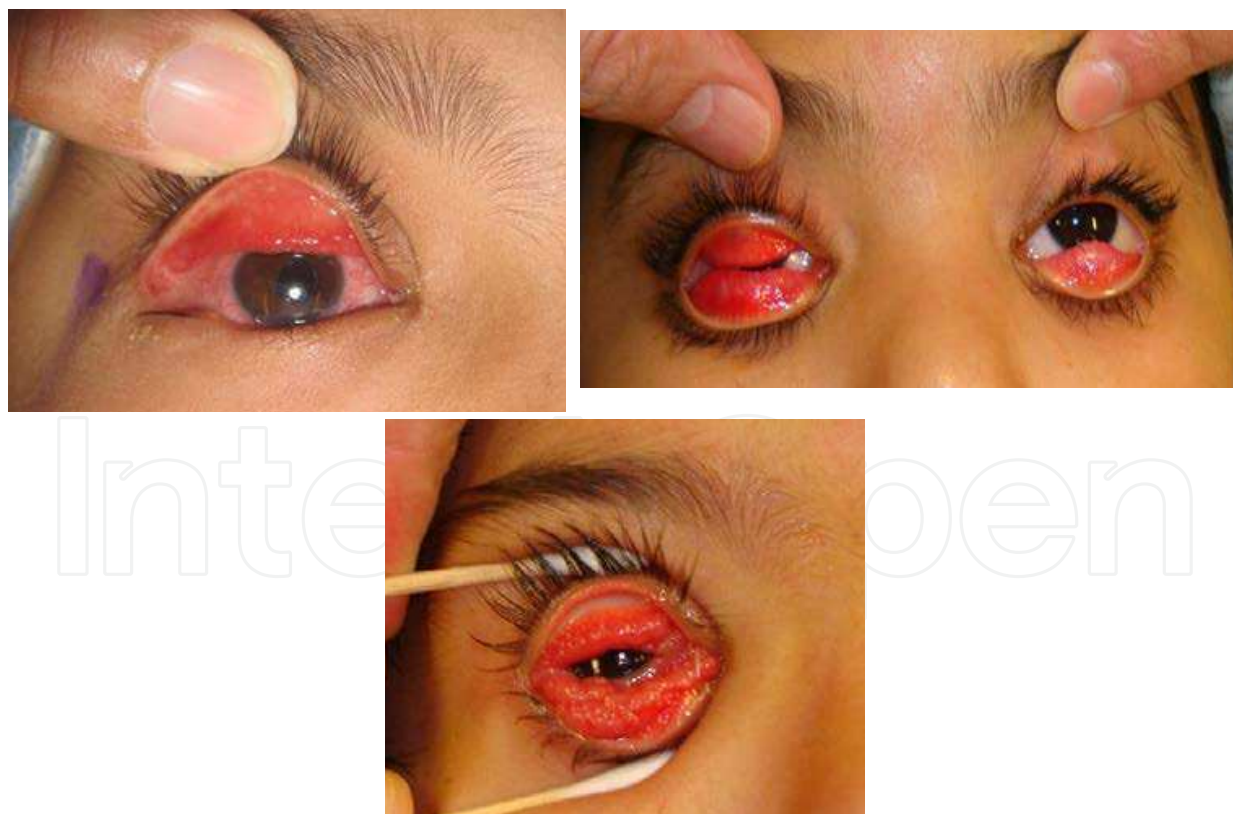

Fig. 1. Right upper eyelid of a child showing follicular reaction due to trachomatous conjunctivitis (upper right). Bilateral trachomatous conjunctivitis in another child with discharge (upper left). Intense follicular reaction in the right eye of a young child with trachomatous conjunctivitis (bottom figure).

commonly found on the palpebral conjunctiva as well as on the bulbar conjunctiva especially on at the limbus.⁶ After healing, these conjunctival follicles may result in Herbert's pits, named after an English ophthalmologist. These patients may be more prone to infection by other bacterial species resulting in secondary conjunctivitis and discharge.

Active trachoma is characterized by a mucopurulent keratoconjunctivitis (Figure 1). The conjunctival surface of the upper eyelid shows a follicular and inflammatory response.⁹ The cornea may have limbal follicles, superior neovascularization (pannus), and punctate keratitis. Infection with *C. trachomatis* concurrently occurs in other extraocular mucous membranes, commonly the nasopharynx, leading to a nasal discharge. Follicular trachoma (designated TF in the WHO simplified trachoma grading scheme), is defined as the presence of 5 or more follicles at least 0.5 mm in diameter in the central part of the upper tarsal conjunctiva. Follicular trachoma indicates active disease. This form is most commonly found in children, with prevalence in those aged between 3 to 5 years of age children. The prevalence rapidly decreases in school-aged children as they leave the pool of re-infection. Follicles are germinal centers that primarily consist of lymphocytes and monocytes.¹⁰ Involution of follicles at the limbus (corneoscleral border) give rise to the pathognomonic lesion of past active trachoma, Herbert's pits. Intense inflammatory trachoma (designated TI in the WHO simplified trachoma grading scheme), is defined as pronounced inflammatory thickening of the upper tarsal conjunctiva that obscures more than one half of the normal deep tarsal vessels.

During the intense inflammatory response, normally thin tarsal conjunctiva develops a velvety thickening. Papillae are visible under slit lamp examination (Figures 1). Intense inflammatory trachoma indicates an increased potential for significant conjunctival scarring and, hence, a higher ultimate risk of blinding disease. Surveying the prevalence of intense inflammatory trachoma in children can help in predicting the risk of future blinding trachoma in that cohort of children.⁵ Trachomatous scarring (designated TS in the WHO simplified trachoma grading scheme), indicates presence of easily visible scars in the tarsal conjunctiva (Figures 2,3). Trachomatous scarring indicates past inflammatory disease and a

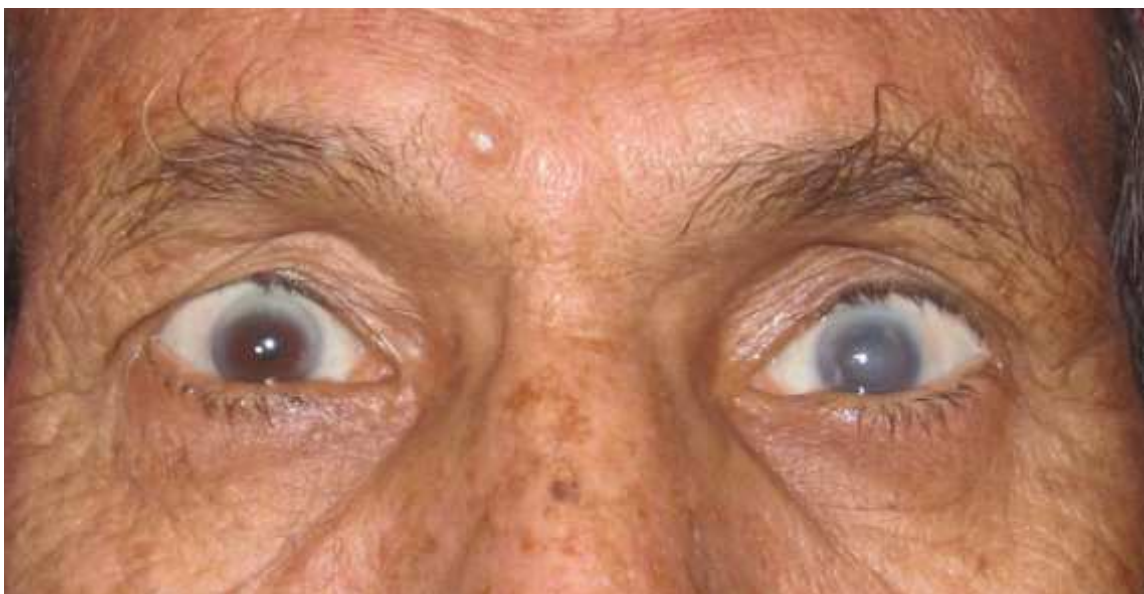

Fig. 2. An elderly patient with bilateral corneal scarring and upper eyelid retraction due to old trachoma

risk of future trichiasis. In the setting of more severe scarring, there is higher risk of subsequent trichiasis.⁸ This form may be associated with the development of dry eye syndrome and picture of chronic conjunctivitis. However, chronic, low-grade bacterial conjunctivitis and dacryocystitis may also lead to a weeping eye.⁶ Trichiasis (designated TT in the WHO simplified trachoma grading scheme), is defined when at least one eyelash rubs on the eyeball or evidence of recent removal of in-turned eyelashes. This condition is a potentially blinding situation that may lead to chronic conjunctivitis and corneal opacification (Figures 2-4). Trichiasis is due to subconjunctival fibrosis over the tarsal plate that leads to lid distortion. Some vision can be restored with the successful correction of trichiasis. Corneal opacity (designated CO in the WHO simplified trachoma grading scheme), is defined as easily visible corneal opacity over the pupil that is so dense that it blurs at least part of the pupillary margin when it is viewed through the opacity (Figures 2-4). Corneal opacity or scarring reflects the prevalence of vision loss and blindness resulting from trachoma.¹¹ This condition includes pannus, epithelial vascularization, and infiltration only if it involves the central cornea.

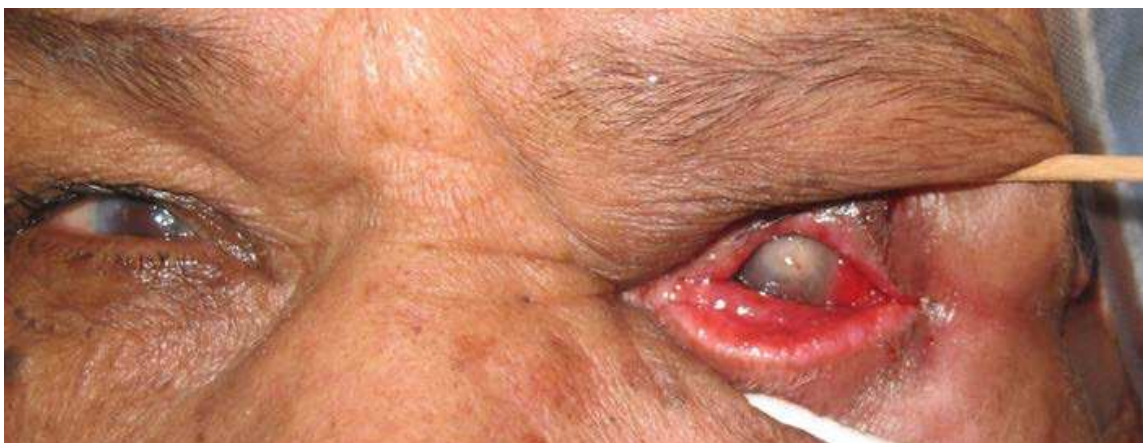

Fig. 3. An elderly patient with old trachomatous corneal scarring and chronic conjunctivitis due to abnormalities of eyelids

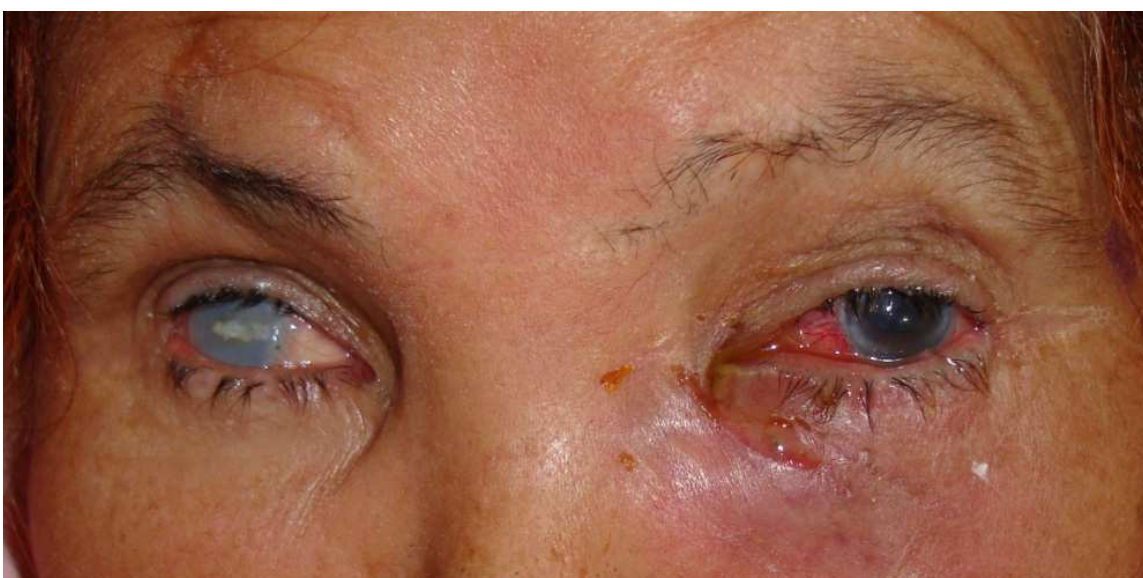

Fig. 4. Patient with long-standing bilateral trachomatous scarring and left-sided nasolacrimal duct obstruction causing chronic conjunctivitis

2.3 Epidemiology of trachomatous conjunctivitis

Despite the fact that trachoma has been eradicated from the well-developed countries of the World, it still persists in hot, dry regions throughout many parts of Africa, Southern Asia, Middle East, Brazil, Mexico and some parts of Australia.¹²⁻¹⁵ According to some rough estimates, worldwide, trachoma infects 84 million people in 55 countries, blinding over 8 million.¹⁶ According to the WHO estimates, if appropriate measures are not taken, over 75 million may become legally blind over the next twenty years.

Trachoma is caused by the eye to eye transmission of infection with *C. trachomatis*. Flies are considered a major factor in the spread of trachoma in many parts of the World.¹⁷ Flies may be more attracted to children with eye discharges or nasal discharges in the setting of dirty environment. Spread of active trachomatis cases can be reduced by controlling the population of flies in the known endemic areas.^{18,19} Over 50% of the household of an infant infected with trachomatous infection may have active trachoma. Cases of active trachoma may be predominantly clustered in families who share communal housing of interconnecting roof spaces through which flies could freely fly. Obviously a close contact with infected ocular secretions within the family is considered to be a significant channel of trachoma transmission. Chronic infection in older women from repeated exposure from their children may be the reason for severe trachomatous scarring, dry eye syndrome and chronic conjunctivitis.²⁰ In the endemic trachoma areas such as North Africa, the Middle East and northern India, most infants become infected by age 2 or 3 and the condition is primarily a disease of childhood.²¹⁻²³

3. Differential diagnoses for trachomatous conjunctivitis

The differential clinical diagnosis for *C. trachomatis* conjunctivitis may include adult inclusion conjunctivitis, adenovirus conjunctivitis, herpes simplex virus conjunctivitis, vernal conjunctivitis, other bacterial conjunctivitis, toxic follicular conjunctivitis, ligneous conjunctivitis and allergic conjunctivitis (Figures 5-7).²⁴ Patients having inclusion

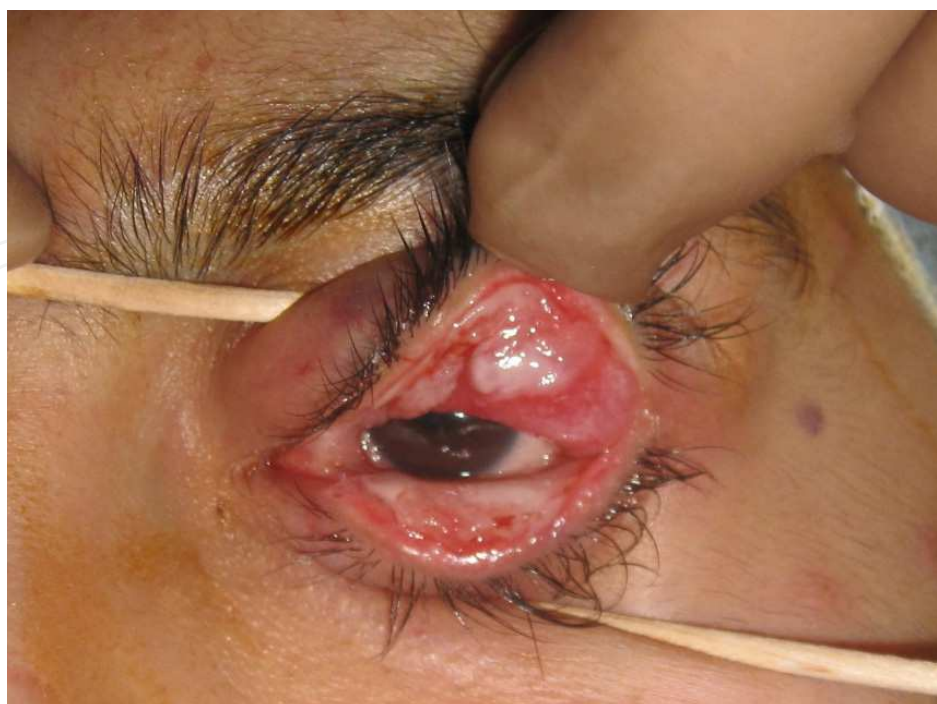


Fig. 5. A young patient with ligneous conjunctivitis

conjunctivitis may present with a history of a red, uncomfortable eye with a mucupurulent discharge. On examination, one may find signs of large lymphoid follicles and conjunctivitis.^{25,26} Majority of these patients have associated urinary tract infections. Chlamydial inclusion conjunctivitis is caused by genital tract serotype D-K of *C. trachomatis*.²⁵ It is thought that eye is infected through transmitting organisms from genital tract secretions by the hands.²⁷ Conjunctival chlamydial infection can be demonstrated by staining a conjunctival smear with *C. trachomatis*-specific fluorescent monoclonal antibody, or by the use of commercial nucleic acid-based diagnostic kits.²⁵

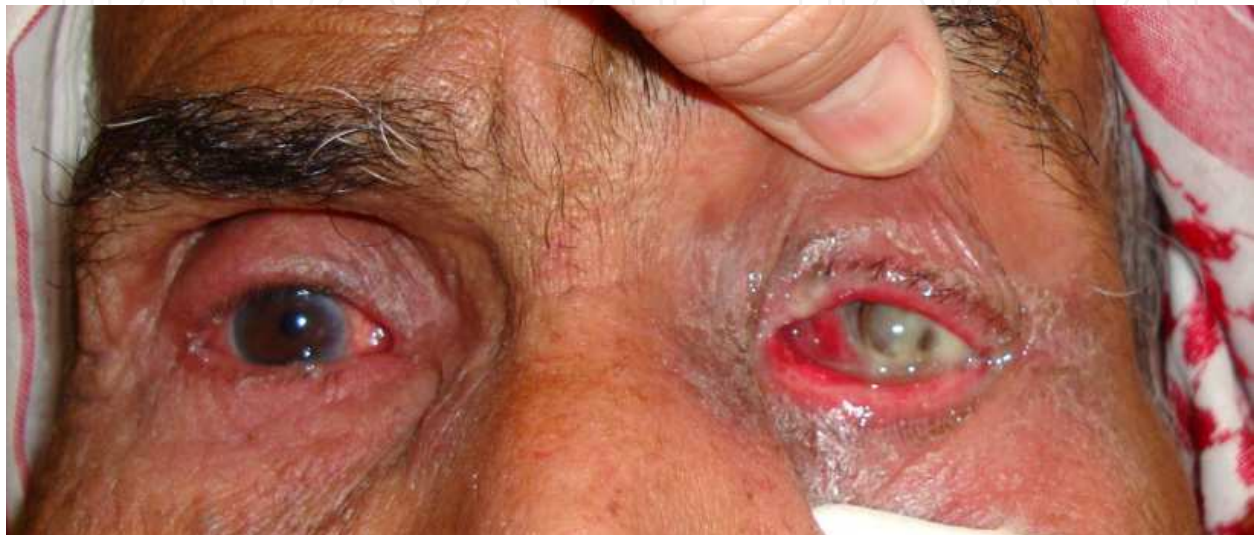

Fig. 6. An elderly patient with old trachomatous scarring and recent bacterial conjunctivitis

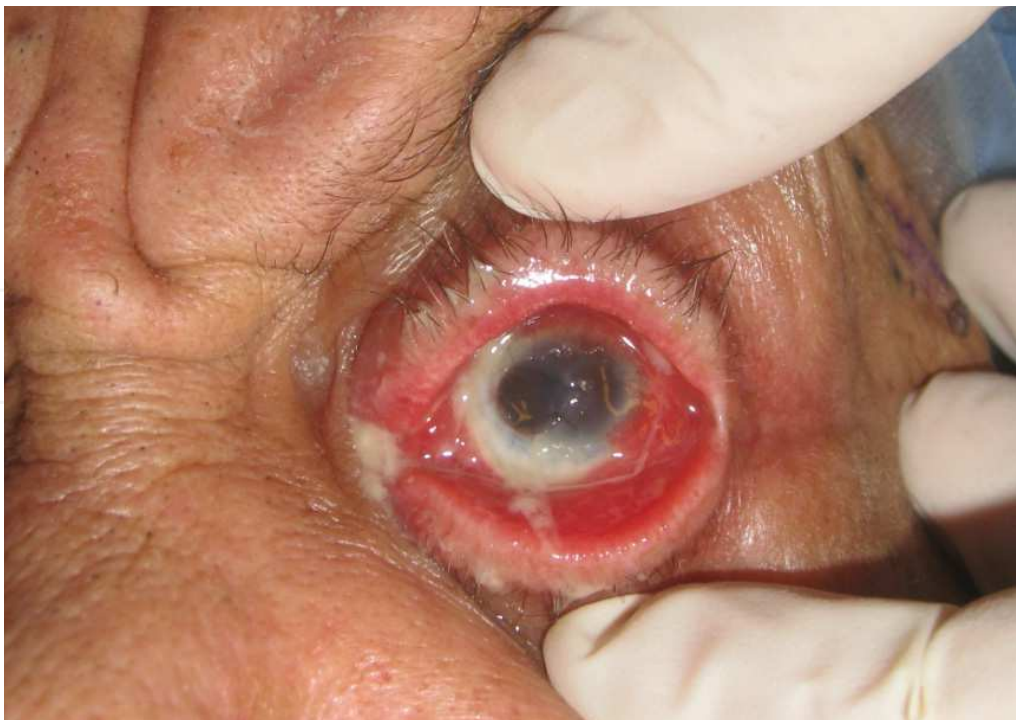

Fig. 7. An older patient having old trachoma and chronic dacryocystitis causing mucupurulent discharge

4. Workup for trachomatous conjunctivitis

The laboratory tests for ocular *C. trachomatis* confirmation for the clinical diagnosis of active trachoma conjunctivitis are based on techniques for the nucleic acid amplification tests, of which the polymerase chain reaction (PCR) is one example.^{25,28} These tests have high specificity and sensitivity. Patients may have infection for several weeks prior to the appearance of any specific clinical signs and symptoms. These patients may have persistent conjunctivitis for few weeks to months after the infection may have resolved. Some of the other useful techniques for laboratory identification of *C. trachomatis* include, direct fluorescein-labeled monoclonal antibody (DFA) assay and enzyme immunoassay (EIA) of smears obtained from conjunctival tissue. These tests are less sensitive than PCR. In Giemsa cytology, microscopic examinations of the stained conjunctival scrapings for intracytoplasmic inclusions may be useful.

5. Pathophysiology of trachomatis conjunctivitis

Chlamydiae are gram-negative, obligate intracellular bacteria. The species *C. trachomatis* causes trachoma and also genital infections (serovars D-K) and lymphogranuloma venereum (serovars L1-L3).²⁵ Serovars D-K occasionally cause a chronic follicular conjunctivitis that is clinically indistinguishable from trachoma, including follicular conjunctivitis with pannus and, at times, conjunctival scarring. However, these genital serovars do not typically enter stable transmission cycles within communities. Therefore, they are not involved in trachomatous conjunctivitis and blindness.

Trachomatous infection causes inflammation, that is, a predominantly lymphocytic and monocytic infiltrate with plasma cells and macrophages in follicles. The follicles are typical germinal centers with islands of intense B-cell proliferation surrounded by T cells.²⁹ Recurrent conjunctival reinfection causes the prolonged inflammation that leads to conjunctival scarring. Scarring is associated with atrophy of the conjunctival epithelium, loss of goblet cells, and replacement of the normal, loose, vascular subepithelial stroma with thick compact bands of collagen.

Active trachoma most commonly occurs in preschool children of both sexes and their (usually female) care providers. Trichiasis and blindness may be 2-4 times more common in women than men. Trachoma is endemic in parts of Africa, Asia, the Middle East, Latin America, the Pacific Islands, and aboriginal communities in Australia.^{15,16,30,31} In endemic areas, most members of nearly all families may have active disease. Active trachoma may be seen in clusters in some families. In 1 of 5 families, most children may have active trachoma (as opposed to 1 in 5 children in most families). This clustering becomes more apparent in communities as the prevalence decreases.^{5,32} Active disease most commonly occurs in preschool children, with the highest prevalence in children aged 3-5 years. Cicatricial disease is most common in middle-aged adults. The age group in which cicatricial disease begins to appear depends on the intensity of transmission in the community. In areas of extremely high recurrent infections, trichiasis may occur in children younger than 10 years of age. Young children may have follicular trachoma with intense conjunctival inflammation, while their mothers may have trachomatous scarring; and middle-aged patients or grandparents may have trichiasis and corneal opacity. Individuals may have episodes of follicular trachoma with intense conjunctival inflammation even after cicatricial complications develop. The active phase resembles many other diseases in which follicular conjunctivitis is a feature. Without laboratory facilities, the diagnosis is solely based on the clinical appearance of active trachoma

in someone living in a community where trachoma is endemic or suspected to be endemic. Many patients with active trachoma may remain relatively asymptomatic.

The duration of disease and infection in active trachoma decreases markedly as the child grows. More rapid disease resolution is found to be the main source of reduction in the prevalence of active trachoma and ocular *C. trachomatis* infection with age. The serious sequelae of repeated infection may result from conjunctival scarring. Although a severe primary childhood infection may result in conjunctival scarring, the evidence is that re-infection is the most important factor. With increasing age, there is an increasing exposure to infection and increasing immunity which may also increase the likelihood of severe sequelae. Poor hygiene increases the likelihood of a high chlamydial load. In some villages of Africa, familial cattle ownership, facial cleanliness and living less than two hours from a source of clean water may be associated with reduced severity of trachoma.^{33,34} Host genetic factors affecting the cellular immune response to trachoma agents may be important in determining disease severity.

In active trachoma, the inflammatory infiltrate is organized as lymphoid follicles in the underlying stroma and cytoplasmic inclusion bodies can be seen in the conjunctival epithelia. In follicular trachoma (grade TF) there is a strong local IgA antibody response to the infecting chlamydiae and this is associated with elevated levels of antibody secreting cells with specificity for chlamydial antigens in the blood. However in the most severe cases with intense inflammation (grade TI) there is a substantial suppression of chlamydia-specific antibody secreting cells for all isotypes, including IgA.^{8,34} The suppression may be a contributory factor leading to local tissue damage with ensuing scarring.

In scarring trachoma there are more marked pathological changes in the tissue of the eye lid. These include: subepithelial fibrous membrane formation, squamous cell metaplasia, loss of goblet cells, pseudogland formation in the conjunctiva, degeneration of the orbicularis oculi muscle fibers, sub-epithelial vascular dilatation and lymphocytic infiltration and localized peri-vascular amyloidosis.^{34,35} Accessory lacrimal glands and the ducts of glands are compromised by sub-epithelial infiltration and scarring. Contraction of the sub-epithelial fibrous tissue formed by collagen fibers and anterior surface drying are considered some of the main factors contributing to the chronic scarring and distortion of the eyelid.³⁶ Ocular *C. trachomatis* infection stimulates local cytokines which favor a strong cell-mediated and pro-inflammatory response in both the acute active and chronic forms of trachoma.

6. Ophthalmia neonatorum (neonatal conjunctivitis)

Often known by its Latin name of Ophthalmia neonatorum, it is conjunctivitis of the eyes of the new born caused by bacterial infection. Usually the infection is derived from the mother's genital tract at birth, in which case the causative organism is either the gonococcus or the genital serotype D to K of *C. trachomatis* (Figure 8).^{37,38} Other bacterial species may also cause conjunctivitis in the newborn, including *Neisseria*, *Pneumococci*, *Klebsiella*, *Pneumoniae* and *Streptococcus mitis*. Some of these organisms are probably acquired after birth, as the mode of delivery has little influence.

In the developing countries, *C. trachomatis* is a much commoner cause of sexually acquired neonatal conjunctivitis than the Gonococcal conjunctivitis. Approximately a third to a half of infants born through a chlamydial infected birth canal may develop neonatal conjunctivitis.³⁸ Chlamydial neonatal conjunctivitis is a significant, but little diagnosed problem in the developing world. Typically, neonatal chlamydial conjunctivitis has an

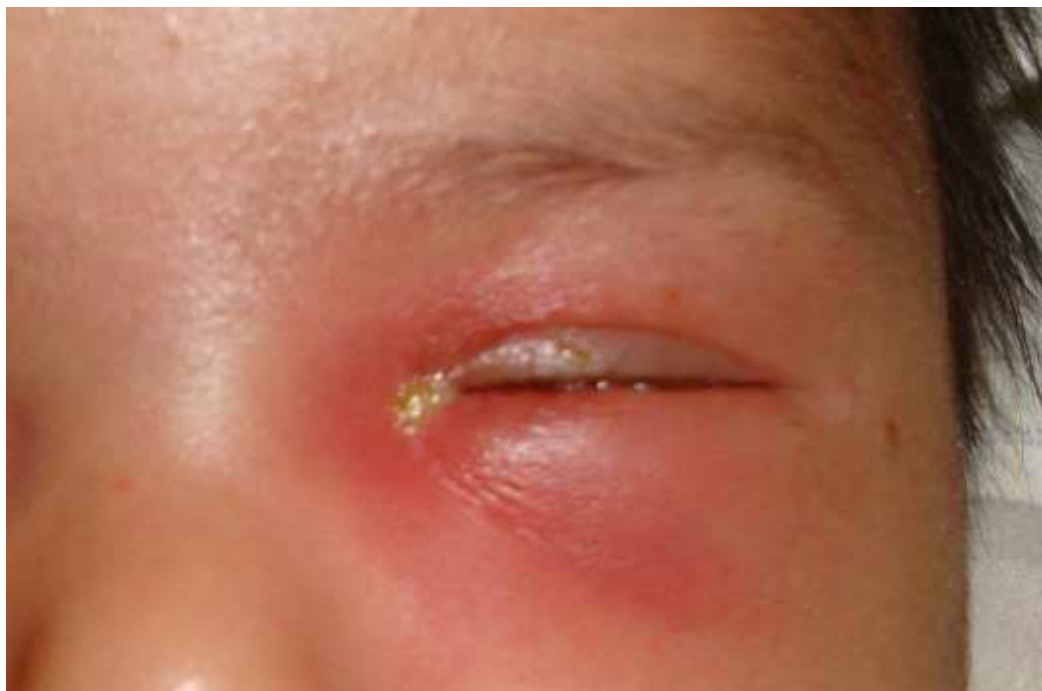

Fig. 8. New born with neonatal conjunctivitis due to Chlamydia

incubation period of 10 to 14 days compared with the much shorter 2 to 3 days incubation for Gonococcal ophthalmia. The conjunctiva of the eye in these patients may be significantly swollen with much mucoid discharge that may be less purulent than that usually seen with overt Gonococcal ophthalmia. The infection is particularly common in pre-mature babies, who are often born to women at particular risk of *C. trachomatis* infection.²⁴ Conjunctival swab obtained from the cul-de-sac of these patients stained with *C. trachomatis* specific fluorescent monoclonal antibody often shows the presence of chlamydial elementary bodies, looking like the "star-spangled sky at night". In neonatal conjunctivitis, the nasopharynx is also commonly infected with *C. trachomatis*, presumably via drainage from the oto-lacrimonal duct, so it is important to treat the infants with systemic rather than topical antibiotic. If left untreated, up-to 20% of infants may develop neonatal pneumonia.³⁹

6.1 Laboratory diagnosis of neonatal trachomatous conjunctivitis and pneumonia

A chlamydial aetiology should be considered in all infants aged less than thirty days with conjunctivitis. There have been no modern studies of commercial nucleic acid amplification based tests for the diagnosis of neonatal conjunctivitis. Commercial tests are not specifically licensed for use on ocular specimens from neonates. An alternative is the identification of chlamydial elementary bodies by direct immunofluorescence. Swabs should be collected from the everted eyelid using a swab. It is important that specimens contain conjunctival cells, not just exudates. The diagnosis of neonatal *C. trachomatis* infection confirms the need for treatment of the mother and her sexual partner as well as the infant.

7. Adult inclusion conjunctivitis

The trachoma serovars of *C. trachomatis* and the oculo-genital serovars associated with adult inclusion conjunctivitis do not appear to differ greatly in their virulence. In trachoma, the complications arise from the fact that, where the disease is endemic repeated infection

may be common that may lead to increased severity. In adult inclusion conjunctivitis secondary to genital tract infection, there is not the same likelihood of re-infection.²⁵ Furthermore, in developed countries there is a greater likelihood that the infection will be treated promptly. Thus conjunctival scarring is rarely a complication of adult inclusion conjunctivitis, although micro-pannus, and micro ulceration of the cornea following punctate keratitis may occur.

7.1 Laboratory diagnosis of adult conjunctivitis

Laboratory testing is usually required to establish, with any certainty, the cause of follicular conjunctivitis in the adult. This is because other agents, most notably adenovirus, may cause a similar clinical appearance. Very occasionally, adenoviral and chlamydial co-infection occur together. This should be considered in patients with prolonged follicular keratoconjunctivitis.⁴⁰

8. Treatment

Prevention of trachoma-related ocular complications may require early intervention and treatment. The WHO endorses the SAFE strategy for trachoma control. At the community level, adequate water access for personal hygiene, sanitation, and fly control determine the risk of endemic trachoma. Infants with untreated chlamydial pneumonia shed *C. trachomatis* and are symptomatic for many weeks. Erythromycin, azithromycin and clarithromycin may be effective for halting transmission to the baby and treating neonatal conjunctivitis.^{41,42} Prophylaxis, however, may be ineffective in some new born patients. Erythromycin base or ethyl succinate 50 mg/kg/day may be given orally divided into four doses daily for 14 days. Data on the use of other macrolides (e.g., azithromycin and clarithromycin) for the treatment of neonatal chlamydial infection are limited although a short course of azithromycin, 20 mg/kg/day orally, one dose daily for 3 days, may be effective.

It is essential that all patients with chlamydial conjunctivitis and their sexual partners be examined and treated for concomitant chlamydial genital tract infection.⁴³ Inclusion conjunctivitis generally responds well to the kind of regimens of macrolide or doxycycline used for treating chlamydial genital tract infection.⁴⁴ In the case of doxycycline, treatment with a weekly dose of 300 mg for three weeks or a daily dose of 1.5 mg/kg for one week may produce a clinical and microbiological response in vast majority of patients with adult chlamydial conjunctivitis. Mild to moderate papillary responses may persist in some patients for several months after completion of their treatment. The best results may be obtained with a daily dose of 100 mg Doxycycline for fifteen days, which may produce rapid clinical and microbiological response in most of the patients. The use of azithromycin for the treatment of trachoma suggests that it is likely to be a convenient and effective drug for use in treating adult chlamydial inclusion conjunctivitis.⁴⁵

Azithromycin is a long-acting antibiotic that has been widely sold in the United States and other industrialized nations since the late 1980s under the name Zithromax. The key to the treatment of trachoma is the SAFE strategy developed by the WHO.³³ In the SAFE strategy, "S" stands for trichiasis surgery. The antibiotics ("A"), facial cleanliness ("F"), and environmental improvement ("E") components of this strategy are described in Medical Care. The WHO recommends 2 antibiotics for trachoma control: oral azithromycin and tetracycline eye ointment. Azithromycin is better than tetracycline, but it is more expensive. National trachoma control programs in a number of countries are beneficiaries of a

philanthropic donation of azithromycin. Azithromycin is the drug of choice because it is easy to administer as a single oral dose. Its administration can be directly observed. Therefore, compliance is higher than with tetracycline and can actually be measured, whereas, with the home administration of tetracycline, the level of compliance is unknown. Azithromycin has high efficacy and a low incidence of adverse effects. When adverse effects occur, they are usually mild; gastrointestinal upset and rash are the most common adverse events. Infection with *C. trachomatis* occurs in the nasopharynx; therefore, patients may re-infect themselves if only topical antibiotics are used. Beneficial secondary effects of azithromycin include its treatment of genital, respiratory, and skin infections.⁴⁵

The aim of treatment is to reduce the amount *C. trachomatis* in the infection reservoir in the family. Treating an individual and not treating infected family members leaves the individual at risk for repeat infection. All family members, including infants, should be treated. The antibiotic of choice for treating active trachoma is azithromycin. The dose for children is 20 mg/kg in a single dose; adults receive a single dose of 1 g. The second-line treatment is topical tetracycline eye ointment 1%. Topical tetracycline is applied to both eyes twice a day for 6 weeks. If the patient lives in a hyperendemic area, the whole district (or whole community) is eligible for antibiotic treatment.

Antibiotic therapy is part of the WHO SAFE strategy for trachoma.⁴⁶ Azithromycin (Zithromax) 1 g PO as a single dose is recommended. Although, plasma concentrations may be low, because of long-tissue life and higher tissue concentrations, it may be valuable in treating intracellular organisms. For pediatric patients, a dose of 20 mg/kg PO once may be sufficient. Current WHO recommendations for antibiotic treatment of trachoma are as follows: Determine the district-level prevalence of follicular trachoma in 1- to 9-year-old children. If the prevalence is 10% or higher, conduct mass treatment with antibiotic of all people throughout the district. If the prevalence is less than 10%, conduct assessment at the community level in areas of known disease. If assessment at the community level is undertaken in communities where the prevalence of follicular trachoma in 1- to 9-year-old children is 10% or more, conduct mass treatment of all people with antibiotics. If assessment at the community level is undertaken in communities where the prevalence of follicular trachoma in 1- to 9-year-old children is 5% or more but less than 10%, targeted treatment should be considered. Targeted treatment involves the identification and treatment of all members of any family in whom one or more members have follicular trachoma.⁴⁷ If assessment at the community level is undertaken in communities where the prevalence of follicular trachoma in 1- to 9-year-old children is less than 5%, antibiotic distribution may not be necessary, though targeted treatment can be considered.

Epidemiologic studies and community-randomized trials have shown that facial cleanliness in children reduces both the risk and the severity of active trachoma.⁸ To be successful, health education and promotion activities must be community based and require considerable effort. Environmental change activities may include the promotion of improved water supplies and improved household sanitation, particularly methods for safe disposal of human feces. These activities should be prioritized. The flies that transmit trachoma preferentially lay their eggs on feces lying exposed on the soil. Controlling fly populations by spraying insecticide is difficult. Studies on the impact of fly control on trachoma have had variable results. Trials undertaken to evaluate the installation of pit latrines suggest that the prevalence of trachoma may be reduced but may not demonstrate a statistically significant effect. Nevertheless, the general improvements in personal and

community hygiene are almost universally associated with a reduction in the prevalence and eventually the disappearance of trachoma. This may be true not only in Europe, the Americas, and Australia but also in Africa and Asia.

8.1 Surgical care

Eyelid surgery to correct trichiasis is important in people with trichiasis, who are at high-risk for trachomatous visual impairment and blindness. Eyelid surgery to correct entropion and/or trichiasis may prevent blindness in individuals at immediate risk (Figure 9).⁴⁸⁻⁵⁰ Eyelid rotation limits the progression of corneal scarring. In some cases, it can result in improvement in visual acuity due to restoration of the visual surface and reductions in ocular secretions and blepharospasm.⁵¹ The WHO has produced a training manual on the bilamellar tarsal rotation procedure. This procedure involves a full-thickness incision of the scarred lid and external rotation of the distal margin by using 3 sutures. In regions where access to ophthalmologists is limited, well-trained and well-supported health workers can perform bilamellar tarsal rotation. Results of randomized clinical trials have confirmed the superiority of this method over other techniques. Even after successful surgery, patients remain at risk for recurrence. Therefore, long-term follow-up care and intermittent screening are important after surgery. Recurrence rates vary greatly between surgeons. Evidence supports the adjuvant use of single-dose azithromycin to patients at the time of surgery. Patients experiencing recurrent episodes of chronic dacryocystitis and/or canaliculitis may benefit from surgical intervention (Figures 4,7,10).

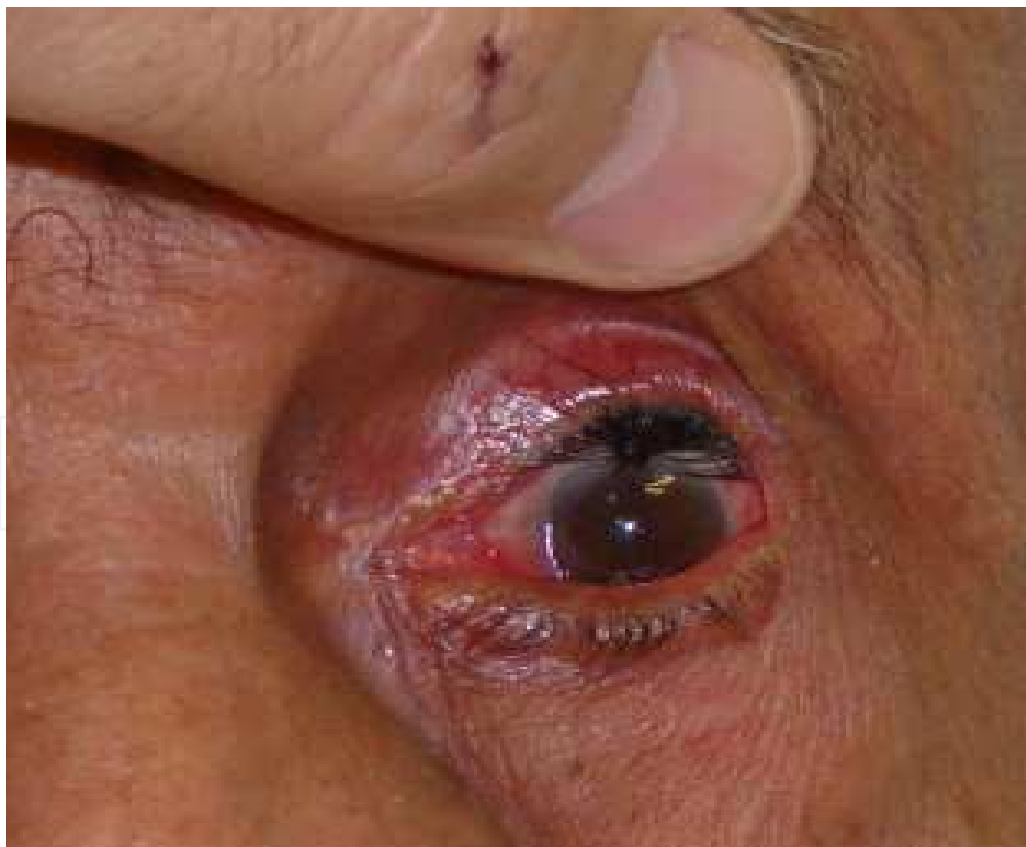

Fig. 9. An elderly patient with old trachomatous scarring and upper eyelid entropion causing chronic conjunctivitis

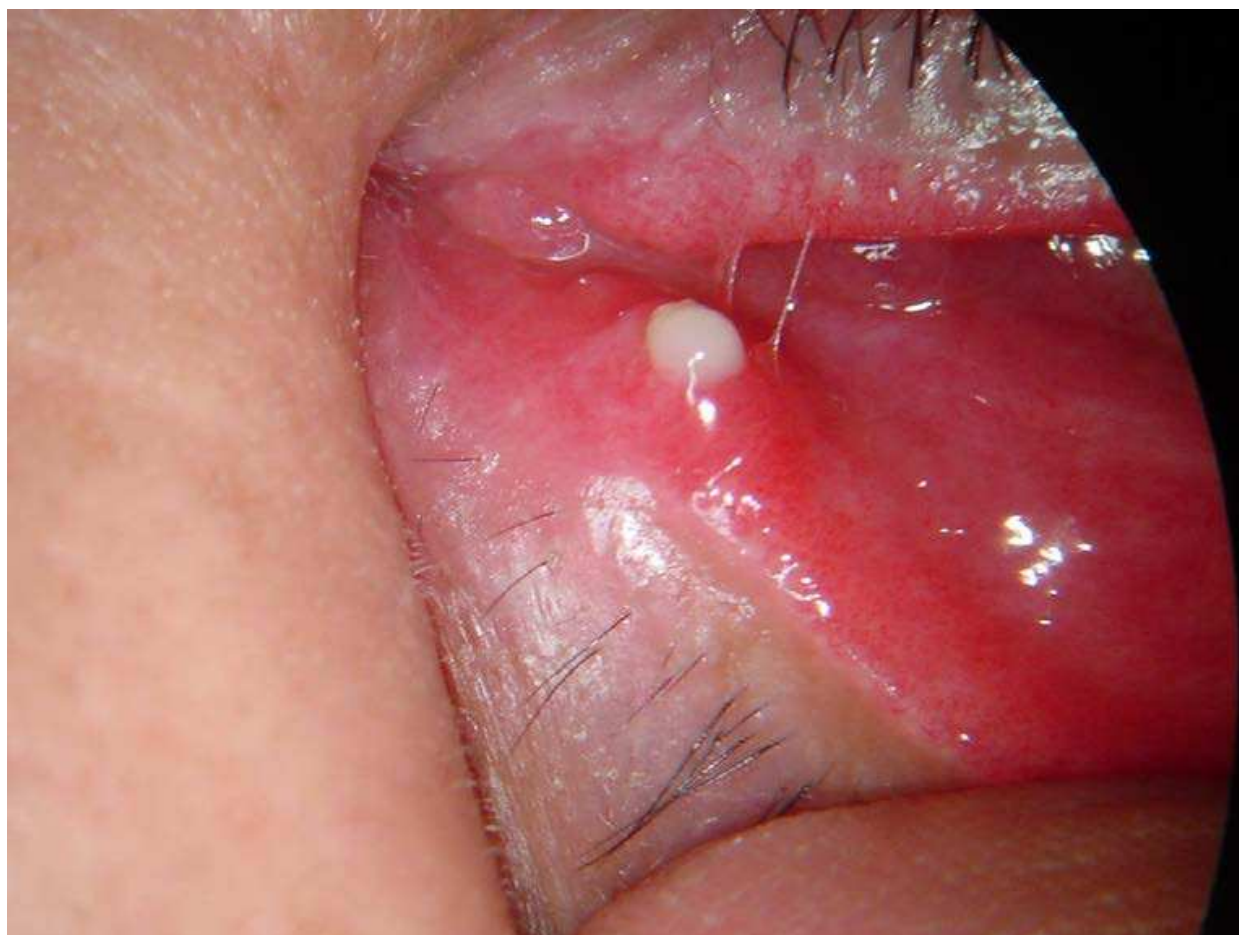

Fig. 10. Patient with chronic trachomatous scarring and canaliculitis and conjunctivitis

9. Trachoma preventive strategies

In the mid 1990s, WHO announced a program called Vision 2020, to tackle the world's major causes of blindness. Approximately 45 million people in the world are blind, with a further 135 million visually disabled. Some 90% of these people live in the developing world. Cataract, trachoma, childhood blindness and onchocerciasis account for roughly 70% of the global burden of blindness, much of it preventable.⁵² Part of this program includes the Global Elimination of Trachoma by the year 2020, the acronym for which is GET 2020. Key to this has been the international trachoma initiative (ITI), a partnership between the pharmaceutical company Pfizer and the Edna MacConnell Clarke Foundation, a philanthropic organization.⁵³ The foundation has already funded much valuable work on trachoma field studies and basic science including some key studies which indicated the efficacy of simple intervention measures, such as face washing, in the prevention of trachoma. Pfizer has provided their anti-chlamydial drug, azithromycin, free of charge for use in pilot studies in some countries of trachoma prevention by antibiotic treatment. These are key elements in the SAFE strategy for GET 2020.

Among the SAFE strategy, Surgery (to correct eyelid defects that lead to blindness), Antibiotic therapy, Facial cleanliness and Environmental improvement (including clean water supplies), surgery and antibiotic therapy dominate most programmes that have been implemented.⁴⁶ Surgery has a sustained effect in preventing an individual going blind, but it

has no effect on trachoma transmission. Prophylactic antibiotic reduces the transmission of infection but, unless frequently repeated, has no sustained effect on disease eradication.⁴⁶ Of the antibiotics most commonly used, oral azithromycin is far easier to administer and thus achieves better patient compliance.^{23,54} Antibiotic treatment might be successful if it is targeted at all children in an endemic area under 10 years of age. Mathematical models suggest that antibiotic therapy should be given to communities twice a year in areas with hyperendemic trachoma (>30% of children infected) and once a year in communities where trachoma is only moderately prevalent (<30% of children infected).⁴⁷

Sustainable reductions in transmission may be more likely through the F and E components of SAFE. Environmental improvement with improved hygiene, better access to water and better sanitation and education reduce trachoma transmission which must eventually lead to the disappearance of blinding sequelae. Evidence from intervention studies indicates that the promotion of face-washing yields modest gains for intense educational effort, raising the question for how long the effect will be sustained once health educators have left a village. Other studies have shown that latrines, improved access to water or reduction in eye-seeking flies are associated with a lower prevalence of active trachoma or with reduced transmission. This suggests that the beneficial effects of a combination of improved water supplies, provision of latrines, facial hygiene promotion through established infrastructure and control of eye-seeking flies may be long term and sustainable. Each of these interventions offers other tangible public health benefits. While the main aim of the SAFE program is to reduce trachoma infection to a level where blindness would be minimal, multiple mass antibiotic treatments alone may be sufficient to eliminate infection in an area with modest disease.

10. References


- [1] al-Rifai K M. Trachoma through history. *International Ophthalmology* 1988;12:9-14.
- [2] Evans TG, Ranson MK. The global burden of trachomatous visual impairment: II. Assessing burden. *International Ophthalmology* 1996;19:271-280.
- [3] Ranson MK, Evans TG. The global burden of trachomatous visual impairment: I. Assessing prevalence. *International Ophthalmology* 1996;19:261-270.
- [4] Schachter J. Infection and disease epidemiology. In Chlamydia. Intracellular biology, pathogenesis and immunity (Stephens RS, ed.) *American Society of Microbiology Press*, 1999, pg139-169, Washington DC, USA.
- [5] Bobo LD, Novak N, Munoz B, Hsieh YH, Quinn TC, West S. Severe disease in children with trachoma is associated with persistent Chlamydia trachomatis infection. *Journal of Infectious Diseases* 1997;176:1524-1530.
- [6] Taylor HR, Johnson SL, Schachter J, Caldwell HD, Prendergast RA. Pathogenesis of trachoma: the stimulus for inflammation. *J Immunol.* 1987;138:3023-7.
- [7] Abu el-Asrar AM, Geboes K, Missotten L. Immunology of trachomatous conjunctivitis. *Bull Soc Belge Ophtalmol.* 2001;280:73-96.
- [8] Mabey DC, Solomon AW, Foster A. Trachoma. *Lancet.* 2003;362:223-9.
- [9] el-Asrar AM, Geboes K, al-Kharashi SA, Al-Mosallam AA, Missotten L, Paemen L, Opdenakker G. Expression of gelatinase B in trachomatous conjunctivitis. *British Journal of Ophthalmology* 2000;84:85-91.
- [10] Bobo L, Novak N, Mkocha H, Vitale S, West S, Quinn TC. Evidence for a predominant proinflammatory conjunctival cytokine response in individuals with trachoma. *Infection and Immunity* 1996;64:3273-3279.

- [11] Schachter J, Dawson CR. The epidemiology of trachoma predicts more blindness in the future. *Scandinavian Journal of Infectious Diseases Supplement*. 1990;69:55-62.
- [12] Tabbara KF, Ross-Degnan D. Blindness in Saudi Arabia. *JAMA*. 1986;255:3378-84. Tabbara KF, al-Omar OM. Trachoma in Saudi Arabia. *Ophthalmic Epidemiol*. 1997;4:127-40.
- [13] Burton MJ. Trachoma: an overview. *Br Med Bull*. 2007;84:99-116.
- [14] West SK, Munoz B, Turner VM, Mmbaga BB, Taylor HR. The epidemiology of trachoma in central Tanzania. *Int J Epidemiol*. 1991;20:1088-92.
- [15] Landers J, Kleinschmidt A, Wu J, Burt B, Ewald D, Henderson T. Prevalence of cicatricial trachoma in an indigenous population of Central Australia: the Central Australian Trachomatous Trichiasis Study (CATTS). *Clin Experiment Ophthalmol*. 2005;33:142-6.
- [16] Chaudhry IA. Eradicating blinding trachoma: what is working? *Saudi J Ophthalmol*. 2010;24:15-21. Available on-line at <http://dx.doi.org/10.1016/j.sjopt.2009.12.008>.
- [17] Emerson PM, Bailey RL, Mahdi OS, Walraven GE, Lindsay SW (2000) Transmission ecology of the fly *Musca sorbens*, a putative vector of trachoma. *Transactions of the Royal Society of Tropical Medicine and Hygiene* 94, 28 - 32.
- [18] Emerson PM, Lindsay SW, Walraven GE, Faal H, Bogh C, Lowe K, Bailey RL. Effect of fly control on trachoma and diarrhoea. *Lancet*. 1999;353:1401-1403.
- [19] West S, Munoz B, Lynch M, Kayongoya A, Chilangwa Z, Mmbaga BB, et al. Impact of face-washing on trachoma in Kongwa, Tanzania. *Lancet*. 1995;345:155-8.
- [20] Abou-Gareeb I, Lewallen S, Bassett K, Courtright P. Gender and blindness: a meta-analysis of population-based prevalence surveys. *Ophthalmic Epidemiology* 2001; 8: 39 - 56.
- [21] Haddad NA. Trachoma in Lebanon: observations on epidemiology in rural areas. *American Journal of Tropical Medicine and Hygiene*. 1965;14:652-655.
- [22] Courtright P, Sheppard J, Lane S, Sadek A, Schachter J, Dawson CR. Latrine ownership as a protective factor in inflammatory trachoma in Egypt. *British Journal of Ophthalmology*. 1991;75:822-825.
- [23] Dawson C, Schachter J. Can blinding trachoma be eliminated world wide? *Archives of Ophthalmology*. 1999;117:974.
- [24] Krohn MA, Hillier SL, Bell TA, Kronmal RA, Grayston JT. The bacterial etiology of conjunctivitis in early infancy. Eye Prophylaxis Study Group. *American Journal of Epidemiology*. 1993;138:326- 32.
- [25] Isobe K, Aoki K, Itoh N, Ohno S, Takashima I, Hashimoto N. Serotyping of *Chlamydia trachomatis* from inclusion conjunctivitis by polymerase chain reaction and restriction fragment length polymorphism analysis. *Japanese Journal of Ophthalmology*. 1996;40: 279-285.
- [26] Mellman-Rubin TL, Kowalski RP, Uhrin M, Gordon YJ. Incidence of adenoviral and chlamydial coinfection in acute follicular conjunctivitis. *American Journal of Ophthalmology*. 1995;119:652-554.
- [27] Postema EJ, Remeijer L, van der Meijden WI. Epidemiology of genital chlamydial infections in patients with chlamydial conjunctivitis; a retrospective study. *Genitourinary Medicine*. 1996;72:203-205.

- [28] Solomon AW, Holland M J, Burton MJ, West SK, Alexander ND, Aguirre A, *et al.* Strategies for control of trachoma: observational study with quantitative PCR. *Lancet*. 2003; 362:198-204.
- [29] Ghaem-Maghami S, Bailey RL, Mabey DC, Hay PE, Mahdi OS, Joof HM, Whittle H. C, Ward ME, Lewis DJ. Characterization of B-cell responses to *Chlamydia trachomatis* antigens in humans with trachoma. *Infection and Immunity*. 1997;65:4958-4964.
- [30] Courtright P, Sheppard J, Schachter J, Said ME, Dawson CR. Trachoma and blindness in the Nile Delta: current patterns and projections for the future in the rural Egyptian population. *British Journal of Ophthalmology* 1989;73:536 - 540.
- [31] Dolin PJ, Faal H, Johnson GJ, Ajewole J, Mohamed AA, Lee PS. Trachoma in The Gambia. *British Journal of Ophthalmology* 1998;82: 930 - 933.
- [32] Dawson CR, Schachter J, Sallam S, Sheta A, Rubinstein RA, Washton H. A comparison of oral azithromycin with topical oxytetracycline/polymyxin for the treatment of trachoma in children. *Clin Infect Dis*. Mar 1997;24:363-8.
- [33] Kuper H, Solomon AW, Buchan J, Zondervan M, Foster A, Mabey D. A critical review of the SAFE strategy for the prevention of blinding trachoma. *Lancet Infectious Diseases*. 2003;3:372-381.
- [34] Solomon AW, Taylor HR. Trachoma. eMedicine Updated: Sep 5, 2007. Downloaded March, 13th 2011.
- [35] el-Asrar AM, Geboes K, Tabbara KF, al-Kharashi SA, Missotten L, Desmet V. Immunopathogenesis of conjunctival scarring in trachoma. *Eye*. 1998;12: 453-460.
- [36] al-Rajhi AA, Hidayat A, Nasr A, al-Faran M. The histopathology and the mechanism of entropion in patients with trachoma. *Ophthalmology*. 1993;100:1293-6.
- [37] Black-Payne C, Ahrabi MM, Bocchini JA Jr, Ridenour CR Brouillette RM. Treatment of *Chlamydia trachomatis* identified with Chlamydiazyme during pregnancy. Impact on perinatal complications and infants. *Journal of Reproductive Medicine*. 1990;35:362-367.
- [38] Francois P, Hirtz P, Rouhan D, Favier M, Gratacap B, Beaudoin A. Maternal-child transmission of *Chlamydia trachomatis*. A prospective inquiry in 168 pregnant women. *Presse Medicale*. 1989;18:17-20.
- [39] Herieka E, Dhar J. Acute neonatal respiratory failure and *Chlamydia trachomatis*. *Sexually Transmitted Infections*. 2001;77:135-136.
- [40] Mellman-Rubin TL, Kowalski RP, Uhrin M, Gordon YJ. Incidence of adenoviral and chlamydial coinfection in acute follicular conjunctivitis. *American Journal of Ophthalmology* . 1995;119: 652-554.
- [41] Black-Payne C, Ahrabi MM, Bocchini JA Jr, Ridenour CR Brouillette RM. Treatment of *Chlamydia trachomatis* identified with Chlamydiazyme during pregnancy. Impact on perinatal complications and infants. *Journal of Reproductive Medicine*. 1990; 35:362-367.
- [42] Hammerschlag MR, Gelling M, Roblin PM, Kutlin A, Jule JE. Treatment of neonatal chlamydial conjunctivitis with azithromycin. *Pediatric Infectious Diseases Journal*. 1998;17:1049-1050
- [43] Garland SM, Malatt A, Tabrizi S, Grando D, Lees MI, Andrew JH, Taylor HR. *Chlamydia trachomatis* conjunctivitis. Prevalence and association with genital tract infection. *Medical Journal of Australia*. 1995; 162:363-866.

- [44] Stenberg K, Mardh PA. Treatment of concomitant eye and genital chlamydial infection with erythromycin and roxithromycin. *Acta Ophthalmology* (Copenhagen). 1993;71:332-335.
- [45] Negrel AD, Mariotti SP. WHO alliance for the global elimination of blinding trachoma and the potential use of azithromycin. *International Journal of Antimicrobial Agents*. 1998;10:259-262.
- [46] Emerson PM, Cairncross S, Bailey RL, Mabey DC. Review of the evidence base for the 'F' and 'E' components of the SAFE strategy for trachoma control. *Tropical Medicine and International Health*. 2000;5:515-527.
- [47] Lietman T, Porco T, Dawson C, Blower S. Global elimination of trachoma: how frequently should we administer mass chemotherapy? *Nature Medicine*. 1999;5:572-576.
- [48] Teichmann KD. Correction of severe upper eyelid entropion. *Int Ophthalmol* 1988;12:37-9.
- [49] Dhaliwal U, Monga PK, Gupta VP. Comparison of three surgical procedures of differing complexity in the correction of trachomatous upper lid entropion: a prospective study. *Orbit* 2004;23:227-36.
- [50] Sadiq MN, Pai A. Management of trachomatous cicatricial entropion of the upper eye lid: our modified technique. *J Ayub Med Coll Abbottabad*. 2005;17:1-4.
- [51] Dhaliwal U, Nagpal G, Bhatia MS. Health-related quality of life in patients with trachomatous trichiasis or entropion. *Ophthal. Epidemiol*. 2006;13:59-66.
- [52] Thylefors BA global initiative for the elimination of avoidable blindness. *American Journal of Ophthalmology*. 1998; 125:90-93.
- [53] Knirsch C, McCaskey J, Chami-Khazraji Y, Kilima P, West S, Cook J. Trachoma elimination and a public private partnership: the International Trachoma Initiative (ITI). In: *Chlamydial Infections: Proceedings of the 10th international symposium on human chlamydial infections* (Schachter J *et al*, eds), 2002. pp 485 - 494, published by International Chlamydia Symposium San Francisco CA 94110.
- [54] Bailey RL, Arullendran P, Whittle HC, Mabey DC. Randomised controlled trial of single-dose azithromycin in treatment of trachoma. *Lancet*. 1993;342:3453-3456.

IntechOpen



Conjunctivitis - A Complex and Multifaceted Disorder

Edited by Prof. Zdenek Pelikan

ISBN 978-953-307-750-5

Hard cover, 232 pages

Publisher InTech

Published online 23, November, 2011

Published in print edition November, 2011

This book presents a number of interesting and useful aspects and facets concerning the clinical features, properties and therapeutical management of this condition. Dr. H. Mejía-López et al. present an interesting survey of the world-wide epidemiologic aspects of infectious conjunctivitis. Dr. U. Ubani evaluates conjunctival symptoms/signs participating in the clinical features of this disorder. Dr. A. Robles-Contreras et al. discuss immunologic aspects underlying possibly the conjunctivitis. Dr. Z. Pelikan presents the cytologic and concentration changes of some mediators and cytokines in the tears accompanying the secondary conjunctival response induced by the nasal challenge with allergen. Dr. S. Sahoo et al. summarize the treatment and pharmacologic control of particular clinical forms of conjunctivitis in general practice. Dr. S. Leonardi et al. explain the basic pharmacologic effects of leukotriene antagonists and their use for the treatment of allergic conjunctivitis. Dr. J.A. Capriotti et al. evaluate the therapeutical effects of various anti-adenoviral agents on the acute conjunctivitis caused by adenovirus. Dr. V. Vanzzini-Zago et al. assess the prophylactic use and efficacy of "povidone-iodium solution", prior the ocular surgery. Dr. F. Abazi et al. present the clinical features, diagnostic and therapeutical aspects of "neonatal conjunctivitis". Dr. I.A. Chaudhry et al. review the special sub-form of conjunctivitis, being a part of the "Trachoma". Dr. B. Kwiatkowska and Dr. M. Maślińska describe the clinical, pathophysiologic and immunologic features of conjunctivitis. Dr. S. Naem reviews the conjunctivitis form caused by *Thelazia* nematodes, occurring principally in animals.

How to reference

In order to correctly reference this scholarly work, feel free to copy and paste the following:

Imtiaz A. Chaudhry, Yonca O. Arat and Waleed Al-Rashed (2011). Trachoma and Conjunctivitis, *Conjunctivitis - A Complex and Multifaceted Disorder*, Prof. Zdenek Pelikan (Ed.), ISBN: 978-953-307-750-5, InTech, Available from: <http://www.intechopen.com/books/conjunctivitis-a-complex-and-multifaceted-disorder/trachoma-and-conjunctivitis>

INTech
open science | open minds

InTech Europe

University Campus STeP Ri
Slavka Krautzeka 83/A
51000 Rijeka, Croatia
Phone: +385 (51) 770 447

InTech China

Unit 405, Office Block, Hotel Equatorial Shanghai
No.65, Yan An Road (West), Shanghai, 200040, China
中国上海市延安西路65号上海国际贵都大饭店办公楼405单元
Phone: +86-21-62489820

www.intechopen.com

Fax: +385 (51) 686 166
www.intechopen.com

Fax: +86-21-62489821

IntechOpen

IntechOpen

© 2011 The Author(s). Licensee IntechOpen. This is an open access article distributed under the terms of the [Creative Commons Attribution 3.0 License](https://creativecommons.org/licenses/by/3.0/), which permits unrestricted use, distribution, and reproduction in any medium, provided the original work is properly cited.

IntechOpen

IntechOpen