

# We are IntechOpen, the world's leading publisher of Open Access books Built by scientists, for scientists

6,900

Open access books available

185,000

International authors and editors

200M

Downloads

Our authors are among the

154

Countries delivered to

TOP 1%

most cited scientists

12.2%

Contributors from top 500 universities



WEB OF SCIENCE™

Selection of our books indexed in the Book Citation Index  
in Web of Science™ Core Collection (BKCI)

Interested in publishing with us?  
Contact [book.department@intechopen.com](mailto:book.department@intechopen.com)

Numbers displayed above are based on latest data collected.  
For more information visit [www.intechopen.com](http://www.intechopen.com)



# Leukotriene Antagonist Drugs as Treatment of Allergic Conjunctivitis and Comorbidities in Children

Salvatore Leonardi<sup>1</sup>, Giovanna Vitaliti<sup>1</sup>, Giorgio Ciprandi<sup>2</sup>, Carmelo Salpietro<sup>3</sup> and Mario La Rosa<sup>1</sup>

<sup>1</sup>*Department of Pediatrics, University of Catania*

<sup>2</sup>*Department of Pediatrics, University of Genova*

<sup>3</sup>*Department of Pediatrics, University of Messina*  
Italy

## 1. Introduction

Allergy includes a variety of different illnesses (rhinitis, conjunctivitis, asthma, urticaria, and dermatitis) with a common pathological basis due to the release of chemical mediators such as histamine, platelet-activating factor, metabolites of arachidonic acid, and chemotactic factors from mastocytes, basophils, and eosinophils. The keyrole of leukotrienes (LTs) as mediators in allergic and inflammatory response justifies the new pharmacologic category of Cysteinil LT antagonists as possible therapeutic use in other allergic diseases beyond asthma (Leonardi et al., 2007).

Since 1938, known as slow-reacting substances of anaphylaxis (Feldberg & Kellaway, 1938), LTs have been products of the arachidonic acid metabolism pathway by the action of 5-lipoxygenase. LTs are generated by a number of cells including mast cells, eosinophils, basophils, and neutrophils, which appear in the airways of patients with asthma and in the skin of patients with chronic urticaria (CU). They mediate chemotaxis, vascular permeability, edema, eosinophils migration, airway constriction, and smooth muscle contraction (Samuelsson et al., 1997). As their effect has a long time efficacy, these molecules are defined as “slow reacting substances”.

Among LTs, LTB<sub>4</sub>, LTC<sub>4</sub>, and LTD<sub>4</sub> have particularly potent effects. LTB<sub>4</sub> is a potent chemoattractant for leukocytes and is involved in the migration of granulocytes into tissues (Lewis et al., 1990; Wenzel et al., 1997). LTC<sub>4</sub> evokes a wheal and flare reaction when intradermally injected. LTC<sub>4</sub>, LTD<sub>4</sub>, and LTE<sub>4</sub> are chemical mediators of the inflammation involved in the pathogenesis of asthma, the overall biological effects of which are bronchial constriction and an increase in both mucus secretion and vascular permeability (Schleimer et al., 1986; Wenzel et al., 1990).

There are two different LT inhibitors/modifiers:

- LT receptors antagonists (LTRAs; montelukast, zafirlukast, and Pranlukast).
- 5-Lipoxygenase inhibitor of LT synthesis (zileuton).

Montelukast and zafirlukast block binding of cysteinil LTs to the cysLT<sub>1</sub> receptor in the extracellular space. Zileuton inhibits 5-lipoxygenase and therefore all LT synthesis within

inflammatory cells. By blocking the actions of LTs, it promotes bronchodilation and decreases the inflammatory response.

Recent studies performed on adult patients suggest that anti-LTs can play an important role not only in the acute phase, but also in controlling the chronic development of bronchial asthma. Anti-LTs also have been used successfully by some authors to control allergic diseases such as rhinitis, atopic dermatitis, chronic urticaria and allergic conjunctivitis. Moreover, recently, new reports have been published concerning other conditions (migraine prophylaxis, sleep disorders, inflammatory bowel disease, and nasal polyposis) that broaden the future range of clinical applications.

## 2. Leukotriene antagonists

### 2.1 Leukotriene synthesis

Leukotrienes are lipidic mediators, synthesised from arachidonic acid, by different reactions of the 5-lipoxygenase enzymatic pathway. The specific enzymatic pathway can be different in different cellular types and its activation depends on external cellular stimuli. However it is well established that the 5-lipoxygenase pathway is more frequently activated in cells deriving from the myeloid pathway (Henderson, 1994). The activation of 5-lipoxygenase pathway needs a signal of cell activation with mobilization of calcium and the availability of arachidonic acid as substrate. This process moreover requires the interaction with a protein called FLAP (protein activating the 5-lipoxygenase), important for the presentation of the arachidonic acid to the 5-lipoxygenase (Henderson WR Jr, 1994). The activation of the 5-lipoxygenase, on cellular and nuclear membranes, leads to the production of an instable intermediate molecule, known as LTA<sub>4</sub>, that could be transformed, according to the cellular type, in leukotriene B<sub>4</sub> or in cysteinil-leukotriene (LTC<sub>4</sub>, LTD<sub>4</sub>, LTE<sub>4</sub>). Recently the gene codifying for LTC<sub>4</sub> synthase was identified on the chromosome 5q, in a genetic region associated with bronchial asthma and atopic diseases (Bigby et al., 1996).

### 2.2 Leukotriene modifier drugs

Members of both types of LT blockers have been approved for use in the USA, Europe, and other nations (eg. Japan). The US Food and Drug Administration approved zileuton, a 5-LO inhibitor, in 1996, and two LT blockers, zafirlukast and montelukast, in 1996 and 1998 respectively; pranlukast was approved in Japan in 1995. The efficacy of montelukast, zafirlukast, pranlukast, and zileuton on bronchial asthma has been established in numerous randomized, controlled, multicenter clinical trials. LT modifiers reduce asthma symptoms, short-acting  $\beta$ 2-antagonist (SABA) use, and asthma exacerbations, and improve all indexes of pulmonary function, as measured by the increases in forced expiratory flow at one second (FEV<sub>1</sub>), peak expiratory flow (PEF), quality of life, and indices of bronchial inflammation (blood eosinophils, inflammatory cells in the bronchial mucosa, exhaled nitric oxide, substance P, neurokin A, eosinophil cationic protein, and serum myeloperoxidase) (Riccioni et al., 2002; Lakomski & Chitre, 2004).

### 2.3 Leukotriene receptor antagonist drugs

**Montelukast.** Montelukast is an orally bioavailable Cys-LTRA that is usually administered once daily. This drug has been approved for long-term treatment of asthma in adults (10 mg/day) and children age 2 to 14 yr (using lower dosages, depending on the age of the child). Therapeutic concentrations do not inhibit cytochrome P450 isoenzymes. The most

common adverse effects observed in adults at the 10 mg daily dosage were compatible with placebo, and included headache (18.4% vs 18.1%), abdominal pain (2.7% vs 2.4%), and cough (2.7% vs 2.4%). Elevations in liver enzymes occurred at a frequency that was generally comparable with placebo. The most common adverse effects that occurred in children at an incidence of 2% were slightly (but not significantly) higher than placebo. These included diarrhea, laryngitis, pharyngitis, nausea, otitis, sinusitis, and viral infections. The adverse event profile did not change with prolonged montelukast treatment (Jones et al., 1995; Spector & Antileukotriene Working Group, 2001).

**Zafirlukast.** Zafirlukast is a Cys-LTRA that is approved for the treatment of asthma in children aged 7 yr or older. It is administered orally twice daily and is metabolized by the liver; hepatic cytochrome P450 is inhibited by therapeutic concentrations. Therefore, there is a risk of drug interactions, and transient elevations of liver enzymes have been reported. The most common adverse effects that were comparable in incidence to placebo included headache (12.9% vs 11.7%), infections (3.5% vs 3.4%), nausea (3.1% vs 2.0%), and diarrhea (2.8% vs 2.1%). Other common adverse effects (eg, pharyngitis, rhinitis, flush syndrome, and increased cough) occurred at incidences identical to or lower than placebo (Accolate: Manufacturer's prescribing information, 1999; Spector & Antileukotriene Working Group, 2001).

**Pranlukast.** Pranlukast is an orally administered Cys- LTRA that is indicated for prophylactic treatment of chronic bronchial asthma in pediatric and adult patients. In clinical trials, pranlukast was well tolerated with an adverse event profile similar to that of the placebo. Gastrointestinal events and hepatic function abnormalities were the most common reported adverse effects, but were not significantly different from other LTRAs (Spector & Antileukotriene Working Group, 2001; Keam et al., 2003; Yanagawa et al., 2004).

**Zileuton.** Zileuton is the only marketed drug with a specific effect on Cys-LT synthesis via inhibition of the 5-LO enzyme. It is administered orally 4 times daily and is approved for treatment of asthma in patients 12 yr and older. It is metabolized by the cytochrome P450 isoenzymes and may, therefore, interact with other drugs metabolized by these enzymes, such as theophylline and warfarin. The use of zileuton is hampered by the dosing regimen and the requirement that liver enzymes be monitored. The adverse event profile in controlled clinical trials was generally similar to LTRAs. The most common adverse effects compared to placebo included headache (24.6% vs 24.0%), dyspepsia (8.2% vs 2.9%), unspecified pain (7.8% vs 5.3%), nausea (5.5% vs 3.7%), abdominal pain (4.6% vs 2.4%), and asthenia (3.8% vs 2.4%). Unlike the LTRAs, therapy with zileuton is associated with hepatotoxicity, and liver function enzymes should be monitored during treatment. Elevations of liver function tests may progress, remain unchanged, or resolve during continued treatment. At a dosage of 600 mg, 4 times daily, zileuton carries a pregnancy category C classification because of abnormalities noted in rabbit and rat fetuses (McGill & Busse, 1996; Spector & Antileukotriene Working Group, 2001).

### 3. Leukotriene antagonists in allergic diseases beyond asthma: Recent applications of antileukotriene drugs

**Paranasal sinus disease.** LTs are inflammatory mediators that have an important role in paranasal sinus disease (PSD) and the formation of nasal polyps (NP). Cys-LTs are overproduced in asthmatic subjects with chronic hyperplastic rhinosinusitis (CHR) and NP (Higashi et al., 2004). In view of the fact that these agents lead to symptoms in

asthmatics patients, the use of LTRAs, particularly montelukast and zafirlukast, seems appropriate (Parnes, 2003; Steinke et al., 2003). A number of studies have indicated their role in inhibiting nasal symptoms in asthmatic patients. In addition, it has been suggested that many aspirin-intolerant asthma patients have NP and that treatment with the LTRAs results in improvement and resolution of the NP (Parnes & Chuma, 2000; Borish, 2002; Arango & Kountakis, 2002; Arango et al., 2002). The LTRAs might be good alternatives to the long-term administration of oral steroids, in view of their systemic anti-inflammatory effects and acceptable safety profiles (Parnes, 2002; Scadding, 2003; Haberal & Corey, 2003; Steinke et al., 2004).

**Bronchiolitis.** Many published studies have documented increased LTE<sub>4</sub> levels in patients with infectious diseases due to respiratory syncytial virus (RSV), such as bronchitis, pneumonia, and bronchiolitis, suggesting that LTs may be involved. Cys- LTs, in fact, are released during RSV infection and may contribute to the inflammatory state (Takahashi et al, 2003). In a 36-months, double-blind trial, 130 infants (median age 9 months) who were hospitalized with acute RSV bronchiolitis were randomized into 2 parallel comparison groups of 5-mg montelukast chewable tablets or matching placebo given for 28 days starting within 7 days after the onset of symptoms. Infants in the montelukast group were free of symptoms on 22% of the days and nights, which was significantly lower than the placebo group, and there were significant reductions in daytime coughing and clinical exacerbations compared to the placebo (Khoshoo et al., 2002; Szeffler & Simoes, 2003; Bisgaard, 2003, 2004).

**Rhinitis.** It is known that 4-11% of people have asthma and 10-30% have allergic rhinitis (AR) (Nathan et al., 1997; Von Mutius, 1998). Frequently comorbidities exists among these pathologies. Both conditions show the same allergic and proinflammatory mediators such as histamine, LTs, cytokines and eosinophils (Vignola et al., 2003). Moreover AR and asthma share common triggers as similar inflammatory cascade on exposure to allergen similar patterns of early and late-phase responses (Spector, 1997). Consequently, today, a combined approach in the managing of asthma and AR is recommended for an optimal strategy. On this regard, the new concept of “one-linked airway disease” between AR and asthma has led to LT modifiers being prescribed also for AR. In fact, it is well known that cysteinil LTs are common mediators as will in upper as in lower airway diseases, cysteinil LT challenges increase rhinorrhea in AR and a release of cysteinil LT reduces symptoms in AR (Howarth, 2000).

**Allergic conjunctivitis.** Allergic conjunctivitis (AC) is the most frequent form of ocular allergy in patients who consult ophthalmologists and allergists (Bhargava et al., 2004; Marmou and Raffard, 2004). The severity of the disease ranges from mild itching and redness, as seen in seasonal AC, to the serious, vision-threatening forms of ocular allergy that affect the cornea, such as atopic keratoconjunctivitis (AK). The pathogenesis of AC involves a complex mechanism that centers around IgE-mediated mast cell degranulation and release of multiple performed and newly formed inflammatory mediators. The diagnosis of AC is usually a clinical one that is made on a thorough history and careful examination (Epstein, 2003).

Treatment of ocular allergy should begin with conservative measures including allergen avoidance, environmental control, ocular irrigation, and cold compresses (Bhargava et al., 2004). Pharmacotherapy of AC consists of several classes of drugs: antihistamines, mast cell stabilizers, NSAIDs, topical steroids, and, in cases of AK, cyclosporine (Marmou and Raffard, 2004). Many studies have evaluated the signs and symptoms of coexisting vernal keratoconjunctivitis in asthmatic patients treated with oral montelukast. There were significant and persistent reductions of ocular signs and symptoms in asthmatic patients with vernal keratoconjunctivitis who were treated for 15 days with montelukast. This points



to a need for double-blind, placebo-controlled trials to evaluate the potential of this new treatment in patients with vernal keratoconjunctivitis (Leonardi and Abelson, 2003; Lambiase et al., 2003).

#### 4. Allergic conjunctivitis and the possible role of nasal allergy

Disorders of the conjunctiva, where an allergic component plays an important causal role are very common. However, the estimations of incidence of 'allergic conjunctivitis' and its particular forms vary (McGill et al., 1998; Bielory, 2000; Ziskin, 2006; Bielory & Friedlaender, 2008; Bielory, 2008; Uchio et al., 2008). Seasonal allergic conjunctivitis (SAC) occurs most frequently, followed by atopic keratoconjunctivitis (AKC), vernal keratoconjunctivitis (VKC) and perennial allergic conjunctivitis (PAC), whereas giant papillary conjunctivitis (GPC) may be seen only sporadically (McGill et al., 1998; Bielory, 2000; Ziskin, 2006; Bielory, 2008; Bielory & Friedlaender, 2008; Uchio et al., 2008). SAC and PAC appear in relatively milder form, whereas AKC and VKC occur in a more severe bilateral form, where the conjunctivae and cornea may also be affected (McGill et al., 1998; Bielory, 2000; Ziskin, 2006; Bielory, 2008; Bielory & Friedlaender, 2008; Uchio et al., 2008).

The relationship between the conjunctiva and the nose is a well-known entity (McGill et al., 1998; Bielory, 2000; Ziskin, 2006; Bielory & Friedlaender, 2008; Uchio et al., 2008;). The coexistence of allergic rhinitis and conjunctivitis has repeatedly been reported in the literature (McGill et al., 1998; Bielory, 2000; Ziskin, 2006; Leonardi, 2005; Ono & Abelson, 2005; Bielory & Friedlaender, 2008; Bielory, 2008; Pelikan, 2009, 2010).

Nasal allergy could cohere with conjunctivitis in various ways. An allergic reaction occurring initially in the nasal mucosa may affect the conjunctiva in different ways upon involving diverse mechanisms: (i) this reaction leads to release of mediators, cytokines and other factors, which can then penetrate to the conjunctiva through the nasolacrimal duct (McGill et al, 1998; Bielory, 2000; Sirigu et al., 2000; Paulsen, 2003; Ono & Abelson, 2005; Pelikan, 2009 a, 2009 b); (ii) the released factors can also be transported to the conjunctiva by the local haematogenic ways (*a. maxillaris- pars pterygopalatina, v. facialis, plexus pterygoideus*) (Dua et al, 1995; Pelikan, 1996; Bielory, 2000; Pelikan, 2009 a, 2009 b); (iii) allergic reactions in the nasal mucosa can stimulate the local neurogenic network and released neuropeptides may reach conjunctiva along and/or through the appropriate nerves (*n. trigemini, n. nasociliaris, pterygopalatine ganglion*) (Pelikan, 1995; Fujishima et al., 1997; Calonge et al, 2005; Zoukhri, 2006; Motterle et al., 2006; Pelikan, 2009 a, 2009 b); and (iv) this reaction and released factors can stimulate the local nasal mucosal lymphatic system, 'nose-associated lymphatic tissue' (NALT), which is able to communicate with the lymphatic tissue of the lacrimal system, 'tear duct-associated lymphatic tissue' (TALT), 'lacrimal drainage-associated lymphoid tissue' (LDALT), 'eye-associated lymphatic tissue' (EALT) and that of the conjunctiva, called 'conjunctiva-associated lymphatic tissue' (CALT) (Pelikan, 1996; Sirigu et al, 2000; Knop & Knop, 2000; Knop & Knop, 2001, Paulsen et al, 2002; Paulsen et al, 2003; Zoukhri et al, 2006; Pelikan, 2009 a, 2009 b). In this way not only transmission of certain signals but also cellular traffic of various cell types, for example, T lymphocytes (Th1 and Th2) and B cells (plasma cells), can also be realized (Dua et al, 1995; Pelikan, 1996; Calder et al, 1999; Bacon, 2000; Magone et al, 2000.; Pelikan, 2002; Helintö, 2004; Ono & Abelson, 2005; Baudouin et al, 2005; Stern et al, 2005; Bielory, 2008; Pelikan, 2009 a, 2009 b). An additional mechanism that could also play a role in the cellular traffic among the particular organ-associated lymphatic tissues is the 'defective homing' of the B lymphocytes

(Pelikan, 1996; Mikulowska-Mennis et al, 2001; Pelikan, 2009 a, 2009 b). Diagnostic confirmation of hypersensitivity mechanism (s) in the nasal mucosa can be performed by various methods, such as skin tests and *in vitro* estimation of the specific immunoglobulin E antibody (Bielory, 2000; Leonardi, 2005; Radcliffe, 2006). However, these tests provide only general evidence for the possible existence of an allergic component somewhere in the body and not specifically in a particular organ or tissue. Moreover, these tests do not reflect the possible participation of local antibodies in the particular organ and do not provide data on the dynamic aspects of the hypersensitivity mechanism(s) (Pelikan, 2009).

Nasal provocation tests (NPTs) combined with registration of the conjunctival parameters are able not only to show the causal role of a certain allergen in the nasal mucosa and subsequently in the conjunctiva, but also to record quantitatively responses in their dynamic and time-related course. (Pelikan, 2009 a, 2009 b). Although the NPTs are a laborious, time-consuming technique and require special apparatus and facilities, they generate important clinical data that cannot be gathered by other tests. By combining of the recorded parameters, NPTs are also able to confirm a causal role of one organ in a response of another organ, in this case the causal relationship of nasal mucosa and nasal allergy in the reactions of the conjunctiva. Significant correlation of the first and repeated NPTs confirms reliable reproducibility of this technique (Pelikan 2009 a, 2009 b, 2010). NPTs can also discriminate between the participation of the allergy and the non-specific hypereactivity in the patient's complaints. (Pelikan, 2009 a, 2009 b, 2010) Another advantage of NPTs is their ability to follow relative parameter values, by comparing the post-challenge with the pre-challenge results. From this point of view the NPTs are independent of the absolute parameter values that regularly show high variability (Pelikan, 1996; Pelikan, 2002; Pelikan, 2009, 2010). Similar motivation is applicable for the conjunctival provocation tests (CPTs) with allergens showing an allergic reaction directly in the conjunctiva and its causal participation in the conjunctival complaints (Anderson, 1996; McGill et al, 1998). The results of Pelikan et al emphasize some important clinical implications. As nasal allergy can induce a secondary conjunctival response (CR), allergic rhinitis may not always be seen only as a coexisting disorder to allergic conjunctivitis, but in some patients as a causal trigger for the allergic conjunctivitis. This fact would implicate existence of two forms of allergic conjunctivitis, a 'primary or classical form' in which the initial allergic reaction and the subsequent steps (clinical symptoms) take place exclusively in the conjunctiva, whereas the 'secondary form' may be induced by an allergic reaction occurring initially in the nasal mucosa and only the consequences (clinical symptoms) are displayed by the conjunctiva (Pelikan, 1996; Pelikan, 2002; Pelikan, 2009 a, 2009 b). The involvement of various types of hypersensitivity in allergic conjunctivitis (Anderson, 1996; Pelikan, 1996; McGill, 1998; Calder et al, 1999; Bielory, 2000; Bacon, 2000; Magone et al., 2000; Pelikan, 2002; Bonini et al, 2003; Cook, 2004; Stahl & Barney, 2004; Baudouin et al., 2005; Ono & Abelson, 2005; Leonardi, 2006; Bielory & Friedlaender, 2008.; Bielory, 2008; Pelikan, 2009 a, 2009 b, 2010;) may result in three types of CR, immediate, late and delayed, analogous to the three basic types of nasal response (NR). (Pelikan, 1996; Pelikan, 2002).

## 5. The ocular allergic response and the role of LTs in allergic conjunctivitis

The burden of allergic conjunctivitis and related allergic diseases have been increasing worldwide. It is speculated that environmental factors are essentially responsible for this increase. Because of environmental degradation, especially in urban cities within developing

countries, children are confronted with an array of new problems of allergic diseases including allergic conjunctivitis. Allergic conjunctivitis is a condition seldom associated with visual loss; however, it is important from the perspective of quality of life.

Particulate matter-pollutants, pollen, dust, mold, mite, animal dander, and other proteins, as well as dirt and sand, is meant to be blocked from reaching the eye by eyebrows, eyelashes, or eyelids. The particles that evade these barriers alight on the ocular surface and are buffered by the tear film, the most important barrier the eye has against foreign substances. Whatever is not washed away by the tear film eventually reaches the ocular surface. The ocular allergic response is caused by exposure of the conjunctiva, the mucus membrane that covers the posterior aspect of the eye, to an antigen. Immunologic recognition of intruders awakens the body's defenses, leading to antigen recognition and sensitization, antibody activation, and a full-blown over-reactive immunologic response.

Dry eye and allergic conjunctivitis are chronic inflammatory diseases of the cornea and conjunctiva (ocular surface). Dry eye affects 5 million individuals in the United States alone and is more prevalent in women than men (Smith et al, 2007). Allergy including seasonal allergic conjunctivitis, vernal keratoconjunctivitis, giant papillary conjunctivitis (also known as contact lens-induced papillary conjunctivitis), and atopic keratoconjunctivitis affects 20% of the population (Ono & Abelson, 2005). Hallmarks of these diseases are symptoms of ocular pain and discomfort, and signs of ocular surface inflammation that generate inflammatory cytokines and matrix metalloproteinases. These inflammatory mediators lead to death of the surface cells of the corneal and conjunctival epithelia (Lemp, 2007) (Figure 1).

The pathophysiological basis of conjunctivitis and other type I hypersensitivity disorders, such as, rhinitis, asthma and dermatitis, relies on the release of chemical mediators from inflammatory cells (Holgate 2000). Histamine plays a pivotal role in ocular hypersensitivity reactions of both immunological and non-immunological origin, by exerting its effects on blood vessels, nociceptive nerves, fibroblasts, epithelial and goblet cells, mainly *via* histaminergic receptor activation in the ocular surface (Abelson & Schaefer, 1993; Leonardi, 2000). Histamine, being the main early activating molecule of the inflammatory cascade leads to the release of late phase reaction mediators, such as nitric oxide (NO) (Meijer et al., 1996; Ko, 2000). Additionally, the *de novo* synthesized pro-inflammatory cysteinyl leukotrienes (cysLTs) seem to be equally important, their release in tears from patients with various forms of conjunctival inflammation having been documented

(Akman et al., 1998). Thus, histamine, cys-LTs and NO are involved in the inflammatory processes associated with type I hypersensitivity reactions, which have two well-defined periods. The early phase appears 5–30 min after challenge and it is characterized by vasodilatation and increased vascular permeability, attributed mainly to histamine, which initiates the production of other mediators, like prostaglandins, leukotrienes (LTs), NO and cytokines (Abelson & Schaefer, 1993; Meijer et al., 1996; Weimer et al., 1998). During the late phase response, which begins 2–6 h after challenge, overproduction of these secondary mediators exacerbates the inflammatory process.

The pathophysiology of allergic conjunctivitis is not a simple process. New findings suggest that a wide range of cytokines, chemokines, proteases and growth factors are involved by complex interrelated interactions (Leonardi *et al.*, 2008). In allergic conjunctivitis, there is increased tear levels of several chemical mediators such as histamine, tryptase, leukotrienes (LTs) and prostaglandins (Ono & Abelson, 2005). In addition, tear levels of LTB<sub>4</sub> and LTC<sub>4</sub> were found to be significantly higher in patients with vernal keratoconjunctivitis than in controls (Akman *et al.*, 1998). In fact, leukotrienes play a role in the development of seasonal



allergic conjunctivitis as well as the more severe forms as vernal keratoconjunctivitis and atopic keratoconjunctivitis (Leonardi *et al.*, 2008).

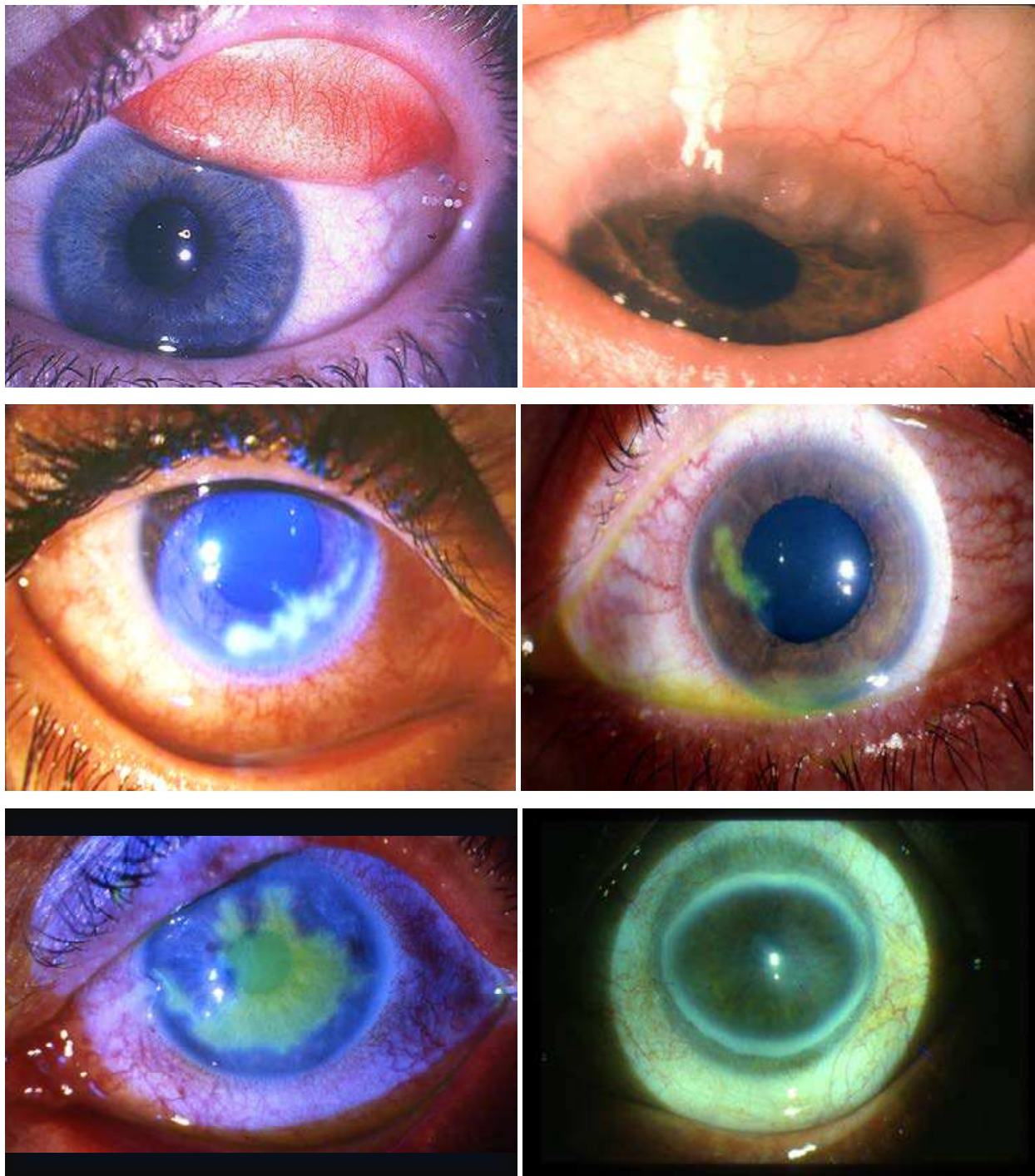

Fig. 1. Images of allergic conjunctivitis in pediatric patients. It is evident the presence of conjunctival hyperemia and oedema.

Dartt DA et al. (2011) showed that cysteinyl leukotrienes LTC<sub>4</sub>, LTD<sub>4</sub>, and LTE<sub>4</sub> produced in the conjunctiva during ocular allergy, dry eye disease, or other inflammatory diseases of the ocular surface stimulate goblet cell mucous secretion that can contribute to

the excess mucous seen in these diseases. The chronic inflammation in these ocular surface diseases damages the cornea and conjunctiva, causing chronic pain from exposed nerve endings. They demonstrated that cysteinyl-leukotriene-stimulated goblet cell secretion was completely blocked by the pro-resolution resolvins RvD1 and RvE1. Thus, resolution of inflammation by the production of pro-resolution mediators, namely, RvD1 and RvE1, can terminate excess goblet cell mucous secretion allowing the ocular surface to repair. These results also support the hypothesis that resolution of inflammation is an active process.

## **6. The use of leukotriene antagonist drugs in the treatment of allergic conjunctivitis**

Allergic conjunctivitis, as described above, is a collection of hypersensitivity disorders that affect the lid, conjunctiva and cornea. It is characterized by immunoglobulin E (IgE-) mediated and/or T-lymphocyte-mediated immune hypersensitivity reactions (Chigbu de, 2009). These reactions are initiated by binding of an allergen with specific IgE on the surface of mast cells. The resultant mast cell degranulation leads to early phase and late phase responses. The early phase response develops immediately after exposure to the allergen with clinical symptoms and signs such as itching, chemosis and congestion. This is followed by the late phase response after 8-24 hours which is characterized by conjunctival cellular infiltrations particularly eosinophilia and neutrophilia (Miyazaki et al., 2008). The pathophysiology of allergic conjunctivitis is not a simple process, and a wide range of cytokines, chemokines, proteases and growth factors are involved by complex interrelated interactions (Leonardi et al., 2008).

Treatment of allergic conjunctivitis includes several drug groups such as antihistamines, mast cell stabilizers, non-steroidal anti-inflammatory drugs and corticosteroids in resistant cases (Bielory and Friedlaender, 2008). However, the increased worldwide prevalence of ocular allergy has stimulated expansion of management strategies towards physiologic and immunologic drug targets. One of these targets is the leukotrienes (Schultz, 2006). The pro-inflammatory effects of leukotrienes have been well described in asthma and rhinitis (Sacre Hazouri, 2008). Leukotriene receptor antagonists have emerged as important therapeutic options that show clinical efficacy in treatment of bronchial asthma

The ocular allergic response results from exposure of the conjunctiva to an environmental allergen and binding with specific IgE on the conjunctival mast cells. The resultant mast cell degranulation plays a key role in the pathogenesis of both the early and late phase responses of ocular allergy (Leonardi et al., 2008). Compound 48/80 is a non-immunogenic mast cell degranulating agent that produces manifestations of external allergic inflammation when applied topically to the ocular surface (Allansmith et al., 1989). The degranulation produced by the compound is less extensive but morphologically similar to that seen in vernal and giant papillary conjunctivitis. Therefore, it can serve as a useful tool for testing ocular anti-inflammatory agents (Udell et al., 1989). Studies with compound 48/80 applied topically to rabbit eyes, producing allergic inflammatory manifestations that were evident on clinical examination of the eye as well as on histopathological examination of conjunctival specimens, have been described in literature to show the efficacy of anti-leukotrienes drugs efficacy in the treatment of allergic conjunctivitis. El-Hossary G.G. et al. demonstrated that pretreatment of allergic conjunctivitis model rabbits with 0.1% montelukast eye drops exhibited

improvement of ocular inflammatory manifestations both clinically and by histopathological examination. The improvement was more evident after 24 hours of compound application. (El-Hossary et al., 2010). In agreement with the results of this study, it was before described that oral montelukast for 15 days produced significant and persistent reduction of ocular signs and symptoms in asthmatic patients with vernal keratoconjunctivitis (Lambiase et al., 2003). In addition, Oral montelukast combined with oral cetirizine were effective in decreasing orbital congestion and inflammation in patients with thyroid eye disease (Lauer et al., 2008). Moreover, oral zafirlukast, another leukotriene receptor antagonist similar to montelukast, could significantly attenuate the development of conjunctival oedema and inhibit the increase in the number of eosinophils in rats with experimental allergic conjunctivitis (Minami et al., 2004).

Regarding topical ocular application of these drugs, topical application of a leukotriene receptor antagonist in combination with a cyclooxygenase inhibitor could significantly improve inflammatory manifestations in rabbit eyes burned with sodium hydroxide (Struck et al., 1995). In addition, Papathanassiou et al. (2004) reported that topical application of zafirlukast to rat eyes, challenged with compound 48/80, produced significant inhibition of the late phase nitric oxide production of the conjunctival hypersensitivity response. The authors concluded that leukotriene receptor antagonists might contribute to the management of ocular inflammatory response (Papathanassiou et al., 2004). Outside the eye, inhaled montelukast could significantly inhibit the bronchial constriction induced by LTC<sub>4</sub> and LTD<sub>4</sub> with no injury to the lung tissue in an animal model of asthma (Muraki et al., 2009) and this demonstrates the therapeutic effectiveness and safety of locally applied montelukast.

Montelukast is a leukotriene receptor antagonist that is currently used to treat persistent asthma (Jarvis and Markham, 2000). Although leukotrienes play a role in development of allergic conjunctivitis, they are not the only mediators involved in this disease. Histamine, tryptase and prostaglandins are also involved in the immediate allergic response (Ono and Abelson, 2005). In addition, mast cell degranulation induces activation of vascular endothelial cells and thus the expression of several chemokines and adhesion molecules that finally lead to the ocular allergic late phase reaction (Leonardi et al., 2008). Moreover, conjunctival and corneal epithelial cells and fibroblasts may contribute to mounting the allergic inflammation by expressing and producing cytokines, chemokines, adhesion molecules and growth factors that maintain local inflammation and lead to tissue remodelling (Leonardi et al., 2006). Montelukast was reported to significantly attenuate LT-induced degranulation of bone marrow derived mast cells (Kaneko et al., 2009). The drug was also found to inhibit the expression of vascular endothelial growth factor and its receptors in lung tissue of experimentally induced asthma in rats. Vascular endothelial growth factor is over-expressed in vernal keratoconjunctivitis and may involve tissue growth and remodelling that occur in severe cases of this disease (Asano-Kato et al., 2005).

In El-Houssary's study, pre-treatment of allergic conjunctivitis model rabbits with 1% prednisolone produced more improvement of the allergic response than montelukast, this detected by significant decrease in the clinical scores at all time intervals of examination and by marked improvement of the histopathological picture as the conjunctiva appeared fairly normal after 24 hours of compound application. The result of this study is expected and logical, as topical corticosteroids are very effective in the treatment of allergic conjunctivitis. They have a variety of actions that play a role in suppressing the allergic diseases, and their



role is well documented in both clinical and experimental situations (Reiss et al., 1996). Nevertheless, topical ocular montelukast can be a potential therapeutic drug with a new route of administration that can be used for treatment of allergic conjunctivitis.

Despite the number of pharmacological agents currently used to prevent the clinical manifestations of ocular hypersensitivity, there are still continuing efforts aiming at the development of more efficacious topical medications to control the most severe episodes of the disease (Yanni et al., 1999). Currently, anti-LT therapies are approved only for patients with asthma (Leff, 2001), though recent reports support the clinical efficacy of cysLT receptor antagonists in patients with rhinitis (Wilson, 2001), and more recently in allergic conjunctivitis.

## 7. Conclusions

Allergic conditions are common in all pediatric age groups, and significantly affect the health and overall quality of life of children and their families. Although allergies seem relatively minor, they often cause considerable disruptions to daily life for pediatric patients, including sleep disturbances, limitation of activities, disrupted reading, computer work, or outside play, and impaired psychosocial functioning. Making certain that patients are properly treated with the appropriate therapy will help to improve their quality of life.

Familiarity with diagnosis, treatment, and potential complications of common pediatric ocular allergic conditions will increase the chances of early intervention and avert potentially serious consequences of these diseases.

Early and accurate detection of ocular allergy syndromes in children presents a challenge in the primary care setting, as young children are often unwilling participants in ocular examinations. Involvement of pediatric ophthalmologists with specialized training and equipment may be necessary to avoid preventable vision loss in more severe cases. It is the responsibility of all involved to optimize the treatment of these children suffering from allergic disease.

Topical ocular montelukast can be a potential therapeutic drug with a new route of administration that can be used for treatment of allergic conjunctivitis, as new therapeutic strategies an add-on therapy in resistant cases of ocular allergic diseases.

## 8. References

- Abelson, M.B. & Schaefer, K. (1993). *Conjunctivitis of allergic origin: Immunologic mechanisms and current approaches to therapy*, Surv Ophthalmol, 38: 115-32.
- Accolate: Manufacturer's prescribing information. (1999). Zeneca Pharmaceuticals, Carolina, Puerto Rico
- Akman, A.; Irkec, M. & Orhan, M. (1998). *Effects of lodoxamide, disodium cromoglycate and fluorometholone on tear leukotriene levels in vernal keratoconjunctivitis*, Eye, 12: 291-95.
- Allansmith, M.R.; Baird, R.S.; Ross, R.S.; Barney, N.P. & Bloch K.J. (1989). *Ocular anaphylaxis induced in the rat by topical ap- Placation of compound 48/80*, Acta Ophthalmol, 67:145-153.
- Anderson, D.F. (1996). *The conjunctival late-phase reaction and allergen provocation in the eye*, Clin Exp Allergy, 26: 1105-7.
- Arango, P.; Borish, L.; Frierson, H.F. & Jr, Kountakis, S.E. (2002). *Cysteinyl leukotrienes in chronic hyperplastic rhinosinusitis*, Otolaryngol Head Neck Surg, 127:512-515.
- Arango, P. & Kountakis, S.E. (2002). *Presence of cysteinyl leukotrienes in asthmatic patients with chronic sinusitis*, Laryngoscope, 112:1190-1192.



- Asano-Kato, N.; Fukugawa, K. & Okada, N. (2005). *TGF-beta1, IL-1 beta, and Th2 cytokines stimulate vascular endothelial growth Factor production from conjunctival fibroblasts*, *Exp Eye Res*, 80:555-560.
- Bacon, A.S.; Ahluwalia, P.; Irani, A.M. et al. (2000). *Tear and conjunctival changes during the allergen-induced early and late-phase responses*, *J Allergy Clin Immunol*, 106: 948-54.
- Baudouin, Ch.; Liang, H.; Bremond-Gignac, D. et al. (2005). *CCR4 and CCR5 expression in conjunctival specimens as differential markers of TH1/TH2 in ocular surface disorders*, *J Allergy Clin Immunol*, 116: 614-19.
- Bhargava, A.; Jackson, W.B. & El-Defray, S.R. (1998) *Ocular allergic disease*, *Drugs Today*, 34:957-971.
- Bielory, L. (2000). *Allergic and immunologic disorders of the eye; Part II: ocular allergy*, *J Allergy Clin Immunol*, 106: 1019-32.
- Bielory, L. (2008). *Ocular allergy overview*, *Immunol Allergy Clin North Am*, 28: 1-23.
- Bielory, L. & Friedlaender, M.H. (2008). *Allergic conjunctivitis*, *Immunol Allergy Clin North Am*, 28: 43-57.
- Bigby, T.D.; Hodulik, C.R.; Arden, K.C. & Fu L. (1996). *Molecular cloning of the human leukotriene C4 synthase gene and assignment to chromosome 5q3*, *Mol Med*, 2:637-646.
- Bisgaard, H. & Study group on montelukast and respiratory syncytial virus. (2003) *A randomized trial of montelukast in respiratory syncytial virus post-bronchiolitis*, *Am J Respir Crit Care Med*, 167:379-383.
- Bisgaard, H. (2004). *Montelukast in RSV-bronchiolitis*, *Am J Respir Crit Care Med*, 169:542-543.
- Bonini, S.; Lambiase, A.; Sachhetti, M. & Bonini, S. (2003) *Cytokines in ocular allergy*, *Int Ophthalmol Clin*, 43: 27-32.
- Borish, L. (2002). *The role of leukotrienes in upper and lower airway inflammation and the implications for treatment*, *Ann Allergy Asthma Immunol*, 88:16-22.
- Calder, V.L.; Jolly, G.; Hingorani, M. et al. (1999). *Cytokine production and mRNA expression by conjunctival T-cell lines in chronic allergic eye disease*, *Clin Exp Allergy*, 29: 1214-22.
- Calonge, M.; De Salamanca, A.E.; Siemasko, K.F. et al. (2005). *Variation in the expression of inflammatory markers and neuroreceptors in human conjunctival epithelial cells*, *Ocul Surf*, 3: 145-8.
- Chigbu de, G.I. (2009). *The pathophysiology of ocular allergy: a review*, *Cont Lens Anterior Eye*, 32:3-15.
- Cook, E.B. (2004). *Tear cytokines in acute and chronic ocular allergic inflammation*. *Curr Opin Allergy Clin Immunol*, 4: 441-5.
- Dartt, D.A.; Hodges, R.R.; Li, D.; Shatos, M.A.; Lashkari, K. & Serhan, C.N. (2011). *Conjunctival goblet cell secretion stimulated by leukotrienes is reduced by resolvins D1 and E1 to promote resolution of inflammation*, *J Immunol*, 186:4455-4466.
- Dua, H.S.; Gomes, J.A.; Donoso, L.A. & Laibson, P.R. (1995). *The ocular surface as part of the mucosal immune system: conjunctival mucosa-specific lymphocytes in ocular surface pathology*, *Eye*, 9: 261-7.
- El-Hossary, G.G.; El-Hamid Rizk, K.A.; El-Shazly A.H.M. & Anafy L.K. (2010). *Montelukast as a new topical ocular therapeutic agent for treatment of allergic conjunctivitis: an experimental comparative study*, *Australian Journal of Basic and Applied Sciences*, 1:71-78.
- Epstein, A.B. (2003). *Ocular allergy*, *Optometry*, 74:795- 797.
- Feldberg, W. & Kellaway C.H. (1938). *Liberation of histamine and formation of lysocytin like substances by cobra venom*, *J Physiol*, 94:187-191.

- Fujishima, H.; Takeyama, M.; Takeuchi, T.; Saito, T. & Tsubota, K. (1997) *Elevated levels of substance P in tears of patients with allergic conjunctivitis and vernal keratoconjunctivitis*, Clin Exp Allergy, 27: 372-8.
- Haberal, I. & Corey, J.P. (2003) *The role of leukotrienes in nasal allergy*, Otolaryngol Head Neck Surg, 129:274- 279.
- Henderson, W.R. Jr. (1994) *The role of leukotrienes in inflammation*, Ann Intern Med, 121:684-697.
- Helintö, M.; Renkonen, R.; Tervo, T. Et al. (2004). *Direct in vivo monitoring of acute allergic reactions in human conjunctiva*, J Immunol, 172: 3235-42.
- Higashi, N.; Taniguchi, M.; Mita, H.; Kawagishi, Y.; Ishii, T.; Higashi, A.; Osame, M. & Akiyama, K. (2004) *Clinical features of asthmatic patients with increased urinary leukotriene E4 excretion (hyperleukotrienuria): involvement of chronic hyperplastic rhinosinusitis with nasal polypsis*, J Allergy Clin Immunol, 113:277-283.
- Holgate, S.T. (2000). *Science, medicine, and the future. Allergic disorders*, Br Med J, 320: 231-34.
- Howarth, P.H. (2000). *Leukotrienes in rhinitis*, Am J Respir Crit Care Med, 161:S133-S136.
- Jarvis, B. & Markham, A. (2000). *Montelukast: a review of its therapeutic potential in persistent asthma*, Drugs, 59:891-928.
- Jones, T.R.; Labelle, M.; Belley, M.; Champion E.; Charette, L.; Evans, J.; Ford-Hutchinson, A.W.; Gauthier, J.Y.; Lord, A. & Masson, P. (1995). *Pharmacology of montelukast sodium (Singulair), a potent and selective leukotriene D4 receptor antagonist*, Can J Physiol Pharmacol, 73:191-195.
- Kaneko, I.; Suzuki, K.; Matsuo, H.; Kumagai, H.; Owada, Y.; Noguchi, N.; Hishinuma, H. & Ono, M (2009). *Cysteinil Leukotrienes enhance the degranulation of bone marrow-derived mast cells through the autocrine mechanism*, Tohoku J Exp Med, 217:185-191.
- Keam, S.J.; Lyseng-Williamson, K.A. & Goa K.L. (2003). *Pranlukast: a review of its use in the management of asthma*, Drugs, 63:991-1019.
- Khoshoo, V.; Ross, G. & Edell, D. (2002) *Effect of interventions during acute respiratory syncytial virus bronchiolitis on subsequent long term respiratory morbidity*, Pediatr Infect Dis J, 21:468-472.
- Knop, N. & Knop, E. (2000). *Conjunctiva-associated lymphoid tissue in the human eye*, Invest Ophthalmol Vis Sci, 41: 1270-9.
- Knop, E. & Knop, N. (2001). *Lacrimal drainage-associated lymphoid tissue (LDALT): a part of the human mucosal immune system*, Invest Ophthalmol Vis Sci, 42: 566-74.
- Ko, S.M.; Kim, M.K. & Kim, J.C. (2000). *The role of nitric oxide in experimental allergic conjunctivitis*, Cornea, 19: 84-91.
- Lakomski, P.G. & Chitre, M. (2004). *Evaluation of the utilization patterns of leukotriene modifiers in a large managed care health plan*, J Manag Care Pharm, 10:115-121.
- Lambiase, A.; Bonini, S.; Rasi, G.; Coassin, M. & Bruscolini, A. (2003). *Montelukast, a leukotriene receptor antagonist, in vernal keratoconjunctivitis associated with asthma*, Arch Ophthalmol, 121: 615-620.
- Lauer, S.A.; Silkiss, R.Z. & McCormick, S. A (2008). *Oral montelukast and cetirizine for thyroid eye disease*, Ophthal Plast Reconstr Surg, 24: 257-261.
- Leff, A.R. (2001). *Regulation of leukotrienes in the management of asthma: biology and clinical therapy*, Annu Rev Med, 52:1-14.
- Lemp, M.; Baudouin, C.; Baum, J.; Dogru, M.; Foulks, G.; Kinoshita, S.; Laibson, P.; McCulley, J.; Murube, J.; Pflugfelder, S. C., et al. (2007). *The definition and classification of dry eye disease: report of the Definition and Classification Subcommittee of the International Dry Eye WorkShop*, Ocul Surf, 5: 75-92.
- Leonardi A. (2000). *Role of histamine in allergic conjunctivitis*, Acta Ophthalmol Scand, 230: S18-21.


- Leonardi, A. & Abelson, M. (2003). *Double-masked, randomized, placebo-controlled, clinical study of the mast cellstabilizing effects of treatment with olopatadine in the conjunctival allergen challenge model in humans*, Clin Ther, 25:2539-2552.
- Leonardi, A. (2005). *In-vivo diagnostic measurements of ocular inflammation*, Curr Opin Allergy Clin Immunol, 5:464-72.
- Leonardi, A.; Fregona, I.A.; Plebani, M.; Secchi, A.G. & Calder VL. (2006). *Th1- and Th2-type cytokines in chronic ocular allerg*, Graefes Arch Clin Exp Ophthalmol, 244:1240-5.
- Leonardi, A.; Motterle, L. & Bortolotti M. (2008). *Allergy and the eye*, Clin. Exp. Immunol, 153:17-21.
- Leonardi, S.; Marchese, G.; Marseglia GL. & La Rosa M. (2007). *Montelukast in allergic diseases beyond asthma*, Allergy Asthma Proc, 28:287-291.
- Lewis, R.A.; Austen, K.F. & Soberman, R.J. (1990). *Leukotrienes and other products of the 5-lipoxygenase pathway. Biochemistry and relation to pathobiology in human diseases*, N Engl J Med, 323:645-655.
- Magone, M.T.; Whitcup, S.M.; Fukushima, A.; Chan, C.C.; Silver, P.B. & Rizzo, L.V. (2000). *The role of IL-12 in the induction of late-phase cellular infiltration in a murine model of allergic conjunctivitis*, J Allergy Clin Immunol, 105:299-308.
- Marmou. S. & Raffard, M. (2004). *Allergic conjunctivitis: diagnosis and treatment*, Allergy Immunol, 36:25-29.
- McGill, K.A. & Busse, W.W. (1996). *Zileuton*, Lancet, 348:519-524.
- McGill, J.I.; Holgate, S.T.; Church, M.K.; Anderson, D.F.; & Bacon, A. (1998). *Allergic eye disease mechanisms*, Br J Ophthalmol, 82: 1203-14.
- Meijer, F.; Van Delft, J.L.; Garrelds, I.M.; Van Haeringen, N.J. & Kijlstra, A. (1996). *Nitric oxide plays a role as a mediator of conjunctival edema in experimental allergic conjunctivitis*, Exp Eye Res, 62: 359- 65.
- Mikulowska-Mennis, A.; Xu, B.; Berberian, J.M. & Michie, S.A. (2001). *Lymphocyte migration to inflamed lacrimal glands is mediated by vascular cell adhesion molecule-1/a4b1 integrin, peripheral node addressin/L-selectin, and lymphocyte function-associated antigen-1 adhesion pathways*, Am J Pathol, 159: 671-81.
- Minami, K.; Fujii, Y. & Kamei, C. (2004). *Participation of chemical mediators in the development of experimental allergic conjunctivitis in rats*, Int. Immunopharmacol, 4: 1531-1535.
- Miyazaki, D. ; Tominaga, T.; Yakura, K.; Cuo, C.; Komatsu, K.; Inoue, Y. & Ono, S.J. (2008). *Conjunctival mast cell as a mediator of eosinophilic response in ocular allergy*, Mol Vis, 14:1525-1532.
- Motterle, L.; Diebold, Y.; De Salamanca, A.E. et al. (2006) *Altered expression of neurotransmitter receptors and neuromediators in vernal keratoconjunctivitis*, Arch Ophthalmol, 124: 462-8.
- Muraki, M.; Imbe, S.; Sato, R.; Ikeda, Y.; Yamagata, S.; Iwanaga T. & Tohda, Y. (2009). *Inhaled montelukast inhibits cystinyl- leukotriene-induced bronchoconstriction in ovalbumin-sensitized guinea-pigs: the potential as a new asthma medication*, Int Immunopharmacol, 9: 1337-1341.
- Nathan, R.A.; Meltzer, E.O.; Selner, J.C. & Storms, W. (1997). *Prevalence of allergic rhinitis in the United States*, J Allergy Clin Immunol, 99: S808-S814.
- Ono, S.J. & Abelson, M.B. (2005). *Allergic conjunctivitis: update on pathophysiology and prospects for future treatment*, J Allergy Clin. Immunol, 115: 118-122.
- Papathanassiou, M.; Giannoulaki V. & Tiligada, E. (2004). *Leukotriene antagonists attenuate late phase nitric oxide production during the hypersensitivity response in the conjunctiva*, Inflamm Res, 53: 373-376.
- Parnes, S.M. (2002). *Targeting cysteinyl leukotrienes in the treatment of rhinitis, sinusitis, and paranasal polyps*, Am J Respir Med, 1:403-408.



- Parnes, S.M. & Chuma, A.V. (2000). *Acute effects of antileukotrienes on sinonasal polyposis and sinusitis*, Ear Nose Throat J, 79:18-20, 24-25.
- Parnes, S.M. (2003). *The role of leukotrienes inhibitors in patients with paranasal sinus syndrome*, Curr Opin Otolaryngol Neck Surg, 11:184-191.
- Paulsen, F. (2003). *The human nasolacrimal ducts*, Adv Anat Embryol Cell Biol, 170: 1-106.
- Paulsen, F.P.; Paulsen, J.L.; Thale, A.B.; Schaudig, U.; Tillmann, B.N. (2002). *Organized mucosa-associated lymphoid tissue human nasolacrimal ducts*, Adv Exp Med Biol, 506: 873-6.
- Pelikan, Z (1996). *The late nasal response*. Thesis, The Free University of Amsterdam, Amsterdam.
- Pelikan, Z. (2002). *The causal role of the nasal allergy in some patients with allergic conjunctivitis*, Allergy, 57: 230.
- Pelikan, Z. (2009 a). *Seasonal and perennial allergic conjunctivitis: the possible role of nasal allerg.* Clin Exp Ophthalmol, 37:448-457.
- Pelikan, Z. (2009 b). *The possible involvement of nasal allergy in allergic keratoconjunctivitis*, Eye, 23:1653-1660.
- Pelikan, Z (2010). *Allergic conjunctivitis and nasal allergy*, Curr Allergy Asthma Resp, 10:295-302
- Radcliffe, M.J.; Lewith, G.T.; Prescott, P.; Church, M.K. & Holgate, S.T. (2006). *Do skin prick and conjunctival provocation tests predict symptom severity in seasonal allergic rhinoconjunctivitis?* Clin Exp Allergy; 36: 1488-93.
- Reiss, J.; Abelson, M.B.; George, M.A. & Wedner, H.J. (1996). *Allergic conjunctivitis*. In *Ocular infection and immunity*, Eds, Pepose, J.S., G.N. Holland and K.R. Wilhelmus. Mosby-Year Book Inc., pp:345-358.
- Riccioni, G.; Santilli, F.; D'Orazio, N.; Sensi, S.; Spoltore, R.; De Benedictis, M.; Guagnano, M.T.; Di Illio, C.; Schiavone, C.; Ballone, E. & DellaVecchia R. (2002). *The role of antileukotrienes in the treatment of asthma*, Int J Immunopathol Pharmacol, 15:171-182.
- Sacre Hazouri, J.A. (2008). *Leukotriene antagonists in the treatment of allergic rhinitis and comorbidities*, Rev Alerg Mex, 55: 164-175.
- Samuelsson, B.; Dahlén, S.E.; Lindgren, J.A.; Rouzer, C.A. & Serhan, C.N. (1987). *Leukotrienes and lipoxins: Structures biosynthesis, and biological effects*, Science, 237:1171-1176.
- Scadding, G.K. (2003). *Recent advances in the treatment of rhinitis and rhinosinusitis*, Int J Pediatr Otorhinolaryngol, 67:S201-204.
- Schleimer, R.P.; MacGlashan, D.W. Jr.; Peters, S.P. et al. (1986). *Characterization of inflammatory mediator release from purified human lung mast cells*, Am Rev Respir Dis, 133:614 -617.
- Schultz, B.L. (2006). *Pharmacology of ocular allergy*, Curr Opin Allergy Clin Immunol, 6:383-389.
- Sirigu, P.; Maxia, C.; Puxeddu, R.; Zucca, I.; Piras, F. & Perra, MT. (2000). *The presence of a local immune system in the upper blind and lower part of the human nasolacrimal duct*, Arch Histol Cytol, 63: 431-9.
- Smith, J.; Albeitz, J.; Begley, C.; Caffery, B.; Nichols, K.; Schaumberg, D. A. & Schein, O. (2007). *The epidemiology of dry eye disease: report of the Epidemiology, Subcommittee of the International Dry Eye WorkShop 2007*. Ocul Surf, 5: 93-107.
- Spector, S.L. (1997). *Overview of comorbid associations of allergic rhinitis*, J Allergy Clin Immunol, 99:S773-S780.
- Spector, S.L. & Antileukotriene Working Group. (2001). *Safety of antileukotriene agents in asthma management*, Ann Allergy Asthma Immunol, 86:18-23.
- Stahl, J.L. & Barney, N.P. (2004). *Ocular allergic disease*, Curr Opin Allergy Clin Immunol, 4: 455-9.



- Stainke, J.W.; Bradley, D.; Arango, P.; Crouse, C.D.; Frierson, H.; Kountakis, S.E.; Kraft, M. & Borish, L. (2003). *Cysteinil Leukotriene expression in chronic hyperplastic sinusitis-nasal polypsis: importance to eosinophilia and asthma*, J Allergy Clin Immunol, 111:342-329.
- Steinke, J.W.; Crouse, C.D.; Bradley, D.; Hise, K.; Lynch, .; Kountakis, S.E.& Borish, L. (2004). *Characterization of interleukin- 4-stimulated nasal polyp fibroblasts*, Am J Respir Cell Mol Biol, 30:212-219.
- Stern, M.E.; Siemasko, K.F. & Niederkorn, J.Y. (2005). *The Th1/Th2 paradigm in ocular allergy*, Curr Opin Allergy Clin Immunol, 5: 446–50.
- Struck, H.G.; Giessler, S. & Giessler, C. (1995). *Effect of non-steroidal anti-inflammatory drugs on inflammatory reaction. An animal experimental study*, Ophthalmologe, 92: 849- 853.
- Szefer, S.J. & Simoes, E.A. (2003) *Montelukast for respiratory syncytial virus bronchiolitis: significant effect or provocative findings?* Am J Respir Crit Care Med, 167: 290-291.
- Takahashi, Y.; Ichikawa, M.; Nawate, M.; Kamoshida, H. & Shikano, T. (2003). *Clinical evaluation of urinary leukotriene E4 levels in children with respiratory syncytial virus infection*, Arerugi, 52:1132-1137.
- Taylor, F.; Hutchinson, S.; Graff-Radford, S. & Harris, L. *Diagnosis and management of migraine in family practice*, J Fam Pract, S3-S24.
- Uchio, E.; Kimura, R.; Migita, H.; Kozawa, M. & Kadonosono, K. (2008) *Demographic aspects of allergic ocular diseases and evaluation of new criteria for clinical assessment of ocular allergy*, Graefes Arch Clin Exp Ophthalmol, 246: 291–6.
- Udell, I.J.; Kenyon, K.R.; Hannien, L.A. & Abelson, M.B. (1989). *Time course of human conjunctival mast cell degranulation. In response to compound 48/80*, Acta Ophthalmol, 31,226-230.
- Vignola, A.M.; Chanez, P. & Bousquet, J. (2003). *The relationship between asthma and allergic rhinitis: Exploring the basis for a common pathophysiology*, Clin Exp Allergy Rev, pp 3:63-68.
- Von Mutius E. (1998). *The rising trend in asthma and allergic disease*, Clin Exp Allergy, pp 28, 45-49.
- Yanagawa, H.; Sugita, A.; Azuma, M.; Ogawa, H.; Kitamuro, C.; Yoneda, K.; Shinkawa, K.; Tani, K.& Sone, S. (2004) *Long-term follow-up of pulmonary function in bronchial asthma in patients treated with pranlukast*, Lung, 182:51-58.
- Yanni, J.M.; Sharif, N.A.; Gamache, D.A.; Miller, S.T.; Weimer, L.K. & Spellman, J.M. (1999). *A current appreciation of sites for pharmacological intervention in allergic conjunctivitis: effects of new topical ocular drugs*, Acta Ophthalmol Scan, 228: 33–7.
- Weimer, L.K.; Gamache, D.A. & Yanni, J.M. (1998). *Histamine-stimulated cytokine secretion from human conjunctival epithelial cells: inhibition by the histamine H1 antagonist emedastine*, Int Arch Allergy Immuno, 115: 288–93.
- Wenzel, S.E.; Szefer S.J.; Leung, D.Y.; Sloan, S.I.; Rex, M.D. & Martin R.J. (1997). *Bronchoscopic evaluation of severe asthma. Persistent inflammation associated with high dose glucocorticoids*, Am J Respir Crit Care Med. 156:737-743.
- Wenzel, S.; Larsen, G.L.; Johnson, K. et al. (1990). *Elevated levels of leukotriene C4 in bronchoalveolar lavage fluid from atopic asthmatics after endobronchial allergen challenge*, Am Rev Respir Dis, 142:112-119.
- Wilson, A.M.; Orr, L.C.; Sims E.J. & Lipworth, B.J. (2001). *Effects of monotherapy with intra-nasal corticosteroid or combined oral histamine and leukotriene receptor antagonists in seasonal allergic rhinitis*, Clin Exp Allergy, 31: 61–8.
- Ziskin, A. (2006). *Allergic conjunctivitis*, Curr Allergy Clin Immunol, 19: 56–9.
- Zoukhri, D. (2006) *Effect of inflammation on lacrimal gland function*, Exp Eye Res, 82: 885–98.



## **Conjunctivitis - A Complex and Multifaceted Disorder**

Edited by Prof. Zdenek Pelikan

ISBN 978-953-307-750-5

Hard cover, 232 pages

**Publisher** InTech

**Published online** 23, November, 2011

**Published in print edition** November, 2011

This book presents a number of interesting and useful aspects and facets concerning the clinical features, properties and therapeutical management of this condition. Dr. H. Mejía-López et al. present an interesting survey of the world-wide epidemiologic aspects of infectious conjunctivitis. Dr. U. Ubani evaluates conjunctival symptoms/signs participating in the clinical features of this disorder. Dr. A. Robles-Contreras et al. discuss immunologic aspects underlying possibly the conjunctivitis. Dr. Z. Pelikan presents the cytologic and concentration changes of some mediators and cytokines in the tears accompanying the secondary conjunctival response induced by the nasal challenge with allergen. Dr. S. Sahoo et al. summarize the treatment and pharmacologic control of particular clinical forms of conjunctivitis in general practice. Dr. S. Leonardi et al. explain the basic pharmacologic effects of leukotriene antagonists and their use for the treatment of allergic conjunctivitis. Dr. J.A. Capriotti et al. evaluate the therapeutical effects of various anti-adenoviral agents on the acute conjunctivitis caused by adenovirus. Dr. V. Vanzzini-Zago et al. assess the prophylactic use and efficacy of "povidone-iodium solution", prior the ocular surgery. Dr. F. Abazi et al. present the clinical features, diagnostic and therapeutical aspects of "neonatal conjunctivitis". Dr. I.A. Chaudhry et al. review the special sub-form of conjunctivitis, being a part of the "Trachoma". Dr. B. Kwiatkowska and Dr. M. Maślińska describe the clinical, pathophysiologic and immunologic features of conjunctivitis. Dr. S. Naem reviews the conjunctivitis form caused by *Thelazia* nematodes, occurring principally in animals.

### **How to reference**

In order to correctly reference this scholarly work, feel free to copy and paste the following:

Salvatore Leonardi, Giovanna Vitaliti, Giorgio Ciprandi, Carmelo Salpietro and Mario La Rosa (2011).  
Leukotriene Antagonist Drugs as Treatment of Allergic Conjunctivitis and Comorbidities in Children,  
Conjunctivitis - A Complex and Multifaceted Disorder, Prof. Zdenek Pelikan (Ed.), ISBN: 978-953-307-750-5,  
InTech, Available from: <http://www.intechopen.com/books/conjunctivitis-a-complex-and-multifaceted-disorder/leukotriene-antagonist-drugs-as-treatment-of-allergic-conjunctivitis-and-comorbidities-in-children>

**INTech**  
open science | open minds

### **InTech Europe**

University Campus STeP Ri  
Slavka Krautzeka 83/A  
51000 Rijeka, Croatia

### **InTech China**

Unit 405, Office Block, Hotel Equatorial Shanghai  
No.65, Yan An Road (West), Shanghai, 200040, China  
中国上海市延安西路65号上海国际贵都大饭店办公楼405单元

[www.intechopen.com](http://www.intechopen.com)

Phone: +385 (51) 770 447  
Fax: +385 (51) 686 166  
[www.intechopen.com](http://www.intechopen.com)

Phone: +86-21-62489820  
Fax: +86-21-62489821

IntechOpen

IntechOpen

© 2011 The Author(s). Licensee IntechOpen. This is an open access article distributed under the terms of the [Creative Commons Attribution 3.0 License](https://creativecommons.org/licenses/by/3.0/), which permits unrestricted use, distribution, and reproduction in any medium, provided the original work is properly cited.

IntechOpen

IntechOpen