

We are IntechOpen, the world's leading publisher of Open Access books Built by scientists, for scientists

6,900

Open access books available

186,000

International authors and editors

200M

Downloads

Our authors are among the

154

Countries delivered to

TOP 1%

most cited scientists

12.2%

Contributors from top 500 universities



WEB OF SCIENCE™

Selection of our books indexed in the Book Citation Index
in Web of Science™ Core Collection (BKCI)

Interested in publishing with us?
Contact book.department@intechopen.com

Numbers displayed above are based on latest data collected.
For more information visit www.intechopen.com



Allergic Conjunctivitis: An Immunological Point of View

Atzin Robles-Contreras and Concepción Santacruz et al.*

*Research Unit and Department of Immunology
Institute of Ophthalmology "Fundación Conde de Valenciana", Mexico City
Laboratory of Molecular Immunology, National School of Biological Sciences
IPN Mexico City
México*

1. Introduction

Allergic conjunctivitis (AC) is an inflammation of the conjunctiva secondary to an immune response to external antigens, usually called allergens. This inflammation could be IgE-mediated and non-IgE mediated and atopy could play a significant role in clinical evolution. (Johansson et al., 2004) AC is not a single disease; in fact it is a syndrome affecting the entire ocular surface, including conjunctiva, lids, cornea, and tear film. The signs and symptoms of allergic conjunctivitis have a meaningful effect on comfort and patient health, and are influenced by genetics, environment, ocular microbiota, and immune regulation mechanisms, all of which work together in a complex immunological response. Dysregulation in such immune homeostasis could turn into a variety of allergic ocular diseases (AOD). This chapter describes the current understanding of cellular and molecular pathways involved in different AOD, the clinical characteristics of ocular allergies, the new therapies related to control of immune activation, and the importance of basic research to generate new types of immunotherapy to treat allergic conjunctivitis

2. Immunological mechanisms of allergic conjunctivitis

Two stages have been defined in AC immune pathophysiology. The first stage is named sensitization phase reaction, and is initiated by preferential activation and polarization of the immune response to environmental antigens, that culminates with a generation of a predominant Th2 immune response and production of IgE antibodies; the second stage, named effector phase reaction, is initiated with a second encounter with antigen (Ag)

*Julio Ayala¹, Eduardo Bracamontes², Victoria Godinez¹, Iris Estrada-García³, Sergio Estrada-Parra³, Raúl Chávez⁴, Mayra Perez-Tapia³, Victor M. Bautista-De Lucio¹ and Maria C. Jiménez-Martínez^{1,4**}

¹Research Unit and Department of Immunology, Institute of Ophthalmology "Fundación Conde de Valenciana", Mexico City, Mexico

²ETN Department, "Clínica de Especialidades con CECIS Churubusco", ISSSTE, Mexico City, México

³Laboratory of Molecular Immunology, National School of Biological Sciences, IPN, Mexico City, México

⁴Department of Biochemistry, Faculty of Medicine, UNAM, Mexico City, México

**Corresponding Author

leading to activation of effector mechanisms, such as degranulation of granulocytes and release of histamine (Abelson et al., 2003).

2.1 Sensitization phase reaction

It has been reported in patients with asthma (Takhar et al., 2007) and allergic rhinitis (Takhar et al., 2005), that both, bronchial and nasal mucosa, have the ability to capture Ag through Langerhans cells (LC). LC could process and present Ag in the context of MHC-II molecules and stimulate specific CD4⁺T cells to induce secretion of interleukin (IL)-4, IL-13 and expression of CD154; this process activates genetic recombination in B cells and class switching to IgE. Similar mechanism could be involved in ocular mucosa, since it has been reported that IgE could be detectable in human tears (Allansmith et al., 1976) and B cells located in the conjunctival lymphoid follicles are CD23⁺ CD21⁺ CD40⁺, suggesting that they might be precursors of IgE-producing B cells and contribute to local IgE synthesis (Abu El-Asrar et al., 2001).

2.2 Effector phase reaction

Allergen-induced cell degranulation is the key event in allergic inflammation and leads to early-phase symptoms. Early phase reaction (EPR) has been studied extensively in both humans and animals; EPR is initiated with a second encounter with the antigen by IgE previously attached to IgE receptors (FcεRI, FcεRII or CD23). Cross-linking of IgE receptors induces: a) release of preformed mediators such as histamine, proteases and chemotactic factors; b) activation of transcription factors and cytokine gene expression, and c) production of prostaglandins and leukotrienes by phospholipase A2 pathway. Activation of mast cells by IgE in conjunctiva is relevant since it is well known that there are up to 6000 cell/mm³ in conjunctiva (Bielory, 2000) and mast cell density is increased in acute and chronic conjunctivitis patients (Anderson et al., 1997; Morgan et al., 1991). Activated mast cells can release several cytokines such as IL-4, IL-6, IL-13, and Tumor Necrosis Factor (TNFα) contributing to increase local inflammatory Th2 response (Anderson et al., 2001; Cook et al., 1998), and also are able to increase FcεRI density in chronic keratoconjunctivitis (Matsuda et al., 2009). On the other hand, cellular infiltration is the main feature of the late phase reaction (LPR). LPR begins 4-24 hr after EPR, and involves the infiltration of inflammatory cells, basophils, neutrophils, T Lymphocytes, and mainly eosinophils (Choi & Bielory, 2008). Animal models of AC have shown that inflammatory migration is directed by T cells; recently, a relevant role for γδ T cells have been suggested since TCRγδ (-/-) mice have shown a decreased clinical manifestations and eosinophilic infiltration compared with wild type mice (Reyes et al., 2011); however, involvement of γδ T cells in human AC is still unknown. Once initiated, LPR can proceed in the presence of little or no detectable allergen-specific IgE antibody. LPR can also be induced by adoptively transference of T cells from allergen-sensitized donors to naïve recipients prior to challenging the ocular surface with the specific antigen (Fukushima et al., 2005). LPR could lead to corneal complications secondary to eosinophil infiltration. Eosinophils are attracted to ocular surface due to ligation of eotaxin-CC-chemokine receptor (CCR) 3 or RANTES-CCR1 (Heath et al., 1997). Notably, CCR3 chemotaxis induced by culture supernatant from corneal keratocytes and tear samples from severely allergic patients, could be inhibited by specific monoclonal antibodies against CCR3 (Fukagawa et al., 2002). Basophil infiltration could also be associated with AC because these cells express CCR3 and contribute with direct damage through FcεRI degranulation. Interestingly in a mice model of AC basophil activation could also be induced by IL-33,

resulting in IL-4 and IL-13 expression, and potentiation of IgE-mediated degranulation (Matsuba-Kitamura et al., 2010). However, during the active inflammatory phase of the disease, multiple Th1-type and Th2-type cytokines are over expressed and produced (Leonardi, et al., 2006; Aguilar-Velazquez et al., 2009), including the typical Th1-type cytokine, interferon (IFN)- γ and TNF α , which might probably contribute to increase ocular inflammation similarly to animal models (Stern et al., 2005; Fukushima et al., 2006). The Th1-cells could also play a pivotal role in the delayed hypersensitivity ocular damage, through cell-mediated mechanisms, acting as a counter-balance factor to the Th2-cells, during antigen presentation and in the activation/inhibition of other cell types. Delayed hypersensitivity damage has also been suggested in asthma and nasal allergy (Pelikan, 2010; Pelikan, 2011)

2.3 Different cell populations and its impact in ocular allergy

Despite the role of dendritic cells (DC) have been extensively studied in animal models, other antigen presenting cells (APC) are still in research. Recently it has been suggested that macrophages could be needed in the development of experimental AC, since it appears they are able to take up antigen-labeled and act as APC (Ishida et al., 2010); nevertheless, further research in human patients is needed to know the real role of macrophages in AC. In addition, fibroblasts, conjunctival and corneal epithelial cells may contribute to human allergic inflammation by expressing and producing cytokines, chemokines, adhesion molecules and factors that maintain local inflammation and lead to tissue remodeling (Bonini et al., 2000; Leonardi et al., 2006).

2.4 T regulatory cells (Tregs)

An increasing number of reports have demonstrated that Tregs suppress allergic specific response (Akdis et al., 2004). In support of the important role of Tregs in controlling allergic diseases, it was demonstrated that CD4+CD25+ T cells protect against experimentally induced asthma, diminishing airway inflammation and hyper-reactivity after *in vivo* transfer of CD4+CD25+ regulatory T cells in IL-10 dependent manner (Lewkowich et al., 2005). In animal models of AC it has been suggested that induction of CD4+CD25+Foxp3+ T cells suppress the development of experimental allergic conjunctivitis through stimulation of alpha-galactosylceramide (Fukushima et al., 2008). Unfortunately research about involvement of Tregs in human AC is not enough yet.

2.5 Other T cell populations

Although in other allergies is well known the involvement of Th9, Th17, Th22, and NKT cells in effector responses, a long way in research is still pending in AC in both, human and animal models. Additionally, other molecules such as Toll like receptors (TLR) and Nucleotide Oligomerization Domain (NOD) receptors that are expressed in epithelial cells, DC and T cell subsets (Bauer et al., 2007) could be modulating the immune response in unexpected ways depending of ocular microbiota, thus AC must be a field of extensive research.

3. Clinical aspect of allergic conjunctivitis

3.1 Classification of allergic ocular diseases

Allergic conjunctivitis includes a spectrum of a number of traditional overlapping conditions that range from intermittent to persistent symptoms and signs, variable in severity and presentation. These forms include seasonal (SAC) and perennial allergic

conjunctivitis (PAC), vernal keratoconjunctivitis (VKC) and atopic keratoconjunctivitis (AKC). Giant papillary conjunctivitis (GPC), and contact or drug-induced dermatconjunctivitis (CDC) are considered as subtypes of allergic conjunctivitis, due to their mechanism of allergy. (Leonardi et al., 2007).

Patients with mild forms of AC report symptoms with active signs not always seen at the time visit. Some of these symptoms include runny nose, sneezing, and or/wheezing. Classic reports describe allergic rhinitis and symptoms of watery (88%), itchy (88%), red (78%), sore (75%), swollen (72%) and stinging eyes (65%) (Dykewicz & Fineman, 1998). The main symptom of ocular allergy is itching, without itching; a condition should not be considered ocular allergy. Clinical manifestations of the effects of eye rubbing include injection of conjunctival vascular bed due to vascular dilation evoked by vasoactive amines released during mast cell degranulation, accompanied by an influx of water from the intravascular space, to the extravascular space, resulting in tissue edema and eyelid swelling, progressing from a milky or pale conjunctiva aspect to conjunctival swelling or chemosis. Swelling appears 15-30 minutes after antigen exposure and slowly diminished; a small quantity of white mucus secretion may form during the acute phase which can later becomes thick strands in the chronic form. In chronic forms a remodeling process is induced in conjunctiva tissue as fibrosis with vascularization that can be easily identified with slit lamp (Ono & Abelson, 2005)

There are numerous classifications for AOD according to the underlying pathophysiology and clinical findings. Common signs and symptoms exist in the different types of allergic disorders with frequent overlapping between SAC, PAC (acute forms of allergic conjunctivitis), VKC and AKC (chronic forms of conjunctivitis); therefore, classifications are recommended to standardize disease based on signs and symptoms, (mild, moderate or severe), (Abelson et al., 1990; Uchio et al., 2008; Pelikan, 2009) length of the disease (acute *vs* chronic disease), mechanism of immunopathogenesis (EPR and LPR stages), and duration of episodes activity (quiescent, intermittent and persistent), only suggested to VKC and AKC (Bonini et al., 2007; Calonge & Herreras, 2007), since they impact the quality of life. Such matter is important and should be consider in AOD diagnosis, similar to other allergic diseases (Del Culvillo et al., 2010). Although it has been suggested that SAC and GPC are milder and there is not involvement of the cornea, PAC and CDC might have a moderate risk of sight threatening, while VKC and AKC are the most serious forms of AC (Tanaka et al., 2004; Foster & Calonge, 1990). Therefore a grade of severity, in terms of signs and symptoms, is crucial to establishment of ocular clinical status, and possible vision compromise in AC patients.

3.2 Evaluation of grade of severity for allergic ocular diseases

The most common way to identify severity based mainly on conjunctiva, palpebral or cornea inflammation are mild, moderate or severe; however to better assess clinical characteristics in AOD groups, and to evaluate possible evolution of AC, the authors propose here, besides to take all recommendations mentioned above, a grading system based on a scale of 0 to 4, when 0=absent, 1=mild, 2=moderate, 3=moderately severe, and 4=severe, for both signs and symptoms. Taking in consideration, frequency in symptoms (itching, tearing, light sensitivity, gritty sensation, and burning sensation), (Table 1) and repercussion of signs implicated on alterations accompanying the inflammation at the

ocular surface, such as eyelid position and skin aspect, eyelid margin state of mucocutaneous junction (MCJ) with involvement of meibomian gland disease (MGD), discharge aspect, implication of limbal stem cell deficiency and even keratoconus involvement. (Figure 1 and Table 2) The total score of signs and symptoms following grade of severity scale would give a total amount of 48 points, twenty of them corresponding to symptoms, and twenty eight of them corresponding to signs. According to this statement, we propose an objective grading system to recognize progress of allergic ocular disease, which could be defined as follows: 0 points= Absent, 1-12 points (mild), 13-24 points (moderate), 25-36 points (moderately severe) and 36-48 points (severe). The score of the more severe side in bilateral cases could be used as a clinical score.


























Evaluation of Grade of Symptoms Severity for Allergic Ocular Diseases					
	0 None of the time	1 Some of the time	2 Half of the time	3 Most of the time	4 All of the time
Itching					
Tearing					
Light Sensitivity					
Gritty Sensation					
Burning Sensation					

Table 1. Evaluation of Grade of Symptoms Severity for Allergic Ocular Diseases

Evaluation of Grade of Severity for Allergic Ocular Diseases							
Signs Grades	Eyelid Position and Skin aspect	Eyelid Margin Marx's Line (MGD)	Conjunctiva hyperemia and swelling	Conjunctiva discharge	Tarsal conjunctiva Inflammation Response	Limbus Involvement	Cornea Involvement
0	No eyelid edema	No displacement of MCJ	No hyperemia or edema	No discharge	No papillary hyperplasia or visible follicles	No visible limbus nodules or dots	No SPK
1	Localized superior or inferior eyelid margin edema without Dennie Lines.	1/3 displacement of MCJ inferior or superior eyelid margin	hyperemia 1+ - 2+ with 1/3 pink edema aspect in conjunctiva. No conjunctiva plica formation in sac fundus	Clear watery discharge and/or slight debris within	Less than 1/3 tarsal papillae size 0.3 with visible uniform conjunctiva tarsal vessels	Less than one quadrant with dot Trantas	Slight SPK without central involvement
2	Generalized superior and/or inferior eyelid edema with slight pseudoptosis and Dennie Lines	2/3 displacement of MCJ inferior or superior eyelid margin	Hyperemia 2+ - 3+ with 2/3 redness edema aspect in conjunctiva, and/ or slight conjunctiva plica formation in sac fundus	White-gray mucoid discharge in sac fundus or adherent 1/3 to limbus or tarsal conjunctiva	1/3 to 2/3 moderate tarsal papillae 0.3-0.5 size with thin visible tarsal conjunctiva vessels.	One ¼ to one half of dot trantas on limbus with slight pigment	One quarter to one half of SPK without compromise of visual axis.
3	Unilateral or bilateral moderate pseudoptosis and several Dennie Lines	Generalized displacement of MCJ	Hyperemia > 3+ with more than 2/3 conjunctiva edema with localized engorgement of ciliary vessels Moderate plica formation in sac fundus	White, gray or yellow thick copious mucoid strands in sac fundus or adherent 2/3 to limbus or tarsal conjunctiva	Cobblestone papillae presentation. More than 2/3 tarsal papillae 0,75 size.with or without fibrosis. fairly irregular tarsal vessels.	More than one half of dot trantas on limbus with slight to moderate pigment or ¼ to one half of LSCD	Generalized SPK with compromise of visual axis, or epithelial defects. Indolent corneal Ulcer on superior quadrants.
4	Uni or Bilateral severe Pseudoptosis with Dennie Lines and changes on skin texture and pigmentation. Hertoghe's sign present.	Scarring or keratinized changes	Same as grade 3+ generalized engorgement of ciliary vessels. Severe plica or conjunctiva folding formation in sac fundus	Thin copious farely strands adherent mainly to cornea surface	Few tarsal papillae > 0.75 with fibrosis or Macro Papillae extrusion and possible formix foreshortening (symblefaron) or Generalized pale tarsal conjunctiva aspect without normal visible tarsal vessels.	Generalized dot trantas on limbus with fibrosis and pigment or more than one half of LSCD	Keratoconus with or without central leucoma
Hyperemia Grading: 0 = Absence of hyperemia. 1+ = mild (1/3 localized sector engorgement of bulbar conjunctival vessels), and 3+ = severe (significant generalized engorgement of bulbar conjunctival vessels) SPK (Superficial punctate Keratopathy) LSCD (Limbal Stem Cell Deficiency) MGD (Meibomian Gland Disease) MCJ (Mucocutaneous junction)							

Table 2. Evaluation of Grade of Signs Severity for Allergic Ocular Diseases

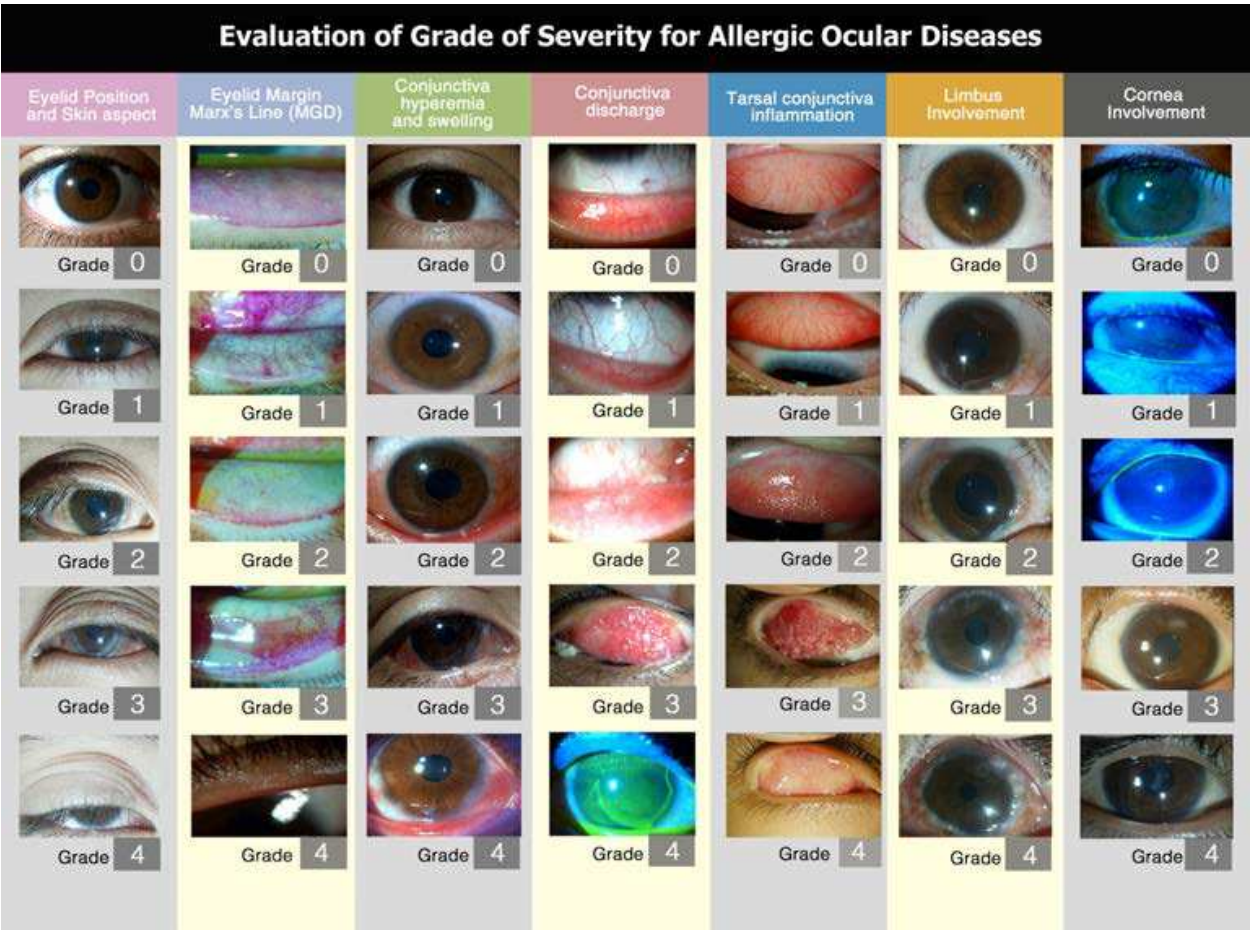


Fig. 1. Evaluation of Grade of Signs Severity for Allergic Ocular Diseases.

3.3 Acute forms of allergic conjunctivitis

3.3.1 Seasonal allergic conjunctivitis and perennial allergic conjunctivitis

Mild forms of SAC and PAC are entities which often go undiagnosed, as well as the ocular component of allergic rhinoconjunctivitis that can go also untreated. Both are acute forms of presentation and are mainly non-sight threatening conditions. Symptoms associated with SAC condition, such as ocular itching and redness, are often accompanied with tearing and nasal congestion (Wormald et al., 2004). Both, SAC and PAC patients, can also manifest symptoms of irritation, burning and foreign body sensation that might be related to increased tear film lipid layer thickness or even alterations of the lipid secretions, causing tear instability with diminished break up time (Suzuki et al., 2006). Eosinophilic activation and concomitant release of inflammatory mediators, which are thought to be detrimental to conjunctival epithelia and goblet cells, are considered the cause of tear film instability (Lobefalo et al., 1999). It has been suggested that PAC patients are sensitized to house dust mite, animal dander and moulds, which are present all year round (Dart et al., 1986). However, we have observed that in our patients (Mexican mestizo population) both, SAC and PAC patients, are sensitized to house dust mite. The clinical characteristics of SAC and PAC patients can be seen on figure 1 and table 2 and correspond mainly to grade 1 and 2.

3.4 Chronic forms of conjunctivitis

3.4.1 Vernal keratoconjunctivitis

VKC is a chronic ocular surface inflammatory condition most commonly observed in young males before puberty living in dry, warm climates. VKC is bilateral and characterized by seasonal or perennial symptoms that exacerbate with recurrences in 60% during spring, early autumn and winter. Prolonged inflammation, more than 3 years, leads to a greater chance of developing perennial symptoms. During exacerbations, intense itching is the predominant feature, followed by photophobia, tearing, and sticky mucus discharge (Bonini et al., 2000). VKC has a wide range of conditions and all of them are not necessarily present at the time of visit, and could be a manifestation of disease evolution. The disease may primarily involve the tarsal or limbal conjunctiva leading to different forms of VKC: tarsal, limbal or mixed forms. In tarsal VKC, there is important hyperemic conjunctiva, chemosis and hypertrophic papillae 0.5-0.75 mm size with a cobblestone appearance representing the hallmark of disease. Typical Maxwell-Lyons sign is recognized for thick strands of mucus over papillae. In limbal VKC gelatinous yellow-gray infiltrates are observed on the limbus, the circumference of which might appear thickened and opaque, with a peripheral and superficial neovascularization. Horner-Trantas dots are white, calcareous-like cellular infiltrates with eosinophil reaction occurring on the edge of limbal conjunctiva and also on top of nodules. Cornea involvement consider superficial punctate keratopathy, corneal erosions, indolent superficial ulcer (shield ulcers) which develops with opaque edges and plaque formation through deposition of mucus and cells, mainly located at the superior quadrants. VKC is also associated with keratoconus, which in fact should be a mandatory condition to search, because there are a 6% of patients that might end up with permanent reduction in visual acuity as a result of the cornea compromise. The higher incidence of compromise due to persistent disease at the ocular surface occurs with chronic limbal inflammation leading to gradual loss of stem cell function as a result of insufficient stromal support, ending up with limbal stem cell deficiency, and conjunctival fibrosis (Sangwan et al., 2005). Fibrosis could be associated with high immunostaining of positive mast cells to TGF, bFGF, and PDGF (Leonardi et al., 2000). Characteristic signs of VKC patients correspond to grade 2 and mainly 3. (Figure 1 and Table 2)

3.4.2 Atopic keratoconjunctivitis

AKC is a chronic ocular surface inflammatory response in men aged 30 to 50 years (Leonardi et al., 2007), however we have identified onset as earlier as in the first decade of life (Mexican mestizo population). It might be depending on severity a sight-threatening condition. The primary symptom of AKC is intense bilateral itching of the lid skin, periorbital area, and conjunctiva. Ocular symptoms also include photophobia, burning and foreign body sensation. Atopic blepharitis is evident, with tylosis and swollen eyelids that have a rugosity aspect with indurated appearance and associated with meibomian gland disease and concomitant dry eye (Onguchi et al., 2006). Infraorbital skin of the eyelid is frequently affected by single or double infraorbital creases known as Dennie-Morgan lines, which are caused by edema or thickening of the skin. Absence of the lateral eyebrow (Hertoghe sign) is present in many older patients and may be due to extensive chronic eye rubbing (Rich & Hanifin, 1985) and in the most severe cases conjunctival scarring with subepithelial fibrosis, fornix foreshortening, symblepharon, corneal ulceration and neovascularization may occur. Manifestations involving other tissues in the context of atopic dermatitis (episcleritis, scleritis, uveitis, keratoconus, cataract, and retinal detachment) must

be considered. AKC is related with an increased risk of secondary infections, including bacterial, herpetic keratitis and *Chlamydia trachomatis* infections (Forte et al., 2009). There is discrepancy of evolution among AKC, the main reason for this is the overlapping of clinical pictures due to possible shift from VKC to AKC in those VKC patients that allergy did not disappear during puberty or adulthood as typical VKC does. These patients usually have at the beginning signs of AKC when they transform into adults, but most probably conserve giant papillary reaction at the upper tarsal conjunctivas. Characteristic signs of AKC patients correspond to grade 3 and mainly 4. (Figure 1 and Table 2)

3.5 Subtypes of allergic conjunctivitis

3.5.1 Giant papillary conjunctivitis (GPC)

It is not a true ocular allergic reaction, as is the case with SAC, PAC, VKC, and AKC. It is a mild ocular allergy caused by repeated mechanical irritation (contact lens wearers, ocular prosthesis, exposed sutures) and is aggravated by concomitant allergy, with an increase of symptoms during spring pollen season. (Leonardi et al., 2007) It is present during the 2nd to 5th decade of life. Symptoms of blurred vision, foreign body sensation, itching and tearing are present. Signs of mucus production with abnormal thickening of conjunctiva and visible white appearance on papillae with white or clear exudates, thick and stringy on awakening become a particular picture, in a chronic manner. Upper tarsal papillary hypertrophy has been described in 5% to 10% of soft and 3% to 4% of hard contact lens wearers. GPC is associated with the infiltration of basophils, eosinophils, plasma cells, and lymphocytes, which suggest a mixed mast cell- and lymphocyte-mediated process. (Chang & Chang, 2001)

3.5.2 Contact blepharitis or dermatconjunctivitis

This type of reaction implies the eyelid skin and surrounding orbital limits. It is related to contact T- cell-mediated delayed hypersensitivity reaction to haptens-carrier complex such as cosmetics, metals, and chemicals as well as topical preparations with drugs or preservatives involved. Symptoms of eyelid itching, eczema, conjunctival redness and punctate keratitis might be seen. There is a participation of Langerhans cells of the eyelid skin or conjunctiva and presented to T-helper lymphocytes in the regional lymph nodes , which in turn sensitized cells react with cytokines resulting in recruitment and activation of inflammatory cells and resident cells. (Leonardi et al., 2007)

3.6 Other clinical allergic conditions and its impact in allergic ocular diseases

3.6.1 Ear nose and throat (ENT) co-morbidities

It is well known that allergic rhinitis could be present during allergic conjunctivitis. Specific nasal symptoms includes nasal congestion, nasal discharge or rhinorrhea, sneezing, hyposmia, breathing alterations, nasal voice, nose bleeding, and in some cases turbinate hypertrophy, and polypoid degenerations (De Groot et al., 2007). Mucosal edema of the upper airways induces changes in the nasal physiological equilibrium (Al-Rawi et al., 1998). Causes related to exacerbation of mucosal reactivity comprise intrinsic and extrinsic factors. Intrinsic factors include allergies, metabolic disorders, and anatomical alterations; while extrinsic factors encompass relative humidity, temperature, pollution, barometric pressure, among others. All of these alterations induce an inflammatory process that could be self limited or persistent, leading to more inflammatory responses (Nacleiro et al., 2010). Mucosal inflammation also stimulates mucin hypersecretion (Yuta et al., 1997), and if inflammatory process continues, drainage system fails and retrograde complications develops, such as paranasal sinus

dysfunction, nasolacrimal duct occlusion and middle ear alterations. Paranasal sinus dysfunction generates stasis of nasal secretions, edema and sinus infection (Ryan & Brooks, 2010). Severe ocular complications due to sinus infection include periorbital cellulitis, and cavernous sinus thrombosis (Moubayed et al., 2011). Nasolacrimal duct occlusion is related with persistent epiphora and ocular infections. (Annamalai et al., 2003) Middle ear alterations include inflammation of Eustachian tube, generating low pressure in the middle ear. Changes in middle ear pressure develops in “glue ear” (middle ear fluid with increased viscosity), decreased audition, and in some cases mechanical vertigo (Pelikan, 2009).

Complications mentioned above can be prevented if the treatment of the rhinitis is just on time. Diagnostic management requires analysis of symptoms, physical examination, searching for eosinophilia in nasal secretions, and total IgE determination. Computerized tomography scan is a mandatory to study paranasal sinus complications (Lee et al., 2008). Treatment depends of each patient and if complications are present or not. The core of treatment must be directed to restructure the physiological nasal function. In this context, we have observed that treatment of AOD gets very favorable results in nasal symptoms; similarly, control of allergic rhinitis induces a better ocular outcome.

3.6.2 Skin co-morbidities

Patients with allergic ocular disease may have, among other systemic allergic co-morbidities, immune-mediated skin disorders. While AKC has been commonly associated with atopic dermatitis (AD), other types of AC may also be associated with conditions such as contact dermatitis (CD), urticaria and angioedema (Calonge, 2000). Early onset of AD is commonly regarded as the first manifestation of the so-called “atopic march”, where asthma and allergic rhinoconjunctivitis arise eventually in patients previously suffering from AD (Spergel & Paller, 2003) (Figure 2). Conjunctival and corneal involvements among patients with AD are common signs in AKC. It has been speculated that AD with ocular involvement could be the most severe end of the spectrum of this chronic relapsing cutaneous disease characterized by erythematous pruritic vesicles that may evolve into chronic lichenified lesions (Spergel & Paller, 2003). AD and AKC may not run parallel courses; in some cases the only manifestations of AD may be limited to the eyelids with eczema and keratinization, as well as chronic blepharitis (Tuft et al., 1991). Interestingly, it has been demonstrated that AD patients have a marked deficiency of IgA in sweat and tear samples, which could account, at least in part, for the increased susceptibility to *Staphylococcus aureus* and Herpes simplex virus infections in the skin and ocular surface (Guglielmettia et al., 2010). Patients with AD may also have a higher tendency to present CD, and so do patients with allergic ocular disease (Calonge, 2000). CD may respond to allergic or irritant mechanisms that cause the development of scaly eczematous lesions. In patients with dermatconjunctivitis, these lesions may be limited to the periorbital skin and be secondary to the application of cosmetics or topical ophthalmologic medications; lesions usually self resolve after discontinuing the offending agent. In patients with AC, acute urticarial lesions characterized by migrating edematous, pruritic plaques with serpiginous borders may develop. Likewise, patients may also develop angioedema, presenting with well-demarcated, non-pruritic areas of deeper cutaneous edema in the eyelids or perioral zone. When mediated by IgE, both urticaria and angioedema, are frequently encountered in atopic individuals, and therefore in patients with AOD.

CD, urticaria and angioedema tend to be self limited in patients with AC, patients with AKC usually have relapsing chronic courses of AD. Hence, these patients could possibly benefit from therapies capable of simultaneously targeting the ocular and cutaneous aspects of their

disease. One such approach could be the use of topical tacrolimus applied to the eyelids and subsequently spread over the conjunctiva in patients with skin involvement limited to the periorbital zone (Zribi et al., 2009). Other promising therapeutic possibilities could include the use of systemic immunosuppressive agents, such as cyclosporine, azathioprine and mycophenolate mofetil (Guglielmettia et al., 2010). Finally, immunobiological therapies such as infliximab (anti TNF- α), alefacept (T-cell inhibition) or rituximab (anti CD20) have proven to be effective in patients with AD, and could be of benefit in patients with AKC (Guglielmettia et al., 2010).

Actinic Conjunctivitis. It has been described in the dermatologic literature as part of a condition termed Actinic Prurigo. Is thought to be a photosensitive reaction to ultraviolet light in susceptible individuals; rather than primarily an allergic response. Begins in childhood and involves mainly the skin, oral mucosa and the conjunctiva. It has been described in Indian or Mestizo heritage located in Mexico or the Andean Regions of South America and in the American Indian population in the southwestern of United States. Typical characteristics consist of localized redness on the temporal side of bulbar conjunctiva advanced lesions becoming thicker and more congested with pigmentary changes, until invasion of limbus causing a linear leukoma. (Figure 2) Actinic conjunctivitis

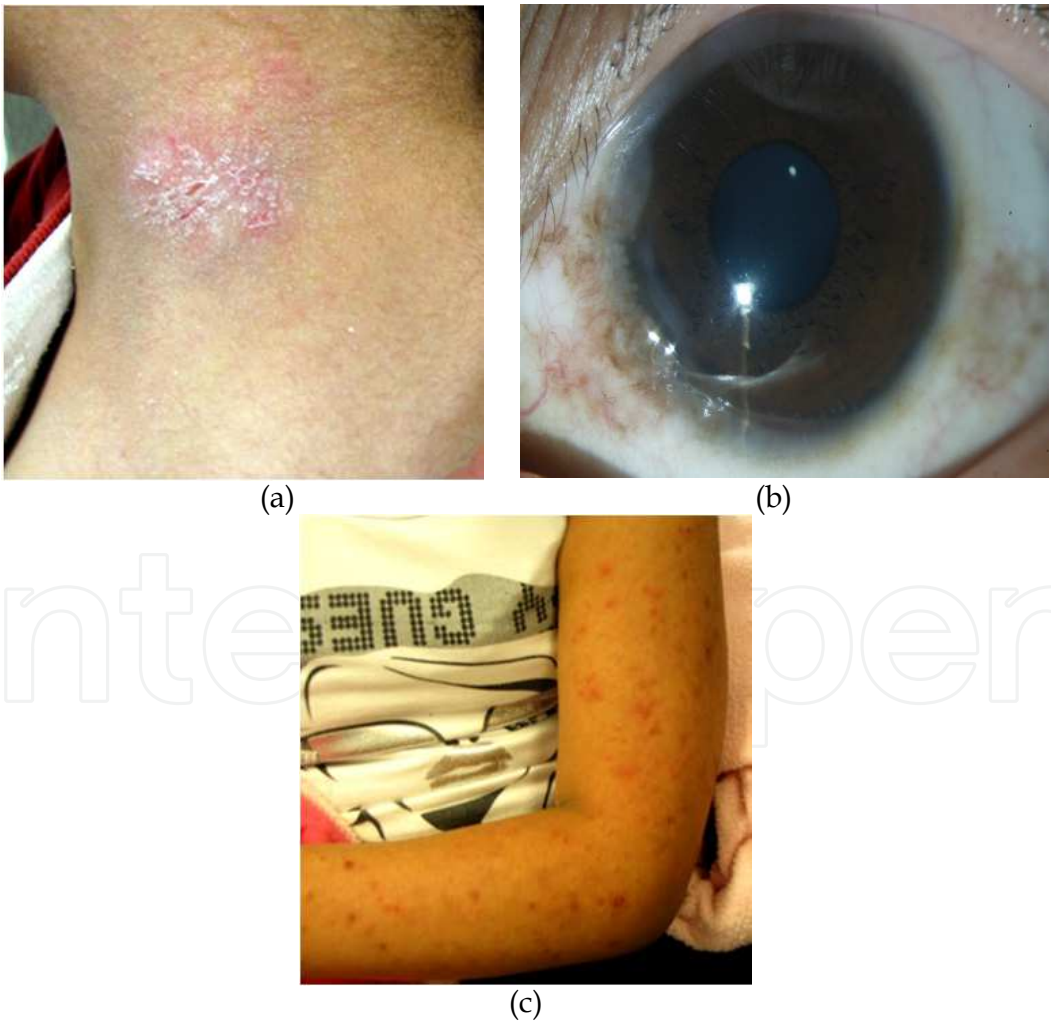


Fig. 2. Skin co-morbidities in patients with AC. Clinical pictures of Atopic Dermatitis in neck (a); Actinic Conjunctivitis (b); and Actinic Prurigo in forearm (c)

has infiltration of epithelium by inflammatory cells and stromal changes with plasmacytic infiltrate, vascular congestion and varying numbers of eosinophils as the source of the lesion. Children with actinic conjunctivitis frequently complain of a burning itchy sensation and relief is gained with the use of steroids. Actinic conjunctivitis, in its earliest stages, is frequently misdiagnosed as vernal conjunctivitis but without papillary reaction (Engel et al., 2009). Despite that actinic conjunctivitis could be considered as a differential diagnosis, authors have observed that in some cases could coexist with AOD.

4. *In vivo* diagnostic and research procedures

Provocation tests are used to know the immediate or delay immune response against several allergens; these tests have high specificity and positive predictive value, and are the most important *in vivo* diagnostic and research procedures, some of these allergy examinations include:

Conjunctival provocation test (CPT)

CPT is used to determine the extent of conjunctival reaction to allergens. A drop of antigen to evaluate is applied to one eye, whereas a drop of balanced salt solution (BSS) is applied to the other eye as a control. Eyes must be examined using slit-lamp at different times. To control and degrade allergic eye reaction, a drop of topical antihistamine is applied at the end of CPT. CPT could be used as a model of ocular allergy to study ocular response to allergenic stimuli, and to evaluate antiallergic therapy. Considerable useful information has been gained on the ocular allergic response and drug efficacy using the CPT and naturally occurring seasonal allergic conjunctivitis. (Mortemousque, 2007; Kasetsuwan et al., 2010).

Nasal provocation test (NPT)

NPT is used to determine nasal and/or conjunctival reaction to allergens. NPT has been used primarily as a research tool for the investigation of allergic and nonallergic rhinitis with a wide variety of techniques depending on the specific scientific purposes. NPT could be a valuable supplementary diagnostic parameter for late nasal response (Pelikan & Pelikan-Filipek, 1989; Litvyakova & Baraniuk, 2001)

Epicutaneous skin test (EST)

EST or Skin Prick Test (SPT) provides a pivotal role in the allergy evaluation, is used to aid establishment of allergic symptoms and specific allergic triggers, and help to evaluate the degree of sensitivity to a specific agent. Many devices are available to perform testing. These devices attempt to allow the performer to achieve reproducible and accurate skin test results when standardized extracts are employed. It has been suggested high correlations between positive results to properly performed epicutaneous skin tests and the results of eye, nose, or lung challenges with the homologous allergen. The results of EST are also highly correlated with the results of *in vitro* tests and clinical histories. These correlations between the tests and challenges are highest when potent, well-characterized allergen extracts are used. For most common allergens, the results of Intracutaneous skin test (IST) add little if anything to correlations between skin test results and the results of challenges or to predicting clinical histories. The extra sensitivity of IST valuable when high potency of extracts are not available or when the test risk of a falsely negative test is high, as with drug or insect venom allergies. All physicians caring for patients with histories suggestive of

allergic disorders must be keenly aware of the strengths and limitations of all available methods. (Ownby, 2001)

Atopy patch test (APT)

This test is able to identify triggering factors and consist of the epicutaneous application of allergens for 48 hours, with an evaluation of eczematous lesions induced after 48 and 72 hours, according to the reading criteria of the European Task Force on Atopic Dermatitis (ETFAD). APT show a higher specificity in atopic dermatitis than skin prick and specific IgE tests, since the pathophysiological mechanism of the reaction induced is very similar to that which occurs in AD lesions. (Nosbaum et al., 2010) Thus, optimization of APTs and progress in the knowledge of the pathophysiology of eczemas associated to ocular diseases could help to develop new immunobiological diagnostic methods and specific immunotherapy that could be used in AOD with skin involvement.

5. Conventional therapeutic intervention and new immunological treatments

Despite that AC is frequent, often is misdiagnosed and not adequately treated. Patients with these conditions may present to a variety of professionals-pharmacists, general practitioners, allergists/immunologists, otolaryngologist, and dermatologists; unfortunately, there is a lack of consensus in the multidisciplinary assessment for better treatment selection.

Treatments for allergic conjunctivitis have been continuously evolving since the early nineties, and several levels of therapeutic intervention have been described. Primary intervention is related to avoid offending antigens without pharmacological measures; secondary intervention is directed to control local effector functions of mast cells/eosinophils/basophils with H1- and H2-receptor antagonists, Disodium cromoglycate, Nedocromil sodium, anti-inflammatory drugs (non-steroids or steroids) (Bielory et al., 2005) and in severe cases, tertiary intervention with immune suppressor therapy, such as ciclosporin or tacrolimus has been used (Daniell et al., 2006; Vichyanond et al., 2004).

5.1 Other therapies

Autologous Serum (AS) has been used to treat dry eye syndrome for many years. It contains several growth factors, vitamins, fibronectin, albumin, lysozyme and other components that have been considered important for corneal and conjunctival integrity (Kojima et al., 2008). To date few studies about AS use in AOD have been reported, improvement of signs and symptoms is not a constant in all patients (Goto et al., 2001; Gaytán-Melicoff et al., 2005). It would be interesting to replicate these studies isolating total or specific IgE from serum before application of autologous serum eye drops in ocular surface, because is a possibility that absence of improvement could be related with activation of local and migrating cells by FcεR, due to AS could contain high IgE concentrations in atopic patients.

5.2 Immune-based therapeutic approaches

All therapeutic interventions mentioned above are focused on topical agents in an effort to control “the effector side of the coin”, than “the sensitization side of the coin”. Research in immune-based therapeutic approaches is needed to perform deeply immunological changes that induce a better clinical outcome in AC patients; some of these therapeutic approaches are specific desensitization/immunotherapy and dialyzable leukocyte extracts. It is very important to clarify that both of these innovative therapies are still in

evaluation, and until now there are not enough scientific information to ensure its efficacy in the treatment of AOD.

5.3 Specific immunotherapy

First described by Noon and Freeman in 1911, immunotherapy is thought to be the most specific treatment for allergic diseases, particularly asthma and allergic rhinitis. It is defined as the administration of low and calculated doses of the biological extract allergen or allergens implicated specifically in the disease of each patient (that is determined by the SPT), increasing gradually until get the highest dose clinically adequate. These vaccines comprise a complex mixture of proteins and glycoproteins that require dedicated standardization procedures to ensure batch-to-batch consistency. The whole desensitization process takes about 3 to 5 years, but the improvement should be reported during the first 3 to 6 months of treatment. There have been reported many ways for its administration, but nowadays only two have provided efficacy and safety: subcutaneous and sublingual (Shakir et al., 2010).

Possible mechanisms of action of subcutaneous immunotherapy, includes the down regulation of cytokines, inhibition of activation and recruitment of effector cells, and modulation of Th1 and Th2 balance, with IFN- γ secretion. This particular aspect seems to be of major relevance and explains by itself many of the changes related to improvement of the allergic symptoms in asthma and rhinitis, and the long lasting efficacy after discontinuation (Frew, 2010). Subcutaneous immunotherapy has been reported effective in patients with SAC in which IgE-mediated hypersensitivity has been demonstrated with a convincingly diagnostic procedure. (Kari & Saari, 2010)

In the case of sublingual immunotherapy (SLIT), it has been reported that allergen is captured within the oral mucosa by Langerhans dendritic cells expressing high-affinity IgE receptors, producing IL-10 and TGF- β , and upregulating indoleamine dioxygenase (IDO), suggesting that such cells are prone to induce tolerance by T regs (Scadding et al., 2010). In humans, SLIT is capable to reduce the proliferative response of T lymphocytes and the inflammatory phenomena (cellular infiltration and adhesion molecule expression on epithelia) in nose and conjunctiva of atopic subjects, decrease methacholine responsiveness and, even it does not affect IgE levels, there are an increase of IgG1 and IgG4 (Moingeon et al., 2006). SLIT has been used in treatment of rhinoconjunctivitis, its success has been reported moderately effective in reducing total and individual ocular symptom scores (Calderon et al., 2011). Unfortunately, not convincing specific data have been presented to demonstrate if SLIT is significantly effective during treatment of AOD and more clinical studies are needed to recognize the relevance of this therapy.

5.4 Dialyzable leukocyte extracts (DLE)

DLE or Transfer Factors, were described by Lawrence in 1955, who proved that the extract obtained from a dialyzed of viable leukocytes from a healthy donor presenting a positive percutaneous tuberculin test was able to transfer to a healthy receptor the ability to respond to this test (Lawrence, 1955). DLE are constituted by a group of numerous molecules all of them with a molecular weight between 1-6 KDa. DLE have been widely used as adjuvant for treating patients with infectious diseases, and deficient cell-mediated immune response (Wilson et al., 1984; Berrón et al., 2007). Transfer factors bind to antigens in an immunologically specific manner. This reactivity probably explains the specificity of

individual transfer factors; it appears the purified materials are immunologically active and antigen-specific. (Kirckpatrick, 1993).

The most consistent effects of transfer factors on the immune system are expression of delayed-type hypersensitivity (DTH) and production of cytokines. DLE are able to induce secretion of macrophage migration inhibitory factor (Kirckpatrick, 1993), to restore the expression of $\text{TNF}\alpha$ and iNOS in a mouse model of tuberculosis, provoking inhibition of bacterial proliferation and significant increase of DTH (Fabre et al., 2004), and to induce expression of mRNA and $\text{IFN-}\gamma$ in peripheral blood mononuclear cells from animal models and during treatment of human diseases (Estrada-Parra et al., 1998; Pineda et al., 2005; Luna-Baca et al., 2007; Santacruz-Valdes et al., 2010). Immune modulation induced by DLE therapy increase $\text{IFN-}\gamma^+$ cells promoting Th1 response and restoring a Th2 balance, thus treatment with DLE has also been used in allergic diseases, such as AD (Sosa et al., 2001; Flores-Sandoval et al., 2005) and asthma (Valdés-Sánchez et al., 1993), in both diseases with promissory results, particularly in moderate persistent allergic asthma, helping to reduce the use of inhaled glucocorticoids (Espinosa Padilla et al., 2009). AOD treatment with DLE has not been enough studied yet; nonetheless, preliminary reports suggest that DLE improves clinical outcome in patients with negative skin reactivity to allergens, suggesting that DLE therapy could be used as therapeutic tool in such patients. (Jiménez-Martínez et al., 2010). However, more research is required to better understand exact indications of DLE in all types of AOD.

6. Biomarkers research and its applications in allergic ocular diseases

Biomarkers are common molecules, such as lipids, glycans or proteins, located in tissues, cells and secretions. Changes in concentration of these molecules, indicates a biological status from “normal” to “pathological” range. Biomarkers can be used as prognostic or diagnostic tools or as a target to new therapies (Hoffmann-Sommergruber et al., 2011). In this context proteomics, immunomics and bioinformatics could aid to explore and to know antigens recognized by immune system during allergic response.

Immunome is defined as the proteome subset of an antigen, recognized by the immune receptors (TCR or BCR) and the tools that help us to study immunome are named immunomics (De Groot, 2006). Exists different ways to analyze immunome, searching in immunome epitope databases could give us newly identified epitope; however, most databases involved TCR epitopes exclusively (Sette et al., 2005). To generate a functional profile for allergic conjunctivitis patients we can select epitopes from the growing, verified database of B cell epitopes (Prechl et al., 2010) but in the case of allergies is needed to know a biomarker candidate, this is only possible if we know the frequency of allergens in our population. Once we have an exploratory biomarker (most frequent allergen recognized by patients IgE antibodies), it could be used as a potential precursor for probable useful biomarker. Protein sequencing, and other functional procedures to evaluate functional proteins (i.e. ELISA, flow cytometry, immune histology techniques), followed by analytical test system (bioinformatics) could lead to identification or prediction of protein structure. (Goodsaid & Frueh, 2006). The last step in biomarker research is related to practical validation of putative biomarkers. If the new biomarker is related to diagnostic, studies should support specificity and sensitivity of the exploratory biomarker (Wilkins et al., 2006). Finally cross-validation processes will include independent validation of new biomarker by

several researchers, and if results are reproducible, the biomarker may be considered valid (Hardouin et al., 2006). All this process is needed to know peptides recognized by IgE antibody in allergic disease. Knowledge could be used to develop diagnostic test i.e. determination of specific IgE in tears or to develop second generation immunotherapy. Recombinant DNA technology could be used to obtain highly purified allergens in their native conformation. The recombinant allergens could then formulated with *ad hoc* adjuvants and/or mucoadhesive excipients so that they specifically target oral Langerhans cells and induce allergen-specific regulatory T cells (Moingeon, 2006).

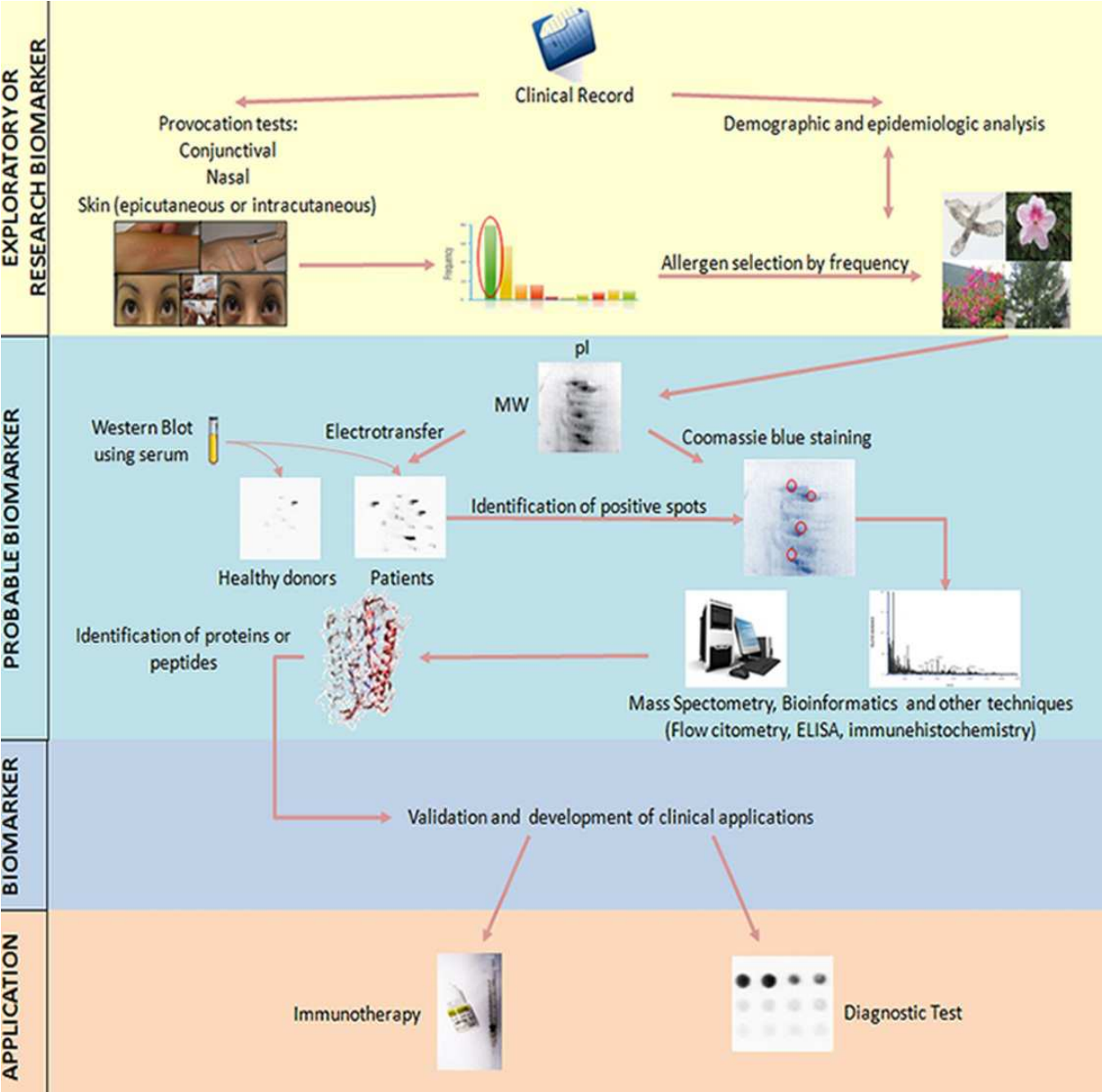


Fig. 3. Research flow in biomarkers related to allergic diseases.

7. Conclusions

Allergic ocular diseases have become a special concern for clinical and basic research. Their impact on quality of life among individuals, annually represent an important issue of investment to find better treatments, particularly to control the effects of chronic diseases which could threat vision and influence on daily life activities. Clinical diagnosis is still a challenger due to a wide range of overlapping entities which might respond differently to conventional treatments; such heterogeneity is important to be considered not only to focus on the ocular problem, but to approach the problem with an interdisciplinary medical group, including allergist/immunologist, ENT specialists, and dermatologist; all working together to improve ocular and systemic health of the allergic patient. Despite that important discoveries about immune pathophysiological mechanisms has brought light into the problem, there is not enough. Research efforts need to be also directed to the discovery of biomarkers and immune therapeutic management to control both, sensitization and effector phases of AOD. Knowledge about the molecular mechanisms involved, together with an interdisciplinary treatment group will support better results in allergic conjunctivitis patients.

8. Acknowledgments

ICYTDF PIFUT-P08124, Fundacion Conde de Valenciana, and Transfer Factor Project. Robles-Contreras A and Santacruz C must be considered as first authors indistinctly. The authors declare that they have no financial and personal relationships with other people or organizations that could inappropriately influence this work.

9. References

- Abelson, MB., Chambers, WA., Smith LM. (1990). Conjunctival Allergen Challenge A Clinical Approach to Studying Allergic Conjunctivitis. *Arch Ophthalmol.* pp.84-88.
- Abelson, MB., Smith L., & Chapin M. (2003). Ocular allergic disease: mechanisms, disease sub-types, treatment. *Ocul Surf.* pp. 127-149.
- Abu El-Asrar, AM., Fatani, RA., Missotten, L. & Geboes, K. (2001). Expression of CD23/CD21 and CD40/CD40 ligand in vernal keratoconjunctivitis. *Eye (Lond).* pp. 217-224.
- Aguilar-Velázquez, G, Santacruz-Valdés, C, Robles-Contreras, A, Ayala-Balboa, J, Bautista-de-Lucio, V, et al. (2009). Tear TNF as a Potential Link in the Pathogenesis of Allergic Conjunctivitis. Correlation between Tear IFN γ /IL-5 and Clinical Data. *Prodeedings of Allergy. Medimond. Argentina*, pp.13-17.
- Akdis, M., Verhagen, J., Taylor, A., Karamloo, F., Karagiannidis, C. et al. (2004). Immune responses in healthy and allergic individuals are characterized by a fine balance between allergen-specific T regulatory 1 and T helper 2 cells. *J Exp Med.* pp. 1567-1575.
- Allansmith, MR., Hahn, GS., & Simon, MA. (1976). Tissue, tear, and serum IgE concentrations in vernal conjunctivitis. *Am J Ophthalmol.* pp. 506-511.

- Al-Rawi, MM., Edelstein, DR. & Erlandson, RA. (1998). Changes in nasal epithelium in patients with severe chronic sinusitis: A clinicopathologic and electron microscopic study. *Laryngoscope*. pp. 1816-1823.
- Anderson, DF., MacLeod, JD., Baddeley, SM., Bacon, AS., McGill, JL., et al. (1997). Seasonal allergic conjunctivitis is accompanied by increased mast cell numbers in the absence of leucocyte infiltration. *Clin Exp Allergy*. pp. 1060-1066.
- Anderson, DF., Zhang, S., Bradding, P., McGill, JL., Holgate, ST., et al. (2001). The relative contribution of mast cell subsets to conjunctival TH2-like cytokines. *Invest Ophthalmol Vis Sci*. pp. 995-1001.
- Annamalai, S., Kumar, NA., Madkour, MB., Sivakumar, S. & Kubba, H. (2003). An association between acquired epiphora and the signs and symptoms of chronic rhinosinusitis: a prospective case-control study. *Am J Rhinol*. pp. 111-114.
- Bauer, S., Hangel, D. & Yu, P. (2007). Immunobiology of toll-like receptors in allergic disease. *Immunobiology*. pp. 521-533.
- Berrón-Pérez, R., Chávez-Sánchez, R., Estrada-García, I., Espinosa-Padilla, S., Cortez-Gómez, R. et al. (2007). Indications, usage, and dosage of the transfer factor. *Rev Alerg Mex*. pp. 134-139.
- Bielory, LJ. (2000). Allergic and immunologic disorders of the eye. Part I: immunology of the eye. *Allergy Clin Immunol*. pp. 805-816.
- Bielory, L., Lien, KW. & Bigelsen, S. (2005). Efficacy and tolerability of newer antihistamines in the treatment of allergic conjunctivitis. *Drugs*. pp. 215-228.
- Bonini, S., Bonini, S., Lambiase, A., Marchi, S., Pasqualetti, P. et al. (2000). Vernal keratoconjunctivitis revisited: a case series of 195 patients with long-term followup. *Ophthalmology*. pp. 1157-1163.
- Bonini, S., Sacchetti, M., Mantelli, F. & Cambiase, A. (2007). Clinical grading of vernal keratoconjunctivitis. *Curr Opin Allergy Clin Immunol*. pp. 436-441.
- Calderon, MA., Penagos, M., Sheikh, A., Canonica, GW. & Durham, S. (2011). Sublingual immunotherapy for treating allergic conjunctivitis. *Cochrane Database Syst Rev*. pp. CD007685.
- Calonge, M. (2000). Ocular Allergies. Association with Immune Dermatitis. *Acta Ophthalmol Scand*. pp. 69-75.
- Calonge, M. & Herreras, JM. (2007). Clinical grading of atopic keratoconjunctivitis. *Curr Opin Allergy Clin Immunol*. pp. 442-445.
- Chang SW, Chang CJ. (2001). Delayed tear clearance in contact lens associated papillary conjunctivitis. *Curr Eye Res*. pp. 253-257.
- Choi, SH. & Bielory, L. (2008). Late-phase reaction in ocular allergy. *Curr Opin Allergy Clin Immunol*. pp. 438-444.
- Cook, EB., Stahl, JL., Miller, ST., Gern, JE., Sukow, KA., et al. (1998). Isolation of human conjunctival mast cells and epithelial cells: tumor necrosis factor-alpha from mast cells affects intercellular adhesion molecule 1 expression on epithelial cells. *Invest Ophthalmol Vis Sci*. pp. 336-43.
- Daniell, M., Constantinou, M., Vu, HT. & Taylor, HR. (2006). Randomised controlled trial of topical ciclosporin A in steroid dependent allergic conjunctivitis. *Br. J Ophthalmol*. pp. 461-464.

- Dart, JK., Buckley, RJ., Monnickendan, M., & Prasad, J. (1986). Perennial allergic conjunctivitis: definition, clinical characteristics and prevalence. A comparison with seasonal allergic conjunctivitis. *Trans Ophthalmol Soc U K.* pp. 513-520.
- De Groot, AS. (2006). Immunomics: discovering new targets for vaccines and therapeutics. *Drug Discov Today.* pp. 203-209.
- De Groot, H., Brand, PL., Fokkens, WF. & Berger, MY. (2007). Allergic rhinoconjunctivitis in children. *BMJ.* pp. 985-988.
- Del Culvillo, A., Montoso, J., Bartra, J., Valero, A., Ferrer, M. et al. (2010). Validation of ARIA duration and severity classifications in Spanish allergic rhinitis patients. The ADRIAL cohort study. *Rhinology.* pp. 201-205.
- Dykewicz, MS. & Fineman, S. (1998). Executive Summary of Joint Task Force Practice Parameters on Diagnosis and Management of Rhinitis. *Ann Allergy Asthma Immunol.* pp. 463-468.
- Engel, JM., Molinari, A., Ostfeld, B., Deen, M. & Croxatto O. (2009). Actinic Conjunctivitis in children: Clinical features, relation to sun exposure, and proposed staging and treatment. *J AAPOS.* pp. 161-165.
- Espinosa Padilla, SE., Orozco, S., Plaza, A., Estrada Parra, S., Estrada Garcia, I. et al. (2009) Efecto del factor de transferencia en el tratamiento con glucocorticoides en un grupo de paciente pediátricos con asma alérgica moderada persistente. *Rev Aler Mex* pp. 67-71.
- Estrada-Parra, S., Nagaya, A., Serrano, E., Rodriguez, O., Santamaria, V. et al. (1998). Comparative study of transfer factor and acyclovir in the treatment of herpes zoster. *Int J Immunopharmacol.* pp. 521-535.
- Fabre, RA., Pérez, TM., Aguilar, LD., Rangel, MJ., Estrada-García, I., et al. (2004) Transfer factors as immunotherapy and supplement of chemotherapy in experimental pulmonary tuberculosis. *Clin Exp Immunol.* pp. 215-23.
- Flores-Sandoval, G., Gómez-Vera, J., Orea-Solano, M., López-Tiro, J., Serrano, E. et al. (2005). Transfer factor as specific immunomodulator in the treatment of moderate-severe atopic dermatitis. *Rev Alerg Mex.* pp. 215-20.
- Forte, R., Cennamo, G., Del Prete, S., Napolitano, N., Farese, E. et al. (2009). Allergic conjunctivitis and latent infections. *Cornea.* pp. 839-842.
- Foster, CS. & Calonge, M. (1990). Atopic Keratoconjunctivitis. *Ophthalmology.* pp. 992-1000.
- Frew, AJ. (2010). Allergen immunotherapy. *J Allergy Clin Immunol.* pp. S306-313.
- Fukagawa, K., Okada, N., Fujishima, H., Nakajima, T., Tsubota, K., Takano, Y. et al. (2002). CC-chemokine receptor 3: a possible target in treatment of allergy-related corneal ulcer. *Invest Ophthalmol Vis Sci.* pp. 58-62.
- Fukushima, A., Ozaki, A., Jian, Z., Ishida, W., Fukata, K., et al. (2005). Dissection of antigen-specific humoral and cellular immune responses for the development of experimental immune-mediated blepharoconjunctivitis in C57BL/6 mice. *Curr Eye Res.* pp. 241-248.
- Fukushima, F., Sumi, T. & Fukuda, K. (2006). Analysis of the interaction between IFN γ and IFN γ R in the effector phase of experimental murine allergic conjunctivitis. *Immunol Lett.* pp.119-124

- Fukushima, A., Sumi, T., Ishida, W., Ojima, A., Kajisako, M., et al. (2008). Depletion of thymus-derived CD4+CD25+ T cells abrogates the suppressive effects of alpha-galactosylceramide treatment on experimental allergic conjunctivitis. *Allergol Int.* pp. 241-246.
- Gaytán-Melicoff, JA., Baca-Lozada, O., Velasco-Ramos, R. & Viggiano-Austria, D. (2005). Comparación entre suero autólogo, clorhidrato de olopatadina y fumarato de ketotifeno, en el manejo de la conjunctivitis alérgica. *Rev Mex Oftalmol.* pp. 25-31.
- Goodsaid, F. & Frueh, F. (2006). Process map proposal for the validation of genomic biomarkers. *Pharmacogenomics.* pp. 773-782.
- Goto, E., Shimmura, S., Shimazaki, J. & Tsubota, K. (2001) Treatment of superior limbic keratoconjunctivitis by application of autologous serum. *Cornea.* pp. 807-810.
- Guglielmettia, S., Dart, JKG. & Calderd, V. (2010). Atopic keratoconjunctivitis and atopic dermatitis. *Current Opinion in Allergy and Clinical Immunology.* pp. 478-485.
- Hardouin, J., Duchateau, M., Joubert-Caron, R. & Caron, M. (2006). Usefulness of an integrated microfluidic device (HPLC-Chip-MS) to enhance confidence in protein identification by proteomics. *Rapid Commun Mass Spectrom.* pp. 3236-3244.
- Heath, H., Qin, S., Rao, P., Wu, L., LaRosa, G., et al. (1997). Chemokine receptor usage by human eosinophils. The importance of CCR3 demonstrated using an antagonistic monoclonal antibody. *J Clin Invest.* pp. 178-84.
- Hoffmann-Sommergruber, K., Paschinger, K. & Wilson, IB. (2011). Glycomarkers in parasitic infections and allergy. *Biochem Soc Trans.* pp. 360-364.
- Ishida, W., Fukuda, K., Kajisako, M., Takahashi, A., Sumi, T., et al. (2010). Conjunctival macrophages act as antigen-presenting cells in the conjunctiva during the development of experimental allergic conjunctivitis. *Mol Vis.* pp. 1280-1285.
- Jimenez-Martinez, MC., Aguilar, G., Santacruz, C., Robles-Contreras, A., Ayala, J. et al. (2010). Sublingual Desensitization or Immune Modulation with Dialyzable Leukocyte Extracts Improves the Clinical Outcome in Allergic Conjunctivitis. *Clin Immunol. FOCIS 2010.* Boston, USA. pp. S103.
- Johansson, SG., Bieber, T., Dahl, R., Friedmann, PS., Lanier, BQ., et al. (2004). Revised nomenclature for allergy for global use: Report of the Nomenclature Review Committee of the World Allergy Organization, October, 2003. *J Allergy Clin Immunol.* pp. 832-6.
- Kari, O & Saari KM. (2010) Updates in the treatment of ocular allergies. *J Asthma Allergy.* pp.149-158.
- Kasetsuwan, N., Chatchatee, P., & Reinprayoon, U. (2010) Efficacy of local conjunctival immunotherapy in allergic conjunctivitis. *Asian Pac J Allergy Immunol.* pp. 237-241
- Kirkpatrick, CH. (1993) Structural nature and functions of transfer factors. *Ann N Y Acad Sci.* pp. 362-368.
- Kojima, T., Higuchi, A., Goto, E., Masumoto, Y., Dogru, M. et al. (2008). Autologous serum eye drops for the treatment of dry eye diseases. *Cornea.* pp.S25-S30.

- Lawrence, HS. (1955). The transfer in humans of delayed skin sensitivity to streptococcal M substance and to tuberculin with disrupted leucocytes. *J Clin Invest.* pp. 219-230.
- Lee, CH., Jang, JH., Lee, HJ., Kim, IT., Chu, MJ. et al. (2008). Clinical characteristics of allergic rhinitis according to allergic rhinitis and its impact on asthma guidelines. *Clin Exp Otorhinolaryngol.* pp. 196-200.
- Leonardi, A., Brun, P., Tavolato, M., Abatangelo, G., Plebani, M. et al. (2000). Growth factors and collagen distribution in vernal keratoconjunctivitis. *Invest Ophthalmol Vis Sci.* 4175-4181.
- Leonardi, A., Curnow, SJ., Zhan, H. & Calder, VL. (2006). Multiple cytokines in human tear specimens in seasonal and chronic allergic eye disease and in conjunctival fibroblast cultures. *Clin Exp Allergy.* pp. 777-784.
- Leonardi, A., Fregona, IA. & Plebani, M. (2006). Th1- and Th2-type cytokines in chronic ocular allergy. *Graefes Arch Clin Exp Ophthalmol* pp. 1240-1245.
- Leonardi, A., De Dominicis, C. & Motterle, L. (2007). Immunopathogenesis of ocular allergy: a schematic approach to different clinical entities. *Curr Opin Allergy Clin Immunol.* pp. 429-435.
- Lewkowich, IP., Herman, NS., Schleifer, KW., Dance, MP., Chen, BL., et al. (2005). CD4+CD25+ T cells protect against experimentally induced asthma and alter pulmonary dendritic cell phenotype and function. *J Exp Med.* pp. 1549-1561.
- Litvyakova, LI. & Baraniuk, JN. (2001). Nasal provocation testing: a review. *Ann Allergy Asthma Immunol.* pp :355-364
- Lobefalo, L., D'Antonio, E., Colangelo, L., Della Loggia, G., Di Gioacchino, M. et al. (1999). Dry eye in allergic conjunctivitis: role of inflammatory infiltrate. *Int J Immunopathol Pharmacol.* pp. 133-137.
- Luna-Baca, GA., Linares, M., Santacruz-Valdes, C., Aguilar-Velazquez, G., Chavez, R. et al. (2007). Immunological study of patients with herpetic stromal keratitis treated with Dialyzable Leukocyte Extracts. *Proceedings Immunology.* pp. 67-71.
- Matsuda, A., Okayama, Y., Ebihara, N., Yokoi, N., Hamuro, J., et al. (2009) Hyperexpression of the high-affinity IgE receptor-beta chain in chronic allergic keratoconjunctivitis. *Invest Ophthalmol Vis Sci.* pp. 2871-2877.
- Matsuba-Kitamura, S., Yoshimoto, T., Yasuda, K., Futatsugi-Yumikura, S., Taki, Y., et al. (2010). Contribution of IL-33 to induction and augmentation of experimental allergic conjunctivitis. *Int Immunol.* pp. 479-489.
- Moingeon, P. (2006). Sublingual immunotherapy: from biological extracts to recombinant allergens. *Allergy.* pp.15-19.
- Moingeon, P., Batard, T., Fadel, R., Frati, F., Sieber, J. et al. (2006). Immune mechanisms of allergen-specific sublingual immunotherapy. *Allergy.* pp. 151-165.
- Morgan, SJ., Williams, JH., Walls, AF., Holgate, ST. (1991) Mast cell hyperplasia in atopic keratoconjunctivitis. An immunohistochemical study. *Eye (Lond)* pp. 729-735.
- Mortemousque, B. (2007). Les tests de provocation conjuntivaux. *J Fr Ophtalmol* pp. 300-305.
- Moubayed, SP., Vu, TT., Quach, C. & Daniel, SJ. (2011). Periorbital cellulitis in the pediatric population: clinical features and management of 117 cases. *J Otolaryngol Head Neck Surg.* pp. 266-270.


- Naclerio, RM., Bachert, C., Baraniuk, JN. (2010). Pathophysiology of nasal congestion. *Int J Gen Med.* pp. 47-57.
- Nosbaum, A., Hennino, A., Berard, F. & Nicolas, JF. (2010). Patch testing in atopic dermatitis patients. *Eur J Dermatol* pp. 563-566.
- Onguchi, T., Dogru, M., Okada, N., Kato, NA., Tanaka, M. et al. (2006). The impact of the onset time of atopic keratoconjunctivitis on the tear function and ocular surface findings. *Am J Ophthalmol.* pp. 569-571.
- Ono, SJ. & Abelson, MB. (2005). Allergic conjunctivitis: update on pathophysiology and prospects for future treatment. *J Allergy Clin Immunol.* pp. 118-122.
- Ownby, DR. (2001). Skin tests in comparison with other diagnostic methods. *Immunol Aller Clin North Am* pp. 355-367.
- Pelikan, Z & Pelikan-Filipek M. (1989). Cytologic changes in the nasal secretions during the late nasal response. *J Allergy Clin Immunol.* pp. 1068-1079.
- Pelikan, Z. (2009). Audiometric changes in chronic secretory otitis media due to nasal allergy. *Otol Neurotol.* pp. 868-875.
- Pelikan, Z. (2009). The possible involvement of nasal allergy in allergic kertoconjunctivitis. *Eye.* pp.1653-1660.
- Pelikan, Z. (2010). Allergic conjunctivitis and nasal allergy. *Curr Allergy Asthma Rep.* pp.295-302.
- Pelikan Z. (2011) Delayed asthmatic response: a new phenotype of bronchial response to allergen challenge and soluble adhesion molecules in the serum. *Ann Allergy Asthma Immunol.* pp. 119-130
- Pineda, B., Estrada-Parra, S., Pedraza-Medina, B., Rodriguez-Ropon, A., Pérez, R. et al. (2005). Interstitial transfer factor as adjuvant immunotherapy for experimental glioma. *J Exp Clin Cancer Res.* pp. 575-583.
- Prechl, J., Papp, K. & Erdei, A. (2010). Antigen microarrays: descriptive chemistry or functional immunomics? *Trends Immunol.* pp. 133-137.
- Reyes, NJ., Mayhew, E., Chen, PW., Niederkorn, JY. (2011) $\gamma\delta$ T cells are required for maximal expression of allergic conjunctivitis. *Invest Ophthalmol Vis Sci.* pp. 2211-2216.
- Rich, LF. & Hanifin, JM. (1985). Ocular complications of atopic dermatitis and other eczemas. *Int Ophthalmol Clin.* pp. 61-76.
- Ryan, MW. & Brooks, EG. (2010). Rhinosinusitis and comorbidities. *Curr Allergy Asthma Rep.* pp. 188-193.
- Sangwan, VS., Murthy, SI., Vemuganti, GK., Bansal, AK., Gangopadhyay, N. et al. (2005). Cultivated corneal epithelial transplantation for severe ocular surface disease in vernal keratoconjunctivitis. *Cornea.* pp. 426-430.
- Santacruz-Valdes, C., Aguilar, G., Perez-Tapia, M., Estrada-Parra, S., Jimenez-Martinez, MC. (2010). Dialyzable Leukocyte extracts (Transfer factor) as adjuvant therapy for fungal keratitis. *Am J Case Rep* 2010 pp. 97-101.
- Scadding, GW., Shamji, MH., Jacobson, MR., Lee, DI., Wilson, D. et al. (2010). Sublingual grass pollen immunotherapy is associated with increases in sublingual Foxp3-expressing cells and elevated allergen-specific immunoglobulin G4, immunoglobulin A and

- serum inhibitory activity for immunoglobulin E-facilitated allergen binding to B cells. *Clin Exp Allergy*. pp. 598-606.
- Sette, A., Fleri, W., Peters, B., Sathiamurthy, M., Bui, HH. et al. (2005). A roadmap for the immunomics of category A-C pathogens. *Immunity*. pp. 155-61.
- Shakir, EM., Cheung, DS. & Grayson, MH. (2010). Mechanisms of immunotherapy: a historical perspective. *Ann Allergy Asthma Immunol*. pp. 340-347.
- Sosa, M., Flores, G., Estrada, S., Orea, M. & Gómez-Vera, J. (2001). Comparative treatment between thalidomide and transfer factor in severe atopic dermatitis. *Rev Alerg Mex*. pp. 56-64.
- Spergel, JM. & Paller, AS. (2003). Atopic dermatitis and the atopic march. *J Allergy Clin Immunol*. pp. S118-27.
- Stern, ME., Siemasko, K. & Gao, J. (2005). Role of Interferon-gamma in a mouse model of allergic conjunctivitis. *Invest Ophthalmol Vis Sci* pp. 3239-3246
- Suzuki, S., Goto, E., Dogru, M., Asano-Kato, N., Matsumoto, Y., et al. (2006). Tear film lipid layer alterations in allergic conjunctivitis. *Cornea*. pp. 277-280.
- Takhar, P., Smurthwaite, L., Coker, HA., Fear, DJ., Banfield, GK. et al. (2005). Allergen drives class switching to IgE in the nasal mucosa in allergic rhinitis. *J Immunol*. pp. 5024-5032.
- Takhar, P., Corrigan, CJ., Smurthwaite, L., O'Connor, BJ., Durham, SR., et al. (2007). Class switch recombination to IgE in the bronchial mucosa of atopic and nonatopic patients with asthma. *J Allergy Clin Immunol*. pp. 213-218.
- Tanaka, M., Dogru, M., Takano, Y., Miyake-Kashima, M., Asano-Kato, N. et al. (2004). The relation of conjunctival and cornea findings in severe ocular allergies. *Cornea*. pp. 464-467.
- Tuft, SJ., Kemeny, DM., Dart, JK. & Buckley, RJ. (1991). Clinical features of atopic keratoconjunctivitis. *Ophthalmology* pp. 150-158.
- Uchio, E., Kimura, R., Migita, H., Kozawa, M. & Kadonosono, K. (2008) Demographic aspects of allergic ocular diseases and evaluation of new criteria for clinical assessment of ocular allergy. *Graefes Arch Clin Exp Ophthalmol*. pp. 291-296
- Valdés-Sánchez, AF., Martín-Rodríguez, OL. & Lastra-Alfonso, G. (1993). Treatment of extrinsic bronchial asthma with transfer factor *Rev Alerg Mex*. pp. 124-131.
- Vichyanond, P., Tantimongkolsuk, C., Dumrongkigchaipom, P., Jirapongsananuruk, O., Visitsunthorn, N. et al. (2004) Result of a novel therapy with 0.1% topical ophthalmic FK-506 ointment. *J Allergy Clin Immunol*. pp. 355-358.
- Wilkins, MR., Appel, RD., Van-Eyk, JE., Chung, MC., Görg, A. et al. (2006). Guidelines for the next 10 years of proteomics. *Proteomics*. pp. 4-8.
- Wilson, GB., Fudenberg, HH. & Keller, RH. (1984). Guidelines for immunotherapy of antigen-specific defects with transfer factor. *J Clin Lab Immunol*. pp. 51-58.
- Wormald, R., Smeeth, L. & Henshaw, K. (2004). Evidence-based ophthalmology, BMJ publishing group.
- Yuta, A., Ali, M., Sabol, M., Gaumond, E. & Baraniuk, JN. (1997). Mucoglycoprotein hypersecretion in allergic rhinitis and cystic fibrosis. *Am J Physiol*. pp. L1203-1207.

Zribi, H., Descamps, V., Hoang-Xuan, T., Crickx, B. & Doan, S. (2009). Dramatic improvement of atopic keratoconjunctivitis after topical treatment with tacrolimus ointment restricted to the eyelids. *J Eur Acad Dermatol Venereol.* pp. 489–490.

IntechOpen

IntechOpen



Conjunctivitis - A Complex and Multifaceted Disorder

Edited by Prof. Zdenek Pelikan

ISBN 978-953-307-750-5

Hard cover, 232 pages

Publisher InTech

Published online 23, November, 2011

Published in print edition November, 2011

This book presents a number of interesting and useful aspects and facets concerning the clinical features, properties and therapeutical management of this condition. Dr. H. Mejía-López et al. present an interesting survey of the world-wide epidemiologic aspects of infectious conjunctivitis. Dr. U. Ubani evaluates conjunctival symptoms/signs participating in the clinical features of this disorder. Dr. A. Robles-Contreras et al. discuss immunologic aspects underlying possibly the conjunctivitis. Dr. Z. Pelikan presents the cytologic and concentration changes of some mediators and cytokines in the tears accompanying the secondary conjunctival response induced by the nasal challenge with allergen. Dr. S. Sahoo et al. summarize the treatment and pharmacologic control of particular clinical forms of conjunctivitis in general practice. Dr. S. Leonardi et al. explain the basic pharmacologic effects of leukotriene antagonists and their use for the treatment of allergic conjunctivitis. Dr. J.A. Capriotti et al. evaluate the therapeutical effects of various anti-adenoviral agents on the acute conjunctivitis caused by adenovirus. Dr. V. Vanzzini-Zago et al. assess the prophylactic use and efficacy of "povidone-iodium solution", prior the ocular surgery. Dr. F. Abazi et al. present the clinical features, diagnostic and therapeutical aspects of "neonatal conjunctivitis". Dr. I.A. Chaudhry et al. review the special sub-form of conjunctivitis, being a part of the "Trachoma". Dr. B. Kwiatkowska and Dr. M. Maślińska describe the clinical, pathophysiologic and immunologic features of conjunctivitis. Dr. S. Naem reviews the conjunctivitis form caused by *Thelazia* nematodes, occurring principally in animals.

How to reference

In order to correctly reference this scholarly work, feel free to copy and paste the following:

Atzin Robles-Contreras, Concepción Santacruz, Julio Ayala, Eduardo Bracamontes, Victoria Godinez, Iris Estrada-García, Sergio Estrada-Parra, Raúl Chávez, Mayra Perez-Tapia, Victor M. Bautista-De Lucio and Maria C. Jiménez-Martínez (2011). Allergic Conjunctivitis: An Immunological Point of View, *Conjunctivitis - A Complex and Multifaceted Disorder*, Prof. Zdenek Pelikan (Ed.), ISBN: 978-953-307-750-5, InTech, Available from: <http://www.intechopen.com/books/conjunctivitis-a-complex-and-multifaceted-disorder/allergic-conjunctivitis-an-immunological-point-of-view>

INTECH
open science | open minds

InTech Europe

University Campus STeP Ri
Slavka Krautzeka 83/A

InTech China

Unit 405, Office Block, Hotel Equatorial Shanghai
No.65, Yan An Road (West), Shanghai, 200040, China

www.intechopen.com

51000 Rijeka, Croatia
Phone: +385 (51) 770 447
Fax: +385 (51) 686 166
www.intechopen.com

中国上海市延安西路65号上海国际贵都大饭店办公楼405单元
Phone: +86-21-62489820
Fax: +86-21-62489821

IntechOpen

IntechOpen

© 2011 The Author(s). Licensee IntechOpen. This is an open access article distributed under the terms of the [Creative Commons Attribution 3.0 License](https://creativecommons.org/licenses/by/3.0/), which permits unrestricted use, distribution, and reproduction in any medium, provided the original work is properly cited.

IntechOpen

IntechOpen