

# We are IntechOpen, the world's leading publisher of Open Access books Built by scientists, for scientists

6,900

Open access books available

186,000

International authors and editors

200M

Downloads

Our authors are among the

154

Countries delivered to

TOP 1%

most cited scientists

12.2%

Contributors from top 500 universities



WEB OF SCIENCE™

Selection of our books indexed in the Book Citation Index  
in Web of Science™ Core Collection (BKCI)

Interested in publishing with us?  
Contact [book.department@intechopen.com](mailto:book.department@intechopen.com)

Numbers displayed above are based on latest data collected.  
For more information visit [www.intechopen.com](http://www.intechopen.com)



## Imaging Rhinosinusitis

Heidi Beate Eggesbø  
Oslo University Hospital, Rikshospitalet  
Norway

### 1. Introduction

Rhinosinusitis is classified as acute, recurrent and chronic. The acute form of rhinosinusitis should be diagnosed on symptoms and clinical findings, and imaging should not be necessary unless inflammatory complications are suspected. In recurrent and chronic rhinosinusitis, imaging is important in making a diagnose and planning the treatment. It is also important to look for inflammatory complications, and to discriminate “simple rhinosinusitis” from fungal infection and neoplasm (Rosenfeld, 2007). Paranasal sinus anatomy and pathology are difficult to interpret correct. Therefore, experienced radiologists as well as optimal imaging with respect to modality and method is mandatory.

### 2. Imaging modalities

Four imaging modalities have been used for imaging rhinosinusitis.

1. Computed tomography (CT) is the “gold standard” in imaging recurrent and chronic rhinosinusitis. CT is perfect for demonstrating the complex bony paranasal sinus anatomy with its variants as well as the localisation and extent of soft the tissue masses. Further, during functional endoscopic sinus surgery (FESS), the coronal or multiplanar CT is used as a bony map. Imaging rhinosinusitis without suspected complications, no intravenous contrast medium is needed (Eggesbo, 1999).
2. Magnetic resonance imaging (MRI) is complementary to CT, when CT has revealed soft tissue masses. In case of advanced unilateral soft tissue masses, MR imaging is mandatory to rule out, or further characterise fungal infection and neoplasm.
3. Plain films do not delineate the bony anatomy or soft tissue masses adequately and therefore this examination no longer have a place in imaging rhinosinusitis. The use of plain films should be limited to cases where CT is not available.
4. Ultrasonography has been used to detect pathology in the maxillary sinuses and anterior nasal fossa, however, the literature is not conclusive of its role in imaging rhinosinusitis.

The radiation dose using CT can be performed with as low mAs (20 mAs) as possible due to the contrast of bone and air, and hence the dose will be almost equal to plain films (Aalokken, 2003; Hagtvedt, 2003). Though MR can demonstrate the anatomy, CT is superior to delineate the bony details, as well as depicting soft tissue masses, in addition the surgeons always use CT as a surgical map.

The only patient preparation needed prior to CT and MR examination is nose blowing. Nasal spray with decongestants prior to examination is not needed. In order to delineate bony anatomy most properly, the patient should be in the prone position at CT in order let fluid drain away from the sinus openings, also referred to as the ostiomeatal complex (OMC) (Babbel, 1991). In acute recurrent rhinosinusitis imaging could favourable be postponed for some weeks for better delineation of the bony details when the soft tissue masses are less pronounced.

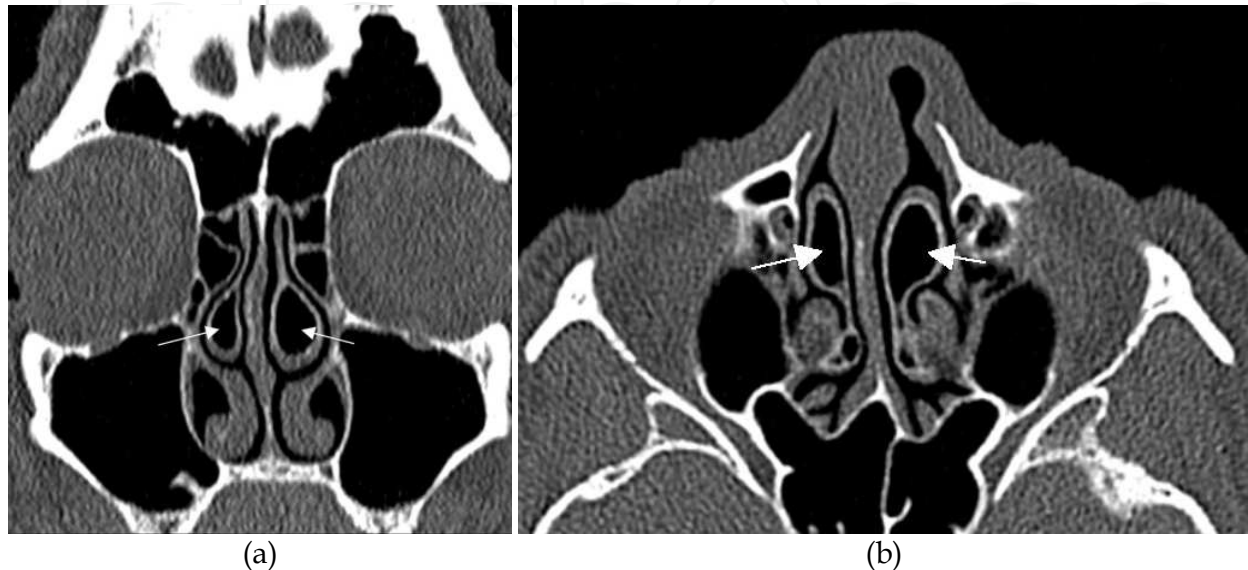


Fig. 1. CT is the primary modality in sinonasal imaging. (a) Coronal CT through the anterior paranasal sinuses with the maxillary, anterior ethmoid including bilateral concha bullosa (arrows) and the frontal sinuses. (b) Axial CT through sphenoid, maxillary and ethmoid sinuses with bilateral concha bullosa (arrows).

### 3. Paranasal sinus development, anatomical and pneumatisation variants

It is mandatory for a correct imaging report that the radiologist is familiar with the development of the paranasal sinuses and recognises the bony variants and their influence on the mucociliary drainage routes.

The paranasal sinuses develop from fetal life till the nearly adult size by the age of 12 years.

The maxillary sinuses are present as evaginations from the nasal cavities at birth and show a biphasic growth with a rapid growth from birth till the age of six years. Then a second accelerated growth from the age of seven years takes place. Chronic rhinosinusitis in childhood may abort this acceleration of sinus development and cause maxillary sinus hypoplasia. On coronal imaging, maxillary sinus hypoplasia is easily recognised as the maxillary sinus floor above the nasal floor together with an oval shaped orbit and low ethmoid roof (Eggesbo, 2001b). The surgeon must be aware of this variant, because the uncinate process that is a bony landmark during surgery, is lateral displaced and the orbit can easily be exposed during surgery as well as a low ethmoid roof may expose the brain.

The sphenoid sinuses also develop from birth. At the age of six years the presphenoid is pneumatised and by the age of twelve years also the sphenoid bone below the sella turcica, termed the basisphenoid, is pneumatised. Finally, pneumatisation of the anterior clinoid

and pterygoid processes may occur. The sphenoid sinuses have close relation to the cranial nerves, 3<sup>rd</sup>, 4<sup>th</sup>, 5<sup>th</sup><sub>I</sub>, 5<sup>th</sup><sub>II</sub> and 6<sup>th</sup>, and the carotid artery passing in the cavernous sinus and the optic nerve. When sphenoethmoid cells or pneumatization of the anterior clinoid process are seen, the optic nerves are frequently inside the sinus and should not be mistaken for a soft tissue mass or polyp.

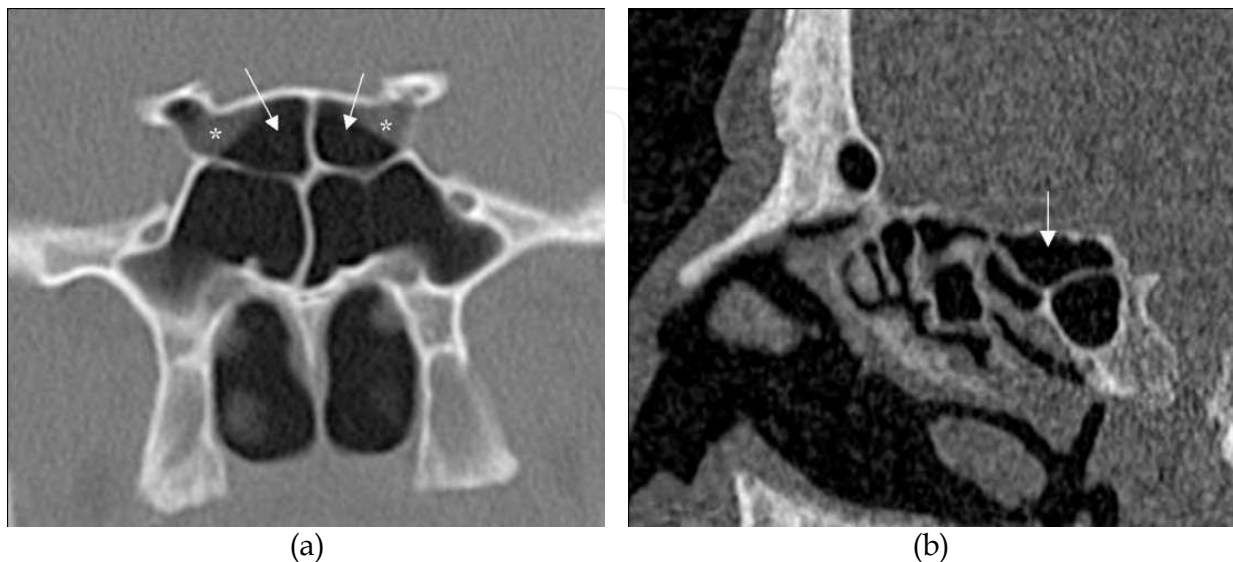


Fig. 2. (a) Coronal CT through the sphenoid bone shows four cells, where the superior cells are posterior ethmoid (sphenoethmoid) cells (arrows) that have continued into the sphenoid bone superior to the true sphenoid sinuses. (b) Sagittal CT demonstrates a sphenoethmoid cell (arrow) superior to the true sphenoid cell. Also notice the optic nerves (asterisks) running through the sphenoethmoid (Onodi) cells in fig (a).

The ethmoid sinuses are developed by birth as fluid filled evaginations, and air-filled during the first year. Adult ethmoid sinuses consist of 3-18 sinuses (termed cells) on each side. The anterior and posterior ethmoid sinuses are divided by the posterior wall (Stammberger, 1995) of the largest and most constant ethmoid cell termed the ethmoid bulla (Latin word for bubble).

In a healthy person with no mucosal disease, the ethmoid cells may expand to the surrounding bone and form extra cells referred to as pneumatization variants.

The most common pneumatization variants from the anterior ethmoid cells are concha bullosa (pneumatization of the middle turbinate), pneumatization below the orbital floor and adjacent to the maxillary ostium, termed infraorbital cells or Haller cells (after the Swiss biologist Albrecht von Haller in 1743 (1708-1777) (Caversaccio, 2011), and agger nasi cells (pneumatization of the most the anterior part of the maxillary bone). The importance of these pneumatization variants is their close relation to the mucociliary drainage routes. E.g. a large infraorbital cell may obstruct the drainage from the maxillary sinus causing an infundibular inflammatory pattern, a large agger nasi cell may obstruct the drainage from the frontal sinus causing frontal sinusitis, and a large concha bullosa or large ethmoid bulla may obstruct the middle meatus and hence involve the ipsilateral frontal, anterior ethmoid and maxillary sinuses referred to as an OMC inflammatory pattern. A large ethmoid bulla may also obstruct the mucociliary clearance from the ipsilateral frontal, anterior ethmoid and maxillary sinuses.

The most common pneumatisation variants from the posterior ethmoid cells are posterior ethmoid cells that continue posteriorly into the sphenoid bone either laterally or superiorly to the sphenoid sinus, termed sphenoethmoid or Onodi cells. (after the Hungarian rhinolaryngologist Adolf Onodi in 1903 (1857-1919)).

The frontal sinuses are the last sinuses to develop and termed frontal sinuses first when the ethmoid recesses (sinuses) pass the superior orbital rims. This usually occurs by the age of six years. Aplasia and hypoplasia of the frontal sinuses is common, with aplasia seen in 5% of the population. A frontal sinus can be regarded as pneumatisation variant since its occurrence depends on the pneumatisation potential of the ethmoid sinuses.

By the simultaneous introduction of CT imaging and endoscopic surgery in the 1980's the pneumatisation variants were viewed as a main cause for rhinosinusitis. This is no longer the theory. Pneumatisation variants are a result of healthy sinuses that has greater pneumatisation potential than diseased sinuses. However, when pneumatisation variants are present, only a slight mucosal swelling can cause obstruction of the mucosal drainage route and cause rhinosinusitis. Therefore, removing the bony walls of pneumatisation variants, is an usual procedure when FESS is required.

#### 4. Mucociliary clearance and normal mucosal variants

The paranasal sinuses are covered by a ciliated epithelium that beats with a frequency up to 1000 cycles a minute. The epithelium produce mucous that entraps particles and microorganisms and the ciliated cells clean up by turning the mucus blanket over every 10-30 minutes. The paranasal sinuses also contribute to humidify the inhaled air. Therefore, the mucous and fluid production of the paranasal sinuses can be as high as one to two liters every day. Each sinus has its own specific drainage route before passing through the ostium into the superior or medial meatus then passing to the choana. The anterior ethmoid, frontal and maxillary sinuses drain into the middle meatus and the posterior ethmoid and sphenoid sinuses drain into the superior meatus.

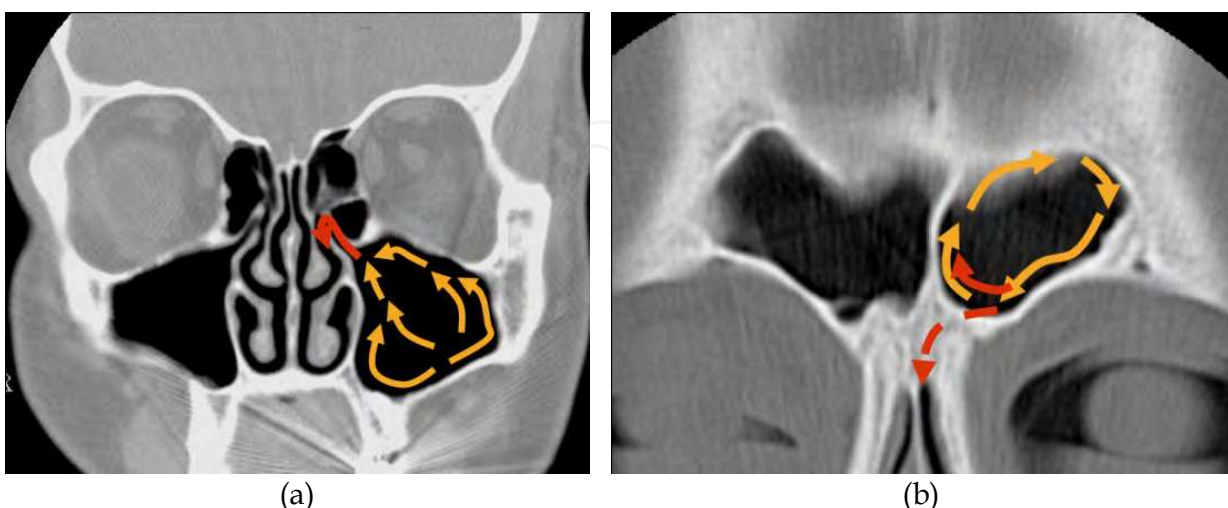


Fig. 3. Coronal CT demonstrating the mucociliary drainage route for (a) the maxillary sinus with it's final route through the ethmoid infundibulum (red arrow) and (b) the frontal sinus with it's final route through the frontal recess (red dotted arrow).

Swelling of the mucosal lining or polyps at the level of the sinus openings cause obstruction of the drainage routes and cause rhinosinusitis. One of the issues of imaging is to evaluate the patency of the mucociliary drainage routes and report on mucosal swellings and anatomical variants that may contribute to obstruction of these drainage routes.

In reporting paranasal sinus imaging the radiologist must be aware of normal physiological changes in order not to “over report” the normal findings as inflammatory changes. E.g. the nasal cycle first described by Kayser in 1889. The nasal cycle is a cyclical swelling of the ipsilateral turbinates and nasal mucosa. Unilateral enlarged turbinates are therefore a normal imaging finding (Zinreich, 1988). Also the ethmoid mucosal linings are influenced by the nasal cycle, hence mucosal thickening of 2 mm is commonly seen due to the nasal cycle and must not be reported as abnormal. Concerning the frontal and sphenoid sinuses the mucosal linings should not be visualised at CT, while maxillary sinus mucosal thickening up to 4 mm is often seen in healthy individuals and considered as a normal finding (Rak, 1991). With age, the nasal cycles become less prominent.

The nasal cycle, paranasal mucosa and mucous/serous production are regulated by the autonomic nerve system and neuropeptides from the primary sensory neurons. The complex system is still not completely understood, however it is known that the parasympathetic system and sympathetic  $\beta$ -receptors stimulate secretion (Naclerio, 2010; Sarin, 2006).

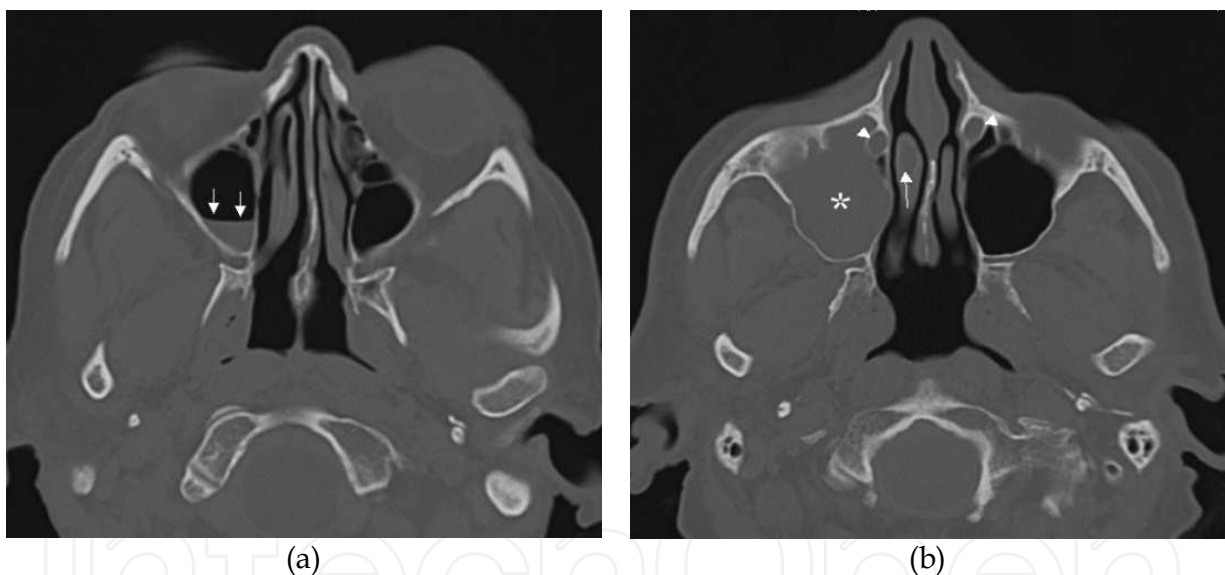


Fig. 4. (a) Axial CT shows incidental finding of an air-fluid level (arrows) in the right maxillary sinus in a patient undergoing cerebral CT. There is no sclerotic bone thickening and hence no indication for follow-up. (b) Axial CT shows incidental total opacification of the right maxillary sinus (asterisk) without sclerotic bone thickening. Unless clinical symptoms of a acute sinusitis, no action to this finding is needed. Notice also opacified right concha bullosa (arrow) and normal fluid filled lacrimal ducts (arrowheads)

Primary sensory neurons releasing neurotransmitters can also cause increased mucosal swelling and fluid production. Finally, drugs that have a vasoactive effect can increase the thickness of mucosal lining and increase the serous fluid production (Cingi, 2011). Fluid filled sinuses can therefore be an incidental finding, especially in bedridden patients, and must be interpreted with care (Naclerio, 2010; Sarin, 2006). Air-fluid level is frequently seen in healthy patients and is not equivalent to rhinosinusitis. Only if the patient has symptoms of

rhinosinusitis and the fluid contains air-bubbles, the findings can be interpreted as acute rhinosinusitis. The surrounding bone is a clue to diagnose chronic rhinosinusitis. If normal thickness of the surrounding bone a chronic infection can be ruled out.

## 5. Solitary polyps and retention cysts

Solitary polyps and retention cysts are common incidental findings in the paranasal sinuses and usually have no clinical implication. The maxillary sinus is the most common origin, especially from the floor of the sinus. Polyps are due to accumulation of fluid in the mucosa as are serous retention cysts, while mucous retention cysts are due to obstruction of a seromucinous gland. Polyps and retention cysts are seen as smooth, outwardly convex soft tissue masses at CT and MR imaging and cannot be differentiated. The MR signal depends on the water and protein content, and when the water content dominates, solitary polyps and retention cysts have homogeneous, high T2- and low T1-signal. If no underlying bony destruction is present at CT, the term retention cyst should be used and no follow-up imaging should be necessary.

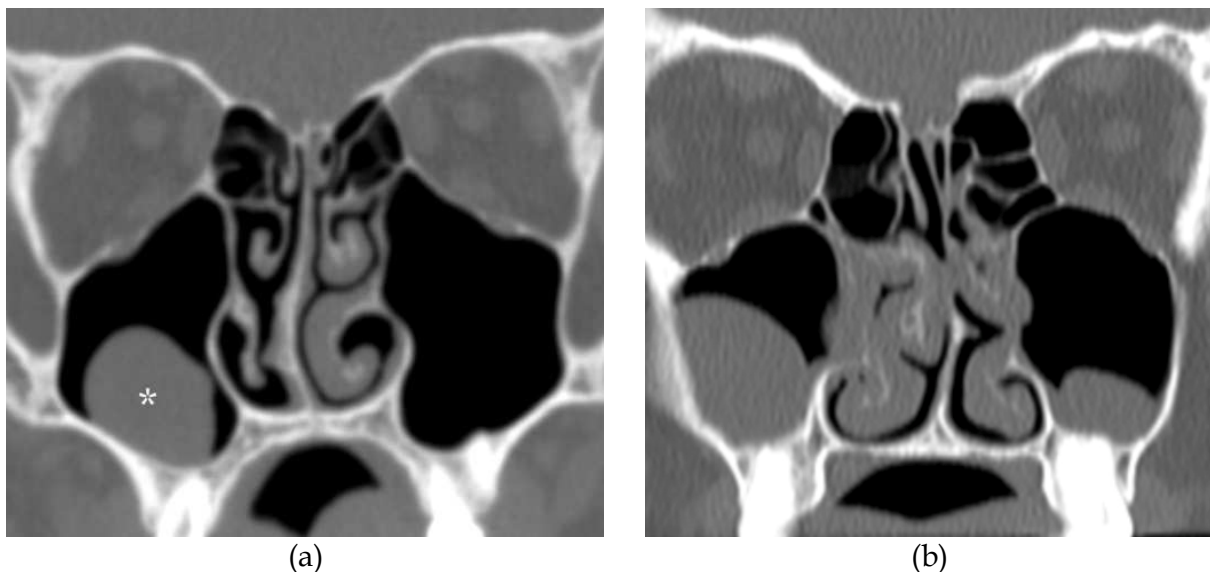


Fig. 5. (a) Coronal CT shows a smooth, outwardly convex soft tissue mass (asterisk) originating from the maxillary floor. No underlying bone destruction or periondontic abscess are seen and the mass should be interpreted as a retention cyst. (b) Coronal CT in another patient shows retention cyst in each maxillary sinus and slight mucosal thickening/retention cyst in the right nasal cavity.

## 6. Inflammatory patterns

Five inflammatory patterns at CT have been described in chronic rhinosinusitis (Sonkens, 1991). These patterns are: 1. Infundibular, 2. Ostiomeatal complex (OMC), 3). Sphenoethmoid recess (SER), 4. Polyposis, and 5. Sporadic. The first three inflammatory patterns are caused by obstruction of mucociliary drainage routes.

1. The first pattern is caused by obstruction at the level of the ethmoid infundibulum, which is the drainage route of the maxillary sinus, and hence called infundibular inflammatory pattern. In this pattern only the ipsilateral maxillary sinus is involved.

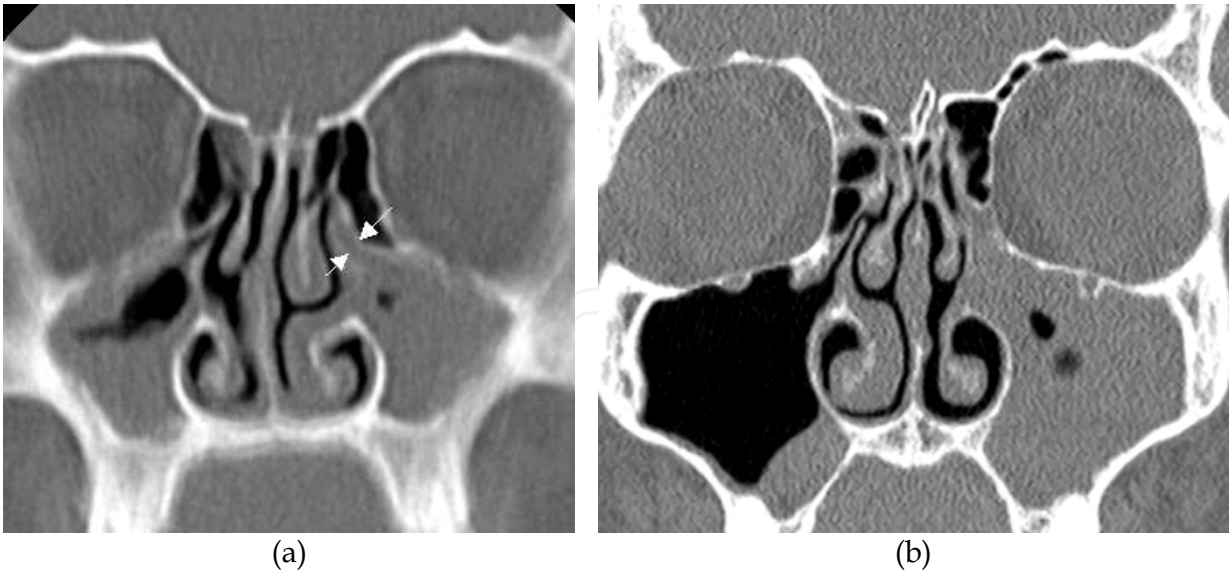


Fig. 6. (a) Coronal CT shows infundibular inflammatory pattern with bilateral opacification of the maxillary sinuses due to obstruction of mucociliary drainage at the level of the ethmoid infundibulum (arrows). (b) Coronal CT shows unilateral left sided infundibular inflammatory pattern, and sporadic mucosal thickening in the right maxillary sinus floor.

- 2. The second pattern is caused by obstruction of the middle meatus, which is the final mucociliary drainage route of the ipsilateral maxillary, anterior ethmoid, and frontal sinuses. This pattern is referred to as the ostiomeatal (derived from ostium and meatus) complex (OMC) inflammatory pattern.

The frontal sinus drains either via the frontal recess directly to the middle meatus or through the antero-superiorly aspect of the ethmoid infundibulum. Isolated frontal sinusitis is regarded as a variant of OMC inflammatory pattern.

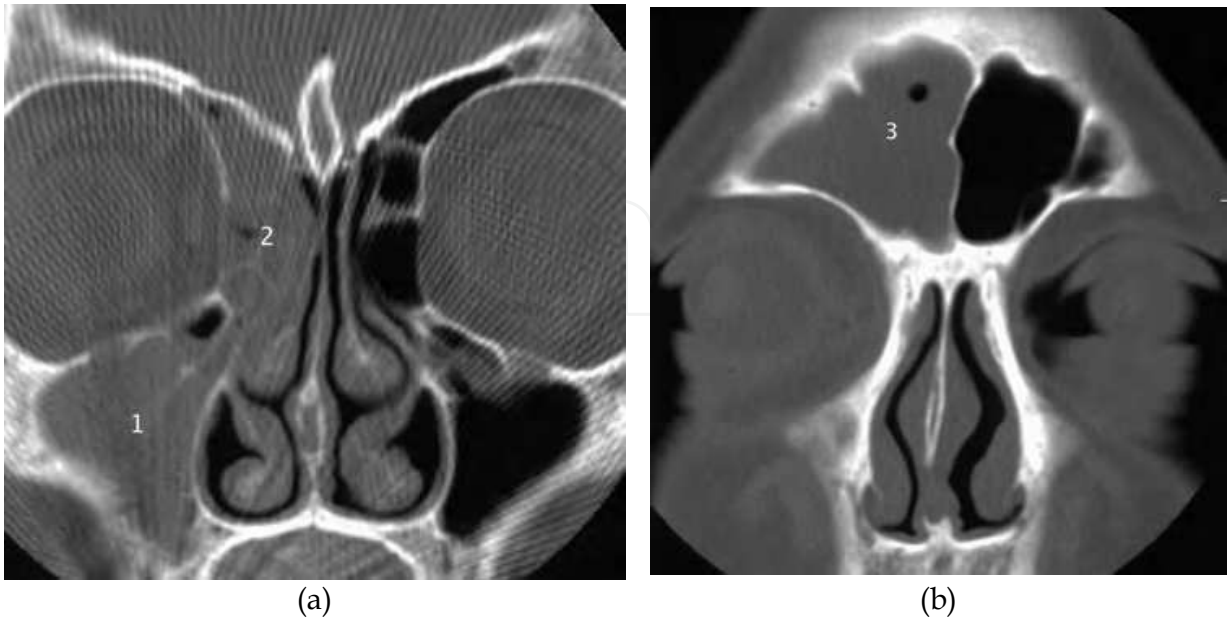

Fig. 7. Coronal CT shows OMC inflammatory pattern with ipsilateral opacification of the (a) maxillary (1), anterior ethmoid (2) and (b) frontal sinuses (3).

3. The third pattern is caused by obstruction of the sphenoethmoid recess (SER), which is the drainage route of both the sphenoid and ipsilateral posterior ethmoid sinuses. An obstruction can proceed to rhinosinusitis only of the sphenoid sinus or also the ipsilateral posterior ethmoid sinus.

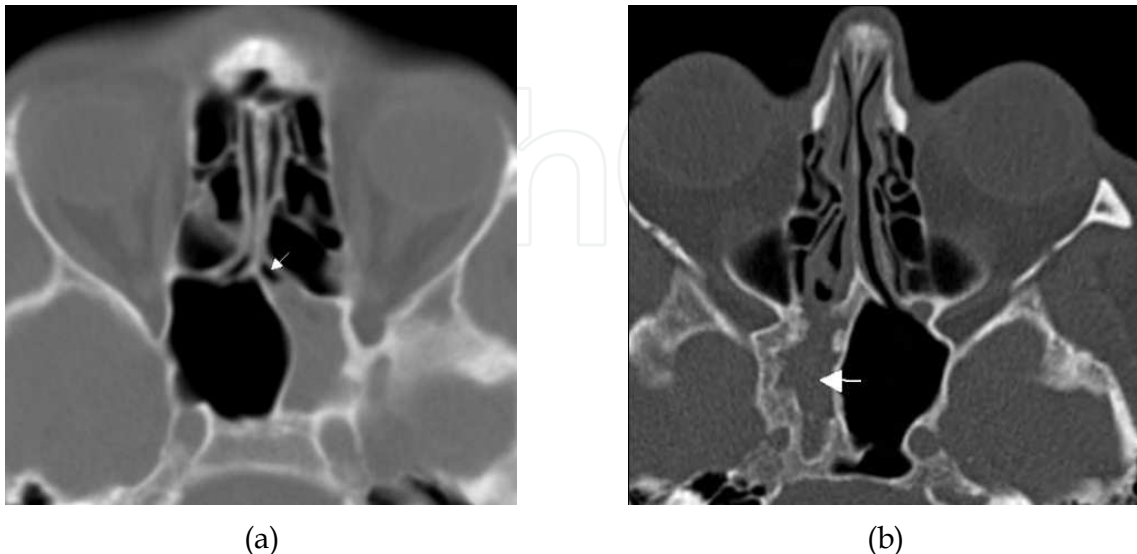


Fig. 8. (a) Axial CT shows total opacification of the left sphenoid sinus with slightly thickening of the surrounding bone. Note that the left SER (arrow) contains air. This indicates that the obstruction can be at the level of the sphenoid ostium or the opacification can be due to a polyp originating from inside the sphenoid sinus. (b) Axial CT shows sclerotic bone surrounding the total opacified right sphenoid sinus (arrow), indicating a longstanding infection.

4. The fourth pattern is bilateral sinonasal polyposis and is characterised by enlargement of the ethmoid infundibulum as well as bulging and remodelling of the ethmoid sinus cells. In addition, the nasal cavities are filled with polyps, recognised by it's downward convexity contour.

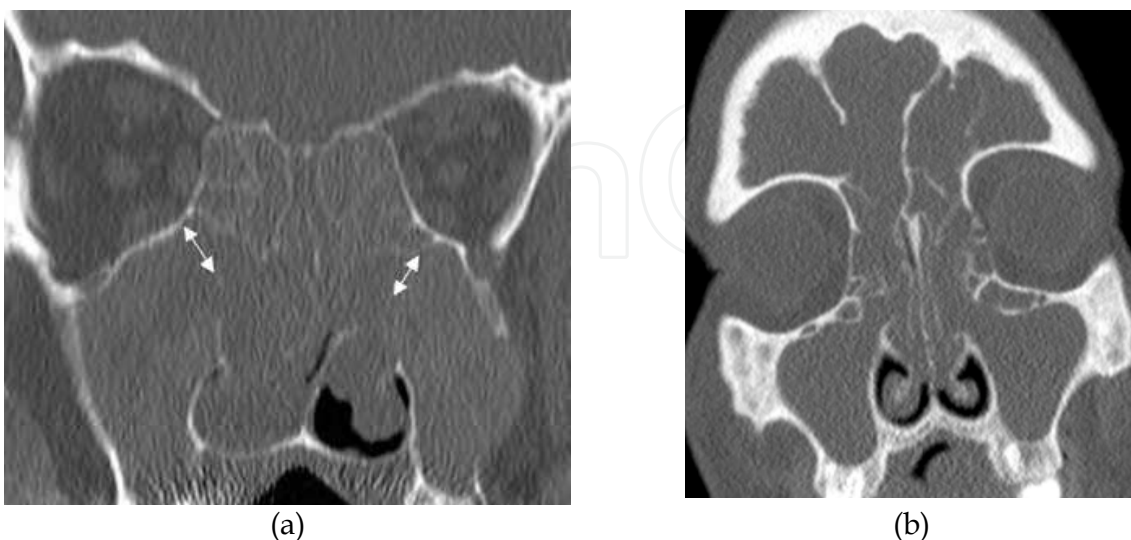


Fig. 9. (a) Coronal CT of polyposis inflammatory pattern. Note the typical broadening of the ethmoid infundibulum bilateral (arrows). (b) Another patient where coronal CT also shows the involvement of the frontal sinuses.

5. The last and fifth pattern, includes all opacities that do not fit into the four previous patterns, e.g. solitary polyps, retention cysts, mucosal thickening, and postoperative mucosal thickening etc. and therefore is referred to as the sporadic pattern.

It is important to recognise these inflammatory patterns in order to plan whether the patient will benefit from FESS, and if so the region and extent of the FESS procedure. E.g. In the infundibular pattern an uncinectomy or medial antrostomy alone will open the natural maxillary sinus ostium, while in the OMC pattern more extensive surgery including both medial antrostomy and anterior ethmoidectomy may be needed.

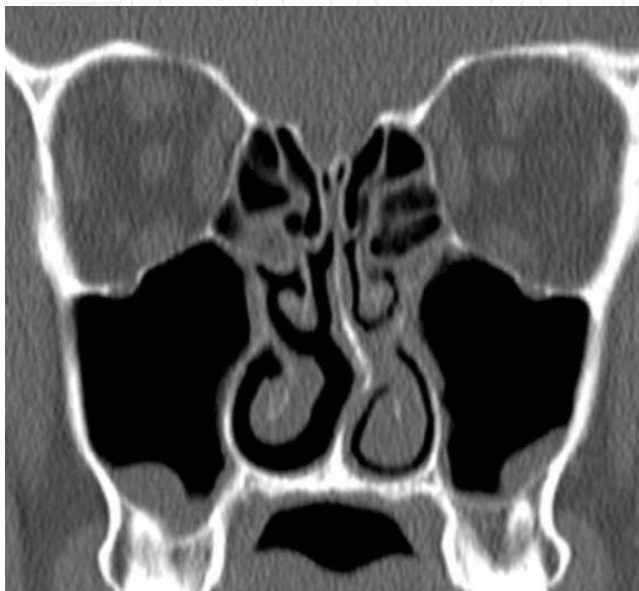

Fig. 10. (a) Coronal CT shows a retention cysts and sparse mucosal thickening classified as a sporadic inflammatory pattern.

## 7. Grading and monitoring chronic rhinosinusitis

In chronic rhinosinusitis, several systems for grading and monitoring have been proposed and evaluated. The Lund-Mackay system from 1997 (Lund, 1997) has been easy to use, however, all staging systems have shown limited clinical application (Zinreich, 2004).

## 8. Conditions mimicking rhinosinusitis

Many conditions may mimic the inflammatory patterns described and differential diagnoses must always be considered.

An antrochoanal polyp that occupies the maxillary sinus can be misinterpreted as an infundibular inflammatory pattern. The clue to the diagnosis is a small air-filled space superior in the sinus and soft tissue masses in the choana and with a polyp seen in the oropharynx.

Periodontal infection may cause inflammation to the ipsilateral maxillary sinus as well as the ipsilateral anterior ethmoid and frontal sinuses, and hence mimic an OMC inflammatory pattern. It is mandatory that the technicians include the maxillary alveolar ridge in the scanning, in order to rule out, or demonstrate an odontogenic origin. In case of dental filling artefacts, axial volume scanning will limit the dental artefacts to the axial plan.

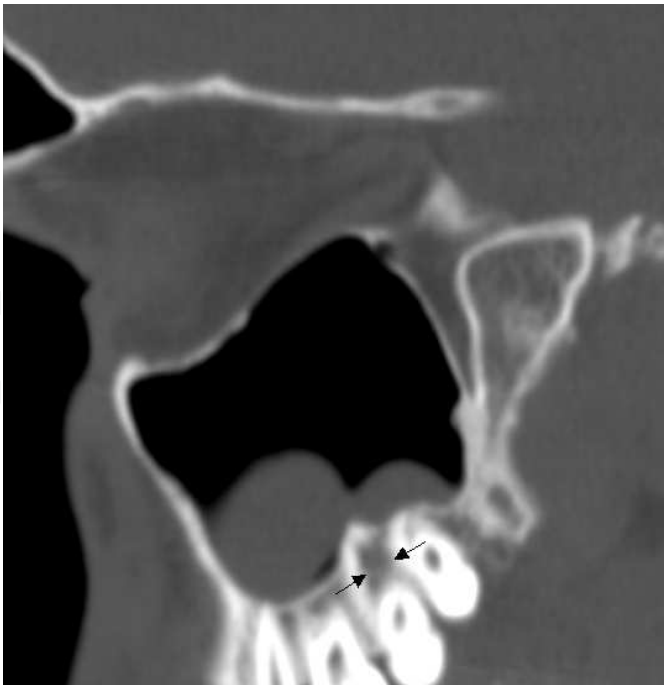

Fig. 11. Sagittal CT shows polypoid mucosal thickening in the maxillary sinus due to underlying odontogen infection (arrows).

Rhinolithiasis is a rare and an under-diagnosed finding that is caused by mineralisation of an endogenous or exogenous foreign material (Yaşar, 2009). The patients usually present with a foul-smelling nasal discharge. When dental amalgam is the cause, the ethmoid infundibulum or the middle meatus may be obstructed and cause rhinosinusitis that mimic the infundibular or OMC patterns. Also an ectopic molar tooth free inside the maxillary sinus can give the same imaging appearance.

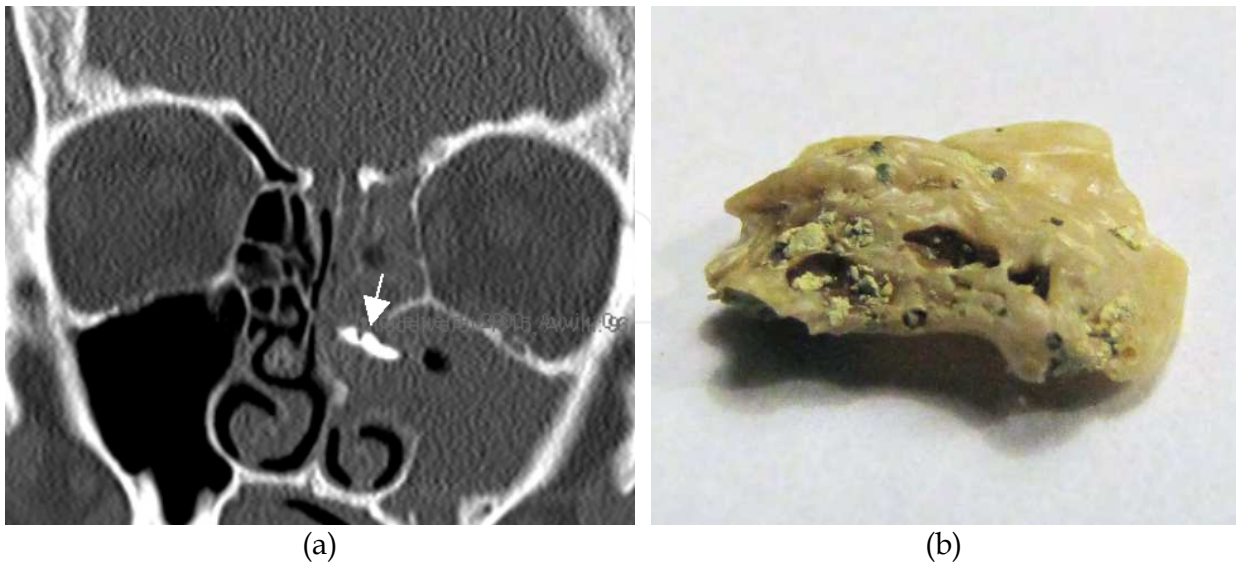


Fig. 12. (a) Coronal CT shows advanced opacification of the left ethmoid and maxillary sinuses as in OMC inflammatory pattern. However, the inflammatory changes are due to an elongated calcification (arrow) located in the middle meatus. (b) A few months later, the patient delivered an ectopic molar tooth.

Several systemic diseases may show or present with sinonasal symptoms that may mimic or be equal to the patterns of inflammatory rhinosinusitis. The systemic diseases that may present with sinonasal manifestations are listed later in this chapter.

Fungal rhinosinusitis can imitate all five inflammatory patterns and must be considered in all patients with chronic rhinosinusitis. The characteristics of fungal rhinosinusitis are described later in this chapter.

Tumours are rare in the paranasal sinuses and contributing to only 1% of all malignant tumours. Therefore, malignant tumours are commonly interpreted as rhinosinusitis. All solitary nasal polyps should be considered for histopathologic examination. Destruction of adjacent bone at CT is one clue to suspect a malignant tumour.

### 9. Inflammatory complications

Sclerotic bone at CT is the most frequent response and complication to recurrent and chronic rhinosinusitis. Opacified sinus together with sclerotic surrounding bone should always alert the radiologist for the need of complementary MR imaging or follow-up CT. The thickness and morphology of the surrounding bone is an important clue to differentiate chronic from acute rhinosinusitis or parasymphathetic dominance in a bedridden patient.

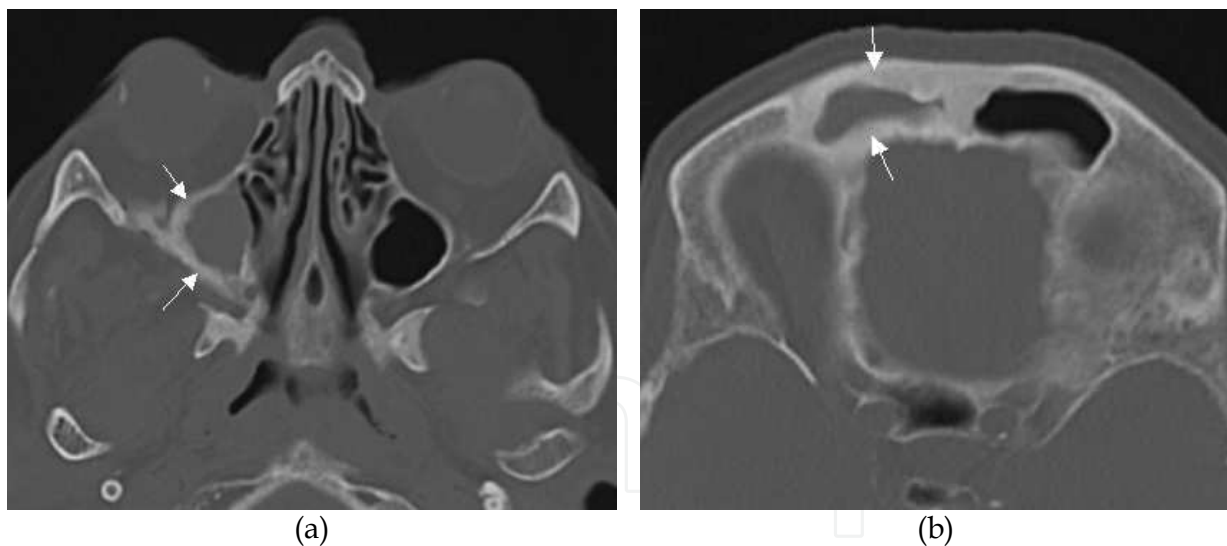


Fig. 13. Axial CT showing total opacification of the maxillary (a) and the frontal (b) sinuses accompanied with sclerotic bone thickening (arrows) indicating a chronic infection.

Osteomyelitis is a rare complication to rhinosinusitis. Infection of the bone marrow of diploetic frontal bone due to frontal sinusitis may present with a subperiosteal abscess, commonly referred to as a Pott's puffy tumour.

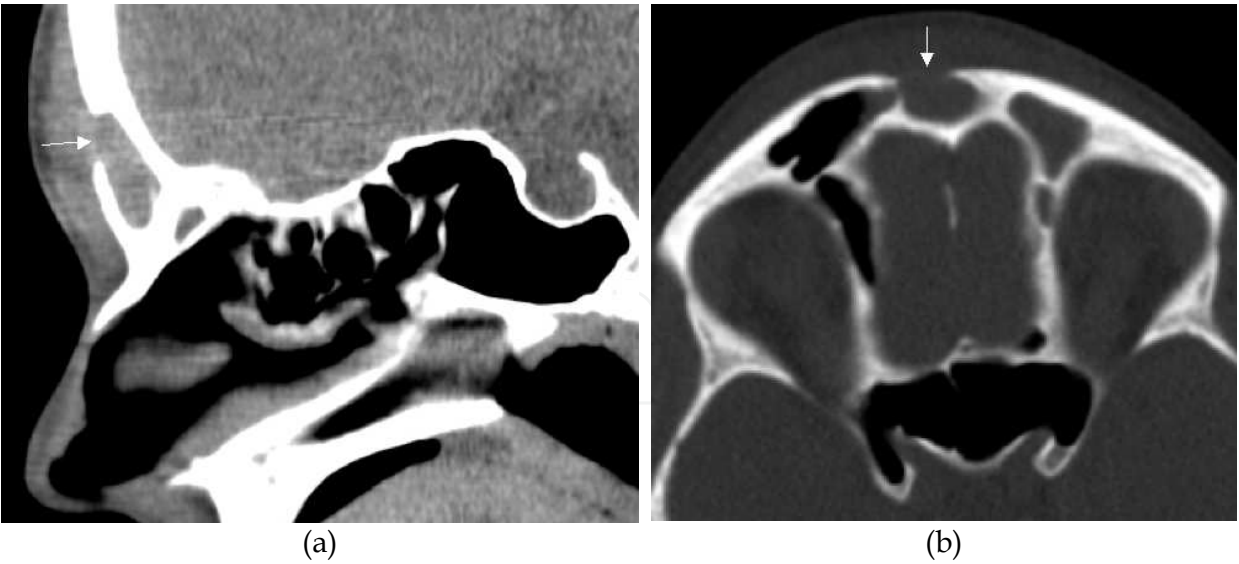


Fig. 14. (a) Sagittal CT shows total opacification of the frontal sinus with erosion of the anterior wall (arrows) due to an eroding frontal sinus abscess, referred to as Pott’s puffy tumour. (b) Axial CT in the same patient

Silent sinus syndrome, also more correctly referred to as chronic maxillary atelectasis, is a relatively newly described entity. The CT imaging features are almost pathognomonic with collapse of the sinus walls due to longstanding negative pressure, sclerotic thickening of the surrounding bone, and oval shaped orbit giving rise to the clinical finding of enophthalmos. (Soparkar, 1994). In this condition, the maxillary sinus volume is small, but should not be misinterpreted as maxillary sinus hypoplasia in where the molar eminence will not be pneumatized. Enophthalmos without the typical CT findings should not be misdiagnosed as silent sinusitis (Burroughs, 2003).

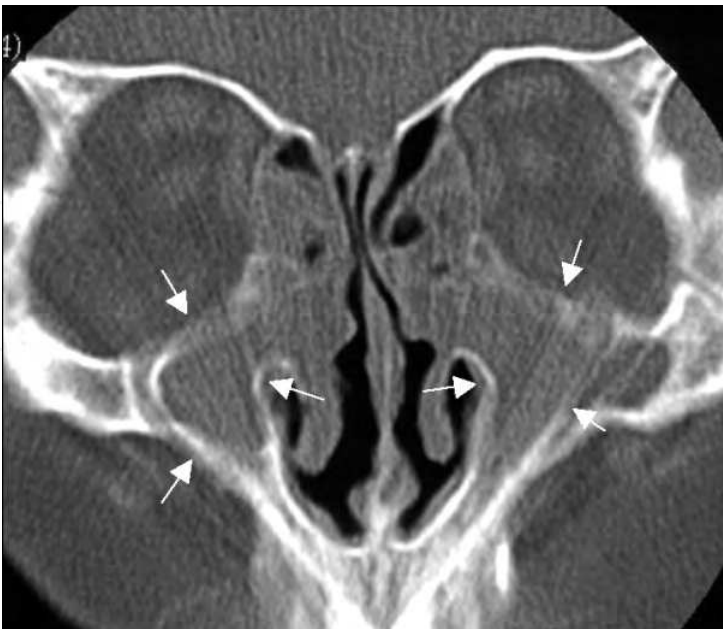

Fig. 15. Coronal CT in a patient with silent sinusitis syndrome due to bilateral, longstanding maxillary rhinosinusitis. The maxillary sinus volumes are reduced due to the inward retraction of the sinus walls (arrows). Note also the enlarged, oval shaped orbits.

Inflammatory spread to the orbits is more common than intracranial spread. In case of orbital abscess, the ethmoid sinuses usually is the origin of infection because the thin lamina papyracea and the ethmoid valveless veins easily allow spread of infection. Inflammatory processes in the sphenoid, maxillary and frontal sinuses, in descending order, are less likely to cause orbital infection.

Only 3% of cerebral abscesses are due to rhinosinusitis, with the frontal and sphenoid sinuses as the most common origin of infection, followed by the ethmoid and maxillary sinuses.

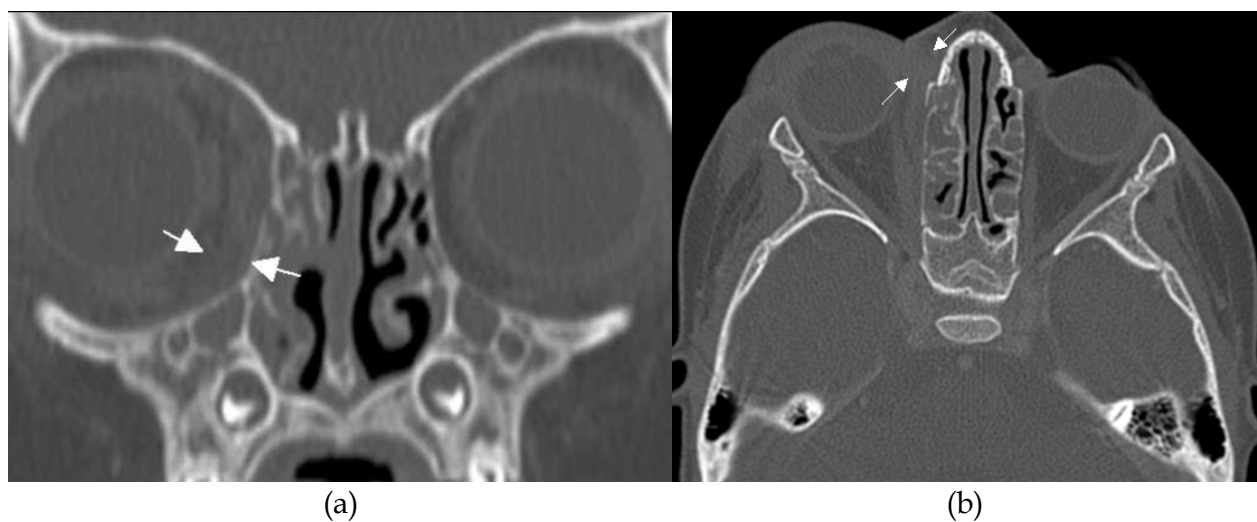


Fig. 16. Coronal (a) and axial (b) CT show bilateral opacification of the ethmoid sinuses. On the right side there is exophthalmos due to spread of infection (arrows) from the right ethmoid sinus.

## 10. Mucocele vs. pyocele

Obstruction of a sinus ostium can proceed to formation of a mucocele, which is made up of mucous and desquamated epithelium. Over time, expanding of a mucocele will remodel the adjacent bone and sometimes also cause extension into neighbouring sinuses, orbit or cranium. Mucocele is most often seen in the frontal sinus, followed by the ethmoid and maxillary sinuses, while rare in the sphenoid sinus. When a mucocele is super-infected it is termed a pyocele.

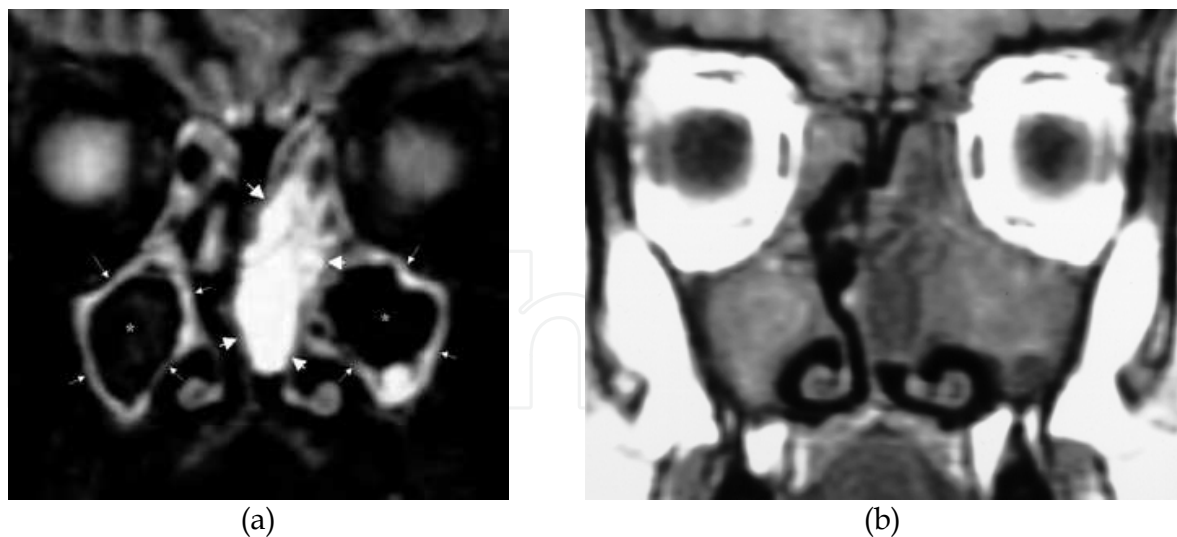


Fig. 17. Pus-filled maxillary sinuses and a fluid-rich polyp in the left nasal cavity. (a) Coronal MR with STIR sequence shows bilateral hyperintense maxillary sinus lining (small arrows). and centrally signal void equal to pus (asterisks). In addition there is a hyperintense mass filling the left nasal cavity equal to a polyp (large arrows). (b) The complementary coronal MR with T1 sequence shows low signal in the mucosal lining and intermediate to high signal centrally, while the fluid-rich polyp has low signal.

At CT a mucocoele and pyocoele cannot be differentiated, though a pyocoele tend to have higher density than the surrounding mucosa. Using MR however, the oedematous mucosal lining shows high T2 signal, surrounding a signal void or low signal centrally equally to the pus-filled lumen. The corresponding T1 signal is high or intermediate (Eggesbo, 2001a).

## 11. Atrophic rhinosinusitis

In atrophic rhinosinusitis the respiratory epithelium covering the nasal and paranasal surface is replaced by non-ciliated epithelium. The primary form presents with a foul-smelling nasal discharge due to *Klebsiella ozenae* and widened nasal passages with a paradoxical feeling of nasal congestion. It is most common in young adults from developing countries as Southern Saudi Arabia, China, Africa, India, Mediterranean and Philippines.

The secondary form is the most frequent and associated to previous nasal injury, surgery or inflammation (deShazo, 2011).

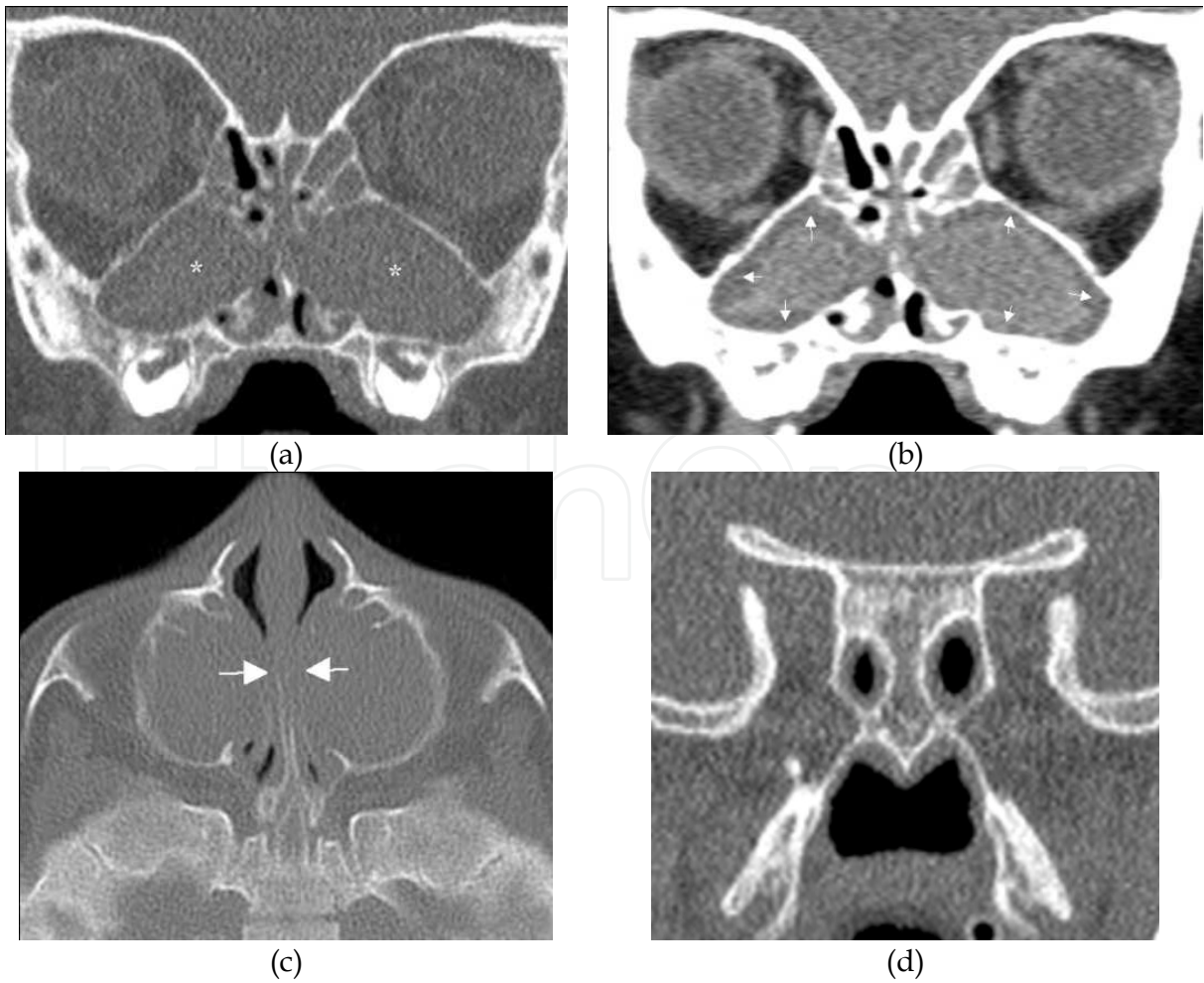
Atrophic rhinitis has become a more common form of chronic rhinosinusitis. However, due to lack of clinical criteria the condition is under-diagnosed (Ly, 2009). It has been suggested that the secondary form is a final common pathway following injury of the nasal mucosa. Only a few papers describe the CT findings in atrophic rhinitis. These are nasal and paranasal mucosal thickening, small inferior and middle turbinates with atrophic mucosa and partial or total bony erosion. In addition small maxillary sinuses are described. This finding may be equal to "silent sinus syndrome" where chronic obstruction cause negative maxillary sinus pressure and with time the sinus walls collapse including the orbital floor, hence the patient may present with bilateral enophthalmos.

12. Sinonasal manifestations in patients with systemic disease

Sinonasal manifestations and chronic rhinosinusitis are described for many systemic diseases ( Som, 2011), and may often also be the initial presentation of the systemic disease.

Cystic fibrosis

Cystic fibrosis is an autosomal recessive disease and almost only present in the Caucasian population. Though lung infections and malabsorption are the main clinical manifestations that usually are referred, all patients have sinonasal disease with mucosal thickening of all sinuses. In addition 40% present with additional polyposis. In CF children with mouth breathing and nocturnal snoring, a common finding is bilateral maxillary sinus pyoceles. At CT imaging, they have characteristic medial bulging of the lateral nasal walls that totally can obstruct the nasal cavities. In these cases, a complementary MR examination will show peripheral mucosal thickening with high T2 signal and centrally signal void or very low signal equivalent to pus. The corresponding T1 signal is high or intermediate and will distinguish pus from an air-filled sinus lumen. The MR examination is mandatory in selecting patients that will benefit from surgery and to guide the surgeons to the pus-filled areas in the maxillary and ethmoid sinuses (Eggesbo, 2001a).



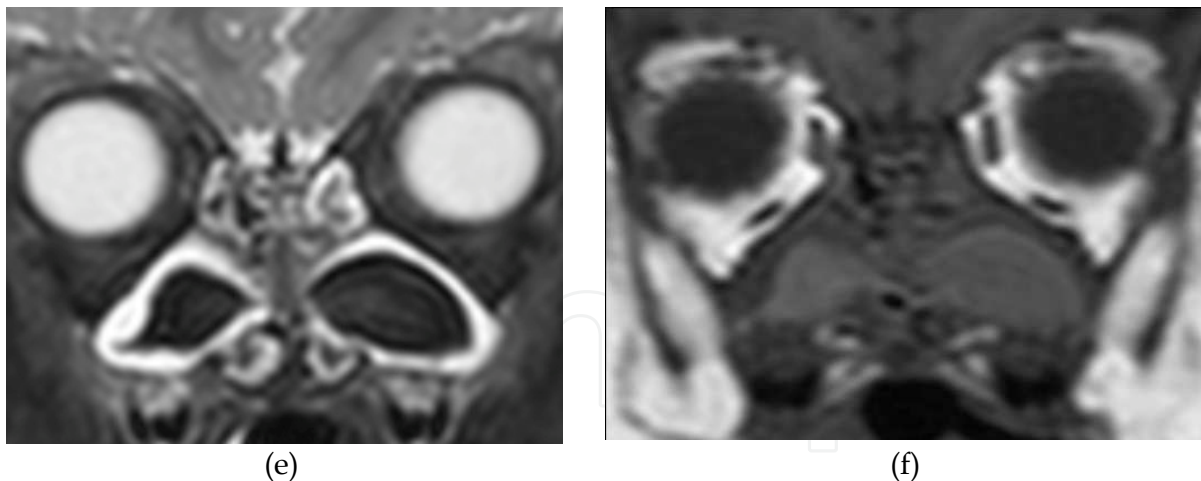


Fig. 18. Two-year-old boy with cystic fibrosis (CF). (a) Coronal CT with bone algorithm shows bilateral, homogeneous, ethmomaxillary soft tissue masses (asterisks). (b) Coronal CT with soft tissue algorithm can differentiate the mucosal lining (arrows) from the sticky mucous centrally. (c) Axial CT demonstrates the advanced medial bulging of the lateral nasal walls (arrows). (d) Coronal CT demonstrates sphenoid sinus hypoplasia seen in all CF patients. (e) Coronal MR with STIR sequence differentiates the mucosal lining from the pus-filled maxillary sinus lumen centrally. (f) The corresponding coronal MR T1 sequence is mandatory in order to discriminate the signal void lumen at STIR sequence from air-filled lumen.

### Primary ciliary dyskinesia

Primary ciliary dyskinesia (immotile cilia syndrome) is an autosomal recessive disease with an incidence of 1/16000. The sinonasal manifestations are almost the same as in cystic fibrosis with opacification of all sinuses.

### Young's syndrome

Young's syndrome manifest with obstructive azoospermie, pulmonary infections and chronic rhinosinusitis. This condition may also present with panopacification of the sinuses.

### Sertoly-cell-only syndrome

Sertoly-cell-only syndrome with absence of spermatogones, bronchiectasis and chronic rhinosinusitis.

### Hyperimmunoglobulinemia E syndrome

Hyperimmunoglobulinemia E syndrome is an autosomal recessive disease with dermatitis, skin infections, otitis media, pneumonia, impaired neutrophile chemotaxis, and high serum IgE and chronic rhinosinusitis is an usual finding.

### Churg-Strauss syndrome

Churg-Strauss syndrome is a rare multisystemic disease, primarily in adults and with initial symptoms of asthma and allergic rhinosinusitis that cannot be differentiated from chronic rhinosinusitis.

**Nijmegen's Breakage syndrome**

Nijmegen's Breakage syndrome have microcephaly and variable rhinosinusitis and hypersensitivity to gamma radiation and hence, MR should be performed instead of CT, if imaging is required.

**Aspirin triad syndrome**

Aspirin triad syndrome in where the patients are hypersensitive to aspirin. The symptoms are asthma and chronic rhinosinusitis with polyposis.

**Cyclic vomiting disorder**

Autonomic nerve dysfunction is common in adult with cyclic vomiting disorder with sympathetic abnormalities dominating, while parasympathetic nerve function appears to be intact (Venkatesan, 2010).

**Yellow nail syndrome**

Yellow nail syndrome is characterised of thickened yellow nail, primary lymphoedema due to lymphatic hypoplasia, chronic cough, pleural effusions, bronchiectasis, and a propensity to develop malignancies. Chronic rhinosinusitis is seen in almost all patients.

**PFAPA syndrome**

"Periodic fever, aphthous stomatitis, pharyngitis and cervical adenitis" syndrome (PFAPA), probably on a genetic basis. This autoinflammatory entity also includes chronic rhinosinusitis.

**Ataxia-Telangiectasia syndrome**

Ataxia-Telangiectasia syndrome is an autosomal recessive disease or sporadic occurring with in immunosystem deficit leading to recurrent or chronic rhinosinusitis.

**Weskit Aldrich syndrome**

Weskit Aldrich syndrome is an X-linked recessive disorder where the patients from early life have eczema, bloody diarrhea and recurrent infections including rhinosinusitis.

**Sarcoidosis**

Sarcoidosis may present with nodules (non-caseating granulomas) in the septum and along the neurovascular bundles and chronic rhinosinusitis though rare, are reported as the initial findings in this systemic disease.

**Wegener's granulomatosis**

Wegener's granulomatosis (WG) is a necrotising granulomatous vasculitis involving the lungs and kidneys. However, the nasal cavity and sinuses are frequently involved and also may be the initial presentation with destruction of the nasal septum and lateral nasal walls accompanied by mucosal inflammation and sclerotic thickening of the paranasal bones. The findings at imaging may mimic postoperative findings and chronic rhinosinusitis.

**Asthma and allergy**

Patients with asthma and allergy commonly show polypoid mucosal thickening of all paranasal sinuses. Due to mucosal thickening also at the level of the mucociliary drainage routes, exacerbation of disease are commonly followed by extensive rhinosinusitis of both

OMC and SER inflammatory patterns. These patients also are more likely to have the sinonasal polyposis inflammatory pattern.

### Gastrointestinal disease

In Crohn's disease and ulcerative colitis sinonasal mucosal thickening is a frequent finding. However, the literature is sparse about the sinonasal manifestations.

### HIV seropositive patients

HIV seropositive patients rarely have rhinosinusitis as a part of the manifestations.

### Cocaine nose

Cocaine nose presents with a hole in the nasal septum. In advanced cases both cartilaginous and bony septum can be eroded with destruction proceeding to the surrounding bones. The imaging findings are similar to Wegener's granulomatosis but the latter usually shows more irregular sclerotic paranasal sinus bones.

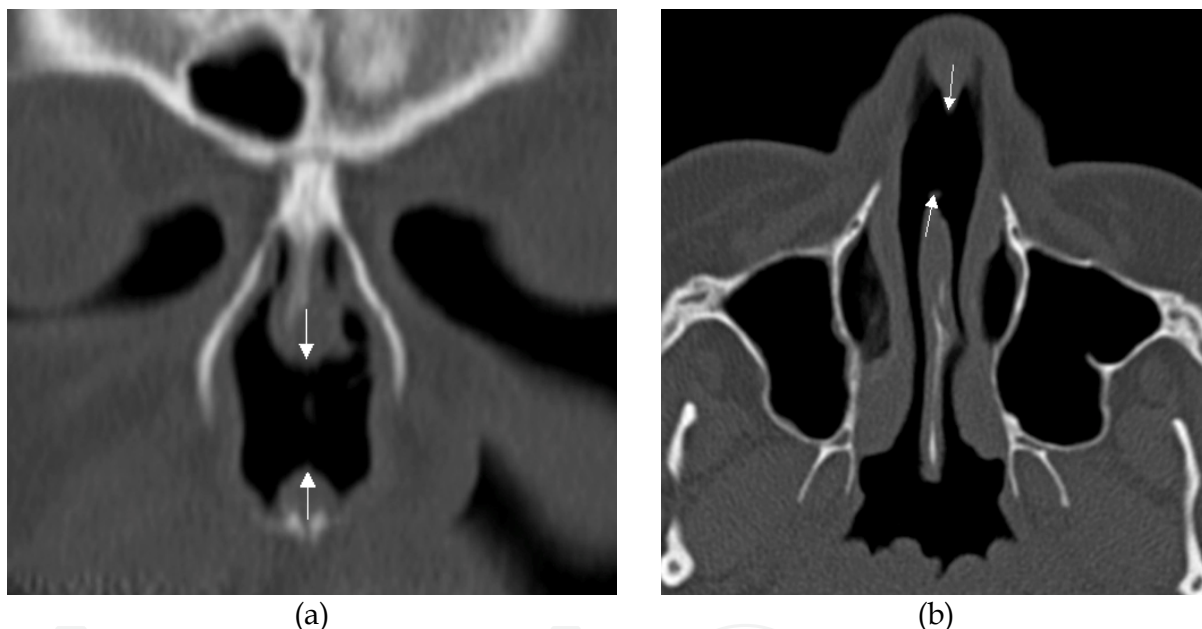


Fig. 19. (a) Coronal and (b) axial CT shows a hole in the anterior nasal septum (arrows) in a patient abusing cocaine.

## 13. Fungal rhinosinusitis

Fungal sinusitis is classified as non-invasive and invasive. The two non-invasive forms are limited within the paranasal sinuses and consist of fungus ball (mycetoma) and allergic fungal sinusitis (AFS). In the invasive forms the fungal hyphae are found in the mucosal lining of the sinuses, in the bone and in the perisinus soft tissue. The three invasive forms are acute, chronic and granulomatous.

A fungus ball presents with foul-smelling nasal discharge. A typical CT finding is advanced unilateral sinus opacification with centrally scattered microcalcifications that are the clue to the correct diagnosis. At MR imaging the fungus ball has low T2 signal due to the microcalcifications, but also due to the paramagnetic properties of iron and manganese in

the fungal hyphae. In response to the fungal hyphae the mucosal lining shows advanced thickening with high T2 signal surrounding the fungus ball.

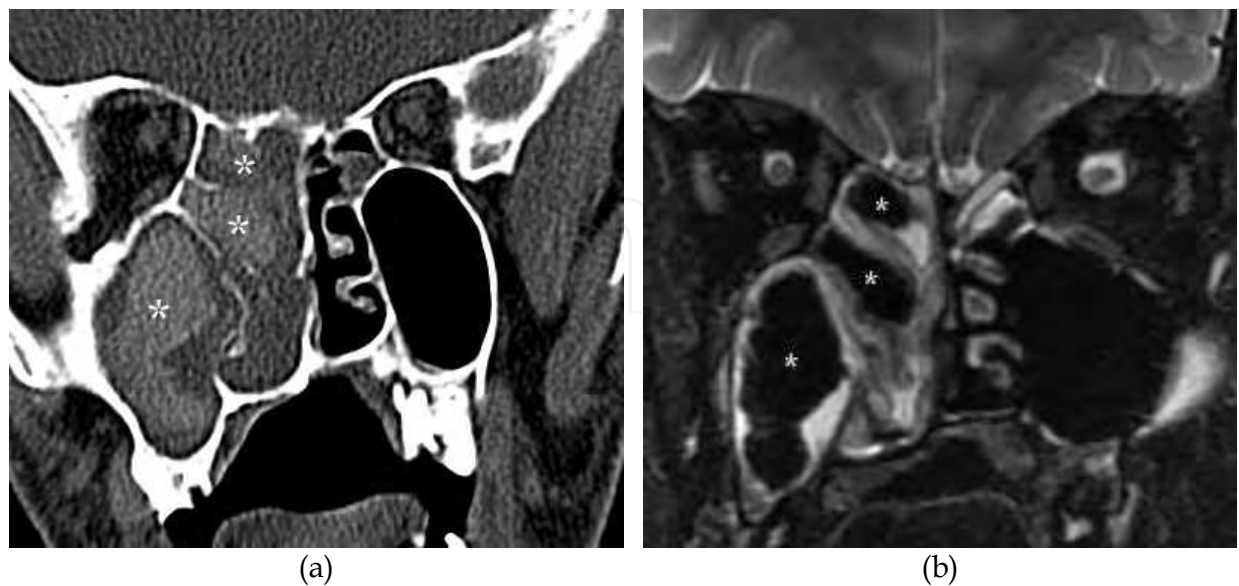

Fig. 20. (a) Coronal CT shows total opacification of ipsilateral maxillary and ethmoid sinuses as well as the nasal cavity. The high density of the opacifications (asterisks) are a typical finding in allergic fungal sinusitis. (b) Coronal MR with STIR sequence shows signal void (asterisks) corresponding to the high density at CT. Courtesy A. ElBeltagi, Kuwait.

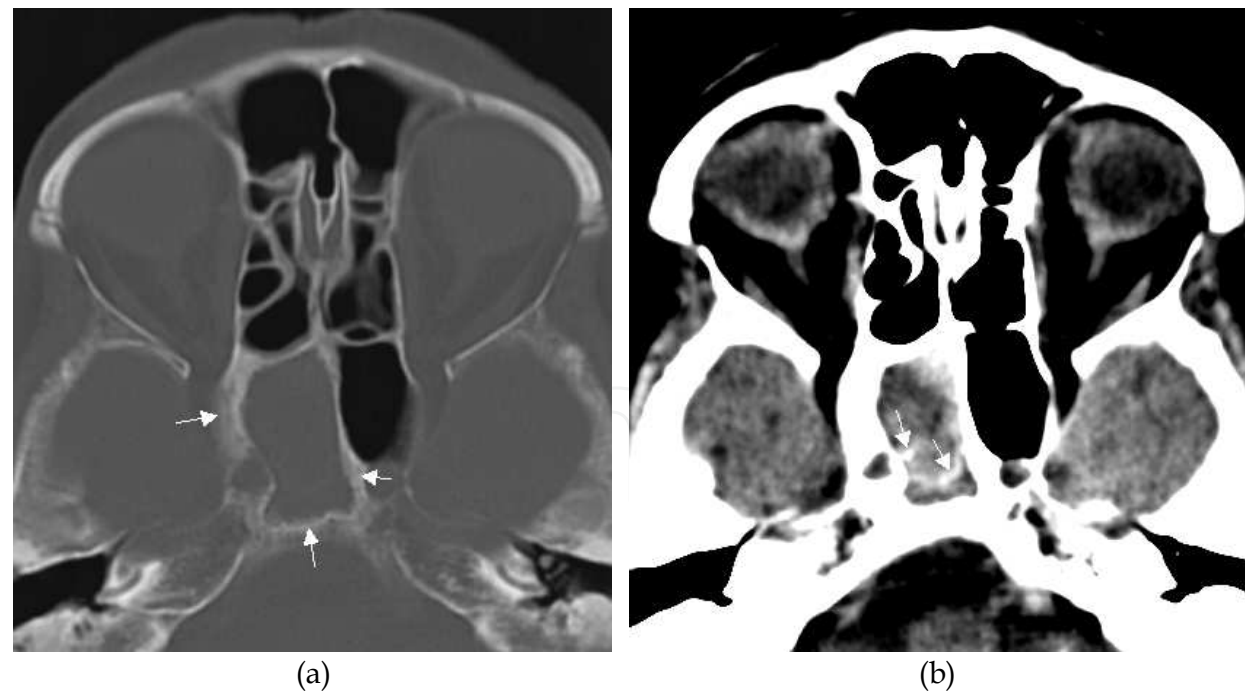


Fig. 21. (a) Axial CT with bone algorithm shows total opacification of the right sphenoid sinus. The surrounding sclerotic bone thickening is equivalent to chronic rhinosinusitis (arrows). (b) Axial CT, with soft tissue algorithm reveals hyperdense calcifications (arrows) highly suspicious of a fungal infection. This was an incidental finding in a patient referred to cerebral CT, and missed initially.

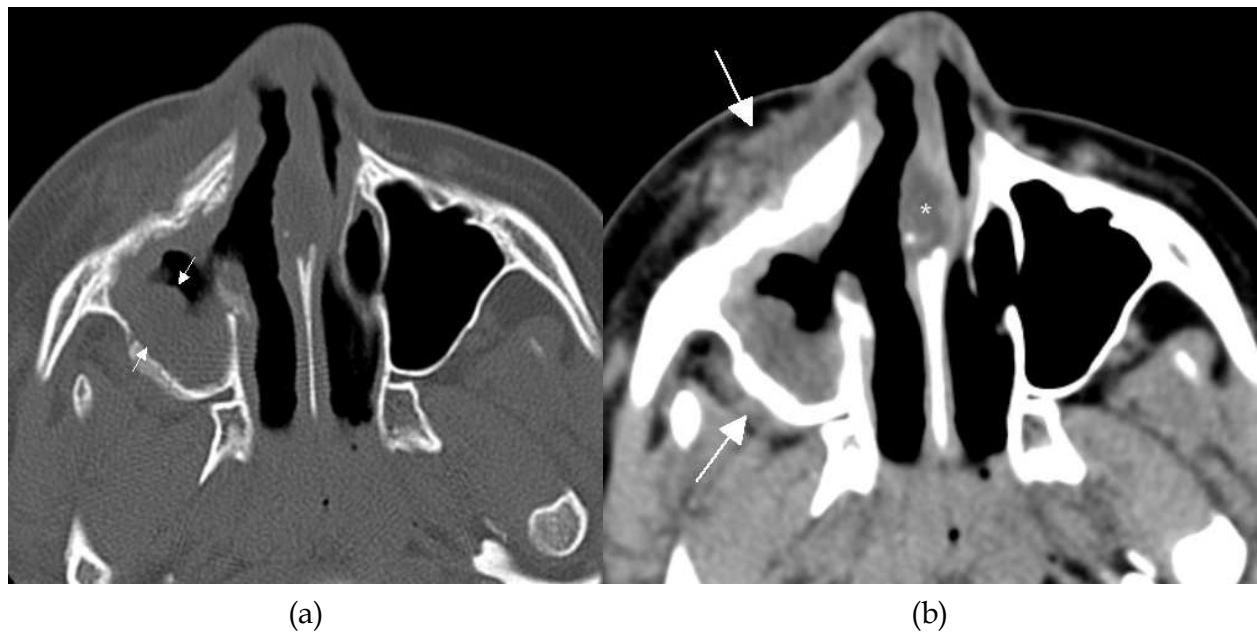


Fig. 22. (a) Axial CT with bone algorithm shows right maxillary sinus with advanced mucosal thickening (arrows) surrounded by sclerotic bone. (b) Axial CT with soft tissue algorithm reveals preantral and postantral soft tissue masses (arrows) due to invasive sinusitis. Notice also the septal thickening referred to as an eschar (asterisk).

Allergic fungal sinusitis is most common in warm and humid areas. The CT findings usually are extensive to all paranasal sinuses, but can also be limited to one sinus. The clue to the diagnosis is hyperdense central fillings surrounded by less dense mucosal thickening. The hyperdense central fillings is due to thick inspissated allergic mucin. At MR, the allergic mucin shows signal void at T2 and high or intermediate signal at T1.

In invasive fungal sinusitis, the acute and chronic form can be differentiated by its presentation. The chronic form can simulate chronic rhinosinusitis, while the acute form presents with rapidly progressive symptoms, while the granulomatous form is rarely seen. The clue to diagnosis of invasive fungal sinusitis is to look for obliteration of the fatty or soft tissue planes outside the sinuses. In invasive fungal sinusitis of the maxillary sinus one should look for preantral and retroantral soft tissue masses. In addition, a nasal septal ulcer may be seen, referred to as an eschar

In case of invasive fungal sinusitis from the sphenoid sinus the orbital apex and cranial nerves may be affected and the patient present with visual disturbances referred to as orbital apex syndrome.

#### 14. Sinonasal tumour

Tumours in the sinonasal cavities can be extremely difficult to discriminate from rhinosinusitis in the early stage. In case of advanced unilateral opacification, bone destruction or bone remodelling, a malign neoplasm must be ruled out with complementary MR imaging. A malignant tumour may present as a single “inflammatory” polyp and therefore all polyps should be considered histopathologic evaluation.

## 15. The radiological report


Every patients referred to imaging may be a candidate for FESS, hence the report should start with developmental, pneumatisation and anatomical variants that may influence on the endoscopic procedure. The next step is to describe the localisation and extent of opacifications and to decide if it fits into one or more of the five inflammatory patterns described. Then most important when the patient has opacifications is to decide whether this is a "simple rhinosinusitis", then if there are complications to the rhinosinusitis, and last to rule out conditions mimicking inflammatory patterns, fungal infection, or tumour. In case of systemic disease, paranasal sinus affection can be sparse or mimic inflammatory disease, hence it is mandatory that the referring clinician includes sufficient information for the radiologist.

## 16. References

- Aalokken, T.M. *et al.* (2003). Conventional sinus radiography compared with CT in the diagnosis of acute sinusitis. *Dentomaxillofac Radiol.* 32, 1, pp 60-2.
- Babbel, R. *et al.* (1991). Optimization of techniques in screening CT of the sinuses. *AJNR Am J Neuroradiol.* 12, 5, pp 849-54.
- Burroughs, J.R. *et al.* (2003). Misdiagnosis of silent sinus syndrome. *Ophthal Plast Reconstr Surg.* 19, 6, pp 449-54.
- Caversaccio, M. *et al.* (2011). Historical review of Haller's cells. *Ann Anat.* 193, 3, pp 185-90.
- Cingi, C. *et al.* (2011). Nasal obstruction as a drug side effect. *Ther Adv Respir Dis.* 5, 3, pp 175-82.
- deShazo, R.D. &S.P. Stringer. (2011). Atrophic rhinosinusitis: progress toward explanation of an unsolved medical mystery. *Current opinion in allergy and clinical immunology.* 11, 1, pp 1-7.
- Eggesbo, H.B. *et al.* (2001a). Complementary role of MR imaging of ethmomaxillary sinus disease depicted at CT in cystic fibrosis. *Acta Radiol.* 42, 2, pp 144-50.
- Eggesbo, H.B. *et al.* (1999). CT and MR imaging of the paranasal sinuses in cystic fibrosis. Correlation with microbiological and histopathological results. *Acta Radiol.* 40, 2, pp 154-62.
- Eggesbo, H.B. *et al.* (2001b). CT characterization of developmental variations of the paranasal sinuses in cystic fibrosis. *Acta Radiol.* 42, 5, pp 482-93.
- Hagtvedt, T. *et al.* (2003). A new low-dose CT examination compared with standard-dose CT in the diagnosis of acute sinusitis. *Eur Radiol.* 13, 5, pp 976-80.
- Lund, V.J. &D.W. Kennedy. (1997). Staging for rhinosinusitis. *Otolaryngol Head Neck Surg.* 117, 3 Pt 2, pp S35-40.
- Ly, T.H. *et al.* (2009). Diagnostic criteria for atrophic rhinosinusitis. *The American journal of medicine.* 122, 8, pp 747-53.
- M Som, P. &H. D Curtin. (2011). Head and Neck Imaging - 2 Volume Set: Expert Consult-Online and Print. pp 3080.
- Naclerio, R.M. *et al.* (2010). Pathophysiology of nasal congestion. *Int J Gen Med.* 3, pp 47-57.
- Rak, K.M. *et al.* (1991). Paranasal sinuses on MR images of the brain: significance of mucosal thickening. *AJR. American journal of roentgenology.* 156, 2, pp 381-4.

- Rosenfeld, R.M. *et al.* (2007). Clinical practice guideline: adult sinusitis. *Otolaryngol Head Neck Surg.* 137, 3 Suppl, pp S1-31.
- Sarin, S. *et al.* (2006). The role of the nervous system in rhinitis. *Journal of Allergy and Clinical Immunology.* 118, 5, pp 999-1014.
- Sonkens, J.W. *et al.* (1991). The impact of screening sinus CT on the planning of functional endoscopic sinus surgery. *Otolaryngol Head Neck Surg.* 105, 6, pp 802-13.
- Soparkar, C.N. *et al.* (1994). The silent sinus syndrome. A cause of spontaneous enophthalmos. *Ophthalmology.* 101, 4, pp 772-8.
- Stammberger, H.R. & D.W. Kennedy. (1995). Paranasal sinuses: anatomic terminology and nomenclature. The Anatomic Terminology Group. *Ann Otol Rhinol Laryngol Suppl.* 167, pp 7-16.
- Venkatesan, T. *et al.* (2010). Autonomic nerve function in adults with cyclic vomiting syndrome: a prospective study. *Neurogastroenterol Motil.* 22, 12, pp 1303-7, e339.
- Yaşar, H. *et al.* (2009). Rhinolithiasis: a retrospective study and review of the literature. *Ear Nose Throat J.* 88, 7, pp E24.
- Zinreich, S.J. (2004). Imaging for staging of rhinosinusitis. *Ann Otol Rhinol Laryngol Suppl.* 193, pp 19-23.
- Zinreich, S.J. *et al.* (1988). MR imaging of normal nasal cycle: comparison with sinus pathology. *J Comput Assist Tomogr.* 12, 6, pp 1014-9.

IntechOpen



## **Peculiar Aspects of Rhinosinusitis**

Edited by Dr. Gian Luigi Marseglia

ISBN 978-953-307-763-5

Hard cover, 112 pages

**Publisher** InTech

**Published online** 23, November, 2011

**Published in print edition** November, 2011

Rhinosinusitis has both a great practical interest and a broad significance due to the scientific complexity of the pathogenetic problems related to the disease, not yet completely resolved, and their implications for clinical treatment. This book highlights certain specific topics that usually are not clarified in other resources. The first chapter is devoted to the impoverished quality of life experienced by patients suffering from rhinosinusitis. The second chapter focuses on the microbiological aspects of rhinosinusitis, while the two subsequent chapters explain the peculiar aspects of chronic rhinosinusitis and of recurrent chronic rhinosinusitis. The first chapter of the second section of the book is dedicated to the imaging techniques used to visualize the nasal sinuses and the other to a medical topical type of treatment.

### **How to reference**

In order to correctly reference this scholarly work, feel free to copy and paste the following:

Heidi Beate Eggesbø (2011). Imaging Rhinosinusitis, Peculiar Aspects of Rhinosinusitis, Dr. Gian Luigi Marseglia (Ed.), ISBN: 978-953-307-763-5, InTech, Available from: <http://www.intechopen.com/books/peculiar-aspects-of-rhinosinusitis/imaging-rhinosinusitis>

**INTech**  
open science | open minds

### **InTech Europe**

University Campus STeP Ri  
Slavka Krautzeka 83/A  
51000 Rijeka, Croatia  
Phone: +385 (51) 770 447  
Fax: +385 (51) 686 166  
[www.intechopen.com](http://www.intechopen.com)

### **InTech China**

Unit 405, Office Block, Hotel Equatorial Shanghai  
No.65, Yan An Road (West), Shanghai, 200040, China  
中国上海市延安西路65号上海国际贵都大饭店办公楼405单元  
Phone: +86-21-62489820  
Fax: +86-21-62489821

© 2011 The Author(s). Licensee IntechOpen. This is an open access article distributed under the terms of the [Creative Commons Attribution 3.0 License](https://creativecommons.org/licenses/by/3.0/), which permits unrestricted use, distribution, and reproduction in any medium, provided the original work is properly cited.

IntechOpen

IntechOpen