

# We are IntechOpen, the world's leading publisher of Open Access books Built by scientists, for scientists

6,900

Open access books available

185,000

International authors and editors

200M

Downloads

Our authors are among the

154

Countries delivered to

TOP 1%

most cited scientists

12.2%

Contributors from top 500 universities



WEB OF SCIENCE™

Selection of our books indexed in the Book Citation Index  
in Web of Science™ Core Collection (BKCI)

Interested in publishing with us?  
Contact [book.department@intechopen.com](mailto:book.department@intechopen.com)

Numbers displayed above are based on latest data collected.  
For more information visit [www.intechopen.com](http://www.intechopen.com)



## Surgical Treatment of Bicuspid Aortic Valve Disease

Ying-Fu Chen<sup>1,3</sup> and Shuo-Tsan Lee<sup>2,3</sup>

<sup>1</sup>*Division of Cardiovascular Surgery, Kaohsiung Medical University Hospital*

<sup>2</sup>*Division of Cardiology, Kaohsiung Medical University Hospital*

<sup>3</sup>*Graduate Institute of Medicine, Kaohsiung Medical University, Kaohsiung Taiwan*

### 1. Introduction

Bicuspid aortic valve (BAV) disease is the most common congenital cardiac abnormality, occurring in 0.5% to 2% of the general population (Ward, 2000; Braverman et al., 2005), and in 0.9% as reported in autopsy studies (Roberts, 1970). It may be sporadic or familial and sporadically transmitted through families by an autosomal dominant pathway with a 4:1 male predominance (Cripe et al., 2004). The BAV may be associated with significant valvular dysfunction (Ward, 2000), will develop aortic stenosis and regurgitation, and will be at risk for infective endocarditis (Braverman et al., 2005; Sabet et al., 1999). The bicuspid valve includes different morphologic phenotypes (Sabet et al., 1999; Fernandes et al., 2004). It usually consists of two cusps unequal in size. The cusps are typically oriented right to left, and the larger cusp has a central raphe or ridge (Sievers & Schmidtke, 2007). Notably, pathologic examination of the raphe could not be demonstrated containing the valve tissue (Pomerance, 1972). A review of the echocardiograms of 1135 children with BAV revealed that the most common morphologic pattern is the fusion of the right and left cusps in 70% of all patients (Fernandes et al., 2004). Sievers & Schmidtke (2007) also reported that 71% of 304 BAV surgical specimens had right and left leaflet fusion. Raphal position was described between the right and left cusps in 86% of cases in surgical pathology study reported by Sabet et al (1999). Previously, much of the original focus centered on the abnormal bicuspid valve. Actually, BAV is not just only a disorder of valvulogenesis, but is also a coexistent genetic disorder of the aorta (Siu & Silversides, 2010). More recent studies have shown that structural abnormalities occur at the cellular level. The structural abnormalities of the thoracic aorta disclose a deficiency of fibrillin-1, increased activity of matrix metalloproteinases (MMPs), elastin fragmentation, and vascular smooth muscles cell (VSMC) apoptosis (Tadros et al., 2009). Genetic studies have reported that BAV is likely due to mutations in different genes with dissimilar patterns of inheritance (Cripe et al., 2004; Siu & Silversides, 2010). Typically, mutation in the *NOTCH1* gene leads to signaling abnormalities, which may be responsible for abnormal development of the aortic valve, and later to accelerated valvular calcium deposition (Garg et al., 2005; Mohamed et al., 2006). In patients with BAV, the presence of BAV is an important risk factor for progressive dilatation of the aortic root and ascending aorta, even in BAV patients with normal valvular function (Nkomo et al., 2003; Gurvitz et al., 2004; Warren et al., 2006). Thus, because of its

frequent association with aortic dilatation, BAV may predispose an individual to aortic dissection or rupture. Based on these findings, valve function as well as the diameter of aortoventricular annulus, sinuses of Valsalva, sinotubular junction, and ascending aorta should be periodically checked (Tadros et al., 2009). In addition, the current American College of Cardiology (ACC)/American Heart Association (AHA) adult congenital heart disease guidelines suggest that echocardiographic screening for BAV in the first-degree relatives of BAV patients is necessary (Warnes et al., 2008).

## **2. Surgical treatment of valve pathology**

Although the clinical presentation of BAV can vary from a benign condition, often undetected throughout life, to severe valve disease in infancy (Fenoglio et al., 1977; Siu & Silversides, 2010), it is typically associated with aortic valve dysfunction in adulthood (Brown et al., 2007; Siu & Silversides, 2010). The common valve dysfunctions include stenosis, regurgitation, and endocarditis. Up to 85% of patients with BAV have aortic stenosis after the fifth decade of life (Sabet et al., 1999; Ashikhmina et al., 2010). In contrast, a pure aortic regurgitation (AR) is less common, develops in approximately 20% of patients with BAV, and usually manifests earlier in life than aortic stenosis (Sabet et al., 1999; Ashikhmina et al., 2010). These patients are typically treated with valvular surgery, often during the third and fourth decade of life (Sabet et al., 1999; Casselman et al., 1999; Ward, 2000; Badiu et al., 2011). Because the population of BAV patients is relatively young, in these young patients the choice of an appropriate heart valve substitute is difficult. The optimal substitute should be durable and have a minimal effect on quality of life and longevity (Schafers et al., 2007; Ashikhmina et al., 2010).

### **2.1 Balloon valvuloplasty**

Percutaneous balloon valvuloplasty was first described in 1983 (Labobidi, 1983), and the effectiveness of this method, as well as the low incidence of restenosis shortly after the procedure, was first documented in children with congenital aortic stenosis (Labobidi et al., 1984) and then in a newborn with critical aortic stenosis (Labobidi & Weinhaus, 1986). During childhood, valve replacement for the stenotic bicuspid valve is suboptimal because of the continuing growth of the child (Siu & Silversides, 2010). Therefore, in the current era, surgical valvotomy has been replaced by balloon valvuloplasty, which has become the procedure of choice in many centers for the treatment of critically ill infants with a severely stenotic aortic valve (Vida et al., 2005) because it has generally been reported to be a relatively low-risk procedure with reasonable short-term results (Mahle et al., 2010). At the University of Padova, (Padua, Italy), critical aortic stenosis in early infancy has been treated routinely with primary balloon valvuloplasty with a low early mortality (2.9%) and a low incidence of complications (2.9%) (Vida et al., 2005). Moreover, valvuloplasty is the interventional strategy of choice in children and in some young adults with BAV and aortic stenosis, because the aortic valve is usually not calcified at this stage and, therefore, the commissural adhesion can be successfully disrupted and the stenotic valve lesion relieved (Siu & Silversides, 2010). Nevertheless, incomplete relief of the valvar stenosis and significant AR are well-documented after percutaneous balloon valvuloplasty (Bacha et al., 2001). Mid-term results have shown a substantial incidence of restenosis, severe AR, and reintervention (Moore et al., 1996). Reich et al. (2004) demonstrated that a small aortic annulus and BAV were independent predictors of an unfavourable outcome. In such a

situation, patients with hypoplastic annuli and functional bicuspid valves may be primarily considered for surgery in order to prevent the risk of aortic regurgitation and the need for valve replacement (Reich et al., 2004).

Actually, any type of treatment for aortic stenosis in newborns and infants is palliative, and future aortic valve replacement is inevitable (Vida et al., 2005). Because the bioprosthetic valve has a high structural failure rate in young patients and mechanical valves have a risk of anticoagulant-related morbidity, the better option of aortic valve substitute in infants and children is the pulmonary autograft because of its potential for growth (Vida et al., 2005; Behery et al., 2009).

## 2.2 Aortic valve replacement

As outlined in the 2006 American College of Cardiology/American Heart Association Guidelines for the Management of Patients With Valvular Heart Disease (Bonow et al., 2006), aortic valve repair involves a lack of uniform applicability and lack of widespread experience with surgical techniques. Moreover, there are no clear indications on when repair should be performed and the regarding data demonstrating its safety and durability are limited (Rao et al., 2000; El Khoury et al., 2006; Aicher et al., 2007; Ashikhmina et al., 2010). In adulthood, the major implication associated with BAV is a tendency toward premature degeneration of the aortic valve with premature presentation of calcific valvular stenosis (Braverman et al., 2005). If aortic valve repair is impossible because of the remarkable structural changes of the aortic valve, the definitive surgical treatment is aortic valve replacement (AVR) (Ali et al., 2010). AVR for aortic valve stenosis is the second most common reason for cardiac surgery in the industrialized countries, and BAV is the second most common cause of aortic valve disease requiring surgery (Etz et al., 2007).

In patients with congenital aortic valve disease such as BAV, Klieverik et al. (2008) reported that the durability of allografts for aortic valve replacement is better than that of bioprostheses, and that their hemodynamic profile is superior to that of mechanical prostheses and bioprostheses. However, the increasing reoperation risk within ten to twenty years remains a major concern. Wijesinghe et al. (2010) proved that transcatheter aortic valve implantation (TAVI) in selected high-risk patients with severe BAV stenosis can be successfully performed with acceptable early clinical outcomes, but that its long-term durability will require further evaluation. On the contrary, Zegdi et al. (2008a) proposed that the valvular opening shape tends to be elliptical rather than circular in patients with BAV; elliptical deployment of valved stents will inevitably create valve distortion that may impede their long-term durability. Thus, BAV stenosis has been considered a questionable indication or even a contraindication for endovascular valve implantation (Zegdi et al., 2008a; Zegdi et al., 2008b).

## 2.3 Ross procedure

Ross (1967) first described replacement of the diseased aortic valve by pulmonary autograft in 1967, and the full root technique with a pulmonary autograft was introduced in 1989 (Stelzer et al., 1989). The Ross operation is an acceptable alternative to conventional aortic valve replacement and has been shown to provide excellent hemodynamic results. The advantages of this therapeutic option are the use of a viable autologous valve and a low incidence of infection and thrombogenicity, avoidance of anticoagulant therapy, as well as its potential to grow in children (Hanke et al., 2007; Brown et al., 2010; Sievers et al., 2010; Ryan et al., 2011). Nevertheless, there is growing concern about autograft failure and

surgical revisions because of the frequently concomitant aortic root and tubular ascending aorta pathology observed in many patients with BAV (Hanke et al., 2010), and the intrinsic abnormalities in the wall of the pulmonary artery based on the common embryological origin of the aortic and pulmonary root, which may contribute to progressive neoaortic root dilatation and AR, or both, when the pulmonary root is placed in the systemic position (David et al., 2000; Siu & Silversides, 2010; Hanke et al., 2010).

Progressive dilatation of the pulmonary autograft with or without regurgitation of the autograft valve is a common indication of reoperation (David et al., 2000; Luciani et al., 2003; Takkenberg et al., 2006; Hanke et al., 2007; Ozaslan et al., 2009; Aljassim et al., 2011). In addition, factors contributing to a limited acceptance are the complexity of the operation and a dearth of long-term clinical information on the durability of the autograft in the aortic position and the durability of the pulmonary conduit substitute (Sievers et al., 2010). This concern has led many to reconsider the indication for the Ross operation in the adult population for whom other surgical options are available (Hanke et al., 2007; David, 2009). There are even some who do not advocate the use of the Ross operation in patients with BAV disease (Siu & Silversides, 2010). Nevertheless, freedom from autograft or pulmonary conduit reoperation was 89% at 10-year follow-ups reported from the German-Dutch Registry (Sievers et al., 2010). They concluded that the autograft procedure is a valuable therapeutic option for treating aortic valve disease (including BAV) in children, adolescents, and young adults (Sievers et al., 2010). Recently, Ryan et al. (2011) reported that freedom from pulmonary autograft reoperation for aortic stenosis patients was 95% at 10 years. They concluded that the Ross procedure in adults provides excellent freedom from autograft failure in patients operated for aortic stenosis. Conversely, the freedom from autograft reoperation rate was 67% at 10 years in patients with AR preoperatively. Thus, the Ross operation provided suboptimal results in patients with aortic insufficiency (David et al., 2010; Ryan et al., 2011). Therefore, other therapeutic alternatives should be strongly considered in adults presenting primarily with aortic insufficiency (Ryan et al., 2011).

Pulmonary autograft dilatation is common after the Ross procedure in adults, and this might be a cause of reoperation (David et al., 2000; Aljassim et al., 2011). Patients with BAV and dilated ascending aortas, or patients with dilated aortic root and primarily AR, have been considered the highest-risk groups for dilatation and neo-aortic valvular regurgitation (Tantengco et al., 1999; Simon-Kupilik et al., 2002; Kouchoukos et al., 2004; Brown et al., 2010). Perhaps the modified Ross procedure, as described by Ungerleider et al., in which the autograft is completely encased in a Dacron graft before implantation, may provide better results in patients with preoperative ascending aortic and sinus dilation. A long-term follow-up for successful valve function will be needed for this technique to be recommended for wider use (Ungerleider et al., 2010).

In summary, although the early outcomes continue to be excellent, follow-ups after more than 10 years show continued deterioration of the autografts and a need for reoperation in a substantial percentage of patients, particularly those in whom the root replacement technique was used. Thus, some investigators suggested that the Ross procedure should not routinely be used for aortic valve replacement in adults (Kouchoukos, 2011).

## 2.4 Repair of regurgitant valve

Clinically, up to 15% to 20% of patients with BAV are reported to have had significant AR as young or middle-aged adults (Roberts, 1970; Olson et al., 1984; Ward, 2000). Although chronic AR is well tolerated for a long time, progressive left ventricular dilatation is a sign



with ominous results if timely intervention is not undertaken (Pretre et al., 2006). This makes the choice of valve substitutes difficult because of the limitations of current prostheses. Mechanical valves have an excellent freedom from reoperation, but the cumulative risk of thromboembolic complications and anticoagulation-related hemorrhage may be substantial due to the long exposure time (Khan, 2002; Salem et al., 2004). The Ross procedure is ideal for young patients with BAV stenosis because of its low operative mortality, excellent hemodynamic performance, low prevalence of infection, avoidance of anticoagulant therapy, and potential to grow in children (El Behery et al., 2009; Takkenberg et al., 2009). However, the presence of preoperative AR and aortic root dilatation are important independent determinants of reoperation for pulmonary autograft failure (Elkins et al., 2008; de Kerchove et al., 2009; Ryan et al., 2011). For these reasons, repairing the BAV is an attractive therapeutic option (Ashikhmina et al., 2010; Boodhwani et al., 2011; Ryan et al., 2011).

Reconstruction of the regurgitant bicuspid valve was proposed as early as 1991 by Cosgrove et al. (1991). Subsequently, others have been able to reproduce reconstructive surgery for regurgitant BAV with good results (Aicher et al., 2004); although some others who used the Cosgrove technique proposed that the intraoperative results were rarely predictable and that there was a high reoperation rate in the early phase (Moidl et al., 1995).

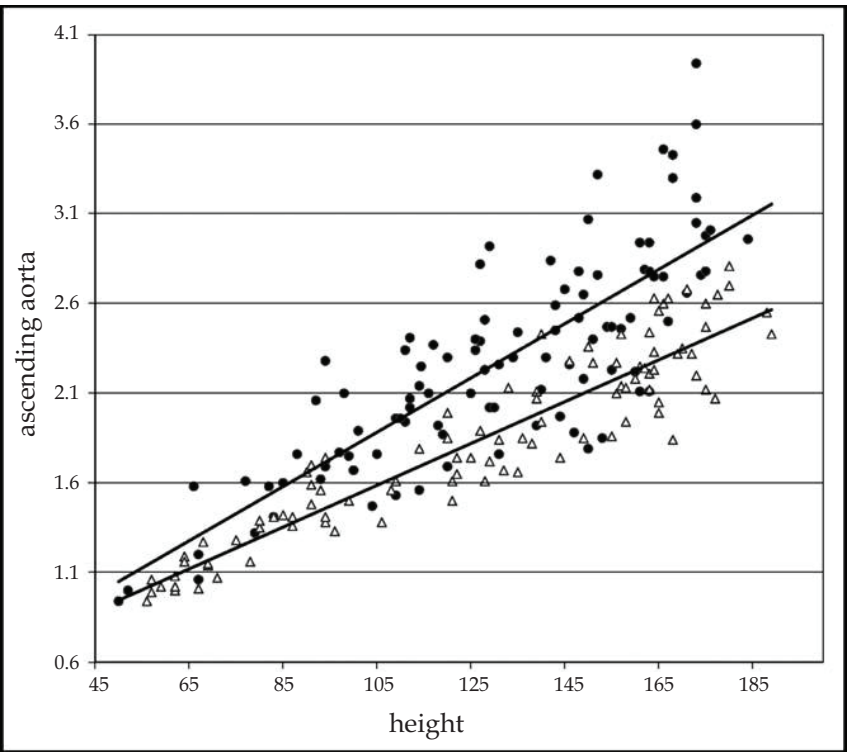
Cusp prolapse may be an isolated cause of AR or may exist in conjunction with dilatation of the proximal aorta. Prolapse can be corrected by central plication, triangular resection, or pericardial patch implantation (Aicher et al., 2007b). In the case of limited cusp prolapse, Aicher et al. (2007b) used plication stitches in the central portion of the free edge of the cusp, which were possibly first used by Spencer et al. (1962). The concept of paracommissural plication has been used in AR with ventricular septal defects (Starr et al., 1960; Garamella et al., 1960). Aicher et al. (2007b) showed that central plication had better valve stability with freedom from recurrent AR and freedom from reoperation at 10 years postoperatively compared with the paracommissural approach. In the presence of a more extensive prolapse, a triangular resection was adopted to avoid excessive bulging of plicated cusp tissue (Aicher et al., 2007b). The reason for their low failure rate may be that they frequently corrected prolapse of both cusps in bicuspid aortic valves. On the other hand, using pericardial patch augmentation to close congenital fenestrations that had led to increase coaptation surface provides reliable early and midterm competence of reconstructed bicuspid aortic valves (Aicher et al., 2007b; Doss et al., 2008).

The systemic segmental approach suggested by Pettersson et al. (2008) is based on echocardiographic evaluation. Their findings emphasized that restrictive cusp motion, due to fibrosis or calcification, is an important predictor for recurrent AR following valve repair. On the contrary, redundant or sufficient cusp tissue offers a greater potential for reparability. Several studies have suggested risk factors for failure of BAV repair. Casselman et al. (1999) described left ventricular dysfunction as a predictor of immediate, persistent regurgitation after valve repair. Nash et al. (2005) reported that the parameters included an eccentric jet of AR, absence of cuspal or commissural thickening, and lack of cusp calcification associated with an increased likelihood of successful valve repair. De Kerchove et al. (2008) suggested that methods of repair of the prolapsed cusp and increased left ventricular end-diastolic diameter were predictors of BAV repair failure. Recently, the size of the aortoventricular junction was also shown to be an independent risk factor for recurrence of regurgitation after repair (Aicher et al., 2011). One should be hesitant to repair a BAV if the aortoventricular diameter is  $\geq 29\text{mm}$ , if commissural orientation is  $< 160^\circ$ , and if a pericardial patch is required for partial cusp replacement (Aicher et al., 2011).

In summary, bicuspid aortic valve repair is a viable alternative to replacement with a bioprosthesis because durability and safety are similar between both surgical management methods for AR. Nevertheless, after initial repair, approximately half of the patients require aortic valve replacement within 10 years (Ashikhmina et al., 2010).

3. Surgical treatment of bicuspid aortic valve with aortopathy

Studies on children (Beroukhim et al., 2006; Warren et al., 2006; Holmes et al., 2007) and adults (Yasuda et al., 2003; Davies et al., 2007; Tadros et al., 2009) have reported significantly faster aortic dilatation in the significantly younger with BAV versus trileaflet aortic valve (Figure). BAV is associated with ascending aortic dilatation and enlargement of the aortic root annulus in as many as half of all individuals (Nkomo et al., 2003; Park et al., 2011). Therefore, the size and shape of the ascending aorta should be serially followed. Measurements of the aortic root dimensions should be performed at the level of the ventriculoaortic diameter, sinuses of Valsalva, sinotubular junction, and proximal ascending aorta (Braverman et al., 2005). Surgery to repair the aortic root or replace the ascending aorta has been recommended for those patients with dilated aortic roots or ascending aortas, with possible early prophylactic surgical intervention to prevent dissection or rupture (Bonow et al., 2008; Tadros et al., 2009).



Reprinted from Beroukhim et al. (2006), with permission from Elsevier. Copyright 2006.

Fig. 1. Measurements of the ascending aorta in centimeters for patients with BAVs (n = 101) and controls (n = 97). The upper slope (*circles*) represents the BAV group, and the lower slope (*triangles*) represents the control group. Regression equations are in the same order ( $y = 0.0151x + 0.2926$ ;  $y = 0.0117x + 0.362$ ). Measurements and height are expressed in centimeters

### 3.1 Valve sparing aortic root replacement

Valve-sparing aortic root replacements are becoming more popular in view of the potential thromboembolic, and infection complications after composite graft replacement (Cozijnsen et al., 2011). Currently, there are two different techniques of valve-sparing root replacement. In the remodeling technique of the aortic root described by Sarsam and Yacoub (1993), the graft is sewn to the remaining aortic wall around the commissures. In the reimplantation technique proposed by David and Feindel (1992), the graft is fixed at the subannular level, and the valve and commissures are reimplanted inside the graft. Both procedures provide an alternative to composite root replacement with excellent short- and medium-term results, but the long-term durability is not yet established (Cozijnsen et al., 2011). Of note, the main limitation of valve-sparing procedures compared with aortic root replacement with a composite graft remains the predominant risk for reoperation on the bicuspid aortic valve due to recurrent regurgitation (Zehr et al., 2004; Badiu et al., 2010). Cattaneo et al. (2004) reported that late results with valve-sparing procedure in children have been compromised by late root dilatation. Kallenbach et al. (2002) reported that some of their patients subsequently required valve replacement after valve-sparing operations because of subsequent increases in AR. On the contrary, Badiu et al. (2010) said that root replacement with aortic valve-sparing should be offered even in the presence of a BAV or severe AR. Aicher et al. (2007a) reported that remodeling of the aortic root can be treated in patients with dilatation of the aortic root and concomitant AR whenever the aortoventricular junction was not dilated. Freedom from reoperation was 96% at 5 and 10 years, and freedom from valve replacement was 98% at 5 and 10 years. Thus, they concluded that root remodeling leads to durable restoration of bicuspid valve function and that the risk of reoperation is low. Therefore, root remodeling is a good option in patients with aortic dilatation and AR undergoing valve-sparing aortic replacement (Aicher et al., 2007a).

Cusp pathology is frequently encountered in patients with supracoronary ascending aortic aneurysm and AR. Severe AR is not a contraindication to valve-sparing surgery, but careful identification and repair of cusp pathology, in addition to sinotubular junction reduction, is critical for durable, long-term outcome (Boodhwani et al., 2011). There is no actual recommendation in the ACC/AHA guidelines for valve-sparing aortic root replacement (Bonow et al., 2006). The guidelines indicate that this may be possible in selected patients for valve-sparing procedures at experienced centers when there is no AR or deformed or calcified aortic valves (Bonow, 2008). Despite reports of good mid-term results with valve-sparing operations (Doss et al., 2010; De Paulis et al., 2010), some experts believe that leaving behind the abnormal BAV is ill-advised. Therefore, the optimal surgical approach for patients with BAV remains to be defined (Siu & Silversides, 2010).

### 3.2 Ascending aorta replacement

It is now widely accepted that an inherent aortopathy exists regardless of whether the valve has any functional abnormalities. Ascending aortic dilatation occurs more frequently and at a younger age in patients with a BAV than in patients with a tricuspid aortic valve (Hahn et al., 1992; Nkomo et al., 2003), and, according to Yasuda et al. (2003), the aorta continues to dilate, even after valve replacement. Because of this, reoperation for aortic aneurysm as well as late aortic dissection and sudden rupture are significantly higher in this group of patients (Russo et al., 2002; Borger et al., 2004). Although the proximal ascending aorta is thought to be the most commonly affected segment (Nkomo et al., 2003; Alegret et al., 2003; Westhoff-Bleck et al., 2005; Tadros et al., 2009; Biner et al., 2009), recent computed tomographic



angiography or magnetic resonance angiography and echocardiography studies of the thoracic aorta morphology in patients with BAV show more diffuse and distinct patterns of aortopathy extending from the aortic root to the proximal aortic arch (Westhoff-Bleck et al., 2005; Fazel et al., 2008; Nazer et al., 2010).

The two main theories explaining the phenomenon of aortopathy in patients with BAV are: (1) the genetic theory, and (2) the hemodynamic theory. Both genetic and hemodynamic causes of aortic pathology associated BAV have been postulated, and there is still a great deal of controversy about the pathogenesis of the dilatation of the ascending aorta. Given the marked heterogeneity of BAV disease, further studies are required in order to more accurately determine which theory is the correct one for explaining BAV-derived aortopathy (Bonow et al., 2008; Tadros et al., 2009; Girdauskas et al., 2011).

Looking at the time of rupture or dissection on a lifetime basis, it can be seen that there are sharp hinge points when the ascending aorta reaches 6 cm in diameter (i.e., the patient has incurred a 34% risk of rupture or dissection) (Elefteriades & Farkas, 2010). The mortality rate for elective surgical correction of ascending aortic aneurysm in an experienced center is 2.5% to 5.0% (Elefteriades, 2002; Isselbacher, 2005; Tadros et al., 2009). Ascending aortic aneurysms with an annual risk of rupture or dissection higher than the combined risks of perioperative mortality should be repaired electively (Tadros et al., 2009). These data permit evidence-based criteria for surgical intervention. Because rupture or dissection occurs at 6 cm or more, most adverse events can be prevented by operating at a criterion of less than 6 cm (Elefteriades, 2010). Therefore, for idiopathic ascending aortic aneurysms, surgical intervention at up to 5.5 cm has been recommended on the basis. In contrast, to accommodate differences in body size for optimal operative decision making, Elefteriades (2002) proposed using the aortic size indexed to body mass, rather than using absolute aortic dimensions to predict risk. In other words, adults with small body size should undergo earlier intervention because a higher ratio of aortic size to body size is a predictor of increased risk (Svensson & Khitin, 2002; Svensson et al., 2003; Davies et al., 2006; Tadros et al., 2009). The risk of rupture, dissection, or death is high (approximately 20% per year) when the aortic size index is above 4.25 cm/m<sup>2</sup> (Davies et al., 2006). However, an aorta less than 5 cm in diameter does not guarantee freedom from aortic complications. Autopsies and clinical studies have shown that aortic dissection certainly occurs in near-normal-sized aortas that do not fall within current guidelines for elective aneurysm surgery (Neri et al., 2005; Pape et al., 2007; Bajona et al., 2010).

Between 2006 and 2008, 3 guidelines that focused on advice for patients with a dilating ascending aorta in combination with BAV or AR were published: (1) the 2006 ACC/AHA guidelines for the management of valvular heart disease (Bonow et al., 2006); (2) the 2007 European Society of Cardiology (ESC) guidelines on the management of valvular heart disease (Vahanian et al., 2007); and (3) the 2008 ACC/AHA guidelines for managing adults with congenital heart disease (Warnes et al., 2008). All give practically the same recommendations as the following guidelines.

Management Guidelines for Patients with Bicuspid Aortic Valve with Dilated Ascending Aorta proposed by the 2008 ACC/AHA guidelines (Bonow et al., 2008).

### **Class I**

1. Patients with known bicuspid aortic valves should undergo an initial transthoracic echocardiogram to assess the diameters of the aortic root and ascending aorta. (Level of Evidence: B)

2. Cardiac magnetic resonance imaging or cardiac computed tomography is indicated in patients with bicuspid aortic valves when morphology of the aortic root or ascending aorta cannot be assessed accurately by echocardiography. (Level of Evidence: C)
3. Patients with bicuspid aortic valves and dilatation of the aortic root or ascending aorta (diameter greater than 4.0 cm\*) should undergo serial evaluation of aortic root/ascending aorta size and morphology by echocardiography, cardiac magnetic resonance, or computed tomography on a yearly basis. (Level of Evidence: C)
4. Surgery to repair the aortic root or replace the ascending aorta is indicated in patients with bicuspid aortic valves if the diameter of the aortic root or ascending aorta is greater than 5.0 cm\* or if the rate of increase in diameter is 0.5 cm per year or more. (Level of evidence: C)
5. In patients with bicuspid valves undergoing AVR because of severe AS or AR repair of the aortic root or replacement of the ascending aorta is indicated if the diameter of the aortic root or ascending aorta is greater than 4.5 cm\*. (Level of evidence: C)

#### Class IIa

6. It is reasonable to give beta-adrenergic blocking agents to patients with bicuspid valves and dilated aortic roots (diameter greater than 4.0 cm\*) who are not candidates for surgical correction and who do not have moderate to severe AR. (Level of Evidence: C)
7. Cardiac magnetic resonance imaging or cardiac computed tomography is reasonable in patients with bicuspid aortic valves when aortic root dilatation is detected by echocardiography to further quantify severity of dilatation and involvement of the ascending aorta. (Level of Evidence: B).

The recent 2010 ACC Foundation/AHA guidelines (Hiratzka et al., 2010) have provided adjusted indications for prophylactic surgery of asymptomatic patients with ascending aortic aneurysm.

#### Class I

Patients with Marfan syndrome or other genetically mediated disorders (vascular Ehlers-Danlos syndrome, Turner syndrome, bicuspid aortic valve, or familial thoracic aortic aneurysm and dissection) should undergo elective operation at smaller diameters (4.0 to 5.0 cm depending on the condition) to avoid acute dissection or rupture. (Level of Evidence: C)

#### Class IIa

Elective aortic replacement is reasonable for patients with Marfan syndrome, other genetic diseases, or bicuspid aortic valves, when the ratio of maximal ascending or aortic root area ( $\pi r^2$ ) in cm<sup>2</sup> divided by the patient's height in meters exceeds 10. (Level of Evidence: C)

More recently, Svensson et al. (2011) proposed that an aortic size larger than 4.5 cm or aortic cross-sectional area/height ratio greater than 8 to 10 should be considered triggers for concurrent aortic repair, because there is no added risk, and late survival is better.

### 3.3 Thoracic endovascular aneurysm repair (TEVAR)

TEVAR is a minimally invasive method for managing descending aortic aneurysms in the acute and chronic settings (Dake et al., 1994; Dake et al., 1999) and is becoming more frequently used (Gopaladas et al., 2010; Coady et al., 2010). TEVAR has been suggested as an

alternative, although controversial, approach for the elderly with comorbidities because of the high risk of open repair (Tadros et al., 2009). Nevertheless, TEVAR is not currently a definitive approach for managing ascending aortic dilatation with BAV because the contour of the ascending aorta is complex and has inadequate landing zones to anchor the stent grafts, especially when dilatation involves the aortic annulus and extends into the arch (Tadros et al., 2009). Whether future developments in these techniques may render them more widely applicable as therapy for ascending aortic aortopathy is still unknown (Atkins et al., 2006; Vallety et al., 2008). On the other hand, the data are limited on TEVAR in patients with connective tissue disease, as well as on continued aortic expansion and higher reintervention rates (Geisbusch et al., 2008). Furthermore, patients with BAV aortopathy typically need intervention at a younger age, and currently TEVAR has not been shown to provide as durable long-term results as does open repair (Tadros et al., 2009).

#### 4. Conclusion

BAV is the most common form of congenital heart defect. Although BAV can be found in isolation because of a disorder of valvulogenesis, it is also represented as coexistent aspects of a genetic disorder of aortopathy, and is most frequently associated with dilatation of the proximal ascending aorta. With or without intervention, patients with BAV require continued surveillance. Because BAV is a disease of both valvular pathology and aortopathy, surgical decision making is more complicated than previously believed. There are several surgical options available to patients with BAV. New surgical techniques have been developed, especially for valve repair and transcatheter aortic valve implantation. The surgical intervention option should be individualized to each patient, depending on the surgical experience and skill of the surgeon. If aortic valve repair for valvular regurgitation or an aortic valve sparing procedure is to be considered, patients should be referred to experienced centers where there is both interest and experience with surgical options available for these patients. Compared with trileaflet aortic valve patients, BAV disease patients have a connective tissue disorder leading to a higher prevalence and faster yearly growth rate of the ascending aorta, which increases the risk of dissection or rupture at a younger age. Thus, ascending aortic dilatation associated with BAV warrants frequent monitoring, with possible early prophylactic intervention to prevent dissection or rupture.

#### 5. References

- Aicher D, Langer F, Kissinger A, Lausberg H, Fries R, & Schafers HJ (2004). Valve-sparing aortic root replacement in bicuspid aortic valve: a reasonable option. *J Thorac Cardiovasc Surg*, Vol 128, No. 5,(November 2004),pp. 662-668, ISSN 0022-5223.
- Aicher D, Langer F, Lausberg H, Bierbach B, & Schafers HJ (2007a). Aortic root remodeling: ten-year experience with 274 patients. *J Thorac Cardiovasc Surg*, Vol 134, No. 4,(October 2007), pp. 909-915, ISSN 0022-5223.
- Aicher D, Langer F, Adam O, Tscholl D, Lausberg H, & Schafers HJ (2007b). Cusp repair in aortic valve reconstruction: does the technique affect stability? *J Thorac Cardiovasc Surg*, Vol 134, No. 6,(December 2007), pp. 1533-1538, ISSN 0022-5223.
- Aicher D, Kuniyara T, Issa OA, Brittner B, Graber S, & Schafers HJ (2011). Valve configuration determines long-term results after repair of the bicuspid aortic valve. *Circulation*, Vol 123, No. 2, (January 2011),pp. 178-185, ISSN 1524-4539.

- Alegret JM, Duran I, Parazon O, Vernis JM, Ameijide A, Rabassa A, & Masana L (2003). Prevalence of and predictors of bicuspid aortic valves in patients with dilated aortic roots. *Am J Cardiol*, Vol 91, No. 5, (March 2003), pp. 619-622, ISSN 0002-9149.
- Ali A, Patel A, Ali ZA, Abu-Omar Y, Freed D, Sheikh AY, Athanasiou T, & Pepper J (2010). Stentless aortic valve replacement in patients with bicuspid aortic valve disease: clinical outcome and aortic diameter changes during follow-up. *Eur J Cardiothorac Surg*, Vol 38, No. 2, (August 2010), pp. 134-140, ISSN 1010-7940.
- Aljassim O, Svensson G, Perrotta S, Jeppsson A, & Bech-Hanssen O (2011). Dilatation of the pulmonary autograft and native aorta after the Ross procedure: a comprehensive echocardiographic study. *J Thorac Cardiovasc Surg*, (In press), ISSN 0022-5223.
- Ashikhmina E, Sundt TM III, Dearani JA, Connolly HM, Li Z, & Schaff HV (2010). Repair of the bicuspid aortic valve: a viable alternative to replacement with a bioprosthesis. *J Thorac Cardiovasc Surg*, Vol 139, No. 6, (June 2010), pp. 1395-1401, ISSN 0022-5223.
- Atkins MD Jr, Black JH 3rd, & Cambria RP (2006). Aortic dissection: perspectives in the era of stent-graft repair. *J Vasc Surg*, Vol 43, No. Suppl A, (February 2006), pp. 30A-43A, ISSN 1097-6809.
- Bacha EA, Satou GM, Moran AM, Zuraakowski D, Marx GR, Keane JF, & Jonas RA (2001). Valve-sparing operation for balloon-induced aortic regurgitation in congenital aortic stenosis. *J Thorac Cardiovasc Surg*, Vol 122, No. 1, (July 2001), pp. 162-168, ISSN 0022-5223.
- Badiu CC, Eichinger W, Bleiziffer S, Hermes G, Hettich I, Krane M, Bauernschmitt R, & Lange R (2010). Should root replacement with aortic valve-sparing be offered to patients with bicuspid valves or severe aortic regurgitation? *Eur J Cardiothorac Surg*, Vol 38, No 5, (November 2010), pp. 515-522, ISSN 1010-7940.
- Badiu CC, Bleiziffer S, Erchinger WB, Zaimova I, Hutter A, Mazzitelli D, Voss B, & Lange R (2011). Are bicuspid aortic valves a limitation for aortic valve repair? *Eur J Cardiothorac Surg* (In Press), ISSN 1010-7940.
- Bajona P, & Feindel CM (2010). Bicuspid-aortic valve surgery: repair or repair or replace? *Curr Opin Cardiol*, Vol 25, No. 2, (March 2010). pp. 119-123, ISSN 0268-4705.
- Behery SE, Rubay J, Sluysmans T, Absil B, & Oaert C (2009). Midterm results of the Ross procedure in a pediatric population: bicuspid aortic valve is not a contraindication. *Pediatr Cardiol*, Vol 30, No. 3, (April 2009), pp. 219-224, ISSN 0172-0643.
- Berouhim RS, Kruzick TL, Taylor AL, Gao D, & Yetman AT (2006). Progression of aortic dilation in children with a functionally normal bicuspid aortic valve. *Am j Cardiol*, Vol 98, No. 6, (September 2006), pp. 828-830, ISSN 0002-9149.
- Biner S, Rafique AM, Ray I, Cuk O, Siegel RJ, & Tolstrup K (2009). Aortopathy is prevalent in relative of bicuspid aortic valve patients. *J Am Coll Cardiol*, Vol 53, No. 24, (June 2009), pp. 2288-2295, ISSN 0735-1097.
- Bonow RO, Carabello BA, Chatterjee K, de Leon AC Jr, Faxon DP, Freed MD, Gaasch WH, Lytle BW, Nishimura RA, O'Gara PT, O'Rourke RA, Otto CM, Shah PM, Shanewise JS, Smith SC Jr, Jacobs AK, Adams CD, Anderson JL, Antman EM, Fuster V, Halperin JL, Hiratzka LF, Hunt SA, Page RL, & Riegel B (2006). ACC/AHA 2006 guidelines for the management of patients with valvular Heart disease: a report of the American College of Cardiology/American Heart Association Task Force on Practice Guidelines (Writing Committee to Revise the 1998 Guidelines for the Management of Patients with Valvular Heart Disease) developed in collaboration



- with the Society of Cardiovascular Anesthesiologists endorsed by the Society for Cardiovascular Angiography and Interventions and the Society of Thoracic Surgeons. *J Am Coll Cardiol*, Vol 48, No. 3, (August 2006), pp. e1-e148, ISSN 0735-1097.
- Bonow RO (2008). Bicuspid aortic valves and dilated aortas: a critical review of the critical review of the ACC/AHA practice guidelines recommendations. *Am J Cardiol*, Vol 107, No. 1, (July 2008), pp. 111-114, ISSN 0002-9149.
- Bonow RO, Carabello BA, Chatterjee K, de Leon AC Jr, Faxon DP, Freed MD, Gaasch WH, Lytle BW, Nishimura RA, O'Gara PT, O'Rourke RA, Otto CM, Shah PM, & Shanewise JS (2008). 2008 Focused Update Incorporated Into the ACC/AHA 2006 Guidelines for the Management of Patients With Valvular Heart Disease. A Report of the American College of Cardiology/American Heart Association Task Force on Practice Guideline (Writing Committee to Revise the 1998 Guidelines for the Management of Patients with Valvular Heart Disease). *Circulation*, Vol 118, No. 15, (October 2008), pp. e523-e661, ISSN 1524-4539.
- Boodhwani M, de Kerchove L, Glineur D, Rubay J, Vanoverschelde JL, Van Dyck M, Noirhomme P, & El Khoury G (2011). Aortic valve repair with ascending aortic aneurysms: associated lesions and adjunctive techniques. *Eur J Cardiothorac Surg* (In press), ISSN 1010-7940.
- Borger MA, Preston M, Ivanov J, Fedak PW, Davierwala P, Armstrong S, & David TE (2004). Should the ascending aorta be replaced more frequently in patients with bicuspid aortic valve disease? *J Thorac Cardiovasc Surg*, Vol 128, No. 5, (November 2004), pp. 677-683, ISSN 0022-5223.
- Braverman AC, Guven H, Beardslee MA, Makan M, Kates AM, & Moon MR (2005). The bicuspid aortic valve. *Curr Probl Cardiol*, Vol 30, No. 9, (September 2005), pp. 470-522, ISSN 0146-2806.
- Brown JW, Ruzmetov M, Rodefeld MD, Mahomed Y, & Turrentine MW. (2007). Incidence of and risk factors for pulmonary autograft dilation after Ross aortic valve replacement. *Ann Thorac Surg*, Vol.83, No. 5, (May 2007), pp. 1781-1817, ISSN 0003-4975.
- Brown JW, Ruzmetov M, Shahriari AP, Rodefeld MD, Mahomed Y, & Turrentine MW (2010). Modification of the Ross aortic valve replacement to prevent autograft dilatation. *Eur J Cardiothorac Surg*, Vol 37, No. 5, (May 2010), pp. 1002-1007, ISSN 1010-7940.
- Casselman FP, Gillinov AM, Akhrass R, Kasirajan V, Blackstone AH, & Cosgrove DM (1999). Intermediate-term durability of bicuspid aortic valve repair for prolapsing leaflet. *Eur J Cardiothorac Surg*. Vol 15, No. 3, (March 1999), pp. 302-308, ISSN 1010-7940.
- Cattaneo SM, Bethea BT, Alejo DE, Spevak PJ, Clauss SB, Dietz HC, Gott VL, & Cameron DE (2004). Surgery for aortic root aneurysms in children: a 21-year experience in 50 patients. *Ann Thorac Surg*, Vol. 77, No. 1, (January 2004), pp. 168-176, ISSN 0003-4975.
- Coady MA, Ikonmidis JS, Cheung AT, Matsumoto AH, Dake MD, Chaikof EL, Cambria RP, Mora-Mangano CT, Sundt TM, Sellke FW, & on behalf of the American Heart Association Council on Cardiovascular Surgery and Anesthesia and Council on Peripheral Vascular Disease (2010). Surgical Management of Descending Thoracic



- Aortic Disease: Open and Endovascular Approaches. A Scientific Statement From the American Heart Association. *Circulation*, Vol 121, No. 25, (January 2010), pp. 2780-2804, ISSN 1524-4539.
- Cosgrove DM, Rosenkranz ER, Hendren WG, Bartlett JC, & Stewart WJ (1991). Valvuloplasty for aortic insufficiency. *J Thorac Cardiovasc Surg*, Vol 102, No. 4, (October, 1999), pp. 571-576, ISSN 0022-5223.
- Cozijnsen L, Braam RL, Waalewijn RA, Schepens MAAM, Loeys BL, van Oosterhout MFM, Barge-Schaapveld DQCM, & Mulder BJM (2011). What is new in dilatation of the ascending aorta? Review of current literature and practical advice for the cardiologist. *Circulation*, Vol 123, No. 8, (March 2011), pp. 924-928, ISSN 1524-4539.
- Cripe L, Andelfinger G, Martin LJ, Shooner K, & Benson DW (2004). Bicuspid aortic valve is heritable. *J Am Coll Cardiol*, Vol 44, No. 1, (July 2004), pp. 138-143, ISSN 0735-1097.
- Dake MD, Miller DC, Semba CP, Mitchell RS, Walker PJ, & Liddell RP (1994). Transluminal placement of endovascular stent-grafts for the treatment of descending thoracic aortic aneurysms. *N Engl J Med*, Vol 331, No. 26, (December 1994), pp. 1729-1734, ISSN 1533-4406.
- Dake D, Kato N, Mitchell RS, Semba CP, Razavi MK, Shimono T, Hirano T, Takeda K, Yada I, & Miller DC (1999). Endovascular stent-graft placement for the treatment of acute aortic dissection. *N Engl J Med*, Vol 340, No. 20, (May 1999), pp. 1546-1552, ISSN 1533-4406.
- David TE, & Feindel CM (1992). An aortic valve-sparing operation for patients with aortic incompetence and aneurysm of the ascending aorta. *J Thorac Cardiovasc Surg*, Vol 103, No. 4, (April 1992), pp. 617-621, ISSN 0022-5223.
- David TE, Omran A, Ivanov J, Armstrong S, de Sa MP, Sonnenberg B, & Webb G, (2000). Dilatation of the pulmonary autograft after the Ross procedure. *J Thorac Cardiovasc Surg*, Vol 119, No. 2, (February 2000), pp. 210-220, ISSN 0022-5223.
- David TE, (2009). Ross procedure at the crossroads. *Circulation*, Vol 119, No. 2, (January 2009), pp. 207-209, ISSN 1524-4539.
- David TE, Woo A, Armstrong S, & Maganti M (2010). When is the Ross operation a good option to treat aortic valve disease? *J Thorac Cardiovasc Surg*, Vol 139, No. 1, (January 2010), pp. 68-75, ISSN 0022-5223.
- Davies RR, Gallo A, Coady MA, Tellides G, Botta DM, Tellides G, Botta DM, Burke B, Coe MP, Kopf GS, & Elefteriades JA (2006). Novel Measurement of relative aortic size predicts rupture of thoracic aortic aneurysms. *Ann Thorac Surg*, Vol 81, No. 1, (January 2006), pp. 169-177, ISSN 0003-4975.
- Davies RR, Kaple RK, Mandapati D, Gallo A, Botha DM Jr, Elefteriades JA, & Coady MA (2007). Natural history of ascending aortic aneurysms in the setting of an unreplaced bicuspid aortic valve. *Ann Thorac Surg*, Vol 83, No. 4, (April 2007), pp. 1338-1344, ISSN 0003-4975.
- De Kerchove L, Glineur D, Poncelet A, Boodhwani M, Rubay J, Dhoore W, Noirhomme P, & El Khoury G (2008). Repair of aortic leaflet prolapse: a ten-year experience. *Eur J Cardiothorac Surg*, Vol 34, No. 4, (October 2008), pp. 785-791, ISSN 1010-7940.
- De Kerchove L, Rubay J, Pasquet A, Poncelet A, Ovaert C, Pirotte M, Buche M, D'Hoore W, Noirhomme P, & El Khoury G (2009). Ross operation in the adult: long-term outcomes after root replacement and inclusion techniques. *Ann Thorac Surg*, Vol 87, No. 1, (January 2009), pp. 95-102, ISSN 0003-4975.

- De Paulis R, Scaffa R, Nardella S, Maselli D, Weltert L, Bertoldo F, Pacini D, Settepani F, Tarelli G, Gallotti R, Di Bartolomeo R, & Chiariello L (2010). Use of the Valsalva graft and long-term follow-up. *J Thorac Cardiovasc Surg*, Vol 140, No. 6S, (December 2010), pp. S23-S27, ISSN 0022-5223.
- Doss M, Sirat S, Risteski P, Martens S, & Moritz A (2008). Pericardial patch augmentation for repair incompetent bicuspid aortic valves at midterm. *Eur J Cardiothorac Surg*, Vol 33, No. 5, (May 2008), pp. 881-884, ISSN 1010-7940.
- Doss M, Risteski P, Sirat S, Bakhtiary F, Martens S, & Moritz A (2010). Aortic root stability in bicuspid aortic valve disease: patch augmentation plus reduction aortoplasty versus modified David type repair. *Eur J Cardiothorac Surg*, Vol 38, No. 5, (November 2010), pp. 523-527, ISSN 1010-7940.
- EI Khoury G, Vanoverschelde JL, Glineur D, Pierard F, Verhelst RR, Rubay J, Funken JC, Watremez C, Astarci P, Lacroix V, Poncelet A, & Noirhomme P (2006). Repair of bicuspid aortic valves in patients with aortic regurgitation. *Circulation*, Vol 114, No. Suppl I, (July 2006), pp. I 610-I 616, ISSN 1524-4539.
- EL Behery, Rubay J, Sluysmans T, Absil B, & Ovaert C (2009). Midterm results of the Ross Procedure in a pediatric population: bicuspid aortic valve is not a contraindication. *Pediatr Cardiol*, Vol 30, No. 3, (April 2009), pp. 219-224, ISSN 0172-0643.
- Elefteriades JA (2002). Natural history of thoracic aortic aneurysms: indications for surgery, and surgical versus nonsurgical risks. *Ann Thorac Surg*, Vol 74, No. 5, (November 2002), pp. S1877-S1880.
- Elefteriades JA, & Farkas E (2010). Thoracic aortic aneurysm: clinically pertinent controversies and uncertainties. *J Am Coll Cardiol*, Vol 55, No. 9, (March 2010), pp. 841-857, ISSN 0735-1097.
- Elkins RC, Thompson DM, Lane MM, Elkin CC, & Peyton MD (2008). Ross operation: 16-year experience. *J Thorac Cardiovasc Surg*, Vol 136, No. 3, (September 2008), pp. 623-630, ISSN 0022-5223.
- Etz C, Homann TM, Silovitz D, Spielvogel D, Bodian CA, Luehr M, DiLuzzo G, Plestis KA, & Griep RB (2007). Long-term survival after the Bentall procedure in 206 patients with bicuspid aortic valve. *Ann Thorac Surg*, Vol 84, No. 4, (October 2007), pp. 1186-1194, ISSN 0003-4975.
- Fazel SS, Mallidi HR, Lee RS, Sheehan MP, Liang D, Fleischman D, Herfkens R, Mitchell RS, & Miller DC (2008). The aortopathy of bicuspid aortic valve disease has distinctive patterns and usually involves the transverse aortic arch. *J Thorac Cardiovasc Surg*, Vol 135, No. 4, (April 2008), pp. 901-907, ISSN 0022-5223.
- Fenoglio JJ Jr, McAllister HA Jr, DeCastro CM, Davia JE, & Cheitlin MD (1977). Congenital bicuspid aortic valve after age 20. *Am J Cardiol*. Vol.39, No. 2, (February 1977), pp. 164-169, ISSN 0002-9149.
- Fernandes SM, Sanders SP, Khairy P, Jenkins KJ, Gauvreau K, Lang P, Simonds H, & Colan SD (2004). Morphology of bicuspid aortic valve in children and adolescents. *J Am Coll Cardiol*, Vol 44, No. 8, (October 2004), pp. 1648-1651, ISSN 0735-1097.
- Garamella JJ, Cruz AB Jr, Heupel WH, Dahl JC, Jensen NK, & Berman R (1960). Ventricular septal defect with aortic insufficiency. Successful surgical correction of both defects by the transaortic approach. *Am J Cardiol*, Vol 5, No. 2, (February 1960), pp. 266-272. ISSN 0002-9149.

- Garg V, Muth AN, Ransom JF, Schluterman MK, Barnes R, King IN, Grossfeld PD, & Srivastava D (2005). Mutations in NOTCH1 cause aortic valve disease. *Nature*, Vol 437, No. 7056, (September 2005), pp. 270-274, ISSN 0028-0836.
- Geisbusch P, Kotelis D, von Tengg-Kobligk H, Hyhlik-Durr A, Allenberg JR, & Bockler D (2008). Thoracic aortic endografting in patients with connective tissue diseases. *J Endovasc Ther*, Vol 15, No. 2, (April 2008), ISSN 1526-6028.
- Girdauskas E, Borger MA, Secknus MA, Girdauskas G, & Kuntze T (2011). Is aortopathy in bicuspid aortic valve disease a congenital defect or a result of abnormal hemodynamics? A critical reappraisal of a one-sided argument. *Eur J Cardiothorac Surg*, Vol 39, No. 6, (January 2011), pp. 809-814. ISSN 1010-7940.
- Gopaldas RR, Huh J, Dao TK, LeMaire SA, Chu D, Bakaeen FG, & Coselli JS (2010). Superior nationwide outcomes of endovascular versus open repair for isolated descending thoracic aortic aneurysm in 11669 patients *J Thorac Cardiovasc Surg*, Vol 140, No. 5, (November 2010), pp. 1001-1010, ISSN 0022-5223.
- Gurvitz M, Chang RK, Drant S, & Allada V (2004). Frequency of aortic root dilation in children with a bicuspid aortic valve. *Am J Cardiol*, Vol 94, No. 10, (November 2004), pp. 1337-1340, ISSN 0002-9149.
- Hahn RT, Roman MJ, Mogtader AH, & Devereux RB (1992). Association of aortic dilation with regurgitant, stenotic and functionally normal bicuspid aortic valves. *J Am Coll Cardiol*, Vol 19, No. 2, (February 1992), pp. 283-288, ISSN 0735-1097.
- Hanke T, Stierle U, Boehm JO, Botha CA, Bechtel JFM, Erasmi A, Misfeld M, Hemmer W, Rein JG, Robinson DR, Lange R, Horer J, Moritz A, Ozaslan F, Wahlers T, Franke UFW, Hetzer R, Hubler M, Ziemer G, Graf B, Ross DM, Sievers HH, & on behalf of the German Ross Registry (2007). Autograft regurgitation and aortic root dimensions after the Ross procedure: the German Ross Registry Experience. *Circulation*, Vol 116, No. 11 Suppl I, (September 2007), pp. I 251-I 258, ISSN 1524-4539.
- Hanke T, Charitos EI, Stierle U, Robinson DR, Hemmer W, Moritz A, Lange R, Sievers HH, & on behalf of the German Ross Registry (2010). The Ross operation - a feasible and safe option in the setting of a bicuspid aortic valve? *Eur J Cardiothorac Surg*, Vol 38, No. 3, (September 2010), pp. 333-339, ISSN 1010-7940.
- Hiratzka LF, Bakris GL, Beckman JA, Bersin RM, Carr VF, Casey Jr DE, Eagle KA, Hermann LK, Isselbacher EM, Kazerooni EA, Kouchoukos NT, Lytle BW, Milewicz DM, Beich DL, Sen S, Shinn JA, Svensson LG, & Williams DM (2010). 2010 ACCF/AHA/AATS/ACR/ASA/SCAI/SIR/STS/SVM Guidelines for the Diagnosis and Management of Patients with Thoracic Aortic Disease. *J Am Coll Cardiol*, Vol 55, No. 14, (April 2010), pp. e27-e129, ISSN 0735-1097.
- Holmes KW, Lehmann CU, Dalal D, Nasir K, Dietz HC, Ravekes WJ, Thompson WR, & Spevak PJ (2007). Progression dilation of the ascending aorta in children with isolated bicuspid aortic valve. *Am J Cardiol*, Vol 99, No. 7, (April 2007), pp. 978-983, ISSN 0002-9149.
- Isselbacher EM (2005). Thoracic and abdominal aortic aneurysms. *Circulation*, Vol 111, No. 6, (February 2005), pp. 816-828, ISSN 1524-4539.
- Kallenbach K, Hagl C, Walles T, Leyh RG, Pethid K, Haverich K, & Harringer W (2002). Results of a valve-sparing aortic root reconstruction in 158 consecutive patients. *Ann Thorac Surg*, Vol. 74, No. 6, (December 2002), pp. 2026-2032, ISSN 0003-4975.

- Khan S (2002). Long-term outcomes with mechanical and tissue valves. *J Heart Valve Dis*, Vol 11, No. Supple I, (January 2002), pp. I8- I14, ISSN 0966-8519.
- Klieverik LMA, Bekkers JA, Roos JW, Eijkemans MJC, Raap GB, Bogers JJC, & Takkenberg JJM (2008). Autograft or allograft aortic valve replacement in young adult patients with congenital aortic valve disease. *Eur Heart J*, Vol 29, No. 11, (June 2008), pp. 1446-1453, ISSN 0195-668X.
- Kouchoukos NT, Masetti P, Nickerson NJ, Castner CF, Shannon WD, & Davila-Roman VG (2004). The Ross procedure: long-term clinical and echocardiographic follow-up. *Ann Thorac Surg*, Vol 78, No. 3, (September 2004), pp. 773-781, ISSN 0003-4975.
- Kouchoukos NT (2011). Should we still do the Ross operation in adult? *Curr Opin Cardiol*, Vol 26, No. 2, (March 2011), pp. 94-98, ISSN 0268-4705.
- Labobidi Z (1983). Aortic balloon valvuloplasty. *Am Heart J*, Vol 106, No. 4, (October 1983), pp. 751-752, ISSN 0002-8703.
- Labobidi Z, Wu JR, & Walls JT (1984). Percutaneous balloon aortic valvuloplasty: results in 23 patients. *Am J Cardiol*, Vol 53, No. 1, (January 1984), pp. 194-197, ISSN 0002-9149.
- Labobidi Z, & Weinhaus L (1986). Successful balloon valvuloplasty for neonatal critical aortic stenosis. *Am Heart J*. Vol 112, No. 5, (January 1986), pp. 913-916, ISSN 0002-8703.
- Luciani GB, Casali G, Favaro A, Prioli MA, Barozzi L, Santini F, & Mazzucco A (2003). Fate of the aortic root late after the Ross operation. *Circulation*, Vol 108, No. Suppl II, (September 2003), pp. II61-II67, ISSN 1524-4539.
- Mahle WT, Sutherland JL, & Frias PA (2010). Outcome of isolated bicuspid aortic valve in childhood. *J Pediatr*, Vol 157, No. 3, (September 2010), pp. 445-449, ISSN 0022-3476.
- Mohamed SA, Aherrahrou Z, Liptau H, Erasmi AW, Hagemann C, Wrobel S, Borzym K, Schunkert H, Sievers HH, & Erdmann J (2006). Novel missense mutations (p.T596M and p.P1797H) in NOTCH1 in patients with bicuspid aortic valve. *Biochem Biophys Res Commun*, Vol 345, No. 4, (July 2006), pp. 1460-1465, ISSN 0006-291X.
- Moidl R, Moritz A, Simon P, Kupilik N, Wolner E, & Mohl W (1995). Echocardiographic results after repair of incompetent bicuspid aortic valves. *Ann Thorac Surg*, Vol 60, No. 3, (September 1995), pp. 669-672. ISSN 0003-4975.
- Moore P, Egilo E, Mowrey H, Perry SB, Lock JE, & Keane JF (1996). Midterm results of balloon dilation of congenital aortic stenosis: predictors of success. *J Am Coll Cardiol*, Vol 27, No. 5, (April 1996), pp. 1257-1263, ISSN 0735-1097.
- Nash PJ, Vitvitsky E, Li J, Cosgrove DM 3rd, Pettersson G, & Grimm RA (2005). Feasibility of valve repair for regurgitant bicuspid aortic valves: an echocardiographic study. *Ann Thorac Surg*, Vol 79, No. 5, (May 2005), pp. 1473-1479, ISSN 0003-4975.
- Nazer RI, Elhenawy AM, Fazel SS, Garrido-Olivares LE, Armstrong S, & David TE (2010). The influence of operative techniques on the outcomes of bicuspid aortic valve disease and aortic dilatation. *Ann Thorac Surg*, Vol 89, No. 6, (June 2010), pp. 1918-1924, ISSN 0003-4975.
- Neri E, Barabesi L, Buklas D, Vricella LA, Benvenuti A, Tucci E, Sassi C, & Massetti M (2005). Limited role of aortic size in the genesis of acute type A aortic dissection. *Eur J Cardiothorac Surg*, Vol 28, No. 6, (December 2005), pp. 857-863, ISSN 1010-7940.



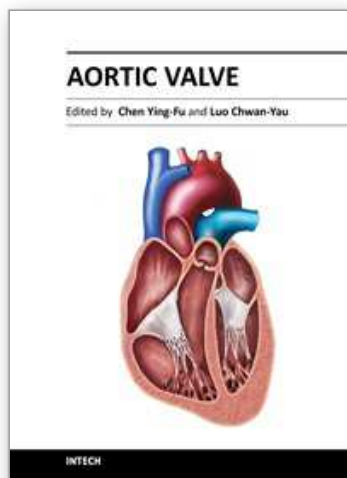
- Nkomo VT, Enriquez-Sarano M, Ammass NM, Melton LJ 3rd, Bailey KR, Desjardins V, Horn RA, & Tajik (2003). Bicuspid aortic valve associated with aortic dilatation: a community-based study. *Arterioscler Thromb Vasc Biol*, Vol 23, No. 4, (February 2003), pp. 351-356, ISSN 1524-4636.
- Olson LJ, Subramanian R, & Edwards WD (1984). Surgical pathology of pure aortic insufficiency: a study of 225 cases. *Mayo Clin Proc*, Vol 59, No. 12, (December 1984), pp. 835-841, ISSN 0025-6196.
- Ozaslan F, Wittlinger T, Monsefi N, Bouhmidi T, Theres S, Doss M, Wimmer-Greinecker G, & Moritz A (2009). Long-term follow-up of supra-annular pulmonary autograft aortic root replacement in patients with bicuspid aortic valve. *Eur J Cardiothorac Surg*, Vol 34, No. 3, (September 2009), pp. 583-588, ISSN 1010-7940.
- Pape LA, Tsai TT, Isselbacher EM, Oh JK, O'Gara PT, Evangelista A, Fattori R, Meinhardt G, Trimarchi S, Bossone E, Suzuki T, Cooper JV, Froehlich JB, Nienaber CA, & Eagle KA (2007). Aortic diameter  $\geq 5.5$  cm is not a good predictor of type A aortic dissection: observations from the International Registry of Acute Aortic Dissection (IRAD). *Circulation*, Vol 116, No. 10, (September 2007), pp. 1120-1127, ISSN 0009-7322.
- Park CB, Greason KL, Suri RM, Michelena HI, Schaff HV, & Sundt TM 3rd (2011). Fate of nonreplaced sinuses of Valsalva in bicuspid aortic valve disease. *J Thorac Cardiovasc Surg*, Vol 142, No.2, (August 2011), pp.278-284, ISSN 0022-5223.
- Pettersson GB, Crucean AC, Savage R, Halley CM, Grimm RA, Svensson LG, Naficy S, Gillinov AM, Feng J, & Blackstone EH (2008). Toward predictable repair of regurgitant aortic valves. A systemic morphology-directed approach to bicommissural repair. *J Am Coll Cardiol*, Vol 52, No. 1, (July 2008), pp. 40-49, ISSN 0735-1097.
- Pomerance A (1972). Pathogenesis of aortic stenosis and its relation to age. *Br Heart J*, Vol 34, No. 6, (June 1972), pp. 569-574, ISSN 0007-0769.
- Pretre R, Kadner A, Dave H, Bettex D, & Genoni M (2006). Tricuspidisation of the aortic valve with creation of a crown-like annulus is able to restore a normal valve function in bicuspid aortic valves. *Eur J Cardiothorac Surg*, Vol 29, No. 6, (June 2006), pp. 1001-1007, ISSN 1010-7940.
- Rao V, van Arsdell GS, David TE, Azakie A, & William WG (2000). Aortic valve repair for adult congenital heart disease: a 22-year experience. *Circulation*, Vol 102 (Suppl 3), No 19, (November 2000), pp.III40-III43, ISSN 1524-4539.
- Reich O, Tax P, Marek J, Gilik J, Tomek V, Chaloupecky V, Bartakova H, & Skovranek J (2004). Long term results of percutaneous balloon valvoplasty of congenital aortic stenosis: independent predictors of outcome. *Heart*, Vol 90, No. 1, (January 2004), pp. 70-76, ISSN 1355-6037.
- Roberts WC (1970). The congenitally bicuspid aortic valve: a study of 85 autopsy cases. *Am J Cardiol*, Vol 26, No. 1, (July 1970), pp. 72-83, ISSN 0002-9149.
- Ross DN (1967). Replacement of aortic and mitral valves with a pulmonary autograft. *Lancet*, Vol 2, No. 7523, (November 1967), pp. 956-958, ISSN 0140-6736.
- Russo CF, Mazzetti S, Garatti A, Ribera E, Milazzo A, Bruschi G, Lanfranconi M, Colombo T, & Vitali E (2002). Aortic complications after bicuspid aortic valve replacement: Long-term results. *Ann Thorac Surg*, Vol 74, No. 5, (November 2002), pp. S1773-S1776, ISSN 0003-4975.



- Ryan WH, Prince SL, Culica D, & Herbert MA (2011). The Ross procedure performed for aortic insufficiency is associated with increased autograft reoperation. *Ann Thorac Surg*, Vol 91, No. 1, (January 2011), pp. 64-70, ISSN 0003-4975.
- Sabet HY, Edwards WD, Tazelaar HD, & Daly RC (1999). Congenitally bicuspid aortic valves: a surgical pathology study of 542 cases (1991 through 1996) and a literature review of 2715 additional cases. *Mayo Clin Proc*, Vol 74, No. 1, (January 1999), pp. 14-26, ISSN 0025-6196.
- Salem DN, Stein PD, Al-Ahmad A, Bussey HI, Horstkotte D, Miller N, & Pauker SG (2004). Antithrombotic therapy in valvular heart disease - native and prosthetic; Seventh ACCP Conference on Antithrombotic and Thrombolytic Therapy. *Chest*, Vol 126, No. 3 Suppl, (September 2004), pp. S457-S482, ISSN 0012-3692.
- Sarsam MA, & Yacoub M (1993). Remodeling of the aortic valve annulus. *J Thorac Cardiovasc Surg*, Vol 105, No. 3, (March 1993), pp. 435-438, ISSN 0022-5223.
- Schafers HJ, Aicher D, Langer F, & Lausberg HF (2007). Preservation of the bicuspid aortic valve. *Ann Thorac Surg*, Vol 83, No. 2, (February 2007), pp. S740-S745, ISSN 0003-4975.
- Sievers HH, & Schmidtke C (2007). A classification system for the bicuspid aortic valve from 304 surgical specimens. *J Thorac Cardiovasc Surg*, Vol 133, No. 5, (May 2007), pp. 1226-1233, ISSN 0022-5223.
- Sievers HH, Stierle U, Charitos EI, Hanke T, Misfeld M, Bechtel M, Gorski A, Franke UFW, Graf B, Robinson DR, Bogers AJJC, Dodge-Khatami A, Boehm JO, Rein JG, Botha CA, Lange R, Hoerer J, Moritz A, Wahlers T, Breuer M, Ferrari-Kuehne K, Hetzer R, Huebner M, Ziemer G, Takkenberg JJM, Hemmer W, & on behalf of the German-Dutch Ross Registry (2010). Major adverse cardiac and cerebrovascular events after the Ross procedure. A report from the German-Dutch Ross Registry. *Circulation*, Vol 122, No. 11 Suppl, (September 2010), pp. S216-S223, ISSN 1524-4539.
- Simon-Kupilik N, Bialy J, Moidl R, Kasimir MT, Mittlbock M, Seebacher G, Wolner E, & Simon P (2002). Dilatation of the autograft root after the Ross operation. *Eur J Cardiothorac Surg*, Vol 21, No. 3, (March 2002), pp. 470-473, ISSN 1010-7940.
- Siu SC, & Silversides CK (2010). Bicuspid aortic valve disease. *J Am Coll Cardiol*, Vol 55, No. 25, (January 2010), pp. 2789-2800, ISSN 0735-1097.
- Spencer FC, Bahnson HT, & Neill CA (1962). The treatment of aortic regurgitation associated with a ventricular septal defect. *J Thorac Cardiovasc Surg*, Vol 43, No. 2, (February 1962), pp. 222-233, ISSN 0022-5223.
- Starr A, Menasche V, & Dotter C (1960). Surgical correction of aortic insufficiency associated with ventricular septal defect. *Surg Gynecol Obstet*, Vol 111, No. 1, (July 1960), pp. 71-76, ISSN 1072-7515.
- Stelzer P, Jones DJ, & Elkins RC (1989). Aortic root replacement with pulmonary autograft. *Circulation*, Vol 80, No. 5 Suppl III, (November 1989), pp. III 209-III 213, ISSN 1524-4539.
- Svensson LG, & Khitin L (2002). Aortic cross-sectional area/height ratio timing of aortic surgery in asymptomatic patients with Marfan syndrome. *J Thorac Cardiovasc Surg*, Vol 123, No. 2, (February 2002), pp. 360-361, ISSN 0022-5223.
- Svensson LG, Kim K-H, Lytle BW, & Cosgrove DM (2003). Relationship of aortic cross-sectional area to height ratio and the risk of aortic dissection in patients with bicuspid aortic valves. *J Thorac Cardiovasc Surg*, Vol 126, No. 3, (September 2003), pp. 892-893, ISSN 0022-5223.

- Svensson LG, Kim KH, Blackstone EH, Rajeswaran J, Gillinov AM, Mihaljevic T, Griffin BP, Grimm R, Stewart WJ, Hammer DF, & Lytle BW (2011). Bicuspid aortic valve surgery with proactive ascending aorta repair. *J Thorac Cardiovasc Surg* Vol 142, No.3, (September 2011), pp.622-629, ISSN 0022-5223.
- Tadros TM, Klein MD, & Shapira OM (2009). Ascending aortic dilatation associated with bicuspid aortic valve: pathophysiology, molecular biology, and clinical implication. *Circulation*, Vol 119, No. 6, (February 2009), pp. 880-890, ISSN 1524-4539.
- Takkenberg JJ, van Herwerden LA, Galema TW, Bekkers JA, Kleyburg-Linkers VE, Eijkemans MJC, & Bogers AJ (2006). Serial echocardiographic assessment of autograft regurgitation and root dimensions after the modified Ross procedure. *J Heart Valve Dis*, Vol 15, No. 1, (January 2006), pp. 100-107, ISSN 0966-8519.
- Takkenberg JJ, Klieverik LM, Schoof PH, van Suylen RJ, van Herwerden LA, Zondervan PE, Ross-Hesselink JW, Eijkemans MJ, Yacoub MH, & Bogers AJ (2009). The Ross procedure: a systemic review and meta-analysis. *Circulation*, Vol 119, No. 2, (January 2009), pp. 222-228, ISSN 1524-4539.
- Tantengco MV, Humes RA, Clapp SK, Lobdell KW, Walters HL 3rd, Hakimi M, & Epstein ML (1999). Aortic root dilation after the Ross procedure. *Am J Cardiol*, Vol 83, No. 6, (March 1999), pp. 915-920, ISSN 0002-9149.
- Urgerleider RM, Ootaki Y, Shen I, & Welke KF (2010). Modified Ross procedure to prevent autograft dilatation. *Ann Thorac Surg*, Vol 90, No. 3, (September 2010), pp. 1035-1037, ISSN 0003-4975.
- Vahanian A, Baumgartner, Baumgartner H, Bax J, Butchart E, Dion R, Filipatos G, Flachskampf F, Hall R, Iung B, Kasprzak J, Nataf P, Tirnos P, Toracca L, & Wenink A (2007). Guidelines on the management of valvular heart disease. *Eur Heart J*, Vol 28, No. 2, (January 2007), pp. 230-268, ISSN 0915-668X.
- Vallely MP, Semsarian C, & Bannon PG (2008). Management of the ascending aorta in patients with bicuspid aortic valve disease. *Heart Lung Circ*, Vol 17, No. 5, (October 2008), pp. 357-363, ISSN 1444-2892.
- Vida VL, Bottio T, Milanesi O, Reffo E, Biffanti R, Bonato R, & Stellin G (2005). Critical aortic stenosis in early infancy: surgical treatment for residual lesions after balloon dilation. *Ann Thorac Surg*. Vol 79, No. 1, (January 2005), pp. 47-51, ISSN 0003-4975.
- Ward C (2000). Clinical significance of the bicuspid aortic valve. *Heart*, Vol 83, No. 1, (January 2000), pp. 81-85, ISSN 1355-6037.
- Warnes CA, Williams RG, Bashore TM, Child JS, Connolly HM, Dearani JA, del Nido P, Fasules JW, Graham TP Jr, Hijazi ZM, Hunt SA, King ME, Landzberg MJ, Miner PD, Radford MJ, Walsh EP, Webb GD, Smith SC Jr, Jacobs AK, Adams CD, Anderson JL, Antman EM, Buller CE, Creager MA, Ettinger SM, Halperin JL, Hunt SA, Krumholz HM, Kushner FG, Lytle BW, Nishimura RA, Page RL, Riegel B, Tarkington LG, Yancy CW; American College of Cardiology; American Heart Association Task Force on Practice Guidelines (Writing Committee to Develop Guidelines on the Management of Adults With Congenital Heart Disease); American Society of Echocardiography; Heart Rhythm Society; International Society for Adult Congenital Heart Disease; Society for Cardiovascular Angiography and Interventions; & Society of Thoracic Surgeons.(2008). ACC/AHA 2008 guidelines for the management of adults with congenital heart disease: a report of the American College of Cardiology/American Heart Association Task

- Force on Practice Guidelines (Writing Committee to Develop Guidelines on the Management of Adults with Congenital Heart Disease) developed in collaboration With the American Society of Echocardiography, Heart Rhythm Society, International Society for Adult Congenital Heart Disease, Society for Cardiovascular Angiography and Interventions, and Society of Thoracic Surgeons. *J Am Coll Cardiol*, Vol. 52, No. 23, (December 2008), pp. e1-e121, ISSN 0735-1097.
- Warren AE, Boyd ML, O'Connell C, & Dodds L (2006). Dilatation of the ascending aorta in paediatric patients with bicuspid aortic valve: frequency, rate of progression and risk factors. *Heart*, Vol 92, No. 10, (October 2006), pp. 1496-1500, ISSN 1355-6037.
- Westhoff-Bleck M, Meyer GP, Lotz J, Tutarel O, Weiss T, Rafflenbeul W, Drexler H, & Schroder E (2005). Dilatation of the entire thoracic aorta in patients with bicuspid aortic valve: a magnetic resonance angiography study. *Vasa*, Vol 34, No. 3, (August 2005), pp. 181-185, ISSN 0000-0000.
- Wijesinghe N, Ye J, Rodes-Cabau J, Cheung A, Velianou JL, Natarajan MK, Dumont E, Nietlispach F, Gurvitch R, Wood DA, Tay E, & Webb JG (2010). Transcatheter aortic valve implantation in patients with bicuspid aortic valve stenosis. *J Am Coll Cardiol Intv*, Vol 3, No. 11, (March 2010), pp. 1122-1125, ISSN 1936-8798.
- Yasuda H, Nakatani S, Stugaard M, Tsujita-Kuroda Y, Bando K, Kobayashi J, Yamagishi M, Kitakaze M, Kitamura S, & Miyatake K (2003). Failure to prevent progressive dilation of ascending aorta by aortic valve replacement in patients with bicuspid aortic valve: comparison with tricuspid aortic valve. *Circulation*, Vol 108, No. Suppl II, (September 2003), pp.II291-II294, ISSN 1524-4539.
- Zegdi R, Khabbaz Z, Ciobotaru V, Noghin M, Deloche A, & Fabiani JN (2008a). Calcific bicuspid aortic stenosis: a questionable indication for endovascular valve implantation? *Ann Throac Surg*, Vol 85, No. 1, (January 2008), pp. 342, ISSN 0003-4975.
- Zegdi R, Ciobotaru V, Noghin M, Sleilaty G, Lafont A, Latremouille C, & Fabiani JN (2008b). Is it reasonable to treat all calcified stenotic aortic valves with a valved stent? *J Am Coll Cardiol*, Vol 51, No. 5, (February 2008), pp. 579-584, ISSN 0735-1097.
- Zehr KJ, Orszulak TA, Mullany CJ, Matloobi A, Daly RC, Dearani JA, Sundt 3rd TM, Puga FJ, Danielson GK, & Schaff RV (2004). Surgery for aneurysms of the aortic root: a 30-year experience. *Circulation*, Vol 110, No. 11, (September 2004), pp. 1364-1371, ISSN 1524-4539.



## **Aortic Valve**

Edited by Prof. Chen Ying-Fu

ISBN 978-953-307-561-7

Hard cover, 350 pages

**Publisher** InTech

**Published online** 09, December, 2011

**Published in print edition** December, 2011

Much has evolved in the field of aortic valve disease because of the increase in knowledge in the last decade, especially in the area of its management. This book "Aortic Valve" is comprised of 18 chapters covering basic science, general consideration of aortic valve disease, infective endocarditis, aortic sclerosis and aortic stenosis, bioprosthetic valve, transcatheter aortic valve implantation and a special section on congenital anomalies of the aortic valve. We hope this book will be particularly useful to cardiologists and cardiovascular surgeons and trainees. We also believe that this book will be a valuable resource for radiologists, pathologists, cardiovascular anesthesiologists, and other healthcare professionals who have a special interest in treating patients with aortic valve disease. We are certain that information in this book will help to provide virtually most new areas of aortic valve disease that will be employed in the current era.

### **How to reference**

In order to correctly reference this scholarly work, feel free to copy and paste the following:

Ying-Fu Chen and Shuo-Tsan Lee (2011). Surgical Treatment of Bicuspid Aortic Valve Disease, Aortic Valve, Prof. Chen Ying-Fu (Ed.), ISBN: 978-953-307-561-7, InTech, Available from:  
<http://www.intechopen.com/books/aortic-valve/surgical-treatment-of-bicuspid-aortic-valve-disease>

**INTech**  
open science | open minds

### **InTech Europe**

University Campus STeP Ri  
Slavka Krautzeka 83/A  
51000 Rijeka, Croatia  
Phone: +385 (51) 770 447  
Fax: +385 (51) 686 166  
[www.intechopen.com](http://www.intechopen.com)

### **InTech China**

Unit 405, Office Block, Hotel Equatorial Shanghai  
No.65, Yan An Road (West), Shanghai, 200040, China  
中国上海市延安西路65号上海国际贵都大饭店办公楼405单元  
Phone: +86-21-62489820  
Fax: +86-21-62489821

© 2011 The Author(s). Licensee IntechOpen. This is an open access article distributed under the terms of the [Creative Commons Attribution 3.0 License](https://creativecommons.org/licenses/by/3.0/), which permits unrestricted use, distribution, and reproduction in any medium, provided the original work is properly cited.

IntechOpen

IntechOpen